

Medical Management of Hepatocellular Carcinoma

Stephen M. Riordan and Roger Williams

1. Introduction

The possibility of effective treatment of hepatocellular carcinoma (HCC), one of the most common cancers worldwide, largely depends on its detection at an early stage before symptoms develop. Screening patients with known cirrhosis, in whom the overall annual incidence of HCC development is of the order of 1–6% (1,2), has the potential to improve the detection rate of such asymptomatic tumors. Such an approach is limited, however, by the fact that cirrhosis is unrecognized prior to presentation with HCC in up to two-thirds of patients in areas with a high incidence of this tumor, such as Asia, and in nearly half of those from low-incidence areas, such as the United Kingdom (3,4). Furthermore, the sensitivity of commonly employed screening tools, such as the serum α -fetoprotein (AFP) level and hepatic ultrasonography, is suboptimal for detecting small tumors (5). In addition, HCC may arise in noncirrhotic patients with chronic hepatitis or carriage of hepatitis B virus in the absence of histological abnormality (6,7). The fibrolamellar variant, which does not produce AFP, also arises in an otherwise normal liver and would not, therefore, be detected by conventional screening programs. Consequently, most patients continue to present with large HCCs that are not amenable to either of the potentially curative surgical options of resection or orthotopic liver transplantation (OLT). Resection is also precluded when lesions, even if small, are sited in an anatomically unsuitable central position or if hepatic functional reserve is considered to be inadequate. In cirrhotic patients, this assessment may be based on a number of parameters, including the residual hepatic volume after planned resection as measured by computerized tomography scanning,

the indocyanine green and bromosulfthalein retention rates, uptake of technetium-99m–diethylenetriaminepentaacetic acid–galactosyl human serum albumin, the serum lecithin aminotransferase level, the Child's class and its individual components, and the hepatic venous pressure gradient (8–12). Of these, a raised preoperative serum bilirubin level and a preoperative hepatic venous pressure gradient > 10 mm Hg are especially important predictors of postoperative hepatic decompensation (10,11). Consideration of Child's class alone is inadequate for selecting patients for hepatic resection, as unresolved deterioration in hepatic function subsequently occurs in more than 50% of Child's A patients (10).

Treatment modalities that have been used in nonsurgical candidates include transcatheter arterial chemoembolization (TACE), percutaneous ethanol injection (PEI), a combination of TACE and PEI, systemic chemotherapy, and hormonal manipulation with antiestrogens, antiandrogens, luteinizing hormone-releasing hormone agonists, and the somatostatin analog, octreotide. Survival comparable to that following surgery has been reported on occasion. Experience with proton irradiation, targeted radiotherapy using ¹³¹I-lipiodol, radio-frequency ablation, interstitial laser photocoagulation, microwave ablation, and cryotherapy is also accumulating. Randomized controlled data allowing a comparison of these medical treatments are limited. Modalities such as immunomodulation, gene therapy, and tumor vaccines are discussed elsewhere in this volume. Although an antitumor effect may be obtained, intervention may not necessarily modify the overall prognosis in Child's C patients, in whom survival is often determined by advanced cirrhosis and its complications rather than progression of the complicating HCC.

2. Transcatheter Arterial Chemoembolization

Transcatheter arterial chemoembolization (TACE) combines targeted chemotherapy with temporary hepatic arterial embolization and is a valid treatment option for patients with HCC confined to the liver, including large or centrally located tumors not amenable to other local treatments. Efficacy of TACE is improved by emulsifying the chemotherapeutic agent(s) with an iodized oil, such as lipiodol (13). The latter prolongs the contact time between anticancer drugs and tumor cells as a consequence of its selective retention by the tumor and by causing temporary sinusoidal embolization. Intra-arterial injection of particulate matter, such as gelfoam, is included in most regimens to further embolize tumor neovascularity. Some protocols additionally incorporate the injection of noradrenaline to constrict normal vasculature and thereby shunt the chemoembolization mixture into the tumor circulation. TACE is generally performed at 6–12 weekly intervals until tumor neovascularity is ablated. Main portal vein occlusion and sepsis are contraindications to TACE.

Many centers also exclude patients with Child's C cirrhosis in view of the possible risk of further hepatic decompensation consequent to transient ischemia of the nontumorous liver. The prevalence of this complication is reduced when gelfoam is not included in the TACE regimen, although the antitumor effect is less (14). Transient fever and right-upper-quadrant pain occur in most patients following the procedure. Uncommon untoward effects include liver abscess, renal failure, and neutropenic sepsis.

Tumor ablation rates following repeated sessions of TACE are substantially higher for HCCs < 4 cm in diameter than for larger tumors, and multivariate analysis has identified tumor size, along with underlying liver function, as an important factor influencing survival following this form of treatment (15,16). In a nonrandomized study, Bronowicki et al. (17) found comparable 5-yr survival rates in patients with small, resectable HCCs treated with TACE, resection, or OLT. Furthermore, the probability of tumor recurrence and/or metastatic dissemination was lower after TACE than following surgery. Similar 1-yr survival to that attained with PEI has similarly been reported in a nonrandomized study (18). Prospective, randomized controlled studies comparing the survival rate following treatment of small HCCs with TACE to those obtained with resection, OLT, PEI, and other modalities discussed later are required. In practice, repeated TACE has predominantly been used to date in patients with large HCCs, not suitable for any of these other treatments. Uncontrolled studies have demonstrated 3-yr survival rates of 13–41% in this setting (19,20). However, two randomized controlled studies comparing TACE using a single chemotherapeutic agent with no treatment have not demonstrated a survival benefit (21,22), at least in part because of instances of treatment-related liver failure masking any possible survival benefit resulting from tumor ablation.

We recently reported our experience with serial, multiagent chemoembolization of HCC using cisplatin, doxorubicin, lipiodol, and gelfoam (23). Most patients were Child–Pugh class B or C and had large, inoperable tumors. Deterioration in Child–Pugh class due to ischemia of nontumorous liver was acceptably low and rarely led to unscheduled hospitalization. Varying degrees of control of tumor neovascularity occurred for a median of 390 d in over 97% of patients. Ablation of tumor neovascularity (**Fig. 1**) was attained in 100% of patients with HCC < 4 cm in diameter and over 33% of those with larger tumors. Significantly more sessions were required to ablate larger tumors. Tumor recurrence in the region of the original lesion was documented in 50% of patients after a median follow-up of 240 d, most often in those with larger initial tumors (**Table 1**). Actuarial survival was 50% at 1 yr and 29% at 2 yr. No long-term survivor was Child–Pugh class C at the outset of treatment.

Limited available data suggests that preoperative TACE to reduce tumor bulk may have a role in improving the postoperative outcome in patients with

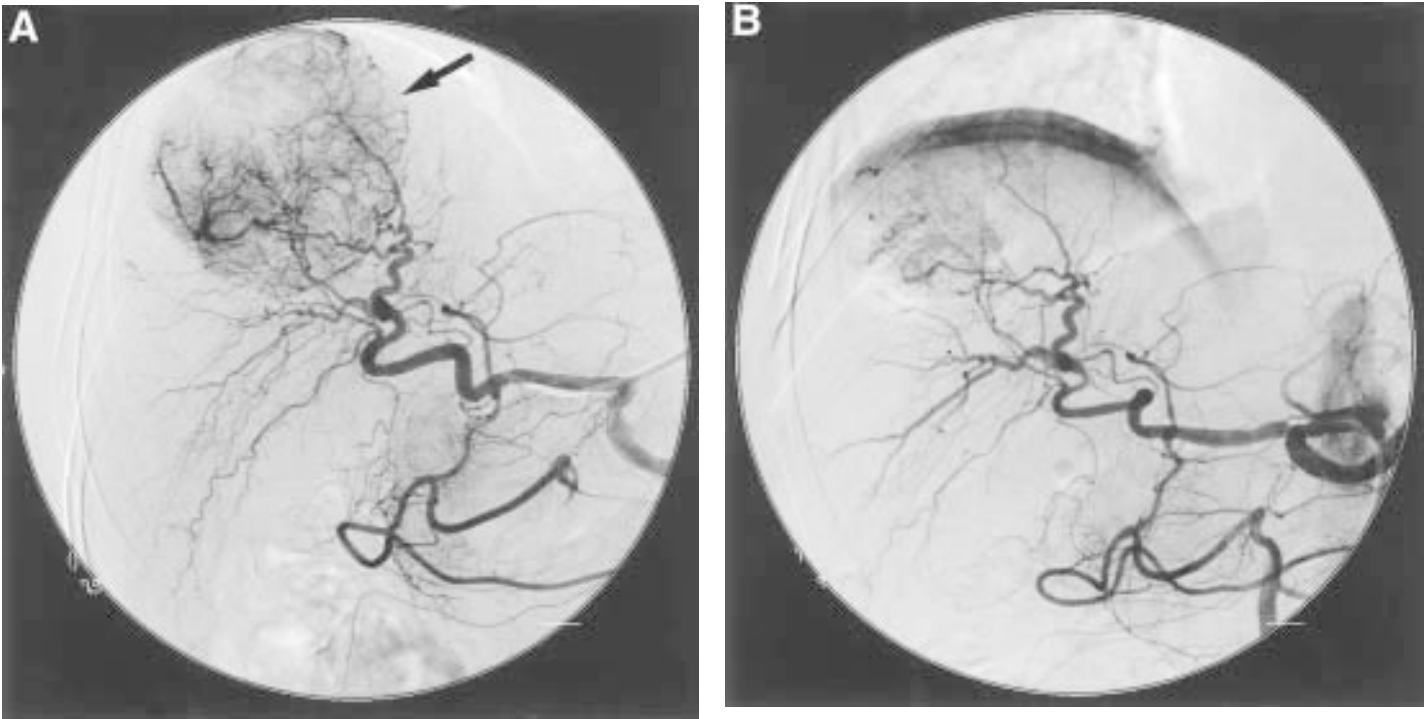


Fig. 1. Serial hepatic arteriography performed in a patient with a large hepatocellular carcinoma (HCC) before (a) and after (b) treatment with transcatheter arterial chemoembolization (TACE), demonstrating substantial reduction in tumor neovascularity (arrow) following treatment. (Reproduced with permission from **ref. 23**.)

Table 1
Rates of Ablation of Tumor Neovascularity with TACE and Recurrent HCC Development in Relation to Size of the Largest Initial HCC Focus

Mean Diameter of Largest HCC Focus (cm)	Ablation of Tumor Neovascularity (%)	Median (Range) TACE Sessions Required for Ablation of Tumor Neovascularity	HCC Recurrence (%)	Time to Detection of HCC Recurrence (d)
< 4	6/6 (100)	3.5 (2-6)	2/6 (33.3)	60, 160
4-7	4/12 (33.3) ^a	5 (4-6)	2/4 (50.0)	120, 360
≥ 8	6/16 (37.5) ^a	6 (4-6) ^b	4/6 (66.7)	90, 210, 240, 240

^a $p < 0.02$ compared to mean diameter of largest HCC focus < 4 cm.

^b $p < 0.05$ compared to mean diameter of largest HCC focus < 4 cm.

Source: Reproduced with permission from **ref. 23**.

HCCs considered borderline for resection, although not all experiences have been favorable (24–26). There is some evidence to suggest that preoperative TACE may significantly prolong the interval between resection and HCC recurrence (27). Literature concerning the possible efficacy of TACE as a means of reducing tumor size to fulfill suitability criteria for OLT is also limited. Although treatment does limit tumor progression in the majority of patients with small HCCs who are awaiting OLT (28), any possible influence on post-OLT tumor recurrence and survival rates has not been adequately assessed.

3. Percutaneous Ethanol Injection

Percutaneous ethanol injection (PEI) of up to 10 mL of absolute alcohol under ultrasound guidance is appropriate in patients with a single HCC focus ≤ 5 cm in diameter or ≤ 3 tumor nodules, each ≤ 3 cm in size, especially if superficially located. The procedure is usually repeated one to three times weekly for several weeks until necrosis of the tumor, as evidenced by a lack of lesion enhancement on contrast-enhanced computerized tomography or magnetic resonance imaging. A single treatment using a larger volume of ethanol is also effective and generally well tolerated. Transient local pain sometimes requiring narcotic analgesia is the most common side effect, even when smaller volumes of ethanol are used. Other complications such as liver abscess, bile duct injury, hemoperitoneum, or chemically induced portal vein thrombosis occur in $< 2\%$ of patients. Rare instances of liver necrosis have also been reported (29,30). The latter have been linked to the possible occlusion of hepatic arterial and portal venous supply resulting from vasculitis induced by ethanol extruded from the lesion (31). As with percutaneous biopsy, needle tract seeding is another potential, though uncommon, complication of PEI (32). Contraindications include ascites and uncorrectable coagulopathy. PEI is not effective against larger tumors, as the texture of the tumor parenchyma and the presence of septa prevent the homogeneous distribution of ethanol within the lesion. PEI is similarly not of value in patients with known extrahepatic dissemination.

Studies by Ebara et al. (33) and Livraghi et al. (34) in patients with favorable tumor characteristics have demonstrated 3-yr survival rates following PEI of up to 79%, depending on the underlying Child's classification. Survival was 0–25% in Child's class C patients (Table 2). Isobe et al. (35) in a nonrandomized comparative study found significantly better survival in patients treated with PEI than in a nontreated control group. In addition, Castells et al. (36) and Kotoh et al. (37) have reported comparable cumulative survival and recurrence rates following PEI and hepatic resection in patients with small HCCs, despite less rigorous patient selection in the PEI group. In view of its lower associated morbidity and cost, PEI is consequently becoming increasingly used as an alternative to hepatic resection in patients with small, resectable HCCs for whom OLT is not available or

Table 2
Survival Rates Following PEI for HCC

HCC Characteristics	Child's Class	3-yr Survival (%)
≤ 3 foci, each ≤ 3 cm diameter (ref. 33)	A	72
	B	72
	C	25
Single focus, ≤ 5 cm diameter (ref. 34)	A	79
	B	63
	C	0
2–3 foci, each ≤ 3 cm diameter (ref. 34)	A	68
	B	59

otherwise contraindicated. However, patients remain predisposed to the development of new HCC foci in the preneoplastic cirrhotic liver. The latter occurs in approximately 50% of patients by 3 yr.

4. Combination TACE and PEI

Combined modality treatment with an initial session of TACE followed after 2 wk by a course of PEI has been proposed for large HCCs, especially when encapsulated, on the basis that complete necrosis of large lesions with TACE alone occurs in approximately 50% or less of cases and that prior TACE would disturb tumor parenchyma and disrupt septa such that ethanol is distributed more evenly throughout large lesions. Two randomized studies performed in patients with HCC > 3 cm in diameter found that tumor ablation rates were substantially higher after combined TACE and PEI treatment than with repeated sessions of TACE alone (**38,39**) (**Table 3**). One-year survival was significantly better in the former group, ranging from 85% to 100% compared to 48–68% in those treated with TACE alone. A recent report of two cases of liver infarction following the PEI component of a combined TACE+PEI regimen, compared with no such instances in 205 patients treated with PEI alone, raises the possibility that this complication may be more prevalent with combination treatment, especially when styrene–maleic acid neocarzinostatin is used for TACE (**40**). Nonetheless, combined TACE and PEI should be considered the treatment of choice at present for patients with large, inoperable HCCs. Conversely, combined TACE and PEI does not improve the efficacy of PEI alone in the treatment of patients with smaller HCCs (**41**).

5. Irradiation

Conventional external beam radiotherapy is not only ineffective against HCC but also may precipitate liver failure as a consequence of radiation

Table 3

Tumor Ablation and Survival Rates Following Treatment with Transcatheter Arterial Chemoembolization Followed by a Course of Percutaneous Ethanol Injection (TACE + PEI) or Repeated Sessions of TACE alone for HCCs > 3 cm in Diameter

Authors (Ref.)	HCC Ablation Rate (%)	
	TACE	TACE + PEI
Bartolozzi et al. (38)	52	85 ^a
Tanaka et al. (39)	20	83

^a $p < 0.05$.

hepatitis. Proton therapy is a relatively new method by which a large amount of radiation can be focused on the lesion, limiting exposure of adjacent nontumorous liver. Matsuzaki et al. (42) applied this technology as monotherapy to 21 patients with HCC and documented at least a 50% reduction in tumor size in the majority of cases. Nonetheless, this therapy is currently limited to only a few centers. Preliminary clinical experience with targeted radiotherapy using intrahepatic arterial injection of lipiodol labeled with iodine-¹³¹I, a β - and γ -emitter that produces a local tumoricidal effect, is also available. In a prospective, randomized trial, tumor size at 2 mo remained static or was partially diminished in 68% of treated patients, comparable to that in those receiving lipiodol-based TACE with epirubicin (43). Actuarial survival rates at 6, 12, and 24 mo were also comparable in the two groups. Large-scale studies to determine the safety and efficacy of these irradiation techniques are awaited.

6. Thermal Modalities

Thermally mediated techniques such as radio-frequency ablation, interstitial laser coagulation, microwave therapy, and cryoablation each induce cell death by coagulative necrosis. Initial clinical experiences with these modalities are, in general, promising. Radio-frequency energy is delivered to the tumor by electrically insulated 14- to 17-gauge needles introduced percutaneously under ultrasound guidance. Radiofrequency ablation of HCCs is achieved in a single session in 85–90% of cases when the tumor is smaller than 5 cm in diameter (44). The rate of local recurrence is less than 10%. Preliminary clinical data in small numbers of patients are also available for interstitial laser coagulation with neodymium–yttrium–aluminum–garnet. Bremer et al. (45) used this modality in two patients with HCCs no larger than 4 cm in diameter, with some evidence of stabilization of tumor size over follow-up of up to 11 mo. Photosensitization with protoporphyrin synthesized from administered δ -aminolevulinic acid followed by laser therapy has recently been shown to have an anti-HCC effect in an

experimental rodent model (46). Whether such therapy will be applicable to human HCC has not yet been addressed. Percutaneous microwave coagulation therapy is associated with tumor ablation or reduction in size in 70% of HCCs ≤ 3 cm in diameter and in 55% of larger lesions (47). Higher response rates have been documented in well-differentiated than in poorly differentiated HCCs. Sato et al. (48) found that this technique can effectively coagulate an area up to 6 cm in diameter in a single session. Use of multiple electrodes may increase applicability to patients with larger tumors. As with PEI, instances of tumor dissemination along the needle tract have been observed (47). Experience with cryotherapy for HCC is limited. In general, this form of therapy must be delivered by ultrasound guidance at laparotomy, thereby limiting its applicability in patients who cannot tolerate general anesthesia because of hepatic decompensation or concurrent medical problems.

7. Hormonal Manipulation

A number of randomized controlled trials have investigated the possible role of treatment with the antiestrogen drug, tamoxifen. Earlier studies performed in relatively small numbers of patients and using varying doses up to 60 mg daily yielded conflicting results (49–52). An Italian study of a large, multicenter cohort of nearly 500 patients randomly allocated to receive 40 mg of tamoxifen daily or no hormonal treatment suggests that tamoxifen has no overall efficacy in prolonging survival in patients with HCC (53). Whether treatment confers any benefit in that subgroup of HCC patients whose tumors express high levels of normally functioning estrogen receptors has not been investigated. Use of luteinizing hormone-releasing hormone analogs and the anti androgens flutamide and nilutamide has no appreciable effect on survival, despite the resultant suppression of sex-hormone synthesis (54–56). Conversely, a recent study performed in a small number of patients with inoperable HCC found that treatment with the somatostatin analog octreotide was associated with improved survival (57). Further studies are required to confirm this finding and to determine the possible mechanism of antineoplastic action.

8. Systemic Chemotherapy

Systemic chemotherapy with a variety of agents, including doxorubicin, epirubicin, mitoxantrone, cisplatin, and etoposide, either alone or in combination, is often used in patients with HCC disseminated beyond the liver, although response rates are generally of the order of only 15%. Furthermore, the value of systemic chemotherapy has never been confirmed in controlled trials. Consequently, this form of treatment has only a limited role in the management of HCC. Recent interest has centered on the possible efficacy of a liposomal doxorubicin preparation preferentially retained by HCC cells and a multicenter trial is currently in progress.

9. Preventive Measures

As the rate of recurrent and, especially, second primary HCC development is high in non-OLT recipients in whom the cirrhotic liver remains *in situ*, despite the apparently successful treatment of the initial tumor, several groups have investigated the possibility of secondary chemoprevention in this group. Muto et al. (58) developed a novel synthetic acyclic retinoid, polyprenoic acid, which binds to the cellular retinoic-binding protein and has been shown to suppress both chemically induced and spontaneous HCC development in rodents (59,60). A placebo-controlled, prospective analysis of 89 patients free of disease after successful treatment of HCC with resection or PEI, predominantly with chronic hepatitis C virus (HCV) infection, demonstrated a threefold reduction in the incidence of recurrent or new tumor development at a median follow-up of 38 mo in the group randomly allocated to receive the retinoid (58). The mechanism of action against human hepatocarcinogenesis *in vivo* remains to be clarified, although the drug has been shown to induce apoptosis in hepatoma cell lines by blocking transforming growth factor- α activity (61). A retrospective study suggests that treatment of patients with chronic HCV infection with interferon- α may also reduce the progression from cirrhosis to HCC by over sixfold (62). Prospective studies are required to confirm this observation. Patients with HCV-related cirrhosis should be encouraged to abstain from alcohol, as HCV and alcohol appear to act synergistically in promoting HCC development. In genetic hemochromatosis, the antineoplastic focus is on early iron chelation therapy in order to prevent the development of cirrhosis.

References

1. Pateron, D., Ganne, N., Trinchet, J. C., Aurousseau, M. H., Mal, F., Meicler, C., et al. (1994) Prospective study of screening for hepatocellular carcinoma in Caucasian patients with cirrhosis. *J. Hepatol.* **20**, 65–71.
2. Zaman, S. N., Melia, W. M., Johnson, R. D., Portmann, B. C., Johnson, P. J., and Williams, R. (1985) Risk factors in development of hepatocellular carcinoma in cirrhosis: prospective study of 613 patients. *Lancet.* **1**, 1357–1360.
3. Lai, C. L., Lam, K. C., Wong, K. P., Wu, P. C., and Todd, D. (1981) Clinical features of hepatocellular carcinoma: review of 211 patients in Hong Kong. *Cancer.* **47**, 2746–2755.
4. Zaman, S. N., Johnson, P. J., and Williams, R. (1990) Silent cirrhosis in patients with hepatocellular carcinoma. *Cancer.* **65**, 1607–1610.
5. The Liver Cancer Study Group of Japan. (1990) Primary liver cancer in Japan, clinicopathologic features and results of surgical treatment. *Ann. Surg.* **211**, 277–287.
6. Kekule, A. S., Lauer, U., Meyer, M., Caselmann, W. H., Hofschneider, P. H., and Koshy, R. (1990) The preS2/S region of integrated hepatitis B virus DNA encodes a transcriptional transactivator. *Nature.* **343**, 457–461.

7. Wang, J., Chenivresse, X., Henglein, B., and Brechot, C. (1990) Hepatitis B virus integration in a cyclin, a gene in a hepatocellular carcinoma. *Nature*. **343**, 555–557.
8. Mizumoto, R. and Noguchi, T. (1992) Hepatic functional reserve and surgical indication in primary liver cancer, in: *Primary Liver Cancer in Japan*. (Tobe, T., Kameda, H., Okudaira, M., Ohto, M., Endo, Y., Mito, M., et al., eds.), Springer–Verlag, Tokyo, pp. 185–197.
9. Nagasue, N., Kohno, H., Chang, Y. C., Taniura, H., Yamanoi, A., Uchida, M., et al. (1993) Liver resection for hepatocellular carcinoma. *Ann. Surg.* **217**, 375–384.
10. Bruix, J., Castells, A., Bosch, J., Feu, F., Fuster, J., Garcia–Pagan, J. C., et al. (1996) Surgical resection of hepatocellular carcinoma in cirrhotic patients: prognostic value of preoperative portal pressure. *Gastroenterology*. **111**, 1018–1023.
11. Sitzmann, J. V. and Greene, P. S. (1994) Perioperative predictors of morbidity following hepatic resection for neoplasm. *Ann. Surg.* **219**, 13–17.
12. Kwon, A. H., Kawa, S., Uetsuji, S., Inoue, T., Matsui, Y., and Kamiyama Y. (1997) Preoperative determination of the surgical procedure for hepatectomy using technetium–99m–galactosyl human serum albumin (^{99m}Tc–GSA) liver scintigraphy. *Hepatology*. **25**, 426–429.
13. Nakao, N., Uchida, H., Kamino, K., Nishimura, Y., Ohishi, H., Takayasu, Y., et al. (1992) Effectiveness of lipiodol in transcatheter arterial embolization of hepatocellular carcinoma. *Cancer Chemother. Pharmacol.* **31**(Suppl), S72–S76.
14. Suzuki, M., Suzuki, H., Yamamoto, T., Mamada, Y., Mizuno, H., Tominaga, T., et al. (1997) Indication of chemoembolization therapy without gelatin sponge for hepatocellular carcinoma. *Semin. Oncol.* **24**, S6–110–S6–115.
15. Sakurai, M., Okamura, J., and Kuroda, C. (1984) Transcatheter chemoembolisation effective for treating hepatocellular carcinoma: a histopathologic study. *Cancer*. **54**, 387–392.
16. Mondazzi, L., Bottelli, R., Brambilla, G., Rampoldi, A., Rezakovic, I., Zavaglia, C., et al. (1994) Transcatheter oily chemoembolisation for the treatment of hepatocellular carcinoma: a multivariate analysis of prognostic factors. *Hepatology*. **19**, 1115–1123.
17. Bronowicki, J. P., Boudjema, K., Chone, L., Nisand, G., Bazin, C., Pflumio, F., et al. (1996) Comparison of resection, liver transplantation and transcatheter oily chemoembolisation in the treatment of hepatocellular carcinoma. *J. Hepatol.* **24**, 293–300.
18. Yamasaki, S., Hasegawa, H., Makuuchi, M., Takayama, T., Kosuge, T., and Shimada, K. (1991) Choice of treatments for small hepatocellular carcinoma: hepatectomy, embolization or ethanol injection. *J. Gastroenterol. Hepatol.* **6**, 408–413.
19. Yamada, R., Kishi, K., Terada, M., Sonomura, T., and Sato, M. (1992) Transcatheter arterial chemoembolization for unresectable hepatocellular carcinoma, in *Primary Liver Cancer in Japan*. (Tobe, T., Kameda, H., Okudaira, M., Ohto, M., Endo, Y., Mito, M., et al. eds.), Springer–Verlag, Tokyo, pp. 259–271.
20. Ikeda, K., Kumada, H., Saitoh, K., Arase, Y., and Chayama, K. (1991) Effect of repeated transcatheter arterial embolization on the survival time in patients with hepatocellular carcinoma: an analysis by the Cox proportional hazard model. *Cancer*. **68**, 2150–2154.

21. Pelletier, G., Roche, A., Ink, O., Anciaux, M., Derhy, S., Rougier, P., et al. (1990) A randomised trial of hepatic arterial chemoembolization in patients with unresectable hepatocellular carcinoma. *J. Hepatol.* **11**, 181–184.
22. Groupe d'Etude et de Traitement du Carcinome Hepatoceleulaire. (1995) Comparison of lipiodol chemoembolization and conservative treatment for unresectable hepatocellular carcinoma. *N. Engl. J. Med.* **332**, 1256–1261.
23. Shah, S. R., Riordan, S. M., Karani, J., and Williams, R. (1998) Tumor ablation and hepatic decompensation rates in multi-agent chemoembolization of hepatocellular carcinoma. *Q. J. Med.* **91**, 821–828.
24. Yu, Y. Q., Xu, D. B., Zhou, X. D., Lu, J. Z., Tang, Z. Y., and Mack, P. (1993) Experience with liver resection after hepatic arterial chemoembolization for hepatocellular carcinoma. *Cancer.* **71**, 62–65.
25. Harada, T., Matsuo, K., Inoue, T., Tamesue, S., Inoue, T., and Nakamura, H. (1996) Is preoperative hepatic arterial chemoembolization safe and effective for hepatocellular carcinoma? *Ann. Surg.* **224**, 4–9.
26. Wu, C., Ho, Y., Linho, W., et al. (1995) Preoperative transcatheter arterial chemoembolization for resectable large hepatocellular carcinoma: a reappraisal. *Br. J. Surg.* **82**, 122–126.
27. Park, J. H., Han, J. K., Chung, J. W., Han, M. C., and Kim, S. T. (1993) Postoperative recurrence of hepatocellular carcinoma: results of transcatheter arterial chemoembolization. *Cardiovasc. Intervent. Radiol.* **16**, 21–24.
28. Duvoux, C., Cherqui, D., Tran Van Nhieu, J., Vavasseur, D., et al. (1994) Chemoembolization for hepatocellular carcinoma in cirrhotic patients: assessment of efficacy on total hepatectomy specimens. *Transplant Proc.* **26**, 4172–4173.
29. Koda, M., Okamoto, M., Miyoshi, Y., and Kawasaki, H. (1992) Hepatic vascular and bile duct injury after ethanol injection therapy for hepatocellular carcinoma. *Gastrointest. Radiol.* **17**, 167–169.
30. Taavitsainen, M., Vehmas, T., and Kaupilla, R. (1993) Fatal liver necrosis following ethanol injection for hepatocellular carcinoma. *Abdom. Imag.* **18**, 357–359.
31. Vehmas, T., Taari, K., Kivisaari, L., Laurila, P., and Taavitsainen, M. (1993) Intra- and peri-hepatic effects of ethanol injections in the pig liver. *Scand. J. Gastroenterol.* **28**, 791–794.
32. Shimada, M., Maeda, T., Saitoh, A., Morotomi, I., and Kano, T. (1995) Needle track seeding after percutaneous ethanol injection therapy for small hepatocellular carcinoma. *J. Surg. Oncol.* **58**, 278–281.
33. Ebara, M., Kita, K., Yoshikawa, M., Sugiura, N., and Ohto, M. (1992) Percutaneous ethanol injection for patients with small hepatocellular carcinoma, in *Primary Liver Cancer in Japan*. (Tobe, T., Kameda, H., Okudaira, M., Ohto, M., Endo, Y., Mito, M., et al., eds.), Springer-Verlag, Tokyo, pp. 291–300.
34. Livraghi, T., Giorgio, A., Marin, G., Salmi, A., de Sio, I., Bolondi, L., et al. (1995) Hepatocellular carcinoma and cirrhosis in 746 patients: long-term results of percutaneous ethanol injection. *Radiology.* **197**, 101–108.
35. Isobe, H., Sakai, H., Imari, Y., Ikeda, M., Shiomichi, S., and Nawata, H. (1994) Intratumor ethanol injection therapy for solitary minute hepatocellular carcinoma. *J. Clin. Gastroenterol.* **18**, 122–126.

36. Castells, A., Bruix, J., Bru, C., Fuster, J., Vilana, R., Navasa, M., et al. (1993) Treatment of small hepatocellular carcinoma in cirrhotic patients: a cohort study comparing surgical resection and percutaneous ethanol injection. *Hepatology*. **18**, 1121–1126.
37. Kotoh, K., Sakai, H., Sakamoto, S., Nakayama, S., Satoh, M., Morotomi, I., et al. (1994) The effect of percutaneous ethanol injection therapy on small solitary hepatocellular carcinoma is comparable to that of hepatectomy. *Am. J. Gastroenterol.* **89**, 194–198.
38. Bartolozzi, C., Lencioni, R., Caramella, D., Vignali, C., Cioni, R., Mazzeo, S., et al. (1995) Treatment of large HCC, transcatheter arterial chemoembolization combined with percutaneous ethanol injection versus repeated transcatheter arterial chemoembolization. *Radiology*. **197**, 812–818.
39. Tanaka, K., Nakamura, S., Numata, K., Okazaki, H., Endo, O., Inoue, S., et al. (1992) Hepatic infarction following percutaneous ethanol injection therapy for hepatocellular carcinoma. *Radiology*. **185**, 457–460.
40. Seki, T., Wakabayashi, M., Nakagawa, T., Imamura, M., Tamai, T., Nishimura, A., et al. (1998) Hepatic infarction following percutaneous ethanol injection for hepatocellular carcinoma. *Eur. J. Gastroenterol. Hepatol.* **10**, 915–918.
41. Shiina, S., Tagawa, K., Unuma, T., Jujino, H., Uta, Y., Niwa, Y., et al. (1990) Percutaneous ethanol injection therapy of hepatocellular carcinoma: analysis of 77 patients. *AJR*. **155**, 1221–1226.
42. Matsuzaki, Y., Osuga, T., Chiba, T., Saito, Y., Tanaka, N., Itai Y., et al. (1995) New, effective treatment using proton irradiation for unresectable hepatocellular carcinoma. *Intern. Med.* **34**, 302–304.
43. Bhattacharya, S., Novell, J. R., Dusheiko, G. M., Hilson, A. J., Dick, R., and Hobbs, K. E. (1995) Epirubicin–lipiodol chemotherapy versus ¹³¹iodine–lipiodol radiotherapy in the treatment of unresectable hepatocellular carcinoma. *Cancer*. **76**, 2202–2210.
44. Solbiati, L. (1998) New applications of ultrasonography: interventional ultrasound. *Eur. J. Radiol.* **27**, S200–S206.
45. Bremer, C., Allkemper, T., Memzel, J., Sulkowski, U., Rummeny, E., and Reimer, P. (1998) Preliminary clinical experience with laser–induced interstitial thermotherapy in patients with hepatocellular carcinoma. *J. Magn. Reson. Imag.* **8**, 235–239.
46. Egger, N. G., Schoenecker, J. A., Gourley, W. K., Motamedi, M., Anderson, K. E., and Weinman, S. A. (1997) Photosensitization of experimental hepatocellular carcinoma with protoporphyrin synthesized from administered delta–aminolevulinic acid: studies with cultured cells and implanted tumors. *J. Hepatol.* **26**, 913–920.
47. Matsukawa, T., Yamashita, Y., Arakawa, A., Nishiهارu, T., Urata, J., Murakami, R., et al. (1997) Percutaneous microwave coagulation therapy in liver tumors. *Acta Radiol.* **38**, 410–415.
48. Sato, M., Watanabe, Y., Kashu, Y., Nakata, T., Hamada, Y., and Kawachi, K. (1998) Sequential percutaneous microwave coagulation therapy for liver tumor. *Am. J. Surg.* **175**, 322–324.

49. Farinati, F., De Maria, N., Fornasiero, A., Salvagnini, M., Fagivoli, S., Chiaramonte, M., et al. (1992) Prospective controlled trial with antiestrogen drug tamoxifen in patients with unresectable hepatocellular carcinoma. *Dig. Dis. Sci.* **37**, 659–662.
50. Castells, A., Bruix, J., Bru, C., Ayuso, C., Roca, M., Boix, L., et al. (1995) Treatment of hepatocellular carcinoma with tamoxifen: a double-blind, placebo-controlled trial in 12 patients. *Gastroenterology*. **109**, 917–922.
51. Elba, S., Giannuzzi, V., Misciagna, G., and Manghisi, O. G. (1994) Randomized controlled trial of tamoxifen versus placebo in inoperable hepatocellular carcinoma. *Ital. J. Gastroenterol.* **26**, 66–68.
52. Martinez-Cerezo, F. J., Tomas, A., Donoso, L., Enriquez, J., Guarner, C., Balanzo, J., et al. (1994) Controlled trial of tamoxifen in patients with advanced hepatocellular carcinoma. *J. Hepatol.* **20**, 702–706.
53. CLIP Group (Cancer of the Liver Italian Programme). (1998) Tamoxifen in treatment of hepatocellular carcinoma: a randomised controlled trial. *Lancet*. **352**, 17–20.
54. Manesis, E. K., Giannoulis, G., Zoumboulis, P., Vafiadou, I., and Hadziyannis, S. J. (1995) Treatment of hepatocellular carcinoma with combined suppression and inhibition of sex hormones, a randomized, controlled trial. *Hepatology*. **21**, 1535–1542.
55. Guehot, J., Peigney, N., Ballet, F., Vaubourdolle, M., Giboudeau, J., and Poupon, R. (1989) Effect of D-triptophan-6-luteinizing hormone-releasing hormone on the tumoral growth and plasma sex steroid levels in cirrhotic patients with hepatocellular carcinoma. *Hepatology*. **10**, 346–348.
56. Bleiberg, H., Grimaldi, C., Gay, F., Messner, M., Rougier, P., Kok, T. C., et al. (1993) Double blind clinical trial of antiandrogen therapy versus placebo in unresectable hepatocellular carcinoma (abstract). *Am. Soc. Clin. Oncol.* **12**, 193.
57. Kouroumalis, E., Skordilis, P., Thermos, K., Vasilaki, A., Moschandrea, J., and Manousos, O. N. (1998) Treatment of hepatocellular carcinoma with octreotide: a randomised controlled study. *Gut*. **42**, 442–447.
58. Muto, Y. M., Moriwaki, H., Ninomiya, M., Adachi, S., Saito, A., Takasaki, K. T., et al. (1996) Prevention of second primary tumors by an acyclic retinoid, polyprenoic acid, in patients with hepatocellular carcinoma. *N. Engl. J. Med.* **34**, 1561–1567.
59. Moriwaka, H., Muto, Y., Ninomiya, M., Kawai, K., Suzuki, Y., and Seto, T. (1988) Inhibitory effects of synthetic acidic retinoid and polyprenoic acid on the development of hepatoma in rats induced by 3'-methyl-N,N-dimethyl-4-aminoazobenzene. *J. Gastroenterol.* **23**, 546–552.
60. Muto, Y., Kawai, K., and Moriwaki, H. (1985) Antitumor activity of a novel synthetic polyprenoic acid (E-5166) on 'spontaneous' hepatic tumors of C3H/HeNCrj mice, in: *Retinoids: New Trends in Research and Therapy*. (Saurat, J. H., ed.), Basel pp. 293–297.
61. Nakamura, N., Shidoji, Y., Yamada, Y., Hatakeyama, H., Moriwaki, H., and Muto, Y. (1995) Induction of apoptosis by acyclic retinoid in the human hepatoma-derived cell line, HuH-7. *Biochem. Biophys. Res. Commun.* **207**, 382–388.
62. International Interferon- α Hepatocellular Carcinoma Study Group. (1998) Effect of interferon- α on progression of cirrhosis to hepatocellular carcinoma: a retrospective cohort study. *Lancet*. **351**, 1535–1539.



<http://www.springer.com/978-0-89603-785-4>

Hepatocellular Carcinoma

Methods and Protocols

Habib, N.A. (Ed.)

2000, XIII, 302 p., Hardcover

ISBN: 978-0-89603-785-4

A product of Humana Press