

CHAPTER 2.1

Arthroscopic Subacromial Decompression: Lateral Approach

John S. Rogerson

Arthroscopic subacromial decompression (ASAD) is becoming a widely performed surgical procedure of the shoulder. The technique has evolved from open anterior acromioplasty as described by Neer,^{1,2} Hawkins et al,^{3,4} Rockwood,⁵ and Bigliani et al.⁶ The transition from open to arthroscopic technique entails a definite learning curve and should not be underestimated. This chapter focuses on the technical aspects of the procedure and how to avoid complications.

HISTORICAL PERSPECTIVE

The arthroscopic technique for subacromial decompression was first described by Johnson⁷ in 1986. Ellman⁸ presented the first series with follow-up and detailed description of the operative technique. Esch et al⁹ evaluated their results with ASAD and related them to the severity of associated rotator cuff tears. Paulos and Franklin¹⁰ presented one of the largest early series (80 patients) and introduced the use of the midlateral subacromial portal.

All of these authors originally described the procedure with the scope viewing from the posterior portal and the instruments entering from a lateral approach.

Sampson et al¹¹ first described the “cutting block” technique for precision acromioplasty in 1991. This technique places the scope laterally and introduces shaving and burring instruments from a posterior portal, using the posterior half of the acromion as a guide for resection. The authors also emphasized the importance of the supraspinatous outlet x-ray in both preoperative planning and postoperative evaluation and the benefits of evaluating the flatness of the cut from both the lateral and the posterior portals.

Many orthopaedists (myself included) who began performing arthroscopic acromioplasty from the originally de-

scribed lateral approach now routinely utilize a technique incorporating the cutting-block principles. There are, however, still a number of cases where the posterior technique as described by Sampson et al will lead to complications, and the lateral approach with modifications is still preferable.

With either approach, the advantages of arthroscopic versus open subacromial decompression are evident and include the following:

1. Less disruption of deltoid insertion and more rapid rehabilitation.
2. Ability to assess both the articular and bursal surfaces of the rotator cuff and fully evaluate the glenohumeral joint for associated pathology.
3. Ease of combining with other arthroscopic techniques (distal clavicle resection and/or rotator cuff debridement or repair).
4. Improved cosmesis.
5. Outpatient setting.

The disadvantages are the significant learning curve and the increased equipment needs of the arthroscopic procedure. Determination of the amount of bone resection, especially with the lateral approach, may be more difficult than with open techniques. Complications, if encountered, may be harder to deal with arthroscopically than with an open procedure.

ETIOLOGY

Impingement is a nonspecific clinical syndrome with a number of different underlying etiologies. Accurate diagnosis is imperative to ensure appropriate nonoperative

or surgical treatment. Patients complaining of pain with overhead activities are differentiated into one of the following categories:

1. Primary impingement
2. Secondary impingement
3. Posterior superior impingement
4. Anterior subcoracoid impingement
5. Pseudoimpingement

Primary Impingement

Neer¹ introduced the concept of extrinsic impingement of the anterior acromion, coracoacromial arch, and the acromioclavicular joint on the underlying rotator cuff and biceps tendon. He also emphasized that forward flexion of the arm is the dominant functional position and that anterior decompression, not lateral acromionectomy, is the appropriate operative approach for significant cuff degeneration. His impingement sign is performed with the patient seated in front of the examiner, who stabilizes the scapula as the arm is elevated slightly lateral to the midline to impinge the tuberosity against the acromion (Fig. 2.1.1). Pain thus produced is eliminated by injecting 10 cc of 1% Xylocaine into the subacromial bursa beneath the anterior acromion (impingement injection test) to confirm the diagnosis. Hawkins and Kennedy⁴ described a second impingement sign in which the arm is flexed forward 90 degrees and then forcibly internally rotated, jamming the supraspinatus tendon against the anterior edge of the coracoacromial ligament to produce pain (Fig. 2.1.2).

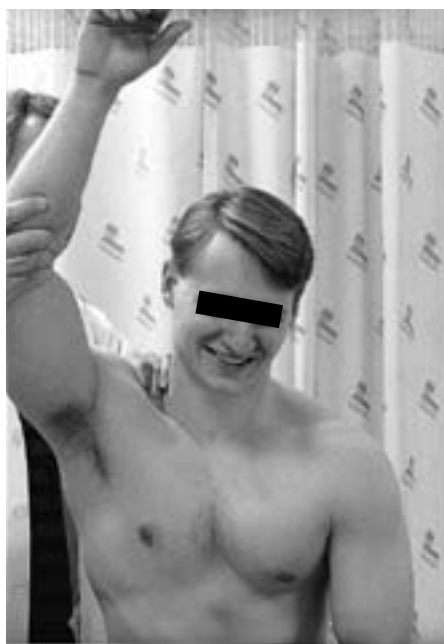

FIGURE 2.1.1. Neer's impingement sign.

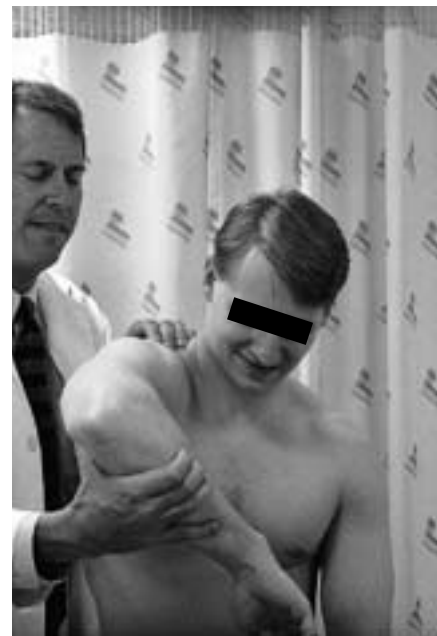

FIGURE 2.1.2. Hawkins's flexion-internal rotation impingement sign.

Patients with primary extrinsic impingement are usually in an older age group or have a bony architecture with an anterior acromial hook or spur that presses directly on the cuff and biceps with forward elevation of the arm. There is also a younger subgroup of overhead athletes who have benign bony anatomy but have a prominent or hypertrophied anterolateral band of the coracoacromial ligament.¹² This produces an extrinsic irritation of the underlying bursa and cuff and occasionally a snap or click. Both of these types of patients have the most predictable operative success with arthroscopic subacromial decompression or coracoacromial ligament resection when conservative treatment has failed.

Secondary Impingement

The concept of secondary impingement originates with Codman,¹³ who proposed an intrinsic tendinous degeneration as the essential lesion in rotator cuff disease. The microvascular studies by Rathbun and McNab,¹⁴ Moseley and Goldie,¹⁵ and Rothman and Parke¹⁶ support this concept. This vascular compromise results in tissue devitalization characterized as "angiofibroblastic hyperplasia" by Nirschl.¹⁷ The subsequent pain and weakness of the supraspinatus compromises its function as a humeral head depressor and allows the upward humeral migration forces of the deltoid to dominate, producing a secondary impingement of the cuff into the acromion.

F. Jobe et al¹⁸ enlarged this concept to include patients with underlying anterior glenohumeral ligament instability. As the humeral head subluxes anteriorly, the

2.1: Arthroscopic Subacromial Decompression: Lateral Approach / 19

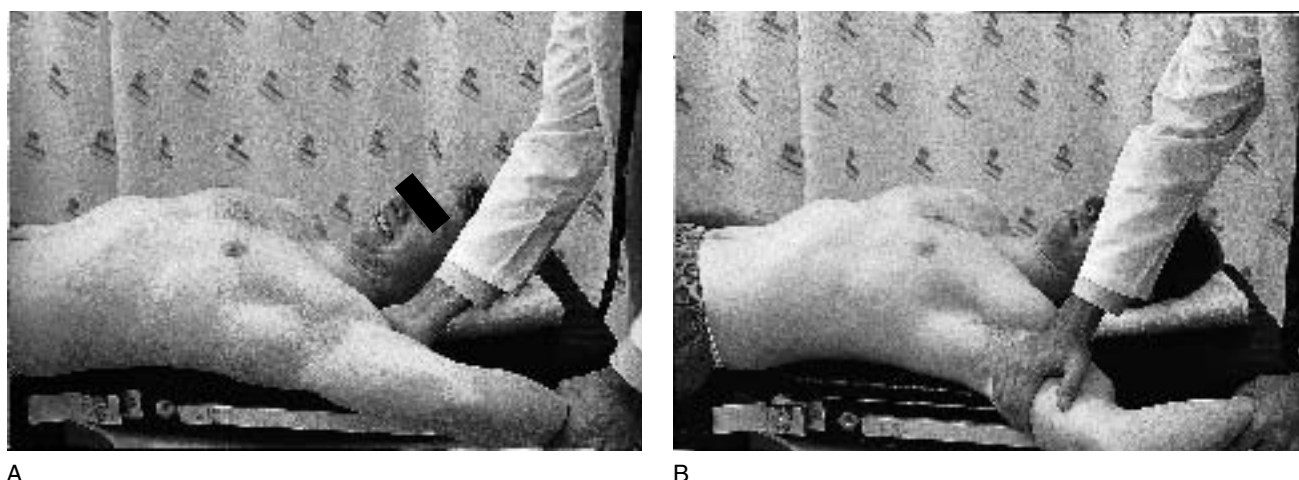


FIGURE 2.1.3. Jobe's subluxation-relocation test. **A:** Subluxation. **B:** Relocation.

cuff is secondarily compressed against the coracoacromial arch.

Secondary impingement is more prevalent in a younger patient population actively involved in sports activities that entail overhead arm motion, and should be suspected when the bony architecture is unremarkable. The subluxation-relocation test, as described by Jobe et al¹⁸ is helpful in differentiating secondary causes of impingement (Fig. 2.1.3). With the arm abducted 90° and externally rotated, an anterior force is applied by the examiner's hand on the posterior aspect of the humeral head. This accentuates the impingement pain in an unstable shoulder as the head and overlying cuff drive into the anterior edge of the acromial arch (*subluxation*). Conversely, posterior pressure on the head alleviates the impingement discomfort (*relocation*).

Posterior Superior Impingement

Walsch et al¹⁹ and C. Jobe²⁰ more recently have described another variety of impingement noted in overhead athletes that occurs when the arm is maximally externally rotated while abducted and extended (such as in the cocking phase of throwing). In this position the posterior superior articular surface fibers of the supraspinatus are placed under tension and shear but are also compressed between the humeral head and adjacent glenoid rim, resulting in posterior superior synovitis and partial undersurface tears. Whether or not any underlying instability is a factor in this compression is still unresolved. While easily confused with primary or secondary anterior impingement, careful examination usually demonstrates pain more at the posterior-superior aspect of the rotator cuff with the arm abducted and externally rotated and extended, in contrast to the impingement positions of Neer and Hawkins. This apprehension position, although painful in this syndrome, does not elicit the usual anxi-

ety found in patients with instability. However, there still may be a reduction of pain with the relocation maneuver of the subluxation-relocation test described by Jobe.

Anterior Subcoracoid Impingement

Gerber et al²¹ have described this type of anterior impingement between the humeral head and the coracoid process secondary to traumatic, iatrogenic, or idiopathic causes. Whatever the underlying etiology, the tip of the coracoid is positioned more lateral than normal, and as the arm is brought into forward flexion there is a compression of the rotator cuff between the humeral head and the tip of the coracoid. This produces pain with Neer's forward flexion test, but it occurs usually between 80 and 130 degrees of flexion rather than at full flexion. Also Hawkins's flexion and internal rotation test is consistently positive, but the pain is lower and more anterior than with superior impingement. The patient also demonstrates decreased horizontal adduction with pain similar to that found with acromioclavicular (AC) disease (Fig. 2.1.4), but the pain is again more at the tip of the coracoid and not at the AC joint.

Pseudoimpingement

Gartsman²² coined the term *pseudoimpingement syndrome* for patients who demonstrated clinical history and physical findings of anterior superior impingement but in whom impingement was due to a lack of full external rotation. This restriction in range of motion does not allow the humerus to rotate externally with elevation, and the rotator cuff is compressed between the greater tuberosity and the acromion when the arm is elevated. This problem is easily confused with primary extrinsic compression but routinely resolves with therapy directed at regaining the lost external rotation.

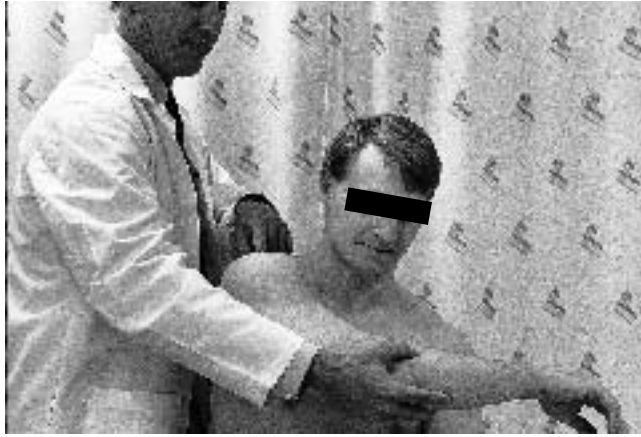

FIGURE 2.1.4. Horizontal adduction test.

ANATOMY

Knowledge of the coracoacromial anatomy is crucial both for diagnostic accuracy and operative facility, and the avoidance of complications.

The bony architecture is composed of the acromion, the AC joint, the coracoid process, and the greater humeral tuberosity. The shape of the acromion and contour of its undersurface is best evaluated with Neer's supraspinatus outlet view (Fig. 2.1.5). Bigliani et al²³ described three distinct acromial shapes: type 1, flat; type 2, curved; and type 3, hooked. They found an increased correlation between the type III hooked acromion and underlying full-thickness rotator cuff tears (69.5% for type 3 and 3% for type 1). This radiographic view is also valuable in determining the overall slope and thickness of the acromion, and in predetermining those cases where the cutting block technique of acromioplasty would be inappropriate.

Rockwood and Lyons²⁴ have described a modified anteroposterior (AP) view of the shoulder for differentiating the hooked acromion. This x-ray involves angulating the beam 30 degrees caudad to accentuate the anterior

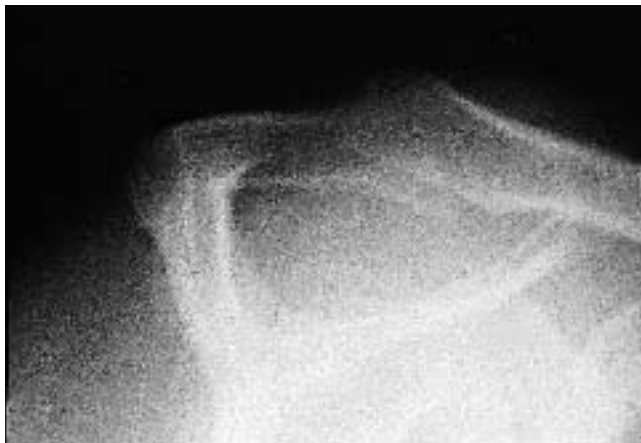

FIGURE 2.1.5. Supraspinatus outlet view (right shoulder, anterior to right).

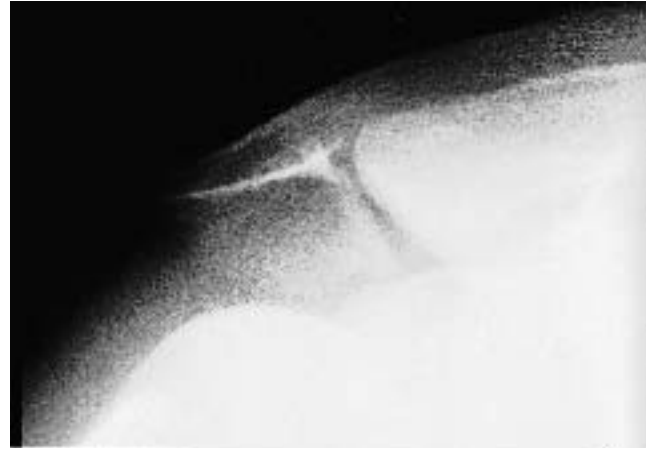

FIGURE 2.1.6. A 30-degree caudal tilt view (right shoulder).

acromial protruberance (Fig. 2.1.6). Although this view is helpful in terms of diagnosis, it is not particularly useful in terms of preoperative planning or determining whether to use a lateral or a posterior approach for the acromioplasty.

The AC joint borders the coracoacromial space medially. As it degenerates, it may play an active role in the extrinsic impingement process. Osteophytic overgrowth on the undersurface of the distal clavicle and medial acromion can impinge on the underlying rotator cuff. The pain of an arthritic or osteolytic joint can also mimic that of anterior impingement. Careful preoperative evaluation is necessary to avoid residual pain at the AC joint after decompression.

The coracoid process forms the anterior border of the subacromial space. It may be enlarged, fractured, or iatrogenically altered, such as occurs with a laterally positioned Bristow transfer of the coracoid tip onto the anterior glenoid rim. Fractures of the coracoid can occur with the recoil of a rifle into the shoulder in hunters. A posterior opening wedge osteotomy for instability also effectively lateralizes the coracoid tip relative to the humeral head. These changes, which can be associated with anterior subcoracoid impingement, are best noted on axillary view x-rays or a computed axial tomography (CAT) scan with the arm flexed 90 degrees and internally rotated.

The greater tuberosity of the humerus forms the floor of the coracoacromial space. It is important to note its size and shape, any osteophytic overgrowth, sclerosis, erosion, or cysts. It is best evaluated radiographically with an AP view with the arm in external rotation.

Soft Tissue Anatomy

It is important to remember that the subacromial bursa is an anterior structure. It extends from the anterior one-half to one-third of the acromion to just medial to the AC joint to 1 to 2 cm anterior to the acromion and 2 to 3 cm laterally (Fig. 2.1.7). The bursal wall is frequently thickened and troublesome posteriorly, and has been named

2.1: Arthroscopic Subacromial Decompression: Lateral Approach / 21

the “posterior bursal curtain.” This curtain frequently “closes” as one backs the scope posteriorly to get a larger field of view of the subacromial bursa. It is frequently necessary to resect a portion of this structure when performing subacromial surgery.

The anatomy of the coracoacromial ligament is pertinent to the technique of acromioplasty. It attaches to the front and undersurface of the acromion as a thick band and continues around the anterolateral corner to attach to the lateral ridge for a variable distance. Anteriorly the coracoacromial ligament attaches to the anterior inferior edge of the acromion, while the deltoid fascia attaches more superiorly (Fig. 2.1.8). As the coracoacromial ligament is detached, it falls away easily from the overlying anterior deltoid muscle and fascia. Laterally, however, the coracoacromial ligament blends inextricably with the deltoid muscle fascia along the lateral acromion. Care must be taken not to aggressively detach the fascia or resect too much bone laterally, as this may result in a deltoid detachment.

Gallino et al²⁶ found that the CA ligament has a variable thickness of insertion on the undersurface of the acromion, ranging from 2 to 5.6 mm. Those patients with excessively thickened ligaments would be the ones most likely to have anterior functional stenosis and/or snapping, as described by O’Boyle et al,¹² and benefit from anterolateral band resection.

Edelson and Luchs²⁵ and others have noted various degrees of transformation of the coracoacromial ligament into bone at its acromial insertion. Gartsman²² labeled this phenomenon “anterior acromial protruberance.” Rockwood⁵ in his open technique recommends resecting 8 to 10 mm of full-thickness anterior bone and then reattaching the deltoid fascia. This technique of full-thickness anterior bone resection back to the level of the AC joint has insinuated itself into some authors’ description of subacromial decompression.²⁶ For the most part the anterior acromial protruberance is really an inferior extension of calcification into the coracoacromial ligament insertion. One does not

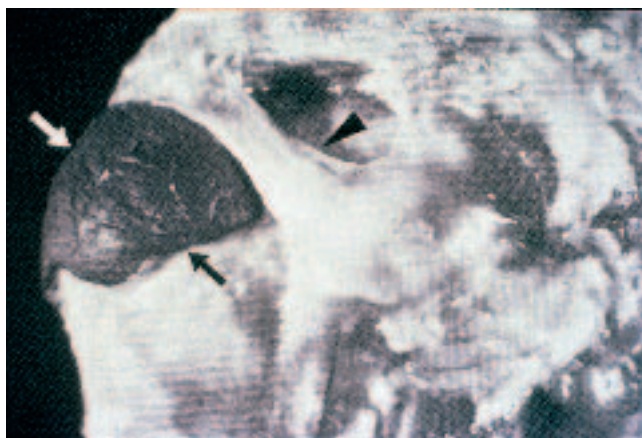

FIGURE 2.1.7. Anterior view of latex injected subacromial bursa. Black arrow, anterior edge of bursa; white arrow, superolateral bursa; black wedge, coracoacromial ligament.

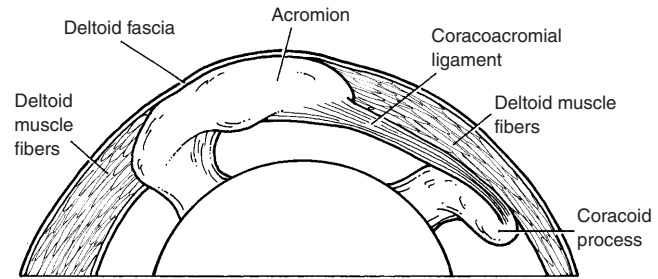
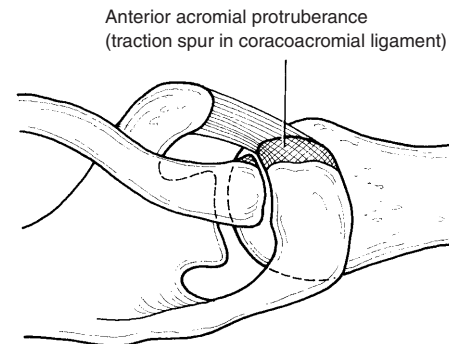


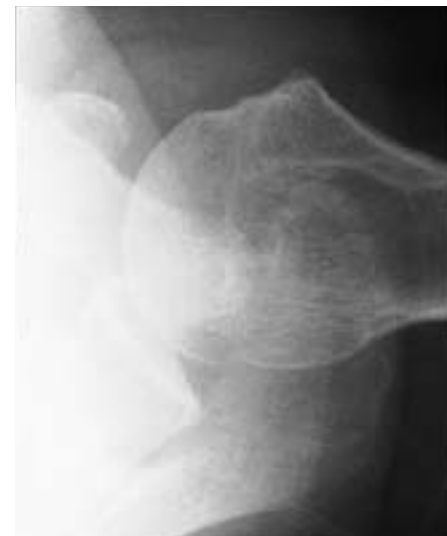FIGURE 2.1.8. Lateral view of coracoacromial ligament and deltoid fascia attachment on anterior acromion. a, deltoid fascia; b, deltoid muscle fibers; c, coracoacromial ligament insertion on undersurface and lateral edge of acromion.

need to resect full-thickness acromial bone anteriorly to remove it, and in fact great care should be taken not to resect too much superior anterior bone, as this may detach the anterior deltoid fascia producing an operative disaster.

The best radiographic views for determining the amount of anterior acromial protruberance are the axillary view and the supraspinatus outlet view (Fig. 2.1.9).



A



B

FIGURE 2.1.9. Anterior acromial protruberance on axillary view. **A:** Protruberance (shaded portion). **B:** Radiograph demonstrating anterior acromial protruberance.

The axillary x-ray is also an excellent view for evaluation of the AC joint, particularly for picking up posterior AC arthritis that may be missed on a routine AP view.

DIAGNOSIS

The history is important. Pain with the cocking and acceleration phase of throwing is most likely secondary to an underlying instability or posterior superior impingement. Nocturnal and rest pain is often indicative of a rotator cuff, whereas patients with cuff tendinitis develop pain with progressive activity.²⁷ Other causes of shoulder pain such as scapular thoracic bursitis, suprascapular nerve syndrome, cervical radiculopathy, and referred pain from the gallbladder, liver, lung, or heart also need to be differentiated.

The clinical signs and x-rays noted previously are the most valuable in making a diagnosis of impingement. Concomitant rotator cuff disease or AC joint disease can be evaluated with both an arthrogram or magnetic resonance imaging (MRI). The arthrogram may be more accurate in determining full-thickness rotator cuff tears but less sensitive in picking up partial-thickness lesions or intratendinous pathology. Isolated AC joint injection and/or bone scan may be helpful in differentiating AC joint versus subacromial disease. It is important to know the status of the AC joint prior to arthroscopic decompression so that residual pathology in this location is not left unattended.

TREATMENT

Conservative care should be diligent and prolonged. The goal is to diminish the inflammation in the tissues and then regain full range of motion and full strength in the scapular stabilizers and rotator cuff to balance the deltoid force couple. This is accomplished with rest, hot and cold modalities, massage, nonsteroidal antiinflammatories, and selective injection. Directed physical therapy and home treatment programs are beneficial. Various authors have recommended from 6 to 18 months of conservative care prior to consideration of operative intervention.

Operative Indications for Arthroscopic Subacromial Decompression

1. Primary extrinsic impingement with type II or III acromion or coracoacromial ligament calcification. Clearly, this patient population has the most predictable success with either the open or arthroscopic operation.
2. Secondary impingement with associated bony changes in conjunction with arthroscopic stabilization for anterior instability.
3. Elderly patients with bony changes and full-thickness rotator cuff tears. If the cuff can technically be

repaired and the patient can comply with the postoperative rehabilitation, then studies would indicate that the final outcome will be more favorable if this is performed either arthroscopically, mini-open, or as an open procedure with the ASAD. Unrepairable massive tears may also respond to decompression, as demonstrated by Rockwood for open procedures.²⁸ When associated, however, with significant glenohumeral degenerative arthritis or superior migration of the humeral head, decompression is not recommended and maintenance of the coracoacromial arch with implantation of an oversized humeral hemiarthroplasty may prove more successful.

4. In conjunction with arthroscopic or mini-open rotator cuff repair.

Indications for Bursectomy, CA Ligament Release, and Resection

1. Younger patients with type I acromion but unresponsive subacromial pain and/or snapping with abduction and rotational maneuvers.
2. Calcific tendinitis of the supraspinatus or subscapularis when associated with type III acromion.

Contraindications

1. Secondary impingement with underlying instability in a young athlete with a type I acromion.
2. Pseudoimpingement syndrome.
3. Anterior subcoracoid impingement.
4. Isolated AC osteolysis.
5. Undersurface partial cuff tears with normal subacromial bursa and benign bony architecture.
6. Association with massive rotator cuff tears and significant degenerative arthritis of the glenohumeral joint.

OPERATIVE TECHNIQUE

Careful preoperative evaluation is necessary to determine the appropriate operative approach and to avoid complications. Outlet and axillary views are the key to evaluating the acromion. The outlet view is utilized to determine the shape of the acromion (type II or type III) and the overall thickness.^{22,29} On the outlet view, lines are drawn on the undersurface of the acromion—one from the front tip of the acromion to the posterior edge, and a second line along the posterior half of the undersurface of the acromion extending out anteriorly. The distance between these two lines at the anterior margin approximates the amount of undersurface anterior bone that will be resected (Fig. 2.1.10).

The axillary view is used to determine the shape of the acromion (cobra versus square tipped) and whether there

2.1: Arthroscopic Subacromial Decompression: Lateral Approach / 23

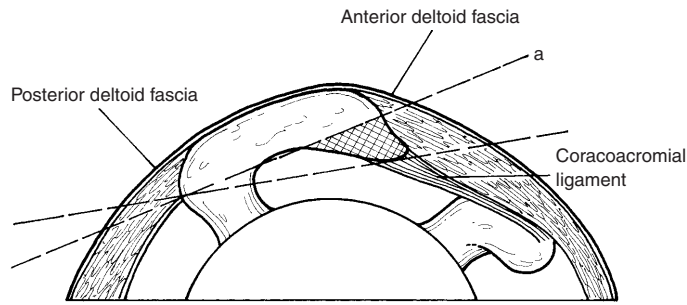


FIGURE 2.1.10. Preoperative planning for ASD. a, cutting-block line.

is any anterior acromial protuberance. If present, this protuberance will need to be resected at the time of coracoacromial ligament release.

If on the outlet view one notes a very thin or curved acromion, the cutting block line on the undersurface of the posterior half of the acromion may actually exit the superior aspect of the acromion, taking off too much anterior bone (Fig. 2.1.11). In these cases, the cutting block technique, as described by Sampson et al,¹¹ would be inappropriate. Instead, the lateral approach (described below) would be more applicable, removing just a small anterior hook and not producing a type I flat acromion.

Poor visualization in the subacromial space is one of the more frustrating aspects of either approach and is usually secondary to either excessive bleeding or inadequate debridement of the subacromial space. Use of electrocautery is strongly recommended. Other strategies to control bleeding during arthroscopic subacromial decompression include the following:

1. Inject 0.25% bupivacaine with epinephrine into the portals (2 cc) and subacromial space (10 cc) at the beginning of the case.
2. Incise skin only and avoid deeper muscle laceration.

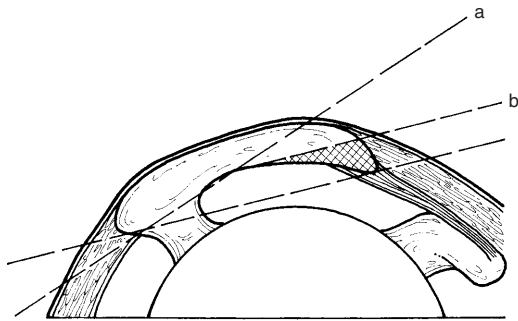


FIGURE 2.1.11. Thin curved acromion where cutting-block technique would not be appropriate. a, Original cutting-block line, b, Modified cut resecting only anterior hook, preserving deltoid fascia and not producing a type I flat acromion.

3. Use a blunted conical trocar for penetration of muscle, joint, and subacromial space.

4. Add epinephrine, 10 mL (1:1,000) per 3-L bag to first irrigation bag only.

5. Avoid debridement of anterior medial acromion and the undersurface of the AC joint until late in the case.

6. Use electrocautery immediately when significant bleeders are encountered.

7. Increase inflow with large-bore sheath at scope. A pump with independent control of pressure and flow rate is helpful.

8. Decrease outflow to maintain pressure. Control suction on shavers and burrs to reduce "red out." Integrated fluid delivery and shaver systems are helpful for this problem.

9. Reduce blood pressure if medical condition allows, to maintain systolic pressure of less than 95 to 100 mm Hg.

10. Increase pressure on pump and elevate bags to level where bleeding is well controlled.

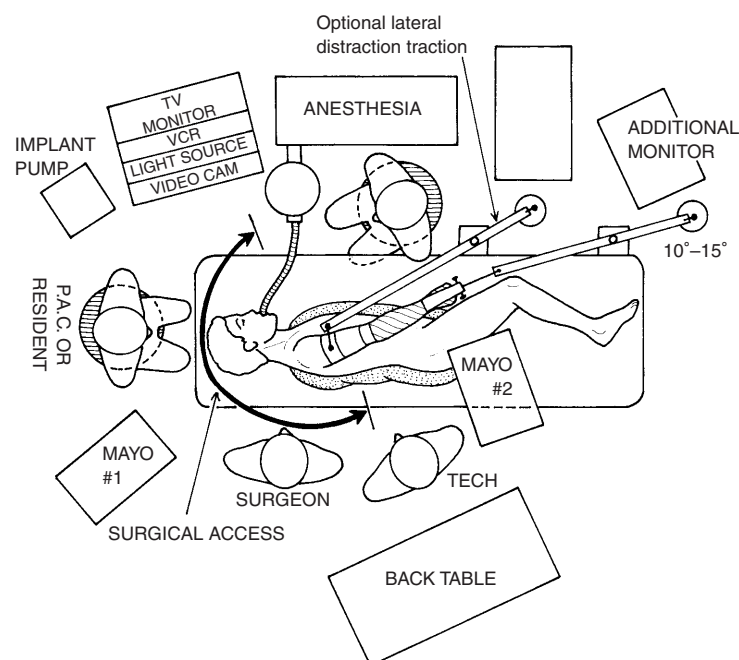
Operating Room Setup (Fig. 2.1.12)

I perform the procedure in an outpatient setting with the patient in the lateral decubitus position. I use general anesthesia. I don't routinely use an interscalene nerve block, but this may ensure better postoperative pain control. The procedure may also be done in a beach-chair position with regional anesthesia as per surgeon preference.

The table is turned approximately 100 to 110 degrees from the anesthesiologist, who is then situated at the patient's abdomen. Long anesthesia tubing is required. The TV monitor tower with contained video equipment is positioned directly anterior to the patient's head and chest. The shoulder holder is attached to the operating table on the anterior side of the body near the foot. The inflow pump is positioned so that it can be observed by the surgeon during the procedure.

Patient Preparation

The patient is positioned in the modified lateral decubitus position as described by Gross and Fitzgibbons.³⁰ This position rolls the patient back 25 to 30 degrees, placing the glenoid orientation parallel to the floor (Fig. 2.1.13). The patient is placed in the beanbag with the U position toward the head and the tails extending to the superior-anterior and posterior chest cephalad to the axilla for support. The shoulder is isolated with large plastic U drapes, and traction is applied to the patient's arm. An axillary roll and appropriate head support is utilized. The arm is positioned at approximately 30 degrees of abduction and 10 degrees of flexion with 7 to 15 pounds of traction

FIGURE 2.1.12. Operating room setup.

applied depending on the patient's size and muscularity. A second dual-traction apparatus may be applied if a stabilization procedure needs to be performed.

Procedure

Glenohumeral Diagnostic Arthroscopy

The anatomy of the shoulder is outlined with a marking pen prior to the operative procedure and the portals marked. The glenohumeral joint is then examined completely from both a posterior and a high anterior portal, established inside out at the superior aspect of the rotator interval. This will later be the anterior portal for the subacromial bursoscopy. Any pathology within the glenohumeral joint is appropriately addressed.

Partial undersurface or small complete rotator cuff tears are frequently marked with a tag suture placed through an 18-gauge needle introduced from superiorly into the joint and retrieved out the anterior portal (Fig. 2.1.14). This suture marker is beneficial later when subacromial bursoscopy is performed, as it provides a quick reference to the questionable cuff area from the superior view. The scope is then removed from the glenohumeral joint and through the same posterior skin portal, redirected at a 10-degree caudad angle to the acromion into the subacromial bursa and far enough anteriorly to enter the chamber. If the bursa is easily entered and distended, then the inflow is brought in at the scope with a pump and a lateral portal is then made on the basis of an accurately placed 18-gauge needle.

If the bursa is significantly inflamed or not easily distended, with poor visualization, then the scope trocar and

sheath is brought directly out anteriorly just lateral to the coracoacromial ligament to exit from the previously made high anterior skin portal. The outflow cannula is then placed on the tip of the trocar and pushed back into the subacromial space so that it lies under the anterior half of the acromion. The sheath is separated slightly, the scope is inserted into the posterior cannula, and flow and visualization are established. A lateral portal is then directed with an 18-gauge needle.

The bursa is then viewed from posteriorly and debrided from the lateral portal until good visualization is established. Any suspicious areas of the rotator cuff that may have been previously identified with a suture marker are debrided and examined from both the posterior portal and the lateral portal.

Lateral Approach for Subacromial Decompression

Preoperatively I will have decided whether I am going to use a modified lateral approach or a cutting-block approach for the decompression. If the patient has a thin curved acromion and a lateral approach is appropriate, I place my lateral portal 3.5 to 4 cm lateral to the acromion and about midway between the midportion of the acromion and the anterolateral corner. I make sure with an 18-gauge needle that I can get the shaver along the anterior-inferior edge of the acromion and a short distance down the anterolateral side, and that it can be directed slightly upward at the acromion for ease in burring and shaving.

The undersurface of the anterior half of the acromion is then debrided with an aggressive shaver and/or a cautery ablation system (Fig. 2.1.15). Care should be

2.1: Arthroscopic Subacromial Decompression: Lateral Approach / 25

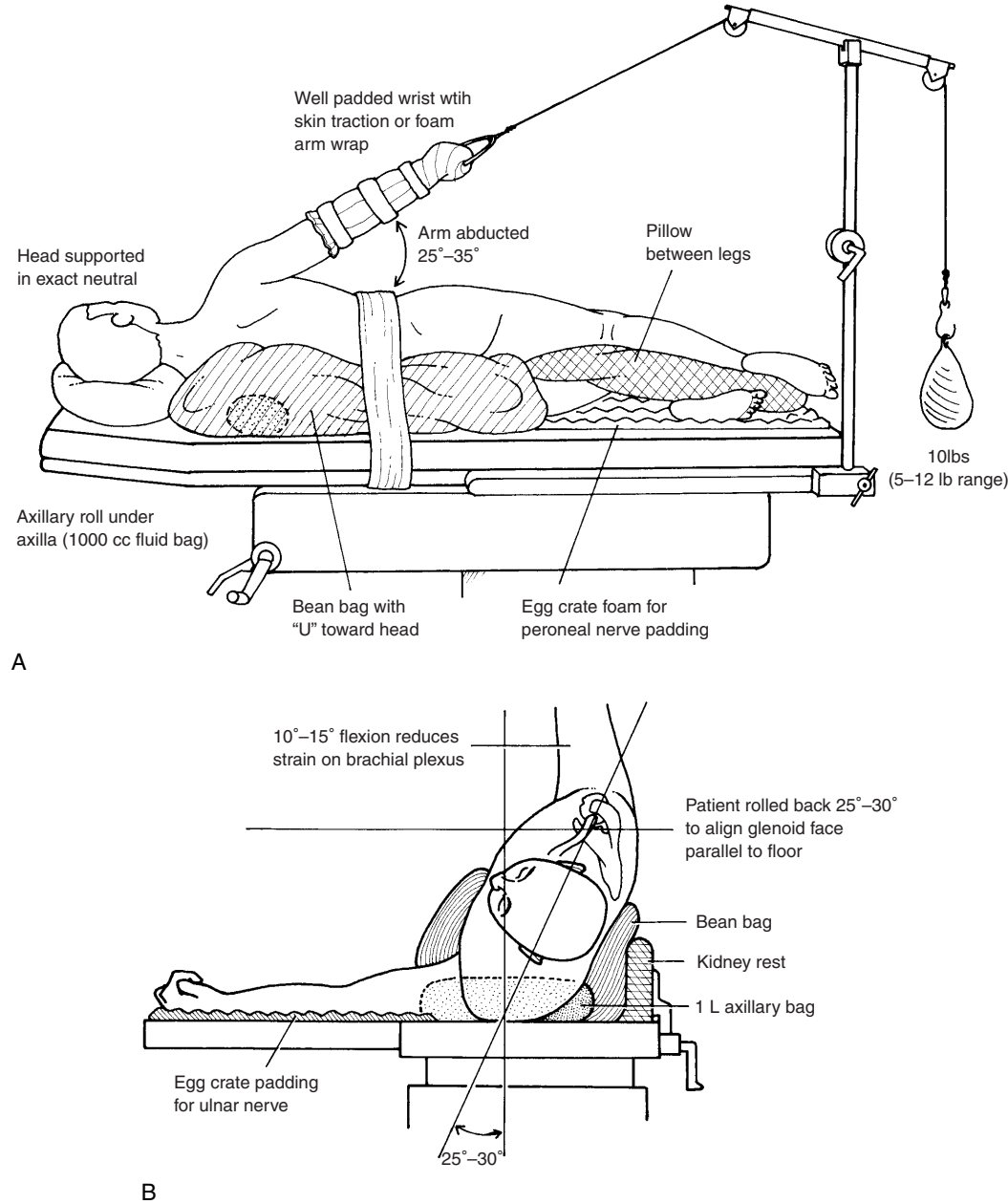


FIGURE 2.1.13. A: Patient position with appropriate support for head and axillary roll. **B:** Roll-back position (Gross³⁰ with permission).

taken with either instrument to stay on the undersurface of the bone and not pop off anteriorly or laterally into the deltoid fibers, which are very vascular. The anterolateral corner of the acromion is identified with an 18-gauge needle directed from superiorly, and the debridement is started at this point and progresses medially toward the AC joint and also posteriorly.

From the preoperative planning, the amount of bone to be resected is known, as is the diameter of the burr. Starting at the anterolateral corner, the appropriate amount of anterior hook is resected from anterior to medial. Care is taken not to remove full-thickness bone anteriorly and thereby detach the anterior deltoid fascia. This cannot be

subsequently repaired as in open operative procedures. After the anterior bone is resected from lateral to medial, tapering of the remaining posterior bone is then accomplished from anterior to posterior to the midportion of the clavicle, or the scope can be placed laterally and the shaver introduced posteriorly to taper from posterior to anterior. Because of the thin and curved nature of the acromion, the goal is not to produce a completely flat undersurface but to perform a smooth and even taper (Fig. 2.1.16). Whether one tapers from anterior to posterior or posterior to anterior, the scope is always placed laterally to evaluate the decompression in two planes.

If there is no evidence of degenerative disease of the

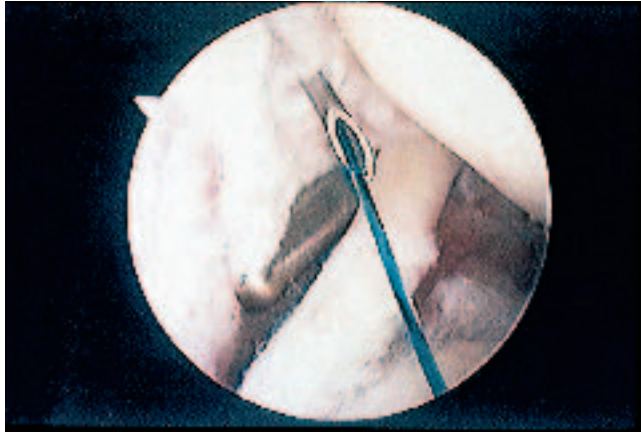


FIGURE 2.1.14. Suture marker through partial-thickness undersurface rotator cuff tear.

AC joint and no inferior osteophytes, I do not take the decompression into the joint or bevel it. If inferior osteophytes are present, then the undersurface of the AC joint is exposed and the osteophytes removed. Manual pressure from above will then deliver a portion of the distal clavicle to view and if it is noticeably arthritic, an arthroscopic distal clavicle resection can be performed. If the articular cartilage looks healthy, then the beveling alone would be performed.

Following adequate decompression, the pump pressure is reduced and hemostasis is obtained with the electrocautery unit. The subacromial space is then instilled with 10 cc of 0.25% bupivacaine with epinephrine and then 1 to 2 cc in each incision. The portals are closed with 4-0 nylon and a sterile dressing is applied.

Postoperative Care

Immediate postoperative motion is allowed and encouraged. No sling is utilized. On the first postoperative day, passive and active motion is encouraged to avoid the pos-

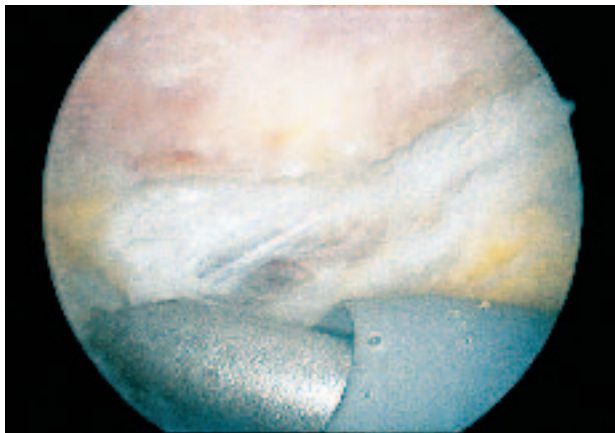
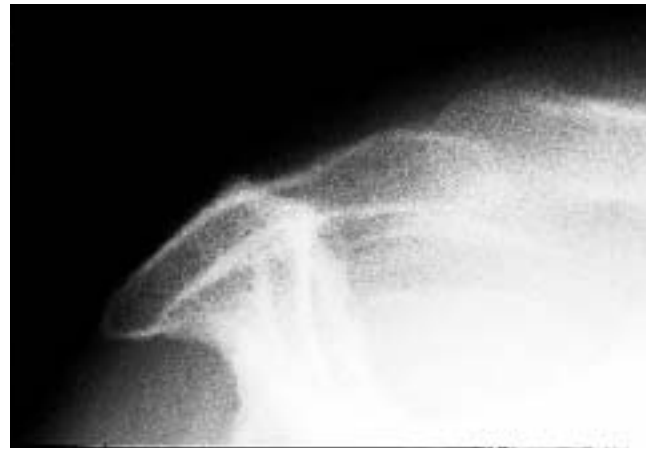
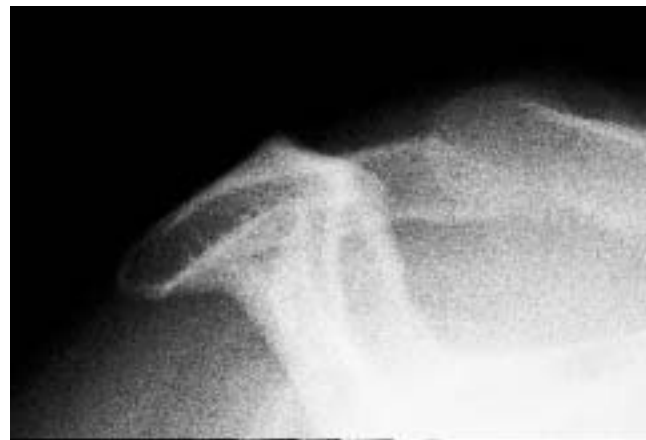
FIGURE 2.1.15. Debridement of anterior half of acromion and bursa (anterolateral corner of acromion to right).



A



B

FIGURE 2.1.16. **A:** Preoperative outlet x-ray of thin curved acromion with exuberant osteophyte. **B:** Postoperative x-ray of anterior osteophyte and hook resection. Note increased anterior acromial-humeral distance in spite of nonflat acromial undersurface.

sibility of developing an adhesive capsulitis or captured shoulder, as described by Gross's group.³¹ Patients are allowed to return to sedentary work as soon as possible. Heavy manual labor usually requires a slower progression and may take from 6 to 12 weeks.

RESULTS

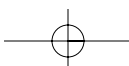
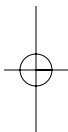
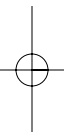
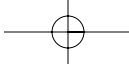
I routinely utilize a two-portal cutting-block technique as described by Sampson et al.¹¹ Although I orient the acromion on the top of the screen when I am in either the posterior or lateral portal, the principles of the procedure still apply. I have found this technique to be considerably more reproducible and reliable than the traditional lateral approach as described herein and by Ellman⁸ and utilize it for at least 95% of my subacromial decompressions. On the rare occasions where a thin, broad, and curved acromion is encountered, then the cutting-block

2.1: Arthroscopic Subacromial Decompression: Lateral Approach / 27

technique is inappropriate. The lateral approach as described above is still utilized with success.

REFERENCES

1. Neer CS. Anterior acromioplasty for chronic impingement syndrome in the shoulder: a preliminary report. *J Bone Joint Surg* 1972;54A:41–50.
2. Neer CS. Impingement lesions. *Clin Orthop* 1983;173:70–77.
3. Hawkins RJ, Brock RM, Abrams JS, et al. Acromioplasty for impingement with an intact rotator cuff. *J Bone Joint Surg* 1986;70B:795–797.
4. Hawkins RJ, Kennedy JC. Impingement syndrome in athletes. *Am J Sports Med* 1980;8:151–158.
5. Rockwood CA Jr. Surgical treatment of the shoulder impingement syndrome: a modification of the Neer anterior acromioplasty in 71 shoulders. *Orthop Trans* 1990;14:251.
6. Bigliani LU, Delessandro DF, Duralde XA, et al. Anterior acromioplasty for subacromial impingement in patients younger than 40 years of age. *Clin Orthop* 1989;246:111–116.
7. Johnson LL. Shoulder arthroscopy. In: Johnson LL, ed. *Arthroscopic surgery: principles and practice*. St. Louis: CV Mosby, 1986;1371–1379.
8. Ellman H. Arthroscopic subacromial decompression: analysis of one to three year results. *Arthroscopy* 1987;3:173–181.
9. Esch J, Ozerkis LR, Helgager JA, et al. Arthroscopic subacromial decompression: results according to the degree of rotator cuff tear. *Arthroscopy* 1988;4:241–249.
10. Paulos LE, Franklin JL. Arthroscopic shoulder decompression development and application—five year experience. *Am J Sports Med* 1990;18:235–244.
11. Sampson TG, Nisbet JK, Glick JM. Precision acromioplasty in arthroscopic subacromial decompression of the shoulder. *Arthroscopy* 1991;7:301–307.
12. O'Boyle M, Newton PM, Arroyo JS, et al. Arthroscopic resection of the anterolateral and of the coracoacromial ligament for impingement in the overhead athlete. Paper presented at the 16th Annual Meeting of the Arthroscopy Association of North America, San Diego, California, April 1997.
13. Codman EA. Rupture of the supraspinatus tendon and other lesions in or about the subacromial bursa. In: *The shoulder*. Boston: Thomas Todd, 1934;73–75.
14. Rathbun JB, McNab I. The microvascular pattern of the rotator cuff. *J Bone Joint Surg* 1970;52B:540–553.
15. Moseley HF, Goldie I. The arterial pattern of the rotator cuff on the shoulder. *J Bone Joint Surg* 1963;45B:780–789.
16. Rothman RH, Parke WW. The vascular anatomy of the rotator cuff. *Clin Orthop* 1965;41:176–186.
17. Nirschl RP. Rotator cuff tendinitis: basic concepts of pathoetiology. *Instr Course Lect* 1989;38:439–445.
18. Hibe FW, Kvitne RS, Giangarra CE. Shoulder pain in the overhead or throwing athlete: the relationship of anterior instability and rotator cuff impingement. *Orthop Rev* 1989;18:963–975.
19. Walsch G, Boylau P, Noel E, et al. Impingement of the deep surface of the supraspinatus tendon on the posterior superior glenoid rim: an arthroscopic study. *J Shoulder Elbow Surg* 1992;1:238–245.
20. Jobe CM. Posterior superior glenoid impingement: expanded spectrum *Arthroscopy*. 1995;11:530–536.
21. Gerber C, Terier F, Ganz R. The role of the coracoid process in chronic impingement syndrome. *J Bone Joint Surg* 1985;67B:703–708.
22. Gartsman GM. Arthroscopic acromioplasty for lesions of the rotator cuff. *J Bone Joint Surg* 1990;72A:169–180.
23. Bigliani LU, Morrison DS, April EW. The morphology of the acromion and its relationship to rotator cuff tears. *Orthop Trans* 1986;10:216.
24. Rockwood CA Jr, Lyons FR. Shoulder impingement syndrome: diagnosis, radiographic evaluation, and treatment with a modified Neer acromioplasty. *J Bone Joint Surg* 1993;75A:409–424.
25. Edelson JG, Luchs J. Aspects of coracoacromial ligament anatomy of interest to the arthroscopic surgeon. *Arthroscopy* 1995;11:715–719.
26. Gallino M, Vatiston B, Annaratone G, et al. Coracoacromial ligament: a comparative arthroscopic and anatomic study. *Arthroscopy* 1995;11:564–567.
27. Esch JC, Baker CL. Rotator cuff disease and impingement. In: Whipple TL, ed. *Arthroscopic surgery—the shoulder and elbow*. Philadelphia: JB Lippincott, 1993:161–163.
28. Rockwood CA Jr. Shoulder function following decompression and irreparable cuff lesions. *Orthop Trans* 1984;8:92.
29. Wuh HCK, Snyder SJ. Modified classification of the supraspinatus outlet view based on the configuration and the anatomical thickness of the acromion. Paper presented at the Fifty-Ninth Annual Meeting of the American Academy of Orthopedic Surgeons, Washington, DC, February 1992.
30. Gross RM, Fitzgibbons TC. Shoulder arthroscopy: A modified approach. *Arthroscopy* 1985;1:156–159.
31. Mormino MA, Gross RM, McCarthy JA. Captured shoulder: a complication of rotator cuff surgery. *Arthroscopy* 1996;12:457–461.



CHAPTER 2.2

Arthroscopic Subacromial Decompression: Posterior Approach

Thomas G. Sampson

HISTORY OF PRECISION ACROMIOPLASTY “CUTTING-BLOCK” TECHNIQUE

Since the advent of subacromial surgery using arthroscopic technique and its popularization by Lanny Johnson¹ and Howard Ellman² in the early to mid-1980s, we have been looking for a better way to reproduce the classic Neer subacromial decompression for impingement syndrome.^{3,4} Up to that time, there had not been any published techniques for an arthroscopic method of flattening the anterior acromion that included preoperative planning, surgical technique, and postoperative assessment that could be done in a precise way. The work of Morrison and Bigliani⁵ noted the association of the shape of acromion and rotator cuff pathology. The flatter acromion was correlated with fewer rotator cuff tears as compared to the hooked acromion, which was associated in a higher incidence of rotator cuff tears.

Our interest in seeking a better technique arose out of two observations. The first was that the posterior two-thirds of the acromial bursal surface was always flat. The second observation occurred during total knee replacement surgery when performing bone resection. Typically a cutting block was pinned to the anterior femur or tibia, facilitating the saw's cutting a flat surface when resecting bone (Fig. 2.2.1). With these concepts in mind, the posterior flat acromial surface mimics the metal jig as the cutting block (Figs. 2.2.2–2.2.4). Therefore, the posterior approach was then conceived in surgery, on a day that began with a total knee replacement and ended with a shoulder arthroscopic subacromial decompression using the new cutting-block technique.

TECHNIQUE

Preparation for the procedure starts with the outlet view on x-ray (Fig. 2.2.5). The line of resection is inscribed along the posterior flat acromial undersurface through the anterior bone to be resected. A second line is drawn from the posterior border of the anterior tip of the acromion, and a vertical line is made at the perpendicular of the first line at the origin of the downslope. From that perpendicular line to the anterior edge is the distance of bone to be removed. The distance is typically 1.8 to 2.0 cm (Fig. 2.2.6).

Through the posterior portal, the amount of acromion to be removed is measured using the probe (Fig. 2.2.7).

Using the posterior portal, the sheath of the burr is resting on the posterior acromion as a jig for cutting away the anterior acromion using an advancing and side-to-side sweeping motion (Fig. 2.2.8).

Once the resection has been completed, the acromion is then remeasured using the probe, and the flatness of the resection is demonstrated (Fig. 2.2.9).

Postoperatively, an outlet view is taken (Fig. 2.2.10). The precise amount of anticipated bony resection is demonstrated by the postoperative x-ray.

Since the first acromionectomy with the cutting-block technique, it has been used successfully in both a lateral decubitus position and the beach-chair position. The ease of applications, fast learning curve, and reproducible results have made this technique our standard for subacromial decompression.

Since the technique's conception in 1983, the indications and contraindications have remained nearly the same, whether the approach is open or arthroscopic; how-



FIGURE 2.2.1. Cutting block pinned to the anterior femur, preparing for the distal femoral cut in a total knee replacement.

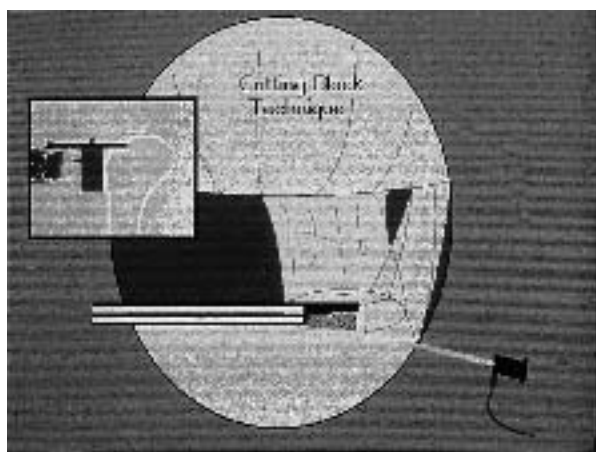


FIGURE 2.2.2. Cutting-block technique. **Inset:** Diagram of the distal femoral cut with the cutting block pinned to the anterior femur. The diagram shows the shaver barrel resting on the posterior acromion advancing forward on the undersurface of the acromion.

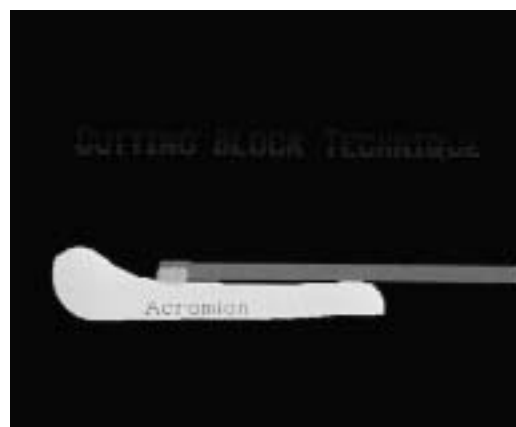

FIGURE 2.2.3. The shaver barrel resting on the posterior acromion as it is advanced anteriorly on the acromial inverted surface.

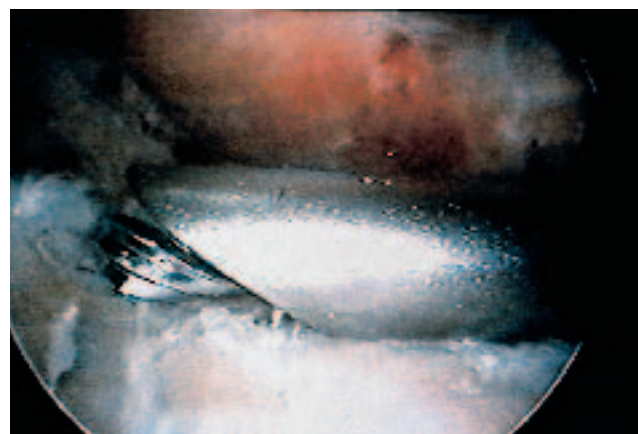


FIGURE 2.2.4. Arthroscopic view of the subacromial space with the shaver barrel and arthroscopic burr resting on the posterior acromion, advancing anteriorly and cutting the undersurface of the acromion.




FIGURE 2.2.5. Outlet view with radiograph lines inscribing the bone to be resected on the anterior acromion.

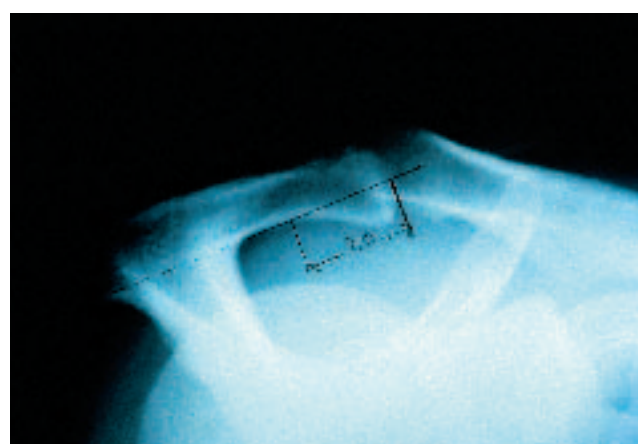


FIGURE 2.2.6. The amount of bone to be resected on the outlet view radiograph.

2.2: Arthroscopic Subacromial Decompression: Posterior Approach / 31

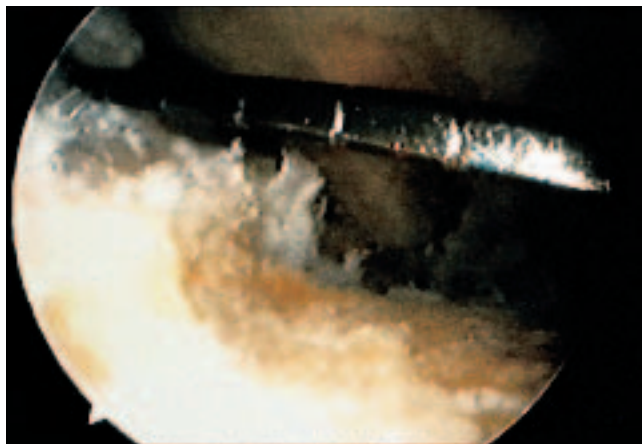


FIGURE 2.2.7. Arthroscopic view of the subacromial space with the probe hook resting on the anterior acromion, spanning the amount of bone to be resected. The marks on the probe are 3 mm apart, indicating that the beginning of the resection is 18 mm from the anterior surface.

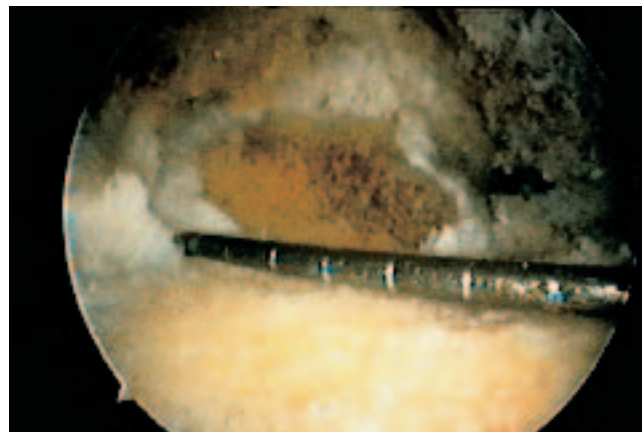


FIGURE 2.2.9. The finished result of resection of the undersurface of the acromion and partial distal claviclectomy, both using the cutting-block technique. Note that the probe sits flat on the undersurface of the acromion in the foreground and in the background; the distal clavicle is the co-planar with the acromion.

ever, the orthopedic surgeon must scrutinize the type of impingement syndrome and the subacromial pathology prior to performing the procedure. We have recently observed that patients with presumptive impingement syndrome may actually have another condition, such as internal derangement of the rotator cuff and evidence of tension failure. In those cases, a decompression and repair should be performed.

The setup and instrumentation has been discussed in Chapter 2.1.

Surgical Procedure

The room setup is the same as with the lateral approach (Fig. 2.2.11). Through the entire procedure the surgeon stands at the head of the table (Fig. 2.2.12). The shoulder

is held by any type of lateral traction device to simply balance the weight of the arm. The arm is held at an angle between 40 and 70 degrees of abduction with some forward flexion, thereby placing the arm in a relaxed position.

Orientation is the key to a good outcome and to the ease of the procedure. The orientation of the shoulder and the acromion while looking down from the head is identical to the orientation of the monitor. With this orientation, the surgeon is able to move instruments from side to side and have those movements correlate exactly with movements on the arthroscopic monitor.

The posterior soft spot is first palpated approximately one finger breadth from the lateral edge of the acromion and one to one and a half finger breadths inferior to the posterior acromial edge. It is important to appreciate the

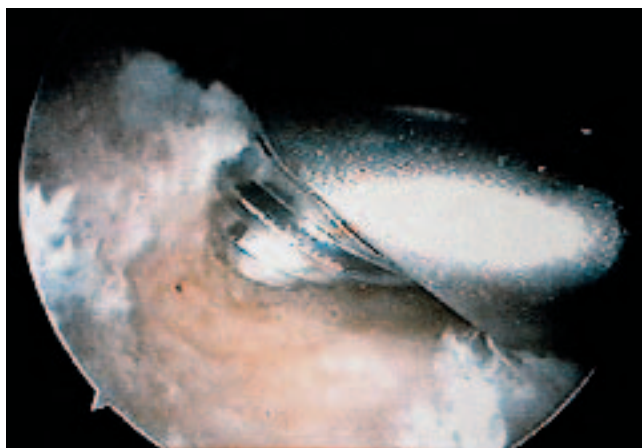


FIGURE 2.2.8. The undersurface of the acromion being resected using the arthroscopic barrel burr.

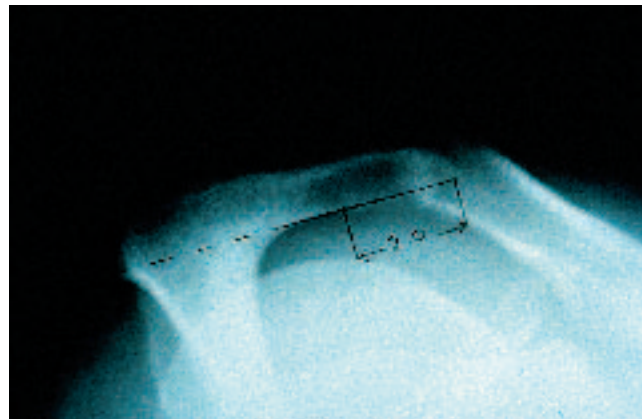


FIGURE 2.2.10. Outlet-view radiograph showing the precise amount of bone that has been resected, producing a type I or flat acromion.

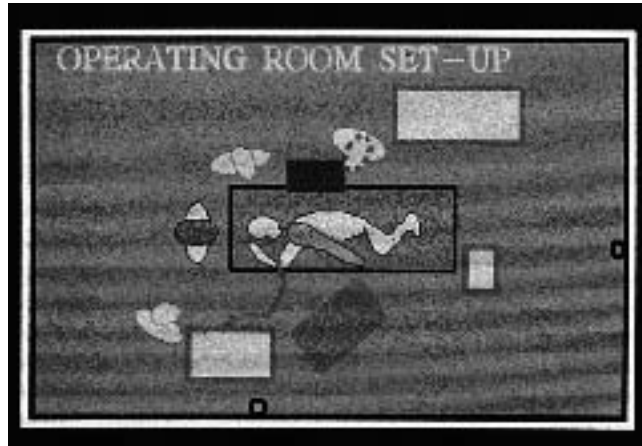


FIGURE 2.2.11. Operating room setup. Note that the surgeon stands at the head of the table.

anatomic acromion slopes from posterior to anterior with a cephalad inclination.

An 18-gauge spinal needle is first placed through the posterior soft spot into the glenohumeral joint simply to mark the level of the joint line. The shoulder is distended with saline as it is easier to puncture a fluid-filled joint than a deflated joint.

After a no. 11 blade is utilized to make the skin incision, the arthroscopic sheath is then placed into the shoulder joint, palpating the posterior glenoid rim step-off as a landmark.

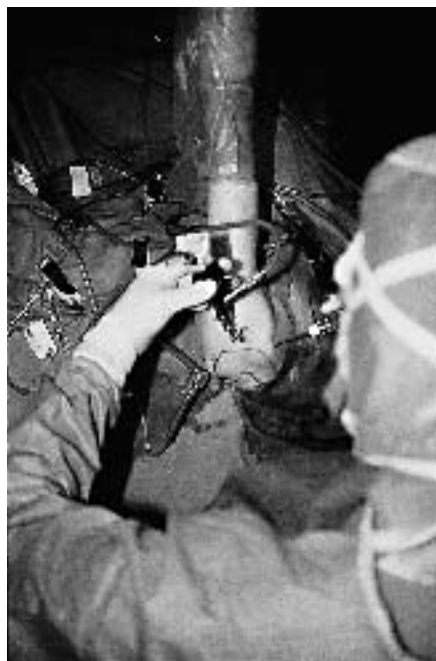

FIGURE 2.2.12. Orientation of the surgeon at the head of the table. The view is from the head of the table, with the arm in lateral traction and the arthroscope in the midlateral portal. To the left is anterior, and to the right is posterior.

If a single-lumen arthroscopic sheath is utilized, then an anterior portal is necessary for inflow or outflow and sensing of an arthroscopic pump. Our preference is to use a triple-lumen arthroscopic sheath, which allows inflow, outflow, and sensing through one portal.

A typical glenohumeral arthroscopy is then performed; specifically, the area of the supraspinatus portion of the rotator cuff, the long head of the biceps, and the labral structures are evaluated for impingement syndrome (Fig. 2.2.13). The area of the crescent and the cable portions of the supraspinatus are then further evaluated for interstitial tearing or complete rupture of the rotator cuff. Hyperemic changes or degeneration in the crescent area may lead to a suspicion of internal tears or tendinosis without frank disruption.

If there is no evidence of pathology of the rotator cuff, long head of the biceps, and labral structures, the procedure is continued in the subacromial space through a midlateral portal. If there is hyperemia of the crescent area and or evidence of what may appear to be some interstitial derangement of the crescent fibers, an 18-gauge spinal needle is placed through the midlateral portal to assess the integrity, thickness, and viability of the critical zone of the rotator cuff. A *polydioxanone suture* (PDS) suture is placed through the 18-gauge needle for later viewing in the subacromial space. Recently, we have been debridging the interstitial changes of the crescent area, and if a hole is created, a side-to-side repair is performed (Figs. 2.2.14 and 2.2.15).

Attention is then directed into the subacromial space. A midlateral portal is created approximately one finger breadth just lateral to the midportion of the acromion. The arthroscope is then placed into the subacromial space and aimed anteriorly into the bursal cavity. Assessment first begins anteriorly. The coracoacromial (CA) ligament is

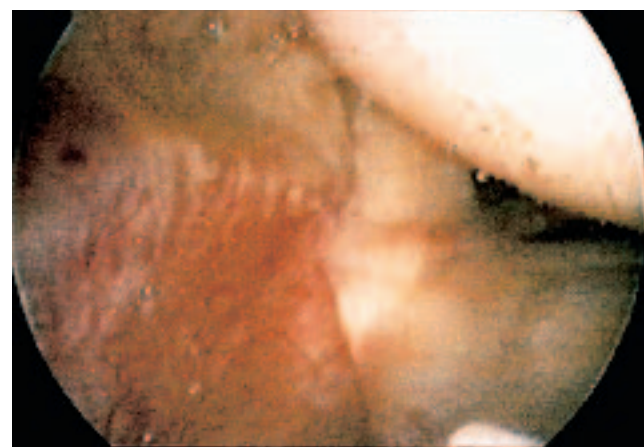


FIGURE 2.2.13. Arthroscopic view of glenohumeral joint from the posterior portal. Note the hyperemic changes of the cable area of the rotator cuff and some deficiency in the crescent area. The long head of the biceps and labrum are intact.

2.2: Arthroscopic Subacromial Decompression: Posterior Approach / 33

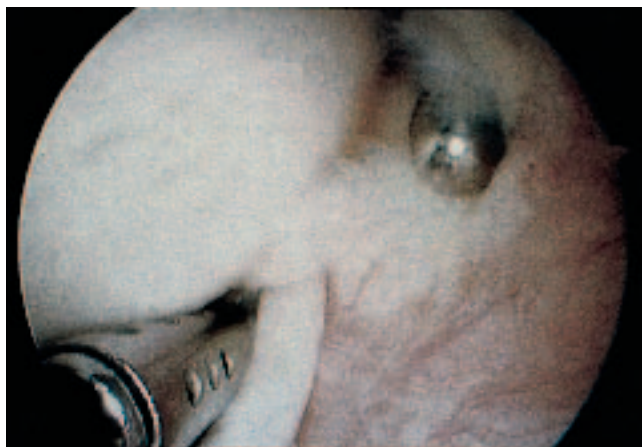

FIGURE 2.2.14. The crescent area of the rotator cuff has a degenerative tear in it. A shaver is being brought through the supraspinatus from the midlateral portal.

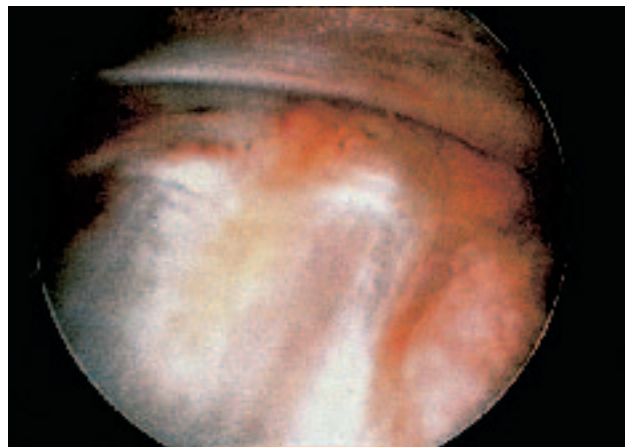


FIGURE 2.2.16. Arthroscopic view of the subacromial space through the midlateral portal, viewing the coracoacromial ligament. The rotator cuff is above and the acromion is below.

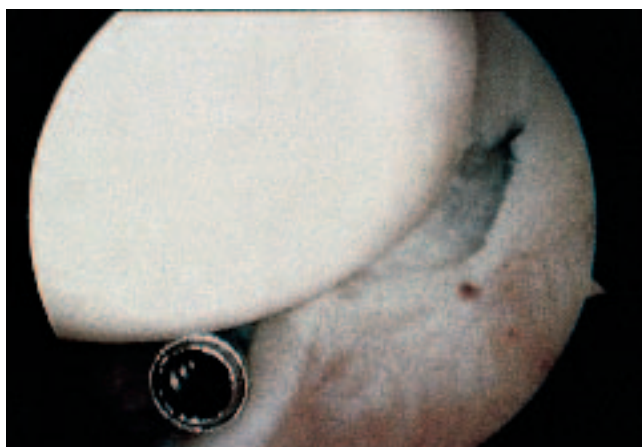

FIGURE 2.2.15. The rotator cuff has been debrided, leaving a small attritional hole.

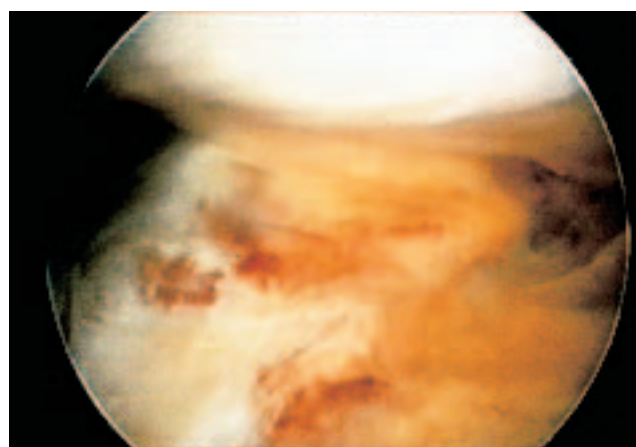


FIGURE 2.2.17. The coracoacromial ligament viewed from the midlateral portal, with hemorrhage within the ligament. Note that the rotator cuff and humeral head are above and the acromion is below.

usually visualized first (Fig. 2.2.16) and assessed for its integrity.

Commonly fraying is identified in the CA ligament near its origin on the anterior lateral acromion in the critical zone. Often the hypertrophic bursa must be cleared using a motorized shaver to see the space (Fig. 2.2.17). If *no* degenerative changes are seen on the CA ligament, one must carefully inspect the bursal side of the rotator cuff for damage (Fig. 2.2.18).

The rotator cuff is then palpated using a probe at its insertion onto the greater tuberosity of the supraspinatus, and the infraspinatus can be identified and examined for tearing or degeneration.

Following the determination that rotator cuff impingement exists, the decompression is begun. First a resector is brought in through the posterior portal and the subacromial soft tissue is removed. This can also be ac-



FIGURE 2.2.18. The critical zone viewed through the midlateral portal. Note the frayed area of the rotator cuff at the coracoacromial ligament.

complished using one of the many electrosurgical devices that both cut and ablate tissue.

If the CA ligament is severely degenerated, it should be excised completely. However, if it has only a small amount of fraying or scratching, then we recommend removing only the portion of the CA ligament that allows visualization of the anterior acromion. A partial release is satisfactory.

After partially excising or releasing the CA ligament, a probe is brought in through the posterior portal and placed on the acromion from anterior to posterior. The acromion is then visualized with the probe from the lateral portal to determine the amount of bone to be resected (Fig. 2.2.19). In addition, the probe is moved from posterior to anterior to determine the natural initial site of inclination and thus the posterior-most site of resection from posterior to anterior. We commonly refer to this site as the “driveway.”

A barrel-shaped burr is brought through the posterior portal and laid flat on the posterior acromion. The burr is then advanced using a side-to-side or medial-to-lateral sweeping motion until the acromion is completely planed down flat (Figs. 2.2.8 and 2.2.9). Bleeding is controlled by elevating the pump pressure or epinephrine in bags of saline or using electrosurgical devices to cauterize obvious bleeders.

Following the partial acromionectomy, the particles of bone are evacuated using the motorized shaver or an out-flow cannula. The acromion is then remeasured, and the flatness is demonstrated with the probe again hooked over the anterior acromion.

If the undersurface of the acromioclavicular (AC) joint is degenerated, exposing the joint, then a partial distal claviclectomy is performed with the cutting-block technique (Fig. 2.2.9), planing the distal clavicle in the same plane as the acromion. With advanced AC arthritis, a complete distal claviclectomy is done.

The subacromial space is then washed out and sutures are placed in the skin. The subacromial space is then injected with a combination of bupivacaine and morphine 2 mg.

Postoperatively the patients are treated with immediate range of motion to tolerance, except those who have had an associated rotator cuff repair. Abduction and external rotation are avoided until the third week postoperation if a rotator cuff repair is done. Postoperative x-rays are taken at the first postoperative office visit to document the flat acromion (Fig. 2.2.20).

It is common postoperatively for patients to develop tightness of their posterior capsule. It is extremely important that the patient be instructed in across-chest stretching in addition to the usual therapeutic exercise as posterior capsule tightness may cause a pseudoimpingement syndrome.

Approximately 600 patients have undergone this procedure as described; 94% appear to have had good to excellent results, with 6% having fair to poor results. On reassessing the poor results, the majority have had ongoing rotator cuff disease and developed progression to partial- or full-thickness rotator cuff tears. A few have developed adhesive capsulitis. There were no infections. The return to work varied with the patient's motivation. Most of the self-employed people and professionals were back to their jobs within days postoperation; however, pain persisted, although decreasingly so, for 2 to 3 months. Returning to sports activities varied with the sport. Upper-extremity athletes took the longest to return to their full performance.

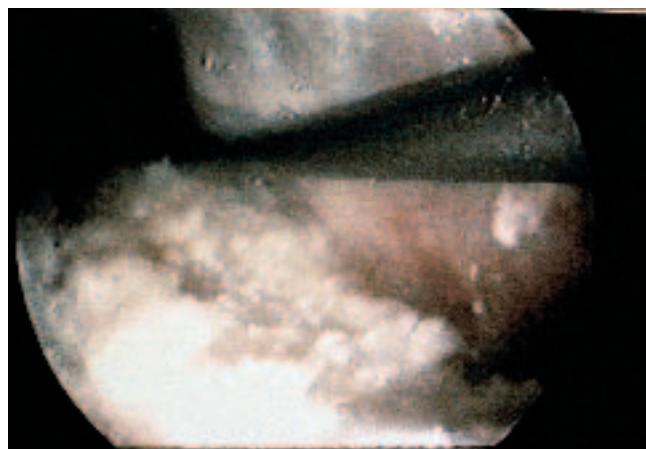


FIGURE 2.2.19. The coracoacromial ligament has been removed. The anterior acromion is being measured by the probe through the posterior portal. Note that the rotator cuff is above, the acromion is below, the anterior is left, and the posterior is right.

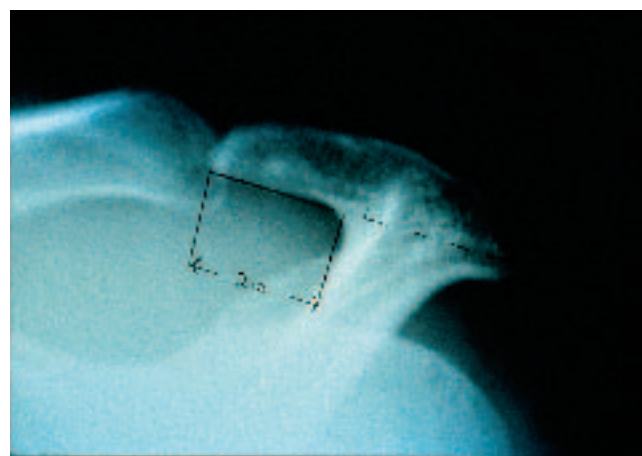


FIGURE 2.2.20. Outlet view radiograph after resection of the anterior-inferior acromion using the cutting-block technique. Note the perfectly flat acromion undersurface.

PITFALLS

If the posterior portal is placed too cephalad, the technique can't be performed as described. Portal placement is crucial to allow the burr sheath to lie perfectly flat on the posterior flat acromial surface. Should the portal placement be incorrect, it is our recommendation that an additional portal be created rather than trying to struggle with the inappropriate entry site. A correctly placed posterior portal may migrate cephalad as the shoulder distends from fluid extravasation. A new portal is advised.

Poor visualization commonly occurs because of bleeding, bone particles, and soft tissue. Bleeding may be controlled by elevating the pump pressure, but watch the clock so as to not cause severe extravasation. The use of epinephrine in the bags or electrocautery may help. Remember to ask the anesthesiologist to lower the patient's blood pressure as a last measure. Tracheal deviation is a severe complication of fluid extravasation and may result in death.

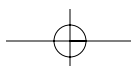
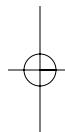
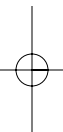
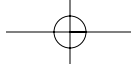
A large outflow cannula will facilitate evacuation of bony debris and improve the view. Always take the time to go back and resect annoying obstructive soft tissue. If all else fails to give an adequate view, remove all instruments, wait a few minutes, and start over. This also allows for an assessment of instrument placement and flow mechanics. The break may save time and frustration in the long run.

SUMMARY

The posterior approach using the cutting-block technique is a practical method for the precise removal of the anterior-inferior protrusion of the acromion. Preoperative planning using outlet x-rays and measurement of the acromion will predict exactly how much bone is to be resected. Using the flat surface of the posterior acromion as the cutting block jig for the arthroscopic barrel burr facilitates a partial acromionectomy transforming it to a type I or flat inferior acromion surface, thus opening up the supraspinatus outlet. The technique has been effective and reproducible for alleviating impingement syndrome. Failures have mainly been due to ongoing rotator cuff disease that was not appreciated at the time of surgery.

REFERENCES

1. Johnson LL. Shoulder arthroscopy. In: Johnson LL, ed. *Arthroscopic surgery: Principles and practice*; St. Louis: CV Mosby, 1986:1371–1379.
2. Ellman H. Arthroscopic subacromial decompression: Analysis of one to three year results. *Arthroscopy* 1988;4:241–249.
3. Neer CS. Anterior acromioplasty for chronic impingement syndrome in the shoulder: A preliminary report. *J Bone Joint Surg* 1972;54A:41–50.
4. Neer CS. Impingement lesions. *Clin Orthop* 1983;173:70–77.
5. Bigliani LU, Morrison DS, April EW. The morphology of the acromion and its relationship to rotator cuff tears. *Orthop Trans* 1986;10:216.





<http://www.springer.com/978-0-387-98808-5>

Advanced Arthroscopy

Chow, J.C.Y. (Ed.)

2001, XXII, 741 p., Hardcover

ISBN: 978-0-387-98808-5