

## Mechanical Injury Models

### *Balloon Catheter Injury to Rat Common Carotid Artery*

**Rodney J. Dilley**

#### **1. Introduction**

Removal of arterial endothelium and damage to medial smooth muscle with a balloon embolectomy catheter lead to formation of a thin mural thrombus, platelet adhesion and degranulation, smooth muscle cell migration to the intima, and cell proliferation and matrix synthesis, ultimately producing a thickened neointimal layer. This model was developed initially by Baumgartner and Studer in the 1960s (1) and was modified (2) and used extensively throughout the 1970s and 1980s to develop our knowledge of vascular smooth muscle and endothelial cell kinetics following injury in adult animals (3). In the 1980s and 1990s it was used extensively to explore the effects of pharmacological agents that might influence vascular smooth muscle cell growth (4-7).

The model may hold some relationship to the vascular repair responses to angioplasty, but several important differences must be recognized: Injury is to nondiseased vessels with no pre-existing neointimal cell populations, and so responses come predominantly from medial cells, there is little intimal/medial tearing, and low-pressure distention and application of a shearing motion during catheter withdrawal are used. Nonetheless it does represent a widely studied model of endothelial and vascular smooth muscle cell proliferation and migration and as such will likely continue to be used widely.

The injury model has been applied predominantly in the rat, with endothelial removal from either the left common carotid artery or the descending thoracic aorta. Rabbits, guinea pigs, and hamsters have also been used, and

similar methods have been performed on dogs and pigs. Atherogenesis has been studied in suitable animal models by addition of cholesterol to the diet after balloon injury (8). Numerous other methods have been used to remove or damage endothelium (9–12) and to generate a neointima; however, balloon catheter denudation is the most widely used model to date with hundreds of published articles.

In this chapter a procedure is described for endothelial denudation of the rat common carotid artery with a balloon embolectomy catheter. The procedure is simple, requiring little more than introduction of a balloon catheter to the common carotid artery lumen and passage of the inflated balloon to remove the endothelium and damage underlying smooth muscle cells to stimulate a repair response.

## 2. Materials

1. Animals. Adult male Sprague-Dawley rats, between 350 and 450 g body weight (*see Note 1*).
2. Anesthetics. Ketamine (100 mg/mL) and xylazine (20 mg/mL), mixed to the indicated concentration (3:2) and administered by intraperitoneal (ip) injection at a ratio of 0.1 mL/100 g body weight.
3. Catheter. Fogarty arterial embolectomy balloon catheter 2F (Baxter Healthcare, Irvine, CA), with a three-way stopcock and 1 mL syringe attached. All are filled with sterile 0.9% saline, and air is excluded.
4. Antiseptic. Aqueous chlorhexidine solution.
5. Surgical equipment. Surgical lighting, warm pad.
6. Instruments. Scalpel, skin forceps, small (5 cm long) blunt-ended scissors, two pairs of fine, curved forceps for blunt dissection and isolation of carotid artery, one pair of jeweler's forceps for holding the wall of the external carotid artery, fine scissors (e.g., iridectomy scissors), three pairs of artery clamps, needle holders, silk suture material (2/0 and 5/0), skin suture material (e.g., 2/0 Dexon) (*see Note 3*).
7. Recovery procedures. Analgesic (Carprofen 5 mg/kg body weight, subcutaneous), warm and quiet recovery space, warm (37°C) saline for rehydration.

## 3. Methods

1. Weigh rats and anesthetize by ip injection of ketamine and xylazine mixture, with the dose based on body weight (0.1 mL/100 g body weight).
2. When the rat is fully anaesthetised, as demonstrated by absence of a foot withdrawal reflex (about 10 min is usually adequate), shave the ventral surface of the neck between the angle of the jaw and the sternum, swab with antiseptic solution to clean the skin, and remove loose hair.
3. Make a midline skin incision with the scalpel. Using the round-ended small scissors, blunt dissect through the midline between the large mandibular salivary glands, then laterally to the left, via planes of fascia to the bifurcation of the left

common carotid artery. The bifurcation lies approximately at the junction of the stylohyoid, omohyoid, and sternomastoid muscles.

4. Locate the internal carotid artery and blunt dissect under it with small curved forceps so that a loose ligature (2/0 silk) can be placed around the vessel (**Fig. 1A**). An artery clamp can then be placed on the end of the ligature to lift the carotid artery and hold it aside.
5. Locate the external carotid artery and similarly place two loose ligatures (5/0 silk) around it (**Fig. 1B,C**).
6. Place a loose ligature on the common carotid artery, proximal to the bifurcation (**Fig. 1D**).
7. Tie the distal ligature on the external carotid artery (**Fig. 1B**), leaving at least 2–3 mm from the bifurcation to allow space proximally for a small arteriotomy and another ligature.
8. Apply pressure to lift the ligatures (use artery clamps) on the proximal common carotid and distal external and internal carotid arteries (**Fig. 1A,B,D**). This will isolate the intervening segment of carotid artery bifurcation from blood flow.
9. With fine scissors make an incision in the external carotid artery, immediately proximal to the distal ligature, ensuring that you leave enough space for the proximal ligature to isolate the arteriotomy (see **Fig. 1E** for placement). This incision must be large enough to admit the balloon catheter, but not so large as to tear the vessel apart (see **Note 4**).
10. After checking the catheter assembly (**Fig. 2**) for leaks and correct inflation volume (see **Notes 5 and 6**), lift the free edge of the incision with fine forceps and feed the catheter into the external carotid artery, toward the bifurcation.
11. Advance the catheter through to the common carotid artery and continue to the first mark on the catheter (approximately 5 cm) so that the catheter tip lies in the arch of the aorta.
12. Inflate the catheter balloon with 0.02 mL saline.
13. Withdraw the catheter through the common carotid artery to the carotid bifurcation, rotating the catheter between your fingers as you proceed.
14. Deflate the catheter balloon and advance the tip to the aorta again, repeating the injury procedure twice more.
15. Remove the catheter after the third passage and tie the proximal ligature (**Fig. 1C**) on the external carotid artery.
16. Release the remaining loose ligatures (**Fig. 1A,D**) and allow approximately 5 min for full assessment of the blood flow in the common carotid artery. A dilated and pulsating common carotid artery should be evident.
17. Suture-close the skin incision and give parenteral fluids (5 mL warm saline sc) and analgesic (carprofen 5 mg/kg body weight, sc).
18. Animals should be kept warm during recovery for at least 1 h after surgery (see **Note 7**).
19. Crushed food pellets and cotton-wool balls soaked with water are placed in the bottom of the cage to allow the animal to feed and drink easily for the first day after neck surgery.

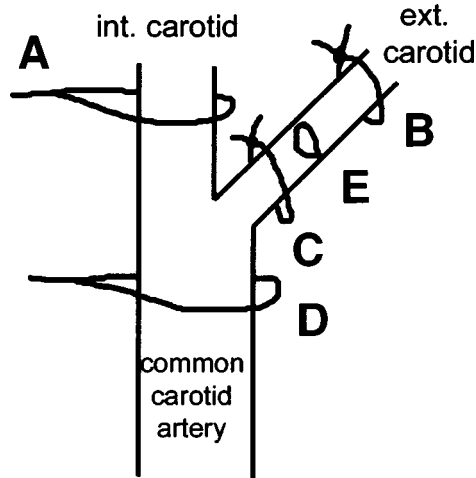


Fig. 1. The carotid artery bifurcation region showing the position of ligatures and arteriotomy during the balloon catheter injury procedure. (A,D) Loose temporary ligatures. (B,C) Permanent ligatures. (E) Arteriotomy.

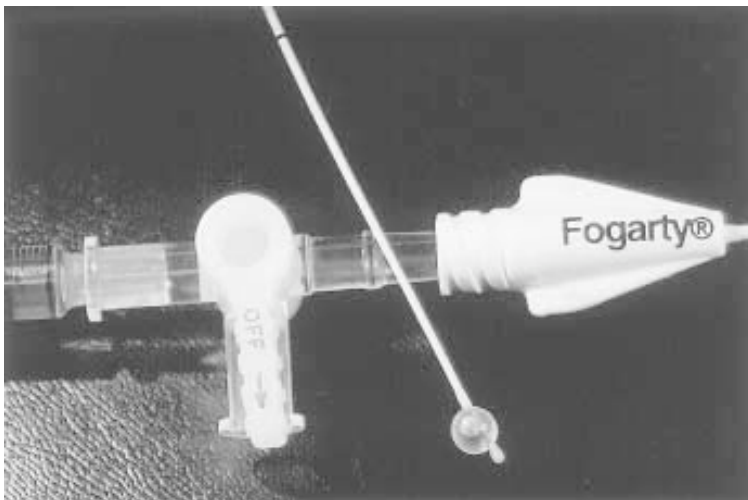


Fig. 2. A balloon catheter assembly showing the syringe filled with 0.02 mL saline (**left**) connected to the catheter (**right**) by a three-way tap (**middle**). The catheter tip with an inflated balloon is shown (**lower right**), indicating the length of catheter inserted into the carotid artery by the black mark on the catheter, 5 cm from the tip.

## 4. Notes

1. Rats of approximately 400 g body weight are convenient to use. The procedure becomes more difficult in small animals (e.g., less than 300–350 g) because of the decreasing size of the external carotid artery.
2. Anesthesia suitable for 30–40 min of surgery is required. Difficult surgical operations may take longer and require additional anesthetic toward the end of the procedure.
3. Fine and accurate tools are essential.
4. Entry of the catheter through the arteriotomy is the most difficult part of the procedure. There are a number of tips that may be helpful in situations in which it is difficult to place the catheter in the artery.
  - a. The arteriotomy should be slightly larger than the tip of the catheter, and the angle of entry must match the angle of the external carotid artery.
  - b. When the arteriotomy is too small, gentle outward pressure from the tips of small scissors or forceps will often make the hole large enough.
  - c. Use light pressure on the loose ligatures to adjust angles for ease of entry.
  - d. It is possible for an assistant to open the arteriotomy with two pairs of fine forceps while the catheter is maneuvered between the forceps into the external carotid artery.
  - e. Use a trocar, a 2–3 cm segment of fine tubing, with a diagonal cut on one end. When placed over the catheter tip, the point of the trocar can be used to enter the artery first to guide the catheter into place.
  - f. A dissecting microscope may be used, although this is generally not necessary and not always helpful.
5. To enable precise control of inflation volume it is helpful to use a syringe containing only 0.02 mL saline. Different inflation volumes may produce different degrees of injury and thus impact on repair responses, so this method makes it easier to provide a constant level of injury to the artery.
6. It is important to free the syringe and catheter of any air bubbles; these will compress during inflation and thus alter inflation pressure. Air can be removed with a three-way tap between syringe and catheter and a 2-mL syringe used to create a vacuum from the side port. With judicious tapping and alternate application of the vacuum and release of saline into the catheter from the saline filled inflation syringe, the air can be removed from the catheter and inflation syringe.
7. For recovery, fluid and warmth are essential. A humidicrib for recovery over approximately 30–60 min is ideal. Monitor the animals for signs of dehydration, bleeding, or general loss of condition.
8. Thrombosis may occur, especially where flow through vessels is low. If thrombosis rates are found to be unacceptably high, then changing the protocol to minimize handling of the common carotid artery can be helpful in preventing

excessive damage and also in reducing spasm. For example, it is possible to dispense with the ligature on the common carotid artery (**Fig. 1D**) and to use the proximal ligature on the external carotid artery (**Fig. 1B**) to control bleeding, but this can be a more difficult procedure. Thrombosis could be managed with judicious use of anticoagulants, although this should be avoided when possible as some, such as heparin, will have effects on smooth muscle growth responses. Vasodilators (such as topical lignocaine) can also be used to overcome spasm.

9. Aortic balloon injury can be performed with a similar method. An increase in inflation volume to 0.03 mL may be used for this procedure, but it is generally not necessary if the aim is to remove the endothelium. The catheter is advanced to the second mark (10 cm) and inflated before withdrawing, with rotation, to the aortic arch.
10. Retrograde balloon injury from a femoral artery access is also possible, and may be particularly useful for double-injury models in carotid or aorta (**13**).
11. Larger animals/vessels may require a larger balloon; However, rabbit carotid arteries can be successfully de-endothelialized with the 2F balloon.
12. Successful endothelial removal can be gaged by the intravenous administration of a bolus of Evans blue dye, 60 mg/kg body weight, 20–30 min before sacrifice (Sigma Chemical Company, St. Louis, MO). Denuded areas of artery wall will stain blue, whereas intact endothelium will remain white.

## References

1. Baumgartner, H. R. and Studer, A. (1966) Effects of vascular catheterization in normo- and hypercholesteremic rabbits. *Pathol. Microbiol.* **29**, 393–405.
2. Clowes, A. W., Reidy, M. A., and Clowes, M. M. (1983) Mechanisms of stenosis after arterial injury. *Lab. Invest.* **49**, 208–215.
3. Clowes, A.W., Clowes, M. M., and Reidy, M. A. (1986) Kinetics of cellular proliferation after arterial injury: III. Endothelial and smooth muscle growth in chronically denuded vessels. *Lab. Invest.* **54**, 295–303.
4. Jackson, C. L. and Schwartz, S. M. (1992) Pharmacology of smooth muscle cell replication. *Hypertension* **20**, 713–736.
5. Zempo, N., Koyama, N., Kenagy, R. D., Lea, H. J., and Clowes, A. W. (1996) Regulation of vascular smooth muscle cell migration and proliferation in vitro and in injured rat arteries by a synthetic matrix metalloproteinase inhibitor. *Arterioscler. Thromb. Vasc. Biol.* **16**, 28–33.
6. Wong, J., Rauhoft, C., Dilley, R. J., Agratis, A., Jennings, G. L., and Bobik, A. (1997) Angiotensin-converting enzyme inhibition abolishes medial smooth muscle PDGF-AB biosynthesis and attenuates cell proliferation in injured carotid arteries: relationships to neointima formation. *Circulation* **96**, 1631–1640.
7. Ward, M. R., Sasahara, T., Agrotis, A., Dilley, R. J., Jennings, G. L., and Bobik, A. (1998) Inhibitory effects of tranilast on expression of transforming growth factor-beta isoforms and receptors in injured arteries. *Atherosclerosis* **137**, 267–275.
8. Campbell, J. H., Fennessy, P., and Campbell, G. R. (1992) Effect of perindopril on the development of atherosclerosis in the cholesterol-fed rabbit. *Clin. Exp. Pharmacol. Physiol. Suppl.* **19**, 13–17.

9. Webster, W. S., Bishop, S. P., and Geer, J. C. (1974) Experimental aortic intimal thickening: II. Endothelialization and permeability. *Am. J. Pathol.* **76**, 265–284.
10. Clowes, A. W., Collazzo, R. E., and Karnovsky, M. J. (1978) A morphologic and permeability study of luminal smooth muscle cells after arterial injury in the rat. *Lab. Invest.* **39**, 141–150.
11. Lindner, V., Reidy, M. A., and Fingerle, J. (1989) Regrowth of arterial endothelium. Denudation with minimal trauma leads to complete endothelial cell regrowth. *Lab. Invest.* **61**, 556–563.
12. Reidy, M. A. and Schwartz, S. M. (1981) Endothelial regeneration: III. Time course of intimal changes after small defined injury to rat aortic endothelium. *Lab. Invest.* **44**, 301–308.
13. Koyama, H. and Reidy, M. A. (1997) Reinjury of arterial lesions induces intimal smooth muscle cell replication that is not controlled by fibroblast growth factor 2. *Circ. Res.* **80**, 408–417.



<http://www.springer.com/978-0-89603-751-9>

Atherosclerosis

Experimental Methods and Protocols

Drew, A.F. (Ed.)

2001, XI, 247 p., Hardcover

ISBN: 978-0-89603-751-9

A product of Humana Press