

Pathology of Kidney Tumors

David J. Grignon

1. Introduction

1.1. Classification

The classification of epithelial tumors of the kidney has undergone considerable change in the last two decades. Systems based on cytoplasmic characteristics and cytogenetic analysis have expanded our understanding of this group of tumors. These new, nontraditional systems have led to the development of a more clinically significant pathological classification (1,2). Although many questions remain unanswered and debate continues concerning the validity of these proposals, research studies on epithelial neoplasms of the kidney must take these advances into consideration. Scientific studies of any type should incorporate information regarding the type of tumor(s) included in the study group. This chapter briefly reviews the accepted subtypes of renal epithelial neoplasms, with a focus on the morphological features that distinguish them.

1.2. The "Mainz" System

In 1986, Thoenes et al. (3) proposed a system based primarily on the cytoplasmic characteristics of tumor cells. This allowed for a greater subdivision of renal epithelial tumors, into what the authors believed would be clinically significant categories. This approach has been adopted in whole or in part by most urologic pathologists, and, combined with cytogenetic information forms the basis for the recent consensus classification (4,5). The basic categories consist of clear-cell, chromophobe-cell, chromophil-cell, mixed tumors, collecting-duct carcinoma, and oncocytoma.

1.3. Cytogenetic Classification

Based on his work as well as that of other investigators, Kovacs proposed a classification of renal epithelial tumors, taking into consideration consistent patterns of cytogenetic abnormalities (6). There is remarkable correlation of the cytogenetic abnormalities with the histologic subtypes described by Thoenes et al. (3).

1.3.1. Nonpapillary Carcinoma (3p-)

This group includes clear-cell renal-cell carcinoma (RCC), and granular (eosinophil subtype of clear cell of Thoenes et al. [3]). renal cell carcinomas not included in other groups. Clear-cell RCC with a pure or partial papillary architecture is also classified here. Up to 98% of cases in this group have the 3p- abnormality (von Hippel Lindau gene mutation) (7). Other frequent abnormalities include 5q+ (70%) and 14q- (41%). The 3p- abnormality is viewed as the primary cytogenetic event in the development of RCC, and does not correlate with clinical aggressiveness; more “malignant” tumors have an accumulation of multiple additional cytogenetic changes.

1.3.2. Papillary Renal Tumors (+7, +17)

Papillary tumors, as defined cytogenetically, are limited to papillary or tubulopapillary neoplasms with columnar or cuboidal eosinophilic or basophilic cells (chromophil tumors of Thoenes, et al.) (3). The small, tubulopapillary cortical lesions that many accept as “adenoma” have trisomy 7 and 17 in up to 100% of cases, but have no other cytogenetic abnormalities. Papillary carcinomas also have the +7 (75%) and +17 (80%) changes, as well as a variety of other abnormalities, including +3q, +8, +12, +16, and +20. Kovacs has argued that cytogenetic analysis can differentiate benign from malignant tumors in this subset (6).

1.3.3. Chromophobe RCC (-1, -2, -6, -10, -13, -17, and -21)

Chromophobe-cell RCC have been evaluated cytogenetically with a consistent but unusual pattern of abnormality with multiple monosomies. Over 80% of cases studied have shown loss of all seven chromosomes indicated here (8).

1.3.4. Oncocytoma

These tumors have shown a lack of consistent cytogenetic abnormalities. The most common are translocations involving the breakpoint region 11q13 and -Y and -1 (2).

1.4. Consensus Classification

Consensus meetings held in Heidelberg, Germany, and Rochester resulted in a working classification being developed and recommended for use (4,5). This classification is a natural extension of the work of Thoenes et al. (3,6) and

Kovacs, and takes into consideration the clinical relevance of these various entities. The classification is presented in **Table 1**. The entities making up this classification scheme are detailed individually in **Subheading 2**.

2. Renal Cortical Adenoma

2.1. Clinical Features

The frequency of small epithelial lesions in the cortex of kidneys has been found to be between 7% and 23% in autopsy series (9). Eble and Warfel reported on a series of 400 consecutive autopsies in which the kidneys were carefully sectioned and examined; (10) and epithelial cortical lesions were found in 83 instances (21%) with increasing frequency with advanced age (10% in 21–40-yr-olds vs 40% in 70–90-yr-olds). Papillary adenomas have been reported in up to one-third of patients in association with acquired cystic disease (11). These appear earlier than carcinomas in this patient group, and are believed to represent the precursor lesion.

2.2. Pathologic Features

Cortical adenomata are grossly identifiable from as small as 1 mm, are well-circumscribed, yellow to gray in color, and are located in the cortex. The majority are tubular, papillary, or tubulo-papillary in architecture, most often corresponding to the basophil cell type as described by Thoenes et al. (3). The cells have round to oval nuclei with stippled to clumped chromatin and inconspicuous nucleoli. Cytoplasm is scant and amphophilic to basophilic. Although well-defined criteria for the distinction of adenoma from carcinoma have yet to be defined, the consensus conference agreed on a working definition until additional information is available. In this system, adenoma is defined as a lesion less than 5 mm in diameter, having a tubulopapillary architecture and a low nuclear grade (4,12).

3. Metanephric Adenoma/Adenofibroma

3.1. Clinical Features

This rare lesion has only recently been described in detail (13–15). It occurs at any age, but is most common in middle age, with a 2:1 female preponderance. Approximately 50% are incidental findings, with others presenting with polycythemia, abdominal/flank pain, mass, or hematuria. Incidental cases may coexist with RCC. The cases reported to date have not recurred or metastasized.

3.2. Pathologic Features

There is a wide range of sizes, with the largest reported case measuring 15 cm. Metanephric adenoma is well-circumscribed, solid or lobulated, and grayish-white. Small cysts and calcifications may be present. It is composed of uniform, round tubules embedded in a loose stroma. Individual cells have small,

Table 1
Classification of Renal Epithelial Tumors

Benign
Papillary adenoma
Oncocytoma
Metanephric adenoma/adenofibroma
Malignant
Conventional (clear-cell) carcinoma
Papillary carcinoma
Chromophobe carcinoma
Collecting-duct carcinoma
Unclassified RCC

regular nuclei, with absent or inconspicuous nucleoli and scant cytoplasm. Less often, papillary or microcystic architectures are seen. Hemorrhage, necrosis, and calcifications including psammoma bodies—are common. The cells do not contain glycogen, and immunohistochemical studies suggest a distal nephron or collecting-duct origin (14). Recent cytogenetic data suggests a relationship with papillary tumors based on the presence of trisomy 7 and 17 (16).

4. Oncocytoma

4.1. Clinical Features

In 1976, Klein and Valensi identified a subset of renal tumors composed of oncocytes exhibiting a benign clinical behavior (17)—an observation subsequently confirmed by several groups (18–20). Oncocytoma comprises approx 4% of kidney tumors in adults, with most detected over age 50; there is a male-to-female ratio of approximately 2–3:1. The majority are discovered as incidental findings, although oncocytoma may present with hematuria or a palpable mass. Origin from the intercalated cell of the collecting duct has been postulated (21).

4.2. Pathologic Features

Oncocytoma is a circumscribed mass with a homogeneous tan or mahogany-brown color. In some cases, bilateral and multifocal lesions are found. In rare cases there are innumerable lesions present—a situation that has been termed "oncocytomatosis" (22). Areas of hemorrhage may be seen, but necrosis is absent. A stellate central scar is characteristic; however, in smaller lesions the scar may not be well-developed and will only be demonstrable on histologic examination. Oncocytoma may coexist with RCC.

The tumor is composed entirely of cells with abundant and intensely eosinophilic cytoplasm, exhibiting coarse granularity. Focal cytoplasmic vacuolization may be present (23). The cells are typically cuboidal, but may be columnar and are arranged in well-defined nests which are peripherally closely packed but separated by a loose stroma toward the central region (Fig. 1). This corresponds to the central scar that may be evident grossly. Cystic change may be seen, and hemorrhage—when present—is frequently associated with these areas. Less often, a tubular or microcystic architecture is found. Nuclei are regular and round to oval in shape, with granular chromatin and central nucleoli. The presence of cells with bizarre pleomorphic nuclei is well-recognized, and believed to be degenerative in nature. Mitoses are absent, and applying strict criteria, the finding of even a single mitotic figure excludes oncocytoma as a diagnosis. In a review of 80 cases, Amin et al. (20) identified a total of two mitotic figures in the entire series, demonstrating the rarity of this finding. The importance of this criterion is highlighted by a report from Memorial Sloan-Kettering Cancer Center. In this series, 16% of tumors reported as oncocytoma had 1–2 mitotic figures per 10 high-powered fields, and there were two cases (3%) which had apparently developed metastases (24).

4.3. Special Studies

Oncocytoma reacts positively for low mol-wt cytokeratin, and does not express vimentin (25). There is positive reactivity for epithelial-membrane antigen (21). Hale's colloidal iron stain is negative. Lectins show a pattern consistent with collecting-duct origin (21). Ultrastructurally, the cells are filled with mitochondria.

5. Conventional (Clear Cell) Carcinoma

5.1. Clinical Features

Clear-cell RCC accounts for approx 70% of all adult epithelial kidney tumors in surgically resected series; thus, it is reflected in much of the literature on RCC (3). The tumor is believed to originate in the proximal tubule. The characteristic cytogenetic abnormalities, found in over 90% of clear-cell RCC cases, involve the short arm of chromosome 3 (3p) (2,6). In many cases, there is loss of the entire short arm; yet other aberrations such as deletions and translocations are described. Studies in patients with von Hippel-Lindau disease have led to the recognition of the von Hippel-Lindau gene (26). The vast majority of cases occur in adults over 40 yr of age, although no age group is spared—even children. There is a male preponderance, with approx a 2:1 ratio. RCC occurs with greater frequency in a few well-described inherited conditions, including von Hippel-Lindau disease (27) and tuberous sclerosis (28).

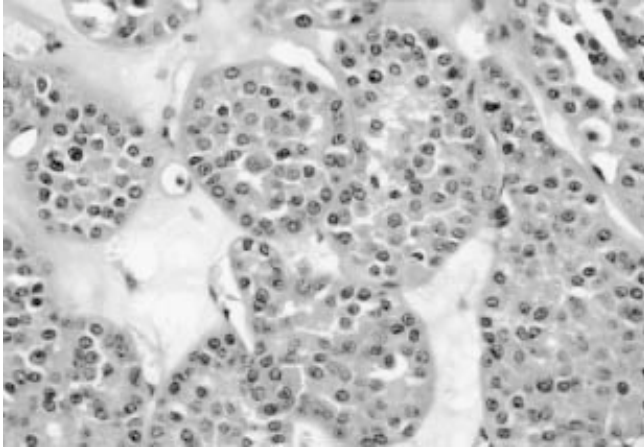


Fig. 1. Renal oncocytoma. The tumor is composed of uniform cells with granular eosinophilic cytoplasm arranged in nests embedded in a loose fibrous stroma.

5.2. Pathologic Features

The most characteristic gross feature of conventional (clear-cell) RCC is a bright yellow color caused by abundant lipid in the tumor. The neoplasm can range in size from millimeters to massive, weighing several kilograms. There is an apparent trend for tumors to be smaller in size, as increasing numbers are discovered earlier. Most present a variegated appearance, with hemorrhage and necrosis; brown areas may reflect old hemorrhage and soft, fleshy grayish-white areas frequently indicate a sarcomatoid component. Fibrosis can impart a firm grayish-white color, usually in the center of the lesion. Most are well-circumscribed, with a thin capsule or pseudocapsule separating the tumor from adjacent tissues. Cystic change occurs in as many as 15% of cases. Bilateral tumors are found in approx 1% of patients, and are more frequent in patients with von Hippel-Lindau disease and tuberous sclerosis.

Clear-cell tumors have transparent, structureless (empty) cytoplasm with well-defined cell borders. The cytoplasm contains variable amounts of glycogen and lipid; mucin stains are negative. In some cells, there is fine eosinophilic material around the nucleus (clear-cell eosinophilia), a feature often associated with high nuclear grades. The nuclei in clear-cell RCC tend to be round to oval and fairly regular, although considerable heterogeneity may exist in a single tumor. The nuclear characteristics have proven to be a significant predictor of behavior. Many studies have now demonstrated the independent

significance of nuclear grading as a prognostic indicator (29,30). Architecturally, clear-cell RCC may display several patterns; compact-alveolar, tubular, and microcystic are the most common. In the former, the small nests are separated by a well-developed sinusoidal vascular network (Fig. 2). Cystic change is common and rarely may produce a predominantly cystic lesion.

5.3. Special Studies

Clear-cell RCC characteristically coexpresses cytokeratin (low mol-wt) and vimentin, a feature of diagnostic importance (31). High mol-wt cytokeratins are not expressed. Carcinoembryonic antigen (CEA) is not expressed. Cells contain abundant glycogen and are mucin-negative. The Hale's colloidal iron stain is negative, although the iron pigment which is often present will stain.

6. Papillary Carcinoma

6.1. Clinical Features

Papillary (chromophil) RCC comprises 10–15% of RCC in surgical series (3,32–34). As emphasized by Delahunt and Eble (33), the term “papillary” in this context is a “name” rather than a “descriptor.” Age ranges from childhood to elderly, with most occurring in middle age; there is a male preponderance (2–4:1). It has been generally considered that chromophil RCC has a better prognosis than the clear-cell type, yet there is limited data available comparing the two types on a stage-for-stage basis. The overall 5-yr survival for papillary carcinoma is >80%, compared to 40–50% for clear-cell carcinoma. Using historical controls, Amin et al. found improved survival to be independent of stage (34).

Cytogenetically, papillary RCC is characterized by trisomy 7 and 17 with loss of the Y chromosome. Trisomies of other chromosomes—including 8, 12, 16, and 20—are also reported, although less frequently (35,36). Studies of hereditary papillary RCC have indicated the presence of a papillary RCC gene, recently reported to be the proto-oncogene *c-met*, located at 7q31.1–34 (37,38). The origin of papillary RCC is uncertain. Tumors express antigens related to both proximal and distal tubules. Some reports have suggested that the eosinophilic subtype originates in the proximal tubules, and the basophilic type in the distal tubules (39).

6.2. Pathologic Features

Papillary RCC is well-circumscribed, and often is surrounded by a thick capsule. The tumor is tan to brown to red-brown in color. It often reflects hemorrhage with a friable cut surface, giving an impression of extensive necrosis; the amount of necrosis is often less than suspected from the gross appearance. Cystic degeneration may be prominent, and areas of calcification may be grossly evident.

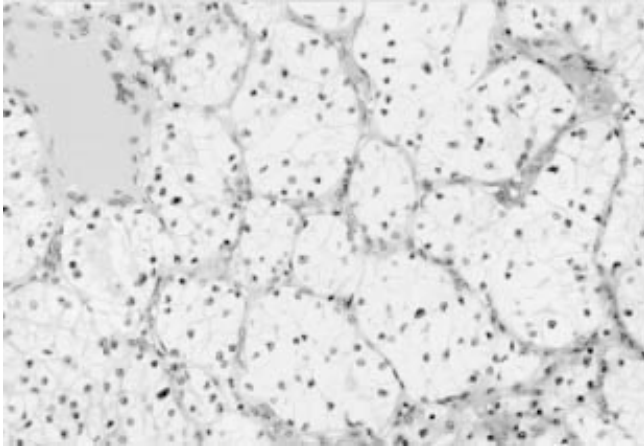


Fig. 2. Conventional (clear-cell) renal carcinoma. In this typical example the tumor cells have clear cytoplasm and are arranged in small nests that are separated from each other by a prominent sinusoidal vascular network.

The majority of tumors have a papillary or tubulo-papillary architecture. These may be tightly packed, resulting in a highly cellular tumor. The papillary structures often contain large numbers of foamy macrophages in the stalks (**Fig. 3**). The papillary stalks may be sclerotic or edematous, with broad papillae. Hemorrhage is often present, with abundant hemosiderin that is frequently within the tumor-cell cytoplasm. Psammoma bodies may be present, but are an inconsistent feature. Sarcomatoid morphology occurs, but is distinctly rare. These tumors tend to have dense granular cytoplasm, and are subclassified as basophil or eosinophil types. Less frequently, both coexist, resulting in so-called duophil neoplasms. In the basophil type, nuclei are typically small and hyperchromatic, with dense chromatin and occasional nuclear grooves, and mitoses are rare. Eosinophil tumors have cuboidal to columnar cells with more abundant and intensely eosinophilic cytoplasm. Eosinophil tumors are of higher nuclear grade (**33,34**), and in one report were more often locally advanced (**33**).

6.3. Special Studies

Papillary tumors express low mol-wt cytokeratins including cytokeratin 7: in one series, 83% of basophil and 20% of eosinophil tumors were CK7-positive (**40**). The reported coexpression of vimentin has ranged from 0–80%

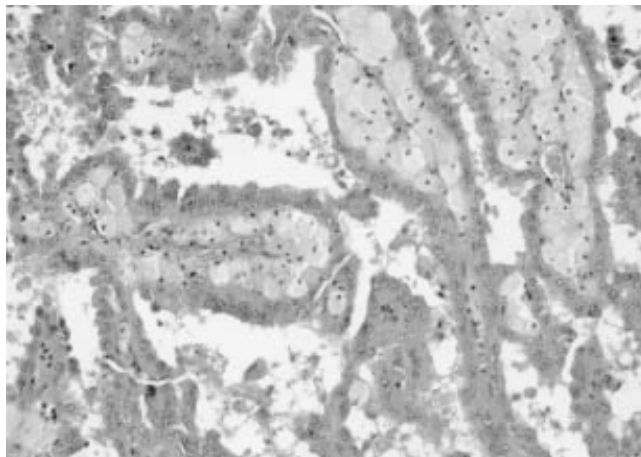


Fig. 3. Papillary carcinoma. This example of the eosinophilic type of papillary carcinoma is composed of tall columnar tumor cells with abundant eosinophilic cytoplasm covering the papillary stalks. Note the presence of abundant foamy macrophages within the papillary cores.

(33,40). *Ulex europaeus*, a marker of collecting-duct epithelium, is negative (33). Weak reactivity to CEA has been reported in a few cases (32). The cells contain scant glycogen, and do not stain with Hale's colloidal iron (except for the hemosiderin). Ultrastructurally, the cytoplasm is complex, with abundant organelles (3).

7. Chromophobe Carcinoma

7.1. Clinical Features

Chromophobe-cell carcinoma was first defined as a distinctive pathologic entity by Thoenes and colleagues in 1985 (41), comprising approx 5% of adult renal epithelial tumors. It occurs predominantly in middle-aged patients, and does not exhibit a sex preference. Emerging data indicates that it has a better prognosis than conventional RCC (42,43). Chromophobe carcinoma is believed to arise from intercalated cells in the renal collecting ducts (44). Cytogenetically, the tumor is distinctive, with the presence of multiple monosomies involving chromosomes 1, 2, 10, 13, 6, 21, and 17 (in descending order of frequency) (45,46).

7.2. Pathologic Features

Chromophobe carcinoma has a homogeneous tan to brown color, similar to that seen in renal oncocytoma. A central scar is not a feature, and areas of hemorrhage and necrosis may be present. Cystic degeneration is rare, and usually only small cysts are seen.

Microscopically, chromophobe tumors have two forms: a classical type and an eosinophilic variant. The typical appearance (*classical variant*) is of cells with voluminous pale eosinophilic cytoplasm, often with perinuclear clearing and more intense staining adjacent to the cell membrane (**Fig. 4**). Careful examination shows the cytoplasm to have a more reticular than granular appearance. Nuclei tend to be centrally located, but may be eccentric and have coarse chromatin with variable nucleoli. The nuclear membrane may be wrinkled, producing a raisin-like appearance. Mitoses are usually present, but may be scant. In a small percentage of cases, the cytoplasm shows a more intense eosinophilia mimicking renal oncocytoma (*eosinophilic variant*). These cells also often have perinuclear clearing, and in most instances, classical areas can be found (at least focally). Sarcomatoid variants are rare, but have been described (47).

7.3. Special Studies

Through immunohistochemistry, tumors express low mol-wt cytokeratin but not vimentin (25,48). Epithelial-membrane antigen is expressed (42). Hale's colloidal iron is uniformly positive, with a reticular pattern of cytoplasmic staining (25,49). The ultrastructural features are highly distinctive, with the cytoplasm containing abundant vesicular structures (50). Occasionally these contain internal smaller vesicles. It has been suggested that these vesicles derive from the mitochondrial membrane. The cells also contain variable numbers of mitochondria, and in the eosinophilic variant these may be quite numerous.

8. Collecting-Duct Carcinoma

8.1. Clinical Features

The first description of collecting-duct carcinoma is attributed to Mancilla-Jimenez et al. who described three cases of papillary RCC in which atypical hyperplastic changes were noted in the collecting-duct epithelium (51). Since then, several reports have appeared further detailing the clinical and pathologic features of this tumor (52,53), and the topic has recently been reviewed by Srigley and Eble (54). Although few cases have been reported to date, some clinical comments may be made. These tumors occur in a younger age group than typical RCC and have a very aggressive course. In a study from the M.D. Anderson Cancer Center, the median survival of 10 patients was only 22 mo (55). Davis and colleagues recently reported an association between sickle-cell disease and a tumor they termed *renal medullary carcinoma*; these

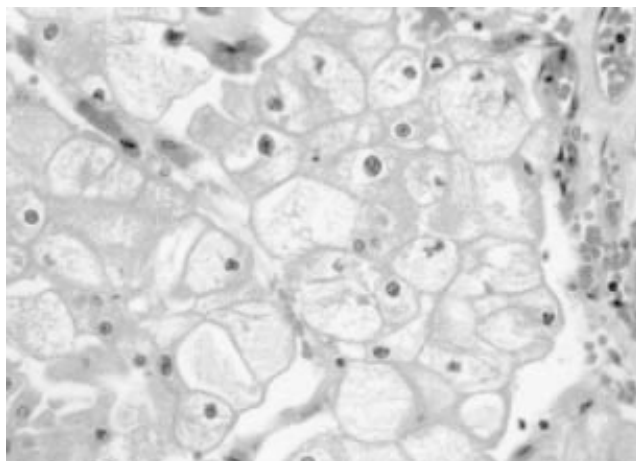


Fig. 4. Chromophobe carcinoma. In the classical type illustrated in this photomicrograph, the tumor cells have voluminous cytoplasm with a reticular appearance and apparent thick-cell membranes resulting from the concentration of organelles at the periphery of the cytoplasm.

also were postulated to originate in the collecting ducts (56). The presentation is similar to other malignant kidney tumors. The cases of this variant reported to date have been very aggressive, with most dying within 1 yr of diagnosis. Finally, low-grade tumors of putative collecting-duct origin have also been reported; and these patients have a good prognosis, with 1 in 10 dying of tumor (57).

Cytogenetic analysis of collecting-duct carcinoma has yielded variable results (2). Among the most frequent findings have been monosomy of chromosome 18 (58), and loss of heterozygosity on chromosome 1q (59).

8.2. Pathologic Features

Collecting-duct carcinoma is located in the renal medulla, although in larger tumors this may not be apparent. It has an infiltrative growth pattern with a white or gray color, and variegation is common, with frequent areas of necrosis. The classical histology is a mixed papillary and infiltrative tubular architecture. The infiltrative component is associated with stromal desmoplasia (Fig. 5). In most cases, foci of dysplasia or “carcinoma *in situ*” may be found in the collecting ducts. Typically, the tumors are of high nuclear grade, corresponding to Fuhrman grades 3 or 4. Sarcomatoid differentiation has been reported in collecting-duct carcinoma (60).

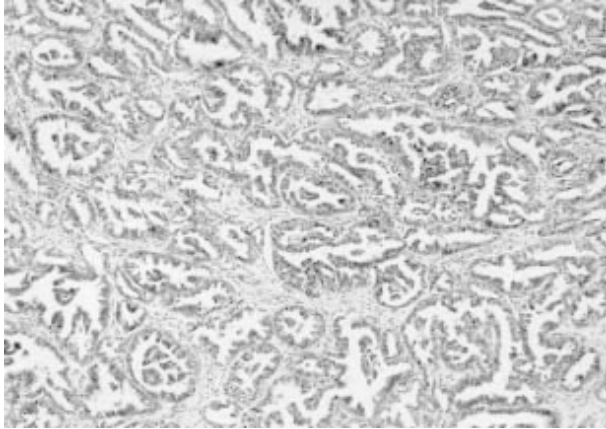


Fig. 5. Collecting-duct carcinoma. The tumor in this case shows a complex papillary ductal architecture with a desmoplastic stroma in the background.

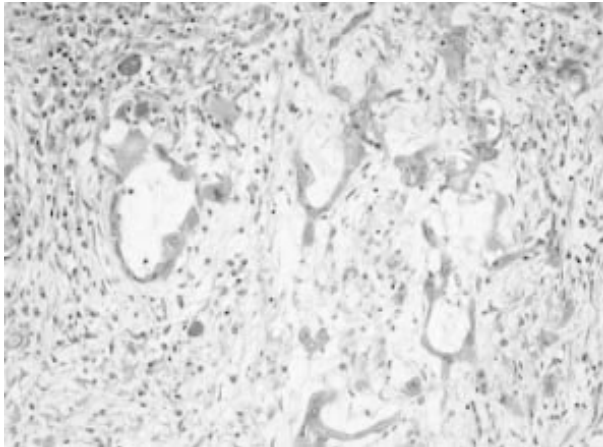


Fig. 6. Medullary carcinoma. In this case the tumor shows the "yolk sac-like" architecture that is most characteristic of this variant of collecting-duct carcinoma.

With medullary carcinoma, the most characteristic feature is a reticular or yolk sac-like appearance combined with adenoid cystic-like areas (**Fig. 6**). In

other areas, tumor cells occur in sheets. An infiltrate of polymorphonuclear leukocytes is usually present. Individual cells have pleomorphic nuclei, with frequent mitoses. In most cases, a prominent desmoplastic stromal response is noted. Sickled erythrocytes may be identified.

Low-grade tumors of presumed collecting-duct origin have been characterized by a predominantly tubulocystic pattern of growth. Mucin positivity was a feature of all cases described, including cytoplasmic staining.

8.3. Special Studies

Collecting-duct carcinoma usually contains relatively small amounts of glycogen, and occasionally focal cytoplasmic mucin is present (61). Immunohistochemical studies support a collecting-duct origin with positivity for high mol-wt cytokeratin (cytokeratin 19), peanut-lectin agglutinin, and *U. europus* agglutinin (53).

References

1. Fleming, S. (1993) The impact of genetics on the classification of renal carcinoma. *Histopathology* **22**, 89–92.
2. Zambrano, N. R., Lubensky, I. A., Merino, M. J., Linehan, W. M., and Walther, M. M. (1999) Histopathology and molecular genetics of renal tumors: toward unification of a classification system. *J. Urol.* **162**, 1246–1258.
3. Thoenes, W., Störkel, S., and Rumpelt, H. J. (1986) Histopathology and classification of renal cell tumors (adenomas, oncocytomas, and carcinomas). *Path. Res. Pract.* **181**, 125–143.
4. Störkel, S., Eble, J. N., Adlakha, K., Amin, M., Blute, M. L., and Bostwick, D. G. (1997) Classification of renal cell carcinoma: workgroup 1. *Cancer* **80**, 987–989.
5. Kovacs, G., Akhtar, M., Beckwith, B. J., Bugert, P., Cooper, P., Cooper, C. S., Delahunt, B., Eble, J. N., Fleming, S., Ljungberg, B., Medeiros, L. J., Moch, H., Reuter, V. E., Ritz, E., Roos, G., Schmidt, D., Srigley, J. R., Störkel, S., van den Berg, E., and Zbar, B. (1997) The Heidelberg classification of renal cell tumors (editorial). *J. Pathol.* **183**, 131–133.
6. Kovacs, G. (1993) Molecular differential pathology of renal cell tumors. *Histopathology* **2**, 1–8.
7. Gnarr, J. R., Tory, K., Weng, Y., Schmidt, L., Wei, M. H., Li, H., Latif, F., Liu, S., Chen, F., and Duh, F. M. (1994) Mutations of the VHL tumour suppressor gene in renal carcinoma. *Nat. Genet.* **7**, 85–90.
8. Schwerdtle, R. F., Störkel, S., Neuhaus, C., Brauch, H., Weidt, E., Brenner, W., Hohenfellner, R., Huber, C., and Decker, H. J. (1996) Allelic losses at chromosomes 1p, 2p, 6p, 10p, 13q, 17p and 21q significantly correlate with the chromophobe subtype of renal cell carcinoma. *Cancer. Res.* **56**, 2927–2930.
9. Grignon, D. J. and Eble, J. N. (1998) Papillary and metanephric adenomas of the kidney. *Semin. Diagn. Pathol.* **15**, 41–53.
10. Eble, J. and Warfel, K. (1991) Early human renal cortical epithelial neoplasia. *Mod. Pathol.* **4**, 45A.

11. Hughson, M. D., Buchwald, D., and Fox, M. (1986) Renal neoplasia and acquired cystic kidney disease in patients receiving long-term dialysis. *Arch. Pathol. Lab. Med.* **110**, 592–601.
12. Delahunt, B. and Eble, J. N. (1997) Papillary adenoma of the kidney: an evolving concept. *J. Urological Pathol.* **7**, 99–112.
13. Jones, E. C., Pins, M., Dickersin, R. D., and Young, R. H. (1995) Metanephric adenoma of the kidney: a clinicopathological, immunohistochemical, flow cytometric, cytogenetic and electron microscopic study of seven cases. *Am. J. Surg. Pathol.* **19**, 615–626.
14. Davis, C. J. Jr., Barton, J. H., Sesterhenn, I. A., and Mostofi, F. K. (1995) Metanephric adenoma: clinicopathological study of fifty patients. *Am. J. Surg. Pathol.* **19**, 1101–1114.
15. Gatalica, Z., Gruzic, S., Kovatich, A., and Petersen, R. O. (1996) Metanephric adenoma: histology, immunophenotype, cytogenetics, ultrastructure. *Mod. Pathol.* **9**, 329–333.
16. Brown, J. A., Anderl, K. L., Borell, T. J., Qian, J., Bostwick, D. G., and Jenkins, R. B. (1997) Simultaneous chromosome 7 and 17 gain and sex chromosome loss provide evidence that renal metanephric adenoma is related to papillary renal cell carcinoma. *J. Urol.* **158**, 370–374.
17. Klein, M. J. and Valensi, Q. J. (1976) Proximal tubular adenomas of the kidney with so-called oncocytic features: a clinicopathologic study of 13 cases of a rarely reported neoplasm. *Cancer* **38**, 906–914.
18. Merino, M. J. and LiVolsi, V. A. (1982) Oncocytomas of the kidney. *Cancer* **50**, 1852–1856.
19. Barnes, C. A. and Beckman, E. N. (1983) Renal oncocytoma and its congeners. *Am. J. Clin. Pathol.* **79**, 312–318.
20. Amin, M. B., Crotty, T. B., Tickoo, S. K., and Farrow, G. M. (1997) Renal oncocytoma: a reappraisal of morphologic features with clinicopathologic findings in 80 cases. *Am. J. Surg. Pathol.* **21**, 1–12.
21. Lyzak, J. S., Farhood, A., and Verani, R. (1994) Intracytoplasmic lumens in renal oncocytoma and possible origin from intercalated cells of the collecting duct. *J. Urol. Pathol.* **2**, 135–151.
22. Warfel, K. A. and Eble, J. N. (1982) Renal oncocytomatosis. *J. Urol.* **127**, 1179–1180.
23. Slagel, D. and Bonsib, S. M. (1995) Renal oncocytoma with unusual features: case report and review of morphologic variants of oncocytoma. *J. Urol. Pathol.* **3**, 223–233.
24. Perez-Ordóñez, B., Hamed, G., Campbell, S., Erlandson, R. A., Russo, P., Gaudin, P. B., and Reuter, V. E. (1997) Renal oncocytoma: a clinicopathologic study of 70 cases. *Am. J. Surg. Pathol.* **21**, 871–883.
25. DeLong, W. H., Sakr, W. A., and Grignon, D. J. (1996) Chromophobe renal cell carcinoma: a comparative histochemical and immunohistochemical study. *J. Urol. Pathol.* **4**, 1–8.

26. Ogawa, O., Kakehi, Y., Ogawa, K., Koshiba, M., Sugiyama, T., and Yoshida, O. (1991) Allelic loss at chromosome 3p characterizes clear cell phenotype of renal cell carcinoma. *Cancer. Res.* **51**, 949–953.
27. Solomon, D. and Schwartz, A. (1988) Renal pathology in von Hippel-Lindau disease. *Hum. Pathol.* **19**, 1072–1079.
28. Washecka, R. and Hanna, M. (1991) Malignant renal tumors in tuberous sclerosis. *Urology* **37**, 340–343.
29. Fuhrman, S. A., Lasky, L. C., and Limas, C. (1982) Prognostic significance of morphologic parameters in renal cell carcinoma. *Am. J. Surg. Pathol.* **6**, 655–663.
30. Grignon, D. J., Ayala, A. G., El-Naggar, A. K., Wishnow, K. I., Ro, J. Y., Swanson, D. A., McLemore, D., Giacco, G. G., and Guinee, V. F. (1989) Renal cell carcinoma: a clinicopathologic and DNA flow cytometric analysis of 103 cases. *Cancer* **64**, 2133–2140.
31. El-Naggar, A. K., Ro, J. Y., and Ensigen, L. G. (1993) Papillary renal cell carcinoma: clinical implication of DNA content analysis. *Hum. Pathol.* **24**, 316–321.
32. Renshaw, A. A. and Corless, C. L. (1995) Papillary renal cell carcinoma: histology and immunohistochemistry. *Am. J. Surg. Pathol.* **19**, 842–849.
33. Delahunt, B. and Eble, J. N. (1997) Papillary renal cell carcinoma: a clinicopathologic and immunohistochemical study of 105 tumors. *Mod. Pathol.* **10**, 537–544.
34. Amin, M. B., Corless, C. L., Renshaw, A. A., Tickoo, S. K., Kubus, J., and Schultz, D. S. (1997) Papillary (chromophil) renal cell carcinoma: histomorphologic characteristics and evaluation of conventional pathologic prognostic parameters in 62 cases. *Am. J. Surg. Pathol.* **21**, 621–635.
35. Kovacs, G. (1989) Papillary renal cell carcinoma: a morphologic and cytogenetic study of 11 cases. *Am. J. Pathol.* **134**, 27–34.
36. Van Den Berg, E., van der Hout, A. H., Oosterhuis, J. W., et al. (1993) Cytogenetic analysis of epithelial renal-cell tumours: rRelationship with a new histopathological classification. *Int. J. Cancer* **55**, 223–227.
37. Zbar, B., Glenn, G., Lubensky, I., Choyke, P., Walther, M. M., Magnusson, G., Bergerheim, U. S., Pettersson, S., Amin, M., and Hurley, K. (1995) Hereditary papillary renal cell carcinoma: clinical studies in 10 families. *J. Urol.* **153**, 907–912.
38. Schmidt, L., Duh, F. M., Chen, F., Kishida, T., Glenn, G., Choyke, P., Scherer, S. W., Zhuang, Z., Lubensky, I., Dean, M., Allikmets, R., Chidabaram, A., Bergerheim, U. R., Feltis, J. T., Casadevall, C., Zamarron, A., Bernues, M., Richard, S., Lips, C. J., Walther, M. M., Tsui, L. C., Geil, L., Orcutt, M. L., Stackhouse, T., and Zbar, B. (1997) Germline and somatic mutations in the tyrosine kinase domain of the MET proto-oncogene in papillary renal carcinomas. *Nat. Genet.* **16**, 68–73.
39. Hughson, M. D., Johnson, L. D., Silva, F. G., and Kovacs G. (1993) Nonpapillary and papillary renal cell carcinoma: a cytogenetic and phenotypic study. *Mod. Pathol.* **6**, 449–456.
40. Gatalica, Z., Kovatich, A., and Miettinen, M. (1995) Consistent expression of cytokeratin 7 in papillary renal-cell carcinoma: An immunohistochemical study in formalin-fixed, paraffin-embedded tissues. *J. Urol. Pathol.* **3**, 205–211.

41. Thoenes, W., Störkel, S., and Rumpelt, H.-J. (1985) Human chromophobe cell renal carcinoma. *Virchows Arch. (Cell Pathol.)* **48**, 207–217.
42. Akhtar, M., Kardar, H., Linjawi, T., McLintock, J., and Ali, M. A. (1995) Chromophobe cell carcinoma of the kidney: a clinicopathologic study of 21 cases. *Am. J. Surg. Pathol.* **19**, 1245–1256.
43. Thoenes, W., Störkel, S., Rumpelt, H.-J., Moll, R., Baum, H. P., and Werner, S. (1988) Chromophobe cell renal carcinoma and its variants—a report on 32 cases. *J. Pathol.* **155**, 277–287.
44. Störkel, S., Steart, P. V., Drenckhahn, D., and Thoenes, W. (1989) The human chromophobe cell renal carcinoma: its probable relation to intercalated cells of the collecting duct. *Virchows Arch. (Cell Pathol.)* **56**, 237–245.
45. Kovacs, A. and Kovacs, G. (1992) Low chromosome number in chromophobe renal cell carcinomas. *Genes Chromosomes Cancer* **4**, 267–268.
46. Speicher, M. R., Schoell, B., du Manoir, S., Schrock, E., Ried, T., Cremer, T., Störkel, S., Kovacs, A., and Kovacs, G. (1994) Specific loss of chromosomes 1,2,6,10,13,17, and 21 in chromophobe renal cell carcinomas revealed by comparative genomic hybridization. *Am. J. Pathol.* **145**, 356–364.
47. Aizawa, S., Chigusa, M., Ohno, Y., and Suzuki, M. (1997) Chromophobe cell renal carcinoma with sarcomatoid component: a report of two cases. *J. Urol. Pathol.* **6**, 51–59.
48. Pitz, S., Moll, R., Störkel, S., and Thoenes, W. (1987) Expression of intermediate filament proteins in subtypes of renal cell carcinomas and in renal oncocytomas. *Lab. Invest.* **56**, 642–653.
49. Tickoo, S. K., Amin, M. B., and Zarbo, R. J. (1998) Colloidal iron staining in renal epithelial neoplasms, including chromophobe renal cell carcinoma: emphasis on technique and patterns of staining. *Am. J. Surg. Pathol.* **22**, 419–424.
50. GerHarz, C.-D., Moll, R., Störkel, S., Ramp, U., Thoenes, W., and Gabbert, H. E. (1993) Ultrastructural appearance and cytoskeletal architecture of the clear, chromophilic, and chromophobe types of human renal cell carcinoma in vitro. *Am. J. Pathol.* **142**, 851–859.
51. Mancilla-Jimenez, R., Stanley, R. J., and Blath, R. A. (1976) Papillary renal cell carcinoma. *Cancer* **38**, 2469–2480.
52. Fleming, S. and Lewi, H. J. E. (1986) Collecting duct carcinoma of the kidney. *Histopathology* **10**, 1131–1141.
53. Rumpelt, H. J., Störkel, S., Moll, R., Scharfe, T., and Thoenes, W. (1991) Bellini duct carcinoma: further evidence for this rare variant of renal cell carcinoma. *Histopathology* **18**, 115–122.
54. Srigley, J. R. and Eble, J. N. (1998) Collecting duct carcinoma of kidney. *Semin. Diagn. Pathol.* **15**, 54–67.
55. Dimopoulos, M. A., Logothetis, C. J., Markowitz, A., Sella, A., Amato, R., and Ro, J. Collecting duct carcinoma of the kidney. *Br. J. Urol.* **71**, 388–391.
56. Davis, C. J., Jr., Mostofi, F. K., and Sesterhenn, I. A. (1995) Renal medullary carcinoma: the seventh sickle cell nephropathy. *Am. J. Surg. Pathol.* **19**, 1–11.

57. MacLennan, G. T., Farrow, G. M., and Bostwick, D. G. (1997) Low-grade collecting duct carcinoma of the kidney: report of 13 cases of low-grade mucinous tubulocystic renal carcinoma of possible collecting duct origin. *Urology* **50**, 679–684.
58. Gregori-Romero, M. A., Morell-Quadreny, L., and Llombart-Bosch, A. (1996) Cytogenetic analysis of three Bellini duct carcinomas. *Genes Chromosomes Cancer* **15**, 170–172.
59. Steiner, G., Cairns, P., Polascik, T. J., Marshall, F. F., Epstein, J. I., Sidransky, D., and Schoenberg, M. (1996) High-density mapping of chromosomal arm 1q in renal collecting duct carcinoma: region of minimal deletion at 1q32.1-32.2. *Cancer Res.* **56**, 5044–5046.
60. Baer, S. C., Ro, J. Y., Ordonez, N. G., Maiese, R. L., Loose, J. H., Grignon, D. J., and Ayala, A. G. (1993) Sarcomatoid collecting duct carcinoma: a clinicopathologic and immunohistochemical study of five cases. *Hum. Pathol.* **24**, 1017–1022.
61. Kennedy, S. M., Merino, M. J., Linehan, W. M., Roberts, J. R., Robertson, C. N., and Neumann, R. D. (1990) Collecting duct carcinoma of the kidney. *Hum. Pathol.* **21**, 449–456.



<http://www.springer.com/978-0-89603-828-8>

Renal Cancer

Methods and Protocols

Mydlo, J.H. (Ed.)

2001, XII, 403 p. 55 illus., Hardcover

ISBN: 978-0-89603-828-8

A product of Humana Press