

FUNCTIONAL ANATOMY OF THE BRAIN STEM **11-33**

strated severe problems:

1) On attempted gaze to the left; a total paralysis of left CN VI plus a lesser paresis of conjugate lateral gaze as regards the right eye.

2) On gaze to the right a) full abduction of the right eye, b) some adduction of the left eye but this was incomplete, and c) coarse nystagmus of the abducting right eye.

3) In primary gaze, the left eye was slightly medial.

4) Convergence was intact for both eyes.

5) Up gaze was intact but minor vertical nystagmus was present.

Conclusions were:

1) Left CN VI paralysis.

2) Left lateral gaze center involved

3) Left medial longitudinal fasciculus involved.

The remainder of the neurological examination was normal.

Clinical Diagnosis: Tumor in pons at the level of the facial colliculus.

This case has been reported in detail by Jockel et al, 1986.

CASE HISTORY 11-2.

This 16-year-old, white male in November was first noted to be lethargic. Gradually from November to March there was progressively poor performance in school with apathy and somnolence. In December the patient had the onset of diplopia with difficulty in reading. In March of the next year he began to sleep throughout the day and could be awakened only with difficulty. Headaches on arising, with nausea and vomiting had been noted. In April evaluation at the Buffalo General Hospital had revealed that the pupils failed to respond to light but did respond to accommodation. Upward gaze was intermittently defective, and conjugate lateral gaze was intact. Findings improved to some degree over a 3-day period.

On the day of admission, an episode of urinary incontinence occurred.

Neurological Examination:

1. *Mental status:* All areas were relatively

intact except for a slowness of response, emotional lability, and immaturity of behavior and questions.

2. *Cranial nerves:*

a. The right eye was deviated outward; the patient was unable to converge. There was a paralysis of upward and downward gaze. Bilateral lid ptosis was present. However, spasm of the eyelids was easily stimulated. Pupils were sluggish in response to light. The right pupil was slightly larger than the left. Horizontal nystagmus was present.

b. The jaw jerk was hyperactive.

c. Guttural and lingual sounds were slurred in a pattern that was consistent with pseudobulbar palsy.

d. Hearing was decreased bilaterally.

3. *Motor system:*

a. Strength was intact.

b. Spasticity was present on passive motion in the lower extremities and possibly in the upper extremities.

c. There was slowness in alternating hand movements. A fixed facies was present.

d. A bilateral intention tremor was present on finger-to-nose testing.

e. Gait was broad-based with truncal ataxia.

4. *Reflexes:*

a. Deep tendon reflexes were hyperactive bilaterally with ankle clonus.

b. Plantar responses were extensor bilaterally (bilateral sign of Babinski).

Clinical Diagnosis: Possible pineal region tumor.

ADDENDUM:

Anatomical Basis of Decerebrate Rigidity.

(Fig 11-12) The studies of Sherrington demonstrated that the corticospinal tracts—that is, pyramidal tracts—were not involved in decerebrate rigidity since with hemisection of the brain stem at the intercollicular level the unilateral rigidity which occurred was ipsilateral to the hemisection. Sherrington also was able to indicate that deafferentation decreased rigidity in a limb. Decerebrate rigidity was conceived to be a release phenomenon.

The studies of Magoun and Rhines (1946)

11-34 CHAPTER 11

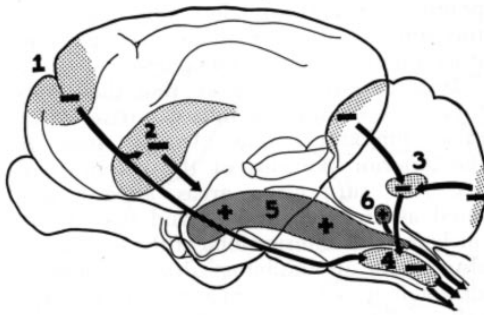


Figure 11-12 Reconstruction of the cat's brain showing the suppressor and facilitatory systems concerned in spasticity. Suppressor pathways are 1, corticobulboreticular; 2, caudatospinal; 3, cerebelloreticular; and 4, reticulospinal. Facilitatory pathways are 5, reticulospinal and 6, vestibulospinal. (From Lindsley, D. B., Schreiner, L. H., and Magoun, H. A.: J. Neurophys., 12:198, 1949.)

demonstrated that stimulation of the reticular formation in a ventromedial area of the medullary tegmentum produced a decrease in decerebrate rigidity, a decrease in the quadriceps deep tendon reflex, and a decrease in the movement which could be elicited by simultaneously stimulating the motor cortex. This area was labeled the *bulbar reticular inhibitory area*. From an anatomical standpoint the inhibitory area of the medulla corresponds to the nucleus reticularis gigantocellularis. The neurons of this nucleus give rise to the lateral reticulospinal tract which is found in the lateral column of the spinal cord.

In contrast, stimulation of a region of the reticular formation in the pons and midbrain resulted in an increase in the degree of decerebrate rigidity. In addition, the quadriceps deep tendon reflex (the knee jerk) was increased and responses to stimulation of the motor cortex were facilitated. This facilitatory area extends into the subthalamus, the adjacent hypothalamus, and the intralaminar areas of the thalamus (e.g., centrum medianum). This area in the more lateral tegmental reticular formation in the pons and midbrain may be termed a *brain stem* (or *bulbar reticular*) *facilitatory area*. From an anatomical standpoint the facilitatory area of the pons corresponds to the nucleus reticularis pontis oralis and caudalis.* The neurons of this nucleus give rise to that medial reticulospinal tract found

in the anterior column.

It is important to note that the inhibitory area of the medulla is driven from other inhibitory areas. Among these are the anterior portions of the cerebral cortex (the suppressor areas indicated as areas 4S and 8) and the caudate nucleus. The anterior lobe of the cerebellum also exerts an inhibitory driving influence although it is uncertain whether this cerebellar influence is as significant in primates and man as in the cat. It is now recognized that flexors and extensors are not equally affected by these facilitatory and inhibitory systems. Rather, it is more proper to speak of these areas as *bulbar reticular extensor inhibitory area* (since actually flexor tone is increased by stimulation of these areas) and *bulbar reticular extensor facilitatory area* (since flexor tone is decreased by stimulation of this area). In the decerebrate animal the effects of the extensor facilitatory system predominate because the extensor inhibitory system must be driven from higher centers. These higher centers, of course, are disconnected from the inhibitory area in the brain stem by the section through the brain stem. On the other hand, the facilitatory center is driven by afferent inputs from below, that is, the collaterals of ascending sensory fibers derived from the spinothalamic tracts and the trigeminal system.

These brain stem reticular areas give rise to reticulospinal pathways which descend to the spinal cord level to influence stretch reflexes. In addition, vestibular centers give rise to facilitatory vestibulospinal pathways which may also influence to some degree stretch reflexes.

As regards the effects of these brain stem reticular centers on stretch reflexes, one may postulate two possible mechanisms of action. There might well be a facilitation or inhibition of large alpha motor neurons. On the other hand, these centers might exert their effects through a facilitation or inhibition of the small gamma neurons. This latter situation would alter tension on the spindle and change the rate of discharge of the muscle spindle.

Granit and Kaada have demonstrated that stimulation of the facilitatory area did augment the spindle discharge. Stimulation of the inhibitory area reduced the spindle discharge. Both effects, then, were exerted via the gamma

system. Classic decerebrate rigidity may be considered essentially "*gamma rigidity*."

Alpha rigidity is less common and results when the cerebellum, particularly the anterior cerebellum, is destroyed in the decerebrate preparation (anemic decerebrate preparation) produced by vascular occlusion. The facilitatory effect may be exerted on the alpha motor neuron by the vestibulospinal tract. There is some evidence that although alpha rigidity may occur in the cat, this is probably not a significant form of rigidity in the primate.

*As discussed previously the nucleus gigantocellularis and the nucleus reticularis pontis oralis and caudalis may be considered as a relatively continuous cell column within the reticular formation, with a major role in reticulospinal motor activities. The other major cell groupings are the paramedian cell groups (paramedian reticular nuclei and reticulotegmental nucleus) concerned with cerebellar relationships and the lateral reticular nucleus. This lateral area of reticular formation is the major relay area for afferent collateral input to the reticular formation.



<http://www.springer.com/978-1-4020-7164-5>

Integrated Neuroscience
A Clinical Problem Solving Approach
Marcus, E.M.; Jacobson, S.
2003, XIII, 739 p., Hardcover
ISBN: 978-1-4020-7164-5