

2

Role of Laparoscopic Nephrectomy in Metastatic Renal Cell Carcinoma

*Stephen E. Pautler, MD, FRCSC
and McClellan M. Walther, MD, FACS*

CONTENTS

INTRODUCTION
INDICATIONS
CONTRAINDICATIONS
OVERVIEW OF SURGICAL TECHNIQUE
RESULTS
CONTROVERSIAL ISSUES
SHORTCOMINGS OF LAPAROSCOPIC TECHNIQUE
REFERENCES

INTRODUCTION

Renal cell carcinoma (RCC) is a life-threatening disease with a significant health burden to society. In 2001, there were an estimated 12,100 deaths from RCC in the United States (1). Presentation with advanced kidney cancer occurs in approximately one-third of patients (2) leading to significant morbidity and mortality. The use of systemic immunotherapy affords this patient population the best chance at survival, although various trials have demonstrated suboptimal response rates (3,4). Results of recent studies from single institutions and two multicenter randomized trials suggest a survival benefit for patients who underwent cytoreductive nephrectomy followed by some form of systemic immunotherapy (5–7). Unfortunately, many patients are not

From: *Laparoscopic Urologic Oncology*
Edited by: J. A. Cadeddu © Humana Press Inc., Totowa, NJ

fit to receive systemic immunotherapy following surgery. In an effort to decrease morbidity from the procedure and to increase the number of patients fit for systemic treatment, the National Cancer Institute (NCI) group began performing cytoreductive laparoscopic radical nephrectomies (LRNs) in appropriate candidates. Herein, we describe the procedure and the early outcomes.

INDICATIONS

The most broadly accepted indications for surgery in the patient with metastatic kidney cancer are symptoms attributed to the primary tumor. These symptoms include intractable gross hematuria, significant pain due to pressure effects or local invasion, and various debilitating paraneoplastic syndromes in selected patients. Furthermore, in the small population of patients who present with an isolated metastasis, nephrectomy in conjunction with metastasectomy can be curative (8,9). Currently, cytoreductive nephrectomy is considered relative indication for patients with a good performance status despite multiple metastases and who are eligible for inclusion in a clinical trial of systemic therapy for treatment of their metastases. It has been extremely rare to observe a response to systemic immunotherapy in the primary tumor (10). Other rationales for cytoreduction include the reduction in tumor burden and the source of future metastases, for harvesting of tumor-infiltrating leukocytes, and for identification of tumor-specific antigens for trials involving tumor vaccines.

CONTRAINDICATIONS

Resectability of the primary tumor must be assessed on a case-by-case basis. A specific size criterion does not exist to preclude a laparoscopic approach, although the surgeon must be cognizant of adjacent organ involvement, working space limitations, and surgeon experience. Several contraindications do exist including poor performance status of the patient, a level III or greater vena cava tumor thrombus, uncorrectable coagulopathy, and massive intraperitoneal tumor metastases. Relative contraindications to cytoreductive LRN include the patient's unwillingness to participate in a clinical trial of systemic therapy, pregnancy, metastases to the central nervous system, and abnormal body habitus impeding positioning. With respect to adjacent organ involvement, techniques have been developed for laparoscopic resection of the diaphragm (11), tail of the pancreas, and spleen if necessary. Recent reports of advanced laparoscopic management of level I–II vena caval thrombi have been reported (12–14).

OVERVIEW OF SURGICAL TECHNIQUE

Preoperatively, patients undergo a mechanical/antibiotic bowel prep and aggressive hydration through a large intravenous (iv) cannula. Subcutaneous heparin and pneumatic stockings are used for deep vein thrombosis prophylaxis. Additionally, patients receive a single dose of iv first generation cephalosporin prophylaxis. A urethral catheter and an orogastric tube are placed. Nitrous oxide anesthetic is avoided to prevent bowel distension. To maximize the working space between the lower costal margin and the anterior superior iliac spine, the patient is positioned with the affected side up and table flexion is used without the use of a beanbag or kidney rest. Generous padding is required; including an axillary roll and support for the ipsilateral arm (Fig. 1)

The preferred approach is transperitoneal due to the increased working space and the ability to survey the abdominal organs for metastases. We prefer an open access rather than a Veress technique because often times the primary tumors are quite large and there can be distortion of the intra-abdominal anatomy leading to an access-related injury if the Veress needle is employed. The camera port is placed in the ipsilateral paramedian line and two working ports are placed in a triangular fashion to facilitate an ergonomic approach to the kidney (Fig. 2). On the right side, an additional subxiphoid port is required for cephalad retraction of the liver using a fan or snake-type retractor. A retractor holder eliminates the need for an assistant to hold the retractor throughout the case (15). Routine use of the AESOP robotic arm for control of the camera is a useful adjunct to reduce surgical assistant fatigue.

The basic steps of dissection follow those pioneered by Clayman and colleagues (16). Several important considerations deserve attention. The key to the procedure is identification and control of the renal hilum. In cytoreductive LRN, there is a higher risk of renal vein and/or vena cava involvement due to the advanced nature of disease. Once the ureter is identified on the right or the gonadal vein on the left, then cephalad dissection following these structures will lead to the hilum. We recommend isolation of the artery and vein separately using meticulous dissection. A right-angled dissector is useful for separation of the vessels. Counter-traction on the kidney aids in identification of the hilar structures. If the primary tumor is large, standard laparoscopic instruments do not provide enough strength for retraction. A gynecological instrument called the spoon/cup biopsy forceps has a solid shaft that allows even very large tumors to be retracted. During left-sided dissections, the surgeon should ligate the gonadal vein prior to dissecting out the renal vein. The lumbar vein can be in close proximity to the renal artery and requires

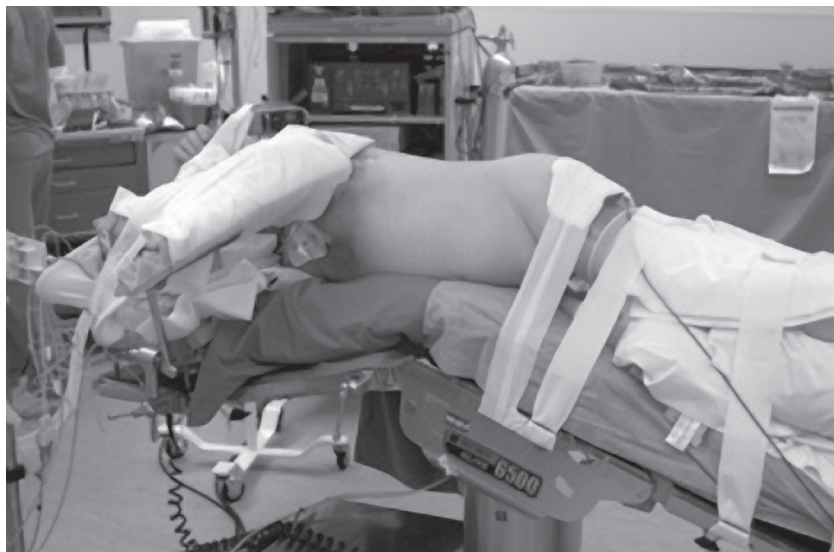

Fig. 1. Patient positioning for cytoreductive laparoscopic radical nephrectomy. Patient is in the flank position with the table flexed and adequate padding of all pressure points.

careful attention. Once the hilum is fully dissected, the artery is ligated using clips or an endovascular-stapling device. Inspection of the renal vein is mandatory to ensure it has collapsed. An instrument can be passed behind the vein to tent it up to ensure the absence of a tumor thrombus or additional arteries. Doppler ultrasound performed using a laparoscopic probe is required if there is any question of tumor thrombus or multiple arteries. The vein is secured using an endovascular stapler.

If adjacent organ resection is required, then the approach should be considered in detail preoperatively. The endovascular staplers are very useful for isolation of the tail of the pancreas and for ligation of the splenic hilum and short gastric arteries if splenectomy is required. Diaphragm resection is occasionally indicated (11,17). A harmonic scalpel or shears provide sufficient vascular control in the majority of cases. During resection, care must be taken not to injure the lung parenchyma or the phrenic nerve. Attention must be paid to the patient's ventilatory status and if hypercarbia or respiratory compromise occurs, then immediate chest tube placement or conversion to open is required (11).

Specimen removal following LRN for localized disease remains somewhat controversial. In the cytoreduction setting, morcellation of the specimen is an attractive option. The data that exists directly com-

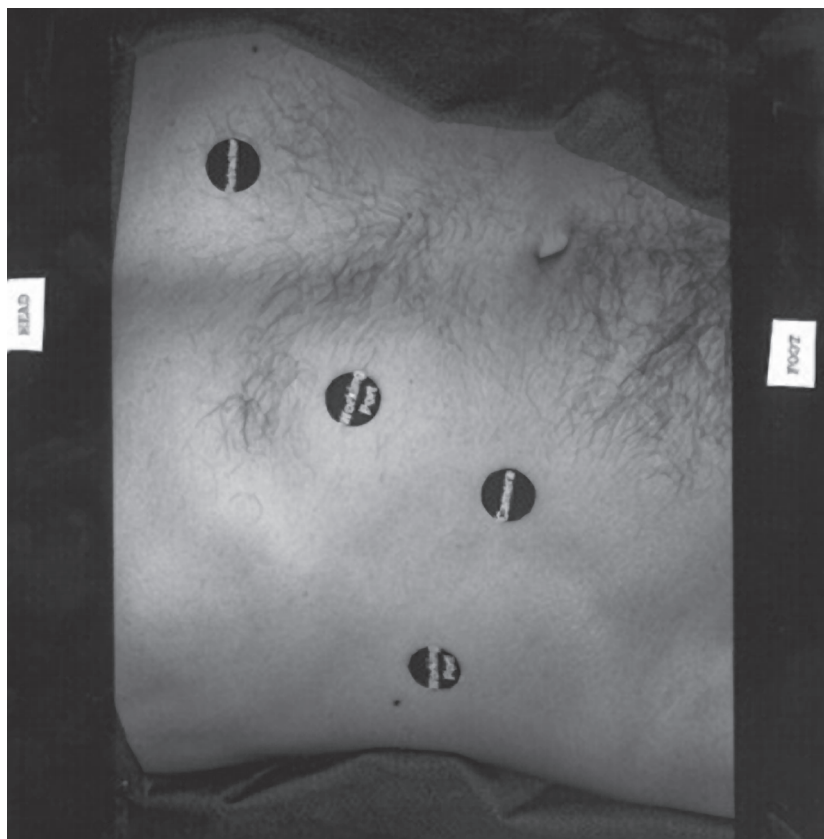


Fig. 2. Port placement for a right-sided cytoreductive laparoscopic radical nephrectomy.

paring intact removal and morcellation in patients undergoing cytoreduction demonstrated an advantage for the morcellation group in terms of postoperative narcotic requirement and time to receive systemic immunotherapy (18). Concern of port-site tumor implantation is less ominous in this population because these patients have documented metastases elsewhere and will be receiving adjuvant therapy. Morcellation requires use of the impermeable LapSac (Cook Urological, Spencer, IN) to prevent tumor spillage. The size limitation of this sack is a specimen diameter of 15 cm. The specimen should freely spin 360° prior to attempting to place it in the sack. Generally, three graspers are used to hold the sack open mandating placement of an additional port in most cases. Recently, a device to hold open the sack has been described (19). Alternatively, a guidewire can be placed through the mouth of the sack

to open it (20). Extra drapes and a skin barrier are used to protect the operative field from tumor spillage.

RESULTS

In the initial NCI pilot series, operative results of cytoreductive LRN revealed significantly longer operative times in comparison to open cytoreduction. Blood loss was not significantly improved via the laparoscopic approach likely reflecting the advanced nature of the disease and difficulty of dissection. Benefits of the pure laparoscopic approach (with specimen morcellation) included less postoperative narcotics, a shorter hospital stay, and a shorter time to the administration of adjuvant high-dose Interleukin (IL)-2 therapy. Previously, up to 38% of patients who underwent open cytoreductive LRN at the NCI were unfit to receive systemic high dose IL-2 due to poor performance status or progressive disease (7,21,22). Mortality associated with open cytoreduction LRN has been reported to be up to 4% in some series (23). To date, no deaths have occurred in hospital following cytoreductive LRN in our series.

Oncologic outcomes are somewhat more difficult to assess. Cytoreductive LRN has been performed in the setting of a large randomized phase III trial of systemic IL-2 therapy, thus limiting the ability to draw any conclusions about the efficacy of LRN in these patients. Clearly, adjuvant therapy is required for these patients and the current standard of care in the United States is systemic IL-2 therapy. With respect to laparoscopy-specific oncology outcomes, no port-site recurrences have occurred.

Cytoreductive LRN is comparable to open cytoreductive nephrectomy with significant complication rates ranging from 13 to 50% (21,22,24–26). The type and severity of complications are similar for the two approaches including blood loss and postoperative ileus. The blood loss seen with laparoscopic cytoreduction is greater than that during LRN for localized disease likely due to the abundant tumor vessels, adjacent organ involvement, and the bulky hilar lymphadenopathy found with advanced disease. We have observed a disproportionate number of cases of skin blistering and even cases of contralateral psoas necrosis due to the prolonged operating times with the patients in the flank position during cytoreductive LRN.

CONTROVERSIAL ISSUES

Experience with cytoreductive LRN is limited. Walther et al. published the largest series to date. There was a statistically significant improvement in morbidity measures such as postoperative narcotic use and time to

treatment with immunotherapy. To date, these results have yet to be validated at other institutions. For cytoreductive LRN to be fairly assessed, a multicenter prospective trial involving experienced laparoscopic urologic oncologists will have to be completed to prove benefit.

Further information has been published suggesting that the presence of retroperitoneal lymphadenopathy portends a poor prognosis in patients with metastatic kidney cancer (27). Additionally, the UCLA group has found that patients with lymphadenopathy at the time of cytoreductive nephrectomy who do not undergo debulking lymphadenectomy have a poorer survival. Thus, if lymphadenopathy is present at the time of cytoreduction, the surgeon should endeavor to perform a lymphadenectomy. Using the laparoscopic approach, retroperitoneal lymphadenectomy can be performed, although no data currently exists regarding the completeness of the dissection or outcomes for metastatic kidney cancer. Clearly, further study is required.

The last subject of controversy remains specimen morcellation. As mentioned earlier, morcellation is an attractive option for patients with metastatic kidney cancer because these patients are able to receive systemic immunotherapy sooner and require less postoperative analgesia (18). Some authors have argued that intact removal and morcellation lead to the same analgesia requirement in the localized kidney cancer setting (28), but these tumors were all small relative to those found at the time of cytoreduction where the incision for intact removal can be quite large. Obtaining an accurate pathological diagnosis is critical prior to the administration of systemic therapy and morcellation in the cytoreductive setting does provide sufficient material for diagnosis (29).

SHORTCOMINGS OF LAPAROSCOPIC TECHNIQUE

Cytoreductive LRN remains a new technique with few centers performing the procedure. To date, the results of an initial pilot series are encouraging although further study must be done to determine the suitability of this procedure in the management of patients with metastatic kidney cancer. The laparoscopic technique is not recommended for patients with large tumor thrombi or extensive adjacent organ involvement in which massive reconstructive procedures will be required. The feasibility and thoroughness of lymphadenectomy for enlarged nodes remains to be proven.

REFERENCES

1. American Cancer Society. Cancer Facts and Figures; 2001.
2. Hock LM, Lynch J, Balaji KC. Increasing incidence of kidney cancer in the last 2 decades in the United States: An analysis of surveillance, epidemiology and end results program data. *J Urol* 2002; 167: 57–60.

3. Fyfe G, Fisher RI, Rosenberg SA, et al. Results of treatment of 255 patients with metastatic renal cell carcinoma who received high-dose recombinant interleukin-2 therapy. *J Clin Oncol* 1995; 13: 688–696.
4. Figlin RA. Renal cell carcinoma: Management of advanced disease. *J Urol* 1999; 161: 381–387.
5. Flanigan RC, Salmon SE, Blumenstein BA, et al. Nephrectomy followed by interferon alfa-2b compared with interferon alfa-2b alone for metastatic renal-cell cancer. *N Engl J Med* 2001; 345: 1655–1659.
6. Mickisch GHJ, Garin A, van Poppel H, et al. Radical nephrectomy plus interferon-alfa-based immunotherapy compared with interferon alfa alone in metastatic renal-cell carcinoma: a randomized trial. *Lancet* 2001; 358: 966–970.
7. Walther MM, Yang JC, Pass HI, et al. Cytoreductive surgery before high dose interleukin-2 based therapy in patients with metastatic renal cell carcinoma. *J Urol* 1997; 158: 1675–1678.
8. Cerfolio RJ, Allen MS, Deschamps C, et al. Pulmonary resection of metastatic renal cell carcinoma. *Ann Thorac Surg* 1994; 57: 339–344.
9. Friedel G, Hürtgen M, Penzenstadler M, Kyriss T, Toomes H. Resection of pulmonary metastases from renal cell carcinoma. *Anticancer Res* 1999; 19: 1593–1596.
10. Wagner JR, Walther MM, Linehan WM, et al. Interleukin-2 based immunotherapy for metastatic renal cell carcinoma with the kidney in place. *J Urol* 1999; 162: 43–45.
11. Pautler SE, Richards C, Libutti SK, Linehan WM, Walther MM. Intentional resection of the diaphragm during cytoreductive laparoscopic radical nephrectomy. *J Urol* 2002; 167: 48–50.
12. Dunn MD, Portis AJ, Shalhav AL, et al. Laparoscopic versus open radical nephrectomy: A 9-year experience. *J Urol* 2000; 164: 1153–1159.
13. Savage SJ, Gill IS: Laparoscopic radical nephrectomy for renal cell carcinoma in a patient with level I renal vein thrombus. *J Urol* 2000; 163: 1243–1244.
14. Sundaram CP, Rehman J, Landman J, Oh J. Hand assisted laparoscopic radical nephrectomy for renal cell carcinoma with inferior vena caval thrombus. *J Urol* 2002; 168: 176–179.
15. Pautler SE, McWilliams GW, Harrington FS, Walther MM. An articulating retractor holder to facilitate laparoscopic adrenalectomy and nephrectomy. *J Urol* 2001; 166: 198–199.
16. Dunn MD, McDougall EM, Clayman RV. Laparoscopic radical nephrectomy. *J Endourol* 2000; 14: 849–855.
17. Rehman J, Landman J, Kerbl K, Clayman RV. Laparoscopic repair of diaphragmatic defect by total intracorporeal suturing: Clinical and technical considerations. *J Soc Lap Surg* 2001; 5: 287–291.
18. Walther MM, Lyne JC, Libutti SK, Linehan WM. Laparoscopic cytoreductive nephrectomy as preparation for administration of systemic interleukin-2 in the treatment of metastatic renal cell carcinoma: A pilot study. *Urology* 1999; 53: 496–501.
19. Pautler SE, Harrington FS, McWilliams GW, Walther MM. A novel laparoscopic specimen entrapment device to facilitate morcellation of large renal tumors. *Urology* 2002; 59: 591–593.
20. Sundaram CP, Ono Y, Landman J, Rehman J, Clayman RV. Hydrophilic guide wire technique to facilitate organ entrapment using a laparoscopic sack during laparoscopy. *J Urol* 2002; 167: 1376–1377.
21. Levy DA, Swanson DA, Slaton JW, Ellerhorst J, Dinney CPN. Timely delivery of biological therapy after cytoreductive nephrectomy in carefully selected patients with metastatic renal cell carcinoma. *J Urol* 1998; 159: 1168–1173.

22. Walther MM, Alexander RB, Wiess GH, et al. Cytoreductive surgery prior to interleukin-2-based therapy in patients with metastatic renal cell carcinoma. *Urology* 1993; 42: 250–257.
23. Flanigan RC, Yonover PM. The role of radical nephrectomy in metastatic renal cell carcinoma. *Sem Urol Oncol* 2001; 19: 98–102.
24. Rackley R, Novick A, Klein E, Bukowski R, McLain D, Goldfarb D. The impact of adjuvant nephrectomy on multimodality treatment of metastatic renal cell carcinoma. *J Urol* 1994; 152: 1399–1403.
25. Bennett RT, Lerner SE, Taub HC, Dutcher JP, Fleischmann J. Cytoreductive surgery for stage IV renal cell carcinoma. *J Urol* 1995; 154: 32–34.
26. Franklin JR, Figlin R, Rauch J, Gitlitz B, Belldegrun A. Cytoreductive surgery in the management of metastatic renal cell carcinoma: the UCLA experience. *Sem Urol Oncol* 1996; 14: 230–236.
27. Vasselli JR, Yang JC, Linehan WM, et al. Lack of retroperitoneal lymphadenopathy predicts survival of patients with metastatic renal cell carcinoma. *J Urol* 2001; 166: 68–72.
28. Savage SJ, Gill IS. Intact specimen extraction during renal laparoscopy: muscle-splitting versus muscle-cutting incision. *J Endourol* 2001; 15: 165–169.
29. Pautler SE, Hewitt SM, Linehan WM, Walther MM. Specimen morcellation after laparoscopic radical nephrectomy: Confirmation of histological diagnosis using needle biopsy. *J Endourol* 2002; 16: 89–92.



<http://www.springer.com/978-1-58829-203-2>

Laparoscopic Urologic Oncology

Cadeddu, J.A. (Ed.)

2004, X, 366 p. 85 illus., Hardcover

ISBN: 978-1-58829-203-2

A product of Humana Press