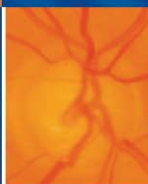

# ESSENTIALS IN OPHTHALMOLOGY

G. K. KRIEGLSTEIN · R. N. WEINREB

Series Editors



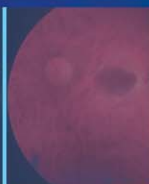**Glaucoma**



**Cataract  
and Refractive  
Surgery**



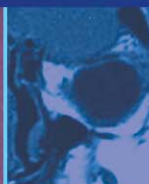
**Uveitis  
and  
Immunological  
Disorders**



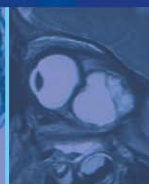
**Vitreo-retinal  
Surgery**



**Medical  
Retina**



**Oculoplastics  
and Orbit**



**Paediatric  
Ophthalmology,  
Neuro-  
ophthalmology,  
Genetics**



**Cornea  
and External  
Eye Disease**

# Glaucoma

Edited by

F. GREHN

R. STAMPER



Springer

---

Sample chapter:

**Essentials in Ophthalmology**

G. K. Krieglstein · R. N. Weinreb (Eds.)



Springer



## Core Messages

- Scarring of subconjunctival connective tissue is the main source of failure of trabeculectomy
- Preoperatively applied topical medications increase the wound healing response after trabeculectomy
- Potent topical corticosteroids after trabeculectomy strongly interfere with many of the wound healing cascades and are the basis for postoperative wound healing modulation
- 5-FU may be recommended as a series of postoperative injections. However, inconvenient side-effects have to be considered and discussed with the patient before surgery
- Mitomycin C is used mostly in refractory glaucomas (repeat-trabeculectomy), secondary glaucomas, and in normal pressure glaucoma. However, some surgeons use it also in primary trabeculectomies. Long-term side effects have to be considered
- MMC can be used postoperatively topically applied to the conjunctiva with a sponge at a 0.05-mg/ml concentration with few side effects
- Subconjunctival injections of TGF- $\beta$ 2 monoclonal antibodies are a new treatment regimen to specifically block excessive wound healing responses after trabeculectomy
- Suramin blocks various cellular wound healing processes and may be an alternative to presently used compounds like MMC or 5-FU

## 13.1

### Introduction

#### 13.1.1

##### Basics

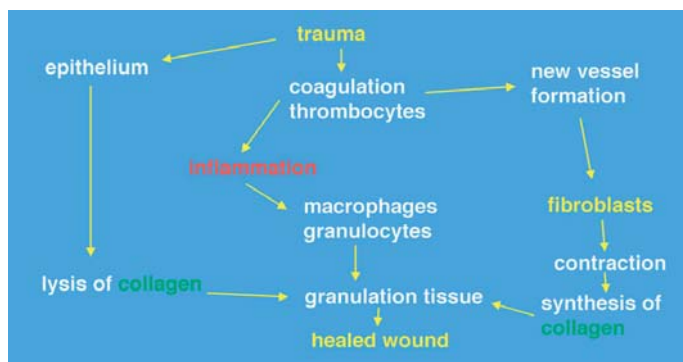
At present, trabeculectomy is the most frequently performed procedure to surgically treat glaucoma. Alternative procedures such as viscocanalostomy and deep sclerectomy do not achieve the amount of reduction of intraocular pressure (IOP) that can be accomplished with trabeculectomy [25]. The AGIS study [1] has pointed out the importance of individual target pressures as opposed to a general cut-off line. The study has shown that eyes with advanced stages of glaucoma have target pressures that are well below usually accepted levels. This makes it important to reduce the IOP in selected cases markedly below values of 22 mmHg or 21 mmHg.

#### 13.1.2

##### Wound Healing Following Trabeculectomy

Scarring at the episcleral and deep Tenon's level is the main cause of failure of trabeculectomy. Several factors influence and control the complicated mechanism of wound healing. Extracellular matrix components such as collagen and fibronectin, cell adhesion molecules such as selectins and integrins, and different growth factors are intimately involved with the fibroblasts (Fig. 13.1) [7].

Among other factors, the amount, duration and kind of pre-operatively topically applied medications have an impact on the conjunctival



**Fig. 13.1.** Flow diagram showing a few important steps regarding conjunctival wound healing following surgical procedures involving the conjunctiva

fibroblasts and on the composition of the extracellular matrix. Conjunctival changes following topical antiglaucomatous therapy include a decrease in the number of epithelial goblet cells, an increase in subepithelial collagen deposition, and a higher number of macrophages, fibroblasts, lymphocytes, and mast cells in the substantia propria [8, 9, 46].

Ongoing studies address the issue of whether it is better to initially perform surgery as compared to medical treatment. Previous studies have suggested a better long-term success of trabeculectomies in eyes with no pre-operative long-term topical antiglaucomatous therapy.

### 13.1.3 Therapeutic Options

In an effort to influence the wound healing cascade at least with some rationale, potential substances should directly interfere with the subsequent single steps that lead to the deposition of new fibrous connective tissue, with fibrocytes being the main target cells.

Different substances have been tested and found effective to interfere with fibroblast proliferation using tissue cultures of human conjunctival fibroblasts. Such tissue samples are easy to obtain for laboratory studies during cataract surgery. Only some of the substances that were promising in tissue culture studies found their way to use in animal models and only a few of these have been reported to improve success rates in human studies [23, 37].

5-Fluorouracil (5-FU) and mitomycin have gained widespread acceptance among glaucoma surgeons [18, 33]. Many authors describe the use of mitomycin as the “gold standard” for trabeculectomies that have an increased risk for failure, and some even promote the use of mitomycin for every trabeculectomy performed.

In contrast to these two highly toxic drugs, attempts were recently made to use a different class of substances that are not antineoplastic. These substances use a new pathway in that they interfere with the action of growth factors on target cells [41]. During surgery, several growth factors are released from the blood, from the tissue, and from the aqueous humor. These growth factors play an important role in the activation of tissue fibroblasts to proliferate and produce ground substance and collagen fibrils [6, 16, 35, 45].

#### 13.1.3.1 Steroids

It may be common sense, but the post-operative application of corticosteroids does have an important effect on the wound healing process. Corticosteroids reduce the deposition of fibrin, reduce leakage of capillaries, reduce the migration of leukocytes and macrophages, and reduce the activity of phagocytosis of these macrophages.

In addition to these effects, corticosteroids reduce the activity of fibroblasts to build and deposit new collagen fibers. The activity of phospholipase A2 is inhibited, which usually liberates arachidonic acid from the plasma membrane phospholipases. Through this mechanism, the synthesis of mediators that activate

the lipooxygenase and cyclooxygenase pathways is down-regulated. Furthermore, the degranulation of granulocytes and mast cells is reduced, stabilizing the intracellular lysosomes and reducing chemotaxis.

These actions are important for the wound healing process itself, and this process runs its own time course as a biological phenomenon. Therefore, clinical impressions from the individual case should not influence the therapeutic regimen too much.

To obtain the optimum effect from the use of corticosteroids, only highly potent corticosteroids such as prednisolone and dexamethasone should be used. Corticosteroids with a more superficial action are less likely to have a strong enough effect on the conjunctiva, and non-steroidal anti-inflammatory substances (NSAID) may similarly not be effective enough.

The time period of intensified application of the corticosteroids should be at least 4–6 weeks after surgery and can be slowly tapered afterwards.

In a few instances, corticosteroids should be avoided or given with caution:

- In patients who are steroid-responders
- In eyes with a conjunctival wound healing problem following the use of antimetabolites

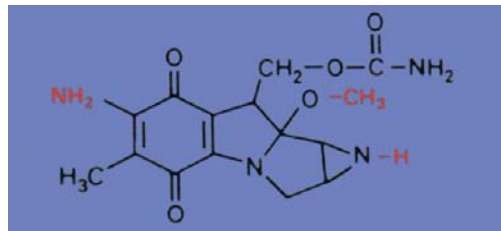
A systemic application of corticosteroids, regardless of the dosage, can not replace the effect of topical medication nor can it increase the efficacy. Therefore, systemic application is not necessary and should be avoided, reducing unnecessary side effects.

### 13.1.3.2 5-Fluorouracil

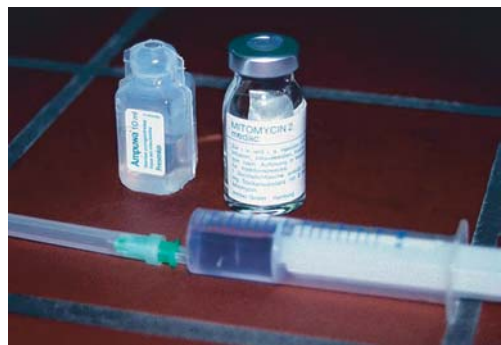5-Fluorouracil was the first antimetabolite that found its way into routine use among glaucoma surgeons. 5-Fluorouracil is a fluorinated pyrimidine analogue that acts as a potent antimetabolite by competitively inhibiting thymidylate synthetase and cell division. Animal models demonstrated decreased fibroblast proliferation and scarring after filtration surgery.

### 13.1.3.3 Mitomycin

Mitomycin C is the most active fraction of the three different mitomycins A, B, and C, and exhibits both antibacterial and antineoplastic activity, the latter in a broad spectrum against transplanted and spontaneous tumors (Fig. 13.2). As an alkylating substance, MMC has three active groups, quinone, urethane, and aziridine. The binding to proteins seems to have a relation to the activity of mitomycin. In mammalian cells, DNA synthesis is inhibited, preformed DNA is degraded, and lysis of nuclei is induced. At markedly higher concentrations than necessary for these effects, RNA synthesis is affected. DNA synthesis inhibition by cross-linking of DNA requires the lowest concentrations of MMC and is the most important mechanism. DNA repair mechanisms do not tend to be influenced. Cells are most vulnerable in the G1 and S phases, although some effect is present at any time throughout the cell cycle (Fig. 13.3).



**Fig. 13.2.** Schematic drawing with the molecule structure of mitomycin C



**Fig. 13.3.** Mitomycin is available as a sterile powder. After dissolving in BSS, the liquid gets a blue color and is light sensitive

**13.1.3.4****Transforming Growth Factor- $\beta$** 

In humans, transforming growth factor- $\beta$  (TGF- $\beta$ ) exists in the three different forms TGF- $\beta$ 1, TGF- $\beta$ 2, and TGF- $\beta$ 3. At least TGF- $\beta$ 1 and TGF- $\beta$ 2 have been shown to be an important component of conjunctival scarring, and it is not surprising that neutralization of its activity makes it a possible target for modulating the scarring response following glaucoma filtration surgery.

For the synthesis of antibodies against these TGF- $\beta$ s, the technique of phage display is used. For identification, a human single chain Fv (scFv) fragment is isolated that neutralizes the hormone from a phage display repertoire. This is converted into a human IgG4 to determine its binding and neutralizing properties. The selected antibodies have a high affinity for TGF- $\beta$ 2 with only low cross-reactivity for TGF- $\beta$ 1 and TGF- $\beta$ 3. In bioassays, the antibodies strongly neutralize the anti-proliferative effect of TGF- $\beta$ 2 in special cell cultures. There is also strong inhibition of binding of TGF- $\beta$ 2 to cell surface receptors in radioreceptor assays.

In animal studies, it was found that repeated subconjunctival injections of 100  $\mu$ l at a concentration of 1 mg/ml caused a slight chemosis, but no inflammation or change of the vascularity of that tissue, when examined both clinically and histopathologically.

**13.1.3.5****Suramin**

Suramin was originally synthesized and designed as an antiparasitic drug, and due to its inhibitory effect on reverse transcriptase, it has recently been used in clinical trials for AIDS, for metastatic disease, and for selected malignancies, including prostate, adrenal cortex, lymphoma, breast, and colon cancer. Because suramin is a heparin analog, it binds to heparin-binding proteins.

More important with relation to ocular wound healing, suramin blocks the effects of growth factors on tumor cells in vitro and interferes with the action of growth factors by competitive binding to growth factor receptors. Growth factors inhibited by suramin include

TGF- $\beta$ 1, TGF- $\beta$ 2, TGF- $\beta$ 3; PDGF A, PDGF B; EGF; bFGF; IGF-I; and IGF-II. Therefore, cytokines that play an important role in stimulating fibroblasts during wound healing are affected by suramin.

In other experiments, cell cultures from human ocular fibroblasts were used and the amount of collagen type I and type III produced under the influence of suramin was measured. The results established a dose response curve and demonstrated that suramin inhibits the production of collagen type I and type III while overall protein production is not affected. This suggests that suramin influences wound healing by blocking growth factor receptors and neutralizing antibodies and has the potential to effectively delay or inhibit the wound healing response.

**13.1.3.6****Further Substances**

Many more substances with antiproliferative potential have been identified in tissue studies, but at this time there are no drugs with a confirmed clinical efficacy or advantage as compared to the substances currently used.

---

**13.2****Clinical Experience  
with the Described Substances****13.2.1****Corticosteroids****13.2.1.1****Topical Post-operative Application  
of Corticosteroids**

There are a few studies that show the benefit of the use of topically applied corticosteroids following trabeculectomy in a clinical setting.

In a prospective fashion, standard trabeculectomies were performed [2]. Afterwards, patients received no steroids at all (group 1), topical 1% prednisolone acetate every 3 h for 20 days (group 2), or in addition to group 2 80 mg oral prednisone, tapered over 16 days (group 3). The patients were followed for up



to 10 years. At that time, the need for one or two topical antiglaucomatous medications was 73 % in group 1, 94 % in group 2, and 92 % in group 3. The need for three or more topical medications was 27 % in group 1, 6 % in group 2, and 8 % in group 3. At 5 years, the mean IOP was 19.3 mmHg in group 1, 13.2 mmHg in group 2, and 15.9 mmHg in group 3. The glaucoma status was worse in 24 % of the cases in group 1, 17 % in group 2, and 17 % in group 3.

These findings demonstrate, in a clinical setting, the importance of a post-operative application of corticosteroids. However, only one regimen of the topical corticosteroids was investigated, so that this study gives no clinically validated information of how much corticosteroids are actually needed.

#### ► Technique for Corticosteroids Following Trabeculectomy

- Dexamethasone 0.1 % eye drops, prednisolone acetate 1 %, or similar should be given 5 times daily for the first 4 weeks
- The drops can then be tapered by one drop per week or slower, according to the clinical course

#### Summary for the Clinician

- The application of steroids following trabeculectomy is mandatory with only few exceptions:
  - In patients who are steroid-responders
  - In eyes with a conjunctival wound healing problem following the use of antimetabolites
- The application does not strictly follow the clinical course, but the biological process of wound healing. This means that the drops should not be reduced too early even when “everything looks fine”

#### 13.2.1.2

#### Corticosteroids for Needling Procedures of Failing Blebs

Needling procedures can be performed as a slit-lamp procedure or under aseptic conditions in the operating room. First, the scar tissue is dissected with a sharp needle and the aim should be to restore filtration either by procedures that

open the firm, prominent blebs themselves or by mobilization of the scleral flap. Thereafter, some of the corticosteroid can be injected in that area to produce some chemosis of the conjunctiva.

#### ► Technique for Post-operative Bleb Revision with Corticosteroids

- Topical anesthesia with oxibuprocaine, proparacaine, tetracaine 0.5 %, or lidocaine 4 %
- A 28-gauge or 30-gauge needle attached to an insulin or tuberculin syringe
- The firm scar tissue is dissected with the needle, the scleral flap is elevated, if necessary to restore filtration
- Immediate injection of 0.5–1.0 ml of betamethasone 4 mg/ml or similar

#### Summary for the Clinician

- Well-accepted therapy to increase the success rate of failing blebs
- The technique may be combined with 5-fluorouracil injections over the following few days

#### 13.2.2

#### 5-Fluorouracil

##### 13.2.2.1

#### Standard Trabeculectomy with Post-operative Injections of 5-Fluorouracil

For the use of 5-fluorouracil, a routine trabeculectomy is carried out first. The standard application of 5-fluorouracil includes repeated subconjunctival injections. These injections can be performed directly into the filtering bleb or directly opposite. The injections can be performed as often as twice per day for the first week and then once per day during the second post-operative week or less frequently. Usually, an amount ranging from 5 mg to 10 mg of 5-fluorouracil is injected each time. Frequent side effects include long-standing corneal erosions, and it has been reported that these injections are quite painful despite topical anesthesia. Typical dosages and results of this kind of application are listed in Table 13.1.



**Table 13.1.** Clinical data on trabeculectomies performed with post-operative subconjunctival injections of 5-fluorouracil

Study	Amount (mg)	Application (injections)	Success (%)	Follow-up (months)
5-FU study group [18]	105	21	51	36
Rockwood et al. [38]	105	21	65	36
Bansal and Gupta [3]	70	14	100	8–27
Jampel et al. [19]	33±10	10	100	8
Patitsas et al. [34]	60	14	71	34
Whiteside-Michel et al. [47]	28±9	14	100	11–50
Liebman et al. [24]	29±10	14	100	24

The use of 5-fluorouracil has been described both for eyes with complicated forms of glaucoma, as well as for primary procedures. A comment regarding this issue is found in Sect. 13.2.3.

► **Technique for Post-operative Injections of 5-Fluorouracil**

- Topical anesthesia of the conjunctiva using oxibuprocaine eye drops or similar
- Injection of 5–10 mg of 5-fluorouracil (5 mg is a good option)
- A total of up to 21 injections during the first 2 weeks after trabeculectomy

**Summary for the Clinician**

- **Well-accepted therapy to increase the success rate. The patient should be aware of the sometimes painful injections before surgery**

**13.2.2.2  
Standard Trabeculectomy  
with Intra-operative Application  
of 5-Fluorouracil**

This option has been adopted from the routine application of mitomycin. Just like a trabeculectomy performed with the application of mitomycin, the intra-operative application of 5-fluorouracil is done just before dissection of the scleral flap. In the initial reports describing this

technique, the scleral flap was dissected first and sponges, soaked with 5-fluorouracil, were then placed on the scleral bed and underneath the conjunctiva. Therefore, it appears that there are at least two different positions regarding sponge application in the literature. Concentrations of 5-fluorouracil range from 25 mg/ml to 50 mg/ml. In none of the publications is there a statement regarding the volume of the 5-fluorouracil solution used. While small pieces regarding sponge can usually hold 0.1 ml, it appears from printed figures of the surgical site that some surgeons used considerably larger volumes and more sponges. This makes it difficult to compare the data and give practical advice.

This technique of 5-fluorouracil application makes it possible to irrigate the surgical site and wash the solution away from the tissues. Typical dosages and results of this kind of application are listed in Table 13.2.

► **Technique for Intra-operative Application of 5-Fluorouracil**

- Standard trabeculectomy including dissection of the scleral flap.  
Then application of sponges soaked with 5-Fluorouracil
- Concentrations of 5-fluorouracil range from 25 mg/ml to 50 mg/ml
- Application time is uniformly 5 min
- Irrigation with BSS is recommended

**Table 13.2.** Clinical data on trabeculectomies performed with intra-operative application of 5-fluorouracil

Study	Amount (mg)	Application (injections)	Success (%)	Follow-up (months)
Smith et al. [43]	50 + 29 mg	1+6 injections	93	4–9
Dietze et al. [15]	50	1	95	3
Egbert et al. [17]	50	1	87	10

### Summary for the Clinician

- Well-accepted therapy to increase the success rate
- The sponges may also be placed on top of the intact sclera
- The technique may be combined with post-operative injections of 5-fluorouracil

### 13.2.2.3

#### 5-Fluorouracil for Failing Filtering Blebs

In order to recognize failing filtering blebs, it is necessary to monitor the patients frequently throughout the first few weeks following trabeculectomy. Failing blebs have been described as encapsulated blebs, characteristically highly elevated, localized, and firm with a patent sclerostomy. Encapsulated blebs develop typically at 2–8 weeks following surgery. However, in one large study, the mean time point of needling revision was 49 weeks with a range from 0.4 weeks to 216 weeks.

In different reports, needling procedures were performed as a slit-lamp procedure or under aseptic conditions in the operating room. It appears to be important to inject the 5-fluorouracil close to the scleral flap and to attempt to restore filtration by manipulating the needle over the scleral flap or underneath the flap. On average, 2.4 injections with a range of 1–7 injections appeared to be necessary to restore filtration. A typical amount of 5-fluorouracil used is 5 mg in 0.5 ml or 5 mg in 0.1 ml.

Other surgeons perform a dissection of the scar tissue with a needle first and inject 5-fluorouracil away from the bleb site on the next days.

### ► Technique for Post-operative Injections of 5-Fluorouracil for Failing Blebs

- Topical anesthesia with oxibuprocaine, proparacaine, tetracaine 0.5 % or lidocaine 4 %
- A 28-gauge or 30-gauge needle attached to an insulin or tuberculin syringe
- The firm scar tissue is dissected with the needle, the scleral flap is elevated, if necessary, to restore filtration
- Immediate or later injection of 5 mg 5-fluorouracil
- Injections may be repeated over the next days

### Summary for the Clinician

- Well-accepted therapy to increase the success rate of failing blebs
- Frequent monitoring of the patient in the weeks following trabeculectomy is necessary

### 13.2.3

#### Mitomycin

A discussion or review of the current use of mitomycin to enhance the outcome of filtering surgery for glaucoma has to start with defining the situation one has to deal with and therefore, as a second step, setting the goal of the procedure.

Some authors advocate that a substance like mitomycin should be used for every trabeculectomy performed. This would mean that the authors do not fear the high incidence of possible side effects of the substance. In addition, this would mean that many primary trabeculectomies are done with mitomycin, since these are the trabeculectomies performed most frequent-

ly. This would also mean that especially low target pressures are attempted, since the use of mitomycin does not only lead to a reduced rate of episcleral scarring, but also to low and very low values of intraocular pressure over a long time. Low intraocular pressures are advocated for patients with only mildly elevated intraocular pressures but advanced glaucomatous damage of the optic nerve head for patients with low tension glaucoma, and for patients with a vascular component of their glaucomatous disease.

Therefore, it is important to distinguish between trabeculectomies performed with mitomycin as procedures for primary surgery and uncomplicated cases of glaucoma and repeat trabeculectomies and cases of complicated glaucoma.

### 13.2.3.1

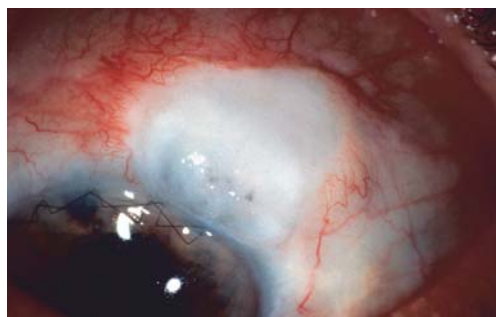#### Primary Procedures with Mitomycin

The issue of whether primary trabeculectomies should be performed with or without the use of an antimetabolite is still controversial and will probably remain such for a while. One should at least keep in mind that uncomplicated cases of glaucoma might have a good prognosis even without the use of antimetabolites (Fig. 13.4).

#### Summarized Information from Important Publications:

In one study, [22] 33 eyes of mostly black patients were operated with a concentration of 0.5 mg/ml of mitomycin and a 3-min exposure. These eyes were compared to a historical control group of 30 eyes. At each time point of the follow-up period of up to 18 months, the mitomycin-operated eyes had a significantly lower intraocular pressure (e.g., 10.0 mmHg versus 17.2 mmHg). The complication of severe hypotony, here defined as an intraocular pressure of less than 6 mmHg, was 15 % in the mitomycin group and 0 % in the control group.

In a second publication [14], a total of 28 eyes were operated with 14 of these receiving mitomycin with a concentration of 0.2 mg/ml for 3 min. The mean follow-up was around 17 months. At the last visit, the intraocular pres-



**Fig. 13.4.** Typical avascular filtering bleb following intra-operative application of mitomycin with a concentration of 0.2mg/ml

sure was below 16 mmHg in 12/14 mitomycin-treated eyes and in 4/14 control eyes. Complications such as choroidal effusion and shallow anterior chamber were more frequent in the mitomycin-treated eyes.

In one series [32], 25 eyes of 23 white patients underwent trabeculectomy with mitomycin with a concentration of 0.2 mg/ml for 5 min. Although there was no control group, the authors were pleased with the outcome, reduction of the mean intraocular pressure from 26.0 mmHg to 12.5 mmHg at a follow-up of 12 months. The only reported complication included a case of temporary hypotonous maculopathy.

In a different study, the effect of no mitomycin compared with a short-term and a longer-term exposure to mitomycin was described [20]. The concentration of mitomycin was 0.5 mg/ml, and a total of 124 eyes were included. In that report, the best control of the intraocular pressure combined with the lowest risk for severe complications was accomplished in the group with a short-term exposure to mitomycin, ranging from 30 to 60 s only.

Different concentrations of mitomycin with a standard application time of 5 min were applied in a study performed by Kitazawa et al. [21]. They treated 11 patients with a standard trabeculectomy with a concentration of mitomycin of 0.2 mg/ml in one eye and a concentration of 0.02 mg/ml in the fellow eye. No control group with no mitomycin was included. The eyes receiving the higher concentration of mitomycin were more successful with regard to

control of the intraocular pressure, but had more complications such as hypotony maculopathy and cataract progression. The authors concluded that the best concentration for mitomycin might be in between the two concentrations tested.

The most recent study with the longest follow up was performed by Bindlish et al. [5]. These authors included a total of 123 eyes and had a follow-up period of 5 years. Concentrations of mitomycin ranged from 0.25 mg/ml to 0.5 mg/ml and exposure times from 0.5 to 5 min. Although the mean intraocular pressure was low with 9.9 mmHg, the rate of complications was relatively high and included hypotony maculopathy, bleb leaks, blebitis, endophthalmitis, and significant loss of central vision.

These authors concluded that the intraocular pressure control with the use of mitomycin is good, but the rate of complications is much higher than with no use of mitomycin. Regarding this study [44], it was mentioned that the mean intraocular pressure of trabeculectomies done without mitomycin is something around 15 mmHg, and that this level of the intraocular pressure is just the one which is sufficient in most cases.

#### ► Technique for Intra-operative Application of Mitomycin

- Preparation of the surgical site where the scleral flap is to be dissected
- Mitomycin, freshly prepared solution of 0.1–0.5 mg/ml (0.2 mg/ml is a good option)
- Volume of 0.1 ml
- Sponge, size 5x5 mm
- After placing the sponge on the sclera, the mitomycin is applied to the sponge using a tuberculin or insulin syringe
- The mitomycin remains for 0.5– 5 min (2–3 min is a good option)
- The whole area is irrigated with at least 10 ml of BSS

#### Summary for the Clinician

- The use of mitomycin for primary trabeculectomy is still under discussion
- Maybe the topical post-operative application should be favored for these cases

#### 13.2.3.2

#### Mitomycin for Complicated Forms of Glaucoma

The review of the literature regarding the use of mitomycin for specific forms of complicated glaucoma including repeat trabeculectomy is difficult, because many studies combine different forms of secondary glaucoma in their reports so that it becomes hard to get specific information for one group of these eyes or another.

A list of forms of secondary glaucoma is given in Table 13.3.

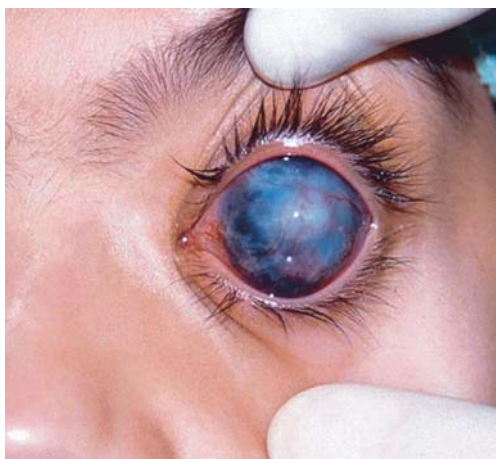#### 13.2.3.3

#### Young Patients

The problem with the definition of these cases of glaucoma starts with the definition. It can be assumed that all of the above-mentioned forms of glaucoma refer to patients up to about 20 years of age. For older patients, one would probably use the terms primary open-angle glaucoma or dysgenetic glaucoma. Some surgeons

**Table 13.3.** List of secondary forms of glaucoma and risk factors for failure of trabeculectomy

Inflammatory
Chronic angle closure
Pseudoexfoliation
Pigmentary
Neovascular
Traumatic
Black patients
Pseudophakia
Previous argon laser trabeculectomy
Juvenile/infantile
Anterior segment dysgenesis
Iridocorneal endothelial syndrome



**Fig. 13.5.** Eye with a severe form of congenital glaucoma and enlargement of the cornea and vascularization. A challenging case for the glaucoma surgeon

tend to be very cautious when using mitomycin for children younger than 10 or 5 years of age, while others insist in using mitomycin especially in these patients because standard filtering procedures have a poor prognosis (Fig. 13.5).

### Important Studies

In 1997, Mandal et al. [26] reported on 19 eyes of 13 patients with congenital glaucoma that underwent trabeculectomy with mitomycin with a concentration of 0.4 mg/ml for 3 min. Complete success was obtained in 18 of the 19 eyes after a mean follow-up period of 19 months. Beck et al. [4] in addition performed a retrospective study of 60 eyes in 49 patients. Trabeculectomy was performed with a concentration of 2.5 mg/ml or 0.5 mg/ml for 5 min. The probability of success was 67 % for 12 months and 59 % for 24 months. The most severe complication encountered was endophthalmitis, occurring in 8 % of the cases.

In another retrospective study published in 1999, Mandal et al. [27] evaluated 38 eyes in 29 patients. The concentration of mitomycin was 0.4 mg/ml, applied for 3 min. The success probability at 18 months was 65 %. No cases of endophthalmitis were reported. Most recently, Sidoti et al. [40] published a retrospective study of 29 eyes in 29 patients. The concentration of mitomycin was 0.5 mg/ml, and it was applied for

1.5–5 min. Success at 24 months was 59 %, and the rate of bleb-related infection was 17 %.

It appears that the overall outcome of the use of mitomycin for young patients is promising, but the long-term behavior of the thin and avascular blebs remains unclear. Infections were noted in three of the four cited studies, and this problem may give rise to severe disease.

#### 13.2.3.4 Black Patients

In general, patients from African populations have a larger risk of post-operative scarring than white patients.

### Important Studies

In 1993, Mermoud et al. [28] published a report on a prospective study evaluating 30 eyes of 26 black patients undergoing trabeculectomy with a concentration of 0.2 mg/ml of mitomycin applied for 5 min. These patients were compared to a historical group of eyes operated without mitomycin. Some 83 % of the mitomycin-operated eyes had an intraocular pressure of less than 21 mmHg at a mean follow-up time of 9.1 months as compared to only 37 % of eyes from the no-mitomycin group. Bleb fibrosis occurred at a rate of 7 % and 20 %, respectively. A late postoperative positive Seidel test was only seen in the mitomycin-treated eyes at a rate of 13 %.

In a study of 44 eyes receiving mitomycin in a concentration of 0.5 mg/ml for 3.5 min, the mean intraoperative pressure was 14.7 mmHg at a mean follow-up of 17.7 months [10]. The patients had advanced open-angle glaucoma. Similarly, Mwanza and Kabasele [31] performed a study with an intra-individual control group using mitomycin with a concentration of 0.4 mg/ml for 2.5 min. The success rate of mitomycin-treated eyes was 82 % compared to 63 % in the untreated controls.

Interestingly, in all three studies cited, no cases of hypotony maculopathy were reported, so that it can be assumed that these patients have a lower risk of developing this specific complication than non-black patients.

### 13.2.3.5 Uveitis

Uveitis is a challenging aspect for glaucoma surgeons, since the success of most surgical procedures appears to be limited in the long run.

In 1994, Prata et al. [36] published a retrospective, uncontrolled study of 24 eyes undergoing trabeculectomy with mitomycin with a concentration of 0.2 mg/ml, applied for 5 min. After a mean follow-up of around 10 months, a complete success was reached in 75 % of the eyes, but complications related to hypotony were quite high. In 1997, Wright et al. [48] published a similarly retrospective study of 24 eyes with a mean follow-up of around 15 months. Complete success was reported in 62 % of the cases. Recently, Ceballos et al. [11] published a report of a retrospective study of 44 eyes with uveitis that were operated with either mitomycin or 5-fluorouracil. The overall success rate was 62 % at 2 years. Interestingly, male gender was a significant risk factor for failure. Phakic patients developed significant cataracts in more than 50 %.

### 13.2.3.6 Repeat Trabeculectomy

Patients undergoing repeat trabeculectomy are probably those that profit the most from the use of mitomycin. Unfortunately, no studies exist that specifically address this problem. In most cases, these eyes are mixed with other forms of

secondary glaucoma, so that no detailed information can be given for repeat trabeculectomies only. However, when looking at the abundant literature regarding this issue, it may be safe to conclude that a repeat trabeculectomy is the classic indication for the use of an antimetabolite. Typical dosages and results of this kind of application are listed in Table 13.4. Typical complications and side effects regarding the use of mitomycin in comparison to 5-fluorouracil are listed in Table 13.5 (Figs. 13.6–13.8).

#### ► Technique for Intra-operative Application of Mitomycin

- Preparation of the surgical site where the scleral flap is to be dissected
- Mitomycin, freshly prepared solution of 0.1–0.5 mg/ml (0.2 mg/ml is a good option)
- Volume of 0.1 ml
- Sponge, size 5x5 mm
- After placing the sponge on the sclera, the mitomycin is applied to the sponge using a tuberculin or insulin syringe
- The sponge remains for 0.5 min - 5 min (2–3 min is a good option)
- The whole area is irrigated with at least 10 ml of BSS

#### Summary for the Clinician

- The use of mitomycin for repeat trabeculectomies and complicated forms of glaucoma is current practice in most glaucoma centers

**Table 13.4.** Clinical data on trabeculectomies performed with intra-operative application of mitomycin

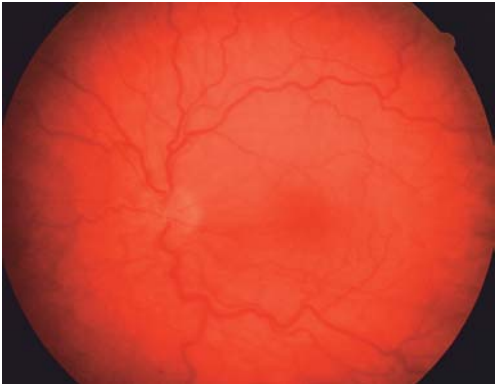Study	Mitomycin (mg/ml)	Time (min)	Success (%)	Follow-up (months)
Shields et al. [39]	0.25	2–5	59	2–12
Chen et al. [12]	0.1–0.4	5	76–100	12–60
Palmer [33]	0.2	5	84	6–42
Kitazawa et al. [21]	0.4	5	100	7–12
Skuta et al. [42]	0.5	5	95	6
Zacharia et al. [49]	0.4	3.5–7	100	2–12
Mermoud et al. [28]	0.2	5	93	3–18
Costa et al. [13]	0.4	1.5–2.5	95	6–7
Mietz andKriegelstein [29]	0.2–0.5	3–5	90	36



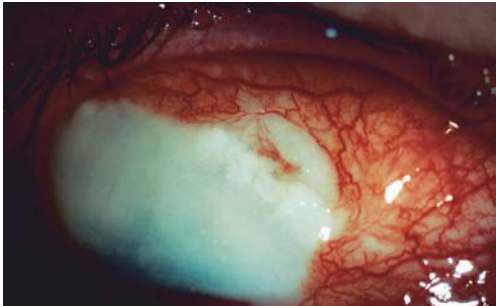
**Table 13.5.** Possible side effects following the use of 5-fluorouracil and mitomycin for trabeculectomy

Complication	5-Fluorouracil	Mitomycin
Painful injection	++	–
Conjunctival dehiscence	+	+
Corneal erosions	++	–
Corneal ulcer	(+)	–
Repeated applications	++	–
Blebitis or endophthalmitis	++	+
Post-operative hypotony	+	+
Hypotony maculopathy	+	+
Suprachoroidal hemorrhage	(+)	(+)
Intraocular toxic sideeffects	+	++
Conjunctival hemorrhages	++	+

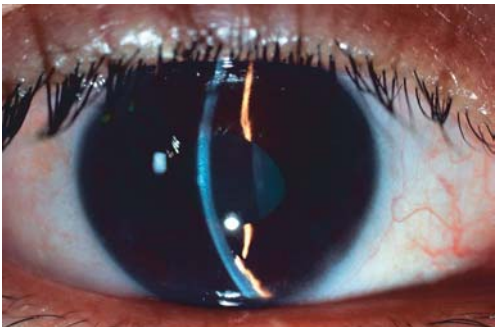
–, Not frequent; +, typical complication; ++, frequently occurring; (+) typical, but rare complication



**Fig. 13.6.** Hypotony maculopathy as a complication of the intra-operative use of Mitomycin



**Fig. 13.8.** A typical avascular filtering bleb. Note the conjunctival dehiscence superiorly. This may give rise to a blebitis



**Fig. 13.7.** Anterior synechiae as a complication of long-standing hypotony with a flat anterior chamber

**13.2.3.7**  
**Topical Application of Mitomycin**

More recently, a topical application of Mitomycin was reported. With this technique, a standard trabeculectomy is performed first. For the first 3 days after surgery, a sponge with mitomycin is placed on the filtering bleb. This can be done under topical anesthesia as an office procedure and does not require aseptic conditions. The application is usually well tolerated by the patients. The main advantage is that a much lower concentration of mitomycin can be used. For



the intra-operative application, a concentration of 0.2 mg/ml or higher is usually employed. For the post-operative application, a concentration of 0.05 mg/ml of mitomycin is used.

#### ► **Technique for Post-operative Application of Mitomycin**

- Application on days 1, 2, and 3 after trabeculectomy
- Topical anesthesia using oxibuprocaine, proparacaine, tetracaine 0.5 %, or lidocaine 4 %
- Insertion of a lid-speculum.
- Sponge with 0.1 ml of 0.05 mg/ml mitomycin for 3 min
- Irrigation with 10 ml BSS

#### **Summary for the Clinician**

- **The post-operative application of mitomycin is a new technique aimed to reduce intra-ocular toxicity**
- **It requires three applications after surgery and is therefore more time consuming**

### 13.2.4

#### **Transforming Growth Factor- $\beta$**

With respect to this treatment modality, the results of two clinical phase II trials are available.

In a first trial, 24 patients underwent primary trabeculectomy. Sixteen patients of these received the specific antibody, while the remaining eight patients served as controls. The antibody was given as a sequence of four subconjunctival injections. Two injections were done on the day of surgery (pre- and post-operatively), one on the day after surgery and one a week after surgery.

After 1 year, the proportion of patients who had not required either intervention or resumption of topical medication was 11 of 16 (69 %) on the TGF- $\beta$  antibody compared with 2 of 8 (25 %) on placebo. Mean IOP at 1 year was 3 mmHg lower in the TGF- $\beta$  antibody group than in the placebo group. There were no significant differences in the incidence of complications between the two groups. Blebs after the TGF- $\beta$  antibody were diffuse, noncystic and nonvascular. The

fall in IOP was greater in the TGF- $\beta$  antibody group at 3 and 6 months ( $p < 0.05$ ) and approached significance at 12 months.

Follow-up results at 2 years showed that the TGF- $\beta$  antibody patients achieved a significantly lower IOP than the control group. The mean values 2 years after surgery were 13.6 mmHg for the TGF- $\beta$  antibody and 17.7 mmHg for the controls.

In a second trial, 56 patients underwent combined glaucoma and cataract surgery. Patients were randomized to receive either the TGF- $\beta$  antibody ( $n=36$ ) or matching placebo ( $n=20$ ). The therapeutic regimen was similar to that in the first clinical trial. Follow-up results at 6 months revealed that the TGF- $\beta$  antibody was safe and well tolerated with no serious drug-related adverse effects and no severe injection site reactions. There was no evidence of increased inflammation in the anterior chamber of the eye. IOP was successfully lowered by surgery in both patient groups. At 6 months after surgery, the achieved IOP was lower in patients receiving the TGF- $\beta$  antibody (14.5 mmHg) compared with those receiving placebo (16.7 mmHg). In the early post-operative period, intervention with 5-FU injection was used in 28 % of TGF- $\beta$  antibody eyes and in 10 % of placebo-treated eyes.

#### ► **Technique for Application of TGF- $\beta$ 2 of TGF- $\beta$ 2 Antibodies:**

- The concentration of the TGF- $\beta$ 2 antibody is 1.0 mg/ml
- For each injection to the filtering bleb, the quantity injected is 100  $\mu$ l
- The first injection is before surgery on the day of surgery
- The second injection is after surgery on the day of surgery
- The third injection is on the first day after surgery
- The fourth injection is at 1 week after surgery

#### **Summary for the Clinician**

- **The use of the TGF- $\beta$  antibody is only possible in ongoing clinical studies in participating study centers**
- **The synthetically engineered TGF- $\beta$  antibody is not yet commercially available**

### 13.2.5 Suramin

For this substance, only information from one clinical study is available [30].

Suramin was first applied during surgery at a concentration of 200 mg/ml and applied for 5 min. On days 1, 2, and 3 following surgery, the patients received a subconjunctival injection of 0.1 ml suramin solution (200 mg/ml) close to the filtering bleb. A historical group of eyes operated with mitomycin (0.2 mg/ml) served as a control.

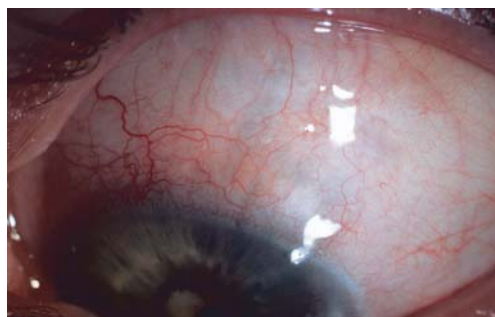The suramin- and mitomycin-treated eyes did not differ significantly for the mean IOP before surgery and at the final visit (32.7 vs. 29.5/19.7 vs. 19.3; both  $p < 0.0001$ ). Following surgery, the filtering blebs were slightly hyperemic in the suramin group, but this effect resolved over time without the need for increased topical therapy.

The most important complication encountered in both the early and late post-operative phase was hypotony. Hypotony as a transient phenomenon occurred frequently in all groups. Hypotony at some point within the first few days or weeks following trabeculectomy occurred twice in the suramin group, but not afterwards. Hypotony as a permanent complication developed in four mitomycin cases, causing hypotony maculopathy in one case. Using an ANOVA survival analysis, no difference was found between the suramin and mitomycin groups ( $p < 0.64$ ). The incidence of failures was not significantly different.

It appears, therefore, that suramin may be a potent substance, its efficacy comparable with that of mitomycin (Fig. 13.9).

#### ► Technique for Suramin Used for Trabeculectomy

- Concentration of 200 mg/ml suramin dissolved in BSS
- One application during surgery using a sponge
- Subconjunctival injections directly to the filtering bleb on days 1, 2, and 3 (total of three injections)



**Fig. 13.9.** Typical appearance of a filtering bleb at 2 years following trabeculectomy with Suramin. No avascularity is present

#### Summary for the Clinician

- At this time, only preliminary data are available. It is too early to recommend a specific therapeutic regimen

### 13.2.6 Additional Substances

Given the lack of data, the use of other substances that interfere with wound healing can not be recommended at this time.

## 13.3 Current Clinical Practice/Recommendations

Summarizing the previously given information, the following recommendations can be made:

- If primary trabeculectomies are performed, additionally used substances should have a low risk profile, if any are used to enhance the success.
- Repeat trabeculectomies or complicated cases should not be operated without the use of an antimetabolite.
- Both 5-fluorouracil and mitomycin are well accepted.
- New substances like TGF- $\beta$  antibodies are on the horizon, but not yet well established.

### 13.4

#### Post-operative Intensified Care

The concept of intensified post-operative care is relatively new and includes the following issues:

- Regular visits following trabeculectomy
- High-dose topical corticosteroids for a longer period after surgery
- Detailed examination and description of the filtering bleb
- Early identification of risk factors for failing blebs
- Early intervention to interfere with the scarring process using injections with 5-fluorouracil or steroids

It was shown in clinical studies that the success rate of routine trabeculectomies could be significantly improved with this regimen of intensified care.

#### References

1. AGIS Investigators (2000) The advanced glaucoma intervention study (AGIS). 7. The relationship between control of intraocular pressure and visual field deterioration. *Am J Ophthalmol* 130: 429-440
2. Araujo SV, Spaeth GL, Roth SM, Starita RJ (1995) A ten-year follow-up on a prospective, randomized trial of postoperative corticosteroids after trabeculectomy. *Ophthalmology* 102: 1753-1759
3. Bansal RK, Gupta A (1992) 5-fluorouracil in trabeculectomy for patients under the age of 40 years. *Ophthalmic Surg* 23: 278-280
4. Beck AD, Wilson WR, Lynch MG, Lynn MJ, Noe R. (1998) Trabeculectomy with adjunctive mitomycin C in pediatric glaucoma. *Am J Ophthalmol* 126: 648-657
5. Bindlish R, Condon GP, Schlosser JD, D'Antonio J, Lauer KB, Lehrer R (2002) Efficacy and safety of mitomycin C in primary trabeculectomy: five-year follow-up. *Ophthalmology* 109: 1336-1341
6. Border WA, Noble NA (1994) Transforming growth factor b in tissue fibrosis. *New Engl J Med* 331: 1286-1292
7. Broadway D, Grierson I, Hitchings R (1993) The effect of topical anti-glaucomatous medications on the cell profile of the conjunctiva. *Curr Opin Ophthalmol* 4: 51-57
8. Broadway D, Grierson I, Hitchings R (1993) Adverse effects of topical antiglaucomatous medications on the conjunctiva. *Br J Ophthalmol* 77: 590-596
9. Broadway DC, Grierson I, O'Brien C, Hitchings RA (1994) Adverse effects of topical antiglaucoma medication. I. The conjunctival cell profile. *Arch Ophthalmol* 112: 1437-1445
10. Byrd SK, Egbert PR, Budenz D (1998) Risk of hypotony after primary trabeculectomy with antifibrotic agents in a black African population. *J Glaucoma* 1998; 7: 82-85
11. Ceballos EM, Beck AD, Lynn MJ (2002) Trabeculectomy with antiproliferative agents in uveitic glaucoma. *J Glaucoma* 11: 189-196
12. Chen CW, Huang HT, Bair JS, Lee CC (1990) Trabeculectomy with simultaneous topical application of mitomycin-C in refractory glaucoma. *J Ocul Pharmacol* 6: 175-182
13. Costa VP, Moster MR, Wilson RP, et al. (1993) Effects of topical mitomycin C on primary trabeculectomies and combined procedures. *Br J Ophthalmol* 77: 693-697
14. Costa VP, Comegno PEC, Vasconcelos JPC, Malta RFS, Jose NK (1996) Low-dose mitomycin C trabeculectomy in patients with advanced glaucoma. *J Glaucoma* 5: 193-199
15. Dietze PJ, Feldman RM, Gross RL (1992) Intraoperative application of 5-fluorouracil during trabeculectomy. *Ophthalmic Surg* 23: 662-665
16. Doxey DL, Ng MC, Dill RE, Iacopino AM (1995) Platelet-derived growth factor levels in wounds of diabetic rats. *Life Sci* 57: 1111-1123
17. Egbert PR, Williams AS, Singh K, Dadzie P, Egbert TB (1993) A prospective trial of intraoperative fluorouracil during trabeculectomy in a black population. *Am J Ophthalmol* 116: 612-616
18. The Fluorouracil Filtering Study Group (1996) Five-year follow-up of the fluorouracil filtering study. *Am J Ophthalmol* 121: 349-366
19. Jampel HD, Jabs DA, Quigley HA (1990) Trabeculectomy with 5-fluorouracil for adult inflammatory glaucoma. *Am J Ophthalmol* 109: 168-173
20. Kim YY, Sexton RM, Shin DH, Kim C, Ginde SA, Ren J, Lee D, Kupin TH (1998) Outcomes of primary phakic trabeculectomies without versus with 0.5- to 1- minute versus 3- to 5- minute mitomycin c. *Am J Ophthalmol* 126: 755-762
21. Kitazawa Y, Suemori-Matshushita H, Yamamoto T, Kawase K (1993) Low-dose and high-dose mitomycin trabeculectomy as an initial surgery in primary open-angle glaucoma. *Ophthalmology* 100: 1624-1628
22. Kupin TH, Juzych MS, Shin DH, Khatana AK, Olivier MDG (1995) Adjunctive mitomycin C in primary trabeculectomy in phakic eyes. *Am J Ophthalmol* 119: 30-39

23. Lee DA, Lee TC, Corres AE, Kitada S (1990) Effects of Mithramycin, Mitomycin, Daunorubicin, and Bleomycin on human subconjunctival fibroblast attachment and proliferation. *Invest Ophthalmol Vis Sci* 31: 2136-2144
24. Liebmann JM, Ritch R, Marmor M, Nunez J, Wolner B (1991) Initial 5-fluorouracil trabeculectomy in uncomplicated glaucoma. *Ophthalmology* 98: 1036-1041
25. Lüke C (2002) A prospective randomized trial of viscocanalostomy versus trabeculectomy in open-angle glaucoma: a 1-year follow-up study. *J Glaucoma* 11: 294-299
26. Mandal AK, Walton DS, John T, Jayagandan A (1997) Mitomycin C-augmented trabeculectomy in refractory congenital glaucoma. *Ophthalmology* 104: 996-1003
27. Mandal AK, Prasad K, Naduvilath TJ (1999) Surgical results and complications of mitomycinC-augmented trabeculectomy in refractory developmental glaucoma. *Ophthalmic Surg Lasers* 1999; 30: 473-480
28. Mermoud A, Salmon JE, Murray DN (1993) Trabeculectomy with mitomycin C for refractory glaucoma in blacks. *Am J Ophthalmol* 116: 72-78
29. Mietz H, Krieglstein GK (1998) Three-year follow-up of trabeculectomies performed with different concentrations of mitomycin-C. *Ophthalmic Surg Lasers* 29: 628-630.
30. Mietz H, Krieglstein GK (2001) Suramin to enhance glaucoma filtering procedures: a clinical comparison with mitomycin. *Ophthalmic Surg Lasers* 2001; 32: 358-369
31. Mwanza J-CK, Kabasele PM (2001) Trabeculectomy with and without mitomycin-C in a black African population. *Eur J Ophthalmol* 2001; 11: 261-263
32. Nuijts RMMA, Vernimmen RCJ, Webers C (1997) Mitomycin C primary trabeculectomy in primary glaucoma of white patients. *J Glaucoma* 6: 293-297
33. Palmer SS (1991) Mitomycin as adjunct chemotherapy with trabeculectomy. *Ophthalmology* 98: 317-321
34. Patitsas CJ, Rockwood EJ, Meisler DM, Lowder CY (1992) Glaucoma filtering surgery with postoperative 5-fluorouracil in patients with intraocular inflammatory disease. *Ophthalmology* 99: 594-599
35. Pierce GE, Tarpley JE, Tseng J, et al (1995) Detection of platelet-derived growth factor (PDGF)-AA in actively healing human wounds treated with recombinant PDGF-BB and absence of PDGF in chronic nonhealing wounds. *J Clin Invest* 96: 1336-1350
36. Prata JA, Neves RA, Minckler DS, Mermoud A, Heuer DK (1994) Trabeculectomy with mitomycin C in glaucoma associated with uveitis. *Ophthalmic Surg* 25: 616-620
37. Rabowski JH, Dukes AJ, Lee DA, Leong KW (1996) The use of bioerodible polymers and daunorubicin in glaucoma filtration surgery. *Ophthalmology* 103: 800-807
38. Rockwood EJ, Parrish RK II, Heuer DK, Skuta GL, Hodapp E, Palmberg PE, Gressel MG, Feuer W (1997) Glaucoma filtering surgery with 5-fluorouracil. *Ophthalmology* 94: 1071-1078.
39. Shields MB, Scroggs MW, Sloop CM, Simons RB (1993) Clinical and histopathologic observations concerning hypotony after trabeculectomy with adjunctive mitomycin C. *Am J Ophthalmol* 116: 673-683
40. Sidoti PA, Belmonte SJ, Liebmann JM, Ritch R (2000) Trabeculectomy with mitomycin-C in the treatment of pediatric glaucomas. *Ophthalmology* 2000; 107: 422-429
41. Siriwardena D, Khaw PT, King AJ, Donalson ML, Overton BM, Migdal C, Cordeiro MF (2002) Human antitransforming growth factor beta (2) monoclonal antibody-a new modulator of wound healing in trabeculectomy: a randomized placebo controlled clinical study. *Ophthalmology* 109: 427-431
42. Skuta GL, Beeson CC, Higginbotham EJ, Lichter PR, Musch DC, Bergstrom TJ, Klein TB, Falck FY (1992) Intraoperative mitomycin versus postoperative 5-Fluorouracil in high-risk glaucoma filtering surgery. *Ophthalmology* 99: 438-444
43. Smith MF, Sherwood MB, Doyle JW, Khaw PT (1992) Results of intraoperative 5-fluorouracil supplementation on trabeculectomy for open-angle glaucoma. *Am J Ophthalmol* 114: 737-741
44. Spaeth GL, Terizidou C, Bhan A (2002) Discussion of above mentioned paper. *Ophthalmology* 109: 1341-1342
45. Sullivan KM, Lorenz HP, Meuli M, Lin RY, Adzick NS (1995) A model of scarless human fetal wound repair is deficient in transforming growth factor beta. *J Ped Surg* 30: 198-203
46. Thomas DW, O'Neill ID, Harding KG, Shepherd JP (1995) Cutaneous wound healing: a current perspective. *J Oral Maxillofac Surg* 53: 442-447
47. Whiteside-Michel J, Liebmann JM, Ritch R (1992) Initial 5-fluorouracil trabeculectomy in young patients. *Ophthalmology* 99: 7-13
48. Wright MM, McGehee RF, Pederson JE (1997) Intraoperative mitomycin-C for glaucoma associated with ocular inflammation. *Ophthalmic Surg Lasers* 1997; 28: 370-376
49. Zacharia PT, Deppermann SR, Schuman JS (1993) Ocular hypotony after trabeculectomy with mitomycin c. *Am J Ophthalmol* 116: 314-326



# ESSENTIALS IN OPHTHALMOLOGY

G. K. KRIEGLSTEIN · R. N. WEINREB

Series Editors

“Essentials in Ophthalmology” is a new proceeding series covering all of ophthalmology categorized in eight subspecialties. It will be published quarterly, thus each subspecialty will be reviewed biannually.

Given the multiplicity of medical publications already available, why is a new series needed? Consider that the half-life of medical knowledge is estimated to be around 5 years. Moreover, it can be as long as 8 years between the first description of a medical innovation in a peer-reviewed scientific journal and publication in a medical textbook. A series that narrows this time span between journal and textbook would provide a more rapid and efficient transfer of medical knowledge into clinical practice, and enhance care of our patients.

F. GREHN · R. STAMPER (Eds.)

**Glaucoma**

**T**his first volume of the series Essentials in Ophthalmology aims to give a picture of recent progress in the field of glaucoma, in both basic clinical research and applied clinical science. Its intention is not to replace textbooks on glaucoma, but to serve as a conceptual bridge between original research and textbook presentation.

The volume encompasses (a) genetic aspects of different forms of glaucoma, such as normal tension glaucoma, pseudoexfoliative glaucoma, childhood glaucoma, and angle closure glaucoma, (b) methods of diagnosis, such as imaging techniques, visual fields, electrophysiology, and ultrasound biomicroscopy, and (c) aspects of therapy, such as the target pressure concept, wound modulation in glaucoma surgery, neuroprotection, treatment of normal tension glaucoma, and the evaluation of nonpenetrating surgery. The editors have set out to provide the reader with a diversity of interesting topics reflective of the evidence-based, modern approach to the field of glaucoma.



<http://www.springer.com/978-3-540-40608-2>

Glaucoma

Grehn, F.; Stamper, R. (Eds.)

2004, XIV, 232 p., Hardcover

ISBN: 978-3-540-40608-2