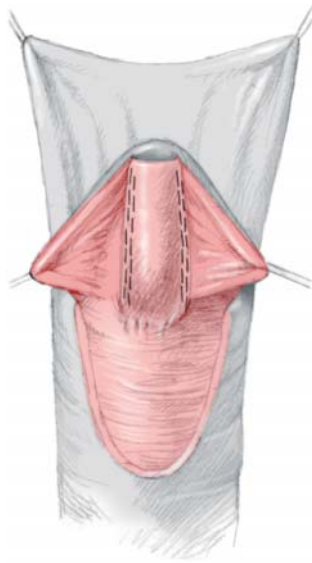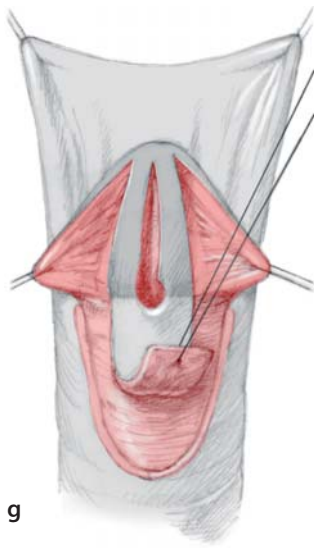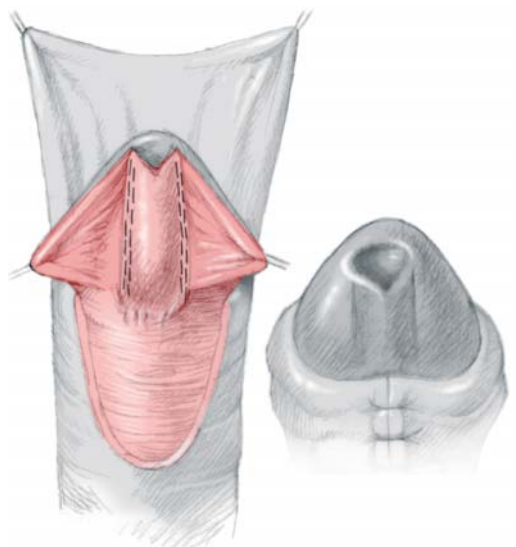
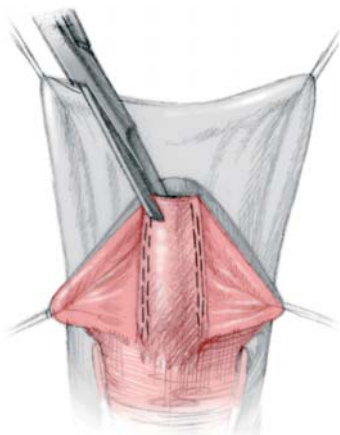
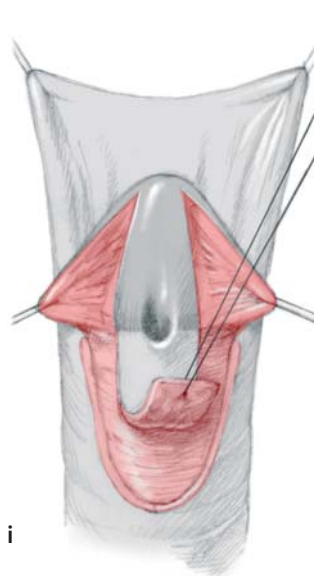
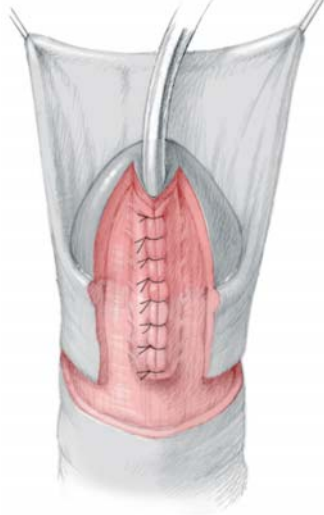
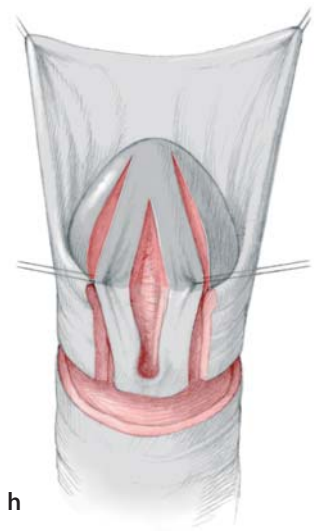


Fig. 25.3 (continued). g Hinging of the urethral plate (Rich et al. 1989). h The tubularised incised plate technique (Snodgrass 1994) follows the same principle. i MAVIS (Boddy and Samuel 2000), a modification of the Mathieu technique, excises a triangle from the apex of the parametatal flap to create a slit-like meatus





<http://www.springer.com/978-3-540-43041-4>

Hypospadias Surgery

An Illustrated Guide

Hadidi, A.; Montgomery, D.A. (Eds.)

2004, XXIII, 375 p., Hardcover

ISBN: 978-3-540-43041-4