

# Repair of Peripheral Radial TFCC Tears

William B. Geissler and Walter H. Short

Arthroscopy has revolutionized the practice of orthopaedics by providing the technical capability to examine and treat intra-articular abnormalities. The development of wrist arthroscopy was a natural progression from the successful application of arthroscopy to other, larger joints. The wrist is a labyrinth composed of 8 carpal bones, multiple articular surfaces with 28 intrinsic and extrinsic ligaments, and the triangular fibrocartilage complex (TFCC), all within a 5-cm interval. This perplexing joint continues to challenge clinicians with an array of potential diagnoses and treatments. Wrist arthroscopy allows direct visualization of the cartilage surfaces, synovial tissue, and the triangular fibrocartilage complex under bright light and magnification.

Ulnar-sided wrist pain is a common complaint that encompasses a broad range of potential differential diagnoses. One potential cause of ulnar-sided wrist pain is a tear or degeneration of the TFCC. Tears of the TFCC can occur centrally or at the radial or ulnar attachment. This chapter addresses the arthroscopic management of radial-sided tears of the triangular fibrocartilage complex.

## ANATOMY OF THE TFCC

The anatomy of the TFCC is quite complicated. It includes the articular disk, meniscus homologue, both the volar and dorsal radioulnar ligaments, and the tendon sheath of the extensor carpi ulnaris tendon. The disk portion of the triangular fibrocartilage complex is thicker at its volar and dorsal margins, which are known as the volar and dorsal radioulnar ligaments. These ligaments function as important stabilizers to the distal radioulnar joint. Approximately 20% of the load of the forearm is transferred through the ulnar side of the wrist and the TFCC. The TFCC acts as an extension of the articular surface of the radius to support the proximal carpal row.

Chidgey et al evaluated the collagen structure of the triangular fibrocartilage complex, attempting to correlate its biomechanic function.<sup>1</sup> He found that short, thick collagen fibers extended from the radius

1 to 2 mm into the articular disk. It is this area where there is a change in collagen arrangement and where many traumatic tears are found (Palmer Class 1A).

The arterial anatomy of the TFCC has also been well studied. Thiru et al. evaluated 12 cadaveric specimens with latex injection and determined three main blood supplies to the triangular fibrocartilage complex.<sup>2</sup> The ulnar artery supplies most of the blood to the TFCC, supporting the ulnar portion through both dorsal and palmar radiocarpal branches. Dorsal and palmar branches of the anterior interosseous artery supply the more radial part of the TFCC. Histological examination of the triangular fibrocartilage complex found vessels filled with latex dye in the outer 15 to 20% of the articular disk. Similarly, Bednar et al. examined 10 cadavers with an ink injection technique and found penetration of the vessels from the peripheral 10 to 40% of the disk.<sup>3</sup> In both studies, there was a relative paucity of vessels found supplying the radial attachment of the triangular fibrocartilage complex. This has significant clinical applications, in that a sufficient blood supply is necessary for successful healing of a repaired peripheral tear. This would be similar to arthroscopic repair of the knee meniscus in its vascular zone. However, several studies have shown clinical improvement and healing following repair of radial-sided TFCC tears, perhaps secondary to stimulating a vascular response from the radius by abrading the bony surface of the sigmoid notch.<sup>4-12</sup> Cooney et al. evaluated 5 patients by MRI evaluation 2 years or more after open repair of a radial-sided tear of the triangular fibrocartilage complex.<sup>5</sup> He documented a solidly healed edge by MRI evaluation.

## CLASSIFICATION OF TFCC TEARS

In 1989, Palmer proposed a classification system for tears of the triangular fibrocartilage complex that divides these injuries into two basic categories: traumatic (Class 1) and degenerative (Class 2) (Table 7.1).<sup>13</sup> Traumatic tears of the triangular fibrocartilage complex from its radial attachment are classified as Type

TABLE 7.1. Classification of TFCC Tears.

| Class 1: Traumatic                                   |   |  |   |  |
|--|---|--|---|--|
| A  | B   | C  | D   |  |
| Central Perforation                                  | Ulnar Avulsion<br>with distal ulnar fx<br>without distal ulnar fx | Distal Avulsion                                    | Radial Avulsion<br>with sigmoid notch fx<br>without sigmoid notch fx                            |  |
| Class 2: Degenerative (Ulnocarpal Abutment Syndrome) |   |  |   |  |
| A  | B   | C  | D   | E  |
| TFCC Wear  | TFCC Wear<br>lunate/ulnar<br>chondromalacia                       | TFCC Perforation<br>lunate/ulnar<br>chondromalacia | TFCC Perforation<br>lunate/ulnar<br>chondromalacia<br>lunotriquetral<br>ligament<br>perforation | TFCC Perforation<br>lunate/ulnar<br>chondromalacia<br>lunotriquetral<br>ligament<br>perforation<br>ulnocarpal<br>arthritis |

ID lesions (Figure 7.1). These tears are traumatic avulsions of the triangular fibrocartilage complex from its attachment on the sigmoid notch, which may or may not include a fracture. It is vital to understand the difference between a Class 1A central perforation and a Class 1D radial avulsion without a bony fragment. A Class 1A central perforation usually runs in a longitudinal volar to dorsal direction and occurs just ulnar to the attachment of the articular disk to the sigmoid notch of the radius. The important distinction between a Class 1A central perforation and Class 1D radial avulsion is involvement of the volar and/or dorsal radioulnar ligaments. When the volar and dorsal radioulnar ligaments are involved in the tear, it affects the stability to the distal radioulnar joint (Figure 7.2) and would be classified as a Class 1D tear.

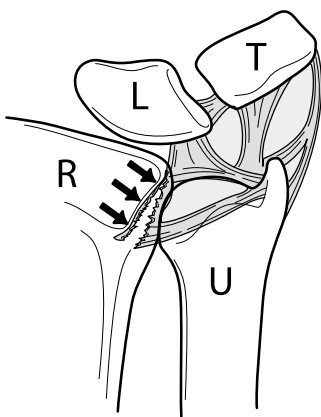
The articular disk has variable thickness throughout its dimension from radial to ulnar. Near its radial attachment, the articular disk is approximately 2 mm thick as compared to its peripheral ulnar attachment, which is up to 5 mm in thickness. Adams has shown

that the peak load occurs along the radial aspect to the articular disk, which is maximized with pronation.<sup>14</sup> The peak strain runs from volar to dorsal in this same area. This is in the area where Chidgey found a change in the collagen arrangement to the articular disk. This is a potential explanation why the prevalence of TFC articular disk injuries occurs along the radial aspect.

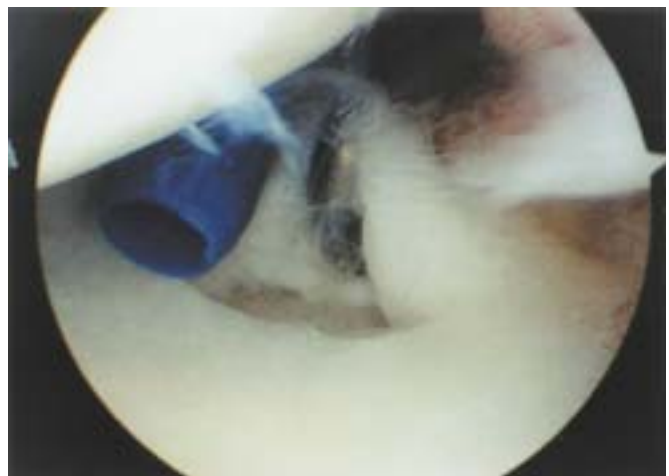
## DIAGNOSIS

### History

Patients with radial sided tears of the triangular fibrocartilage complex commonly report ulnar-sided wrist pain. This may limit work or sports activities. Patients frequently report a single traumatic event, usually a hyperextension injury with the wrist in ulnar deviation, with an acute onset of pain. A common



**FIGURE 7.1.** A Palmer Type 1D tear is a radial tear of the articular disk from the sigmoid notch of the radius with or without a bony avulsion and involvement of the radioulnar ligaments. R = radius, T = triquetrum, U = ulnar, L = lunate.



**FIGURE 7.2.** Arthroscopic view of a Palmer Type 1D peripheral radial tear of the TFCC. The articular disk is torn from its insertion onto the sigmoid notch of the radius, and the volar radioulnar ligament is involved as well.

history is the driver with hands on the steering wheel involved in a motor vehicle accident. Occasionally, patients report a history of a hypertwisting injury to the wrist as well.

### Physical Examination

Physical examination of the wrist frequently reveals ulnar-sided wrist swelling. Patients are tender to palpation over the area of the triangular fibrocartilage complex between the triquetrum and the ulnar styloid. Patients complain of pain with radial and ulnar deviation, as ulnar deviation compresses the TFCC, and radial deviation applies tension to a peripheral tear. Patients may complain of a click when the wrist is pronated passively and supinated in maximum ulnar deviation. This click often represents a tear in the triangular fibrocartilage complex interposed between the head of the ulna and the proximal row of the carpus. Occasionally, when both wrists are flexed, there may be an increased dorsal prominence of the head of the ulna as compared to the unaffected side.

### Diagnostic Modalities

Standard radiographic posterior, anterior, and lateral views may reveal a bony avulsion, and also evaluate ulnar variance. Oblique radiographs are helpful when a bony avulsion is seen. The position of the extremity with the wrist in neutral flexion/extension, the forearm in neutral pronation/supination with the elbow flexed 90 degrees, and the shoulder abducted 90 degrees is used as a standard to measure ulnar variance. Patients with positive ulnar variance may have ulnar impingement syndrome, which is more likely to be associated with a triangular fibrocartilage complex tear. It is important to shorten the ulna at the same sitting with a peripheral repair in a patient with an ulnar-positive wrist.

The use of MRI has become more common in diagnosing tears of the triangular fibrocartilage complex. T2-weighted images are best for evaluation of traumatic tears. The synovial fluid has a high signal intensity on T2-weighted images, allowing it to act as a contrast material. In T1-weighted images, traumatic tears and degenerative changes appear as an intermittent signal. The articular cartilage of the distal radius as it continues as the articular cartilage of the sigmoid notch may be misinterpreted as a radial-sided tear of the triangular fibrocartilage complex on T1-weighted images.

Triple-injection wrist arthrography is the most accurate technique for wrist arthrography if this is chosen to evaluate for tears of the triangular fibrocartilage complex.<sup>15,16</sup> This technique involves an initial injection of the radial carpal joint under fluoroscopic evaluation, followed by injection and evaluation of the midcarpal and distal radioulnar joints. Approximately 25% of triangular fibrocartilage complex abnormali-

ties may be missed by a single-injection wrist arthrography. The distal radioulnar joint injection is important for evaluation of ulnar-sided attachment and partial tears of the proximal surface of the TFCC. Patients with persistent symptoms and a negative arthrogram may still have a peripheral tear of the triangular fibrocartilage complex. This is due to synovitis that forms over the tear, blocking the flow of contrast material. Also, a positive arthrogram must have a strong clinical correlation, as there is a high rate of false positive arthrograms in asymptomatic patients.<sup>17</sup> The natural history of TFCC tears shows that asymptomatic, age-related attrition occurs in more than half of patients over the age of 50. Brown et al. found perforation of the TFCC in 59% of symptomatic patients and in 51% of asymptomatic patients undergoing arthrography for lateral wrist pain.<sup>17</sup>

Wrist arthroscopy continues to be the gold standard for the diagnosis of triangular fibrocartilage complex tears. This technique allows evaluation of the articular disk under bright light and magnified conditions. A probe may be used to palpate the tension to the articular disk using the trampoline test. The articular disk should have a normal taut appearance when palpated by the probe. In a patient with a peripheral tear of the articular disk, the disk is boggy and redundant. In particular, wrist arthroscopy is extremely useful to differentiate between a Palmer Class 1A tear and a radial sided Palmer 1D peripheral tear with involvement of the volar and/or dorsal radioulnar ligaments. The treatment for these two different types of traumatic tears varies significantly.

## TREATMENT

### Nonoperative Management

The nonoperative management for patients with traumatic tears of the articular disk includes a trial of immobilization. Occasionally, a physical therapy program encompassing range of motion and strengthening may be utilized. Steroid or lidocaine injections are extremely useful to differentiate a peripheral tear from tendinitis of the extensor carpi ulnaris tendon.

### Indications for Surgery

Surgical indications include failure to improve after 3 months of conservative treatment, with symptoms that impair function. A second indication would include instability of the distal radioulnar joint.

## SURGICAL TECHNIQUE

The patient is positioned supine on the operating room table with the affected arm on a hand table and a

padded tourniquet proximal to the arm. A tourniquet is applied but rarely inflated during the procedure. After general endotracheal anesthesia has been obtained, the wrist is suspended in a traction tower with approximately 10 pounds of traction. The wrist is systematically evaluated, with the arthroscope initially placed in the 3-4 viewing portal. A probe is utilized in the 6-R portal to palpate the articular disk and to assess the tension to the articular disk. If the tear is ulnar to the attachment of the articular disk to the radius with no loss of tension and does not involve the volar or dorsal radioulnar ligaments, the tear is arthroscopically debrided as described in Chapter 9. When the tear involves the entire length of the sigmoid notch with involvement of the volar and/or dorsal radioulnar ligament and the disk is soft with loss of tension, this would be consistent with a Palmer Class 1D radial-sided tear of the triangular fibrocartilage complex. A number of arthroscopic repair techniques for radial-sided tears of the triangular fibrocartilage complex have been described in the literature.<sup>4,6,7,9-12,18,19</sup>

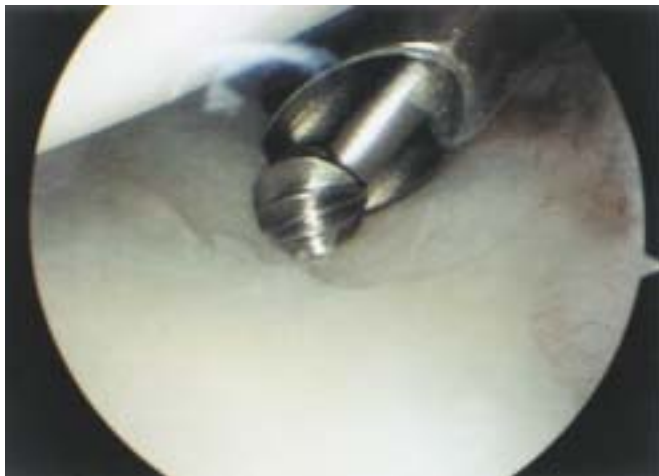Patients who have a bony avulsion of the articular disk from the sigmoid notch to the radius are arthroscopically pinned. The wrist is removed from traction. Under fluoroscopic control, two 0.045 Kirschner wires are placed just proximal to the articular surface from the radial styloid across the radius into the avulsed fragment. The starting position for the Kirschner wire just beneath the articular surface of the radial styloid is visualized under fluoroscopy. It is important to make approximately a 1 cm skin incision and insert the Kirschner wires through a soft tissue protector to protect the soft tissues, particularly the dorsal sensory branch of the radial nerve. Under fluoroscopic control, the Kirschner wires are started into the radius and advanced ulnarly just short of crossing the avulsed fracture fragment. The wrist is then placed back in traction. The arthroscope is then placed in the 3-4 portal, and a probe is utilized in the 6-R portal. Under direct arthroscopic visualization, the fracture fragment is reduced and potentially stabilized with the probe in the 6-R portal. Once the fracture is anatomically reduced under direct observation with the arthroscope, the Kirschner wires are advanced across the fracture fragment. Following placement of the Kirschner wires, the wrist is removed from traction and viewed under fluoroscopy. Two Kirschner wires are usually inserted. It is important to view this under fluoroscopy to determine that the pins have not violated the distal radioulnar joint or the articular surface. Once this has been confirmed fluoroscopically, the wrist is pronated and supinated to note any crepitance. If crepitance is noted, the pins are backed up slightly, as they are impinging upon the distal radioulnar joint. Following successful pinning, the wrist is immobilized. The pins may then be removed in the office approximately 6 weeks later. If the fracture fragment is relatively large, consideration can be given to potentially using a head-

less cannulated screw. Generally, one screw would be used. The technique for using a headless cannulated screw is similar to using Kirschner wires. Two cannulated guidewires are placed, from radial to ulnar, similar to the Kirschner wire technique. One cannulated guidewire is for placement of the screw, and the second is to control rotation while the fracture fragment is drilled and the screw is inserted. Once the guidewires have been advanced into the fracture fragment as viewed arthroscopically, the wrist is taken out of traction. The radius and avulsion fragment are drilled with a cannulated reamer, and a headless cannulated screw is then placed under fluoroscopic control across the radius into the avulsion fragment. Following placement of the screw, the wrist is placed in pronation and supination to confirm that the distal radioulnar joint has not been violated and that there is no impingement of the screw against the articular surface of the ulna. Once this has been confirmed, the wrist is again suspended in traction, and the reduction is checked under arthroscopic control to make sure the fragment is not rotationally malpositioned. After anatomic reduction of the avulsion fragment is confirmed arthroscopically, the secondary guidewire used to protect against rotation is removed. The wrist is then immobilized.

Several arthroscopic techniques have been developed for repair of a Palmer Type 1D radial-sided tear of the triangular fibrocartilage complex that does not involve bone.<sup>4,6,7,9-12</sup> Sagerman and Short have described an arthroscopic technique for reattachment of radial-sided tears of the articular disk.<sup>7</sup> Utilizing their technique, the wrist is suspended in a traction tower with 10 pounds of traction. The arthroscope is introduced into the 3-4 portal, and working portals are made in the 6-R and 6-U portals. Particularly when making the 6-U portal, it is vital to excise only the skin, with just the tip of the knife blade. This is performed by pulling the tip of the knife blade against the skin with the thumb. Blunt dissection is then continued with a hemostat to level the capsule, and an arthroscopic wrist cannula is then introduced into the 6-U portal. It is important to protect the dorsal sensory branch of the ulnar nerve when utilizing these techniques. Prior to making the 6-U portal, a needle is inserted into the proposed location and viewed intra-articularly with the arthroscope in the 3-4 portal. It is important to determine the ideal location of the 6-U portal so that it is not too proximal or distal to violate the carpus of the wrist or too proximal to pass through the articular disk itself.

An arthroscopic bur is brought in through the 6-R portal. The sigmoid notch of the distal radius is then abraded with the bur (Figure 7.3). The purpose of this is to help stimulate a vascular response to facilitate healing of the radial triangular fibrocartilage complex. This is similar in principle to abrading the greater tuberosity of the humerus while repairing a tear of the



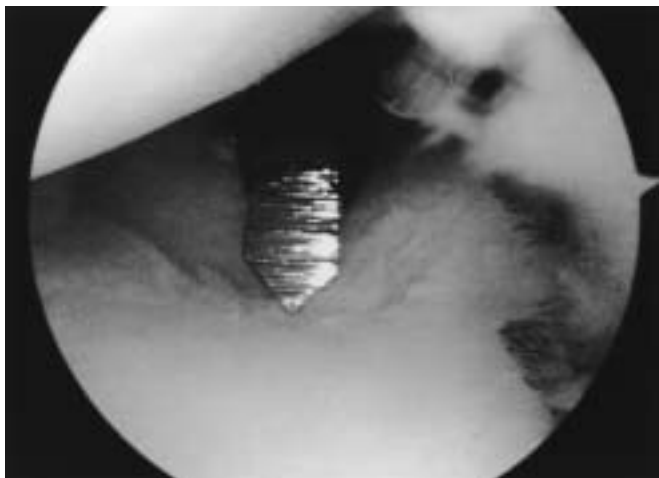


**FIGURE 7.3.** Arthroscopic view of a burr inserted through 6-R working portal being used to abrade lightly the sigmoid notch of the radius to facilitate revascularization of the radial TFCC tear that is to be repaired

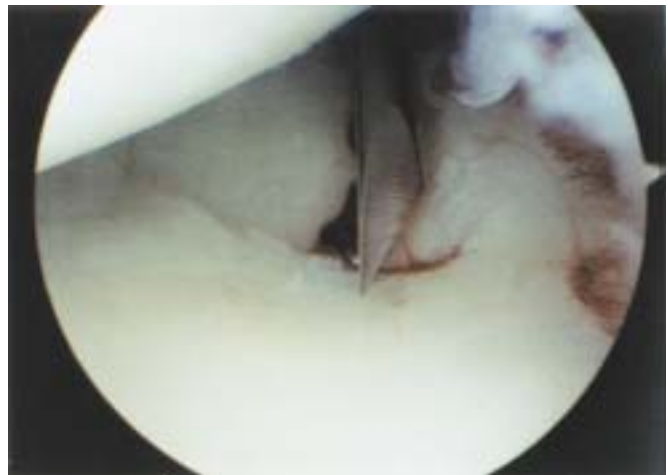rotator cuff. The key in this technique is not to overabrade the sigmoid notch of the radius. If the sigmoid notch is aggressively abraded and too much bone is taken, the articular disk may not reach the radius. It is best to slightly abrade the sigmoid notch until cancellous bone is visualized. Following abrasion of the sigmoid notch, a 0.062 Kirschner wire is brought in through the 6-U portal in the cannula (Figure 7.4). The cannula is important to protect the soft tissues, particularly the dorsal sensory branch of the ulnar nerve. The 0.062 Kirschner wire is used to make the drill hole, rather than a drill bit. There is less tendency for the Kirschner wire to travel when initially making the drill hole. Three drill holes are then made, starting at the sigmoid notch and exiting across the radius. The wires should exit on the distal third of the

radial side of the forearm. The three drill holes are spaced equally, volar to dorsal. Double-armed, long meniscus repair needles with nonabsorbable suture are then utilized. The first limb of the needle is placed through the cannula (Figure 7.5). The needle is placed through the articular disk and into the volar-most drill hole made by the Kirschner wire. A trick to help the needle penetrate the articular disk is to flip up the torn edge of the articular disk with a probe inserted through the 6-R portal. Another option is to take a grasper through the 6-R portal and grab the torn edge of the articular disk and invert this. This makes it easier for the needle to penetrate through the articular disk. There is always concern about finding the drill hole made in the sigmoid notch and across the radius with the Kirschner wire with the needle after it has penetrated through the articular disk. This is usually not a problem. The drill hole made by a 0.062 Kirschner wire is considerably larger than the meniscus repair needle. It is usually relatively easy and straightforward to find this hole with a needle. A grasper inserted through the 6-R portal can further help to direct the needle into the drill hole, as these needles are quite flexible and may be hard to control inserting through the 6-U portal and a cannula. The meniscus repair needle is then advanced through the drill hole in the radius and advanced out the skin. A second arm of the meniscus repair needle is then brought in through the 6-U portal and advanced through the articular disk in a horizontal mattress fashion (Figure 7.6). The wire is then passed through the middle drill hole of the sigmoid notch and out the radius. The sutures are tagged with a hemostat.

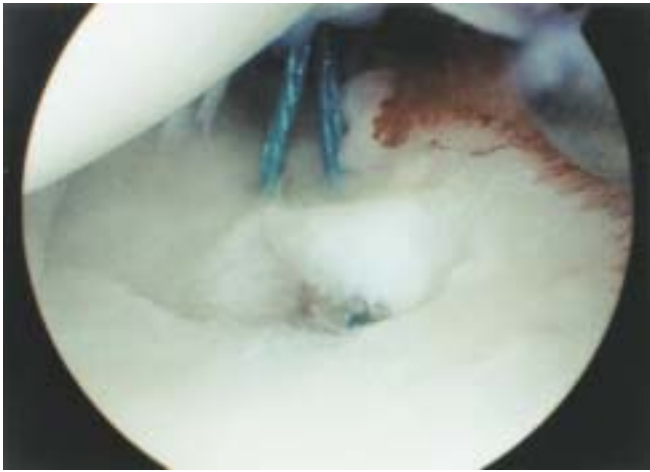
The procedure is repeated with a second set of meniscus repair needles. The first arm of the needle is passed through the articular disk and through the



**FIGURE 7.4.** Arthroscopic view of a 0.062 Kirschner wire being inserted through a cannula in the 6-U portal to drill 3 holes volar to dorsal from the sigmoid notch across the radius and exiting at the distal radial portion of the radius.



**FIGURE 7.5.** Arthroscopic view of the tip of a long meniscal repair needle inserted through a cannula in the 6-U portal as it is about to be inserted through the radial articular disk.



**FIGURE 7.6.** Arthroscopic view of the 2-0 braided suture being pulled through the articular disk to reattach it to the sigmoid notch.

central drill hole. The last arm of the meniscus repair needle is passed through the articular disk into the dorsalmost drill hole in the sigmoid notch (Figure 7.7). Following placement of the sutures, a small skin incision is made over the radius. Dissection is carried down to identify the suture. The suture is then tied down directly on bone. It is important to visualize that the knot is tied directly down to the bone so that no soft tissue is impaled in the repair, such as the tendons of the extensor carpi ulnaris longus or, particularly, the dorsal sensory branch of the radial nerve. Previous attempts have been made to tie the sutures over a 3.5 mm screw by the lead author. However, this screw frequently caused a painful bursa over the extensor carpi radialis brevis tendon, and this technique is no longer utilized. The distal radioulnar joint may then be pinned in neutral position with a 0.062 Kirschner wire, depending on the surgeon's preference.

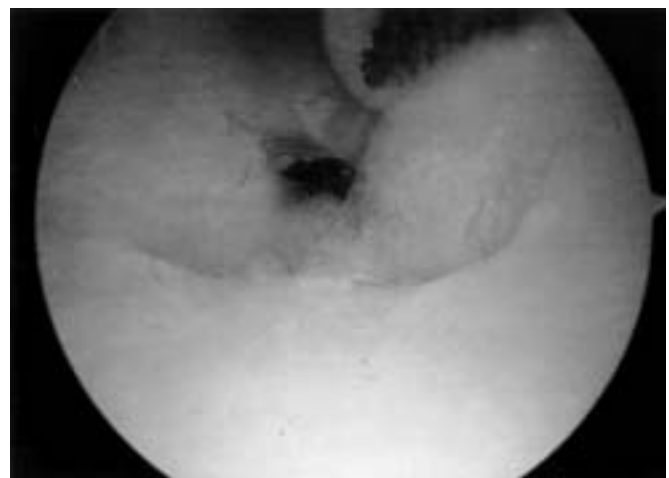
Trumble et al described a similar technique.<sup>4</sup> In his technique, the arthroscope is again placed in the 3-4 portal and meniscus repair sutures (2-0 Maxon, Davis & Geck, Manati, PA) are placed into the 6-U cannula and into the radial edge of the TFCC tear under arthroscopic guidance. The needles are then driven across the radius using a power wire driver, aiming to exit between the first and second dorsal compartments of the radial aspect of the wrist. He notes that care must be taken to avoid coiling of the double-arm sutures, which is accomplished when drilling the first needle by loosely holding the suture, and allowing the second needle to rotate. The first suture is brought out through the skin, and a second suture is placed. To avoid coiling as the second needle is passed, Trumble advised placing the wire driver with the suture folded next to the needle and placing a curved retractor around the loop of the suture between the tip of the wire driver and the patient. As the wire advances, the suture coils around the needle until it reaches the

length of the needle, when the driver wire is reversed. The coiling and uncoiling of the sutures continue until the needle exits the skin along the radial side of the wrist. Trumble recommends two sets of repair sutures be placed to secure the triangular fibrocartilage complex to the radius. In a modification of Trumble's technique, long Keith needles may be placed through the 6-U portal into the articular disk and advanced with a power driver across the radius. Once the needle exits the skin on the radial side of the wrist, a non-absorbable suture may be placed through the eye of the Keith needle and the needle then pulled through the articular disk and out the radius. In this technique, the coiling and uncoiling of the suture is minimized.

Plancher describes his surgical technique for arthroscopic repair of radial-sided tears of the triangular fibrocartilage complex.<sup>12</sup> In his technique, he utilizes a small-joint arthroscopic guide inserted with a point through the 4-5 portal. A guidewire is then brought in from radial to ulnar through the articular disk. This guidewire is then used to pass a 2-0 PDS suture through the radius. A Mulberry knot is then tied in the PDS suture to stabilize the articular disk.

Similarly, Jantea has developed a specialized jig for radial-sided TFC repair.<sup>9,10</sup> With this specialized jig, the meniscus repair needle is brought in through the 6-U portal and out the distal radius. This jig helps to identify the location of the needle as it exits the radial side of the wrist.

New arthroscopic techniques to simplify the repair of radial- and ulnar-sided tears of the triangular fibrocartilage complex are currently being developed. One such technique currently being developed by Geissler utilizes technology similar to the DePuy Mitek RAPIDLOC™ (Norwood, MA), a hybrid suture device for meniscus repair of the knee. In this technique, the arthroscope is placed in the 3-4 portal and two drill holes are made in the sigmoid notch with a Kirschner

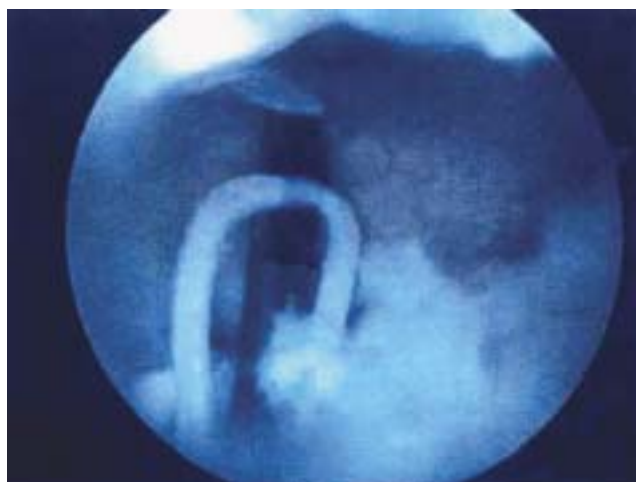


**FIGURE 7.7.** Arthroscopic view of the braided permanent suture securing the radial articular disk tear back to the sigmoid notch of the radius.

wire again inserted into the 6-U portal. A very small incision is then made over the radial side of the wrist, where the Kirschner wire has exited. Dissection is carried bluntly down to the bone where the Kirschner wire is seen exiting. An inserting device is then placed through the drill hole of the radius and out the sigmoid notch of the radius (Figure 7.8). A grasper is inserted through the 6-R portal to invert the edge of the articular disk. The inserter needle is then passed through the articular disk under direct observation with the arthroscope in the 3-4 portal (Figure 7.9). The absorbable PLA backstop is then deployed through the inserter needle across the radial-sided tear of the articular disk. The PLA TopHat is then slid down, with a pretied slipknot, the attached 2/0 ETHIBOND® (ETHICON, Inc., Somerville, NJ) securing the TopHat against the bone of the distal radius. This greatly simplifies the radial-sided repair of the articular disk. One or two devices are placed utilizing this technique. This new technique appears quite promising, particularly for its simplicity; however, continued clinical evaluation will need to be performed to evaluate its effectiveness. Ulnar repairs may also be performed with appropriate modifications to the technique and inserter.

## RESULTS

Open and arthroscopic repair of radial-sided tears of the triangular fibrocartilage complex have been reported with acceptable results in the literature. Cooney et al reported on the results of open radial-sided triangular fibrocartilage repairs in 23 patients.<sup>5</sup> Eleven patients had concomitant shortening of the ulna. In their series, 18 patients had good or excellent results, 4 had fair results, and 1 patient had a poor re-

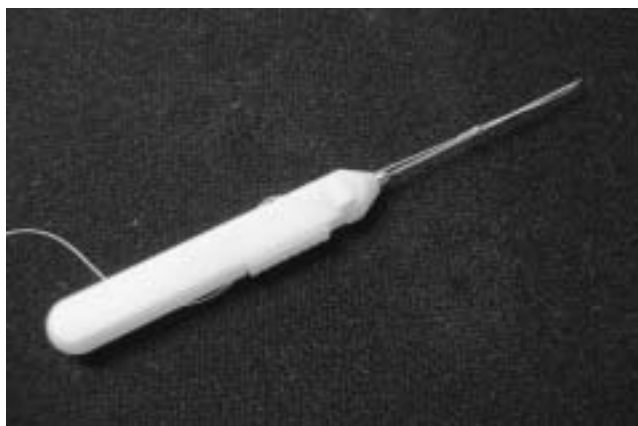

**FIGURE 7.9.** Arthroscopic view of the needle passed through the radius and articular disk before the backstop is inserted through the radial TFCC tear.

sult. Of the patients with an unsatisfactory result, 2 had experienced reinjury and 1 had experienced postoperative pain syndrome. As noted earlier, 5 patients in the study underwent MRI imaging after more than 2 years post repair. MRI documented healing in 4 of the 5 patients. The authors concluded that repair of radial-sided tears of the triangular fibrocartilage complex is warranted, given the important biomechanical function to the wrist.

Sagerman and Short reported their results of arthroscopic repair of peripheral radial-sided tears of the TFCC in 12 patients.<sup>7</sup> They reported good or excellent results in 8 of 12 patients. Five patients underwent postoperative arthrogram evaluation. There was no leak found in 3 of 5 patients who underwent a postoperative arthrogram evaluation. Trumble reported on 13 patients with isolated Palmer Type 1D triangular fibrocartilage complex tears with an average follow-up of 34 months.<sup>4</sup> In his study, patients regained 87% of their total range of motion and 89% of their strength, compared with the contralateral wrist. This compares favorably with reports of ulnar-sided TFCC repairs. The authors also addressed the fate of radial-sided repairs in 10 of the 13 patients. The triangular fibrocartilage complex was found to be intact in 4 of 5 patients who underwent postoperative arthrograms, in 3 of 3 patients who underwent postoperative MRI imaging studies, and in both of 2 patients who were followed up by arthroscopy.

Traumatic radial-sided tears of the triangular fibrocartilage complex are much less common than central perforations or ulnar-sided tears. However, radial-sided tears of the TFCC are an important potential cause of ulnar-sided wrist pain, particularly when involvement of the volar and/or dorsal radioulnar ligaments leads to potential chronic pain and instability of the distal radioulnar joint.



**FIGURE 7.8.** View of a new TFCC repair device (DePuy Mitek, Norwood, MA) to fix both radial and ulnar-sided peripheral tears of the articular disk. The needle perforates the articular disk and the backstop is inserted through the disk. The TopHat is then slid down with a pre-tied slip knot to secure the tear against the radius (radial TFCC tear) or the tendon sheath of the extensor carpi ulnaris (ulnar TFCC tear).

## CONCLUSION

Wrist arthroscopy is a sensitive modality to evaluate for tears of the triangular fibrocartilage complex. It allows precise identification of the tear pattern as well as the severity of the tear. Wrist arthroscopy allows evaluation of the integrity of the articular disk through palpation with a probe and documents when the tear extends to involve radioulnar ligaments. When a radial-sided tear of the articular disk includes the volar and/or dorsal radioulnar ligaments, arthroscopic repair of the TFCC should be considered. Although anatomic studies have shown decreased vascularity on the radial side of the triangular fibrocartilage complex, several studies have shown successful repair of the articular disk, both clinically and by objective imaging with arthrograms and MRI.

Arthroscopic repair of radial-sided tears of the TFCC is safe and effective. Several surgical techniques have been described in the literature. Arthroscopic techniques have less morbidity and potentially accelerated rehabilitation for patients compared to open repair. New techniques continue to be developed to further simplify the procedure.

## References

1. Chidgey LK, Dell PC, Bittar ES, et al. Histologic anatomy of the triangular fibrocartilage. *J Hand Surg* 1991;16:1084–1100.
2. Thiru RG, Ferlic DC, Clayton MI, et al. Arterial anatomy of the triangular fibrocartilage of the wrist and its surgical significance. *J Hand Surg* 1986;11:258–263.
3. Bednar MS, Arnoczky SP, Weiland AJ. The microvasculature of the triangular fibrocartilage complex: its clinical significance. *J Hand Surg* 1991;16:1101–1105.
4. Trumble TE, Gilbert M, Vedder N. Isolated tears of the triangular fibrocartilage: management by early arthroscopic repair. *J Hand Surg* 1997;22:57–65.
5. Cooney WP, Linscheid RL, Dobyns JH. Triangular fibrocartilage tears. *J Hand Surg* 1994;19:143–154.
6. Fellingner M, Peicha G, Seibert FJ, et al. Radial avulsion of the triangular fibrocartilage complex in acute wrist trauma: a new technique for arthroscopic repair. *Arthroscopy* 1997;13:370–374.
7. Sagerman SD, Short W. Arthroscopic repair of radial-sided triangular fibrocartilage complex tears. *Arthroscopy* 1996;12:339–342.
8. Herrmannsdorfer JD, Kleinman WB. Management of chronic peripheral tears of the triangular fibrocartilage complex. *J Hand Surg* 1991;16:340–346.
9. Jantea CL. Radial TFCC repairs. *Hand Clin* 1995;11:31–38.
10. Jantea CL, Baltzer A, Ruther W. Arthroscopic repair of radial sided lesion of the triangular fibrocartilage complex. *Hand Clin* 1995;11:31–36.
11. Jones MD, Trumble TE. Arthroscopic repair of radial sided triangular fibrocartilage complex tears. *Atlas Hand Clin* 2001;6:221–239.
12. Plancher KD. Arthroscopic repair of radial TFCC tears. *Techn Hand Upper Ext* 1999;3:44–50.
13. Palmer AK. Triangular fibrocartilage complex lesions: a classification. *J Hand Surg* 1989;14:594–606.
14. Adams B. Partial excision of the triangular fibrocartilage complex articular disk, a biomechanical study. *J Hand Surg* 1993;18:334–340.
15. Levinsohn EM, Rosen ID, Palmer AK. Wrist arthrography: value of the three-compartment injection method. *Radiology* 1991;179:231–239.
16. Zinberg EM, Palmer AK, Coren AB, et al. The triple injection wrist arthrogram. *J Hand Surg* 1988;13:803–809.
17. Brown JA, Janzen DL, Adler BD, et al. Arthrography of the contralateral, asymptomatic wrist in patients with unilateral wrist pain. *Can Assoc Radiol J* 1994;45:292–296.
18. Minami A, Kaneda K, Itoga H. Hemiresection interposition arthroplasty of the distal radioulnar joint associated with repair of triangular fibrocartilage complex lesions. *J Hand Surg* 1991;16:1120–1125.
19. Geissler WB, Fernandez DL, Lamey DM. Distal radioulnar joint injuries associated with fractures of the distal radius. *Clin Orthop* 1996;327:135–146.



Wrist Arthroscopy

Geissler, W. (Ed.)

2005, XIV, 202 p. 321 illus., 44 illus. in color., Hardcover

ISBN: 978-0-387-20897-8