

Historical Issues and Atypical Parkinsonian Disorders

Christopher G. Goetz

Studying archetypes is a fundamental task in nosography. Duchenne de Boulogne practiced it instinctively, and many others have done it before and after him: It is indispensable, and the only way to extract a specific pathological state from the chaos of imprecision. The history of medicine, which is long and grand, shows this truth well. But once the archetype is established, the second nosographic operation begins: dissect the archetype and analyze its parts. One must, in other words, learn how to recognize the imperfect cases, the *formes frustes*, or examples where only one feature occurs in isolation. Using this second method, the physician will see the archetypal illness in an entirely new light. One's scope enlarges, and the illness becomes much more important in the doctor's daily practice. To the patient's benefit, the doctor becomes attentive and sensitive to recognizing a disease, even when it is in its earliest developmental stages (1).

INTRODUCTION

As shown in the above quotation from Jean-Martin Charcot's teaching of the late 19th century, the concept of *atypical Parkinsonian disorders* and *formes frustes* of the classic disease emerged in parallel with the definition of Parkinson's disease itself. In 1817, James Parkinson, a London general practitioner, described resting tremor and gait impairment in the small sample of subjects whose symptoms would later be coalesced into a disorder that would bear his name (2). Nearly 50 yr later, Charcot returned to this early description and used his large patient population to study Parkinson's disease in full detail. With access to thousands of elderly patients who lived in the sprawling hospital-city of the Hôpital de la Salpêtrière in central Paris, Charcot studied the evolution of signs from very early disease through the most advanced stages (3,4). Charcot used specialized recording equipment to distinguish the rest tremor of typical Parkinson's disease from the tremors typical of multiple sclerosis and other conditions where posture- or action-induced exacerbation occurred (5). He was particularly adept in distinguishing bradykinesia as a cardinal feature of the illness and separating it from weakness. These studies led him to discourage the original designation of *paralysis agitans*, because patients did not develop clinically significant loss of muscle power until very late. Charcot further emphasized the distinctive elements of rigidity and delineated its distinction from spasticity or other forms of hypertonicity. Finally, he succinctly described the stance and gait of the subject with Parkinson's disease:

His head bends forward, he takes a few steps and they become quicker and quicker to the point that he can even bump into the wall and hurt himself. If I pull on his trousers from behind, he will repulse in the same distinctive way (4).

Charcot's celebrated teaching courses and publications established these four features—rest tremor, bradykinesia, rigidity, and postural reflex impairment in balance and stance—as the cardinal features of typical Parkinson's disease. Charcot complemented these studies with documentation of trophic and arthritic features of the illness, with further studies of pain and autonomic nervous system alterations, and with pharmacological observations (3). At the same time, however, as indicated in the introductory quotation of this chapter, he emphasized the importance of recognizing cases that he termed variants or *formes frustes*, cases that were similar to and yet distinct from the classic, archetypal form of the disease. These cases were termed *atypical Parkinson's disease*, at a time when the pathological substrate of Parkinson's disease itself remained unknown. As a historical introduction to the conditions that are the primary focus of this book and today collectively termed *atypical parkinsonian disorders*, these historical cases provide source material for the early study of conditions later to be separated from Parkinson's disease and defined in the mid- and late-20th century as progressive supranuclear palsy, multiple system atrophy, and corticobasal degeneration.

EARLY CONCEPTS OF ATYPICAL PARKINSON'S DISEASE

Nineteenth-century neurologists recognized three basic categories of parkinsonism that were suitably different from typical Parkinson's disease to merit designation: cases without typical tremor, those with atypical postures (extension rather than flexion), and those with marked asymmetry in the form of seeming hemiplegia. Within these categories, modern neurologists will find characteristics that typify progressive supranuclear palsy, multiple system atrophy, and corticobasal degeneration, though these latter diagnoses were not defined specifically until clinical-pathological studies distinguished them as distinct from Parkinson's disease itself. Each of these clinical categories is described from the perspective of 19th-century neurology and then followed by a specific discussion of the history of progressive supranuclear palsy, multiple system atrophy, and corticobasal degeneration.

Parkinsonism Without Prominent Rest Tremor

Early neurologists recognized resting tremor as the most distinctive feature of typical Parkinson's disease, and placed patients who had unusual, intermittent tremor patterns or no tremor into the clinical category termed "Parkinson's disease without tremor" (3,4). Some of these cases actually had tremor, but the movements were mild in severity or intermittent and primarily induced with emotion or action (3). It is possible that myoclonus, a feature frequently seen in corticobasal degeneration, and mild action tremor that can be seen in multiple system atrophy would have been categorized as one of these intermittent tremors. Myoclonus was appreciated in the 19th century, especially by Germanic and Austrian researchers (6,7), but not specifically designated as an aspect of atypical Parkinson's disease. Charcot studied tremor extensively and drew attention to its typical features in Parkinson's disease. He conducted his tremor examination with patients at rest and during activity. In addition to clinical observation, he used tremor oscillometers (Fig. 1) and small portable lamps that he attached to the shaking extremities in order to record the trajectory movements on light-sensitive paper (8). To accentuate an appreciation of very mild tremor, he attached feathers or other lightweight objects to the shaking body part to magnify the oscillations. He held strongly that titubation was not part of typical Parkinson's disease, but lip and tongue tremors could occur. Because parkinsonian cases without tremor were still considered as variants of the primary disease, Charcot advocated the use of the term Parkinson's disease, rather than "paralysis agitans," as coined by Parkinson himself (3,4).

Parkinsonism With Atypical Postures

Charcot studied muscle tone extensively and established that most Parkinson's disease subjects showed a flexed posture with the shoulders hunched forward, neck bent down toward the chest, and the arms held in partial flexion at rest. In contrast, he found a small number of parkinsonian patients

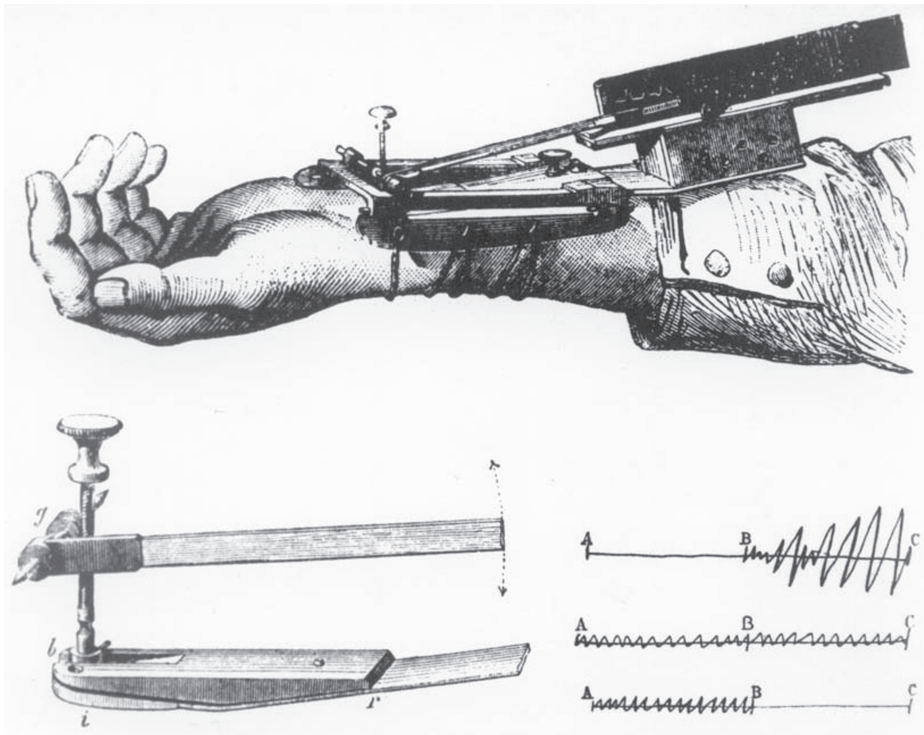


Fig. 1. Tremor recording machine used by Charcot to separate cases of typical rest tremor from those with postural tremor and action-induced tremor. Early studies focused on the differentiation by tremor type of multiple sclerosis and Parkinson's disease, but this apparatus was later used to study the various *formes frustes* of Parkinson's disease as well. In the insert, tremor recordings are shown for resting posture (AB) and action (BC) in patients with different tremor patterns. From *Dictionnaire Encyclopédique des Sciences Médicales*, 1883.

who were bradykinetic, unstable in their stance and gait, and yet showed a very different posture. These subjects, collectively termed "Parkinson's disease with extended posture," were of particular interest to Charcot, and he recognized several features of these cases that distinguished them from the archetypal cases of Parkinson's disease. These cases are further discussed later in the subheading on Progressive Supranuclear Palsy and shared several additional features of this diagnosis including the distinctive facial expression, swallowing difficulties, and frequent falls (Fig. 2).

Hemiplegic Parkinson's Disease

Early neurologists considered Parkinson's disease to be a bilateral condition, but often commented on the mild asymmetry of tremor, especially in the early years of disease. Within the context of this asymmetric but bilateral archetype, they distinguished another form of Parkinson's disease that was highly asymmetric with prominent disability in the involved upper extremity beyond that expected with bradykinesia alone (3). Collectively termed *hemiplegic Parkinson's disease*, these cases form a large series in the French neurological literature of the late 19th century and include cases of abrupt strokelike onset as well as slowly progressive disability (9) (Fig. 3). They are discussed in the section on corticobasal degeneration, because they clinically fit best into this designation among the group of atypical parkinsonian disorders. Because infectious disease (abscess and hemorrhagic strokes especially from military tuberculosis) were frequent disorders in the 19th century, some of these cases may not have related to primary neurodegeneration. Furthermore, autopsy reports were not systematically recorded, so that analysis of cases as corticobasal degeneration remains only suggestive.

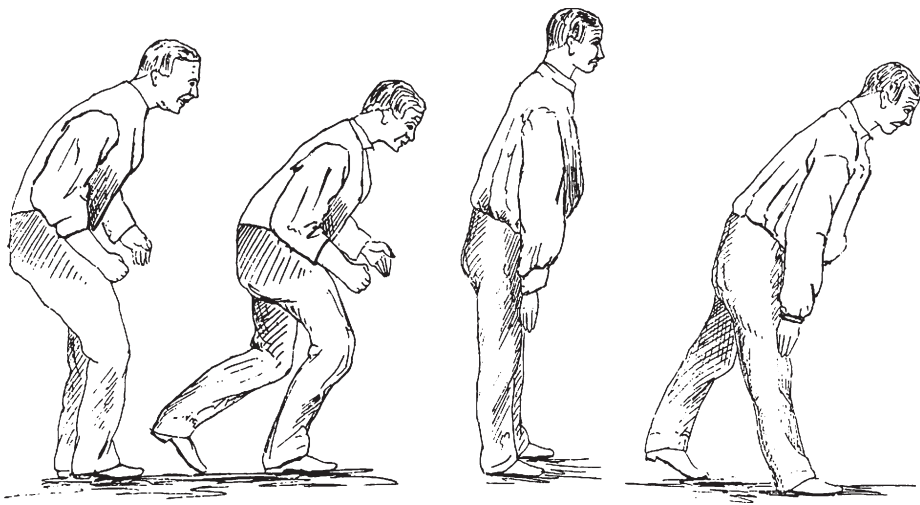


Fig. 2. Drawing by J-M Charcot comparing two patients: (left) typical Parkinson's disease with flexed posture and (right) another patient with an atypical variant of extended posture (4).



Fig. 3. Photograph from an article by Dutil (17) showing asymmetric parkinsonism suggestive of corticobasal degeneration but with an extended trunk and neck posture with gaze impairment suggestive of progressive supranuclear palsy.

HISTORICAL DESCRIPTIONS OF ATYPICAL PARKINSONIAN DISORDERS

Progressive Supranuclear Palsy

In 1963, Steele, Richardson, and Olszewski presented a report at the American Neurological Association of a new syndrome typified by parkinsonism, marked vertical gaze paresis, dementia, and axial rigidity (10,11). Though they felt they were describing a new syndrome, they referred colleagues to similar cases from the recent past (12–14) (Fig. 4). H. Houston Merritt opened the discussion, commenting that he had not seen similar cases, that the involved areas all related to cell populations of similar phylogenetic age, and that dementia was of particular interest. F. McNaughton acclaimed: “I believe that the authors have described a clear-cut neurological syndrome and to judge from the pathological studies, it may, in fact, represent a new disease entity.” D. Denny-Brown was less sure and ascribed the cases to variants of Jakob’s “spastic pseudosclerosis” (10).

Prior to these 20th-century descriptions, several cases of “Parkinson’s disease with extended posture” can be identified with characteristics suggestive of progressive supranuclear palsy. Charcot presented a man, named Bachère, to his students on several occasions (*see* Fig. 2). Commenting on June 12, 1888, Charcot mentioned that Bachère did not have marked tremor and emphasized the issue of extension posture:

There is something else unusual here worth noting. Look how he stands. I present him in profile so you can see the inclination of the head and trunk, well described by Parkinson. All this is typical. What is atypical, however, is that Bachère’s forearms and legs are extended, making the extremities like rigid bars, whereas in the ordinary case, the same body parts are partly flexed. One can say then that in the typical case of Parkinson’s disease, flexion is the predominant feature, whereas here, extension predominates and accounts for this unusual presentation. The difference is even more evident when the patient walks (3).

In addition to extended posture, this patient had particular facial bradykinesia and contracted forehead muscles (15). Charcot commented that the patient had the perpetual look of surprise because the eyes remained widely opened and the forehead continually wrinkled (Fig. 5). In a modern setting, Jankovic has detailed similar facial morphology in Parkinsonism-plus patients, specifically those with progressive supranuclear palsy (16). The extended truncal posture of this patient would be compatible with the posture of progressive supranuclear palsy, although Charcot did not comment on specific supranuclear eye movement abnormalities. Another Salpêtrière patient with “Parkinson’s disease in extension” was described by Dutil in 1889 and eye movement abnormalities are mentioned, although a supranuclear lesion is not documented clinically (17,18) (*see* Fig. 3). This case also had highly asymmetric rigidity of the extremities, a feature more reminiscent of corticobasal degeneration than progressive supranuclear palsy (*see* next subheading). In this case, the extended neck posture was graphically emphasized:

The face is masked, the forehead wrinkled, the eyebrows raised, the eyes immobile. This facies, associated with the extended posture of the head and trunk, gives the patient a singularly majestic air (17,18).

With clinical features reminiscent of both progressive supranuclear palsy and corticobasal degeneration, this patient was mentioned in several articles from the Salpêtrière school, although no autopsy was apparently performed.

In their studies of tremor and Parkinson’s disease, Charcot and contemporary colleagues described several other cases of parkinsonian patients who never suffered with either prominent resting or postural tremor. Although the descriptive details are often cursory, several of these cases may well represent cases of progressive supranuclear palsy. Bourneville published two cases in 1876 (19), and later French students chose this subclass of patients for special clinical emphasis (20). In his thesis on

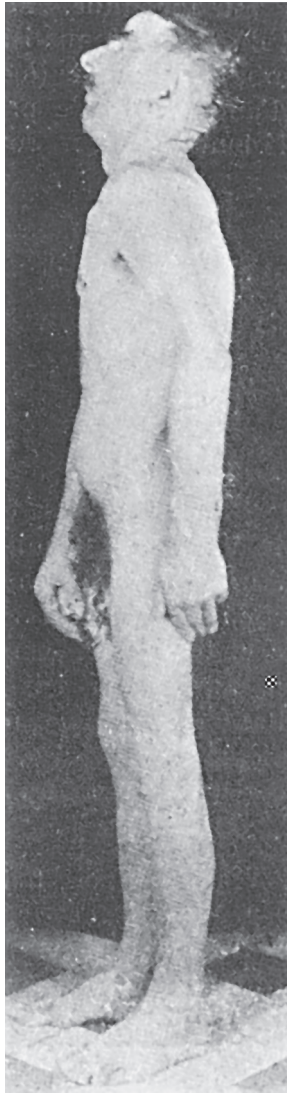

Fig. 4. Photograph from 1951 article by Chavany (12) showing a patient with extended posture suggestive of progressive supranuclear palsy prior to the definitive description by Steele and colleagues in 1964.

atypical forms of parkinsonism, Compin specifically noted that parkinsonian cases without tremor showed especially marked rigidity and often fall (20). His first case history documented several additional features typical of the group of parkinsonism-plus syndromes, including early age of onset (age 45), prominent gait and balance difficulty within the first years of illness, and other midline dysfunction such as marked and early speech impairment.

Historical research on early medical diagnoses has occasionally benefited from nonmedical sources, especially literary descriptions. Because movement disorders are particularly visual in their character, it is reasonable to search the writings of celebrated authors known for their picturesque descriptive




Fig. 5. Four pictures drawn by Charcot of a patient with likely progressive supranuclear palsy. The top two sketches emphasize the superior orbicularis contracture of the forehead, whereas the lower sketches capture the activation of the palpebral portion of the orbicularis (muscle of reflection, left) and the combined activation of the frontalis superior portion of the orbicularis and platysma, giving a frightened expression (right) (4).

writings. In this context, Larner proposed that Charles Dickens captured the essential features of progressive supranuclear palsy in his description of a character in *The Lazy Tour of Two Idle Apprentices* (21). Dickens wrote:

A chilled, slow, earthy, fixed old man. A cadaverous man of measured speech. An old man who seemed as unable to wink, as if his eyelids had been nailed to his forehead. An old man whose eyes—two spots of fire—had no more motion than if they had been connected with the back of his skull by screws driven through it and riveted and bolted outside, among his grey hair. He had come in and shut the door, and he now sat down. He did not bend himself to sit, as other people do, but seemed to sink bold upright, as if in water until the chair stopped him (22).

For the medical reader with a knowledge of progressive supranuclear palsy, this description provides images compatible with the medical diagnosis. On the other hand, the passage falls short of the more convincing descriptions of sleep apnea in the *Pickwick Papers* or torticollis in *Little Dorrit*.

Corticobasal Degeneration

The clinical and pathological hallmarks of corticobasal degeneration were delineated in 1968 by Rebeiz (23). Asymmetric parkinsonism in the context of a progressive dyspraxia, unilateral dystonia, and cortical sensory impairment are the major clinical findings found in association with corticodentatonigral degeneration with neuronal achromasia. In addition to the Dutil report cited earlier (*see* Fig. 3), a thesis by Béchet (24), dated 1892, documents a patient (case VIII) with possible corticobasal degeneration. The patient's hallmarks were progressive tremor and contracture of the right upper extremity. Gradually, the trunk and neck developed extreme rigidity as well. The remarkable posture of the right upper extremity dominated the atypical picture:

The right upper extremity is held along side the body, extended and stiff, the elbow held straight, the wrist flexed, the hand pronated and held in front of the thigh. The hand is markedly contorted . . . the fingers completely flexed, especially the last three digits to the point that the finger nails sometimes leave impressions on the palm. The flexion of the index finger is less marked and the adducted thumb is held over the palmer surface of the middle finger. This contracture of the flexor muscles, however is only one of appearance, for the examiner can (with a some effort, admittedly) extend the hand and fingers completely, and afterwards, they can hold this position briefly (24).

Further discussing the functional impairment of the involved right upper extremity and the asymmetry of the case, he continued:

Spontaneous movements of the upper extremity are practically impossible, very limited and extremely slow. The upper left extremity is only mildly flexed and the hand has no notable deformity (24).

No photographs or medical drawings accompanied the report.

Nearly 30 yr later, in 1925, J. Lhermitte reported a case to the French Neurological Society that may also represent an early case of the same diagnosis (25,26). A carpenter retired at age 67 because of progressive right-hand clumsiness. At age 72, he could no longer walk independently and ambulated with a wide-based, shuffling gait with the right arm flexed. In addition, his right arm moved involuntarily "like a foreign body." In spite of normal primary sensation, he could not recognize objects placed in his right hand. The patient did not have an autopsy (Fig. 6).

With the advent of cognitive neurology as a subspecialization of neurology, historical research efforts related to corticobasal degeneration have focused on descriptions of cases with signs of cortical dysfunction rather than motor. The clinical disorder of the celebrated composer, Maurice Ravel, has been retrospectively diagnosed as corticobasal degeneration, focal dementia, and progressive aphasia without dementia (27,28). These analyses provide interesting reading, but, because the medical information is incomplete and no autopsy material has been identified, they do not substantially advance historical understanding of corticobasal degeneration.

Multiple System Atrophy

This diagnosis is particularly difficult to study historically, because the variety of symptoms and different phenotypes have been labeled with a wide vocabulary and nosology. In 1865, Sanders introduced the term "dystaxia or pseudo-paralysis agitans" to describe a patient with severe action tremor and gait impairment without sensory loss (29). Dejerine and Thomas described olivopontocerebellar atrophy in 1900 and emphasized varying mixtures of parkinsonian, cerebellar, and autonomic dysfunction (30). Critchley and Greenfield reviewed cases from the early 20th century, citing such names as Pierre Marie, Murri, Lhermitte, and Wilson, commenting on the changing terminology and nosographic confusion related to this disorder (31). In 1925, Ley reported the same type of presentation as Dejerine and Thomas in a 50-yr-old man, and at autopsy, he noted not only olivopontocerebellar lesions, but also atrophic substantia nigra (32,33).

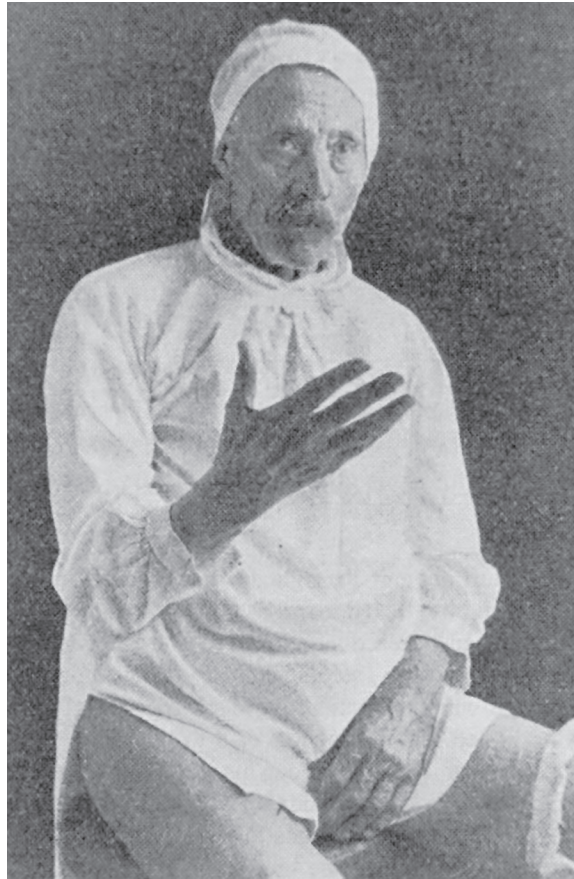


Fig. 6. Photograph from 1925 article by Lhermitte (25) and studied by Ballan and Tisson (26), showing a patient with possible corticobasal degeneration. The picture captures his unusual posturing of the right arm and hand with marked dyspraxia.

In 1960, Shy and Drager described two patients with orthostatic hypotension and parkinsonism or pyramidal/cerebellar features, who showed highly distinctive autopsy features including vacuolation of the autonomic ganglia, shrunken, hyperchromatic cells in the intermediolateral column, and degenerative changes in the pons, substantia nigra, hypothalamus, locus ceruleus, and Purkinje layer of the cerebellum (34). Striatonigral degeneration became widely known after Adams, van Bogaert, and van der Eecken published their series in 1961 (35). The conditions were consolidated in the seminal article by Graham and Oppenheimer (36).

Early reports of multiple system atrophy of the striatonigral phenotype were written by Lewy's student, Fleischhacker, in 1924 and Scherer in 1933, both analyzed by Wenning and colleagues (37–39). Of these five subjects, three had severe parkinsonism and two had more prominent cerebellar features. All had neuropathological evidence of putaminal and pallidal degeneration as well as depigmentation and degeneration of the small cells of the substantia nigra. Those with cerebellar features had additional olivopontocerebellar lesions. Fleischhacker's case had been clinically diagnosed during life as *paralysis agitans*, but the author argued that both clinically and pathologically, the findings were atypical for Parkinson's disease. Clinically, he emphasized the atypical tremor (coarse and

postural rather than resting), an early age of disease onset, and prominent rigidity. Berciano considers that Scherer's contribution was essential in establishing the striatal-nigral lesions that underlie parkinsonism in this phenotype. With his report, he definitively established that parkinsonism in olivopontocerebellar atrophies related to additional degenerative changes outside this system (33).

FUTURE PERSPECTIVES

The study of early texts that describe Parkinson's disease and other forms of parkinsonism remains vital as the search for causes of these illnesses intensifies. Epidemiological and neurotoxicological research that will be reviewed in this text has focused increasingly on the putative role of environmental factors to parkinsonian syndromes, and many current industrial exposures did not exist in prior eras. It may not be by chance that the first medical description of Parkinson's disease emerged from the center of international industrialization in the midst of the Industrial Revolution. The identification of atypical parkinsonian disorders naturally followed the identification of the archetype of Parkinson's disease, but establishing exactly when such cases came to medical attention has not been precisely defined. In this light, readers of early medicine, literature, and other disciplines offer an important resource for research efforts in the 21st century. As readers examine the evidence for genetic and environmental causes of the atypical parkinsonian disorders discussed in this book, a vigilance to literature, artworks, and early medical descriptions will complement these data and may further the understanding of these collective entities.

REFERENCES

1. Charcot J-M. (March 20, 1888) *Leçons du Mardi: Policlinique à la Salpêtrière*. Paris: Bureaux du Progrès Médical, 1887–1888.
2. Parkinson J. *The Shaking Palsy*. London: Whittingham & Rowland, 1817.
3. Charcot J-M. De la paralysie agitante, Leçon 5. In: *Oeuvres Complètes*, vol 1. Paris: Bureaux du Progrès Médical, 1892:155–189 [In English: On paralysis agitans. In: *Lectures on Diseases of the Nervous System*, Sierson, G, trans. Philadelphia:HC Lea, 1879:105–127.
4. Charcot J-M. (Leçon 21: June 12, 1888) *Leçons du Mardi: Policlinique à la Salpêtrière*. Paris:Bureaux du Progrès Médical, 1888.
5. Goetz CG, Bonduelle M, Gelfand T. *Charcot: Constructing Neurology*. New York: Oxford University Press, 1995.
6. Friedreich N. Neuropathologische Beobachtung beim Paramyoklonus mutiplex. *Virchow Arch Path Anat* 1881; 86:421–434.
7. Unverricht H. *Die Myoclonie*. Leipzig:Franz Deuticke, 1891.
8. Goetz CG. Visual art in the neurological career of Jean-Martin Charcot. *Arch Neurol* 1991;48:421–425.
9. Marie P. Hémiplégie chez les parkinsoniens. In: Brouardel P, Gilbert JP, eds. *Traité de Médecine et de Thérapeutique*. Masson, 1911.
10. *Transactions of the American Neurological Association*. St. Paul MN: American Neurological Association, 1963.
11. Steele J, Richardson JC, Olszewski J. Progressive supranuclear palsy. A heterogeneous degeneration involving the brain stem, basal ganglia and cerebellum with verticle gaze and pseudobulbar palsy, nuchal dystonia and dementia. *Arch Neurol* 1964;10:333–359.
12. Chavany JA, van Bogaert L, Godlewski S. Sur un syndrome de rigidité, à prédominance axiale avec perturbation des automatismes oculo-palpébraux d'origine encéphalopatique. *Presse Méd* 1951;50:958–962.
13. Brusa A. Dégénérescence plurisystématisée du névraxe, de caractère sporadique. *Rev Neurol* 1961;104:412–429
14. Steele JC. Historical notes. *J Neural Transm* 1994(Suppl);42:3–14.
15. Goetz CG. *Charcot, the Clinician: The Tuesday Lessons*. New York: Raven, 1987.
16. Jankovic J. Progressive supranuclear palsy. *Neurol Clin* 1984;2:473–486.
17. Dutil A. Sur un cas de paralysie agitante à forme hémiplégique avec attitude anormale de la tête et du tronc (extension). *Nouv Icon Salpêtrière* 1889;2:165–169.
18. Goetz CG. Visual art in the neurological career of Jean-Martin Charcot. *Arch Neurol* 1991;48:421–425.
19. Bourneville D-M. Deux cas de la maladie de Parkinson sans tremblement. *Prog Méd* Sept. 17, 1876, Paris.
20. Compin P. *Etude clinique des formes anormales de la maladie de Parkinson* (Thèse de Médecine). Lyon: FA Rey, 1902.
21. Larner AJ. Did Charles Dickens described progressive supranuclear palsy in 1857? *Mov Disorders* 2002;17:832–833.
22. Dickens C. The lazy tour of two idle apprentices. *Household Words* 1857;3:44–46, 4:66–72; 5:72–89.
23. Rebeiz JL, Kolodny EW, Richardson EP. Corticodentatonigral degeneration with neuronal achromasia. *Arch Neurol* 1968;18:20–33.

24. B  chet A. Etude clinique des formes de la maladie de Parkinson (Th  se de M  decine). Paris: Bureaux du Progr  s M  dical, 1892.
25. Lhermitte J, L  vy G, Kyriaco N. Les perturbations de la representation spatiale chez les apraxiques. *Rev Neurolog (Paris)* 1925;2:586–600.
26. Ballan G, Tison F. A historical case of probable corticobasal degeneration? *Mov Disord* 1997;12:1073–1074.
27. Baeck E. Was Maurice Ravel’s illness a corticobasal degeneration? *Clin Neurol and Neurosurg* 1996;98:57–61.
28. Cytowic RE. Aphasia in Maurice Ravel. *Bull Los Angeles Neurol Soc* 1976;41:109–114.
29. Sanders WR. Case of an unusual form of nervous disease, dystaxia or pseudo-paralysis agitans. *Edinburgh Med J* 1865;10:987–997.
30. Dejerine J, Thomas AA. L’atrophie olivo-ponto-c  r  belleuse. *Nouv Icon Salep  tr  re* 1900;13:330–370.
31. Critchley M, Greenfield JG. Olivo-ponto-cerebellar atrophy. *Brain* 1948;61:343–364.
32. Ley R. Forme atypique d’atrophie olivo-ponto-c  r  belleuse. *J Belge Neurol Psychiatr* 1925;25:92–108.
33. Berciano J, Combarros O, Polo JM. An early description of striatonigral degeneration. *J Neurol* 1999;246:462–466.
34. Shy SM, Drager GA. A neurological syndrome associated with orthostatic hypotension. *Arch Neurol* 1963;2:511–517.
35. Adams RD, van Bogaert L, Vander Eecken H. Striato-nigral degeneration. *J Neuropath Exper Neurol* 1964;23:584–608.
36. Graham JG, Oppenheimer DR. Orthostatic hypotension and nicotine sensitivity in a case of multiple system atrophy. *J Neurol Neurosurg Psychiatr* 1969;32:28–34.
37. Fleischhacker H. Afamili  re chronisch-progressive Erkrankung des mittleren Lebensalters vom Pseudosklerosetyp. *Z ges Neurol Psychiatr* 1924;91:1–22.
38. Scherer HJ. Extrapyramidale St  rungen bei der Olivopontocerebellarer Atrophie. Ein Beitrag zum Problem des lokalen vorzeitigen Alterns. *Zbl ges Neurol Psychiatr* 1933;145:406–419.
39. Wenning GK, Jellinger KJ, Quinn NP, Werner HP. An early report of striatonigral degeneration. *Mov Disord* 2000;15(1):159–162.

<http://www.springer.com/978-1-58829-331-2>

Atypical Parkinsonian Disorders

Clinical and Research Aspects

Litvan, I. (Ed.)

2005, XX, 512 p. With online files/update., Hardcover

ISBN: 978-1-58829-331-2

A product of Humana Press