
2 Positron Emission Tomography and Single-Photon Emission Tomography in the Diagnosis of Parkinson's Disease

Differential Diagnosis From Parkinson-Like Degenerative Diseases

PAUL D. ACTON, PhD

SUMMARY

Parkinsonian symptoms are associated with a number of neurodegenerative disorders, such as Parkinson's disease, multiple system atrophy, and progressive supranuclear palsy. Positron emission tomography (PET) and single-photon emission tomography (SPECT) now are able to visualize and quantify changes in cerebral blood flow, glucose metabolism, and neurotransmitter function produced by parkinsonian disorders. Both PET and SPECT have become important tools in the differential diagnosis of these diseases and may have sufficient sensitivity to detect neuronal changes before the onset of clinical symptoms. Imaging is now being used to elucidate the genetic contribution to Parkinson's disease and in longitudinal studies to assess the efficacy and mode of action of neuroprotective drug and surgical treatments.

Key Words: Imaging; Parkinson's disease; multiple system atrophy; progressive supranuclear palsy; essential tremor; differential diagnosis; positron emission tomography (PET); single-photon emission tomography (SPECT); dopamine transporter; dopamine receptor; cerebral blood flow; cerebral glucose metabolism.

1. INTRODUCTION

The differential diagnosis of the various parkinsonian disorders based on clinical symptoms alone is difficult (1–3). Clinical criteria for the diagnosis of Parkinson's disease (PD) provide high sensitivity for detecting parkinsonism but show poor specificity for identifying brainstem Lewy body disease or for differentiating atypical and typical PD (4). Tremor is a classic feature of PD, although this can also be found in patients with progressive supranuclear palsy (PSP) and multiple system atrophy (MSA). Similarly, a general criterion for diagnosing PD is a good, sustained response to levodopa (L-dopa) therapy, although, again, this also is found in some patients with MSA

and dopa-responsive dystonia. Indeed, some post mortem histopathological studies have shown that as many as 25% of all patients who were diagnosed with PD before death had been misdiagnosed (1,2). Detecting preclinical disease by using biochemical markers for neurodegeneration has not been successful. Familial PD sometimes exhibits a mutation of the α -synuclein gene, but this cannot be used as a genetic marker for the majority of cases because the pathogenesis is rarely related to genetic mutation. These observations have contributed to the motivation for developing objective neuroimaging techniques that can differentiate between these disorders.

Structural changes induced by parkinsonian diseases are generally small and often only evident when the disease is in an advanced stage. Consequently, the diagnostic accuracy of anatomical imaging modalities (e.g., magnetic resonance imaging [MRI]) in neurodegenerative disorders is poor (5). Preceding changes in brain morphology, alterations in the way the brain consumes glucose, or disruptions in regional cerebral blood flow (rCBF) may provide useful indicators of neurodegeneration. However, it is likely that changes in neurotransmitter function, most notably in the dopaminergic system, will become evident long before structural, metabolic, or blood flow variations.

In general, positron emission tomography (PET) and single-photon emission tomography (SPECT) imaging have provided a better platform for the diagnosis of parkinsonian disorders than MRI. Functional imaging of neurodegenerative disease with PET and SPECT has followed two main paths; studies of blood flow and cerebral metabolism to detect abnormal tissue functioning or imaging of the dopaminergic neurotransmitter system to study the loss of dopamine neurons.

2. IMAGING BLOOD FLOW AND METABOLISM

PET studies of cerebral glucose metabolism have used the glucose analog [^{18}F]fluorodeoxyglucose ([^{18}F]FDG), whereas radioactive water (H_2^{15}O), and the SPECT tracers $^{99\text{m}}\text{Tc}$ -hexamethylpropylene amine oxime ($^{99\text{m}}\text{Tc}$ -HMPAO) and $^{99\text{m}}\text{Tc}$ -ethylcysteinate dimer ($^{99\text{m}}\text{Tc}$ -ECD) are markers of cere-

bral blood flow and perfusion. Striatal glucose metabolism and perfusion are generally found to be normal in PD (6–10), although some studies have demonstrated an asymmetry of striatal metabolism (11). Interestingly, atypical parkinsonian disorder has been differentiated from idiopathic PD by the appearance of striatal metabolic abnormalities in the atypical group (12), which may provide a useful adjunct to routine clinical examination. Many studies have shown more global cortical hypometabolism or hypoperfusion or a loss of posterior parietal metabolism with a pattern similar to that observed in Alzheimer's, and other neurodegenerative diseases (8,9,13–18). Others have used the differences in regional metabolism or rCBF to discriminate between PD and MSA (10,19) or PSP (20). Studies of blood flow and glucose metabolism in patients with pure Lewy body disease with no features of Alzheimer's disease have consistently shown biparietal, bitemporal hypometabolism, a pattern that was once thought to represent the signature of Alzheimer's.

Imaging studies of glucose metabolism and CBF have shown important changes concomitant with degeneration in cognitive performance or autonomic failure (21–25). Although blood flow studies have shown a poor correlation with laterality in hemi-Parkinson's patients (26), there are clearly dramatic changes in CBF and glucose metabolism resulting from cognitive impairment (18,27–29). This is similar in detail to patients with other neurodegenerative disorders, such as Alzheimer's disease and dementia with Lewy bodies (30), but may be useful to distinguish vascular parkinsonism (31). Interestingly, patients with gait disorders generally exhibit an internal verbal cue to compensate for the loss of control in the motor cortex (32). Blood flow PET imaging also has been used to study the effects of novel therapies, such as Voice Treatment, on the reorganization of brain function to compensate for motor dysfunction (33). Studies of blood flow and metabolism have indicated conflicting results when the on- and off-dopamine replacement therapy conditions are compared. Both reduced (11,18,34) and normal (35,36) regional glucose metabolism and rCBF have been reported after L-dopa treatment.

Recent advances in image analysis, using the voxel-based statistical techniques, such as statistical parametric mapping (37,38), may provide greater accuracy in detecting focal changes in rCBF. These techniques compare changes in rCBF, voxel-by-voxel, or in glucose metabolism to identify regions of statistically significant differences. Although statistical parametric mapping has found important applications in studies of blood flow and metabolic changes in neurodegenerative disease (39,40), it is limited to the comparison of groups of subjects, rather than the diagnosis of individuals. Other statistical methodologies have been developed to attempt to automate the diagnosis of patients with PD and other parkinsonian disorders, based on scans of individual subjects (41,42).

3. IMAGING THE DOPAMINERGIC SYSTEM

In general, the diagnostic accuracy of CBF and glucose metabolism in differentiating neurodegenerative disorders is relatively poor in comparison with direct imaging of the dopaminergic nigrostriatal pathway (20). Early PET studies of the nigrostriatal pathway used the uptake of 6-[¹⁸F]fluoro-1-3,4-

dihydroxyphenylalanine ([¹⁸F]fluorodopa) as a measure of the integrity of dopamine neurons (43,44). [¹⁸F]fluorodopa measures changes in aromatic L-amino decarboxylase activity, which is dependent on the availability of striatal dopaminergic nerve terminals and is proportional to the number of dopamine neurons in the substantia nigra (45).

Quantitative parameters associated with [¹⁸F]fluorodopa uptake, such as the striatal-to-background uptake ratio, and the influx rate constant, have been shown to be useful indicators of dopaminergic degeneration in PD and other syndromes (46–67). Indeed, [¹⁸F]fluorodopa and PET are often regarded as the “gold standard” in the detection of dopamine neuronal loss (68), although the contributions from SPECT imaging, and other direct measures of the dopaminergic binding sites, both pre- and postsynaptic, are increasing (55,56,69–71). The analysis of [¹⁸F]fluorodopa PET studies is known to have a number of serious potential problems. [¹⁸F]fluorodopa is metabolized into a number of diffusible and nondiffusible labeled metabolites ([¹⁸F]3-*O*-methyl-fluorodopa (3OMFD) in peripheral and brain tissue, and [¹⁸F]dopamine (FDA), [¹⁸F]3-4-dihydroxyphenylacetic acid (FdopaC), and [¹⁸F]homovanillic acid in brain tissue). A further issue with the distribution of [¹⁸F]fluorodopa in PET scans is the kinetic rate constants tend to disagree with in vitro measurements by a large factor (up to 10 times lower) (72–76). Despite the fact that in vivo measurements of the decarboxylation rate, k_3 , gave values considerably lower than in vitro measurements, it has been concluded that k_3 accurately reflects striatal aromatic L-amino decarboxylase activity in vivo with [¹⁸F]fluorodopa PET (75,76). Other technical considerations, which are common to all PET and SPECT imaging techniques, include partial volume effects (62), which decrease the apparent striatal uptake of these tracers due to the limited resolution of the scanner.

Direct measurements of dopamine transporter binding sites are possible with [¹¹C]cocaine (77), or the cocaine analogs 2β-carbomethoxy-3β-[4-iodophenyl] tropane (β-CIT) and *N*-ω-fluoropropyl-2β-carbomethoxy-3β-[4-iodophenyl] tropane (FP-CIT), labeled with either ¹⁸F or ¹¹C for PET or ¹²³I for SPECT (78–80). Other dopamine transporter ligands include *N*-[3-iodopropen-2-yl]-2β-carbomethoxy-3β-[4-chlorophenyl] tropane ([¹²³I]IPT) (81), its 4-fluorophenyl analog [¹²³I]altropane (82), 2β-carbomethoxy-3β-[4-fluorophenyl] tropane ([¹¹C]CFT) (83), and [¹¹C]d-threo-methylphenidate (84). Of particular importance is the recent development of the first successful ^{99m}Tc-labeled dopamine transporter ligand, ^{99m}Tc-Technetium[2-[[[3-(4-chlorophenyl)-8-methyl-8-azabicyclo[3.2.1]oct-2-yl]-methyl](2-mercaptoethyl) amino]-ethyl] amino] ethane-thiolato-*N*2,*N*2',*S*2,*S*2'] oxo-[1*R*-(exo-exo)] (^{99m}Tc-TRODAT-1) (85, 86). Because ^{99m}Tc is so much more widely available and less expensive than ¹²³I, this new tracer could move imaging of the dopaminergic system from a research environment into routine clinical practice, particularly with simplified imaging protocols (87).

Several tracers exist for imaging postsynaptic dopamine D2 receptors, using radioactively labeled dopamine receptor antagonists. The most widely used for SPECT include *S*-(−)-3-iodo-2-hydroxy-6-methoxy-*N*-[(1-ethyl-2-pyrrolidiny) methyl] benzamide ([¹²³I]IBZM) (88–90), *S*-5-iodo-7-*N*-[(1-ethyl-2-

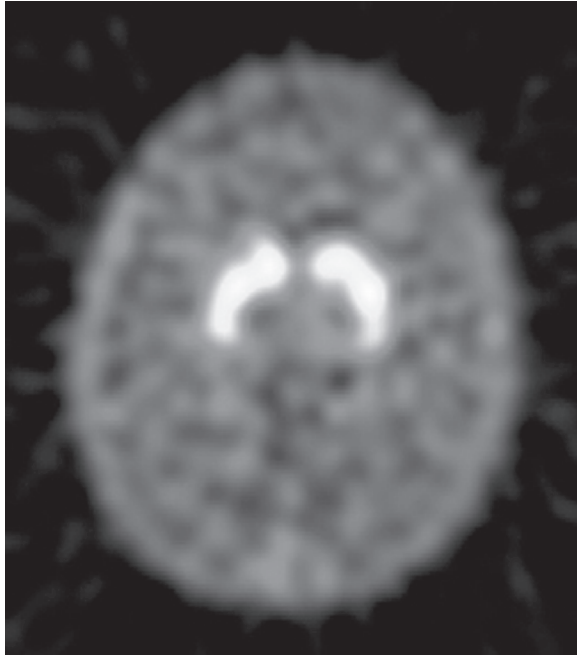


Fig. 1. Transaxial slice at the level of the striatum showing uptake of ^{99m}Tc -TRODAT-1 in dopamine transporters in a normal healthy volunteer. Good uptake is seen in the caudate nucleus and putamen, with background activity throughout the rest of the brain. Image courtesy of Dr. Andrew Newberg, University of Pennsylvania. See color version on Companion CD.

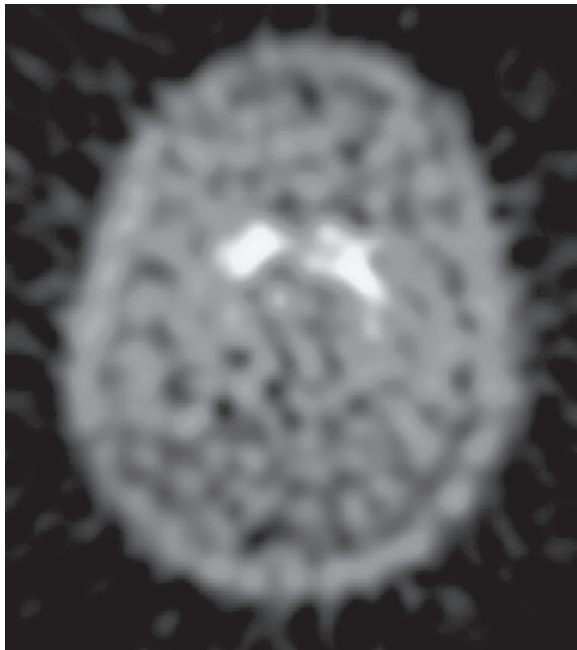


Fig. 2. Uptake of ^{99m}Tc -TRODAT-1 in the striatum of a patient with mild Parkinson's disease shows bilateral decrease in tracer concentration, particularly in the putamen, indicating a loss of dopaminergic neurons in these brain regions. Image courtesy of Dr. Andrew Newberg, University of Pennsylvania. See color version on Companion CD.

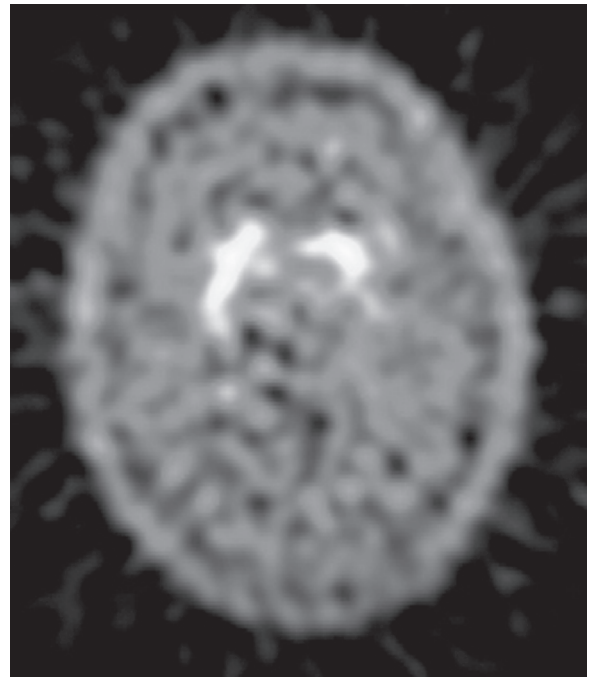


Fig. 3. A patient with hemi-PD exhibits a unilateral decrease in the uptake of ^{99m}Tc -TRODAT-1 in the side contralateral to clinical symptoms, most severely in the putamen. Although the clinical symptoms are confined to one side of the body, there also is reduced tracer uptake in the ipsilateral side, indicating a preclinical reduction in dopaminergic neurons, and demonstrating the sensitivity of imaging techniques for measuring dopaminergic dysfunction before clinical symptoms become apparent. Image courtesy of Dr. Andrew Newberg, University of Pennsylvania. See color version on Companion CD.

iodo-2,3-dimethoxybenzamide ($[^{123}\text{I}]$ epidepride) (93,94) and for PET include *S*-(-)-3,5-dichloro-*N*-[(1-ethyl-2-pyrrolidinyl)] methyl-2-hydroxy-6-methoxybenzamide ($[^{11}\text{C}]$ raclopride) (95) and $[^{11}\text{C}]$ or $[^{18}\text{F}]$ *N*-methylspiroperidol (96,97).

PET and SPECT studies of radiotracer binding to postsynaptic dopamine receptors and presynaptic dopamine transporters have proved to be powerful techniques for quantifying the loss of dopaminergic neurons in normal aging (98–107), PD (67,108–162) and other neurodegenerative disorders (48, 143,163–184). Studies of neuronal degeneration associated with the effects of normal aging have indicated that, whereas dopamine transporter concentrations decrease as a natural consequence of aging, the changes are small compared with the effects of disease (106) (Fig. 1). PET and SPECT studies have indicated a consistent pattern of dopaminergic neuronal loss in PD, usually with more pronounced depletion in the putamen rather than in the caudate (Fig. 2). In addition, there is frequently a marked asymmetry, particularly in the early stages of the disease (Fig. 3), and a good correlation with symptom severity (114,161) and illness duration (152). Most importantly, imaging studies may be sensitive enough to detect very early PD (4,61,115,123,130,141,185–189), perhaps even before clinical symptoms become apparent.

Characteristically, PD begins with unilateral symptoms of motor deficit, which gradually progress bilaterally over time. Studies of patients with early hemi-PD have shown that, despite the subject exhibiting only one-sided clinical symptoms, the

pyrrolidinyl) methyl] carboxamido-2,3-dihydrobenzofuran ($[^{123}\text{I}]$ IBF) (91,92), *S*-*N*-[(1-ethyl-2-pyrrolidinyl) methyl]-5-

PET and SPECT findings demonstrated bilateral decreases in tracer binding, with a greater reduction in the side contralateral to the clinical signs (41,115,123,190,191). The ability of PET and SPECT to detect presymptomatic PD may have important consequences for the screening of familial PD (187,188,192). PET and SPECT studies of parkinsonian kindreds have implicated a genetic foundation for familial PD, including mutations in the *parkin* gene. Hereditary parkinsonism has been detected in asymptomatic relatives with heterozygous *parkin* mutations, using imaging to determine the extent of neuronal damage (187,193–196). Indeed, PET and SPECT imaging of the dopaminergic system is able to demonstrate presynaptic dysfunction in asymptomatic relatives, which is fully compatible with early parkinsonism (187). Even subjects with apparently normal alleles exhibited reduced dopaminergic function on imaging, indicating a preclinical disease in these subjects that is likely to progress to full PD (187). The same features were observed in asymptomatic twins, both monozygotic and dizygotic, of a sibling with parkinsonism (188).

Although most of the PET and SPECT imaging studies have shown highly significant differences between groups of Parkinson's patients and age-matched normal controls, the statistically significant differential diagnosis of an individual subject is more problematic. Patients with severe PD are easily separated from healthy controls even by simple visual inspection of striatal images, quantified using some form of discriminant analysis (122,126,150,152,164,186,197) possessing a sensitivity and specificity close to 100% in the proper clinical setting. The differentiation between PD and vascular parkinsonism (173,182) and between PD and drug-induced parkinsonism (133) also appears possible using imaging of the dopaminergic system. However, patients presenting much earlier in the course of the disease are more difficult to detect, with potentially significant overlap with an age-matched control group (185,198) and consequential loss of diagnostic accuracy. The situation may be further complicated if the early differential diagnosis between several neurodegenerative disorders is required. Many of the symptoms associated with parkinsonian disorders are nonspecific, which is why the accurate clinical diagnosis of these diseases is difficult. Studies have shown little difference between radiotracer binding to dopamine transporters in patients with PD, MSA, or PSP (164,166) (Fig. 4). Based on current methods of analysis, it appears that the detection of early PD, or the differential diagnosis between various neurodegenerative disorders, may not be possible in individual cases based on imaging of a single neurotransmitter system alone (121). Interestingly, progress on the differential diagnosis of PD and other parkinsonian disorders may come from PET and SPECT imaging outside the brain. Recent studies of the functional integrity of postganglionic cardiac sympathetic neurons, using [^{123}I]MIBG or [^{11}C]HED, have indicated a distinct difference between cardiac autonomic dysfunction in patients with PD and those with MSA (199,200).

4. MULTIMODALITY AND MULTITRACER STUDIES

The relative merits of anatomical and functional imaging have been combined in some studies utilizing either several different radiotracers or data from both MRI/PET or SPECT. Regional

glucose metabolism has been studied in parkinsonian disorders with [^{18}F]FDG and PET, and the data combined with striatal [^{18}F]fluorodopa uptake measurements to give an improved diagnostic indicator, and a better understanding of the underlying disease processes (19,51,59,201). However, it should be noted that the improvement was relatively small over the good predictive capabilities of [^{18}F]fluorodopa by itself in these patient groups. Some studies have used the complementary information coming from structural MRI and functional [^{18}F]FDG PET in distinguishing between control subjects and patients with MSA (53,202–205), in whom both focal MRI hypointensities, changes in striatal and midbrain size, and reduced glucose metabolism occurred on the side contralateral to clinical symptoms. Magnetic resonance spectroscopy adds an important new probe to complement functional PET and SPECT imaging studies (204). Other studies have combined data from MRI and postsynaptic dopamine receptor concentrations using [^{123}I]IBZM and SPECT, giving useful information on the involvement of multiple brain regions in PSP (206) and MSA (207).

However, the greatest discrimination between various neurodegenerative disorders may be found using PET or SPECT imaging of both pre- and postsynaptic dopaminergic function (116,121,208). A study of [^{123}I]β-CIT and [^{123}I]IBZM binding in patients with early PD showed marked unilateral reductions in dopamine transporters measured by [^{123}I]β-CIT concomitant with elevated dopamine D2 receptor binding of [^{123}I]IBZM (209). Recent SPECT studies investigating pre- and postsynaptic dopamine binding sites in the differential diagnosis of PD, MSA, and PSP have shown promising results, with a reduction in dopamine transporter availability in all diseases, and some discrimination between disorders in the pattern of dopamine D2 receptor concentrations (142,210,211) (Fig. 5). Similar results were observed in PET studies of early Parkinson's patients, where striatal [^{18}F]fluorodopa uptake was reduced and [^{11}C]raclopride binding was upregulated, with the degree of increase in dopamine receptor binding inversely proportional to disease severity (47,53). These studies also used [^{18}F]FDG imaging of the same patients to determine the optimum combination of neuroreceptor function and glucose metabolism to differentiate between healthy controls and patients with PD (47) or MSA (48,53). The results suggest that striatal [^{18}F]FDG and particularly [^{11}C]raclopride are sensitive to striatal function and may help with the characterization of patients with MSA, whereas [^{18}F]fluorodopa can accurately detect nigrostriatal dopaminergic abnormalities consistent with parkinsonian disorders. Other parkinsonian syndromes, such as Wilson disease, a disorder related to copper deposition, have been studied using imaging and demonstrate a significant decline in dopaminergic function, both pre- and postsynaptic, that can be differentiated from idiopathic PD (170).

SPECT imaging of both pre- and postsynaptic dopamine binding sites simultaneously has now been performed in nonhuman primates, using $^{99\text{m}}\text{Tc}$ -TRODAT-1 and [^{123}I]IBZM or [^{123}I]IBF, separating the two radiotracers based on their different energy spectra (212,213). The possibility of simultaneously imaging both dopamine transporters and D2 receptors in neurodegenerative disorders is an exciting prospect, providing a unique probe in the investigation and diagnosis of these diseases.

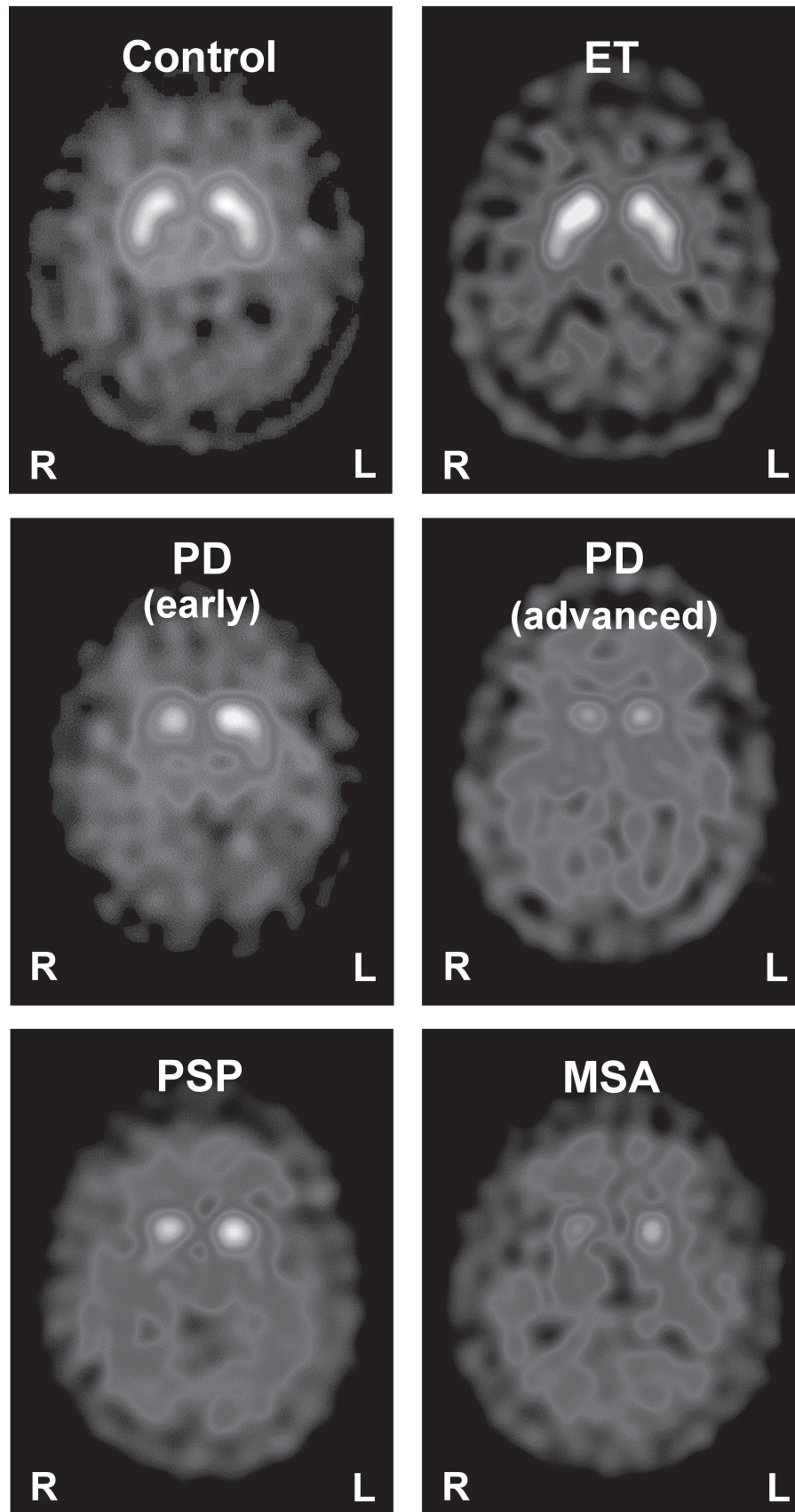


Fig. 4. Presynaptic dopamine transporter imaging with SPECT and $[^{123}\text{I}]\text{FP-CIT}$, used to distinguish between disease with and without nigrostriatal deficit. Whereas neurodegenerative parkinsonian syndromes such as PD, MSA, and PSP present with compromised dopamine terminal function, illnesses without involvement of those terminals (e.g., essential tremor [ET]) present with normal findings. Images courtesy of Prof. Klaus Tatsch, University of Munich. See color version on Companion CD.

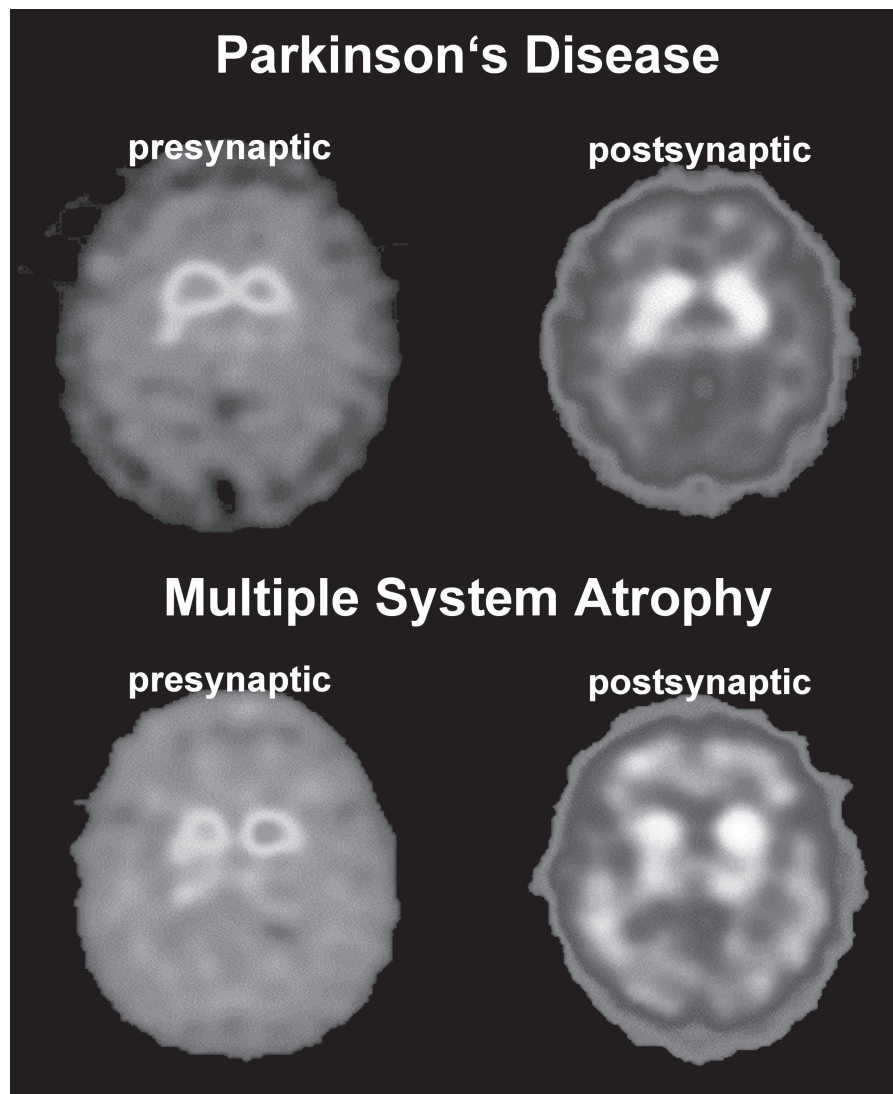


Fig. 5. Postsynaptic dopamine D2 receptor imaging with [^{123}I]IBZM SPECT used to distinguish between PD and atypical parkinsonian syndromes. PD patients present with normal or increased D2 receptor binding suggesting preserved or upregulated postsynaptic receptors, whereas in atypical parkinsonian syndromes (e.g., MSA) D2 receptor binding is reduced, reflecting degeneration of postsynaptic receptor binding sites. Presynaptic terminal function, measured with [^{123}I]FP-CIT SPECT, is compromised in both PD and atypical parkinsonian syndromes. Images courtesy of Prof. Klaus Tatsch, University of Munich. See color version on Companion CD.

5. IMAGING OTHER NEUROTRANSMITTER SYSTEMS

Although most imaging studies have investigated the effects of parkinsonian disorders on the dopaminergic system, neuropathologic and biochemical studies suggest that serotonin neurons also are affected by the disease process (214). The integrity of serotonin neurons in the midbrain region can be studied using the SPECT tracer [^{123}I]β-CIT (215,216). Although this radioligand is more commonly associated with measurements of the dopamine transporter, it also binds with high affinity to the serotonin transporter. However, owing to the high concentration of dopamine transporters in the striatum, imaging of the serotonergic system with this tracer is limited to the midbrain (217). Despite these technical difficulties, studies suggest that

dopamine and serotonin transporters are differentially affected in PD, and serotonin transporters in the midbrain region may not be affected in relatively early stages of PD (218,219). In later stages of the disease, serotonin transporters are reduced in thalamic and frontal areas of the brain and correlate with scores of disease severity (139). Indeed, others have demonstrated that dysfunction in the serotonin system is closely related to the neuropsychiatric symptoms of PD, whereas the dopaminergic system correlates more with motor deficits (220). This is not unexpected, because the serotonin transporter is a well-known target for antidepressant drugs (221). However, the role of imaging the serotonin system in the differential diagnosis of parkinsonian disorders is still unclear and may obtain a more prominent position using the more selective serotonin transporter PET and SPECT ligands that have been developed recently (222–230).

6. CONCLUSION

There are a large number of imaging techniques that can be used to attempt to differentiate between the various neurodegenerative disorders. Taken in isolation, many of them can diagnose parkinsonian disorders with some success. However, the diagnosis at an early stage in the progression of each disease, possibly even before clinical symptoms have become apparent, is much more difficult and may require multiple imaging modalities or combinations of tracers. The widespread availability of SPECT imaging, perhaps combined with newer and less expensive tracers, may lead to the routine implementation of SPECT scanning in the diagnosis of parkinsonian disorders.

ACKNOWLEDGMENTS

The author is indebted to Dr. Andrew Newberg, University of Pennsylvania, and Prof. Klaus Tatsch, University of Munich, for providing the images to accompany this chapter. This work was supported in part by grants from the National Institutes of Health (R01-EB002774 and R01-AG017524).

REFERENCES

1. Raiput AH, Rozdilsky B, Raiput A. Accuracy of clinical diagnosis in parkinsonism—a prospective study. *Can J Neurol Sci* 1991;12:219–228.
2. Hughes AJ, Daniel SE, Blankson S, Lees AJ. A clinicopathologic study of 100 cases of Parkinson's disease. *Arch Neurol* 1993;50:140–148.
3. Testa D, Filippini G, Farinotti M, Palazzini E, Caraceni T. Survival in multiple system atrophy: a study of prognostic factors in 59 cases. *J Neurol* 1996;243:401–404.
4. Brooks DJ. The early diagnosis of Parkinson's disease. *Ann Neurol* 1998;44:S10–S18.
5. Schrag A, Kingsley D, Phatouros C, et al. Clinical usefulness of magnetic resonance imaging in multiple system atrophy. *J Neurol Neurosurg Psychiatry* 1998;65:65–71.
6. Kuhl DE, Metter EJ, Riege WH, Markham CH. Patterns of cerebral glucose utilisation in Parkinson's disease and Huntington's disease. *Ann Neurol* 1984;15:119–125.
7. Smith FW, Gemmell HG, Sharp PF, Besson JA. Technetium-99m HMPAO imaging in patients with basal ganglia disease. *Br J Radiol* 1988;61:914–920.
8. Wang SJ, Liu RS, Liu HC, et al. Technetium-99m hexamethylpropylene amine oxime single photon emission tomography of the brain in early Parkinson's disease: correlation with dementia and lateralization. *Eur J Nucl Med* 1993;20:339–344.
9. Markus HS, Lees AJ, Lennox G, Marsden CD, Costa DC. Patterns of regional cerebral blood flow in corticobasal degeneration studied using HMPAO SPECT; comparison with Parkinson's disease and normal controls. *Mov Disord* 1995;10:179–187.
10. Otsuka M, Ichiya Y, Kuwabara Y, et al. Glucose metabolism in the cortical and subcortical brain structures in multiple system atrophy and Parkinson's disease: a positron emission tomography study. *J Neurol Sci* 1996;144:77–83.
11. Dethy S, Van Blercom N, Damhaut P, Wikler D, Hilderbrand J, Goldman S. Asymmetry of basal ganglia glucose metabolism and dopa responsiveness in parkinsonism. *Mov Disord* 1998;13:275–280.
12. Antonini A, Kazumata K, Feigin A, et al. Differential diagnosis of parkinsonism with [^{18}F]fluorodeoxyglucose and PET. *Mov Disord* 1998;13:268–274.
13. Pizzolato G, Dam M, Borsato N, et al. [$^{99\text{m}}\text{Tc}$]-HM-PAO SPECT in Parkinson's disease. *J Cerebral Blood Flow Metab* 1988;8:S101–S108.
14. Liu RS, Lin KN, Wang SJ, et al. Cognition and 99mTc-HMPAO SPECT in Parkinson's disease. *Nucl Med Commun* 1992;13:744–748.
15. Eberling JL, Richardson BC, Reed BR, Wolfe N, Jagust WJ. Cortical glucose metabolism in Parkinson's disease without dementia. *Neurobiol Aging* 1994;15:329–335.
16. Eidelberg D, Moeller JR, Ishikawa T, et al. Early differential diagnosis of Parkinson's disease with [^{18}F]-fluorodeoxyglucose and positron emission tomography. *Neurology* 1995;45:1995–2004.
17. Pierr M, Koeppe RA, Giordani B, Minoshima S, Kuhl DE. Determination of regional rate constants from dynamic FDG-PET studies in Parkinson's disease. *J Nucl Med* 1996;37:1115–1122.
18. Berding G, Odin P, Brooks DJ, et al. Resting regional cerebral glucose metabolism in advanced Parkinson's disease studied in the off and on conditions with [(18)F]FDG-PET. *Movement Disorders* 2001;16:1014–1022.
19. Otsuka M, Kuwabara Y, Ichiya Y, et al. Differentiating between multiple system atrophy and Parkinson's disease by positron emission tomography with 18F-dopa and 18F-FDG. *Ann Nucl Med* 1997;11:251–257.
20. Defebvre L, Lecoiffe P, Destee A, Houdart P, Steinling M. Tomographic measurements of regional cerebral blood flow in progressive supranuclear palsy and Parkinson's disease. *Acta Neurol Scand* 1995;92:235–241.
21. Jagust WJ, Reed BR, Martin EM, Eberling JL, Nelson-Abbott RA. Cognitive function and regional cerebral blood flow in Parkinson's disease. *Brain* 1992;115:521–537.
22. Samuel M, Ceballos-Baumann AO, Boecker H, Brooks DJ. Motor imagery in normal subjects and Parkinson's disease patients: an H215O PET study. *Neuroreport* 2001;12:821–828.
23. Sawada H, Uda F, Kameyama M, et al. SPECT findings in Parkinson's disease associated with dementia. *J Neurol Neurosurg Psychiatry* 1992;55:960–963.
24. Wu JC, Iacono R, Ayman M, et al. Correlation of intellectual impairment in Parkinson's disease with FDG PET scan. *Neuroreport* 2000;11:2139–2144.
25. Antonini A, De Notaris R, Benti R, De Gaspari D, Pezzoli G. Perfusion ECD/SPECT in the characterization of cognitive deficits in Parkinson's disease. *Neurol Sci* 2001;22:45–46.
26. Agniet A, Celsis P, Viallard G, et al. Cognition and cerebral blood flow in lateralised parkinsonism: lack of functional lateral asymmetries. *J Neurol Neurosurg Psychiatry* 1991;54:783–786.
27. Arahata Y, Hirayama M, Ieda T, et al. Parieto-occipital glucose hypometabolism in Parkinson's disease with autonomic failure. *J Neurol Sci* 1999;163:119–126.
28. Bissessur S, Tissingh G, Wolters EC, Scheltens P. rCBF SPECT in Parkinson's disease patients with mental dysfunction. *J Neural Transmission Suppl* 1997;50:25–30.
29. Ceballos-Baumann AO. Functional imaging in Parkinson's disease: activation studies with PET, fMRI and SPECT. *J Neurol* 2003;250 Suppl 1:15–23.
30. Costa DC, Ell PJ, Burns A, Philpot M, Levy R. CBF tomograms with [$^{99\text{m}}\text{Tc}$]-HM-PAO in patients with dementia (Alzheimer type and HIV) and Parkinson's disease—initial results. *J Cerebral Blood Flow Metab* 1988;8:S109–S115.
31. De Reuck J, Siau B, Decoo D, et al. Parkinsonism in patients with vascular dementia: clinical, computed- and positron emission-tomographic findings. *Cerebrovasc Dis* 2001;11:51–58.
32. Albani G, Kunig G, Soelch CM, et al. The role of language areas in motor control dysfunction in Parkinson's disease. *Neurol Sci* 2001;22:43–44.
33. Liotti M, Ramig LO, Vogel D, et al. Hypophonia in Parkinson's disease: neural correlates of voice treatment revealed by PET. *Neurology* 2003;60:432–440.
34. Feigin A, Fukuda M, Dhawan V, et al. Metabolic correlates of levodopa response in Parkinson's disease. *Neurology* 2001;57:2083–2088.
35. Rougemont D, Baron JC, Collard P, Bustany P, Comar D, Agid Y. Local cerebral glucose utilisation in treated and untreated patients with Parkinson's disease. *J Neurol Neurosurg Psychiatry* 1984;47:824–830.
36. Markus HS, Costa DC, Lees AJ. HMPAO SPECT in Parkinson's disease before and after levodopa: correlation with dopaminergic

- gic responsiveness. *J Neurol Neurosurg Psychiatry* 1994;57:180–185.
37. Friston KJ, Holmes AP, Worsley KJ, Poline JP, Frith CD, Frackowiak RSJ. Statistical parametric maps in functional imaging: a general linear approach. *Hum Brain Map* 1995;2:189–210.
 38. Acton PD, Friston KJ. Statistical parametric mapping in functional neuroimaging: beyond PET and fMRI activation studies. *Eur J Nucl Med* 1998;25:663–667.
 39. Imon Y, Matsuda H, Ogawa M, Kogure D, Sunohara N. SPECT image analysis using statistical parametric mapping in patients with Parkinson's disease. *J Nuclear Med* 1999;40:1583–1589.
 40. Lozza C, Marie RM, Baron JC. The metabolic substrates of bradykinesia and tremor in uncomplicated Parkinson's disease. *Neuroimage* 2002;17:688–699.
 41. Acton PD, Mozley PD, Kung HF. Logistic discriminant parametric mapping: a novel method for the pixel-based differential diagnosis of Parkinson's disease. *Eur J Nucl Med* 1999;26:1413–1423.
 42. Slomka PJ, Radau PE, Hurwitz GA, Dey D. Automated three-dimensional quantification of myocardial perfusion and brain SPECT. *Comput Med Imaging Graph* 2001;25:153–164.
 43. Garnett ES, Firnau G, Chan PKH, Sood S, Belbeck LW. [18F]-Fluoro-dopa, an analogue of dopa, and its use in direct external measurements of storage, degradation, and turnover of intracerebral dopamine. *Proc Natl Acad Sci USA* 1978;75:464.
 44. Garnett ES, Firnau G, Nahmias C. Dopamine visualised in the basal ganglia of living man. *Nature* 1983;305:137.
 45. Snow BJ, Tooyama I, McGeer EG. Human positron emission tomographic (fluorine-18) fluorodopa studies correlate with dopamine cell counts and levels. *Ann Neurol* 1993;34:324–330.
 46. Dhawan V, Ma Y, Pillai V, et al. Comparative analysis of striatal FDOPA uptake in Parkinson's disease: ratio method versus graphical approach. *J Nucl Med* 2002;43:1324–1330.
 47. Antonini A, Vontobel P, Psylla M, et al. Complementary positron emission tomographic studies of the striatal dopaminergic system in Parkinson's disease. *Arch Neurol* 1995;52:1183–1190.
 48. Antonini A, Leenders KL, Vontobel P, Maguire RP, Missimer J, Psylla M, Gunther I. Complementary PET studies of striatal neuronal function in the differential diagnosis between multiple system atrophy and Parkinson's disease. *Brain* 1997;120:2187–2195.
 49. Dhawan V, Ishikawa T, Patlak C, et al. Combined FDOPA and 3OMFD PET studies in Parkinson's disease. *J Nucl Med* 1996;37:209–216.
 50. Doudet DJ, Chan GL, Holden JE, et al. 6-(18F)Fluoro-L-DOPA PET studies of the turnover of dopamine in MPTP-induced parkinsonism in monkeys. *Synapse* 1998;29:225–232.
 51. Eidelberg D, Moeller JR, Dhawan V, et al. The metabolic anatomy of Parkinson's disease: complementary (18F)fluorodeoxyglucose and (18F)fluorodopa positron emission tomographic studies. *Mov Disord* 1990;5:203–213.
 52. Ghaemi M, Rudolf J, Hilker R, Herholz K, Heiss WD. Increased pineal Fdopa uptake is related to severity of Parkinson's disease—a PET study. *J Pineal Res* 2001;30:213–219.
 53. Ghaemi M, Hilker R, Rudolf J, Sobesky J, Heiss WD. Differentiating multiple system atrophy from Parkinson's disease: contribution of striatal and midbrain MRI volumetry and multi-tracer PET imaging. *J Neurol Neurosurg Psychiatry* 2002;73:517–523.
 54. Hoshi H, Kuwabara H, Leger G, Cumming P, Guttman M, Gjedde A. 6-(18F)fluoro-L-dopa metabolism in living human brain: a comparison of six analytical methods. *J Cerebral Blood Flow Metab* 1993;13:57–69.
 55. Huang WS, Chiang YH, Lin JC, Chou YH, Cheng CY, Liu RS. Crossover study of (99m)Tc-TRODAT-1 SPECT and (18F)-FDOPA PET in Parkinson's disease patients. *J Nucl Med* 2003;44:999–1005.
 56. Huang WS, Ma KH, Chou YH, Chen CY, Liu RS, Liu JC. 99mTc-TRODAT-1 SPECT in healthy and 6-OHDA lesioned parkinsonian monkeys: comparison with 18F-FDOPA PET. *Nucl Med Commun* 2003;24:77–83.
 57. Kawatsu S, Kato T, Nagano-Saito A, Hatano K, Ito K, Ishigaki T. New insight into the analysis of 6-(18F)fluoro-L-DOPA PET dynamic data in brain tissue without an irreversible compartment: comparative study of the Patlak and Logan analyses. *Radiat Med* 2003;21:47–54.
 58. Kuwabara H, Cumming P, Yasuhara Y, et al. Regional striatal DOPA transport and decarboxylase activity in Parkinson's disease. *J Nucl Med* 1995;36:1226–1231.
 59. Laureys S, Salmon E, Garraux G, et al. Fluorodopa uptake and glucose metabolism in early stages of corticobasal degeneration. *J Neurol* 1999;246:1151–1158.
 60. Melega WP, Raleigh MJ, Stout DB, et al. Longitudinal behavioral and 6-(18F)fluoro-L-DOPA-PET assessment in MPTP-hemiparkinsonian monkeys. *Exp Neurol* 1996;141:318–329.
 61. Nurmi E, Ruottinen HM, Bergman J, et al. Rate of progression in Parkinson's disease: a 6-[18F]fluoro-L-dopa PET study. *Mov Disord* 2001;16:608–615.
 62. Rousset OG, Deep P, Kuwabara H, Evans AC, Gjedde AH, Cumming P. Effect of partial volume correction on estimates of the influx and cerebral metabolism of 6-[(18F)]fluoro-L-dopa studied with PET in normal control and Parkinson's disease subjects. *Synapse* 2000;37:81–89.
 63. Ruottinen HM, Partinen M, Hublin C, et al. An FDOPA PET study in patients with periodic limb movement disorder and restless legs syndrome. *Neurology* 2000;54:502–504.
 64. Takikawa S, Dhawan V, Chaly T, et al. Input functions for 6-(fluorine-18)fluorodopa quantitation in parkinsonism: comparative studies and clinical correlations. *J Nucl Med* 1994;35:955–963.
 65. Broussolle E, Dentesangle C, Landais P, et al. The relation of putamen and caudate nucleus 18F-Dopa uptake to motor and cognitive performances in Parkinson's disease. *J Neurol Sci* 1999;166:141–151.
 66. de la Fuente-Fernandez R, Pal PK, Vingerhoets FJ, et al. Evidence for impaired presynaptic dopamine function in parkinsonian patients with motor fluctuations. *J Neural Transmission* 2000;107:49–57.
 67. De La Fuente-Fernandez R, Lim AS, Sossi V, et al. Age and severity of nigrostriatal damage at onset of Parkinson's disease. *Synapse* 2003;47:152–158.
 68. Frey KA. Can SPET imaging of dopamine uptake sites replace PET imaging in Parkinson's disease? *Eur J Nucl Med Mol Imaging* 2002;29:715–717.
 69. Tatsch K. Can SPET imaging of dopamine uptake sites replace PET imaging in Parkinson's disease? *For. Eur J Nucl Med Mol Imaging* 2002;29:711–714.
 70. Brucke T, Djamshidian S, Bencsits G, Pirker W, Asenbaum S, Podreka I. SPECT and PET imaging of the dopaminergic system in Parkinson's disease. *J Neurol* 2000;247(Suppl 4):2–7.
 71. Fernandez HH, Friedman JH, Fischman AJ, Noto RB, Lannon MC. Is altopane SPECT more sensitive to fluoroDOPA PET for detecting early Parkinson's disease? *Medical Sci Monitor* 2001;7:1339–1343.
 72. Cumming P, Boyes BE, Martin WRW, et al. The metabolism of (18F)6-fluoro-L-3,4-dihydroxyphenylalanine in the hooded rat. *J Neurochem* 1987;48:601.
 73. Cumming P, Hausser M, Martin WR, Grierson J, Adam MJ, Ruth TJ. Kinetics of in vitro decarboxylation and the in vivo metabolism of 2-18F- and 6-18F-fluorodopa in the hooded rat. *Biochem Pharmacol* 1988;37:247–250.
 74. Cumming P, Brown E, Damsma G, Fibiger HC. Formation and clearance of interstitial metabolites of dopamine and serotonin in rat striatum: an in vivo microdialysis study. *J Neurochem* 1992;59:1905–1914.
 75. Cumming P, Kuwabara H, Gjedde AH. A kinetic analysis of 6-[18F]fluoro-L-dihydroxyphenylalanine metabolism in the rat. *J Neurochem* 1994;63:1675–1682.
 76. Yee RE, Huang SC, Stout DB, et al. Nigrostriatal reduction of aromatic L-amino acid decarboxylase activity in MPTP-treated squirrel monkeys: in vivo and in vitro investigations. *J Neurochem* 2000;74:1147–1157.
 77. Fowler JS, Volkow ND, Wolf AP, et al. Mapping cocaine binding sites in human and baboon brain in vivo. *Synapse* 1989;4:371–377.

78. Bergstrom KA, Kuikka JT, Ahonen A, Vanninen E. [123I] β -CIT, a tracer for dopamine and serotonin re-uptake sites: preparation and preliminary SPECT studies in humans. *J Nucl Biol Med* 1994;38:128–131.
79. Madras BK, Spealman RD, Fahey MA, Neumeyer JL, Saha JK, Milius RA. Cocaine receptors labeled by [3H]2b-carbomethoxy-3b-(4-fluorophenyl)tropane. *Mol Pharmacol* 1989;36:518–524.
80. Neumeyer JL, Wang S-Y, Milius RA, et al. [123I]-2b-Carbomethoxy-3b-(4-iodophenyl)tropane: high-affinity SPECT radiotracer of monoamine reuptake sites in brain [letter]. *J Med Chem* 1991;34:3144–3146.
81. Kung M-P, Essman WD, Frederick D, et al. IPT: a novel iodinated ligand for the CNS dopamine transporter. *Synapse* 1995;20:316–324.
82. Madras BK, Meltzer PC, Liang AY, Elmaleh DR, Babich J, Fischman AJ. Altopane, a SPECT or PET imaging probe for dopamine neurons: I. Dopamine transporter binding in primate brain. *Synapse* 1998;29:93–104.
83. Canfield DR, Spealman RD, Kaufman MJ, Madras BK. Autoradiographic localization of cocaine binding sites by [3H]CFT ([3H]WIN 35,428) in the monkey brain. *Synapse* 1990;6:189–195.
84. Volkow ND, Ding YS, Fowler JS, et al. A new PET ligand for the dopamine transporter: studies in the human brain. *J Nucl Med* 1995;36:2162–2168.
85. Kung HF, Kim H-J, Kung M-P, Meegalla SK, Plössl K, Lee H-K. Imaging of dopamine transporters in humans with technetium-99m TRODAT-1. *Eur J Nucl Med* 1996;23:1527–1530.
86. Kung M-P, Stevenson DA, Plössl K, et al. [99mTc]TRODAT-1: a novel technetium-99m complex as a dopamine transporter imaging agent. *Eur J Nucl Med* 1997;24:372–380.
87. Acton PD, Kushner SA, Kung MP, Mozley PD, Plössl K, Kung HF. Simplified reference region model for the kinetic analysis of [99mTc]TRODAT-1 binding to dopamine transporters in non-human primates using SPET. *Eur J Nucl Med* 1999;26:518–526.
88. Kung HF, Billings JJ, Guo Y-Z, et al. Preparation and biodistribution of (125I)IBZM: a potential CNS D2 dopamine receptor imaging agent. *Nucl Med Biol* 1988;15:195–201.
89. Kung HF, Pan S, Kung M-P, Billings JJ, et al. In vitro and in vivo evaluation of (123I)IBZM: a potential CNS D2 dopamine receptor imaging agent. *J Nucl Med* 1989;30:88–92.
90. Kung HF, Alavi A, Chang W, et al. In vivo SPECT imaging of CNS D2 dopamine receptors: initial studies with iodine-123-IBZM in humans. *J Nucl Med* 1990;31:573–579.
91. Kung MP, Kung HF, Billings J, Yang Y, Murphy RA, Alavi A. The characterization of IBF as a new selective dopamine D-2 receptor imaging agent. *J Nucl Med* 1990;31:648–654.
92. Billings JJ, Guo YZ, Kung MP, Kung HF. Localization of IBF as a D-2 dopamine receptor imaging agent in nonhuman primates. *Eur J Nucl Med* 1993;20:1146–1153.
93. Kessler RM, Ansari MS, Schmidt DE, et al. High affinity dopamine D2 receptor radioligands. 2. [125I]Epidipride, a potent and specific radioligand for the characterization of striatal and extrastriatal dopamine D2 receptors. *Life Sci* 1991;49:617–628.
94. Kessler RM, Mason NS, Votaw JR, et al. Visualization of extrastriatal dopamine D2 receptors in the human brain. *Eur J Pharmacol* 1992;223:105–107.
95. Ehrin E, Farde L, de Paulis T. Preparation of ¹¹C-labelled raclopride, a new potent dopamine receptor antagonist: preliminary PET studies of cerebral dopamine receptors in the monkey. *Int J Appl Rad Isot* 1985;36:269–273.
96. Arnett CD, Wolf AP, Shiue C-Y, et al. Improved delineation of human dopamine receptors using (18F)-N-methylspiroperidol and PET. *J Nucl Med* 1986;27:1878–1882.
97. Shiue C-Y, Fowler JS, Wolf AP, McPherson DW, Arnett CD, Zecca L. No-carrier-added fluorine-18-labeled N-methylspiroperidol: synthesis and biodistribution in mice. *J Nucl Med* 1986;27:226–234.
98. Volkow ND, Fowler JS, Wang G-J, et al. Decreased dopamine transporters with age in healthy human subjects. *Ann Neurol* 1994;36:237–239.
99. Vandyck CH, Seibyl JP, Malison RT, et al. Age-related decline in striatal dopamine transporter binding with iodine-123- β -CIT SPECT. *J Nucl Med* 1995;36:1175–1181.
100. Volkow ND, Ding YS, Fowler JS, et al. Dopamine transporters decrease with age. *J Nucl Med* 1996;37:554–559.
101. Mozley PD, Kim HJ, Gur RC, et al. [I-123]IPT SPECT imaging of CNS dopamine transporters: non-linear effects of normal aging on striatal uptake values. *J Nucl Med* 1996;37:1965–1970.
102. Martin WRW, Palmer MR, Patlak CS, Calne DB. Nigrostriatal function in man studied with positron emission tomography. *Ann Neurol* 1989;26:535–542.
103. Sawle GV, Colebatch JG, Shah A, Brooks DJ, Marsden CD, Frackowiak RSJ. Striatal function in normal aging: implications for Parkinson's disease. *Ann Neurol* 1990;28:799–804.
104. Cordes M, Snow BJ, Cooper S, et al. Age-dependent decline of nigrostriatal dopaminergic function: a positron emission tomographic study of grandparents and their grandchildren. *Ann Neurol* 1994;36:667–670.
105. Antonini A, Leenders KL, Reist H, Thomann R, Beer HF, Locher J. Effect of age on D2 dopamine receptors in normal human brain measured by positron emission tomography and ¹¹C-raclopride. *Arch Neurol* 1993;50:474–480.
106. Mozley PD, Acton PD, Barraclough ED, et al. Effects of age on the cerebral distribution of (Tc-99m)TRODAT-1 in healthy humans. *J Nucl Med* 1999;40:1812–1817.
107. van Dyck CH, Seibyl JP, Malison RT, et al. Age-related decline in dopamine transporters: analysis of striatal subregions, nonlinear effects, and hemispheric asymmetries. *Am J Geriatric Psychiatry* 2002;10:36–43.
108. Leenders KL. The nigrostriatal dopaminergic system assessed in vivo by positron emission tomography in healthy volunteer subjects and patients with Parkinson's disease. *Arch Neurol* 1990;47:1290.
109. Brooks DJ. Detection of preclinical Parkinson's disease with PET. *Neurology* 1991;41(5 Suppl 2):24–27; discussion 28.
110. Brooks DJ, Ibanez V, Sawle GV, et al. Differing patterns of striatal 18F-dopa uptake in Parkinson's disease, multiple system atrophy, and progressive supranuclear palsy. *Ann Neurol* 1990;28:547.
111. Brooks DJ. PET and SPECT studies in Parkinson's disease. *Baillieres Clin Neurol* 1997;6:69–87.
112. Seibyl JP, Marek KL, Quinlan D, et al. Decreased single-photon emission computed tomographic [123I] β -CIT striatal uptake correlates with symptom severity in Parkinson's disease. *Ann Neurol* 1995;38:589–598.
113. Tatsch K, Schwarz J, Oertel WH, Kirsch C-M. SPECT imaging of dopamine D2 receptors with [123I]IBZM in Parkinsonian syndromes. *J Nucl Med* 1991;32:1014–1015.
114. Tatsch K, Schwarz J, Mozley PD, et al. Relationship between clinical features of Parkinson's disease and presynaptic dopamine transporter binding assessed with [123I]IPT and single-photon emission tomography. *Eur J Nucl Med* 1997;24:415–421.
115. Booij J, Tissingh G, Boer GJ, et al. [123I]FP-CIT SPECT shows a pronounced decline of striatal dopamine transporter labelling in early and advanced Parkinson's disease. *J Neurol Neurosurg Psychiatry* 1997;62:133–140.
116. Tissingh G, Booij J, Winogrodzka A, van Royen EA, Wolters EC. IBZM- and CIT-SPECT of the dopaminergic system in parkinsonism. *Neural Transmission Suppl* 1997;50:31–37.
117. Asenbaum S, Brücke T, Pirker W, et al. Imaging of dopamine transporters with iodine-123- β -CIT and SPECT in Parkinson's disease. *J Nucl Med* 1997;38:1–6.
118. Kim HJ, Im JH, Yang SO, et al. Imaging and quantitation of dopamine transporters with iodine-123-IPT in normal and Parkinson's disease subjects. *J Nucl Med* 1997;38:1703–1711.
119. Fischman AJ, Bonab AA, Babich JW, et al. Rapid detection of Parkinson's disease by SPECT with altopane: a selective ligand for dopamine transporters. *Synapse* 1998;29:128–141.
120. Muller T, Farahati J, Kuhn W, et al. [123I] β -CIT SPECT visualizes dopamine transporter loss in de novo Parkinsonian patients. *Eur Neurol* 1998;39:44–48.

121. Booij J, Tissingh G, Winogrodzka A, van Royen EA. Imaging of the dopaminergic neurotransmission system using single-photon emission tomography and positron emission tomography in patients with parkinsonism. *Eur J Nucl Med* 1999;26:171–182.
122. Prunier C, Bezard E, Montharu J, et al. Presymptomatic diagnosis of experimental Parkinsonism with 123I-PE2I SPECT. *Neuroimage* 2003;19:810–816.
123. Prunier C, Payoux P, Guilloteau D, et al. Quantification of dopamine transporter by 123I-PE2I SPECT and the noninvasive Logan graphical method in Parkinson's disease. *J Nuclear Med* 2003;44:663–670.
124. Radau PE, Linke R, Slomka PJ, Tatsch K. Optimization of automated quantification of 123I-IBZM uptake in the striatum applied to parkinsonism. *J Nucl Med* 2000;41:220–227.
125. Ransmayr G, Seppi K, Donnemiller E, et al. Striatal dopamine transporter function in dementia with Lewy bodies and Parkinson's disease. *Eur J Nucl Med* 2001;28:1523–1528.
126. Anonymous. A multicenter assessment of dopamine transporter imaging with DOPASCAN/SPECT in parkinsonism. Parkinson Study Group. *Neurology* 2000;55:1540–1547.
127. Antonini A, Moresco RM, Gobbo C, et al. The status of dopamine nerve terminals in Parkinson's disease and essential tremor: a PET study with the tracer (11-C)FE-CIT. *Neurol Sci* 2001;22:47–48.
128. Bao SY, Wu JC, Luo WF, Fang P, Liu ZL, Tang J. Imaging of dopamine transporters with technetium-99m TRODAT-1 and single photon emission computed tomography. *J Neuroimaging* 2000;10:200–203.
129. Benamer HT, Patterson J, Wyper DJ, Hadley DM, Macphee GJ, Grosset DG. Correlation of Parkinson's disease severity and duration with 123I-FP-CIT SPECT striatal uptake. *Mov Disord* 2000;15:692–698.
130. Berendse HW, Booij J, Francot CM, et al. Subclinical dopaminergic dysfunction in asymptomatic Parkinson's disease patients' relatives with a decreased sense of smell. *Ann Neurol* 2001;50:34–41.
131. Booij J, Habraken JB, Bergmans P, et al. Imaging of dopamine transporters with iodine-123-FP-CIT SPECT in healthy controls and patients with Parkinson's disease. *J Nucl Med* 1998;39:1879–1884.
132. Booij J, Hemelaar TG, Speelman JD, de Bruin K, Janssen AG, van Royen EA. One-day protocol for imaging of the nigrostriatal dopaminergic pathway in Parkinson's disease by (123I)FP-CIT SPECT. *J Nucl Med* 1999;40:753–761.
133. Booij J, Speelman JD, Horstink MW, Wolters EC. The clinical benefit of imaging striatal dopamine transporters with (123I)FP-CIT SPET in differentiating patients with presynaptic parkinsonism from those with other forms of parkinsonism. *Eur J Nucl Med* 2001;28:266–272.
134. Chouker M, Tatsch K, Linke R, Pogarell O, Hahn K, Schwarz J. Striatal dopamine transporter binding in early to moderately advanced Parkinson's disease: monitoring of disease progression over 2 years. *Nucl Med Commun* 2001;22:721–725.
135. Davis MR, Votaw JR, Bremner JD, et al. Initial human PET imaging studies with the dopamine transporter ligand 18F-FECNT. *J Nucl Med* 2003;44:855–861.
136. Dentesangle C, Veyre L, Le Bars D, et al. Striatal D2 dopamine receptor status in Parkinson's disease: an (18F)dopa and (11C)raclopride PET study. *MovDisord* 1999;14:1025–1030.
137. Dueschesne N, Soucy JP, Masson H, Chouinard S, Bedard MA. Cognitive deficits and striatal dopaminergic denervation in Parkinson's disease: a single photon emission computed tomography study using 123iodine- β -CIT in patients on and off levodopa. *Clin Neuropharmacol* 2002;25:216–224.
138. Eising EG, Muller TH, Freudenberg L, et al. SPECT imaging with [123I]- β -CIT in Parkinsonism: comparison of SPECT images obtained by a single-headed and a three-headed gamma camera. *Nucl Med Commun* 2001;22:145–150.
139. Haapaniemi TH, Ahonen A, Torniaainen P, Sotaniemi KA, Myllyla VV. [123I] β -CIT SPECT demonstrates decreased brain dopamine and serotonin transporter levels in untreated parkinsonian patients. *Mov Disord* 2001;16:124–130.
140. Happe S, Pirker W, Klosch G, Sauter C, Zeitlhofer J. Periodic leg movements in patients with Parkinson's disease are associated with reduced striatal dopamine transporter binding. *J Neurol* 2003;250:83–86.
141. Huang WS, Lin SZ, Lin JC, Wey SP, Ting G, Liu RS. Evaluation of early-stage Parkinson's disease with 99mTc-TRODAT-1 imaging. *J Nucl Med* 2001;42:1303–1308.
142. Ichise M, Kim YJ, Ballinger JR, Vines D, Erami SS, Tanaka F, et al. SPECT imaging of pre- and postsynaptic dopaminergic alterations in L-dopa-untreated PD. *Neurology* 1999;52:1206–1214.
143. Ilgin N, Zubieta J, Reich SG, Dannals RF, Ravert HT, Frost JJ. PET imaging of the dopamine transporter in progressive supranuclear palsy and Parkinson's disease. *Neurology* 1999;52:1221–1226.
144. Kaasinen V, Nagren K, Hietala J, et al. Extrastriatal dopamine D2 and D3 receptors in early and advanced Parkinson's disease. *Neurology* 2000;54:1482–1487.
145. Kaasinen V, Ruottinen HM, Nagren K, Lehtikoinen P, Oikonen V, Rinne JO. Upregulation of putaminal dopamine D2 receptors in early Parkinson's disease: a comparative PET study with [11C] raclopride and [11C]N-methylspiperone. *J Nucl Med* 2000;41:65–70.
146. Kaasinen V, Rinne JO. Functional imaging studies of dopamine system and cognition in normal aging and Parkinson's disease. *Neurosci Biobehav Rev* 2002;26:785–793.
147. Kaasinen V, Aalto S, K NA, Hietala J, Sonninen P, Rinne JO. Extrastriatal dopamine D(2) receptors in Parkinson's disease: a longitudinal study. *J Neural Transmission* 2003;110:591–601.
148. Kao PF, Tzen KY, Yen TC, et al. The optimal imaging time for (99Tcm)TRODAT-1/SPET in normal subjects and patients with Parkinson's disease. *Nucl Med Commun* 2001;22:151–154.
149. Linke R, Gostomzyk J, Hahn K, Tatsch K. [123I]IPT binding to the presynaptic dopamine transporter: variation of intra- and interobserver data evaluation in parkinsonian patients and controls. *Eur J Nucl Med* 2000;27:1809–1812.
150. Lokkegaard A, Werdelin LM, Friberg L. Clinical impact of diagnostic SPET investigations with a dopamine re-uptake ligand. *Eur J Nucl Med Mol Imaging* 2002;29:1623–1629.
151. Marek K, Innis R, van Dyck C, et al. [123I] β -CIT SPECT imaging assessment of the rate of Parkinson's disease progression. *Neurology* 2001;57:2089–2094.
152. Mozley PD, Schneider JS, Acton PD, et al. Binding of (Tc-99m)TRODAT-1 to dopamine transporters in patients with Parkinson's disease and healthy volunteers. *J Nucl Med* 2000;41:584–589.
153. Muller U, Wachter T, Barthel H, Reuter M, von Cramon DY. Striatal (123I) β -CIT SPECT and prefrontal cognitive functions in Parkinson's disease. *J Neural Transmission* 2000;107:303–319.
154. Nakabeppu O, Nakajo M, Mitsuda M, Tsuchimochi S, Tani A, Osame M. Iodine-123 iodobenzofuran (I-123 IBF) SPECT in patients with parkinsonism. *Ann Nucl Med* 1999;13:447–452.
155. Nurmi E, Ruottinen HM, Kaasinen V, et al. Progression in Parkinson's disease: a positron emission tomography study with a dopamine transporter ligand [18F]CFT. *Ann Neurol* 2000;47:804–808.
156. Rinne JO, Bergman J, Ruottinen H, et al. Striatal uptake of a novel PET ligand, (18F) β -CFT, is reduced in early Parkinson's disease. *Synapse* 1999;31:119–124.
157. Rinne JO, Ruottinen H, Bergman J, Haaparanta M, Sonninen P, Solin O. Usefulness of a dopamine transporter PET ligand ((18F) β -CFT) in assessing disability in Parkinson's disease. *J Neurol Neurosurg Psychiatry* 1999;67:737–741.
158. Sakakibara R, Shinotoh H, Uchiyama T, Yoshiyama M, Hattori T, Yamanishi T. SPECT imaging of the dopamine transporter with (123I)- β -CIT reveals marked decline of nigrostriatal dopaminergic function in Parkinson's disease with urinary dysfunction. *J Neurol Sci* 2001;187:55–59.
159. Shinotoh H, Uchida Y, Ito H, Harrori T. Relationship between striatal [123I] β -CIT binding and four major clinical signs in Parkinson's disease. *Ann Nucl Med* 2000;14:199–203.
160. Staffen W, Mair A, Unterrainer J, Trinka E, Ladurner G. Measuring the progression of idiopathic Parkinson's disease with (123I) β -CIT SPECT. *J Neural Transmission* 2000;107:543–552.

161. Staffen W, Mair A, Unterrainer J, Trinka E, Bsteh C, Ladurner G. [123I] β -CIT binding and SPET compared with clinical diagnosis in parkinsonism. *Nucl Med Commun* 2000;21:417–424.
162. Winogrodzka A, Bergmans P, Booij J, van Royen EA, Janssen AG, Wolters EC. [123I]FP-CIT SPECT is a useful method to monitor the rate of dopaminergic degeneration in early-stage Parkinson's disease. *J Neural Transmission* 2001;108:1011–1019.
163. Van Royen E, Verhoeff NFLG, Speelman JD, Wolters EC, Kuiper MA, Janssen AGM. Multiple system atrophy and progressive supranuclear palsy. Diminished striatal D2 receptor activity demonstrated by 123IBZM single photon emission computed tomography. *Arch Neurol* 1993;50:513–516.
164. Burn DJ, Sawle GV, Brooks DJ. Differential diagnosis of Parkinson's disease, multiple system atrophy, and Steele-Richardson-Olszewski syndrome: discriminant analysis of striatal 18F-dopa PET data. *J Neurol Neurosurg Psych* 1994;57:278–284.
165. Pirker W, Asenbaum S, Wenger S, et al. Iodine-123-epidepride-SPECT: studies in Parkinson's disease, multiple system atrophy and Huntington's disease. *J Nucl Med* 1997;38:1711–1717.
166. Brucke T, Asenbaum S, Pirker W, et al. Measurement of the dopaminergic degeneration in Parkinson's disease with [123I] β -CIT and SPECT. Correlation with clinical findings and comparison with multiple system atrophy and progressive supranuclear palsy. *J Neural Transm* 1997;50:9–24.
167. Messa C, Volonte MA, Fazio F, et al. Differential distribution of striatal [123I] β -CIT in Parkinson's disease and progressive supranuclear palsy, evaluated with single photon emission tomography. *Eur J Nucl Med* 1998;25:1270–1276.
168. Hierholzer J, Cordes M, Venz S, et al. Loss of dopamine-D2 receptor binding sites in Parkinsonian plus syndromes. *J Nucl Med* 1998;39:954–960.
169. Barthel H, Sorger D, Kuhn HJ, Wagner A, Kluge R, Hermann W. Differential alteration of the nigrostriatal dopaminergic system in Wilson's disease investigated with [123 I]ss-CIT and high-resolution SPET. *Eur J Nucl Med* 2001;28:1656–1663.
170. Barthel H, Hermann W, Kluge R, et al. Concordant pre- and postsynaptic deficits of dopaminergic neurotransmission in neurologic Wilson disease. *Am J Neuroradiol* 2003;24:234–238.
171. Brashear A, Mulholland GK, Zheng QH, Farlow MR, Siemers ER, Hutchins GD. PET imaging of the pre-synaptic dopamine uptake sites in rapid-onset dystonia-parkinsonism (RDP). *Mov Disord* 1999;14:132–137.
172. Eisensehr I, Linke R, Noachtar S, Schwarz J, Gildehaus FJ, Tatsch K. Reduced striatal dopamine transporters in idiopathic rapid eye movement sleep behaviour disorder. Comparison with Parkinson's disease and controls. *Brain* 2000;123:1155–1160.
173. Gerschlagel W, Bencsits G, Pirker W, et al. (123I) β -CIT SPECT distinguishes vascular parkinsonism from Parkinson's disease. *Mov Disord* 2002;17:518–523.
174. Huang CC, Yen TC, Weng YH, Lu CS. Normal dopamine transporter binding in dopa responsive dystonia. *J Neurol* 2002;249:1016–1020.
175. Jeon B, Kim JM, Jeong JM, et al. Dopamine transporter imaging with (123I)- β -CIT demonstrates presynaptic nigrostriatal dopaminergic damage in Wilson's disease. *J Neurol Neurosurg Psychiatry* 1998;65:60–64.
176. Jeon BS, Jeong JM, Park SS, et al. Dopamine transporter density measured by (123I) β -CIT single-photon emission computed tomography is normal in dopa-responsive dystonia. *Ann Neurol* 1998;43:792–800.
177. Katzenschlager R, Costa D, Gerschlagel W, et al. [123I]-FP-CIT-SPECT demonstrates dopaminergic deficit in orthostatic tremor. *Ann Neurol* 2003;53:489–496.
178. Oyanagi C, Katsumi Y, Hanakawa T, et al. Comparison of striatal dopamine D2 receptors in Parkinson's disease and progressive supranuclear palsy patients using [123I] iodobenzofuran single-photon emission computed tomography. *J Neuroimaging* 2002;12:316–324.
179. Pirker W, Asenbaum S, Bencsits G, et al. [123I] β -CIT SPECT in multiple system atrophy, progressive supranuclear palsy, and corticobasal degeneration. *Mov Disord* 2000;15:1158–1167.
180. Pirker W, Djamshidian S, Asenbaum S, et al. Progression of dopaminergic degeneration in Parkinson's disease and atypical parkinsonism: a longitudinal β -CIT SPECT study. *Mov Disord* 2002;17:45–53.
181. Sjöholm H, Sundsfjord J, Mellgren SI. Beta-CIT-SPECT combined with UPDRS appears to distinguish different parkinsonian conditions. *Acta Neurol Scand* 2002;105:5–7.
182. Tzen KY, Lu CS, Yen TC, Wey SP, Ting G. Differential diagnosis of Parkinson's disease and vascular parkinsonism by (99m)Tc-TRODAT-1. *J Nucl Med* 2001;42:408–413.
183. Varrone A, Marek KL, Jennings D, Innis RB, Seibyl JP. [(123I)] β -CIT SPECT imaging demonstrates reduced density of striatal dopamine transporters in Parkinson's disease and multiple system atrophy. *Mov Disord* 2001;16:1023–1032.
184. Walker Z, Costa DC, Walker RW, et al. Differentiation of dementia with Lewy bodies from Alzheimer's disease using a dopaminergic presynaptic ligand. *J Neurol Neurosurg Psychiatry* 2002;73:134–140.
185. Morrish PK, Sawle GV, Brooks DJ. Clinical and [18F]dopa PET findings in early Parkinson's disease. *J Neurol Neurosurg Psychiatry* 1995;59:597–600.
186. Tissingh G, Bergmans P, Booij J, et al. Drug-naïve patients with Parkinson's disease in Hoehn and Yahr stages I and II show a bilateral decrease in striatal dopamine transporters as revealed by [123I] β -CIT SPECT. *J Neurol* 1998;245:14–20.
187. Hilker R, Klein C, Ghaemi M, et al. Positron emission tomographic analysis of the nigrostriatal dopaminergic system in familial parkinsonism associated with mutations in the parkin gene. *Ann Neurol* 2001;49:367–376.
188. Laihininen A, Ruottinen H, Rinne JO, et al. Risk for Parkinson's disease: twin studies for the detection of asymptomatic subjects using [18F]6-fluorodopa PET. *J Neurol* 2000;247(Suppl 2):110–113.
189. Morrish PK, Rakshi JS, Bailey DL, Sawle GV, Brooks DJ. Measuring the rate of progression and estimating the preclinical period of Parkinson's disease with [18F]dopa PET. *J Neurol Neurosurg Psychiatry* 1998;64:314–319.
190. Marek KL, Seibyl JP, Zoghbi SS, et al. [I-123] β -CIT SPECT imaging demonstrates bilateral loss of dopamine transporters in hemi-Parkinson's disease. *Neurology* 1996;46:231–237.
191. Rakshi JS, Uema T, Ito K. Statistical parametric mapping of three dimensional 18F-dopa PET in early and advanced Parkinson's disease (abstract). *Mov Disord* 1996;11:147.
192. Maraganore DM, O'Connor MK, et al. Detection of preclinical Parkinson disease in at-risk family members with use of (123I) β -CIT and SPECT: an exploratory study. *Mayo Clinic Proc* 1999;74:681–685.
193. Antonini A, Moresco RM, Gobbo C, et al. Striatal dopaminergic denervation in early and late onset Parkinson's disease assessed by PET and the tracer [11C]FECIT: preliminary findings in one patient with autosomal recessive parkinsonism (Park2). *Neurol Sci* 2002;23(Suppl 2):S51–S52.
194. Khan NL, Brooks DJ, Pavese N, et al. Progression of nigrostriatal dysfunction in a parkin kindred: an (18F)dopa PET and clinical study. *Brain* 2002;125:2248–2256.
195. Wu RM, Shan DE, Sun CM, et al. Clinical, 18F-dopa PET, and genetic analysis of an ethnic Chinese kindred with early-onset parkinsonism and parkin gene mutations. *Mov Disord* 2002;17:670–675.
196. Khan NL, Valente EM, Bentivoglio AR, et al. Clinical and sub-clinical dopaminergic dysfunction in PARK6-linked parkinsonism: an 18F-dopa PET study. *Ann Neurol* 2002;52:849–853.
197. Sawle GV, Playford ED, Burn DJ, Cunningham VJ, Brooks DJ. Separating Parkinson's disease from normality: discriminant function analysis of [18F]Dopa PET data. *Arch Neurol* 1993;51:237–243.
198. Rinne JO, Laihininen A, Nagren K, Ruottinen H, Ruotsalainen U, Rinne UK. PET examination of the monoamine transporter with

- [11C] β -CIT and [11C] β -CFT in early Parkinson's disease. *Synapse* 1995;21:97–103.
199. Druschky A, Hilz MJ, Platsch G, et al. Differentiation of Parkinson's disease and multiple system atrophy in early disease stages by means of I-123-MIBG-SPECT. *J Neurol Sci* 2000;175:3–12.
 200. Berding G, Schrader CH, Peschel T, et al. [N-methyl 11C]meta-Hydroxyephedrine positron emission tomography in Parkinson's disease and multiple system atrophy. *Eur J Nucl Med Mol Imaging* 2003;30:127–131.
 201. Boecker H, Weindl A, Leenders K, et al. Secondary parkinsonism due to focal substantia nigra lesions: a PET study with [18F]FDG and [18F]fluorodopa. *Acta Neurol Scand* 1996;93:387–392.
 202. Kato T, Kume A, Ito K, Tadokoro M, Takahashi A, Sakuma S. Asymmetrical FDG-PET and MRI findings of striatonigral system in multiple system atrophy. *Radiat Med* 1992;10:87–93.
 203. Kume A, Shiratori M, Takahashi A, et al. Hemi-parkinsonism in multiple system atrophy: a PET and MRI study. *J Neurol Sci* 1992;110:37–45.
 204. Hu MT, Taylor-Robinson SD, Chaudhuri KR, et al. Cortical dysfunction in non-demented Parkinson's disease patients: a combined (31)P-MRS and (18)FDG-PET study. *Brain* 2000;123:340–352.
 205. Ghaemi M, Raethjen J, Hilker R, et al. Monosymptomatic resting tremor and Parkinson's disease: a multitracer positron emission tomographic study. *Mov Disord* 2002;17:782–788.
 206. Arnold G, Tatsch K, Oertel WH, et al. Clinical progressive supranuclear palsy: differential diagnosis by IBZM-SPECT and MRI. *J Neural Transm* 1994;42:111–118.
 207. Schulz JB, Klockgether T, Peterson D, et al. Multiple system atrophy: natural history, MRI morphology, and dopamine receptor imaging with 123IBZM-SPECT. *J Neurol Neurosurg Psych* 1994;57:1047–1056.
 208. Acton PD, Mozley PD. Single photon emission tomography imaging in parkinsonian disorders: a review. *Behav Neurol* 2000;12:11–27.
 209. Wenning GK, Donnemiller E, Granata R, Riccabona G, Poewe W. 123I- β -CIT and 123I-IBZM SPECT scanning in levodopa-naïve Parkinson's disease. *Mov Disord* 1998;13:438–445.
 210. Kim YJ, Ichise M, Tatschida T, Ballinger JR, Vines D, Lang AE. Differential diagnosis of parkinsonism using dopamine transporter and D2 receptor SPECT. *J Nucl Med* 1999;5(Suppl):68P.
 211. Kim YJ, Ichise M, Ballinger JR, et al. Combination of dopamine transporter and D2 receptor SPECT in the diagnostic evaluation of PD, MSA, and PSP. *Mov Disord* 2002;17:303–312.
 212. Dresel SHJ, Kung MP, Huang XF, et al. Simultaneous SPECT studies of pre- and post-synaptic dopamine binding sites in baboons. *J Nucl Med* 1999;40:660–666.
 213. Ma KH, Huang WS, Chen CH, et al. Dual SPECT of dopamine system using (99mTc)TRODAT-1 and (123I)IBZM in normal and 6-OHDA-lesioned Formosan rock monkeys. *Nucl Med Biol* 2002;29:561–567.
 214. Miyawaki E, Meah Y, Koller WC. Serotonin, dopamine, and motor effects in Parkinson's disease. *Clin Neuropharmacol* 1997;20:300–310.
 215. Brucke T, Kornhuber J, Angelberger P, Asenbaum S, Frassine H, Podreka I. SPECT imaging of dopamine and serotonin transporters with (123I) β -CIT. Binding kinetics in the human brain. *J Neural Transmission* 1993;94:137–146.
 216. Pirker W, Asenbaum S, Hauk M, et al. Imaging serotonin and dopamine transporters with 123I- β -CIT SPECT: binding kinetics and effects of normal aging. *J Nucl Med* 2000;41:36–44.
 217. Malison RT, Price LH, Berman R, et al. Reduced brain serotonin transporter availability in major depression as measured by (123I)-2b-carbomethoxy-3b-(4-iodophenyl)tropane and single photon emission computed tomography. *Biol Psychiatry* 1998;11:1090–1098.
 218. Kim SE, Lee WY, Choe YS, Kim JH. SPECT measurement of iodine-123- β -CIT binding to dopamine and serotonin transporters in Parkinson's disease: correlation with symptom severity. *Neurol Res* 1999;21:255–261.
 219. Kim SE, Choi JY, Choe YS, Choi Y, Lee WY. Serotonin transporters in the midbrain of Parkinson's disease patients: a study with 123I- β -CIT SPECT. *J Nucl Med* 2003;44:870–876.
 220. Murai T, Muller U, Werheid K, et al. In vivo evidence for differential association of striatal dopamine and midbrain serotonin systems with neuropsychiatric symptoms in Parkinson's disease. *J Neuropsychiatry Clin Neurosci* 2001;13:222–228.
 221. Owens MJ, Nemeroff CB. Role of serotonin in the pathophysiology of depression: focus on the serotonin transporter. *Clin Chem* 1994;40:288–295.
 222. Acton PD, Kung MP, Mu M, et al. Single photon emission tomography imaging of serotonin transporters in the nonhuman primate brain with the selective radioligand [123I]IDAM. *Eur J Nucl Med* 1999;26:854–861.
 223. Acton PD, Mu M, Plössl K, et al. Single photon emission tomography imaging of serotonin transporters in the nonhuman primate brain with [123I]ODAM. *Eur J Nucl Med* 1999;26:1359–1362.
 224. Acton PD, Choi SR, Hou C, Plössl K, Kung HF. Quantification of serotonin transporters in nonhuman primates using [123I]ADAM and single photon emission tomography. *J Nucl Med* 2001;42:1556–1562.
 225. Choi SR, Hou C, Oya S, et al. Selective in vitro and in vivo binding of [125I]ADAM to serotonin transporters in rat brain. *Synapse* 2000;38:403–412.
 226. Ginovart N, Wilson AA, Meyer JH, Hussey D, Houle S. Positron emission tomography quantification of (11C)-DASB binding to the human serotonin transporter: modeling strategies. *J Cereb Blood Flow Metab* 2001;21:1342–1353.
 227. Kung MP, Hou C, Oya S, Mu M, Acton PD, Kung HF. Characterization of (123I)IDAM as a novel single photon emission tomography tracer for serotonin transporters. *Eur J Nucl Med* 1999;26:844–853.
 228. Oya S, Kung MP, Acton PD, Hou C, Mu M, Kung HF. A new SPECT imaging agent for serotonin transporters, [I-123]IDAM: 5-iodo-2-[[2-2-[(dimethylamino) methyl] phenyl] thio] benzyl alcohol. *J Med Chem* 1999;42:333–335.
 229. Oya S, Choi SR, Hou C, et al. 2-((2-((dimethylamino)-methyl)phenyl)thio)-5-iodophenylamine (ADAM): an improved serotonin transporter ligand. *Nucl Med Biol* 2000;27:249–254.
 230. Zhuang ZP, Choi SR, Hou C, et al. A novel serotonin transporter ligand: 5-iodo-2-(2-dimethylaminomethylphenoxy)-benzyl alcohol (ODAM). *Nucl Med Biol* 2000;27:169–175.



<http://www.springer.com/978-1-58829-391-6>

Bioimaging in Neurodegeneration

Broderick, P.A.; Rahni, D.N.; Kolodny, E.H. (Eds.)

2005, XVI, 314 p. With CD-ROM., Hardcover

ISBN: 978-1-58829-391-6

A product of Humana Press