

HIV-1 Infection of the Central Nervous System

Andreas Büttner, MD and Serge Weis, MD

CONTENTS

INTRODUCTION

EPIDEMIOLOGY

GROSS ANATOMICAL CHANGES

CHANGES PRIMARILY ATTRIBUTABLE TO HIV-1

CHANGES PROBABLY ATTRIBUTABLE TO HIV-1

VIRAL INFECTIONS IN THE COURSE OF HIV-1 INFECTION

PARASITIC INFECTIONS

FUNGAL INFECTIONS

NEOPLASIA IN THE COURSE OF HIV-1 INFECTION

FREQUENCY AND TOPOGRAPHICAL DISTRIBUTION OF NEUROPATHOLOGICAL CHANGES

IMMUNOHISTOCHEMICAL DEMONSTRATION OF HIV-1: FREQUENCY AND TOPOGRAPHY

DIAGNOSTIC DIFFICULTIES: UNSPECIFIED NODULAR ENCEPHALITIS

NEUROPATHOLOGICAL CHANGES IN CHILDREN INFECTED WITH HIV-1

NEUROPATHOLOGICAL CHANGES IN EARLY STAGES OF HIV-1 INFECTION

NEUROPATHOLOGICAL CHANGES IN THE (HAART) ERA

CEREBROVASCULAR COMPLICATIONS

PATHOGENETIC MECHANISMS

REFERENCES

From: *Forensic Pathology Reviews, Vol. 3*
Edited by: M. Tsokos © Humana Press Inc., Totowa, NJ

SUMMARY

The forensic pathologist frequently is confronted with human immunodeficiency virus (HIV)-1 infection, especially in the context of drug abuse. After involvement of the lung, the brain is the second most frequently affected organ in HIV-1 infection. Because HIV-1 rarely is the cause of focal macroscopical lesions, even in severely infected patients, the systematic sampling of specimens for histological examination is required. If focal lesions are present, they are almost always attributed to opportunistic infections, cerebrovascular complications, or neoplasms. Changes primarily attributed to HIV-1 include HIV-1 encephalitis, HIV-1 leukoencephalopathy, and HIV-1 myelitis. Early changes in the course of the infection are characterized by meningeal lymphocytic infiltration and perivascular lymphocytic infiltration. Changes probably attributed to HIV-1 include vacuolar myelopathy and vacuolar leukoencephalopathy. Opportunistic infections seen in the course of HIV-1 infection include a broad spectrum of viral, parasitic, fungal, and bacterial infections. Furthermore, ischemic stroke and intracranial hemorrhage, as well as lymphoma and Kaposi sarcoma, may be encountered. Despite the introduction of antiretroviral therapies with a greater life expectancy of HIV-1-infected individuals, epidemiological data suggest that involvement of the brain in acquired immunodeficiency syndrome subjects continues to be a frequent autopsy finding. In the brains of HIV-1-infected children, the most common findings are vascular mineralization/calcification, myelin pallor, and gliosis of the white matter as well as inflammatory infiltrates and/or multinucleated giant cells. In contrast to adults, opportunistic infections are comparatively uncommon. The pathogenetic mechanisms induced by HIV-1 infection and leading to the multiple facets of brain damage are not yet clearly understood. The development of brain lesions caused by opportunistic infections and lymphomas might be explained by the lack of a competent immunological defense system. In contrast, changes caused by direct or rather indirect effects of HIV-1 are more controversially discussed. HIV-1 enters the brain mainly by being passively carried by T lymphocytes and monocytes. Thereafter, perivascular macrophages spread productive HIV-1 infection to neighboring microglia. These are the major cell populations in the brain that are productively infected with HIV-1. They serve as a reservoir for persistent viral infection and replication, a vehicle for viral dissemination throughout the brain, and a major source of neurotoxic products that affect glial function, the blood-brain barrier and neuronal function and finally lead to cell death.

Key Words: Central nervous system; forensic pathology; HIV-1 infection; opportunistic infections; pathogenesis.

1. INTRODUCTION

Human immunodeficiency virus (HIV)-1 infection is a serious health problem worldwide, and the forensic pathologist frequently is confronted with this disease, especially in the context of drug abuse (1–11). Intravenous drug abuse is a major risk factor for HIV-1 infection, and several drugs of abuse have been shown to enhance both the HIV-1 entry into the central nervous system (CNS) as well as the effects of HIV-1 on the CNS (2,6,12–25). Similar to HIV-1, many abused drugs tend to affect neuronal function and enhance the microglial activation resulting from HIV-1 infection in some individuals (26,27). Further paralleling HIV-1, some drugs seem to compromise immune function, which in turn may have secondary detrimental effects on the CNS (28).

Neuropathological examinations show, in up to 95% of the brains, changes that may be attributed to the primary effect of HIV-1 or to opportunistic agents (29–45).

In this chapter, the neuropathological features seen in the brains of patients infected with HIV-1 are reviewed briefly, and representative illustrations are shown. The reader also is referred to the multitude of articles and textbooks describing the neuropathological changes (6,14,16,29–76) as well as review articles on HIV-1 and the brain (34,72,77–110). Moreover, changes especially seen in the early stages of HIV-1 infection in adults as well as those seen in the brains of children infected with HIV-1 are described briefly. In the following, the nomenclature and the neuropathology-based terminology as proposed in the consensus report of Budka et al. (31) is adopted. The definitions given in this report serve as guidelines for the neuropathological descriptions.

The term “AIDS dementia complex” (ADC) was coined in 1986 (42,97) to describe cognitive and motor disturbances frequently encountered in patients infected with HIV-1. The authors suggested that the pathogenesis of ADC was attributed to the changes found in the basal ganglia. Thus, ADC was considered to belong to the class of subcortical dementias. The name ADC was later changed into HIV-1-associated cognitive and motor complex with HIV-1-associated dementia complex (motor)/(behavior) (HAD) and HIV-1-associated myelopathy as its severe manifestations and HIV-1-associated minor cognitive/motor disorder as its mild manifestation (111). It eventually affects up to 30% of untreated adult patients with acquired immunodeficiency syndrome (AIDS [31,112,113]). It is characterized by progressive cognitive decline, motor dysfunction, and behavioral abnormalities in 65% of patients (97,98,101,112,114). HAD is the most devastating CNS consequence of AIDS because of its poor prognosis and functional impairment. In some persons

with HAD, the behavioral abnormalities can lead to violence and other criminal behavior (115).

The pathogenesis of HIV-1-induced brain damage is uncertain, and there is evidence that multiple mechanisms leading to neurological injury occur (*see* Section 17). These mechanisms include the role of neurovirulent strains of HIV-1, the potential neurotoxicity of HIV proteins, macrophage/microglia-mediated CNS injury, and altered blood–brain barrier (BBB) permeability (77,83,84,98,103,105,116–118).

Table 1 provides a survey of the neuropathological changes seen in the brains of patients infected with HIV-1. Table 2 summarizes the changes occurring in the peripheral nervous system and skeletal muscles of patients infected with HIV-1, but these are not dealt with in this review. The reader is directed to articles dealing in more detail with the neuropathology of peripheral nervous system and skeletal muscles (119–127).

As a rule in the forensic setting, the HIV status of all persons undergoing autopsy should be determined ahead by enzyme-linked immunosorbent assay analysis of blood samples, which may be obtained from femoral vessels. The precautions in performing the autopsy of a patient who was infected with HIV, including the removal and fixation of the brain, are reviewed elsewhere and should be strictly practiced (128–133). For a thorough neurohistopathological examination, infected cells may be identified by *in situ* hybridization or immunohistochemistry against HIV-1 proteins (31,134–137).

2. EPIDEMIOLOGY

Worldwide, 33 million adults and 2 million children are infected with HIV-1. Despite preventive efforts, the epidemic continues to spread rapidly, and the socioeconomic consequences of the neurological dysfunction caused by HIV-1 infection are of enormous proportions. Most of the affected patients live in developing countries, where anti-retroviral medications are not available.

After involvement of the lung (75–85%), the brain is the second most frequently affected organ (60–80%) in HIV-1 infection (16). The neurological complications of HIV-1 infection are highly stage-specific. Therefore, incidence rates depend on the stage, in which the individual is in, during the course of systemic HIV-1 infection (70,99).

Neurological signs and symptoms are seen in up to 50% of patients infected with HIV-1 (34,60,66,99,138,139). In approx 10% of the cases, neurological signs are the first presentation of the disease (34,60,66,139). HIV-1-associated CNS complications vary with ethnicity (140) and geography (40,47,141,142). The different findings likely reflect afflictions common to

Table 1

Survey of the More Common Neuropathological Changes Seen in the Brains of Patients Infected With HIV-1

Changes primarily attributable to HIV-1

1. HIV-1 encephalitis (HIVE)
2. HIV-1 leukoencephalopathy (HIVL)
3. HIV-1 myelitis
4. Lymphocytic meningitis (LM), meningeal lymphocytic infiltration (MLI), and perivascular lymphocytic infiltration (PLI)

Changes probably attributable to HIV-1

1. Vacuolar myelopathy (VM)
2. Vacuolar leukoencephalopathy (VL)

Opportunistic infections and neoplasias

1. Viral Infections
 - Cytomegalovirus infection (CMV)
 - Progressive multifocal leukoencephalopathy (PML)
 - Others including herpes simplex 1, herpes simplex 2, herpes zoster, HTLV-1
 2. Parasitic infections
 - Protozoa: *Toxoplasma gondii*, *Acanthamoeba*, *Leptomyxid amoeba*, *Trypanosoma cruzi*
 - Metazoa: *Strongyloides*
 3. Fungal infections
 - *Aspergillus fumigatus*
 - *Candida albicans*
 - *Cryptococcus neoformans*
 - Others including *histoplasma*, *phycomyces*, *coccidioides*, *blastomyces*, *acremonium*, *cladosporium*
 4. Bacterial infections
 - Pyogenic: *Escherichia coli*, *Listeria*, *Staphylococcus*, *Salmonella*
 - Mycobacterial: *Mycobacterium tuberculosis*, *Mycobacterium avium intracellulare*
 - Spirochetal: *Treponema pallidum*
 - Filamentous: *Nocardia*
 - Miscellaneous: Whipple's disease
 5. Neoplasia
 - Lymphoma (primary and secondary)
 - Kaposi sarcoma
-

Table 2

Neuropathological Changes Observed in the Peripheral Nervous System and Skeletal Muscles of Patients Infected With HIV-1

Peripheral nervous system

1. Acute inflammatory demyelinating (poly) (radiculo) neuropathy
2. Chronic inflammatory demyelinating (poly) (radiculo) neuropathy
3. Axonal neuropathy
4. Ganglionitis, ganglioradiculitis, (poly) (radiculo) neuritis
5. Necrotizing vasculitis, vasculitic neuropathy

Skeletal muscle

1. (Poly-)myositis
 2. Necrotizing myopathy
 3. Nemaline rod myopathy
 4. Vesicular myopathy, mitochondrial myopathy
 5. Necrotizing vasculitis
-

developing countries—a high prevalence of opportunistic infections and a high mortality rate. These conditions rarely lead to the development of complications such as lymphoma, which usually occurs later in the natural course of the HIV-1 infection. Death caused by systemic opportunistic infections may punctuate the course of HIV-1 encephalitis and prevent its full-blown morphological expression. However, larger autopsy studies of patients infected with HIV-1 over the course of longer time periods suggest that, despite the beneficial effects of modern antiretroviral combination therapy, involvement of the brain in AIDS subjects continues to be a frequent autopsy finding (16,143–145).

3. GROSS ANATOMICAL CHANGES

It is important to emphasize the diffuse nature of the alterations that are likely to be present on gross examination. HIV-1 is rarely the cause of focal macroscopical lesions, even in heavily infected patients (71). Therefore, systematic sampling of specimens for histological examination is required. If focal lesions are present, they are almost always caused by opportunistic infections, hemorrhages, or neoplasms.

Using imaging techniques (computed tomography, magnetic resonance imaging), it was claimed that brain atrophy is viewed in patients with HIV-1 infection and that this atrophy is already apparent in early stages of the infec-

tion (146–148). Using autopsy brains and applying morphometrical techniques, one can assess whether signs of atrophy occur, which parts of the brain are affected, and to which extent these regions are affected.

The brain weight can be used as a rough indicator for atrophic changes occurring in the brain. Data on the weight of brains infected with HIV-1 are rarely published. The brain weight of 165 brains from HIV-1-positive patients and 155 age- and gender-matched controls was analyzed (Weis et al., unpublished data). No significant difference between controls and AIDS brains existed: the average brain weight of controls was 1434.94 g and that of HIV-1-positive patients was 1406.22 g. The degree of brain edema was rated using a three-point scale (0 = no brain edema; 1 = moderate brain edema; 2 = severe brain edema). There was no significant difference between the brains of controls and patients with AIDS. Furthermore, we used a three-point rating scale for assessing the widening of the ventricles (0 = no widening of lateral ventricles; 1 = moderate widening of lateral ventricles; 2 = marked widening of lateral ventricles). The widening of the lateral ventricles in the brains of patients with AIDS reached the level of statistical significance ($p = 0.04$; Weis et al., unpublished data).

Gelman and Guinto (146) measured cerebrospinal fluid (CSF) spaces in 64 consecutively autopsied patients with AIDS, which were compared with age-matched non-AIDS subjects (1992). Of the patients with AIDS, 37 (58%) had a CSF space index greater than 2 standard deviations above the mean of the age-matched control subjects. CSF spaces were expanded most in the frontal and temporal lobes; ventricular spaces were expanded more than the sulcal spaces. Patients with atrophy were much more likely to have HIV-1-associated histopathological changes in their brains, but the relationships were too weak to establish the microscopical cause of the atrophy.

Oster et al. (147) obtained stereological estimates of mean volumes, surface areas, and cortical thicknesses on formalin-fixed brains from 19 men with AIDS and 19 controls. In AIDS, the mean volume of the neocortex was reduced by 11%, and that of the central brain nuclei by 18%. Mean ventricular volume was increased by 55%. Mean neocortical thickness was reduced by 12%. The mean volume of the white matter was reduced by 13%. The findings in six clinically demented AIDS patients were not statistically different from the rest of the group.

The volumes of 20 cortical and 17 subcortical brain structures were estimated using Cavalieri's principle by Weis et al. (149). Furthermore, the surface area and the mean cortical thickness of all cortical structures were measured. No significant changes were found in the cerebral cortex of patients

infected with HIV-1 as compared with age- and gender-matched controls. Only a significant reduction in volume was found in the internal capsule. The lack of significant changes in the brains of patients infected with HIV-1 might be attributed to the selection of the sample, which was composed of brains with the neuropathological diagnosis of HIV-1 encephalitis but that showed no remarkable gross anatomical changes.

Subbiah et al. (148) also used unbiased, stereological methods on post-mortem brain specimens to estimate volumes of different brain regions in patients prospectively diagnosed with and without HIV-associated dementia. A significant reduction in the mean neocortical volume (15%) was observed in the group with AIDS when compared with the seronegative controls, and this difference was accentuated when comparing only the group with HIV-associated dementia to the seronegatives (neocortex: 18%).

4. CHANGES PRIMARILY ATTRIBUTABLE TO HIV-1

4.1. HIV-1 Encephalitis

HIV-1 encephalitis (HIVE) is characterized by multiple disseminated inflammatory foci composed of microglia, macrophages, and multinucleated giant cells (MGCs). The foci are predominantly located perivascularly in the cortex, deep gray matter, and the white matter. The MGCs serve as the hallmark for HIVE, representing an HIV-1-specific cytopathic effect and are derived from HIV-1-mediated fusion of infected microglia and macrophages (Fig. 1A [31,71,103,150]). In their absence, the presence of HIV antigen or HIV nucleic acids has to be demonstrated either by immunohistochemistry (Fig. 1B) or by *in situ* hybridization, respectively (31). MGCs contain as many as 20 round or elongated, basophilic nuclei that usually are arranged at the periphery of the cell. There is no strong correlation between HIVE and the clinical stages of the HAD (71). The cytoplasm of MGCs is eosinophilic and appears densely stained in the center and vacuolated at the periphery. The cells are of monocyte/histiocyte lineage and include microglia and macrophages, as shown by immunohistochemical studies (32,37,150,151). The nucleic acids of HIV proteins are located within their cytoplasm (116). Electron microscopic analysis reveals retroviral particles either free in the cytoplasm or in cytoplasmic cisternae (32). Microglia/macrophages and MGCs are capable of HIV synthesis and, thus, constitute the major reservoir and vehicle for the spread of the virus (71,77,109,118,152).

Despite the introduction of highly active anti-retroviral therapy (HAART) with a greater life expectancy of infected individuals, epidemiological data

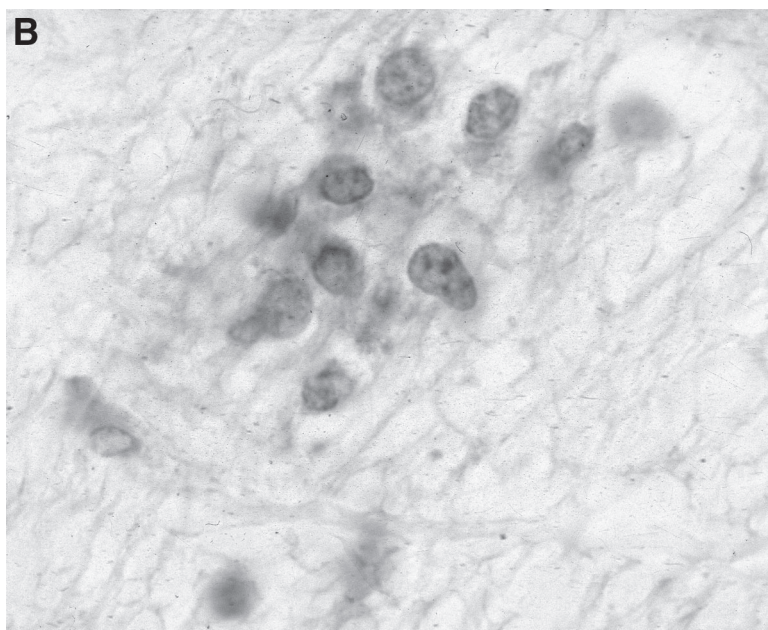
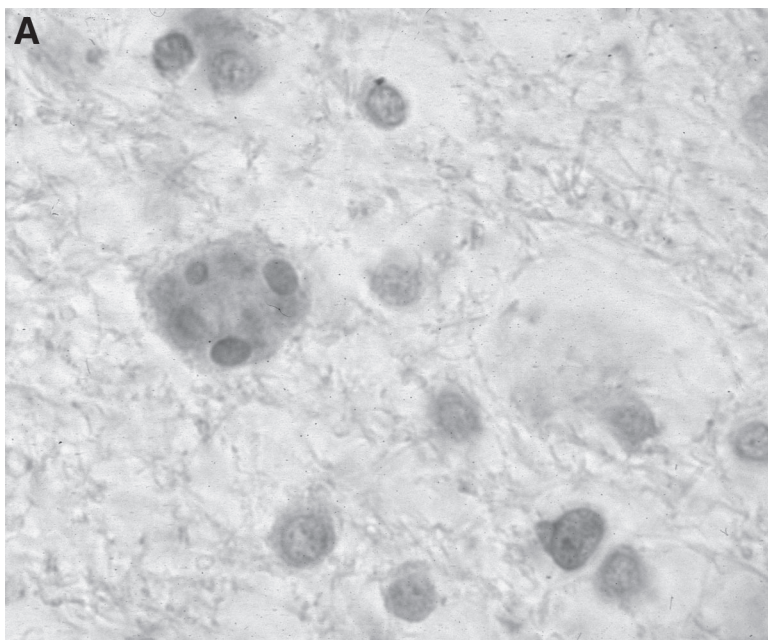


Fig. 1. (A), Multinucleated giant cell (cresyl violet). **(B),** HIV-1 antigen shown in a small gliomesenchymal nodule (immunohistochemistry for p24).

suggest that the prevalence of HIVE is on the rise (153–155). Additionally, a new variant of HIVE has emerged in the era of HAART as a severe leukoencephalopathy with significant perivascular infiltration of macrophages and lymphocytes, which is assumed to be the result of an exaggerated response from a newly reconstituted immune system (155). Synonyms previously used to describe HIVE include giant-cell encephalitis, multifocal giant-cell encephalitis, multinucleated cell encephalitis, and subacute encephalitis.

4.2. HIV-1 Leukoencephalopathy

HIV-1 leukoencephalopathy (HIVL) is characterized by diffuse damage to the white matter with myelin loss, reactive astrogliosis, macrophages, and MGCs. Only few, if any, inflammatory infiltrates are seen. In the absence of MGCs, the presence of HIV-1 antigen or HIV nucleic acids has to be demonstrated either by immunohistochemistry or by *in situ* hybridization (31). Axonal damage can be demonstrated with immunohistochemistry for β -amyloid precursor protein (156,157). *Progressive diffuse leukoencephalopathy* is another phrase previously used in describing HIVL.

HIVE and HIVL usually occur in the later stages of the AIDS infection. The differentiation between HIVE and HIVL can be confusing because in both cases the histological features have been described as MGCs in a focus with reactive astrocytes, microglia, and lymphocytes occurring in the white matter for HIVL and in both gray and white matter for HIVE. On the basis of our experience, the term HIVE should be used to describe the above-mentioned changes occurring in the gray matter only and HIVL to changes occurring in the white matter only. However, in most of the cases, myelin pallor usually is found around the gliomesenchymal nodule containing the MGCs. Furthermore, the analysis of 300 autopsy cases in our laboratory (Weis et al., unpublished observation) shows that the above-described changes (gliomesenchymal nodule with MGC) are found mainly in the cortex and deep gray matter but less frequently in the white matter, hence, necessitating a clear-cut delineation between HIVE and HIVL. Thus, the term HIVE should be reserved for changes in the gray matter and HIVL for changes in the white matter. If both gray and white matter are involved, the term HIVE/L should be used.

4.3. Lymphocytic Meningitis, Meningeal Lymphocytic Infiltrates, and Perivascular Lymphocytic Infiltration

Lymphocytic meningitis (LM) is characterized by a significant number of lymphocytic infiltrates in the leptomeninges (Fig. 2A). No opportunistic

pathogens are present in the meninges (31). LM should be distinguished from meningeal lymphocytic infiltrates (MLI), which show lymphocytes in lesser quantity infiltrating the leptomeninges than LM (Fig. 2B). Perivascular lymphocytic infiltration (PLI) is characterized by a significant number of lymphocytic infiltrates in the perivascular spaces of the brain tissue (Fig. 2C). No opportunistic pathogens are present in the perivascular brain tissue (31).

The relation of MLI and PLI to the HIV-1 infection is not yet clearly established, but it seems that lymphocytic infiltrates in the leptomeninges and in the perivascular spaces of the brain tissue constitute changes occurring in the early stages of the HIV-1 infection (*see* Section 14).

5. CHANGES PROBABLY ATTRIBUTABLE TO HIV-1

Vacuolar myelopathy (VM) and vacuolar leukoencephalopathy (VL) are changes that are probably attributable to HIV-1 (31). However, it is not yet clear whether these changes are caused by a direct effect of HIV-1 or constitute secondary changes.

5.1. Vacuolar Myelopathy

VM is characterized by numerous vacuolar myelin swellings and macrophages in multiple areas of the spinal cord (31,71,158–163). VM predominantly involves the dorsolateral spinal tracts (Fig. 3A,B). Some macrophages may be found in the vacuoles. The axon is at first unaffected, but it is damaged in the later stages of the disease (71,164).

The changes of VM might not be specific for HIV-1 because they can occur in the absence of HIV-1. However, in several studies HIV-1 has been shown to be present in spinal cord tissue showing VM using immunohistochemistry or *in situ* hybridization (38,163,165). Thus, a direct relationship between the presence of HIV-1 and the changes of VM can be drawn.

HIV-1 may rarely produce a MGC myelitis analogous to HIVE (71,161,163). Opportunistic infections and lymphomas of the spinal cord are uncommon (161,163).

5.2. Vacuolar Leukoencephalopathy

VL is characterized by numerous vacuolar myelin swellings in the central white matter. Some macrophages may be found in the vacuoles. VL is a rare condition (166).

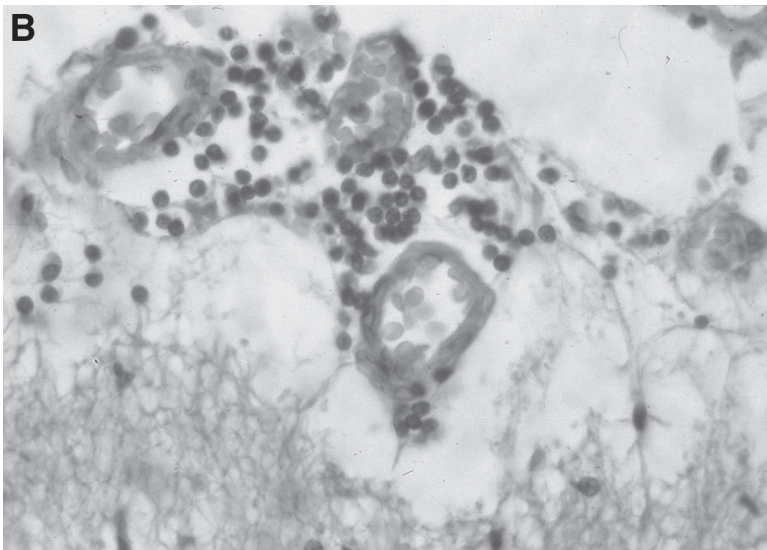
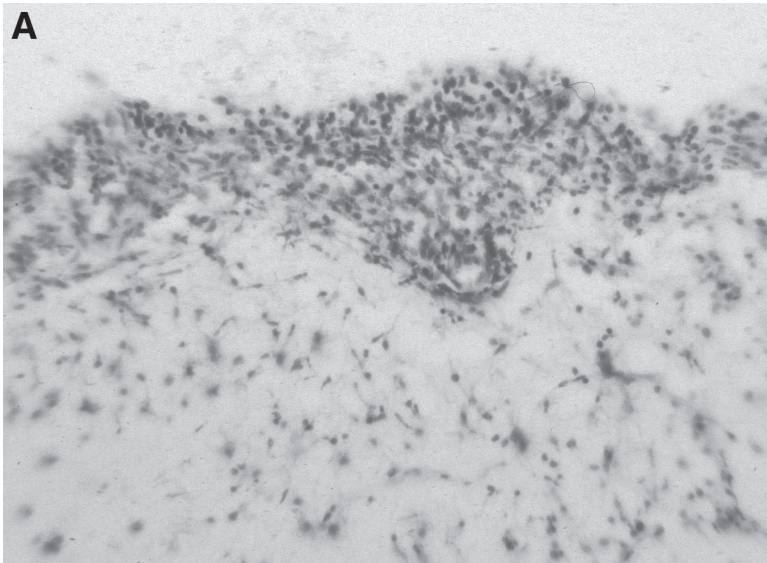


Fig. 2. (A), Lymphocytic meningitis (cresyl violet stain). **(B),** Meningeal lymphocytic infiltrates (Hematoxylin and eosin stain). **(C),** Perivascular lymphocytic infiltrates (Cresyl violet stain).



Fig. 2. (continued)

6. VIRAL INFECTIONS IN THE COURSE OF HIV-1 INFECTION

6.1. Cytomegalovirus Infection

In general, there are no gross anatomical changes in the brains of patients with AIDS who have cytomegalovirus (CMV) infection (167–171). In some cases, a necrotizing ependymitis with small areas of necrosis lining the ventricles is seen (172). Histologically, microglial nodules are seen scattered throughout the nervous system. Within these microglial nodules, large cells containing inclusion bodies are found (Fig. 4A). The microglial nodules located in the gray and white matter usually are not surrounded by a necrotic area, whereas along the periventricular spaces, CMV-containing cells are found within the necrotic areas. Figure 4B shows the immunohistochemical staining of an inclusion body. Diagnostic difficulties encountered are described in Sec-

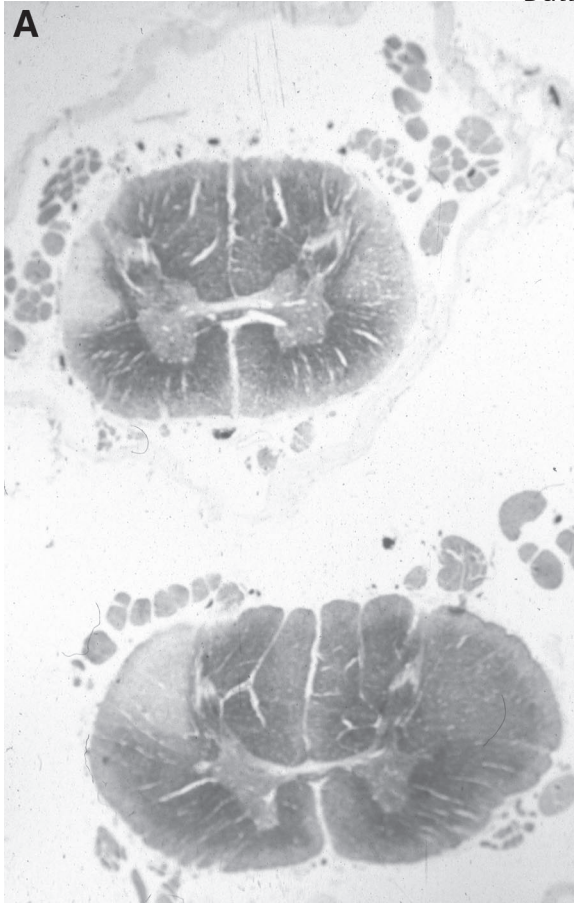


Fig. 3. Spinal cord showing vacuolar myelopathy of the dorsal tracts. **(A)**, Woelcke's myelin stain; **(B)**, Hematoxylin and eosin stain.

tion 12. The effects of CMV on the peripheral nervous system are reviewed elsewhere (173,174).

6.2. Progressive Multifocal Leukoencephalopathy

The causative agent in progressive multifocal leukoencephalopathy (PML) is papovavirus. Grossly, multiple areas of discoloration of the white matter are quite characteristic of PML (Fig. 5). Sometimes, the white matter may appear softened and mottled. Histologically, the diagnostic features for the presence of PML are (a) multiple foci of demyelination seen in the white matter consisting of loss of myelin sheaths; (b) enlarged, bizarre astrocytes; and

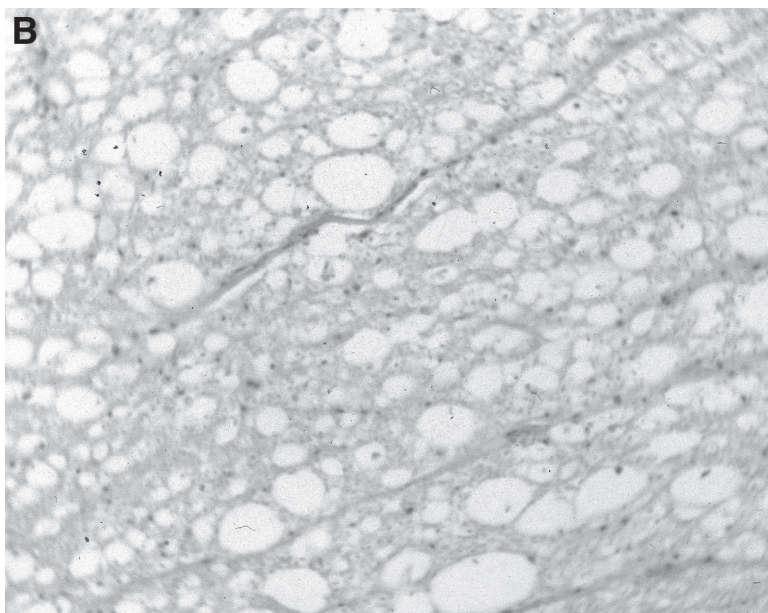


Fig. 3. (continued)

(c) intranuclear inclusions found within large swollen oligodendrocytes, the latter being the hallmark of PML (175–178).

7. PARASITIC INFECTIONS

7.1. *Toxoplasma gondii*

Macroscopically, lesions appear as zones of necrosis with an area of hyperemia and/or small hemorrhages surrounded by a poorly defined area of edema (Fig. 6A). Microscopically, large zones of necrosis are found in the brain tissue. Chronic inflammatory cell response may be seen in the area of necrosis, which might be intense and sometimes gives the appearance of a lymphoma. The infiltrates are composed of lymphocytes, plasma cells, and histiocytes. The necrotic lesions are surrounded by reactive astrocytes, activated microglia, and inflammatory cells. *Toxoplasma* may be found in two forms: encysted organisms (Fig. 6B) and tachyzoites found in small or larger collections diffusely distributed near the junctional area between necrosis and brain tissue (179,180). Toxoplasmosis restricted to the CNS can be pathogenetically classified as reactivation of a latent infection, whereas acute, systemic toxoplasmosis involving other organs is seen in patients who prob-

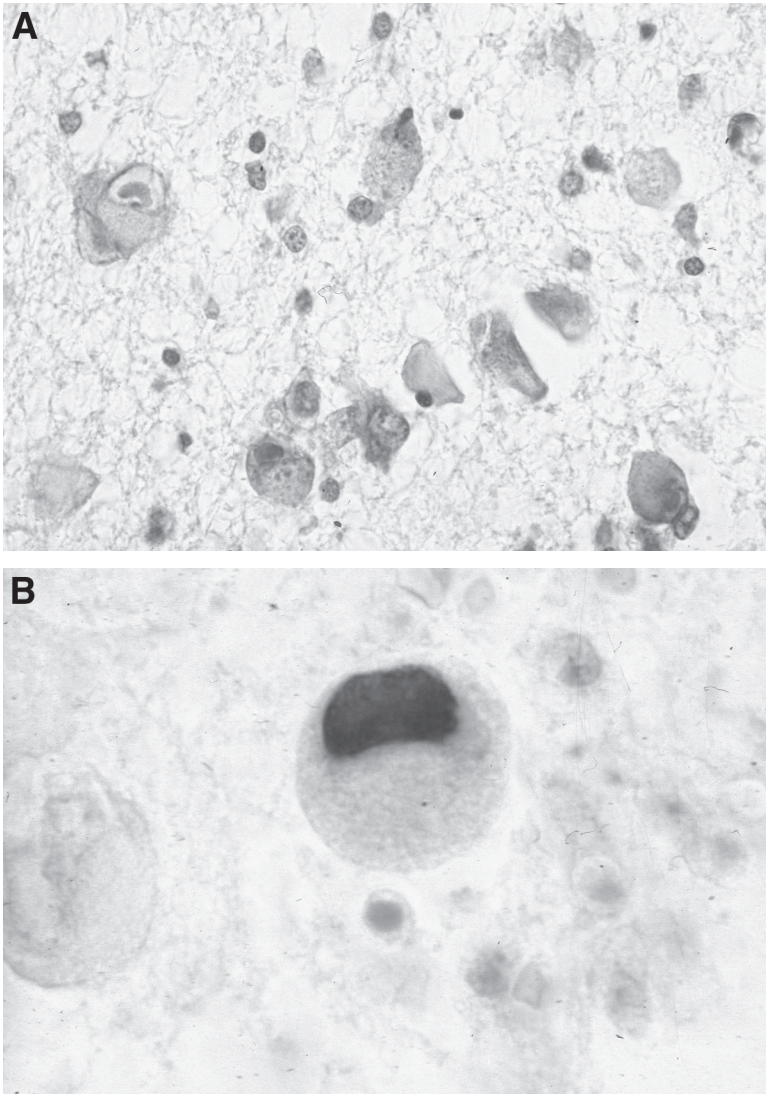


Fig. 4. Cytomegalovirus (CMV) infection. **(A)**, Cells with inclusion bodies (Nissl stain). **(B)**, Cytomegalic cell with inclusion body (immunohistochemistry for CMV).

ably acquired the infection during HIV-induced immunosuppression (181). Diffuse, necrotizing toxoplasma encephalitis with widespread, confluent areas of necrosis was observed primarily during the early period of the AIDS epidemic and restricted to patients who did not receive chemotherapy. In subse-

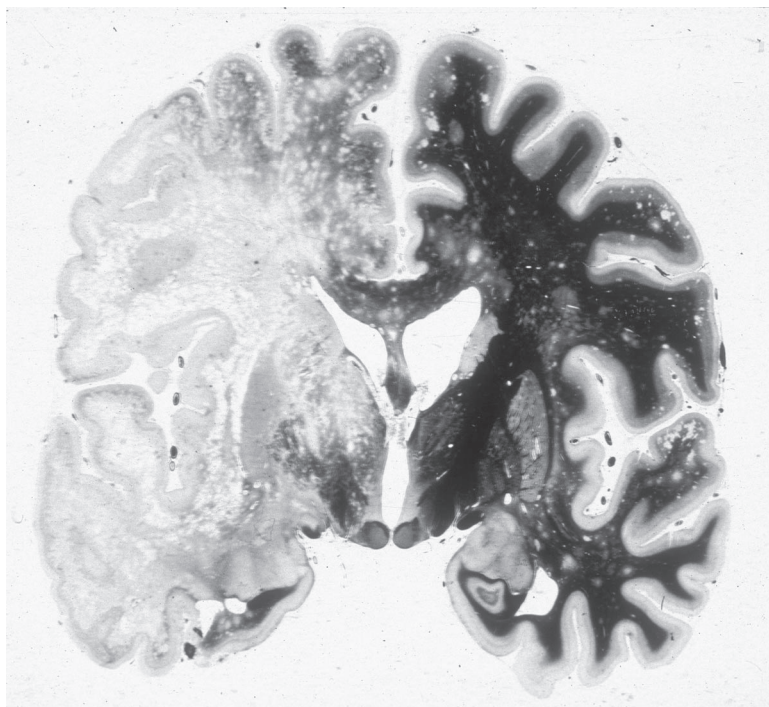


Fig. 5. Progressive multifocal leukoencephalopathy (Woelcke's myelin stain).

quent years, chronic, burnt-out lesions were observed. These are mainly composed of lipid-laden macrophages and immunocytochemistry for *Toxoplasma gondii* usually fails to detect the parasite (181).

8. FUNGAL INFECTIONS

8.1. *Aspergillus fumigatus*

Macroscopically, necrotizing lesions in various regions of the brain might be seen in patients with *Aspergillus* infection. *Aspergillus* mainly involves large vessels. Thus, the lesions are usually associated with hemorrhage and hemorrhagic infarctions in large areas of the brain, but can be less pronounced. Microscopically, the vessel walls are invaded by septated, branching hyphae. Thrombosis of the vessels and invasion of the tissue by the organisms are associated with necrosis (64,76).

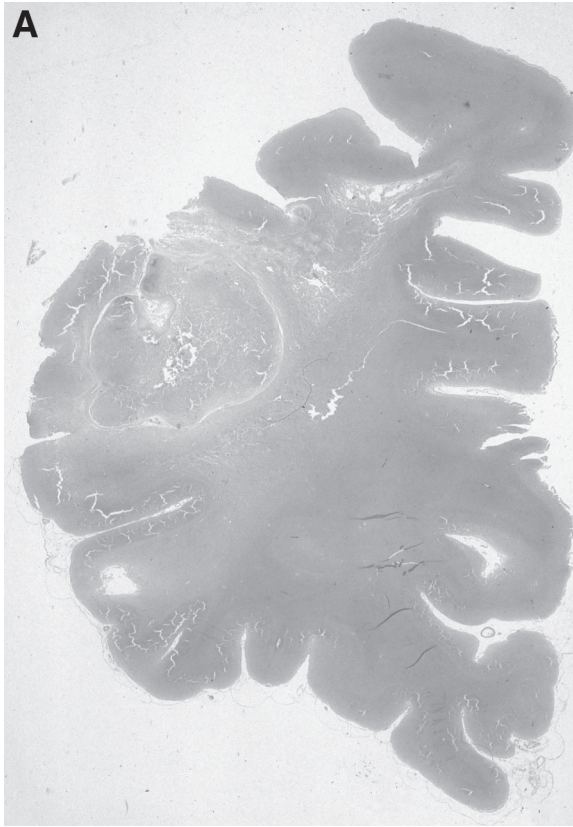


Fig. 6. *Toxoplasma gondii* infection. **(A)**, Large area of necrosis in the frontal lobe (hematoxylin and eosin stain); **(B)**, Encysted organisms in a gliomesenchymal nodule (cresyl violet stain).

8.2. *Candida albicans*

Nonspecific changes are found in the brain at gross anatomical examination. Occasionally, a mild to moderate edema with yellow softening of the brain tissue is noted. Histologically, multifocal microabscesses might be found containing polymorphonuclear, monocytic, and microglial cells sometimes surrounded by necrosis (139).

8.3. *Cryptococcus neoformans*

Macroscopically, the appearance of the brain lesions attributable to cryptococcus are diverse (11,182). Sometimes, no changes can be discerned, or

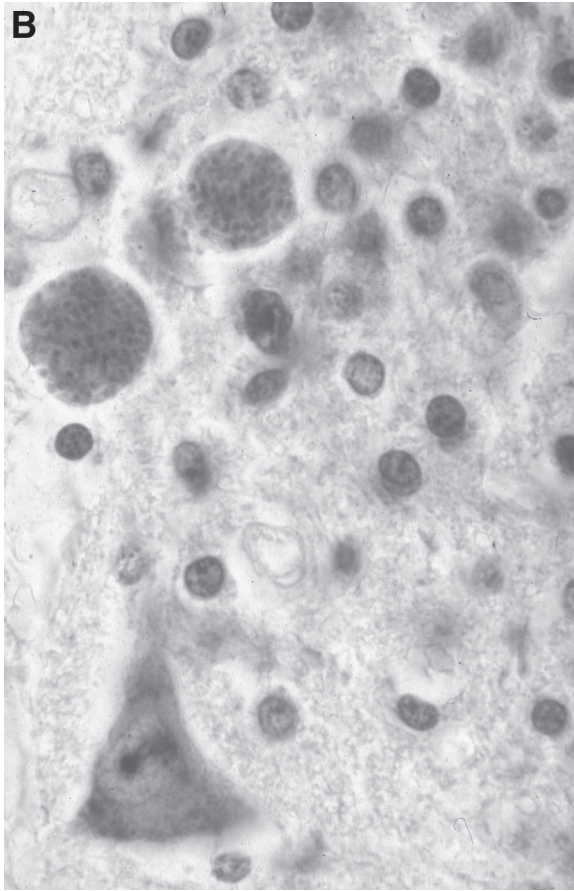


Fig. 6. (continued)

only small or large foci of gelatinous material may be seen either in the leptomeninges or within the brain parenchyma (Fig. 7). These gelatinous areas are histologically composed of thick mucin-positive capsules that contain the cryptococcus spores. There may be minimal inflammatory response in the neighborhood of the capsules (182).

Furthermore, a spectrum of various opportunistic diseases, for example, varizella-zoster virus (183,184), herpes simplex virus (185), neurosyphilis (186), tuberculosis (40,187), rabies (188), nocardiosis (189), and coccidioidomycosis (190) has been described in patients infected with HIV-1, but these are rare conditions.

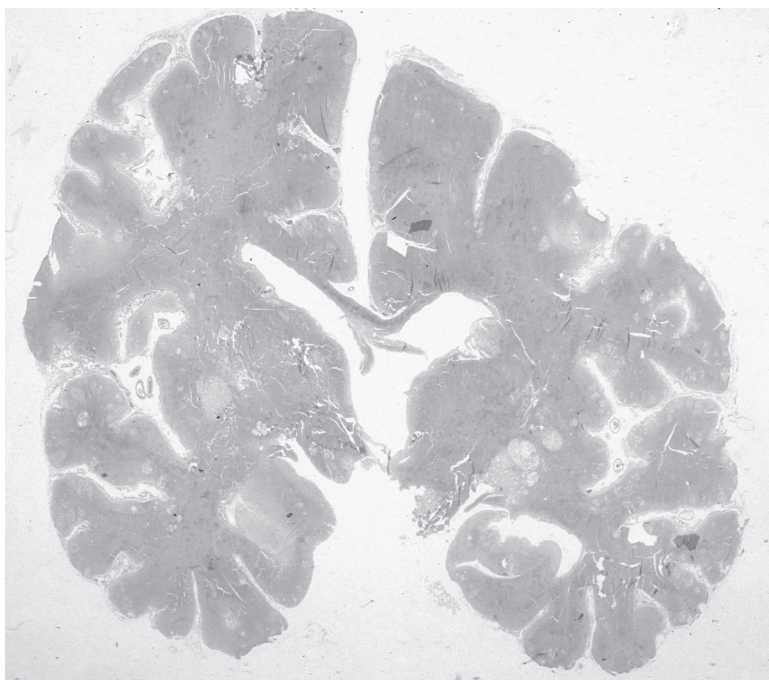


Fig. 7. *Cryptococcus neoformans* infection (Alcian blue stain).

9. NEOPLASIA IN THE COURSE OF HIV-1 INFECTION

9.1. Lymphomas

Lymphomas may occur as primary or secondary lesions; primary lymphoma is most commonly seen in AIDS brains (191,192). Multifocal mass lesions that may be partially necrotic, partially hemorrhagic can be macroscopically localized anywhere in the brain. The tumors are composed of a high number of large, pleomorphic malignant cells with cleaved and folded nuclei and a varying amount of cytoplasm (Fig. 8). Most of the lymphomas are non-Hodgkin's B-cell tumors (193–196). The infiltration of the tumor consists either of single cells or of cells that diffusely infiltrate the adjacent tissue. Diffuse infiltration of the vessel walls can be noted.

Brain tumors (excluding lymphomas) occurring in patients infected with HIV-1 have only occasionally been described (197) but must be considered in the differential diagnosis of an intracranial space-occupying lesion in this population.

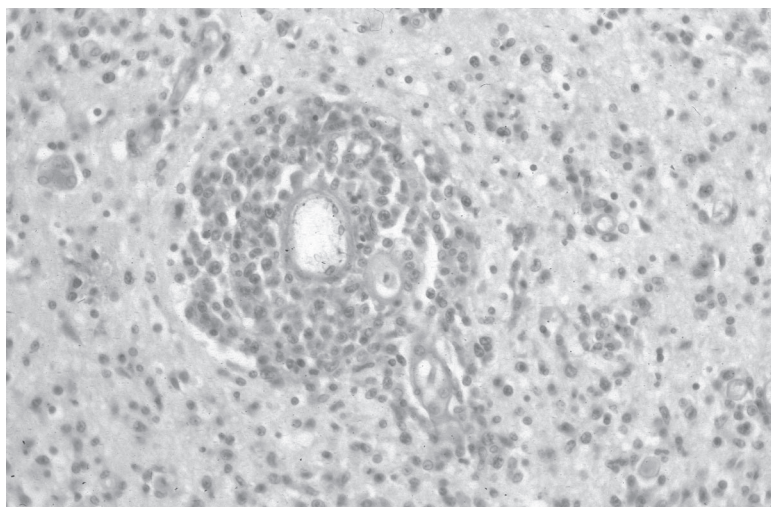


Fig. 8. Polymorphic non-Hodgkin's B-cell lymphoma (hematoxylin and eosin stain).

9.2. Kaposi Sarcoma

Intracerebral Kaposi sarcoma, which is frequently present in peripheral organs, has only been found in rare cases (198).

10. FREQUENCY AND TOPOGRAPHICAL DISTRIBUTION OF NEUROPATHOLOGICAL CHANGES

10.1. Frequency of Neuropathological Changes

The frequency of neuropathological changes seen in the brains of patients infected with HIV-1 by different research groups is shown in Table 3 (Weis et al., unpublished data and refs. 6,8,14,16,29,32,33,35,37–43,47–49,51,52,55,57,60,61,63–65,69,70,74–76,80,139,141,143,151,194,199–202).

Table 3 shows a high variation in the frequency of the different neuropathological entities varying among the different research groups. These differences in the frequency and the occurrence of the various neuropathological changes might be caused by several factors that are given in the next section.

10.1.1. Sample Size

Sample size was quite small in the early reports. In recent reports the sample size ranges between 150 and 200 cases. However, although the variability might be reduced by large sample sizes, there still exist intercontinen-

Table 3

Comparison of the Reported Frequencies of Neuropathological Changes in Brains of Patients Infected With HIV-1 (in %)

City/ Country	Year	<i>n</i>	HIVE	HIVL	CMV	PML	TOXO	LYM	Ref- erence
Miami	1984	52	5.7	nip	3.8	3.8	30.7	1.9	41
NYCor	1984	40	nip	nip	37.5	2.5	12.5	7.5	65
New Jersey	1985	8	0.0	nip	12.5	12.5	50.0	0.0	74
UCSF	1985	128	27.3	nip	nip	1.6	14.1	8.6	139
UCLA	1986	89	^a	nip	15.7	6.7	6.7	4.5	29
NYCor	1986	70	28.1	nip	24.3	nip	nip	nip	42
NYCor	1986	153	28.2	nip	26.1	2.0	10.5	5.9	43
Sao Paulo	1986	22	nip	nip	0.0	0.0	18.2	9.1	141
Bronx	1987	53	9.4	nip	11.3	nip	9.4	5.6	37
Boston	1987	30	90.0	nip	6.6	3.3	16.6	6.6	151
USC	1987	100	nip	nip	17.0	nip	5.0	13.0	69
AU/I	1987	100	26.0 ^b	25.0 ^b	18.0	5.0	17.0	6.0	32
Frankfurt	1987	28	60.7	nip	17.8	3.6	28.6	7.1	199
France	1988	40	37.5	nip	20.0	5.0	47.5	2.5	55
CH	1989	135	15.5	nip	10.4	6.6	25.9	6.6	39
Mu/I	1989	51	50.9 ^c	nip	5.8	7.8	19.6	5.8	35
Denmark	1989	43	nip	nip	18.6	2.3	9.3	6.9	57
Oxf/Lon-hem	1989	11	9.1	nip	0.0	0.0	0.0	nip	80
Ox/Lon-nonhem		31	25.8	nip	9.7	9.7	22.6	nip	80
London	1989	26	23.0	nip	7.6	nip	7.6	11.5	60
Genoa (I)	1989	22	22.7	nip	13.6	18.2	31.8	13.6	52
UCLA	1989	158	10.1	nip	17.1	5.1	7.6	3.2	75
Japan	1991	15	26.6	nip	20.0	6.6	13.3	13.3	51
New York	1991	111	nip	nip	nip	nip	nip	13.5	194
Texas	1991	141	19.8	nip	16.3	2.8	3.5	6.4	33
Bronx	1991	221	25.8	nip	12.7	5.4	13.1	5.4	38
Sao Paulo	1992	252	10.7	nip	7.9	0.8	34.1	4.0	47
Vancouver	1992	39	43.5	nip	23.1	2.6	17.9	28.2	48
Milan	1993	202	27.7 ^d	19.8	nip	nip	nip	nip	200
Untreated		120	29.2	27.5	nip	nip	nip	nip	200
Zidovudine- treated		82	25.6	8.5	nip	nip	nip	nip	200
USC	1993	400	35.7 ^e	8.0 ^e	7.7	nip	8.2	5.7	70
Düsseldorf	1993	70	17.1	2.8	8.5	2.8	21.4	8.6	64
Berlin	1995	200	33.5 ^f	nip	13.0	8.0	34.0	14.0	61
Drug abusers		37	59.5	nip	8.0	16.0	43.0	11.0	61

Table 3
(continued)

City/ Country	Year	<i>n</i>	HIVE	HIVL	CMV	PML	TOXO	LYM	Ref- erence
Homo/ bisexuals		150	28.0	nip	13.0	7.0	35.0	16.0	61
Hamburg	1996	28	10.7	nip	3.6	nip	3.6	nip	8
New York ^g	1996	471	10.6	nip	2.7	1.9	4.7	3.8	6
Asymptomatic		123	0.0	nip	0.0	0.0	0.0	0.0	6
Early stages		127	16.5	nip	0.0	0.0	0.0	0.0	6
Full-blown AIDS		221	13.1	nip	5.9	4.1	10.0	8.1	6
UK	1997 ^h	349							
Homo/bisexual		238	21.4	—	20.2	6.7	8.8	13.9	49
Injecting drug users		53							
Blood recipient		40	17.5	—	12.5	2.5	5.0	5.0	49
Heterosexual		18							
Poland	1997	100	22.0	7.0	23.0	11.0	16.0	10.0	63
India	1998	85	0.0	—	7.0	—	13.0	—	40
Poland	1998	172	nip	nip	22.7	9.3	16.3	nip	76
International	1998	1087	26.4 ⁱ	—	16.4	5.3	16.0	11.1	14
Baltimore		293	24.6	—	18.7	3.4	7.5	10.2	14
Newark		115	13.0	—	5.2	1.7	13.0	2.6	14
Edinburgh		81	44.4	—	13.6	3.7	8.6	16.0	14
London		283	22.3	—	18.4	4.9	9.5	11.3	14
Paris		243	30.0	—	16.5	10.7	38.7	13.6	14
Budapest		72	38.9	—	19.4	4.2	12.5	13.9	14
UCSD	2000	390	26.3	nip	22.3	2.9	2.5	8.4	143
Austria	2000	450	8.4	4.4	16.9	6.7	19.1	8.0	16
1984–1992		190	11.5	2.6	17.4	5.7	24.0	6.3	16
1993–1995		162	5.6	6.2	20.0	8.7	20.4	11.2	16
1996–1999		98	8.0	5.0	11.0	5.0	8.0	6.0	16
pre-HAART, <1996 ^j		352	8.5	4.3	18.5	7.1	22.2	8.5	16
UCSD	2003	151	38.4	nip	16.5	5.9	2.6	13.2	201
Before 1995		62	25.8	nip	16.1	6.4	6.4	19.3	201
After 1995		89	43.8	nip	16.8	5.6	0.0	8.9	201
France	2003	23	17.4	nip	8.7	17.4	13.0	13.0	202
Munich		300	11.1	3.2	13.0	0.8	13.0	7.1	Weis unpub- lished

Table 3
(continued)

^aAuthors report microglial nodules present in 62.9% of the cases without further specification.

^b13% of the cases with HIVE only, 12% of cases with HIVL only and 13% of cases with HIVE + HIVL.

^cSubacute microglial encephalitis with and without multinucleated giant cells.

^dThe combination of HIVE + HIVL gave the following results: 6.4% of the total sample, 8.3% in the untreated group, and 3.6% of the zidovudine treated group.

^eNodular encephalitis defined as gliomesenchymal cell or microglial nodules and diffuse leukoencephalopathy defined as white matter pallor, demyelination, spongiform change, macrophages, and astrogliosis. Note that there is no specific mention of multinucleated giant cells.

^fHIV-related encephalopathy defined as vacuolization or spongy changes and astrocytosis in subcortical white matter and, occasionally, in gray matter. Note that there is no specific mention of multinucleated giant cells. MGCs were seen in 17.5% of the cases.

^gA total of 221 persons from this study were used in a paper published by Kure et al. (38).

^hHIVE and HIVL given together as HIVE/L.

ⁱDiagnoses were given as HIVE/L.

^jThis category was created by the authors of the present paper.

nip, no information provided; NYCor, New York Cornell University; UCSF, University of California, San Francisco; UCLA, University of California, Los Angeles; USC, University of Southern California; AU, Austria; I, Italy; CH, Switzerland; Mu, Munich; Oxf/Lon, Oxford/London; UCSD, University of California, San Diego.

tal differences (e.g., United States, European countries), differences between countries (e.g., Switzerland, Austria, Italy, Germany) and differences between various regions within one country.

10.1.2. Composition of the Sample

The composition of the sample according to age (only adults), race (blacks, Caucasians), ethnic origin (Haitians, Hispanics), and risk group (drug addicts, hemophiliacs, homosexuals) might have an influence on the observed differences in the frequency of changes. However, there exists, until now, no paper dealing systematically with this problem.

10.1.3. Source of the Brains Analyzed

In our experience, differences result if brains are derived from Institutes of Pathology or from Institutes of Forensic Medicine. Brains derived from Institutes of Pathology show changes mainly seen in the late stages of the disease. Brains derived from Institutes of Forensic Medicine (composed mainly of brains from autopsied persons who committed suicide or had lethal accidents or died from other non-natural causes) mainly show changes seen in the

Table 4
*Frequency of Lesions Encountered in the Late Stages of HIV-1 Infection
as Related to Their Topographical Localization in the Brain*

Region	HIVE	HIVL	CMV	PML	TOX	CRY	ASP	LYM
Frontal	8.3	2.9	3.4	1.0	8.3	1.9	0.0	5.8
Parietal	3.2	1.6	3.2	1.1	7.4	2.1	0.0	1.6
Temporal	4.7	0.5	6.7	1.0	6.2	1.6	0.5	3.6
Occipital	2.0	1.5	3.9	1.0	7.1	1.5	0.5	4.1
Basal ganglia	5.7	–	7.8	–	8.8	1.6	0.5	4.7
Thalamus	4.9	–	7.4	–	2.5	1.8	0.0	3.1
Cerebellum	3.0	0.0	7.1	0.0	6.6	2.0	0.5	3.0
Mesencephalon	3.7	0.0	3.7	0.5	3.7	1.6	0.5	4.3
Pons	2.6	0.0	5.7	0.0	3.1	1.5	0.0	5.2
Medulla oblongata	2.6	0.0	6.7	0.0	3.1	1.5	0.5	4.1

HIVE, HIV-1 encephalitis; HIVL, HIV-1 leukoencephalopathy; CMV, cytomegalovirus encephalitis; PML, progressive multifocal leukoencephalopathy; TOX, *Toxoplasma gondii* encephalitis; CRY, *Cryptococcus encephalitis*; ASP, *Aspergillus fumigatus* encephalitis; LYM, lymphoma.

early stages of the disease. However, data regarding the time of seroconversion as well as the presence of clinical and neurological signs are often lacking.

10.1.4. Bias in Sampling

The number of patients infected with HIV-1 who undergo an autopsy after death might also have a considerable influence. Most of the time, clinicians are interested to see only the brains from interesting clinical cases to be analyzed by a pathologist/neuropathologist and insist for an autopsy, whereas “uninteresting cases” might not undergo autopsy.

10.1.5. Diagnostic Criteria

The diagnostic criteria may play a fundamental role. The use of immunohistochemistry or *in situ* hybridization to render the diagnosis of HIV encephalitis is not performed in all laboratories dealing with brains infected with HIV-1, thus limiting the reliability of this diagnosis.

10.2. Topographical Distribution of Neuropathological Changes

The topographical localization of the various neuropathological changes has not been described systematically until now. Table 4 shows the results of

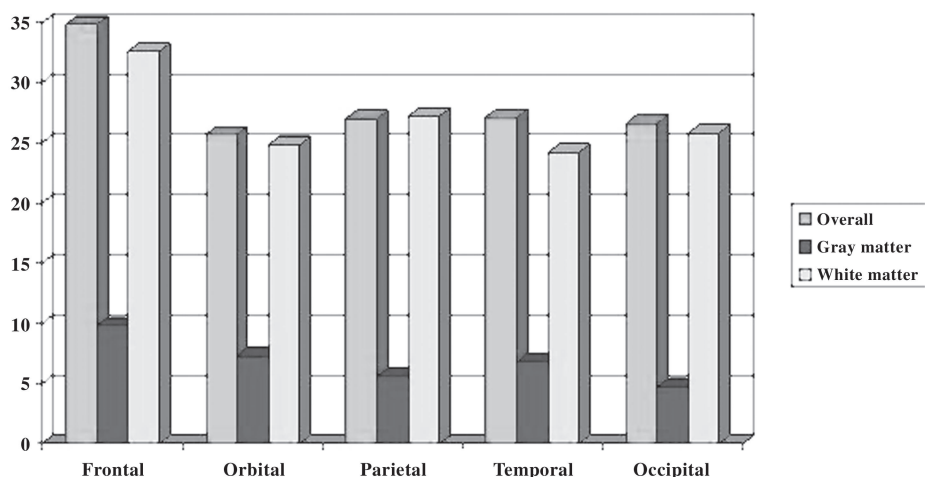


Fig. 9. Frequencies expressed as percent of cases of p24-immunopositive cells in various cortical regions.

a study in our laboratory of 300 cases. No consistent pattern for the distribution of the various neuropathological changes can be discerned (Weis et al., unpublished data).

11. IMMUNOHISTOCHEMICAL DEMONSTRATION OF HIV-1: FREQUENCY AND TOPOGRAPHY

The incidence and distribution of HIV-1 antigen, as shown immunohistochemically with an antibody against the glycoprotein p24, is shown in Fig. 9 (Weis et al., unpublished data). Data derived from other systematic analyses are, thus far, lacking.

12. DIAGNOSTIC DIFFICULTIES: UNSPECIFIED NODULAR ENCEPHALITIS

In many of the brains of patients infected with HIV-1, the only histological finding is the presence of gliomesenchymal nodules (GMNs; Fig. 10). GMNs, which are composed of microglia, macrophages, and reactive astrocytes, are found in the gray and white matter. The diagnostic problem is a result of the fact that there are neither MGCs present in the nodules nor large cells containing inclusion bodies. The differential diagnosis for GMNs includes HIV-1 encephalopathy/leukoencephalopathy, CMV encephalitis or *Toxoplasma*

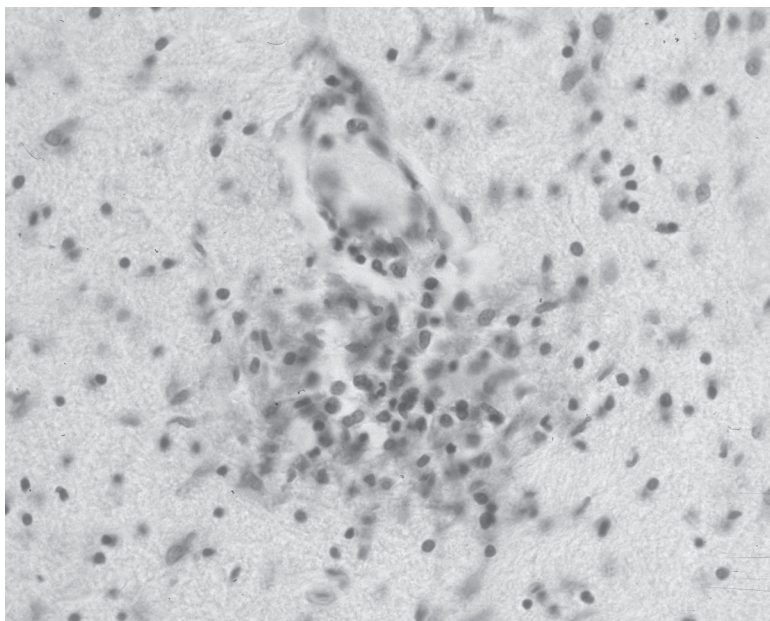


Fig. 10. Unspecified nodular encephalitis (cresyl violet stain).

gondii encephalitis. As proposed by Budka et al. (32), these nodules are very suspicious to contain CMV when further serial sectioning is performed. In our experience, immunohistochemistry for CMV is of limited value. As described by Schmidbauer et al. (169), improvement may be provided by *in situ* hybridization, which might yield a positive result in cases with negative immunohistochemistry. In most of the cases, there is no immunohistochemical staining for gp41 or p24. Thus, the term “unspecified nodular encephalitis” is used in the diagnosis of these cases. Complete clarification is sometimes not possible.

13. NEUROPATHOLOGICAL CHANGES IN CHILDREN INFECTED WITH HIV-1

Children born to mothers who are infected with HIV-1 also are infected by the virus 10 to 39% of the time (203). These children develop symptoms before the age of 2 years. Approximately 30% of children infected with HIV-1 develop opportunistic infection or HIV-1 encephalopathy within the first year of life. Brain growth is impaired, leading to intellectual deficiency. The macroscopical analysis frequently shows brains that are too small for the child's age, either as microcephaly and/or brain atrophy (203,204). The most com-

mon finding in the brains of children infected with HIV-1 is mineralization/calcification of predominantly small vessels in the basal ganglia found in 95% of the cases (203,206). Myelin pallor and gliosis are noted changes of the white matter and occur in 78% of the cases (203,205). Inflammatory infiltrates and/or MGCs are seen in 62% of children infected with HIV-1 (203,205). HIV-1 infection in fetal brains usually is below the limits of detection of immunocytochemistry, but HIV-1 detection is usually successful with polymerase chain reaction (PCR [38]). In contrast to adults, opportunistic infections are comparatively uncommon in the pediatric population (203). For details, the reader is referred to some articles and textbooks (38,203,205–217).

14. NEUROPATHOLOGICAL CHANGES IN EARLY STAGES OF HIV-1 INFECTION

Gray et al. described early brain changes in 11 HIV-1 seropositive, non-AIDS cases in comparison with 11 HIV-1 seronegative heroin addicts (218). Cerebral vasculitis was significantly more frequent and marked in HIV seropositive cases and was often associated with lymphocytic meningitis. Granular ependymitis, myelin pallor with reactive astrocytosis, and microglial proliferation also were more frequent and more severe in HIV seropositive cases. Immunohistochemistry for HIV antigens was negative. Later, these authors interpreted their results as being related to the occurrence of a usually asymptomatic and transient immunopathological reaction coinciding with early HIV infection of the nervous system (219). This immunological process includes an inflammatory T-cell reaction with vasculitis and leptomeningitis and immune activation of brain parenchyma with an increased number of microglial cells, upregulation of major histocompatibility complex class II antigens, and local production of cytokines (220,221). Some co-authors of the Gray et al. (220) review articles reported separately their findings on 36 brains of asymptomatic individuals (222). They detected HIV-1 DNA in 17 cases (47%), astrogliosis in 34 cases (94%), microgliosis in 31 cases (86%), and meningitis in 11 cases (31%). One has to stress that astrogliosis and microgliosis were only rated, but no quantitative data were provided. Furthermore, the authors demonstrated highly expressed cytokines (tumor necrosis factor- α , interleukin [IL]-1, -4, -6). They used these findings to explain neuropathologic changes and neuronal damage confirmed by the demonstration of apoptotic neurons by *in situ* end labeling (222). Interestingly, it was stated in the review article by this group (220) that neuronal death is only observed in the late stages of the HIV-1 infection. The same group also reported having detected HIV-1 DNA by PCR in all HIV-1-positive asymptomatic cases and

by *in situ* PCR in astrocytes and endothelial cells, in addition to microglial cells, in 6 of 18 HIV-1-asymptomatic patients (223). The validity of the studies reporting the presence of HIV-1 in various cell types other than macrophages was questioned recently (224).

In an ongoing study of 44 males in our laboratory representing early stages of HIV-1 infection, PLIs or MLIs were found in 70% of the cases. PLI alone was observed in 61% of the cases, MLI alone in 43% of the cases, and the combination of PLI and MLI in 34% of the cases (Weis et al., unpublished data). Sometimes, the extent of lymphocytic infiltrates in the meninges is more than normal but not enough to render a diagnosis of LM. Therefore, we apply the term MLI to describe these changes. Both changes, PLI and MLI, may occur together or separately in the brains of patients with HIV-1 at the early stages of infection. The histopathological changes of vasculitis and leptomeningitis, as reported by Gray et al. (218–220), are rarely seen in the late stages of full-blown AIDS. In our study of 300 cases, we could never identify these changes either in the pre-AIDS stages or the late stages of the infection. Our data are in accordance with findings published by Kibayashi et al. in 1996 on 123 asymptomatic carriers and 127 persons with the early stages of AIDS (6). They found lymphocytic infiltration of the meninges in 24.4% and of the perivascular spaces in 28.5% of the asymptomatic carriers, whereas these respective changes were seen in 11.8% and 11% of the early stage patients.

15. NEUROPATHOLOGICAL CHANGES IN THE HAART ERA

In 1995/1996, HAARTs that combine nucleoside reverse transcriptase inhibitors (NRTI) and protease inhibitors (PIs) were introduced in the treatment of patients infected with HIV-1. NRTIs specifically inhibit the viral reverse transcriptase enzyme necessary for DNA chain elongation of the virus. The non-nucleoside reverse transcriptase inhibitors (NNRTI) are similar to the NRTIs in their mechanism of action; however, their effects on reverse transcriptase are by noncompetitive means. The PIs prevent the production of active virus by interfering with the cleavage of proteins necessary for viral assembly (225).

The frequency of HIV-1-related CNS diseases has been reduced by these combinations of antiviral agents, in part through the reduction of both viral load in the blood and continuous penetration of virus into the brain (226), although this therapy will probably not be sufficient to completely abolish any neurological risk. HIV-1-related dementia also depends on the intensity of glial cell activation in the CNS, which induces reactivation of latent infection in these cells, and on the secretion of soluble inflammatory mediators

acting on nearby neurons. During the HAART era, patients who test positive for HIV live longer (144). The median survival after AIDS increased from 19.6 months for those patients diagnosed with AIDS in 1993–1995 to 39.6 months for those diagnosed in 1996–2000 in an Australian patient group (227). The proportion of deaths that followed an HIV-related disease decreased by 23% annually; in contrast, there was a 32% yearly increase in the proportion of deaths caused by known causes other than HIV-related or suicides (144). The higher prevalences of cirrhosis and arteriosclerosis suggest that entities not targeted by antiretroviral reconstitution of immunity will play an increasingly important role in HIV-related mortality in the future (140).

Maschke et al. (228) compared the incidence and prevalence in two groups of 563 patients seen between 1995–1996 and 1997–1998. Significantly, more patients received HAART in 1997/1998 and the mean CD4⁺ cell count was significantly higher in this group. The prevalence of HIV-associated dementia and HIV-associated polyneuropathy were significantly lower in 1997–1998, and the incidence of toxoplasma encephalitis decreased from 5.7% in 1995–1996 to 2.2% in 1997–1998. In a prospective, single-center study of all consecutive patients infected with HIV who presented with focal brain lesions observed between January 1991 and December 1998 ($n = 281$), Ammassari et al. (229) reported the following results: during the HAART period, patients were less likely to be male, contracted HIV more often through heterosexual exposure, had fewer previous AIDS-defining events, received anti-toxoplasma prophylaxis less frequently, and had a CD4⁺ lymphocyte count 2.5 times higher. They found a relevant decline of primary CNS lymphoma, whereas the frequency of toxoplasma encephalitis decreased during the pre-HAART period and was stable afterward. A slight increase was observed over time for PML. Focal white-matter lesions without mass effect or contrast enhancement became the focal brain lesions observed most frequently. In an Australian patient group of 4351 AIDS cases, the proportion of patients with ADC increased from 5.2% in 1993–1995 to 6.8% in 1996–2000. The median survival after ADC increased from 11.9 months in 1993–1995 to 48.2 in 1996–2000. Most striking was the increase in survival among those patients with ADC and a CD4 cell count below 100×10^6 cells/L at diagnosis (5.1 months in 1993–1995 to 38.5 months in 1996–2000 [227]).

Larger cohort autopsy studies of HIV-infected patients over longer time periods suggest that, despite the beneficial effects of modern anti-retroviral combination therapy, involvement of the brain in AIDS subjects continues to be a frequent autopsy finding (16,55,143,153,154,230).

Vago et al. (230) recently reviewed 1597 consecutive autopsies of HIV-1-positive patients performed between 1984 and 2000 and divided into four

Table 5
Incidence of HIVE/L and Opportunistic Infections Under
Different Therapeutic Regimes

Year infections	<i>n</i>	Therapy	HIVE/L	Opportunistic
1984–1987	119	None	53.8	40.3
1988–1994	1116	Mono	32.2	46.8
1995–1996	256	Dual	17.9	42.6
1997–2000	106	Triple	15.1	42.5

From ref. 230.

time periods on the basis of the therapeutic regimens available: 1984–1987: no therapy; 1988–1994: monotherapy (zidovudine); 1995–1996: dual combination therapy with NRTIs; and 1997–2000: triple combination therapy, including two NRTIs and at least one PI or non-NRTI (230). They reported the results for HIV-related lesions (including HIVE and HIVL) and opportunistic infectious diseases (without specifying the causative agent) as shown in Table 5.

The results of other autopsy studies with more detailed information of neuropathological entities are listed in Table 6 (16,55,143,202). The most consistent feature in it is its inconsistency of results. Thus, no consistent trend for the frequency of HIV-1-related changes is seen. In one study the frequency decreases, whereas in a second study it remains stable but increases dramatically in a third study. The frequency of CMV was reduced in two of three studies. PML and non-Hodgkin's lymphomas were increased in frequency in one study, whereas the frequency was unchanged in two studies. In all three studies, the frequency of toxoplasma encephalitis was significantly reduced.

Gray et al. speculated that the overall decrease in incidence of cerebral toxoplasmosis, CMV encephalitis, and HIVE was the result of successful treatment (202). They also described a new variant of HIVE characterized by severe leukoencephalopathy with intense perivascular macrophage and lymphocytic infiltration, possibly the result of an exaggerated response from a newly reconstituted immune system. Furthermore, they detected chronic "burnt-out" forms of HIVE as well as varicella zoster virus encephalitis, toxoplasmosis, and PML, possibly associated with prolonged survival, in which neither inflammation nor organisms, could be detected.

In contrast, Langford et al. suggested that the increasing resistance of HIV strains to antiretrovirals led to the resurgence in the frequency of HIVE and HIVL (201). HIVE and HIVL in AIDS patients failing HAART is charac-

Table 6

Frequencies of Various Neuropathological Changes in the Pre-HAART Era Compared With the HAART Era (in %; n = sample size)

Author (year) (Reference)	n	HIVE	HIVL	CMV	PML	TOX	LYM
Gray et al. (1988) (55) pre-HAART	40	37.5	nip	20.0	5.0	47.5	2.5
Gray et al. (2003) (202) ^a HAART	23	17.4	nip	8.7	17.4	13.0	13.0
Jellinger et al. (2000) (16) pre-HAART	352	8.5	4.3	18.5	7.1	22.2	8.5
HAART	98	8.0	5.0	11.0	5.0	8.0	6.0
Langford et al. (2003) (201) pre-HAART	62	25.8	nip	16.1	6.4	6.4	19.3
HAART	89	43.8	nip	16.8	5.6	0.0	8.9

^aFrequencies for the pre-HAART could not be calculated because of the lack of original data in this publication.

HIVE, HIV-1 encephalitis; HIVL, HIV-1 leukoencephalopathy; CMV, cytomegalovirus encephalitis; PML, progressive multifocal leukoencephalopathy; TOX, *Toxoplasma gondii* encephalitis; LYM, primary non-Hodgkin's lymphoma; nip, no information provided.

terized by massive infiltration of HIV-infected monocytes/macrophages into the brain and extensive white matter destruction. This condition might be attributable to interactions of anti-retrovirals with cerebrovascular endothelium, astroglial cells, and white matter of the brain. These interactions might lead to cerebral ischemia, increased BBB permeability and demyelination. The authors postulate that potential mechanisms of such interactions include alterations in host cell signaling that may result in trophic factor dysregulation and mitochondrial injury (201).

Future studies have to address the above-mentioned points by systematic investigation of the various cell systems (e.g., neurons, astrocytes, microglia, oligodendrocytes) in much larger samples. Before reaching final conclusions about the changed pattern of neuropathological changes in the HAART era, one has also to prove that these reported divergent results are not due to a sampling error, for example, the most interesting cases undergo autopsy, whereas the less interesting cases are not autopsied.

Table 7

Incidence of Cerebral Infarcts and Cerebral Hemorrhages in Larger Autopsy Series of Patients Infected With HIV-1

Authors (Year) (Reference)	Ischemic stroke	Intracranial hemorrhage
Anders et al. (1986) (29)	14.6% (13/89)	5.6% (5/89)
Berger et al. (1990) (231)	7.2 % (13/181)	nip
Budka et al. (1987) (32)	nip	11.0% (11/100)
Burns et al. (1991) (33)	7.8% (11/141)	5.7% (8/141)
Jellinger et al. (2000) (16)	5.6–6.3%	1.2–4.0%
Kieburz et al. (1993) (235)	30% (14/70)	nip
Kure et al. (1991) (38)	19.5% (43/221)	5.4% (12/221)
Mizusawa et al. (1988) (236)	29% (24/83)	6% (5/83)
Moskowitz et al. (1984) (41)	3.9% (2/52)	8.0% (4/52)
Rhodes et al. (1993) (70)	9.0% (36/400)	5.8% (23/400)

nip, no information provided.

16. CEREBROVASCULAR COMPLICATIONS

Several case reports and larger autopsy series described cerebrovascular complications in patients with HIV-1 infection (16,29,32,33,38,41,47,70,231–237). Cerebrovascular disease has been reported to occur in about 10% of asymptomatic HIV-1 carriers, 7% of patients with early AIDS, and 5% of patients with fully developed AIDS (6). Autopsy series of patients with AIDS have found a 4% to 30% prevalence of cerebral infarction and 1.2% to 11% of intracranial hemorrhage (Table 7). Cerebral infarcts were mostly caused by nonbacterial thrombotic endocarditis or concomitant opportunistic CNS infection, whereas intracerebral hemorrhages were usually associated with thrombocytopenia or primary CNS lymphoma. In a recent study it could be demonstrated that AIDS patients have an increased risk of stroke with an adjusted relative risk of 9.1 for ischemic stroke and 12.7 for intracerebral hemorrhage (238). According to the authors, AIDS is strongly associated with both ischemic stroke and intracranial hemorrhage.

Besides these macromorphological changes, alterations of the BBB could be demonstrated by several research groups (*see* Section 17). Furthermore, an HIV-1-associated vasculopathy with small vessel thickening, rarefaction, perivascular pigment deposition, and vessel wall mineralization has been described in HIV-1-infected patients (232,239), but a true cerebral vasculitis is exceptionally rare (240).

17. PATHOGENETIC MECHANISMS

The pathogenetic mechanisms induced by the HIV-1 infection and leading to the multiple facets of brain damage are not yet clearly understood. A complete review of the proposed mechanisms is not within the scope of the present chapter; rather, we elected to briefly describe some of the most probable aspects.

17.1. Mode of Entrance of HIV-1 to the Brain

HIV-1 is believed to enter the CNS by being passively carried by T-lymphocytes and monocytes, that is, the “Trojan Horse” hypothesis (77,241,242). Recent evidence suggests that cell-free HIV-1 particles may also penetrate brain microvascular endothelial cells (243). After crossing the BBB into the CNS, macrophages spread productive HIV-1 infection to neighboring microglia (77,89,105,118,244). The potential role of the CSF or the choroid plexus as a means for HIV-1 entry in the brain is still unclear (245). At the time of primary HIV-1 infection, an acute aseptic meningitis or encephalitis indicates CNS invasion (103). Opportunistic infectious agents or drugs of abuse disturbing the BBB may further attract more HIV-1 infected T-lymphocytes and macrophages into the brain. The point in time when the migration of HIV-1-infected lymphocytes into the brain takes place is not known. It has been shown that, at the time of seroconversion, HIV-1 can be detected in the CSF; this is the time when, clinically, a subacute meningitis develops, thus, suggesting that HIV-1 enters the CNS at a very early stage of the disease (96,246).

17.2. Target Cells of HIV-1

Although it has been claimed that HIV-1 is neurotrophic, the few articles describing the localization of HIV-1 in nerve cells have been subsequently disproved (59,71,89,247). Despite the detection of HIV-1 proteins in endothelial cells (248), it is now generally believed that productive HIV-1 infection of the cerebral endothelium does not occur (103,137,247). Furthermore, there is only infection at low level in a subset of astrocytes (71,103,249). Bissel and Wiley (224) reviewed the evidence of productive and nonproductive infection for each cell type (neurons, astrocytes, oligodendrocytes, microglia/macrophages, endothelial cells) in the brains of patients with HIV with and without HIV encephalitis. They concluded that despite the voluminous literature and substantial experimental effort during the past two decades, evidence for productive infection of any brain cell other than macrophages is weak.

The cells in the brain identified to contain HIV-1 are the microglia, macrophages, and MGCs (59,71,84,89,109,116–118,137,152,247,250,251).

Microglia and monocyte-derived macrophages are the only cells in the CNS that express both the CD4 and chemokine coreceptors (CCR5, CXCR4), the prerequisite for HIV-1 to enter a cell (77,252,253). The HIV-1 glycoprotein-mediated syncytia formation, which results from fusion of microglia or brain macrophages, may be observed as multinucleated giant cells (*see* Subheading 4.1.). It has been demonstrated that perivascular macrophages are a major CNS cell population that is productively infected with HIV-1. Such productive infection occurs with an accumulation of macrophages in perivascular cuffs, an event that correlates with entry of HIV-1 to the CNS (241). Brain macrophages and microglia serve as a reservoir for persistent viral infection, a vehicle for viral dissemination throughout the brain, and a major source of neurotoxic products that, when produced in abundance, affect neuronal function and finally lead to cell death (89,105,118,155). How HIV-1 evades the immune function characteristic for these cells as a first line of defense is still unclear.

In vitro test system by cell culture enables one to infect neuronal, astroglial, and endothelial cell lines, but does not seem to be the appropriate medium to test the infectivity of cell groups. Moreover, these results contradict the in vivo situation of the human brain.

17.3. Mechanisms of Brain Lesions

HIV-1 infection of the CNS occurs early after infection in the periphery, from hours to days, but neurological symptoms and HIV-associated dementia often occur years later, concomitant with or after the development of AIDS. Because productive infection reemerges with the development of AIDS, it is suggested that virus that enter the CNS early after infection can become latent and then reemerge with AIDS or that productive infection, which results with the development of AIDS, occurs from reseeding new virus from the periphery (241).

The development of brain lesions from opportunistic infections and lymphomas might be explained by the lack of a competent immunological defense system. The clinical signs and symptoms can be correlated with the site of the lesion as well as the brain structures involved.

In contrast, changes caused by direct or rather indirect effects of HIV-1 are more controversially discussed. Data based on systematic morphometrical analyses of the various constituents of the brain give new insight into the damage of the brain caused by HIV-1 (147–149,254–256). Neuronal loss was shown by independent research groups to occur in the frontal, parietal, and temporal cortex (50,257,258). Ketzler et al. (257), Weis et al. (258), and Weis (256) showed that this neuronal dropout occurs in brain regions that are free from any neuropathological changes. Others showed that neuronal damage in AIDS

was, at least, partly caused by apoptosis (259–262). However, no correlation was found between the presence and severity of neuronal loss or of neuronal apoptosis and a history of cognitive disorders.

Weis et al. (263) showed an increase of glial fibrillary acidic protein-positive astrocytes, a decrease of glial fibrillary acidic protein-negative astrocytes, but no changes in the total number of astroglial cells. The reactive astrogliosis was not correlated with the loss of nerve cells, indicating that this reaction pattern is rather a response to toxic factors secreted into the brain tissue.

In addition, significant structural and functional abnormalities in the microvasculature have been identified, including serum protein leakage (264–266), alterations in endothelial cells and basement membranes (267–269), as well as disruption of tight junctions (252,270–272), suggestive for BBB damage in the course of HIV-1 infection. These alterations are believed to be the result of a complex cascade of events and molecules involving HIV-1 proteins as well as products of monocytes, microglia, astrocytes, and activated brain endothelial cells (155,244,246,252,273–277).

One might assume that the above-described changes might result from infection with HIV-1. However, it has been shown that neither neurons, nor astrocytes, nor endothelial cells are significantly infected with HIV-1 (103). Therefore, these changes are more probably the result of indirect toxic factors that are produced either by infected MGCs or by activated microglia, or neurotoxic viral proteins (77,84,89,107–109,116,275).

The number of activated microglia/macrophages is significantly increased in all brain regions (278). This activation of microglia is not correlated with the presence of HIV-1 antigen in the brain tissue. This result might give a hint that, most probably, the activated microglia/macrophages, rather than MGCs, secrete toxic factors. However, this hypothesis remains to be proven. How a finite number of infected macrophages/microglia, localized in particular areas of the brain, can lead to widespread neuronal injury is summarized below.

The neurotoxicity associated with HIV-1 infection is mediated, in part, through cytokines and arachidonic acid metabolites, produced during cell-to-cell interactions between HIV-1 infected brain macrophages and astrocytes (84,89,103,105,118,155,279–281). The relationship between viral proteins, CA^{2+} channels, NMDA receptors, chemokines, and cytokines on one hand and cell damage on the other is summarized elsewhere (84,89,93,94,103,155,282–286).

Briefly, the pathobiological events underlying the neurodegenerative processes in HIV-1-associated dementia are believed to begin with productive infection of monocytes/macrophages by HIV-1. Peripheral activation causes

the differentiation of macrophages to produce a variety of immune products that lead to the upregulation of adhesion molecules on brain microvascular endothelial cells and the expression of cytokines on the monocyte-macrophage cell surface. After penetration of the BBB, the differentiated brain macrophages and microglia can be vehicles for viral dissemination throughout the brain and focal reservoirs for productive HIV-1 replication. The neurotoxic events in the brain are caused by neurotoxins produced by these cells, which are primed by HIV-1 and secondarily activated by factors such as immune stimuli or by T-cells trafficking through the nervous system. The primed and immune-activated brain macrophages/microglia secrete a variety of factors that affect neural and glial function and eventually lead to CNS inflammation. A proinflammatory cytokine response from blood-derived monocytes/macrophages, microglia, and astrocytes is amplified and leads finally to neurodegeneration. Immune neurotoxic factors may contribute to the breakdown of the BBB and affect the generation of chemokines, leading to transendothelial migration of monocytes into the brain perpetuating the inflammatory cascade. As a result of the neurotoxic activities of activated macrophages/microglia, astrocytes may suppress or increase macrophages/microglia secretory functions and toxicity, depending on the astrocytic functional status. Cytolytic T-lymphocytes serve to eliminate infected cells, but are lost in late-stage HIV-1 disease, allowing the virus-induced, neurodegenerative response to continue unabated (84,89,105,118,155,244).

ACKNOWLEDGMENTS

The help of Ida C. Llenos, MD, in correcting the manuscript is highly appreciated. We thank Susanne Ring for her skillful technical assistance.

REFERENCES

1. Appel PW, Joseph H, Richman BL (2000) Causes and rates of death among methadone maintenance patients before and after the onset of the HIV/AIDS epidemic. *Mt Sinai J Med* 67, 444–451.
2. Bell JE, Arango JC, Robertson R, Brett RP, Leen C, Simmonds P (2002) HIV and drug misuse in the Edinburgh cohort. *J Acquir Immune Defic Syndr* 31, Suppl 2, S35–S42.
3. Farabee D, Prendergast M, Cartier JA (2002) Methamphetamine use and HIV risk among substance-abusing offenders in California. *J Psychoactive Drugs* 34, 295–300.
4. Fehlaue F, Koops A, Lockemann U, et al. (1999) Prävalenz von Hepatitis B, Hepatitis C und HIV-Infektionen bei Drogentodesfällen in Hamburg (1985 bis 1997) unter Berücksichtigung von epidemiologischen, forensischen und morphologischen Aspekten. *Rechtsmedizin* 9, 205–209.

5. Hagan H, Des Jarlais DC (2000) HIV and HCV infection among injecting drug users. *Mt Sinai J Med* 67, 423–428.
6. Kibayashi K, Mastri AR, Hirsch CS (1996) Neuropathology of human immunodeficiency virus infection of different disease stages. *Hum Pathol* 27, 637–642.
7. Lockemann U, Wischhusen F, Püschel K (1997) Entwicklung der HIV-1-Prävalenz bei Drogentodesfällen in Deutschland und Europa—Analyse des vergangenen Jahrzehnts (1985–1994). *Rechtsmedizin* 7, 117–120.
8. Makrigeorgi-Butera M, Hagel C, Laas R, Püschel K, Stavrou D (1996) Comparative brain pathology of HIV-seronegative and HIV-infected drug addicts. *Clin Neuropathol* 15, 324–329.
9. Penning R, Tutsch-Bauer E, Beer G, Gürtler L, Spann W (1989) HIV-Infektion bei gerichtlichen Leichenöffnungen. *Beitr Gerichtl Med* 47, 23–29.
10. Püschel K (1993) HIV-1-Prävalenz bei Drogentoten in der Bundesrepublik Deutschland sowie im internationalen Vergleich (Stand 31.12.1991). *Rechtsmedizin* 3, 40–43.
11. Zappi E, Zappi M, Zugibe FT (1995) Disseminated cryptococcosis and sudden death. Report of an autopsy case. *Am J Forensic Med Pathol* 16, 38–41.
12. Bouwman FH, Skolasky R, Hes D, et al. (1998) Variable progression of HIV-associated dementia. *Neurology* 50, 1814–1820.
13. Chao CC, Gekker G, Sheng WS, Hu S, Tsang M, Peterson PK (1994) Priming effect of morphine on the production of tumor necrosis factor- α by microglia: implications in respiratory burst activity and human immunodeficiency virus-1 expression. *J Pharmacol Exp Ther* 269, 198–203.
14. Davies J, Everall IP, Weich S, et al. (1998) HIV-associated brain pathology: a comparative international study. *Neuropathol Appl Neurobiol* 24, 118–124.
15. Goodkin K, Shapshak P (1998) Cocaine abuse and HIV-1 infection: epidemiology and neuropathogenesis. *J Neuroimmunol* 83, 88–101.
16. Jellinger K, Setinek U, Drlicek M, Böhm G, Steurer A, Lintner F (2000) Neuropathology and general autopsy findings in AIDS during the last 15 years. *Acta Neuropathol* 100, 213–220.
17. Li Y, Wang X, Tian S, Guo CJ, Douglas SD, Ho W-Z (2002) Methadone enhances human immunodeficiency virus infection of human immune cells. *J Infect Dis* 185, 118–122.
18. Li Y, Merrill JE, Mooney K, et al. (2003) Morphine enhances HIV infection of neonatal macrophages. *Pediatr Res* 54, 282–288.
19. Maragos WF, Young KL, Turchan JT, et al. (2002) Human immunodeficiency virus-1 Tat protein and methamphetamine interact synergistically to impair striatal dopaminergic function. *J Neurochem* 83, 955–963.
20. Marder K, Liu X, Stern Y, et al. (1995) Risk of human immunodeficiency virus type 1-related neurologic disease in a cohort of intravenous drug users. *Arch Neurol* 52, 1174–1182.
21. Nath A, Maragos WF, Avison MJ, Schmitt FA, Berger JR (2001) Acceleration of HIV dementia with methamphetamine and cocaine. *J Neurovirol* 7, 66–71.
22. Nath A, Hauser KF, Wojna V, et al. (2002) Molecular basis for interactions of HIV and drugs of abuse. *J Acquir Immune Defic Syndr* 31, Suppl 2, S62–S69.

23. Shapshak P (1996) HIV-1 neuropathogenesis and abused drugs. Current views, problems, and solutions. *Adv Exp Med Biol* 402, 171–186.
24. Tyor WR, Middaugh LD (1999) Do alcohol and cocaine abuse alter the course of HIV-associated dementia complex? *J Leukoc Biol* 65, 475–481.
25. Zhang L, Looney D, Taub D, et al. (1998) Cocaine opens the blood-brain barrier to HIV-1 invasion. *J Neurovirol* 4, 619–626.
26. Arango JC, Simmonds P, Brettell RP, Bell JE (2004) Does drug abuse influence the microglial response in AIDS and HIV encephalitis? *AIDS* 18, Suppl 1, S69–S74.
27. Tomlinson GS, Simmonds P, Busuttill A, Chiswick A, Bell JE (1999) Upregulation of microglia in drug users with and without pre-symptomatic HIV infection. *Neuropathol Appl Neurobiol* 25, 369–379.
28. Basso M, Bornstein RA (2000) Neurobehavioural consequences of substance abuse and HIV infection. *J Psychopharmacol* 14, 228–237.
29. Anders KH, Guerra WF, Tomiyasu U, Verity MA, Vinters HV (1986) The neuropathology of AIDS. UCLA experience and review. *Am J Pathol* 124, 537–558.
30. Budka H (1989) Human immunodeficiency virus (HIV)-induced disease of the central nervous system: pathology and implications for pathogenesis. *Acta Neuropathol* 77, 225–236.
31. Budka H, Wiley CA, Kleihues P, et al. (1991) HIV-associated disease of the nervous system: review of nomenclature and proposal for neuropathology-based terminology. *Brain Pathol* 1, 143–152.
32. Budka H, Costanzi G, Cristina S, et al. (1987) Brain pathology induced by infection with the human immunodeficiency virus (HIV). A histological, immunocytochemical, and electron microscopical study of 100 autopsy cases. *Acta Neuropathol* 75, 185–198.
33. Burns DK, Risser RC, White CL (1991) The neuropathology of human immunodeficiency virus infection. The Dallas, Texas, Experience. *Arch Pathol Lab Med* 115, 1112–1124.
34. De Girolami U, Smith TW, Hénin D, Hauw JJ (1990) Neuropathology of the acquired immunodeficiency syndrome. *Arch Pathol Lab Med* 114, 643–655.
35. Gullotta F, Kuchelmeister K, Masini T, Ghidoni P, Cappricci E (1989) Zur Morphologie der HIV-Enzephalopathie. *Zentralbl allg Pathol pathol Anat* 135, 5–13.
36. Kanzer MD (1990) Neuropathology of AIDS. *Crit Rev Neurobiol* 5, 313–362.
37. Kato T, Hirano A, Llena JF, Dembitzer HM (1987) Neuropathology of acquired immune deficiency syndrome (AIDS) in 53 autopsy cases with particular emphasis on microglial nodules and multinucleated giant cells. *Acta Neuropathol* 73, 287–294.
38. Kure K, Llena JF, Lyman WD, et al. (1991) Human immunodeficiency virus-1 infection of the nervous system: an autopsy study of 268 adult, pediatric, and fetal brains. *Hum Pathol* 22, 700–710.
39. Lang W, Miklossy J, Deruaz JP, et al. (1989) Neuropathology of the acquired immune deficiency syndrome (AIDS): a report of 135 consecutive autopsy cases from Switzerland. *Acta Neuropathol* 77, 379–390.
40. Lanjewar DN, Jain PP, Shetty CR (1998) Profile of central nervous system pathology in patients with AIDS: an autopsy study from India. *AIDS* 12, 309–313.

41. Moskowitz LB, Hensley GT, Chan JC, Gregorios J, Conley FK (1984) The neuropathology of acquired immune deficiency syndrome. *Arch Pathol Lab Med* 108, 867–872.
42. Navia BA, Cho EK, Petito CK, Price RW (1986) The AIDS dementia complex: II. Neuropathology. *Ann Neurol* 19, 525–535.
43. Petito CK, Cho EK, Lemann W, Navia BA, Price RW (1986) Neuropathology of acquired immunodeficiency syndrome (AIDS): an autopsy review. *J Neuropathol Exp Neurol* 45, 635–646.
44. Sharer LR (1992) Pathology of HIV-1 infection of the central nervous system. A review. *J Neuropathol Exp Neurol* 51, 3–11.
45. Vinters HV, Anders KH (1990) Neuropathology of AIDS. CRC Press, Boca Raton.
46. Artigas J, Grosse G, Niedobitek F (1993) The Central Nervous System in AIDS. Neurology, Radiology, Pathology, Ophthalmology. Springer, Berlin.
47. Chimelli L, Rosenberg S, Hahn MD, Lopes MBS, Barretto Netto M (1992) Pathology of the central nervous system in patients infected with the human immunodeficiency virus (HIV): a report of 252 autopsy cases from Brazil. *Neuropathol Appl Neurobiol* 18, 478–488.
48. Cornford ME, Holden JK, Boyd MC, Berry K, Vinters HV (1992) Neuropathology of the acquired immune deficiency syndrome (AIDS): report of 39 autopsies from Vancouver, British Columbia. *Can J Neurol Sci* 19, 442–452.
49. Davies J, Everall IP, Weich S, McLaughlin J, Scaravilli F, Lantos PL (1997) HIV-associated brain pathology in the United Kingdom: an epidemiological study. *AIDS* 11, 1145–1150.
50. Everall IP, Luthert PJ, Lantos PL (1993) A review of neuronal damage in human immunodeficiency virus infection: its assessment, possible mechanism and relationship to dementia. *J Neuropathol Exp Neurol* 52, 561–566.
51. Funata N, Maeda Y, Koike M, Okeda R (1991) Neuropathology of the central nervous system in acquired immune deficiency syndrome (AIDS) in Japan. With special reference to human immunodeficiency virus-induced encephalomyelopathies. *Acta Pathol Jpn* 41, 206–211.
52. Giampalmo A, Pesce C, Ardoino S, Provaggi MA, Quaglia AC (1989) Neuropathological findings in an autopsy series of Italian subjects with AIDS. *Clin Neuropathol* 8, 120–125.
53. Gonzales MF, Davis RL (1988) Neuropathology of acquired immunodeficiency syndrome. *J Neuropathol Exp Neurol* 14, 345–363.
54. Gray F (1993) Atlas of the Neuropathology of HIV Infection. Oxford University Press, Oxford.
55. Gray F, Gherardi R, Scaravilli F (1988) The neuropathology of the acquired immune deficiency syndrome (AIDS). A review. *Brain* 111, 245–266.
56. Hall WW, Farmer PM, Takahashi H, Tanaka S, Furuta Y, Nagashima K (1991) Pathological features of virus infections of the central nervous system (CNS) in the acquired immunodeficiency syndrome (AIDS). *Acta Pathol Jpn* 41, 172–181.
57. Jensen OA, Klinken L (1989) Pathology of brain and eye in the acquired immune deficiency syndrome (AIDS). *APMIS* 97, 325–333.

58. Kibayashi K, Ng'walali PM, Mbonde M, et al. (1999) Neuropathology of human immunodeficiency virus 1 infection. Significance of studying in forensic autopsy cases at Dar es Salaam, Tanzania. *Arch Pathol Lab Med* 123, 519–523.
59. Koenig S, Gendelman HE, Orenstein JM, et al. (1986) Detection of AIDS virus in macrophages in brain tissue from AIDS patients with encephalopathy. *Science* 233, 1089–1093.
60. Lantos PL, McLaughlin JE, Schoitz CL, Berry CL, Tighe JR (1989) Neuropathology of the brain in HIV infection. *Lancet* 1, 309–311.
61. Martínez AJ, Sell M, Mitrovics T, et al. (1995) The neuropathology and epidemiology of AIDS. A Berlin experience. A review of 200 cases. *Pathol Res Pract* 191, 427–443.
62. Matthiessen L, Marche C, Labrousse F, Trophilme D, Fontaine C, Vedrenne C (1992) Etude neuropathologique de l'encéphale de 174 patients morts du SIDA dans un hôpital parisien, de 1982 à 1988. *Ann Med Interne (Paris)* 143, 43–49.
63. Mossakowski MJ, Zelman IB (1997) Neuropathological syndromes in the course of full blown acquired immune deficiency syndrome (AIDS) in adults in Poland (1987–1995). *Folia Neuropathol* 35, 133–143.
64. Neuen-Jacob E, Figge C, Arendt G, Wendtland B, Jacob B, Wechsler W (1993) Neuropathological studies in the brains of AIDS patients with opportunistic diseases. *Int J Legal Med* 105, 339–350.
65. Nielsen SL, Petito CK, Urmacher CD, Posner JB (1984) Subacute encephalitis in acquired immune deficiency syndrome: a postmortem study. *Am J Clin Pathol* 82, 678–682.
66. Nielsen SL, Davis RL (1988) Neuropathology of acquired immunodeficiency syndrome. In Rosenblum ML, Levy RM, Bredesen DE, eds., *AIDS and the Nervous System*. Raven Press, New York, pp. 155–181.
67. Petito CK (1988) Review of central nervous system pathology in human immunodeficiency virus infection. *Ann Neurol* 23, Suppl, 54–57.
68. Rao C, Anzil AP, Hollenberg Sher J (1993) The neuropathology of AIDS: a review. *Adv Neuroimmunol* 3, 1–15.
69. Rhodes RH (1987) Histopathology of the central nervous system in the acquired immunodeficiency syndrome. *Hum Pathol* 18, 636–643.
70. Rhodes RH (1993) Histopathologic features in the central nervous system of 400 acquired immunodeficiency syndrome cases: implications of rates of occurrence. *Hum Pathol* 24, 1189–1198.
71. Rosenblum MK (1990) Infection of the central nervous system by the human immunodeficiency virus type 1. Morphology and relation to syndromes of progressive encephalopathy and myelopathy in patients with AIDS. *Pathol Annu* 25, 117–169.
72. Rosenblum ML, Levy RM, Bredesen DE (1988) *AIDS and the Nervous System*. Raven Press, New York.
73. Scaravilli F (1993) *The Neuropathology of HIV Infection*. Springer, London.
74. Sharer LR, Kapila R (1985) Neuropathologic observations in acquired immunodeficiency syndrome (AIDS). *Acta Neuropathol* 66, 188–198.

75. Vinters HV, Tomiyasu U, Anders KH (1989) Neuropathologic complications of infection with the human immunodeficiency virus (HIV). In Rotterdam H, Sommers SP, Raes P, Meyer PR, eds., *Progress in AIDS Pathology*. Field & Wood, New York, NY, pp. 101–130.
76. Zelman IB, Mossakowski MJ (1998) Opportunistic infections of the central nervous system in the course of acquired immune deficiency syndrome (AIDS). Morphological analysis of 172 cases. *Folia Neuropathol* 36, 129–144.
77. Albright AV, Soldan SS, González-Scarano F (2003) Pathogenesis of human immunodeficiency virus-induced neurological disease. *J Neurovirol* 9, 222–227.
78. Brew BJ (1994) The clinical spectrum and pathogenesis of HIV encephalopathy, myelopathy, and peripheral neuropathy. *Curr Opin Neurol* 7, 209–216.
79. Epstein LG, Gendelman HE (1993) Human immunodeficiency virus type I infection of the nervous system: pathogenetic mechanisms. *Ann Neurol* 33, 429–436.
80. Esiri MM, Scaravilli F, Millard PR, Harcourt-Webster JN (1989) Neuropathology of HIV infection in haemophiliacs: comparative necropsy study. *Br Med J* 299, 1312–1315.
81. Fauci AS (1988) The human immunodeficiency virus: infectivity and mechanisms of pathogenesis. *Science* 239, 617–622.
82. Gabuzda DH, Johnson RT (1990) Nervous system infection with human immunodeficiency virus: biology and pathogenesis. *Curr Asp Neurosci* 1, 285–309.
83. Gartner S (2000) HIV infection and dementia. *Science* 287, 602–604.
84. Gendelman HE, Lipton SA, Tardieu M, Bukrinsky MI, Nottet HSLM (1994) The neuropathogenesis of HIV-1 infection. *J Leukoc Biol* 56, 389–398.
85. Glass JD, Johnson RT (1996) Human immunodeficiency virus and the brain. *Annu Rev Neurosci* 19, 1–26.
86. Ho DD, Pomerantz RJ, Kaplan JC (1987) Pathogenesis of infection with human immunodeficiency virus. *N Engl J Med* 317, 278–286.
87. Johnson RT (1995) The pathogenesis of HIV infections of the brain. *Curr Top Microbiol Immunol* 202, 1–10.
88. Johnson RT, McArthur JC, Narayan O (1988) The neurobiology of human immunodeficiency virus infections. *FASEB J* 2, 2970–2981.
89. Kaul M, Garden GA, Lipton SA (2001) Pathways to neuronal injury and apoptosis in HIV-associated dementia. *Nature* 410, 988–994.
90. Kolson DL (2002) Neuropathogenesis of central nervous system HIV-1 infection. *Clin Lab Med* 22, 703–717.
91. Kolson DL, Lavi E, González-Scarano F (1998) The effects of human immunodeficiency virus in the central nervous system. *Adv Virus Res* 50, 1–47.
92. Levy JA (1993) Pathogenesis of human immunodeficiency virus infection. *Microbiol Rev* 57, 183–289.
93. Lipton SA (1991) HIV-related neurotoxicity. *Brain Pathol* 1, 193–199.
94. Lipton SA, Yeh M, Dreyer EB (1994) Update on current models of HIV-related neuronal injury: platelet-activating factor, arachidonic acid and nitric oxide. *Adv Neuroimmunol* 4, 181–188.
95. Masliah E, Ge N, Mucke L (1996) Pathogenesis of HIV-1 associated neurodegeneration. *Crit Rev Neurobiol* 10, 57–67.

96. Michaels J, Sharer LR, Epstein LG (1988) Human immunodeficiency virus type 1 (HIV-1) infection of the nervous system: a review. *Immunodef Rev* 1, 71–104.
97. Navia BA, Jordan BD, Price RW (1986) The AIDS dementia complex: I. Clinical features. *Ann Neurol* 19, 517–524.
98. Power C, Johnson RT (1995) HIV-1 associated dementia: clinical features and pathogenesis. *Can J Neurol Sci* 22, 92–100.
99. Price RW (1996) Neurological complications of HIV infection. *Lancet* 348, 445–452.
100. Price RW, Perry SW (1992) HIV, AIDS and the brain. *J Neurol Sci* 113, 125–132.
101. Price RW, Brew BJ, Sidtis J, Rosenblum M, Scheck AC, Cleary P (1988) The brain in AIDS: central nervous system HIV-1 infection and AIDS dementia complex. *Science* 239, 586–592.
102. Rafalowska J (1998) HIV-1 infection in the CNS. A pathogenesis of some neurological syndromes in the light of recent investigations. *Folia Neuropathol* 36, 211–216.
103. Sotrel A, Dal Canto MC (2000) HIV-1 and its causal relationship to immunosuppression and nervous system disease in AIDS: a review. *Hum Pathol* 31, 1274–1298.
104. Spencer DC, Price RW (1992) Human immunodeficiency virus and the central nervous system. *Annu Rev Microbiol* 46, 655–693.
105. Swindells S, Zheng J, Gendelman HE (1999) HIV-associated dementia: new insights into disease pathogenesis and therapeutic interventions. *AIDS Patient Care STDs* 13, 153–163.
106. Tucker T (1989) Central nervous system AIDS. *J Neurol Sci* 89, 119–133.
107. Tyor WR, Wesselingh SL, Griffin JW, McArthur JC, Griffin DE (1995) Unifying hypothesis for the pathogenesis of HIV-associated dementia complex, vacuolar myelopathy, and sensory neuropathy. *J Acquir Immune Defic Syndr Hum Retrovirol* 9, 379–388.
108. van de Bovenkamp M, Nottet HSLM, Pereira CF (2002) Interactions of human immunodeficiency virus-1 proteins with neurons: possible role in the development of human immunodeficiency virus-1-associated dementia. *Eur J Clin Invest* 32, 619–627.
109. Williams KC, Hickey WF (2002) Central nervous system damage, monocytes and macrophages, and neurological disorders in AIDS. *Annu Rev Neurosci* 25, 537–562.
110. Zink WE, Zheng J, Persidsky Y, Poluektova L, Gendelman HE (1999) The neuropathogenesis of HIV-1 infection. *FEMS Immunol Med Microbiol* 26, 233–241.
111. No authors listed (1991) Nomenclature and research case definitions for neurologic manifestations of human immunodeficiency virus-type 1 (HIV-1) infection. Report of a Working Group of the American Academy of Neurology AIDS Task Force. *Neurology* 41, 778–785.
112. Masliah E, Achim CL, Ge N, DeTeresa R, Terry RD, Wiley CA (1992) Spectrum of human immunodeficiency virus-associated neocortical damage. *Ann Neurol* 32, 321–329.
113. McArthur JC, Hoover DR, Bacellar H, et al. (1993) Dementia in AIDS patients: incidence and risk factors. *Neurology* 43, 2245–2252.

114. Ho DD, Bredezen DE, Vinters HV, Daar ES (1989) The acquired immunodeficiency syndrome (AIDS) dementia complex. *Ann Intern Med* 111, 400–410.
115. Tselis A, Booss J (2003) Behavioral consequences of infections of the central nervous system: with emphasis on viral infections. *J Am Acad Psychiatry Law* 31, 289–298.
116. Brew BJ, Rosenblum M, Cronin K, Price RW (1995) AIDS dementia complex and HIV-1 brain infection: clinical-virological correlations. *Ann Neurol* 38, 563–570.
117. Glass JD, Fedor H, Wesselingh SL, McArthur JC (1995) Immunocytochemical quantitation of human immunodeficiency virus in the brain: correlations with dementia. *Ann Neurol* 38, 755–762.
118. Perry VH, Lawson LJ, Reid DM (1994) Biology of the mononuclear phagocyte system of the central nervous system and HIV infection. *J Leukoc Biol* 56, 399–406.
119. Dalakas MC, Pezeshkpour GH (1988) Neuromuscular diseases associated with human immunodeficiency virus infection. *Ann Neurol* 23, Suppl, S38–S48.
120. Fuller GN, Jacobs JM (1993) Peripheral nerve and muscle disease in HIV infection. In Scaravilli F, ed., *The Neuropathology of HIV Infection*. Springer, London, pp. 215–233.
121. Fuller GN, Jacobs JM, Guilloff RJ (1993) Nature and incidence of peripheral nerve syndromes in HIV infection. *J Neurol Neurosurg Psychiatry* 56, 372–381.
122. Gherardi R (1994) Skeletal muscle involvement in HIV-infected patients. *Neuropathol Appl Neurobiol* 20, 232–237.
123. Hantai D, Fournier J-G, Vazeux R, Collin H, Baudrimont M, Fardeau M (1991) Skeletal muscle involvement in human immunodeficiency virus infection. *Acta Neuropathol* 81, 496–502.
124. Lange DJ, Britton CB, Younger DS, Hays AP (1988) The neuromuscular manifestations of human immunodeficiency virus infections. *Arch Neurol* 45, 1084–1088.
125. Miller RG, Kiprov DD, Parry G, Bredezen DE (1988) Peripheral nervous system dysfunction in acquired immunodeficiency syndrome. In Rosenblum ML, Levy RM, Bredezen DE, eds., *AIDS and the Nervous System*. Raven Press, New York, pp. 65–78.
126. Pardo CA, McArthur JC, Griffin JW (2001) HIV neuropathy: insights in the pathology of HIV peripheral nerve disease. *J Periph Nerv Syst* 6, 21–27.
127. Rizzuto R, Cavallero T, Monaco S, et al. (1995) Role of HIV in the pathogenesis of distal symmetrical peripheral neuropathy. *Acta Neuropathol* 90, 244–250.
128. Demiryürek D, Bayramoglu A, Ustaçelebi S (2002) Infective agents in fixed human cadavers: a brief review and suggested guidelines. *Anat Rec* 269, 194–197.
129. Geller SA (1990) The autopsy in acquired immunodeficiency syndrome. How and why. *Arch Pathol Lab Med* 114, 324–329.
130. Ironside JW, Bell JE (1996) The ‘high-risk’ neuropathological autopsy in AIDS and Creutzfeldt-Jakob disease: principles and practice. *Neuropathol Appl Neurobiol* 22, 388–393.
131. Klatt EC, Noguchi TT (1990) AIDS and infection control in forensic investigation. *Am J Forensic Med Pathol* 11, 44–49.
132. Lucas SB (1993) HIV and the necropsy. *J Clin Pathol* 46, 1071–1075.

133. Reichert CM (1992) New safety considerations for the acquired immunodeficiency syndrome autopsy. *Arch Pathol Lab Med* 116, 1109–1110.
134. Achim CL, Wang R, Miners DK, Wiley CA (1994) Brain viral burden in HIV infection. *J Neuropathol Exp Neurol* 53, 284–294.
135. Morrison HL, Neal JW, Parkes AB, Jasani B (1998) Immunohistochemical retrieval of the principal HIV antigens p24, gp41, and gp120 in formalin fixed tissue: an investigation using HIV infected lymphoblasts and postmortem brain tissue from AIDS cases. *Mol Pathol* 51, 227–231.
136. Shapshak P, Yoshioka M, Sun NC, et al. (1992) HIV-1 in postmortem brain tissue from patients with AIDS: a comparison of different detection techniques. *AIDS* 6, 915–923.
137. Takahashi K, Wesselingh SL, Griffin DE, McArthur JC, Johnson RT, Glass JD (1996) Localization of HIV-1 in human brain using polymerase chain reaction/in situ hybridization and immunocytochemistry. *Ann Neurol* 39, 705–711.
138. de Gans J, Portegies P (1989) Neurological complications of infection with human immunodeficiency virus type 1. A review of literature and 241 cases. *Clin Neurol Neurosurg* 91, 199–219.
139. Levy RM, Bredesen DE, Rosenblum ML (1985) Neurological manifestations of the acquired immunodeficiency syndrome (AIDS): experience at UCSF and review of the literature. *J Neurosurg* 62, 475–495.
140. Morgello S, Mahboob R, Yakoushina T, Khan S, Hague K (2002) Autopsy findings in a human immunodeficiency virus-infected population over 2 decades. *Arch Pathol Lab Med* 126, 182–190.
141. Rosemberg S, Lopes MBS, Tsanaclis AM (1986) Neuropathology of acquired immunodeficiency syndrome (AIDS). Analysis of 22 Brazilian cases. *J Neurol Sci* 76, 187–198.
142. Trujillo JR, Garcia-Ramos G, Novak IS, Rivera VM, Huerta E, Essex M (1995) Neurologic manifestations of AIDS: a comparative study of two populations from Mexico and the United States. *J Acquir Immune Defic Syndr Hum Retrovirol* 8, 23–29.
143. Masliah E, DeTeresa R, Mallory M, Hansen LA (2000) Changes in pathological findings at autopsy in AIDS cases for the last 15 years. *AIDS* 14, 69–74.
144. Mocroft A, Brettle RP, Kirk O, et al. (2002) Changes in the cause of death among HIV positive subjects across Europe: results from the EuroSIDA study. *AIDS* 16, 1663–1671.
145. Sacktor N, Lyles RH, Skolasky R, et al. (2001) HIV-associated neurologic disease incidence changes: multicenter AIDS cohort study, 1990–1998. *Neurology* 56, 257–260.
146. Gelman BB, Guinto FC (1992) Morphometry, histopathology, and tomography of cerebral atrophy in the acquired immunodeficiency syndrome. *Ann Neurol* 32, 31–40.
147. Oster S, Christofferson P, Gundersen HJG, Nielson JO, Pakkenberg B, Pedersen C (1993) Cerebral atrophy in AIDS: a stereological study. *Acta Neuropathol* 85, 617–622.
148. Subbiah P, Mouton P, Fedor H, McArthur JC, Glass JD (1996) Stereological analysis of cerebral atrophy in human immunodeficiency virus-associated dementia. *J Neuropathol Exp Neurol* 55, 1032–1037.

149. Weis S, Llenos IC, Büttner A, Rebhan A, Soreth D, Mehraein P (1993) Macroscopic morphometry of human brains in neurodegeneration. *Acta Stereol* 12, 299–304.
150. Budka H (1986) Multinucleated giant cells in brain: a hallmark of the acquired immune deficiency syndrome (AIDS). *Acta Neuropathol* 69, 253–258.
151. De la Monte SM, Ho DD, Schooley RT, Hirsch MS, Richardson EP Jr (1987) Subacute encephalomyelitis of AIDS and its relation to HTLV-III infection. *Neurology* 37, 562–569.
152. Cosenza MA, Zhao ML, Si Q, Lee SC (2002) Human brain parenchymal microglia express CD14 and CD45 and are productively infected by HIV-1 in HIV-1 encephalitis. *Brain Pathol* 12, 442–455.
153. Brew BJ (2004) Evidence for a change in AIDS dementia complex in the era of highly active antiretroviral therapy and the possibility of new forms of AIDS dementia complex. *AIDS* 18, Suppl 1, S75–S78.
154. Neuenburg JK, Brodt HR, Herndier BG, et al. (2002) HIV-related neuropathology, 1985 to 1999: rising prevalence of HIV encephalopathy in the era of highly active antiretroviral therapy. *J Acquir Immune Defic Syndr* 31, 171–177.
155. Persidsky Y, Gendelman HE (2003) Mononuclear phagocyte immunity and the neuropathogenesis of HIV-1 infection. *J Leukoc Biol* 74, 691–701.
156. Giometto B, An SF, Groves M, et al. (1997) Accumulation of β -amyloid precursor protein in HIV encephalitis: relationship with neuropsychological abnormalities. *Ann Neurol* 42, 34–40.
157. Raja F, Sherrieff FE, Morris CS, Bridges LR, Esiri MM (1997) Cerebral white matter damage in HIV infection demonstrated using β -amyloid precursor protein immunoreactivity. *Acta Neuropathol* 93, 184–189.
158. Artigas J, Grosse G, Niedobitek F (1990) Vacuolar myelopathy in AIDS. A morphological analysis. *Pathol Res Pract* 186, 228–237.
159. Bergmann M, Gullotta F, Kuchelmeister K, Masini T, Angeli G (1993) AIDS myelopathy. A neuropathological study. *Pathol Res Pract* 189, 58–65.
160. Goldstick L, Mandybur TI, Bode R (1985) Spinal cord degeneration in AIDS. *Neurology* 35, 103–106.
161. Hénin D, Smith TW, DeGirolami U, Sughayer M, Hauw JJ (1992) Neuropathology of the spinal cord in the acquired immunodeficiency syndrome. *Hum Pathol* 23, 1106–1114.
162. Maier H, Budka H, Lassmann H, Pohl P (1989) Vacuolar myelopathy with multinucleated giant cells in the acquired immune deficiency syndrome (AIDS). Light and electron microscopic distribution of human immunodeficiency virus (HIV) antigens. *Acta Neuropathol* 78, 497–503.
163. Shepherd EJ, Brettle RP, Liberski PP, et al. (1999) Spinal cord pathology and viral burden in homosexuals and drug users with AIDS. *Neuropathol Appl Neurobiol* 25, 2–10.
164. Rottnek M, Di Rocco A, Laudier D, Morgello S (2002) Axonal damage is a late component of vacuolar myelopathy. *Neurology* 58, 479–481.
165. Rhodes RH, Ward JM, Cowan RP, Moore PT (1989) Immunohistochemical localization of human immunodeficiency viral antigens in formalin-fixed spinal cords with AIDS myelopathy. *Clin Neuropathol* 8, 22–27.

166. Schmidbauer M, Budka H, Okeda R, Cristina S, Lechi A, Trabattoni R (1990) Multifocal vacuolar leukoencephalopathy: a distinct HIV-associated lesion of the brain. *Neuropathol Appl Neurobiol* 16, 437–443.
167. Cinque P, Marenzi R, Ceresa D (1997) Cytomegalovirus infections of the nervous system. *Intervirology* 40, 85–97.
168. Holland NR, Power C, Mathews VP, Glass JD, Forman M, McArthur JC (1994) Cytomegalovirus encephalitis in acquired immunodeficiency syndrome (AIDS). *Neurology* 44, 507–514.
169. Schmidbauer M, Budka H, Ulrich W, Ambros P (1989) Cytomegalovirus (CMV) disease of the brain in AIDS and connatal infection: a comparative study by histology, immunocytochemistry and in situ DNA hybridization. *Acta Neuropathol* 79, 286–293.
170. Setinek U, Wondrusch E, Jellinger K, et al. (1995) Cytomegalovirus infection of the brain in AIDS: a clinicopathologic study. *Acta Neuropathol* 90, 511–515.
171. Vinters HV, Kwok MK, Ho HW, et al. (1989) Cytomegalovirus in the nervous system of patients with the acquired immune deficiency syndrome. *Brain* 112, 245–268.
172. Kalayjian RC, Cohen ML, Bonomo RA, Flanigan TP (1993) Cytomegalovirus ventriculoencephalitis in AIDS. A syndrome with distinct clinical and pathologic features. *Medicine* 72, 67–77.
173. Morgello S, Simpson DM (1994) Multifocal cytomegalovirus demyelinating polyneuropathy associated with AIDS. *Muscle Nerve* 17, 176–182.
174. Roullet E, Assuerus V, Gozlan J, et al. (1994) Cytomegalovirus multifocal neuropathy in AIDS: analysis of 15 consecutive cases. *Neurology* 44, 2174–2182.
175. Berger JR, Concha M (1995) Progressive multifocal leukoencephalopathy: the evolution of a disease once considered rare. *J Neurovirol* 1, 5–18.
176. Chaisson RE, Griffin DE (1990) Progressive multifocal leukoencephalopathy in AIDS. *JAMA* 264, 79–82.
177. Kuchelmeister K, Gullotta F, Bergmann M, Angeli G, Masini T (1993) Progressive multifocal leukoencephalopathy (PML) in the acquired immunodeficiency syndrome (AIDS). A neuropathological autopsy study of 21 cases. *Pathol Res Pract* 189, 163–173.
178. von Einsiedel RW, Fife TD, Aksamit AJ, et al. (1993) Progressive multifocal leukoencephalopathy in AIDS: a clinicopathologic study and review of the literature. *J Neurol* 240, 391–406.
179. Bertoli F, Espino M, Arosemena JR, Fishback JL, Frenkel JK (1995) A spectrum in the pathology of toxoplasmosis in patients with acquired immunodeficiency syndrome. *Arch Pathol Lab Med* 119, 214–224.
180. Falangola MF, Reichler BS, Petito CK (1994) Histopathology of cerebral toxoplasmosis in human immunodeficiency virus infection: a comparison between patients with early-onset and late-onset acquired immunodeficiency syndrome. *Hum Pathol* 25, 1091–1097.
181. Strittmatter C, Lang W, Wiestler OD, Kleihues P (1992) The changing pattern of human immunodeficiency virus-associated cerebral toxoplasmosis: a study of 46 postmortem cases. *Acta Neuropathol* 83, 475–481.

182. Lee SC, Dickson DW, Casadevall A (1996) Pathology of cryptococcal meningoencephalitis: analysis of 27 patients with pathogenetic implications. *Hum Pathol* 27, 839–847.
183. Gray F, Bélec L, Lescs MC, et al. (1994) Varizella-zoster virus infection of the central nervous system in the acquired immune deficiency syndrome. *Brain* 117, 987–999.
184. Kleinschmidt-DeMasters BK, Amlie-Lefond C, Gilden DH (1996) The patterns of varicella zoster virus encephalitis. *Hum Pathol* 27, 927–938.
185. Chrétien F, Bélec L, Hilton BA, et al. (1996) Herpes simplex virus type 1 encephalitis in acquired immunodeficiency syndrome. *Neuropathol Appl Neurobiol* 22, 394–404.
186. Katz DA, Berger JR (1989) Neurosyphilis in acquired immunodeficiency syndrome. *Arch Neurol* 46, 895–898.
187. Farrar DJ, Flanigan TP, Gordon NM, Gold RL, Rich JD (1997) Tuberculous brain abscess in a patient with HIV infection: case report and review. *Am J Med* 102, 297–301.
188. Adle-Biassette H, Bourhy H, Gisselbrecht M, et al. (1996) Rabies encephalitis in a patient with AIDS: a clinicopathologic study. *Acta Neuropathol* 92, 415–420.
189. LeBlang SD, Whiteman MLH, Post MJD, Uttamchandani RB, Bell MD, Smirniotopoulos JG (1995) CNS nocardia in AIDS patients: CT and MRI with pathologic correlation. *J Comput Assist Tomogr* 19, 15–22.
190. Mischel PS, Vinters HV (1995) Coccidioidomycosis of the central nervous system: neuropathological and vasculopathic manifestations and clinical correlates. *Clin Infect Dis* 20, 400–405.
191. Straus DJ (1997) Human immunodeficiency virus-associated lymphomas. *Med Clin N Am* 81, 495–510.
192. Zelman IB, Mossakowski MJ, Niewiadomska H (1998) Cerebral lymphomas in AIDS. Neuropathological study. *Folia Neuropathol* 36, 65–79.
193. Iglesias-Rozas JR, Bantz B, Adler T, et al. (1991) Cerebral lymphoma in AIDS. Clinical, radiological, neuropathological and immunopathological study. *Clin Neuropathol* 10, 65–72.
194. Ioachim HL, Dorsett B, Cronin W, Maya M, Wahl S (1991) Acquired immunodeficiency syndrome associated lymphomas: clinical pathologic, immunologic, and viral characteristics of 111 cases. *Hum Pathol* 22, 659–673.
195. Morgello S, Petito CK, Mouradian JA (1990) Central nervous system lymphoma in the acquired immunodeficiency syndrome. *Clin Neuropathol* 9, 205–215.
196. So YT, Beckstead JH, Davis RL (1986) Primary central nervous system lymphoma in acquired immune deficiency syndrome: a clinical and pathological study. *Ann Neurol* 20, 566–572.
197. Büttner A, Weis S (1999) Non-lymphomatous brain tumors in HIV-1 infection: a review. *J Neurooncol* 41, 81–88.
198. Büttner A, Marquart KH, Mehraein P, Weis S (1997) Kaposi's sarcoma in the cerebellum of a patient with AIDS. *Clin Neuropathol* 16, 185–189.
199. Schlote W, Gräfin Vitzthum H, Thomas E (1987) Neuropathologische Beobachtungen in 28 Fällen von erworbenem Immundefektsystem (AIDS). In

- Fischer PA, Schlote W, eds., AIDS und Nervensystem. Springer, Berlin, pp. 85–116.
200. Vago L, Castagna A, Lazzarin A, Trabattoni G, Cinque P, Costanzi G (1993) Reduced frequency of HIV-induced brain lesions in AIDS patients treated with zidovudine. *J Acquir Immune Defic Syndr* 6, 42–45.
201. Langford TD, Letendre SL, Larrea GJ, Masliah E (2003) Changing patterns in the neuropathogenesis of HIV during the HAART era. *Brain Pathol* 13, 195–210.
202. Gray F, Chrétien F, Vallat-Decouvelaere AV, Scaravilli F (2003) The changing pattern of HIV Neuropathology in the HAART era. *J Neuropathol Exp Neurol* 62, 429–440.
203. Burns DK (1992) The neuropathology of pediatric acquired immunodeficiency syndrome. *J Child Neurol* 7, 332–346.
204. Kozłowski PB, Brudkowska J, Kraszpulski M, et al. (1997) Microencephaly in children congenitally infected with human immunodeficiency virus—a gross-anatomical morphometric study. *Acta Neuropathol* 93, 136–145.
205. Kozłowski PB, Snider DA, Vietze PM, Wisniewski HM (1990) Brain in pediatric AIDS. Karger, Basel.
206. Dickson DW, Llena JF, Nelson SJ, Weidenheim KM (1993) Central nervous system pathology in pediatric AIDS. *Ann NY Acad Sci* 693, 93–106.
207. Bell JE, Lowrie S, Koffi K, et al. (1997) The neuropathology of HIV-infected African children in Abidjan, Cote d'Ivoire. *J Neuropathol Exp Neurol* 56, 686–692.
208. Belman AL (1992) Acquired immunodeficiency syndrome and the child's central nervous system. *Pediatr Clin North Am* 39, 691–714.
209. Belman AL, Ultmann MH, Horoupian D, et al. (1985) Neurological complications in infants and children with acquired immune deficiency syndrome. *Ann Neurol* 18, 560–565.
210. Brennenman DE, McCune SK, Gozes I (1990) Acquired immune deficiency syndrome and the developing nervous system. *Int Rev Neurobiol* 32, 305–353.
211. Epstein LG, Gelbard HA (1999) HIV-1-induced neuronal injury in the developing brain. *J Leukoc Biol* 65, 453–457.
212. Epstein LG, Sharer LR, Goudsmit J (1988) Neurological and neuropathological features of human immunodeficiency virus infection in children. *Ann Neurol* 23, Suppl, S19–S23.
213. Gavin P, Yogev R (1999) Central nervous system abnormalities in pediatric human immunodeficiency virus infection. *Pediatr Neurosurg* 31, 115–123.
214. Joshi VV (1993) Pathology of pediatric AIDS. Overview, update, and future direction. *Ann NY Acad Sci* 693, 71–92.
215. Masini T, Chinaglia D, Ghidoni P, Gullotta F (1994) Autoptic findings in HIV-1 positive children. *Klin Pädiatr* 206, 45–49.
216. Sharer LR, Dowling PC, Michaels J, et al. (1990) Spinal cord disease in children with HIV-1 infection: a combined molecular biological and neuropathological study. *Neuropathol Appl Neurobiol* 16, 317–331.
217. Sharer LR, Epstein LG, Cho ES, et al. (1986) Pathologic features of AIDS encephalopathy in children: evidence for LAV/HTLV-III infection of brain. *Hum Pathol* 17, 271–284.

218. Gray F, Lescs MC, Keohane C, et al. (1992) Early brain changes in HIV infection: neuropathological study of 11 seropositive, non-AIDS cases. *J Neuropathol Exp Neurol* 51, 177–185.
219. Gray F, Hurtrel M, Hurtrel B (1993) Early central nervous system changes in human immunodeficiency virus (HIV)-infection. *Neuropathol Appl Neurobiol* 19, 3–9.
220. Gray F, Scaravilli F, Everall IP, et al. (1996) Neuropathology of early HIV-1 infection. *Brain Pathol* 6, 1–15.
221. Wingertsman L, Chrétien F, Authier FJ, Paraire F, Durigon M, Gray A (1997) Les lésions du système nerveux central au stade précoce de l'infection par le VIH. *Arch Anat Cytol Pathol* 45, 106–117.
222. An SF, Scaravilli F (1997) Early HIV-infection of the central nervous system. *Arch Anat Cytol Pathol* 45, 94–105.
223. An S, Groves M, Gray F, Scaravilli F (1999) Early entry and widespread cellular involvement of HIV-1 DNA in brains of HIV-1 positive asymptomatic individuals. *J Neuropathol Exp Neurol* 58, 1156–1162.
224. Bissell SJ, Wiley CA (2004) Human immunodeficiency virus infection of the brain: pitfalls in evaluating infected/affected cell populations. *Brain Pathol* 14, 97–108.
225. Clifford DB (1998) Antiretroviral therapies for HIV infection implications for treatment of neurologic manifestations: an overview. In Gendelman HE, Lipton SA, Epstein L, Swindells S, eds., *The Neurology of AIDS*. Chapman and Hall, New York, NY, pp. 353–363.
226. Tardieu M (1999) HIV-1-related central nervous system diseases. *Curr Opin Neurol* 12, 377–381.
227. Dore GJ, McDonald A, Li Y, Kaldor JM, Brew BJ (2003) Marked improvement in survival following AIDS dementia complex in the era of highly active antiretroviral therapy. *AIDS* 17, 1539–1545.
228. Maschke M, Kastrop O, Esser S, Ross B, Hengge U, Hufnagel A (2000) Incidence and prevalence of neurological disorders associated with HIV since the introduction of highly active antiretroviral therapy (HAART). *J Neurol Neurosurg Psychiatry* 69, 376–380.
229. Ammassari A, Cingolani A, Pezzotti P, et al. (2000) AIDS-related focal brain lesions in the era of highly active antiretroviral therapy. *Neurology* 55, 1194–1200.
230. Vago L, Bonetto S, Nebuloni M, et al. (2002) Pathological findings in the central nervous system of AIDS patients on assumed antiretroviral therapeutic regimens: retrospective study of 1597 autopsies. *AIDS* 16, 1925–1928.
231. Berger JR, Harris JO, Gregorios J, Norenberg MD (1990) Cerebrovascular disease in AIDS: a case-control study. *AIDS* 4, 239–244.
232. Connor MD, Lammie GA, Bell JE, Warlow CP, Simmonds P, Brett RP (2000) Cerebral infarction in adult AIDS patients: observations from the Edinburgh HIV autopsy cohort. *Stroke* 31, 2117–2126.
233. Evers S, Nabavi D, Rahmann A, Heese C, Reichelt D, Husstedt IW (2003) Ischaemic cerebrovascular events in HIV infection: a cohort study. *Cerebrovasc Dis* 15, 199–205.

234. Gillams AR, Allen E, Hrieb K, Venna D, Craven D, Carter AP (1997) Cerebral infarction in patients with AIDS. *AJNR Am J Neuroradiol* 18, 1581–1585.
235. Kieburz KD, Eskin TA, Ketonen L, Tuite MJ (1993) Opportunistic cerebral vasculopathy and stroke in patients with the acquired immunodeficiency syndrome. *Arch Neurol* 50, 430–432.
236. Mizusawa H, Hirano A, Llena JF, Shintaku M (1988) Cerebrovascular lesions in acquired immune deficiency syndrome (AIDS). *Acta Neuropathol* 76, 451–457.
237. Pinto AN (1996) AIDS and cerebrovascular disease. *Stroke* 27, 538–543.
238. Cole JW, Pinto AN, Hebel JR, et al. (2004) Acquired immunodeficiency syndrome and the risk of stroke. *Stroke* 35, 51–56.
239. Smith TW, DeGirolami U, Hénin D, Bolgert F, Hauw JJ (1990) Human immunodeficiency virus (HIV) leucoencephalopathy and the microcirculation. *J Neuropathol Exp Neurol* 49, 357–370.
240. Büttner A, Pfister HW, Quintern J, Itoh K, Mehraein P, Weis S (1997) Vasculitis with predominantly leptomeningeal involvement in an AIDS patient. *Neuropathology* 17, 238–242.
241. Kim WK, Corey S, Alvarez X, Williams K (2003) Monocyte/macrophage traffic in HIV and SIV encephalitis. *J Leukoc Biol* 74, 650–656.
242. Peluso R, Haase A, Stowring L, Edwards M, Ventura P (1985) A Trojan Horse mechanism for the spread of visna virus in monocytes. *Virology* 147, 231–236.
243. Liu NQ, Lossinsky AS, Popik W, et al. (2002) Human immunodeficiency virus type 1 enters brain microvascular endothelia by macropinocytosis dependent on lipid rafts and the mitogen-activated protein kinase signaling pathway. *J Virol* 76, 6689–6700.
244. Nottet HSLM (1999) Interactions between macrophages and brain microvascular endothelial cells: role in pathogenesis of HIV-1 infection and blood-brain barrier function. *J Neurovirol* 527, 659–669.
245. Falangola MF, Hanly A, Galvao-Castro B, Petito CK (1995) HIV infection of human choroid plexus: a possible mechanism for viral entry into the CNS. *J Neuropathol Exp Neurol* 54, 497–503.
246. Annunziata P (2003) Blood-brain barrier changes during invasion of the central nervous system by HIV-1. Old and new insights into the mechanism. *J Neurol* 250, 901–906.
247. Budka H (1991) Neuropathology of human immunodeficiency virus infection. *Brain Pathol* 1, 163–175.
248. Poland SD, Rice GPA, Dekaban GA (1995) HIV-1 infection of human brain-derived microvascular endothelial cells in vitro. *J Acquir Immune Defic Syndr Hum Retrovirol* 8, 437–445.
249. Ranki A, Nyberg M, Ovod V, et al. (1995) Abundant expression of HIV Nef and Rev proteins in brain astrocytes in vivo is associated with dementia. *AIDS* 9, 1001–1008.
250. Dickson DW, Mattiace LA, Kure K, Hutchins K, Lyman WD, Brosnan CF (1991) Microglia in human disease, with an emphasis on acquired immune deficiency syndrome. *Lab Invest* 64, 135–156.
251. Gosztonyi G, Artigas J, Lamperth L, Webster HD (1994) Human immunodeficiency virus (HIV) distribution in HIV encephalitis: study of 19 cases with com-

- bined use of in situ hybridization and immunocytochemistry. *J Neuropathol Exp Neurol* 53, 521–534.
252. Persidsky Y, Zheng J, Miller D, Gendelman HE (2000) Mononuclear phagocytes mediate blood-brain barrier compromise and neuronal injury during HIV-1-associated dementia. *J Leukoc Biol* 68, 413–422.
253. Albright AV, Shieh JTC, Itoh T, et al. (1999) Microglia express CCR5, CXCR4, and CCR3, but of these, CCR5 is the principal coreceptor for human immunodeficiency virus type 1 dementia. *J Virol* 73, 205–213.
254. Oster S, Christoffersen P, Gundersen HJG, Nielsen JO, Pedersen C, Pakkenberg B (1995) Six billion neurons lost in AIDS. A stereological study of the neocortex. *APMIS* 103, 525–529.
255. Weis S (1992) Morphometric aspects of the brain in HIV-1 infection. In Weis S, Hippus H, eds., *HIV-1 Infection of the Central Nervous System. Clinical, Pathological, and Molecular Aspects*. Hogrefe & Huber Publishers, Seattle, pp. 199–220.
256. Weis S (1994) Neuronal loss in HIV [letter]. *Neurology* 44, 1365–1366.
257. Ketzler S, Weis S, Haug H, Budka H (1990) Loss of neurons in the frontal cortex in AIDS brains. *Acta Neuropathol* 80, 92–94.
258. Weis S, Haug H, Budka H (1993) Neuronal damage in the cerebral cortex of AIDS brains: a morphometric study. *Acta Neuropathol* 85, 185–189.
259. Adle-Biasette H, Chrétien F, Wingertsman L, et al. (1999) Neuronal apoptosis does not correlate with dementia in HIV infection but is related to microglial activation and axonal damage. *Neuropathol Appl Neurobiol* 25, 123–133.
260. Adle-Biasette H, Levy Y, Colombel M, et al. (1995) Neuronal apoptosis in HIV infection in adults. *Neuropathol Appl Neurobiol* 21, 218–227.
261. An SF, Giometto B, Scaravilli T, Tavolato B, Gray F, Scaravilli F (1996) Programmed cell death in brains of HIV-1 positive AIDS and pre-AIDS patients. *Acta Neuropathol* 91, 169–173.
262. Petito CK, Roberts B (1995) Evidence of apoptotic cell death in HIV encephalitis. *Am J Pathol* 146, 1121–1130.
263. Weis S, Budka H, Haug H (1993) Astroglial changes in the cerebral cortex of AIDS brains: a morphometric and immunohistochemical investigation. *Neuropathol Appl Neurobiol* 19, 329–335.
264. Petito CK, Cash KS (1992) Blood-brain barrier abnormalities in the acquired immunodeficiency syndrome: immunohistochemical localization of serum proteins in postmortem brain. *Ann Neurol* 32, 658–666.
265. Power C, Kong PA, Crawford TO, et al. (1993) Cerebral white matter changes in acquired immunodeficiency syndrome dementia: alterations of the blood-brain barrier. *Ann Neurol* 34, 339–350.
266. Rhodes RH (1991) Evidence of serum-protein leakage across the blood-brain barrier in the acquired immunodeficiency syndrome. *J Neuropathol Exp Neurol* 50, 171–183.
267. Büttner A, Mehraein P, Weis S (1996) Vascular changes in the cerebral cortex of HIV-1 infected brains: an immunohistochemical and lectin histochemical analysis. *Acta Neuropathol* 92, 35–41.

268. Weis S, Haug H, Budka H (1996) Vascular changes in the cerebral cortex in HIV-1 infection: I. A morphometric investigation by light and electron microscopy. *Clin Neuropathol* 15, 361–366.
269. Weis S, Haug H, Budka H (1988) Stereological investigation of the microvasculature of cerebral cortex in AIDS-demented patients. *Clin Neuropathol* 7, 221.
270. András IE, Pu H, Deli MA, Nath A, Hennig B, Toborek M (2003) HIV-1 Tat protein alters tight junction protein expression and distribution in cultured brain endothelial cells. *J Neurosci Res* 74, 255–265.
271. Boven LA, Middel J, Verhoef J, De Groot CJA, Nottet HSLM (2000) Monocyte infiltration is highly associated with loss of tight junction protein zonula occludens in HIV-1-associated dementia. *Neuropathol Appl Neurobiol* 26, 356–360.
272. Dallasta LM, Pisarov LA, Esplen JE, et al. (1999) Blood-brain barrier tight junction disruption in human immunodeficiency virus-1 encephalitis. *Am J Pathol* 155, 1915–1927.
273. Banks WA, Akerstrom V, Kastin AJ (1998) Adsorptive endocytosis mediates the passage of HIV-1 across the blood-brain barrier: evidence for a post-internalization coreceptor. *J Cell Sci* 111, 533–540.
274. Hurwitz AA, Berman JW, Lyman WD (1994) The role of the blood-brain barrier in HIV infection of the central nervous system. *Adv Neuroimmunol* 4, 249–256.
275. Kanmogne GD, Kennedy RC, Grammas P (2002) HIV-1 gp120 proteins and gp160 peptides are toxic to brain endothelial cells and neurons: possible pathways for HIV entry into the brain and HIV-associated dementia. *J Neuropathol Exp Neurol* 61, 992–1000.
276. Kim TA, Avraham HK, Koh YH, Jiang S, Park IW, Avraham S (2003) HIV-1 tat-mediated apoptosis in human brain microvascular endothelial cells. *J Immunol* 170, 2629–2637.
277. Persidsky Y, Ghorpade A, Rasmussen J, et al. (1999) Microglial and astrocyte chemokines regulate monocyte migration through the blood-brain barrier in human immunodeficiency virus-1 encephalitis. *Am J Pathol* 155, 1599–1611.
278. Weis S, Neuhaus B, Mehraein P (1994) Activation of microglia in HIV-1 infected brains is not dependent on the presence of HIV-1 antigens. *Neuroreport* 5, 1514–1516.
279. Genis P, Jett M, Bernton EW, et al. (1992) Cytokines and arachidonic metabolites produced during human immunodeficiency virus (HIV)-infected macrophage-astroglia interactions: implications for the neuropathogenesis of HIV disease. *J Exp Med* 176, 1703–1718.
280. Giulian D, Vaca K, Noonan CA (1990) Secretion of neurotoxins by mononuclear phagocytes infected with HIV-1. *Science* 250, 1593–1596.
281. Sabri F, Titanji K, de Milito A, Chiodi F (2003) Astrocyte activation and apoptosis: their roles in the neuropathology of HIV infection. *Brain Pathol* 12, 84–94.
282. Garden GA (2002) Microglia in human immunodeficiency virus-associated neurodegeneration. *Glia* 40, 240–251.
283. Merrill JE, Chen ISY (1991) HIV-1, macrophages, glial cells, and cytokines in AIDS nervous system disease. *FASEB J* 5, 2391–2397.
284. Mrak RE, Griffin WST (1997) The role of chronic self-propagating glial responses in neurodegeneration: implications for long-lived survivors of human immunodeficiency virus. *J Neurovirol* 3, 241–246.

285. Ryan LA, Cotter RL, Zink WEI, Gendelman HE, Zheng J (2002) Macrophages, chemokines and neuronal injury in HIV-1-associated dementia. *Cell Mol Biol* 48, 137–150.
286. Seilhean D, Kobayashi K, He Y, et al. (1997) Tumor necrosis factor- α , microglia and astrocytes in AIDS dementia complex. *Acta Neuropathol* 93, 508–517.



<http://www.springer.com/978-1-58829-416-6>

Forensic Pathology Reviews Vol 3

Tsokos, M. (Ed.)

2005, XIV, 470 p., Hardcover

ISBN: 978-1-58829-416-6

A product of Humana Press