

12

Lymphoma

Christopher J. Palestro, Josephine N. Rini, and Maria B. Tomas

In patients with lymphoma, prognosis and treatment are related to the stage of disease at diagnosis, and accurate staging, therefore, is essential for proper management. The staging procedures currently used include history and physical examination; computed tomography (CT) of the chest, abdomen, and pelvis; bone marrow biopsy; and, occasionally, staging laparotomy. Radionuclide studies, including gallium scintigraphy, bone scintigraphy, and more recently, positron emission tomography (PET) with fluorine-18 fluorodeoxyglucose (^{18}F -FDG) have been used as adjuncts for staging, follow-up, and prognosis in children with Hodgkin's disease and non-Hodgkin's lymphoma.

Hodgkin's Disease

Hodgkin's disease (HD) accounts for 13% of malignant lymphomas and less than 1% of all malignancies (1). Although it is a relatively uncommon malignancy, HD accounts for 19% of all malignancies occurring in adolescents 15 to 19 years of age (2). Furthermore, it is among the few potentially curable malignancies with an overall 5-year survival rate of 85% (3).

The current international staging classification of HD, the Cotswold Classification, which is a modification of the earlier Ann Arbor Classification, defines the extent of nodal involvement, extranodal disease, and systemic symptoms (4,5). Stage I is defined as involvement of a single lymph node region or lymphoid structure. Stage II is defined as involvement of two or more lymph node regions on the same side of the diaphragm. Stage III is defined as involvement of lymph node regions or structures on both sides of the diaphragm. Stage IV is defined as extranodal involvement, such as bone or lung disease. Each stage is also classified by the presence or absence of symptoms. "A" indicates that the patient is asymptomatic; "B" indicates that the patient has weight loss, fevers, chills, and/or sweats.

Depending on the stage of disease at diagnosis, HD is treated with radiation therapy and/or chemotherapy. Because HD is not treated

with surgery, and because it is impractical and unethical to biopsy all suspected sites of disease, stage is determined clinically in the majority of patients. Currently recommended staging procedures include history and physical examination; CT of the chest, abdomen, and pelvis; bone marrow biopsy; and, rarely, staging laparotomy (4).

Non-Hodgkin's Lymphoma

Non-Hodgkin's lymphoma (NHL), like HD, is a malignant neoplasm of the lymphopoietic system. This once relatively rare, but rapidly lethal, disease has increased in frequency over the past decade, and is currently the fifth most common malignancy in the United States, accounting for 4% of all cancers and 7% of cancers in children and adolescents (6).

As with HD, the prognosis and treatment of NHL are highly dependent on the histopathologic subtype and stage of disease at diagnosis. In contrast to HD, however, NHL is a heterogeneous group of pathologic entities; numerous schemes for classification have been formulated over time, specifically to guide clinicians in instituting therapy and predicting outcome. The most widely utilized classification scheme for pediatric NHL is the Revised European-American Lymphoma (REAL) classification, which emphasizes the immunophenotype of the tumor, that is, B cell or T cell (7). This classification has been further refined by the World Health Organization (WHO) classification of lymphoproliferative diseases (8). Approximately 90% of NHL is of B-cell origin and 10% is of T-cell origin. The vast majority of childhood NHLs are clinically aggressive, high-grade tumors. There are four major subtypes of pediatric NHL. Small noncleaved cell (SNCC) (Burkitt's and Burkitt's-like) accounts for about 40% of these tumors, 30% are lymphoblastic, 20% are B-large cell, and 10% are anaplastic large cell. In contrast to adults, extranodal disease is common in children with NHL. The most common sites of extranodal disease are the abdomen (31%), head and neck (29%), and thorax (26%) (9).

The initial staging of NHL is accomplished with a careful history, detailed physical examination, laboratory tests, imaging, and bone marrow biopsy. The staging strategy often used is the St. Jude Children's Research Hospital staging system, which distinguishes patients with limited disease (stages I and II) from those with extensive disease (stages III and IV). Stage I disease is defined as a single tumor or nodal area outside of the abdomen and mediastinum. Stage II disease is defined as a single tumor with regional node involvement, two or more tumors or nodal areas on one side of the diaphragm, or a primary gastrointestinal tract tumor (resected) with or without regional node involvement. Stage III disease consists of tumors or lymph node areas on both sides of the diaphragm, or any primary intrathoracic or extensive intraabdominal disease, or any paraspinal or epidural disease. Stage IV disease includes central nervous system and bone marrow involvement, with or without other sites of disease. Bone marrow involvement is defined as at least 5% malignant cells in an otherwise

normal bone marrow with normal peripheral blood counts and smears (9).

^{18}F -FDG-PET in Lymphoma

Nuclear medicine, in particular gallium-67 (^{67}Ga) imaging, has long played an important part in the diagnosis, staging, and restaging of HD and NHL in children with lymphoma. ^{18}F -FDG-PET, which was approved by Medicare in July 1999, is gradually replacing gallium imaging for these indications (10,11). It has several advantages over gallium, including same-day imaging, improved spatial resolution, and a higher target-to-background ratio. The primary role of PET in patients with lymphoma, as it has been for gallium imaging, is to monitor response during therapy, to detect residual disease or relapse after treatment, and to provide prognostic information (12). Although CT is the primary imaging modality for initial staging of lymphoma, gallium and PET also play a role at the time of initial staging. Specifically, baseline studies documenting gallium or FDG-avid disease are necessary in order for posttherapy studies to be meaningful. The current Children's Oncology Group (COG) research treatment protocols for children and adolescents with newly diagnosed intermediate-risk Hodgkin's disease and advanced-stage anaplastic large-cell non-Hodgkin's lymphoma require PET or gallium imaging prior to initiation of therapy, followed by repeat imaging to assess treatment response after two cycles of chemotherapy for patients with HD, and at the end of induction chemotherapy for patients with NHL. Biopsy of PET-positive nonosseous lesions at the end of induction chemotherapy is required for patients with NHL. If the test is negative after induction chemotherapy, follow-up is recommended at the end of therapy, at relapse, and at 6 and 12 months following completion of therapy.

Because radionuclide studies provide whole-body screening, they have the potential to identify stage IV disease in a single examination (13,14). Hoh et al. (15) found that a whole-body PET-based staging algorithm may be an accurate and cost-effective method for staging lymphoma.

Physiologic Variants in Uptake of ^{18}F -FDG

Interpretation of PET scans performed for pediatric patients undergoing evaluation for lymphoma may be complicated by variable physiologic uptake of ^{18}F -FDG by the thymus gland, brown adipose tissue, skeletal muscle, and bone marrow. Recognition of normal variations in the biodistribution of ^{18}F -FDG is important in order to avoid misinterpreting normal findings as disease, as well as to avoid overlooking disease.

Thymus Uptake of FDG

The thymus gland, situated in the anterior mediastinum, is the primary site where T-cell lymphocytes differentiate and become functionally

competent. The thymus gland weighs approximately 22 g at birth and attains its peak weight of about 35 g at puberty, after which time it decreases in size. Up to age 20, more than 80% of the gland is composed of lymphoid tissue. This tissue gradually is replaced by fatty infiltration, over time, and beyond the age of 40 only about 5% of the gland is morphologically lymphoid (16). During the first decade of life, the gland is usually quadrilateral in shape with convex lateral borders and a homogeneous appearance on CT. After age 10, the gland assumes a more triangular or arrowhead appearance. The normal thymus gradually decreases in size after puberty, becoming increasingly heterogeneous in appearance on CT because of progressive fatty infiltration (17,18).

Benign uptake of FDG may be seen in morphologically normal thymus glands as well as in thymic hyperplasia. Thymic uptake of FDG also occurs with malignancy, including lymphomatous infiltration, primary thymic neoplasms, and metastatic disease (19). Differentiating benign thymic uptake of ^{18}F -FDG from malignant infiltration is based on the intensity and configuration of tracer activity in combination with the morphologic appearance of the gland on CT (Figs. 12.1 and 12.2). Benign thymic uptake is situated in the retrosternal region and appears as an area of increased FDG activity, corresponding to the bilobed configuration of the thymus gland. The intensity of benign thymic uptake is variable. Although it tends to be mild and less than that which is seen with disease, the intensity of uptake may overlap with that of disease. For example, a maximum standard uptake value (SUV) of 3.8 was reported for physiologic thymic uptake occurring in a child following chemotherapy for osteosarcoma (20). Ferdinand et al. (19) suggest that although further research and experience are needed before identifying an upper SUV limit for physiologic thymic uptake, a maximum SUV above 4.0 may be cause to reconsider attributing anterior mediastinal uptake of ^{18}F -FDG to physiologic thymic uptake.

The incidence of benign thymic uptake is higher in younger patients with larger glands, although it may be seen well beyond puberty. One study reported that 32 of 94 patients, ranging in age from 18 to 29 years, exhibited physiologic thymic uptake of FDG (21). Benign thymic uptake of FDG is seen in children and young adults both before and after chemotherapy (22). This is in contrast to ^{67}Ga , which usually accumulates only in the thymus gland after chemotherapy and is indicative of thymic hyperplasia. In our experience with pediatric lymphoma patients, when thymic uptake of ^{18}F -FDG is seen following chemotherapy, it is identified within 2 to 12 months of chemotherapy and may persist for up to 18 months.

Brown Adipose Tissue and Skeletal Muscle Uptake of FDG

Nonpathologic, curvilinear cervical, and supraclavicular uptake of FDG, first described in 1996, originally was attributed to skeletal muscle, due to its fusiform configuration and because it usually resolved on repeat imaging after pretreatment with a muscle relaxant

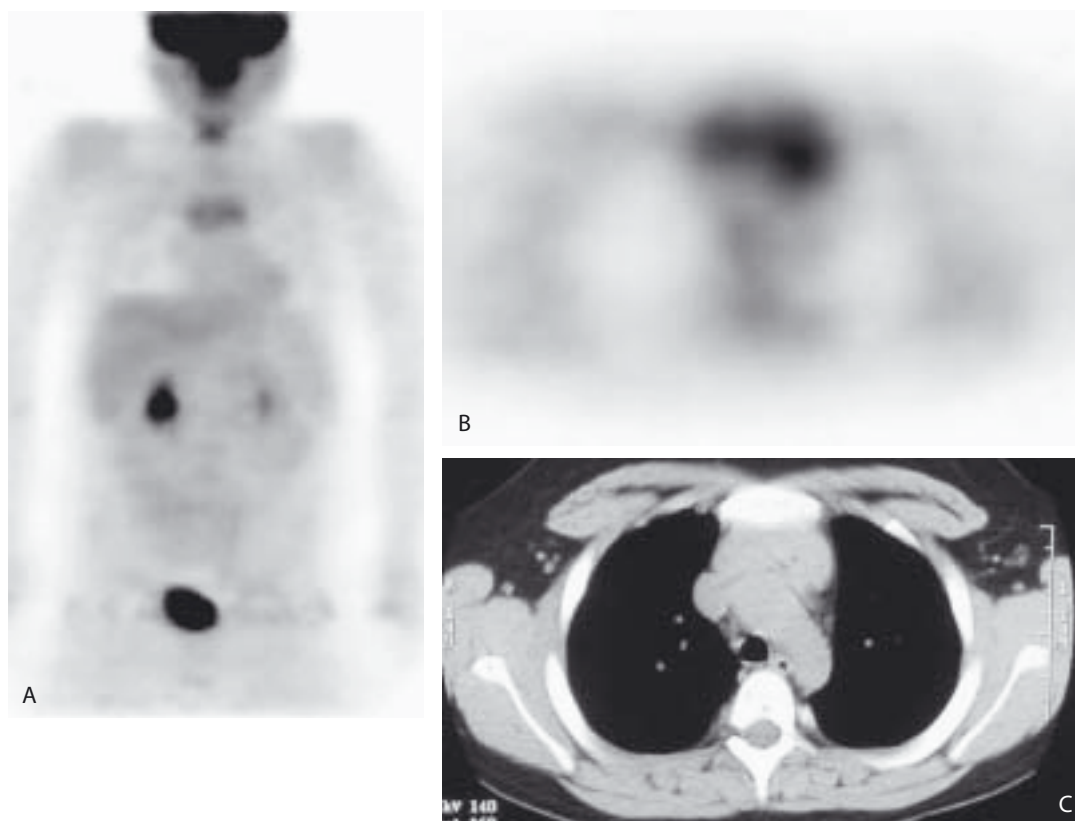


Figure 12.1. A chest x-ray (not shown) performed on a 13-year-old boy with a history of cough demonstrated a prominent mediastinum. The patient underwent positron emission tomography (PET) and computed tomography (CT) imaging with a presumptive diagnosis of lymphoma. There is mildly increased FDG uptake in the mediastinum on the PET image (A). An axial image (B) confirms the anterior location of this activity, which corresponds to a prominent but otherwise normal, thymus gland on CT (C). The child's cough resolved, and no additional workup was performed.

(diazepam) (23). With the introduction of inline hybrid PET-CT in 2001, it became apparent that bilateral curvilinear ^{18}F -FDG activity, with or without focal nodularity, extending from the neck to the supraclavicular regions and sometimes to the axillae, corresponded to adipose tissue in 2% to 4% of patients, and cervical musculature in 1% to 6% of patients studied (24–26). Benign, physiologic uptake of ^{18}F -FDG in perinephric fat, mediastinal fat, and unspecified tissue in the thoracic paravertebral region was also identified using inline hybrid PET-CT but in fewer patients and only in those patients who also demonstrated uptake in neck fat (26).

The intensity of physiologic ^{18}F -FDG uptake in adipose tissue and cervical/supraclavicular musculature is very variable with maximum standard uptake values (SUV_{max}) ranging from 1.9 to 20 and the average SUV_{max} approximately 5 or greater, which is within the commonly

accepted pathologic range (26). Adipose tissue uptake in the neck is seen predominantly in females, whereas uptake in normal musculature is more often seen in males. Of the 26 pediatric patients (<17 years old), four (15%) had fat uptake in the neck, in contrast to 16 of 837 (1.9%) adult patients who showed this pattern. Furthermore, normal muscle uptake was observed only in adult patients.

Fluorodeoxyglucose uptake by adipose tissue is attributed specifically to uptake by brown adipose tissue (BAT), which is capable of thermogenesis and is rich in mitochondria, sympathetic nerves, and adrenergic receptors. It is normally present in the neck, and near large vessels in the chest, axillae, perinephric regions, intercostal spaces along the spine, and in the paraaortic regions. It is more prominent in younger patients and in women, and it generates heat in

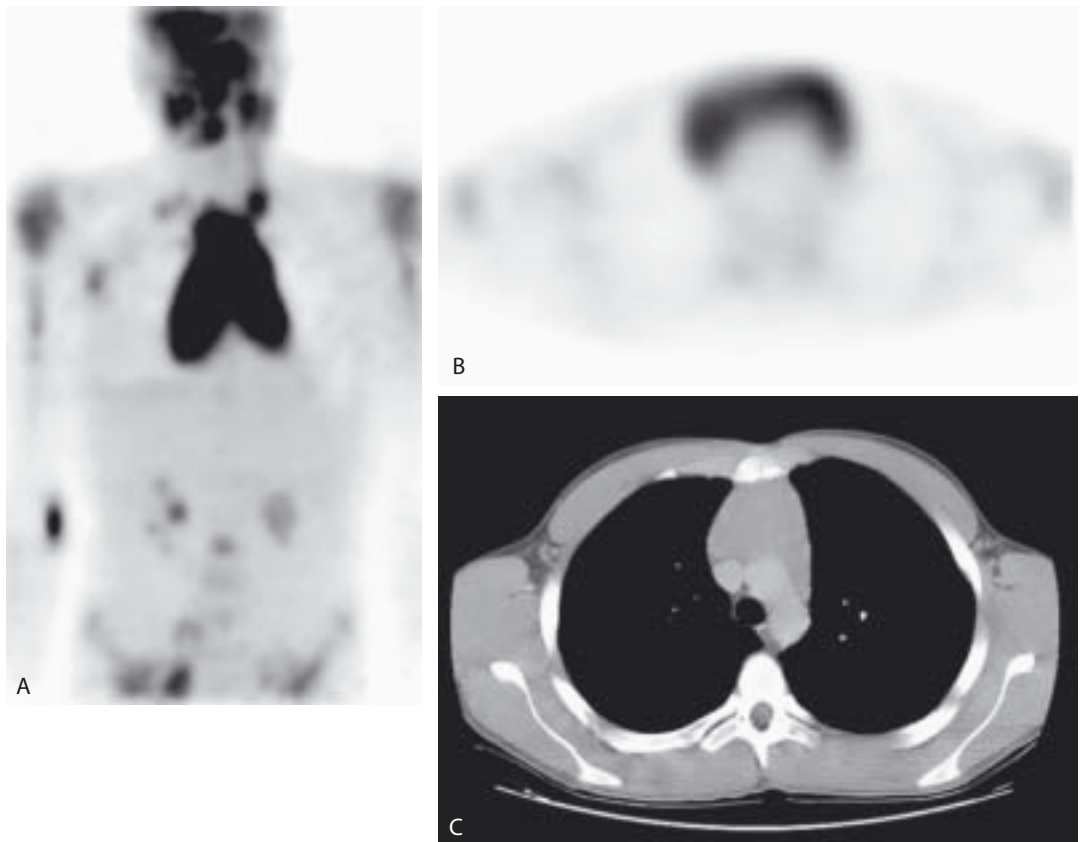


Figure 12.2. A: A PET image of a 16-year-old boy with stage IV T-cell lymphoblastic lymphoma shows numerous fluorodeoxyglucose (FDG)-avid lesions including a very large, hypermetabolic focus in the mediastinum. An axial image (B) shows the retrosternal location of this abnormality, which corresponds to lymphomatous infiltration of the thymus identified on the CT scan (C). Compare both the extent and intensity of thymic FDG uptake in this patient with lymphomatous involvement of the gland to that in the normal thymus gland in Figure 12.1.

response to cold exposure because it expresses a protein that causes uncoupling of oxidative phosphorylation in the mitochondria. This leads to the production of heat, rather than adenosine triphosphate (ATP). Thermogenesis by BAT requires increased glucose utilization (27).

Sympathetic stimulation results in increased BAT utilization of glucose. Benzodiazepines may reduce BAT uptake of FDG because they decrease anxiety, which leads to a decrease in sympathetic activity (Fig. 12.3). It also is possible that benzodiazepines have a direct action on the metabolism of BAT, as benzodiazepine receptors have been identified in BAT of rats (28,29). A recent report described resolution of benzodiazepine-resistant BAT uptake of FDG in response to temperature control, in two adolescent patients with a history of Hodgkin's lymphoma (30). In addition, a rodent study showed that propranolol and reserpine diminish BAT uptake of FDG (31).

Diffuse Bone Marrow Uptake of FDG

Diffuse bone marrow uptake of ^{18}F -FDG, regardless of intensity, usually reflects hypercellular bone marrow and not lymphomatous involvement. Nunez et al. (32) recently reviewed bone marrow and splenic uptake of FDG in 29 patients with HD, who had no evidence of marrow or splenic disease. These investigators found that there was a direct correlation between the intensity of marrow uptake and an increasing white cell count and an inverse correlation with hemoglobin and, to a lesser extent, with the platelet count; that is, the lower the hemoglobin or platelet count, the greater the marrow uptake of FDG. In all cases the marrow uptake was diffuse. The bone marrow is a metabolically active organ, and the increased FDG uptake reported by these investigators likely reflects increased metabolism and hence increased glucose consumption, by the bone marrow in response to hematologic stress. Thus the presence of diffusely increased bone marrow uptake at the time of diagnosis in patients with lymphoma should not be interpreted as evidence of marrow involvement with the disease (Fig. 12.4).

Treatment also affects bone marrow uptake of FDG, and treatment-induced metabolic changes in the bone marrow can be seen on PET studies during and after treatment for a variety of tumors. These changes do not appear to be due to chemotherapy; rather they are produced by hematopoietic cytokines, which alter the normal pattern of glucose metabolism in this organ (33). Granulocyte colony-stimulating factors (G-CSFs) and granulocyte-macrophage colony-stimulating factors (GM-CSFs) stimulate and support the proliferation of hematopoietic stem cells and mobilize stem cells into the peripheral blood. The increased proliferative activity is accompanied by increased blood flow to the bone marrow along with upregulation of glucose transport and metabolism (34). The effect of these agents on bone marrow uptake of FDG is both rapid and dramatic. In a series of 18 patients with melanoma and normal bone marrow, Yao et al. (34) reported that in patients receiving GM-CSF, the average glucose

Figure 12.3. A 9-year-old boy with newly diagnosed stage I B-cell non-Hodgkin's lymphoma (NHL). A: The initial PET scan was performed on an exceptionally cold winter day. Despite benzodiazepine (diazepam) pretreatment, there was extensive, intense FDG accumulation in the upper and lower cervical, supraclavicular, and pectoral regions bilaterally, as well as along the paravertebral regions of the thoracic spine. B: The PET scan was repeated 7 days later, using both diazepam and room temperature control. There is complete resolution of the activity seen in A. Faint anterior mediastinal activity represents thymic uptake of FDG. (No antineoplastic treatment was administered between the two studies.) Temperature control is useful in cases of benzodiazepine resistant BAT uptake of FDG.

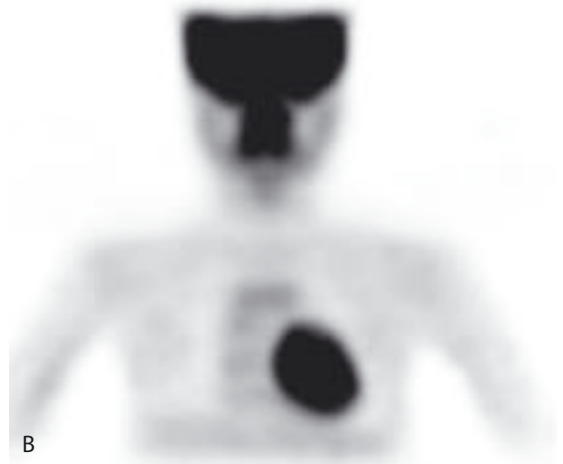
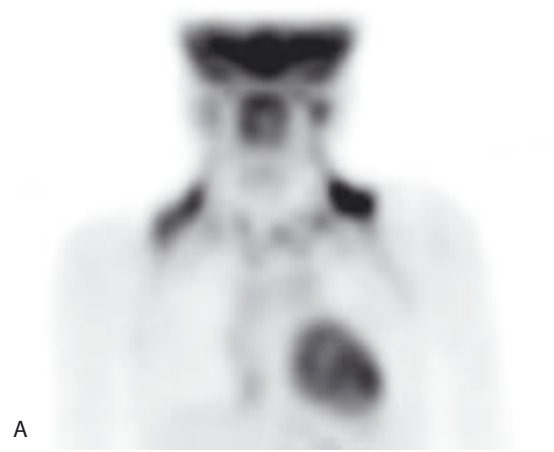
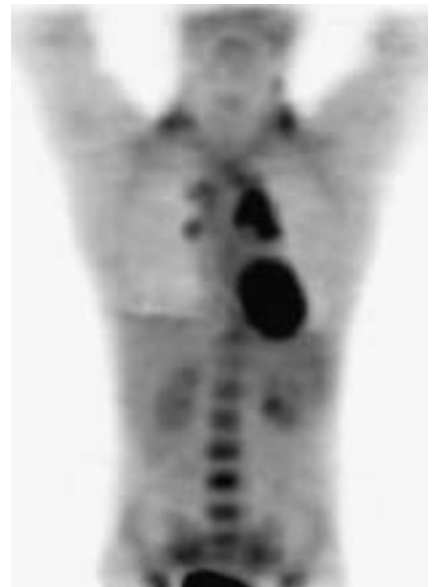Figure 12.4. A PET image of a 14-year-old girl with stage IIIA nodular sclerosing Hodgkin's disease (HD) shows disease in the neck, mediastinum, and abdomen. There is homogeneous, prominent marrow activity. Bone marrow biopsy was negative for disease. The bone marrow is a metabolically active organ, and diffusely increased FDG uptake reflects increased metabolism, and hence increased glucose consumption, in response to hematologic stress. This pattern should not be interpreted as indicative of diffuse marrow disease.



metabolic rate on the third day of treatment was 97% above baseline, and on the 10th day of treatment was an average of 170% above baseline. Three days after completion of GM-CSF therapy, the glucose metabolic rate of the marrow had decreased to 60% above baseline but remained elevated significantly above baseline for more than 3 weeks after cessation of treatment. In contrast, the magnitude of change was more modest in patients receiving macrophage-CSF (M-CSF), perhaps because granulocytes and their precursors comprise about 60% of the marrow versus only about 2% to 5% for monocytes/macrophages. Thus, diffusely increased marrow activity soon after CSF therapy should be recognized as a manifestation of hypermetabolic bone marrow, rather than diffuse metastatic disease.

Granulocyte colony-stimulating factor exerts similar effects on splenic uptake of FDG. Sugawara et al. (35) reported substantially increased FDG uptake by the spleen during and after G-CSF treatment in patients with locally advanced breast carcinoma. This increase was less frequent and less marked, however, than the changes in the bone marrow of the same patients (Fig. 12.5).

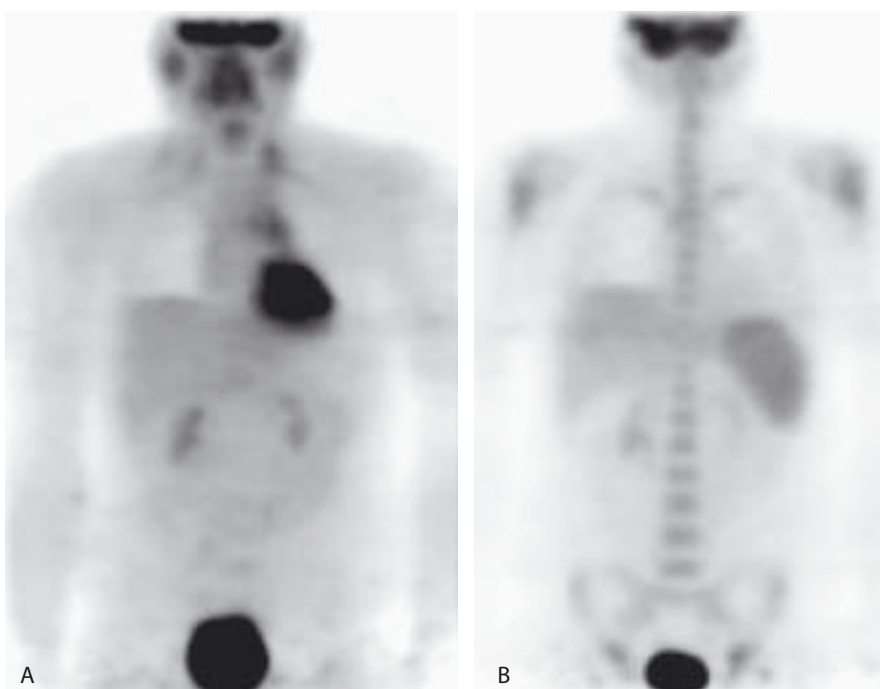


Figure 12.5. A 17-year-old boy with stage IIA nodular sclerosing Hodgkin's disease. A: Pretreatment PET demonstrates FDG uptake in the left neck and mediastinum. B: On the follow-up PET, performed after two cycles of chemotherapy, the neck and mediastinal abnormalities have resolved. There is homogeneously increased FDG activity in the bone marrow and spleen. Increased marrow and splenic activity, which is often observed after treatment in patients with lymphoma, is due to the effects of colony-stimulating factors on the hematopoietic system.

With the proliferation of cytokine use in patients with malignancies and with the increasing use of FDG-PET in oncology, hypermetabolic bone marrow is likely to be observed with increasing frequency and should not be confused with diffuse bone marrow disease. This physiologically increased bone marrow activity, unfortunately, results in increased background activity, which can potentially mask foci of disease. Thus, whenever possible, a sufficient amount of time between treatment and imaging should elapse to facilitate the differentiation of hypermetabolic from diseased marrow.

Initial Staging

Studies comparing imaging modalities in patients with lymphoma have common methodologic problems because biopsy is performed in only a small number of lymph nodes and thus histologic confirmation of results is limited. Typically, once the diagnosis is made, additional sites are biopsied only when the results of biopsy influence staging or treatment. These limitations notwithstanding, it has been shown that PET is a useful adjunct in the initial staging of lymphoma.

Nodal Staging

Newman et al. (36) compared PET and CT in thoracoabdominal lymphoma. They reported that PET identified a total of 54 sites of disease in the 16 patients studied, including all 49 sites identified by CT and five additional sites not identified on CT. In 60 patients with untreated lymphoma, Moog et al. (10) reported that both PET and CT were abnormal in 160 of the 740 sites evaluated. Seven of 25 additional sites detected only on PET were confirmed to be disease. There were two false-positive sites and 16 unresolved sites. Of six sites detected only on CT, three were false positives and three were unresolved. In this series, PET was more sensitive and specific than CT. Jerusalem et al. (37) compared PET and conventional nodal staging results in 60 patients. In this series PET identified additional nodal disease sites in 15 patients, including 10 with high-grade lymphoma. Conventional staging methods, CT, and physical examination detected PET-negative sites in 11 patients, seven of whom had low-grade lymphoma. These investigators concluded that PET is complementary to, and not a substitute for, conventional staging methods.

Recently, Rini et al. (38) compared PET and gallium imaging in children and young adults, 5 to 23 years old, with newly diagnosed, untreated HD. The PET studies were performed using a coincidence detection system with measured attenuation correction. Gallium imaging included planar whole-body imaging and single photon emission computed tomography (SPECT) from the top of the ears to the mid-thighs. There were 118 sites of nodal disease in this population, 105 (89%) of which were supradiaphragmatic. Positron emission tomography was slightly more sensitive overall (89%) than gallium (86%). Both tests were equally sensitive (89%) for supradi-

aphragmatic nodal disease. Not surprisingly, PET was more sensitive (77%, 10/13) than gallium (54%, 7/13) for infradiaphragmatic disease (Fig. 12.6).

Extranodal Staging

Moog et al. (39) compared PET and CT for detecting extranodal disease in 81 patients. The studies detected 42 extranodal sites; PET identified 19 sites that were not identified on CT. Fourteen of the sites were subsequently confirmed to be lymphoma: bone marrow (nine), spleen (three), other (two). There were seven extranodal lesions seen only on CT, only one of which proved to be diseased. There were five false-positive lesions, and one was not resolved. Jerusalem et al. (37) found a high rate of agreement between PET and CT in the liver, spleen, and digestive tract. In 30 patients with Hodgkin's disease, Rini et al. (38) found that PET detected 15 (75%) of 20 extranodal sites of disease, whereas gallium detected only seven (35%). Although the sensitivity of both tests was similar for lung and bone disease, PET was significantly more sensitive than gallium for detecting splenic disease (Fig. 12.6).

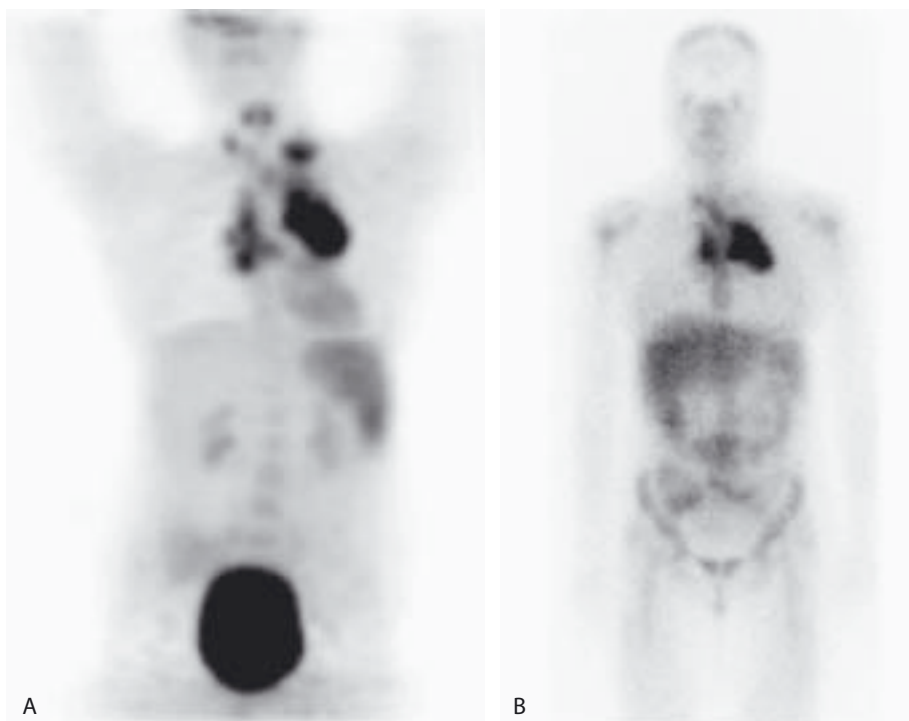


Figure 12.6. A 16-year-old girl with stage IVB nodular sclerosing HD and laparoscopically confirmed splenic disease. PET (A) shows extensive supraclavicular and mediastinal disease that also is well seen on gallium (B). Splenic disease is clearly seen on PET but not on gallium.

Based on available data, PET is superior to bone scintigraphy for detecting lymphomatous involvement of the bone. Moog et al. (40) studied 56 patients with both PET and bone scintigraphy. Skeletal involvement was detected by both methods in 12 patients. Positron emission tomography identified disease in an additional three patients with negative bone scans. Bone scintigraphy, in contrast, failed to detect any patients with osseous involvement who were not identified with PET (Fig. 12.7).

The results of PET for detecting lymphomatous involvement of the marrow have been variable. In one series, PET correctly identified only 13 of 21 (62% sensitivity) patients with biopsy-proven marrow involvement. Three patients with positive PET studies had negative biopsies (37). In another investigation, PET results agreed with marrow biopsy results in 39 of 50 (78%) patients. There were eight false-positive and three false-negative PET studies (41). In yet another series, PET and marrow biopsies were concordant in 64 (82%) of 78 patients, concordant and positive in seven patients, and concordant and negative in 57 patients. The two tests were discordant in 14 (18%) patients. Among the discordant results, PET was false negative in four patients and true positive in eight patients. In two patients, the discordant results were unresolved. Among the eight patients with true-positive PET/false-negative marrow biopsies, the abnormalities on the radionuclide study were focal and remote from the biopsy site (42). Thus, at the present time, PET is complementary to, but not a substitute for, marrow biopsy. Biopsy is probably more sensitive for diffuse marrow disease, whereas the radionuclide test is useful for identifying focal disease remote from the biopsy site.

Lymphomatous involvement of the spleen is characterized by one or more tumor nodules, often less than 1 cm in diameter. Although marked splenomegaly almost always indicates tumor involvement, lymphomatous spleens frequently are normal in size, and modestly enlarged spleens often do not contain tumor (43). Computed tomography, which traditionally has been used to evaluate the spleen, is associated with large numbers of false-positive and false-negative results, with reported accuracies ranging from 37% to 91% (44,45). Aygun et al. (46) reported that in 17 patients with HD who underwent staging laparotomy, the sensitivity and specificity of the CT-derived splenic index, for detecting splenic disease, were 50% and 66%, respectively. The positive and negative predictive values of the test were 57% and 60%, respectively. Indeed, for patients with lymphoma, in whom therapy would be altered if splenic disease were encountered, surgical evaluation of the spleen may be required. Because of the morbidity and potential complications associated with surgery, a noninvasive technique capable of reliably assessing the spleen in these patients would be of considerable value.

Recent studies have shown that PET accurately characterizes the spleen in patients undergoing initial staging of lymphoma. For patients with newly diagnosed, untreated HD or NHL, the presence of diffuse or focal splenic uptake of FDG more intense than hepatic uptake sug-

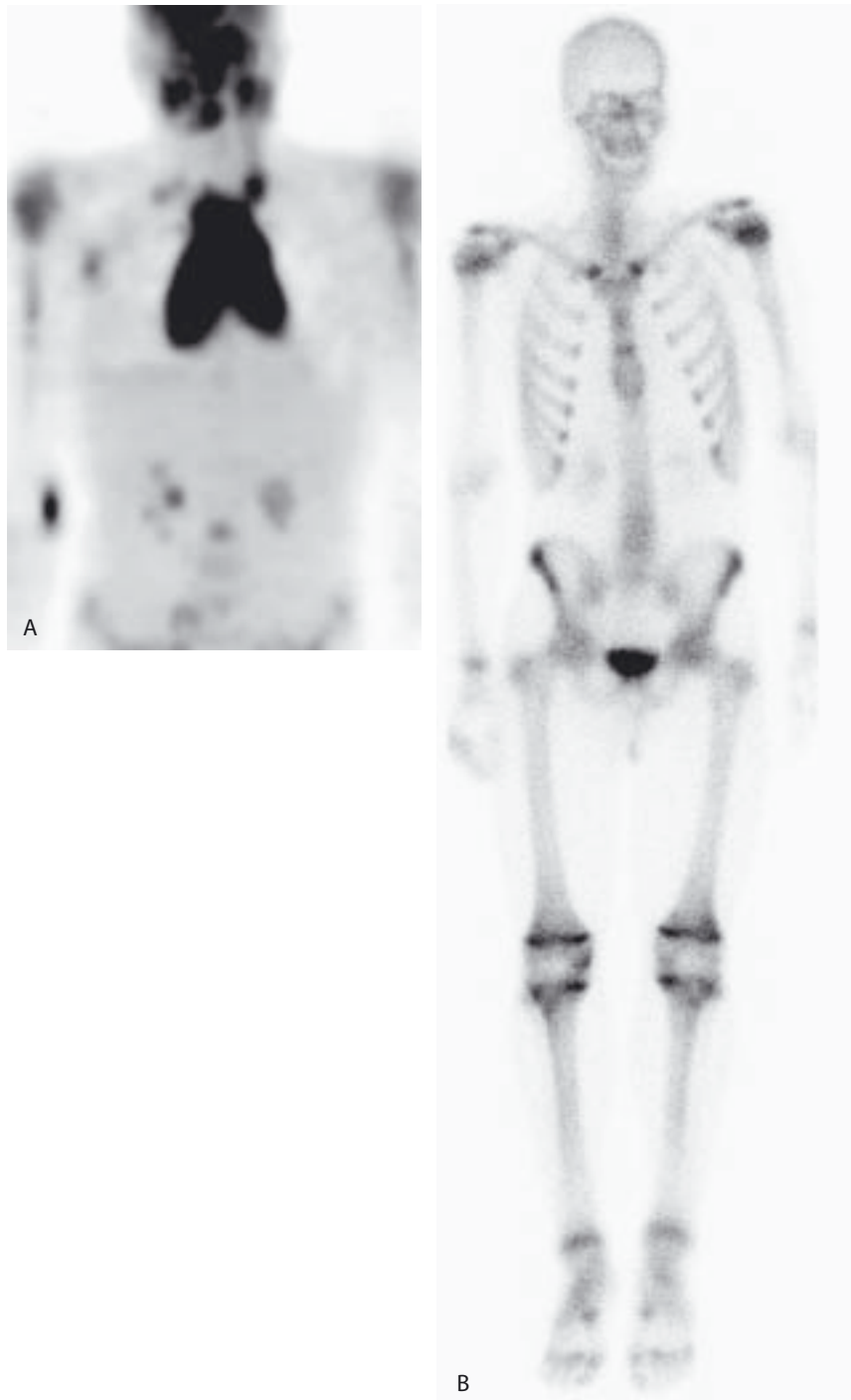


Figure 12.7. A 16-year-old boy with stage IV T-cell lymphoblastic lymphoma (same patient illustrated in Fig. 12.2). A: In addition to the FDG-avid soft tissue lesions on the PET scan, there are numerous bony lesions in the humeri, mid-lumbar spine and the pelvis. B: On the bone scan, however, only the proximal left humeral lesion is identified.

gests lymphomatous involvement (47,48). Application of these criteria to PET studies performed in children and adults with recently diagnosed HD or NHL yielded overall accuracies of 97% and 100% (47,48). Positron emission tomography was more accurate than CT (100% versus 57%) using a positive CT-derived splenic index or splenic hypodensities as the criterion for a positive CT scan (48). Positron emission tomography also was more accurate than gallium (97% versus 78%), with the criterion for a positive gallium study being splenic uptake of gallium at least as intense as hepatic uptake (47). In a series of 30 children and young adults with newly diagnosed HD, Rini et al. (38) reported that PET was significantly more accurate than gallium (93% versus 67%) for detecting splenic disease. Among four patients who underwent surgical staging (two with splenic disease and two without), the accuracy of PET was 100%. Gallium was negative in all four patients including both with splenic disease, for an accuracy of 50%. The CT-derived splenic index was correct in only one patient (25% accuracy). Computed tomography was false negative in one patient with disease and false positive in two patients without disease (Figs. 12.8 and 12.9).

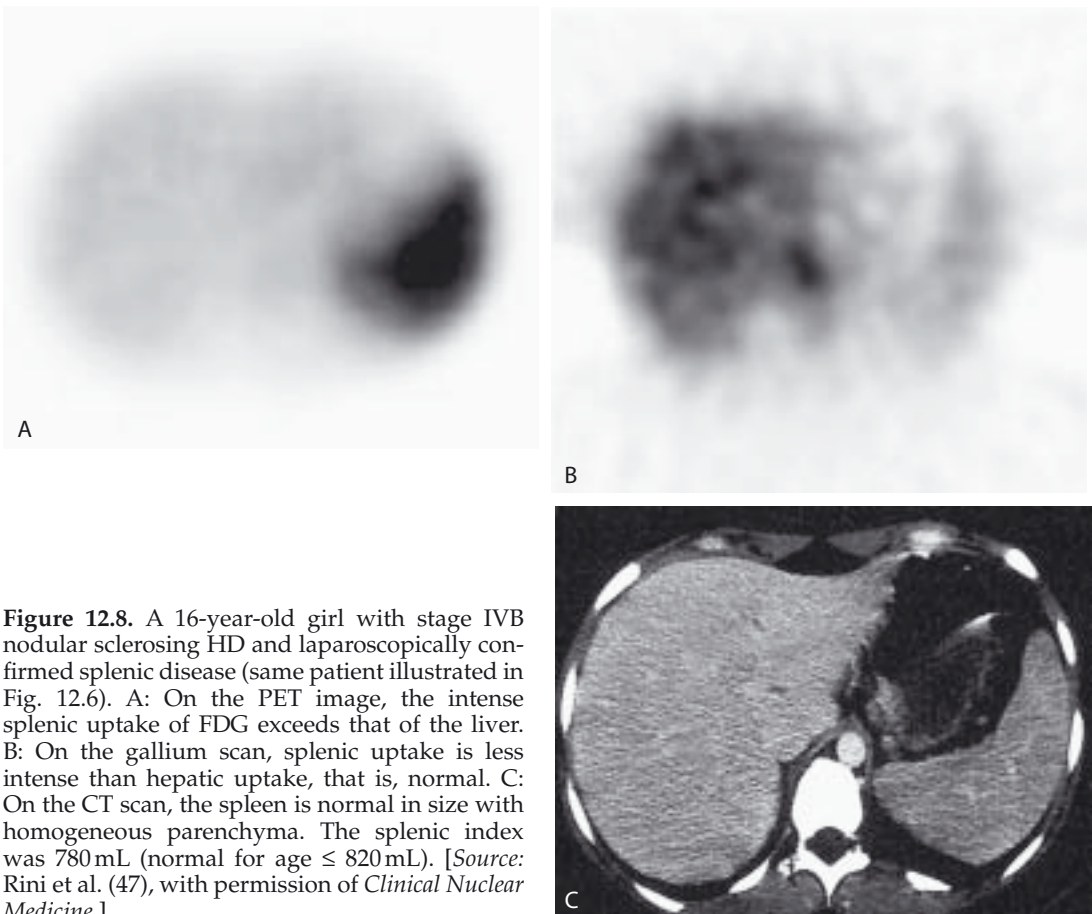


Figure 12.8. A 16-year-old girl with stage IVB nodular sclerosing HD and laparoscopically confirmed splenic disease (same patient illustrated in Fig. 12.6). A: On the PET image, the intense splenic uptake of FDG exceeds that of the liver. B: On the gallium scan, splenic uptake is less intense than hepatic uptake, that is, normal. C: On the CT scan, the spleen is normal in size with homogeneous parenchyma. The splenic index was 780 mL (normal for age \leq 820 mL). [Source: Rini et al. (47), with permission of *Clinical Nuclear Medicine*.]

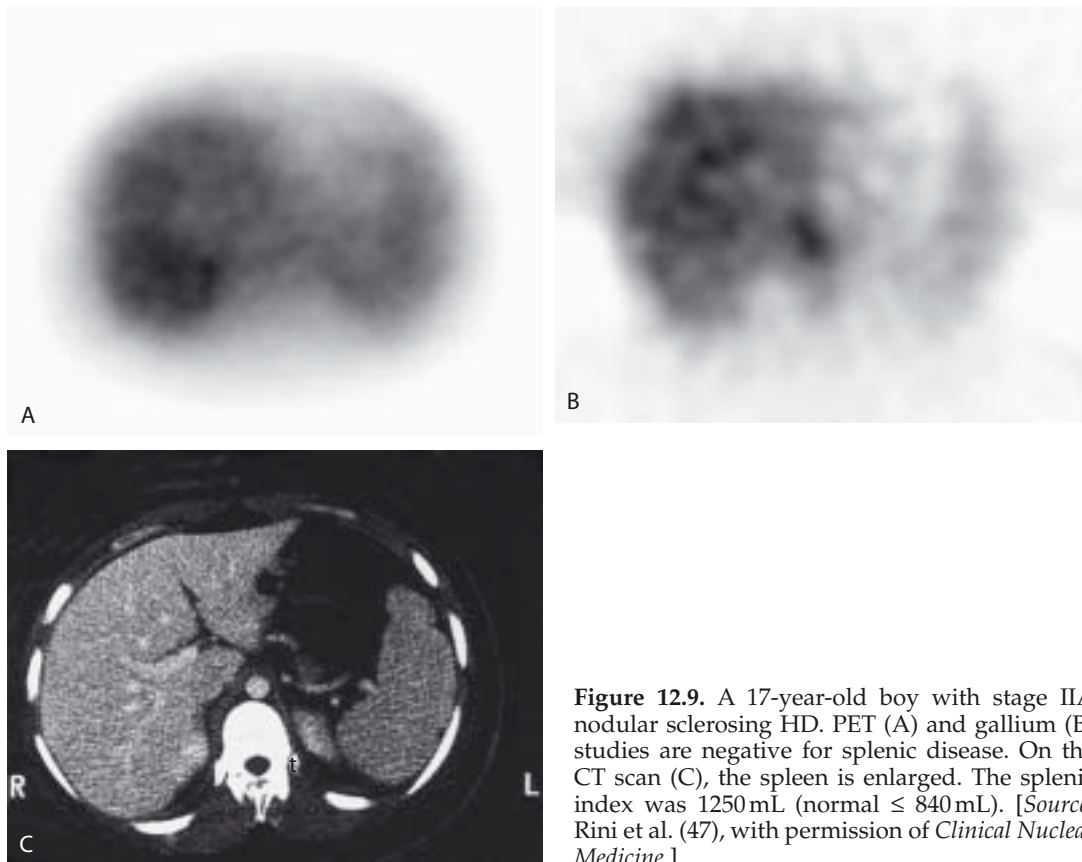


Figure 12.9. A 17-year-old boy with stage IIA nodular sclerosing HD. PET (A) and gallium (B) studies are negative for splenic disease. On the CT scan (C), the spleen is enlarged. The splenic index was 1250 mL (normal ≤ 840 mL). [Source: Rini et al. (47), with permission of *Clinical Nuclear Medicine*.]

With the development of increasingly sophisticated noninvasive diagnostic techniques, the need for surgical staging of lymphoma has decreased steadily. The use of PET to evaluate the spleen in patients undergoing initial staging of lymphoma may further reduce the need for surgical staging.

Monitoring the Response to Therapy

Response to Treatment after Completion of Therapy

Evaluation of the treatment response is an important part of the management of lymphoma. Accurate identification of residual viable tumor following completion of therapy facilitates the initiation of salvage therapy earlier in the course of the disease, rather than waiting for clinical evidence of disease relapse. Incomplete resolution of a lymphomatous mass after treatment is a significant problem in the patient with lymphoma. Although residual abnormalities occur in more than 60% of patients with lymphoma, viable tumor is present in less than 20% of these masses (49). There are no reliable CT or magnetic resonance imaging (MRI) criteria for differentiating residual disease from

fibrosis or necrosis. Gallium imaging has for many years been the standard imaging test for posttreatment evaluation of patients with lymphoma. There are data that suggest that PET may be superior to gallium for the posttreatment assessment of patients with lymphoma. The positive and negative predictive values of the test range between 70% and 100% and 83% and 100%, respectively. Cremerius et al. (50), in a study of 27 patients, found that PET correctly identified all 15 patients with residual disease or relapse, and 11 of 12 patients who remained disease-free; PET was significantly more accurate than CT in this population (Fig. 12.10).

Spaepen et al. (51) evaluated 93 patients with NHL after treatment. Nine patients with negative PET scans received additional therapy based on abnormal CT results. Fifty-eight patients with negative PET scans remained in complete remission during a median follow-up period of 21 months. Twenty-six patients had persistently abnormal PET scans at the end of treatment and all of them relapsed. It is important to note that in 14 (54%) of these 26 patients only PET demonstrated evidence of disease.

Jerusalem et al. (52) compared FDG-PET and CT in the posttreatment evaluation of patients with lymphoma. Residual masses were present on CT in 24 (44%) of 54 patients. All six patients in whom both PET and CT were abnormal relapsed, whereas only five of 19 patients with abnormal CT and normal PET scans relapsed. Three of 29 patients in whom CT and PET were both normal relapsed. The positive predictive values for relapse of PET and CT were 100% and 42%, respectively. These investigators also found that a positive PET scan after treatment was associated with poor survival. The 1-year progression-free survival of patients with positive PET studies after treatment was 0%, whereas the 1-year progression-free survival of patients with negative PET studies after treatment was 86%.

Guay et al. (53) reviewed the prognostic value of posttreatment PET in 48 patients with HD. These investigators found that the sensitivity and specificity of PET to predict relapse in the population studied were 79% and 97%, respectively, and the positive and negative predictive values of the test both were 92%. The 92% diagnostic accuracy of PET was significantly higher than the 56% diagnostic accuracy of CT.

Depas et al. (54) evaluated 16 children with lymphoma after completion of treatment. The PET studies were true negative in 15 patients and false positive in one patient (94% specificity). In contrast, conventional methods were false positive in seven patients (56% specificity).

Zinzani et al. (55) reviewed the results of 44 patients with abdominal lymphoma at the end of treatment. In this investigation, none of the seven patients with negative PET and negative CT scans relapsed. Twenty-four patients had abnormal CT scans and normal PET scans; only one relapsed. All 13 patients in whom both PET *and* CT scans were abnormal relapsed.

The results of these investigations illustrate the importance of including PET studies in the evaluation of patients following treatment of lymphoma. These data also suggest that it may be possible, on the basis of the combined results of PET and CT, to stratify patients into risk

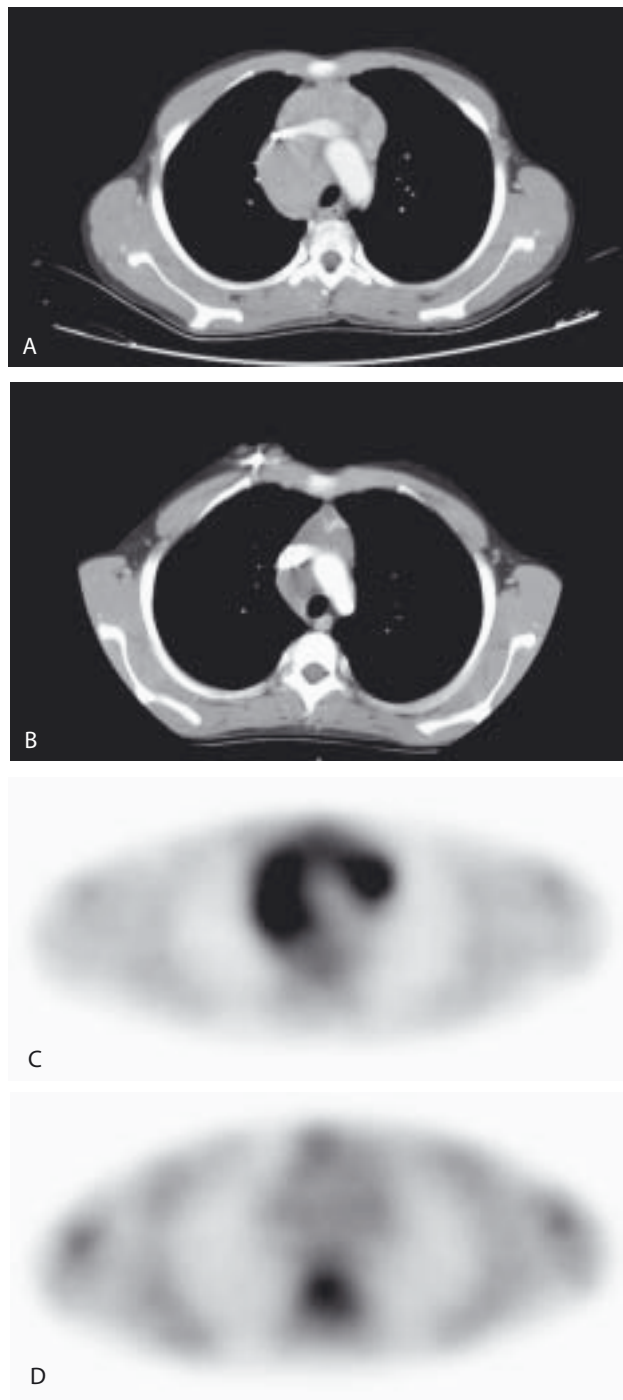


Figure 12.10. A 14-year-old boy with stage IIIB nodular sclerosing HD. A: Extensive mediastinal lymphadenopathy is present on the pretreatment CT scan. B: There is residual lymphadenopathy on the posttreatment CT scan, and it is not possible to differentiate persistent disease from fibrosis. C: There is extensive metabolically active disease on the pretreatment PET scan. D: There is complete resolution of the mediastinal activity on the posttreatment PET scan, however, confirming that the residual adenopathy present on the post-treatment CT scan did not contain viable tumor.

groups for relapse. Patients in whom both studies are abnormal would be at highest risk, whereas those in whom both studies were negative would be at lowest risk for relapse.

Neither PET nor any other currently available imaging technique can exclude the possibility of subsequent relapse, because of an inherent inability to detect microscopic foci of disease. Although the ability of PET to detect residual disease is now well documented, the benefits of additional therapies given on the basis of the PET findings remain to be determined. Finally, the effectiveness of FDG-PET to detect residual disease in the various subgroups of HD and NHL must also be determined.

Predicting Response During Therapy

Early recognition of ineffective treatment would allow prompt initiation of a potentially more effective therapeutic regimen. Initial studies indicate that, in patients with lymphoma, PET can distinguish responders from nonresponders early in the course of treatment (Fig. 12.11). Jerusalem et al. (56) evaluated patients after a median three courses of chemotherapy and found that all patients who had negative PET scans went into complete remission, whereas only one of five patients with persistent abnormal activity on PET scans went into complete remission. Hoekstra et al. (57) reported that PET scans were normal after two cycles of chemotherapy in patients who eventually achieved complete remission. Treatment failures, in contrast, were associated with high uptake on the PET scans, and a variable outcome was associated with low-level uptake. Although Romer et al. (58) observed markedly decreased tumor uptake as early as 7 days after commencement of chemotherapy, these investigators found that uptake at 42 days, just before the third cycle of chemotherapy, was a better predictor of long-term outcome than FDG uptake at 7 days. Kostakoglu et al. (59) reported that PET has a high prognostic value for evaluation of response after one cycle of therapy in aggressive NHL and HD. Ninety percent of patients with abnormal PET studies after one cycle of treatment had relapse of their disease, with a median progression-free survival of 5 months. Eighty-five patients with negative FDG-PET studies after one cycle remained in complete remission for at least 18 months. All but one patient who had abnormal PET scans after one cycle and after completion of therapy relapsed. Finally, in this investigation the relapse rate for patients with negative PET scans after completion of treatment was 35%, whereas in patients with negative PET scans after one cycle, the relapse rate was 15%.

Depas et al. (54) performed PET scans on 19 children at various times during treatment; PET was negative in all 19 patients. Three patients had an incomplete response to treatment, and PET failed to identify any of them.

In summary, in patients with lymphoma, PET is predictive of response to therapy after, as well as during, treatment. A negative PET result early in the course of treatment suggests that these patients could probably complete a full course of their first-line treatment. Patients

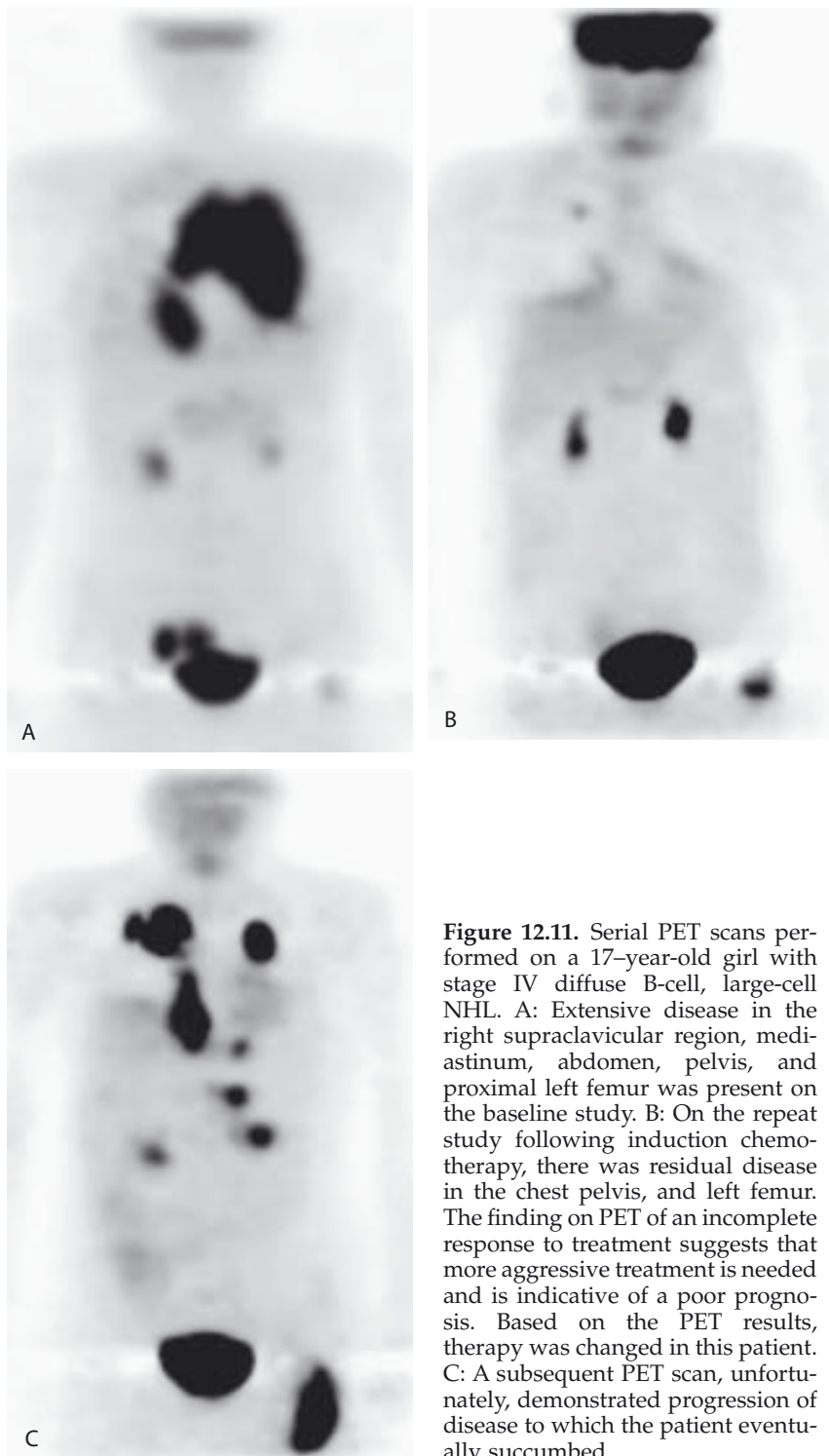


Figure 12.11. Serial PET scans performed on a 17-year-old girl with stage IV diffuse B-cell, large-cell NHL. A: Extensive disease in the right supraclavicular region, mediastinum, abdomen, pelvis, and proximal left femur was present on the baseline study. B: On the repeat study following induction chemotherapy, there was residual disease in the chest, pelvis, and left femur. The finding on PET of an incomplete response to treatment suggests that more aggressive treatment is needed and is indicative of a poor prognosis. Based on the PET results, therapy was changed in this patient. C: A subsequent PET scan, unfortunately, demonstrated progression of disease to which the patient eventually succumbed.

with positive PET results during treatment have a less favorable prognosis and could be switched to more aggressive therapy, including stem cell transplantation, sooner, with the hope of achieving a more favorable outcome.

Routine Follow-Up in Asymptomatic Patients

Few data are available on the role of PET in the routine follow-up of asymptomatic patients after treatment. Depas et al. (54) reviewed the results of 59 PET scans performed in 19 children with lymphoma who were in long-term remission. Fifty-six of the 59 studies were true negative, and three were false positive: atrial uptake, asymmetric thymic uptake, and axillary adenitis. In contrast there were 20 false-positive results using conventional methods.

In a series of 36 patients with HD, patients were imaged at 4- to 6-month intervals for up to 3 years after completion of therapy (60). Patients who demonstrated abnormal FDG accumulation underwent repeat PET imaging 4 to 6 weeks later. One patient had residual disease and four patients relapsed. All five were detected with PET prior to their detection with clinical examination, laboratory tests, or CT. Six patients had false-positive PET scans, but the confirmatory PET scan was always negative. These investigators concluded that PET could help identify patients needing salvage chemotherapy prior to the appearance of clinically overt disease.

Conclusion

Fluorodeoxyglucose-PET is a powerful new tool in the management of children with lymphoma. It is complementary to conventional imaging studies in the staging of the disease, and it is extremely useful for monitoring response to therapy. Although more investigation is needed, this technique at the end of therapy can, together with CT, potentially stratify patients into risk groups for relapse. Equally exciting is the potential ability of FDG-PET to identify nonresponders early in the course of their treatment, facilitating a change in their management sooner rather than later, with the anticipation of improved survival.

References

1. Jemal A, Tiwari RC, Murray T, et al. Cancer statistics, 2004. *CA Cancer J Clin* 2004;54:8–25.
2. Bleyer A. Older adolescents with cancer in North America: deficits in outcome and research. *Pediatr Clin North Am* 2004;49:1027–1042.
3. Kennedy BJ, Fremgen AM, Menck HR. Hodgkin's disease survival by stage and age. *J Am Geriatr Soc* 2000;48:315–317.
4. Lister TA, Crowther D, Sutcliffe SB, et al. Report of a committee convened to discuss the evaluation and staging of patients with Hodgkin's Disease: Cotswolds Meeting. *J Clin Oncol* 1989;7:1630–1636.
5. Moog F, Bangerter M, Diederichs CG, et al. Lymphoma: role of whole-body 2-deoxy-2-[F-18]fluoro-D-glucose (FDG) PET in nodal staging. *Radiology* 1997;203:795–800.

6. Percy CL, Smith MA, Linet M, et al. Lymphoma and reticuloendothelial neoplasms, In: Ries LA, Smith MA, Gurney JG, et al., eds. *Cancer Incidence and Survival Among Children and Adolescents: US SEER Program 1975–1995*. NIH Publication No. 99–4649. Bethesda, MD: National Cancer Institute, 1999:35–50.
7. Harris N, Jaffe E, Stein H, et al. A revised European-American classification of lymphoid neoplasms: a proposal from the International Study Group. *Blood* 1994;84:1361–1392.
8. Harris N, Jaffe E, Diebold J, et al. World Health Organization classification of neoplastic diseases of the hematopoietic and lymphoid tissues: report of the clinical advisory committee meeting—Airlie House, Virginia, November 1997. *J Clin Oncol* 1999;17:3835–3849.
9. Murphy SB, Fairclough DL, Hutchison RE, et al: Non-Hodgkin's lymphomas of childhood: an analysis of the histology, staging, and response to treatment of 338 cases at a single institution. *J Clin Oncol* 1989;7:186–193.
10. Moog F, Bangerter M, Diederichs CG, et al. Lymphoma: role of whole-body 2–deoxy-2-[F-18]fluoro-D-glucose (FDG) PET in nodal staging. *Radiology* 1997;203:795–800.
11. Kostakoglu L, Goldsmith SJ. Fluorine-18 fluorodeoxyglucose positron emission tomography in the staging and follow-up of lymphoma: is it time to shift gears? *Eur J Nucl Med* 2000;27:1564–1578.
12. Rehm PK. Radionuclide evaluation of patients with lymphoma. *Radiol Clin North Am* 2001;39:957–978.
13. Parkhurst JB, Foster P, Johnson SF, et al. Upstaging of non-Hodgkin's lymphoma in a child based on 67 gallium scintigraphy. *J Pediatr Hematol Oncol* 1998;20:174–176.
14. Anderson KC, Leonard RC, Canellos GP, et al. High-dose gallium imaging in lymphoma. *Am J Med* 1983;75:327–331.
15. Hoh CK, Glaspy J, Rosen P, et al. Whole-body FDG-PET imaging for staging of Hodgkin's disease and Lymphoma. *J Nucl Med* 1997;38:343–348.
16. Parslow TG. Lymphocytes and lymphoid tissue. In: Sites DP, Terr AI, Parslow TG, eds. *Basic and Clinical Immunology*. Norwalk, CT: Appleton and Lange, 1994:22–40.
17. Francis IR, Glazer GM, Bookstein FL, et al. The thymus: reexamination of age-related changes in size and shape. *AJR* 1984;145:249–254.
18. Baron RL, Lee JKT, Sagel SS, et al. Computed tomography of the normal thymus. *Radiology* 1982;142:121–125.
19. Ferdinand B, Gupta P, Kramer EL. Spectrum of thymic uptake at 18F-FDG PET. *RadioGraphics* 2004;24:1611–1616.
20. Brink I, Reinhardt MJ, Hoegerle S, et al. Increased metabolic activity in the thymus studied with FDG PET: age dependency and frequency after chemotherapy. *J Nucl Med* 2001;42:591–595.
21. Nakahara T, Fujii H, Ide M, et al. FDG uptake in the morphologically normal thymus: comparison of FDG positron emission tomography and CT. *Br J Radiol* 2001;74:821–824.
22. Rini JN, Leonidas JC, Tomas MB, Chen B, Karaylcin G, Palestro CJ. ¹⁸F-FDG uptake in the anterior mediastinum: Physiologic thymic uptake or disease? *Clin Positron Imaging* 2000;3:115–125.
23. Barrington SF, Maisey MN. Skeletal muscle uptake of fluorine-18-FDG: effect of oral diazepam. *J Nucl Med* 1996;37:1127–1129.
24. Cohade C, Osman M, Pannu HK, et al. Uptake in supraclavicular area fat ("USA-Fat"): description on 18F-FDG PET/CT. *J Nucl Med* 2003;44:170–176.

25. Hany T, Gharehpapagh E, Kamel E, et al. Brown adipose tissue: a factor to consider in symmetrical tracer uptake in the neck and upper chest region. *Eur J Nucl Med Mol Imaging* 2002;29:1393–1398.
26. Yeung HWD, Grewal RK, Gonen M, et al. Patterns of ¹⁸F-FDG uptake in adipose tissue and muscle: a potential source of false-positives for PET. *J Nucl Med* 2003;44:1789–1796.
27. Himms-Hagen J. Thermogenesis in brown adipose tissue as an energy buffer. *N Engl J Med* 1984;311:1549–1558.
28. Anholt R, de Souza E, Oster-Granite M, Snyder S. Peripheral-type benzodiazepine receptors: autoradiographics localization in whole-body sections of neonatal rats. *J Pharmacol Exp Ther* 1985;233:517–526.
29. Hirsch J. Pharmacological and physiological properties of benzodiazepine binding sites in rodent brown adipose tissue. *Comp Biochem Physiol [C]* 1984;77:339–343.
30. Garcia CA, Van Nostrand D, Majd M, et al. Benzodiazepine-resistant “brown fat” pattern in positron emission tomography: two case reports of resolution with temperature control. *Mol Imaging Biol* 2004;6:368–372.
31. Tatsumi M, Engles JM, Ishimori T, et al. Intense ¹⁸F-FDG uptake in brown fat can be reduced pharmacologically. *J Nucl Med* 2004;45:1189–1193.
32. Nunez RF, Rini JN, Tronco GG, et al. Correlacion de los parametros hematologicos con la captacion de FDG en medula osea y bazo en la PET. *Rev Esp Med Nucl* 2005;24:107–112.
33. Sugawara Y, Fisher SJ, Zasadny KR, et al. Preclinical and clinical studies of bone marrow uptake of fluorine-1-fluorodeoxyglucose with or without granulocyte colony-stimulating factor during chemotherapy. *J Clin Oncol* 1998;16:173–180.
34. Yao W-J, Hoh CK, Hawkins RA, et al. Quantitative PET imaging of bone marrow glucose metabolic response to hematopoietic cytokines. *J Nucl Med* 1995;36:794–799.
35. Sugawara Y, Zasadny KR, Kison PV, et al. Splenic fluorodeoxyglucose uptake increased by granulocyte colony-stimulating factor therapy: PET imaging results. *J Nucl Med* 1999;40:1456–1462.
36. Newman JS, Francis IR, Kaminski MS, et al. Imaging of lymphoma with PET with 2-[F-18]-fluoro-2-deoxy-D-glucose: correlation with CT. *Radiology* 1994;190:111–116.
37. Jerusalem G, Warland V, Najjar F, et al. Whole-body ¹⁸F-FDG PET for the evaluation of patients with Hodgkin’s disease and non-Hodgkin’s lymphoma. *Nucl Med Commun* 1999;20:13–20.
38. Rini JN, Nunez R., Nichols K, et al. Coincidence-detection FDG-PET versus gallium in children and young adults with newly diagnosed Hodgkin’s Disease. *Pediatr Radiol* 2005;35:169–178.
39. Moog F, Bangerter M, Diederichs CG, et al. Extranodal malignant lymphoma: detection with FDG PET versus CT. *Radiology* 1998;206:475–481.
40. Moog F, Kotzerke J, Reske SN. FDG PET can replace bone scintigraphy in primary staging of malignant lymphoma. *J Nucl Med* 1999;40:1407–1413.
41. Carr R, Barrington SF, Madan B, et al. Detection of lymphoma in bone marrow by whole-body positron emission tomography. *Blood* 1998;91:3340–3346.
42. Moog F, Bangerter M, Kotzerke J, et al. ¹⁸F-fluorodeoxyglucose-positron emission tomography as a new approach to detect lymphomatous bone marrow. *J Clin Oncol* 1998;16:603–609.
43. Castellino RA. Hodgkin disease: practical concepts for the diagnostic radiologist. *Radiology* 1986;159:305–310.

44. Strijk SP, Wagener DJ, Bogman MJ, et al. The spleen in Hodgkin disease: diagnostic value of CT. *Radiology* 1985;154:753–757.
45. Munker R, Stengel A, Stabler A, Hiller E, Brehm G. Diagnostic accuracy of ultrasound and computed tomography in the staging of Hodgkin's disease. Verification by laparotomy in 100 cases. *Cancer* 1995;76:1460–1466.
46. Aygun B, Karakas SP, Leonidas J, et al. Reliability of splenic index to assess splenic involvement in pediatric Hodgkin's Disease. *J Pediatr Hematol Oncol* 2004;26:74–76.
47. Rini JN, Manalili EY, Hoffman MA, et al. The utility of 18FDG and 67Ga for the detection of splenic involvement in Hodgkin's disease. *Clin Nucl Med* 2002;27:572–577.
48. Rini JN, Leonidas JC, Tomas MB, et al. FDG PET versus CT for evaluating the spleen during initial staging of lymphoma. *J Nucl Med* 2003;44:1072–1074.
49. Kostakoglu L, Goldsmith SJ. 18F-FDG PET for evaluation of the response to therapy for lymphoma, and for breast, lung, and colorectal carcinoma. *J Nucl Med* 2003;44:224–239.
50. Cremerius U, Fabry U, Neuerburg J, et al. Positron emission tomography with 18F-FDG to detect residual disease after therapy for malignant lymphoma. *Nucl Med Commun* 1998;19:1055–1063.
51. Spaepen K, Stroobants S, Dupont P, et al. Prognostic value of positron emission tomography (PET) with fluorine-18 fluorodeoxyglucose ([18F]FDG) after first-line chemotherapy in non-Hodgkin's lymphoma: is [18F]FDG-PET a valid alternative to conventional diagnostic methods? *J Clin Oncol* 2001;19:414–419.
52. Jerusalem G, Beguin Y, Fassotte MF, et al. Whole-body positron emission tomography using 18F-fluorodeoxyglucose for posttreatment evaluation in Hodgkin's disease and non-Hodgkin's lymphoma has higher diagnostic and prognostic value than classical computed tomography scan imaging. *Blood* 1999;94:429–433.
53. Guay C, Lepine M, Verreault J, et al. Prognostic value of PET using 18F-FDG in Hodgkin's disease for posttreatment evaluation. *J Nucl Med* 2003;44(8):1225–1231.
54. Depas G, De Barsey C, Jerusalem G, et al. 18F-FDG PET in children with lymphomas. *Eur J Nucl Med Mol Imaging* 2005;32:31–38.
55. Zinzani PL, Magagnoli M, Chierichetti F, et al. The role of positron emission tomography (PET) in the management of lymphoma patients. *Ann Oncol* 1999;10:1181–1184.
56. Jerusalem G, Beguin Y, Fassotte MF, et al. Persistent tumor 18F-FDG uptake after a few cycles of polychemotherapy is predictive of treatment failure in non-Hodgkin's lymphoma. *Haematologica* 2000;85:613–618.
57. Hoekstra OS, Ossenkoppele GJ, Golding R, et al. Early treatment response in malignant lymphoma, as determined by planar fluorine-18-fluorodeoxyglucose scintigraphy. *J Nucl Med* 1993;34:1706–1710.
58. Romer W, Hanauske AR, Ziegler S, et al. Positron emission tomography in non-Hodgkin's lymphoma: assessment of chemotherapy with fluorodeoxyglucose. *Blood* 1998;91:4464–4471.
59. Kostakoglu L, Coleman M, Leonard JP, et al. PET predicts prognosis after 1 cycle of chemotherapy in aggressive lymphoma and Hodgkin's disease. *J Nucl Med* 2002;43:1018–1027.
60. Jerusalem G, Beguin Y, Fassotte MF, et al. Early detection of relapse by whole-body positron emission tomography in the follow-up of patients with Hodgkin's disease. *Ann Oncol* 2003;14:123–130.



<http://www.springer.com/978-0-387-28836-9>

Pediatric PET Imaging

Charron, M. (Ed.)

2006, XXIV, 575 p., Hardcover

ISBN: 978-0-387-28836-9