

CHAPTER 2

Histology of Epithelial Skin Tumors

Jörg Reichrath* and Kerstin Querings

Squamous Cell Carcinoma

Squamous Cell Carcinoma in Situ

Actinic Keratosis (Squamous Cell Carcinoma in Situ, Type Actinic Keratosis;

Synonym: Solar Keratosis, Senile Keratosis)

Although this topic is still a matter of debate, actinic keratoses can now be considered to represent early squamous cell carcinomas in situ.¹⁻⁴ However, it appears that only a small proportion of actinic keratoses will develop into an invasive squamous cell carcinoma. Regression of some cases of actinic keratoses has also been reported, most likely as a result of immune mechanisms.⁵ Metastases after transformation of actinic keratosis into invasive squamous cell carcinoma are very rare except for those tumors that arise on the ear, lip, anus and vulva, which have been reported to be often associated with a more aggressive behaviour.⁶ Actinic keratoses are characterized by dysplasia of varying degree (from mild changes through to typical carcinoma in situ), predominantly in keratinocytes of the interadnexal epidermis (Fig. 1). Parakeratosis is usually present. Variants of actinic keratosis include the hyperplastic, the proliferating, the atrophic, the acantholytic, the epidermolytic and the bowenoid subtype. The dermis underlying and adjacent to actinic keratoses typically shows the presence of ectatic vessels and solar elastosis.^{7,8}

Bowen's Disease (Squamous Cell Carcinoma in Situ, Type Bowen's Disease)

In Bowen's disease, the epidermis typically shows full thickness dysplasia resembling carcinoma in situ, which involves keratinocytes of the entire epidermis including the intraepidermal portions of the cutaneous adnexae (Fig. 2). In addition, very large atypical cells (Bowen's cells) and bizarre mitoses⁷ are usually found (Fig. 2). Characteristically, the stratum corneum is thickened and parakeratosis with diminished or absent stratum granulosum is present. The parakeratotic scales may show prominent and hyperchromatic nuclei. Occasionally, lesions may be markedly glycogenated and verrucous architectural characteristics may also be observed. In many cases, the superficial dermis adjacent to and underlying the tumor shows prominently dilated and proliferating vessels, fibrosis, and a chronic inflammatory infiltrate. The latter is likely to represent a localized immune response.⁷⁻⁹ Progression towards invasive carcinoma (Bowen's carcinoma) has been reported to be relatively uncommon, occurring in approximately 5% of patients.⁸ Of these roughly 30% have been reported to have metastatic potential.⁸ Bowen's disease affecting the penis is referred to as erythroplasia of Queyrat.¹⁰ In a large series of more

*Corresponding Author: Jörg Reichrath—The Saarland University Hospital, Clinic for Dermatology, Allergology and Venerology, Kirrbergerstr., D-66421 Homburg/Saar, Germany. Email: hajrei@uniklinik-saarland.de

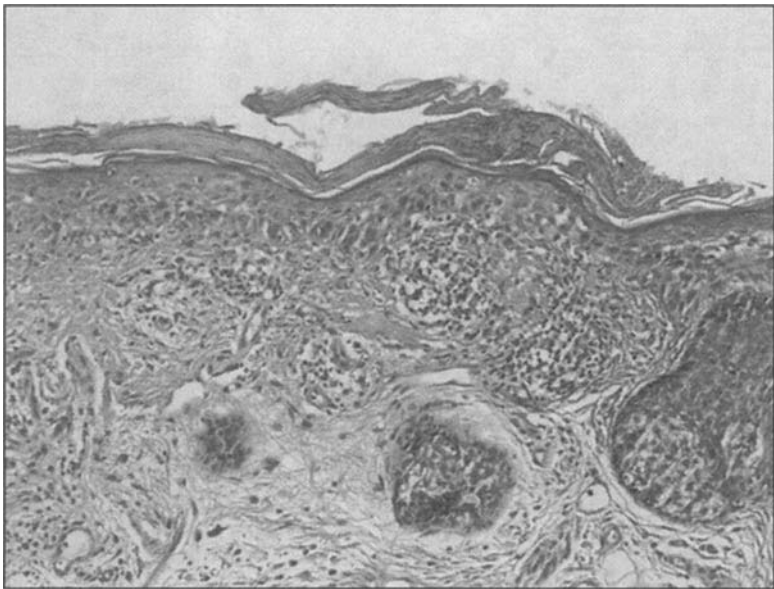


Figure 1. Actinic keratosis (HE-stain, original magnification x200).

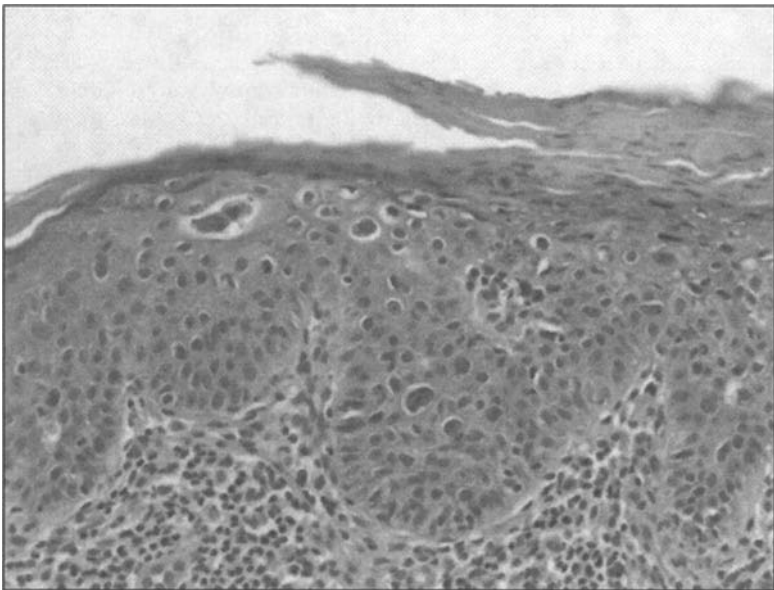


Figure 2. Bowen's disease (HE-stain, original magnification x400).

than 100 cases with erythroplasia of Queyrat, 22% recurred, 8% progressed to invasive tumor and 2% metastasised.¹¹

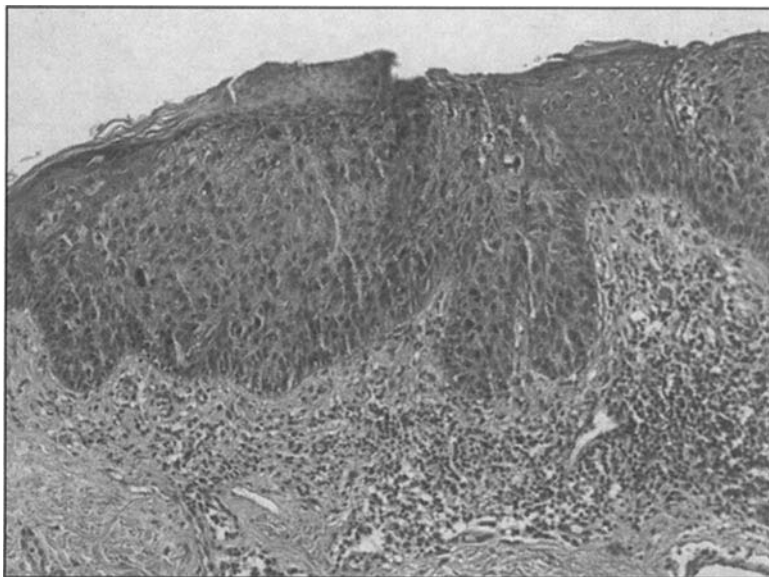


Figure 3. Superficial cutaneous squamous cell carcinoma (HE-stain, original magnification x200).

Invasive Squamous Cell Carcinoma

Squamous cell carcinoma (Fig. 3) is an invasive malignant tumor of epidermal keratinocytes, that retains variable characteristics of uninvolved suprabasal epidermis. In most cases, the tumor arises from an dysplastic epithelium resembling actinic keratosis (in situ carcinoma) and presents as infiltrating sheets and islands of variably differentiated squamous epithelium. Although the in situ forms may give rise to invasive lesions, an in situ stage is not necessary for the development of invasive squamous cell carcinoma.⁹ Degree of mitotic activity and cell pleomorphism of tumor cells may vary. Differentiation is towards keratinisation, that typically results in the formation of so called keratin “pearls”, horn cysts and/or scattered keratinised cells. Squamous cell carcinomas can be classified into well differentiated, moderately differentiated and poorly differentiated tumors. Alternatively, Broders system of classification, based on four grades of differentiation, has been used: grade 1 – 75% or more of the lesion well differentiated; grade 2 – 50% or more well differentiated; grade 3 – 25%-50% well differentiated; grade 4 – less than 25% well differentiated.¹² Variants of squamous cell carcinoma include clear cell, spindle cell, acantholytic, and verrucous squamous carcinoma as well as lymphoepithelioma-like carcinoma and Bowen’s carcinoma.^{8,9,13}

In general, poorly differentiated tumors recur and metastasize more frequently than well differentiated variants.⁸ Neurotropism is associated with high recurrence and metastasis rates.⁸ Perineural spread is particularly common in tumors arising on the head and neck, especially the lip and mid-face. In a large series of such cases, 14% of tumors showed involvement of the perineural space, particularly spindle cell and acantholytic variants.¹⁴

Although the genesis of invasive squamous cell carcinoma of the skin is considered to be a complex, multistage process, it has been demonstrated that mutations in the tumor suppressor gene p53 and in the Ha-ras gene are of high importance for the cancerogenesis of squamous cell carcinomas.^{15,16} Recent work on human epidermis reveals that sustained Ras signaling coupled with suppression of Ras-induced growth arrest is sufficient to drive the entire process of squamous cell carcinogenesis and that the $\alpha 6 \beta 4$ integrin and its laminin 5 ligand are essential components of this process.¹⁶ Additionally, a connection between development of epidermal p53 clones and squamous cell carcinomas has been suggested.¹⁷ It has been

demonstrated that reduced levels of apoptotic cells in squamous cell but not in basal cell carcinomas correlate with the detection of cutaneous human papillomavirus.¹⁸ Interestingly, different expression patterns of calpain isozymes 1 and 2 (CAPN1 and 2) have been detected in squamous cell carcinomas and basal cell carcinomas.¹⁹ Calpain, also named CAPN (for calcium-activated neutral protease), is an ubiquitous intracellular cytoplasmic nonlysosomal cysteine endopeptidase that requires calcium ions to exert its activity. Many known substrates of the different calpain isoenzymes, such as the transcription factors c-Fos and c-Jun, the tumour suppressor protein p53, protein kinase C, pp60src, or the adhesion molecule integrin, have been implicated in the pathogenesis of squamous and basal cell carcinomas, suggesting an important role of the calpain isoenzymes in these diseases. CAPN1 immunoreactivity is markedly reduced in basal cell carcinomas compared to normal human skin or squamous cell carcinomas, while in contrast CAPN1 mRNA levels are markedly elevated in basal cell carcinomas and squamous cell carcinomas compared to normal human skin. No differences are found analysing CAPN2 protein and mRNA expression in normal human skin, basal cell carcinomas and squamous cell carcinomas.¹⁹ Increasing evidence indicates that, besides other factors, the vitamin D system is of importance for the growth characteristics of cutaneous squamous cell carcinomas.²⁰ Expression of vitamin D receptor (VDR) and of the main enzymes involved in the metabolism and catabolism of the biologically active vitamin D metabolite, 1,25-dihydroxyvitamin D₃ (vitamin D-25-hydroxylase (25-OHase), 25-hydroxyvitamin D-1alpha-hydroxylase (1alpha-OHase), and 1,25-dihydroxyvitamin D-24-hydroxylase (24-OHase)) was detected in squamous cell carcinomas. Modulation of VDR expression and local synthesis or metabolism of vitamin D metabolites may be of importance for growth characteristics of squamous cell carcinomas.

Keratoacanthoma

Keratoacanthomas can be described as fastly growing, if left untreated often spontaneously regressing tumors. However, one has to keep in mind that perineural invasion²¹ and in very rare cases intravascular spread²² have been reported. In most cases, these tumors affect sun-exposed hair follicle-bearing skin of elderly individuals and they mimic clinically and histopathologically well-differentiated squamous cell carcinomas. Although this topic is still a matter of debate, keratoacanthomas can therefore be considered as a histologic variant of squamous cell carcinoma with distinctive clinical and pathologic attributes.^{23,24,25} Recently, it has been reported that analysis of telomerase activity, COX-2, and p53 expression provide evidence that keratoacanthoma and squamous cell carcinoma are indeed distinct entities and that this analysis may also help in discriminating these two lesions, which may closely resemble each other on conventional morphology.²⁶ Additionally, amphiregulin overexpression has been demonstrated in keratoacanthomas (21 of 21 positive, strong immunoreactivity) and conventional squamous cell carcinomas (5 of 6 positive, in general weak staining) while all basal cell carcinomas (6 of 6) analyzed in that study were negative.²⁷ Interestingly, it has been reported that expression of VCAM (CD-106) and ICAM (CD-54) adhesion molecules²⁸ and the level of syndecan-1²⁹ may distinguish keratoacanthomas from cutaneous squamous cell carcinomas. In contrast, MIB-1 immunohistometry, although presenting insights into the proliferative potential of keratoacanthomas and conventional squamous cell carcinomas, has been shown to be of only limited value for the differential diagnosis of the two lesions in routine surgical pathology.³⁰ In general, keratoacanthomas are characterized by a distinctive histologic architecture and, at least in most cases, by spontaneous regression. Typically, these tumors represent an exophytic and endophytic neoplasm with a typical cup-shape that is sharply demarcated from the surrounding epidermis and dermis. The center of the tumor is characterized by a crater that is filled with eosinophilic laminated orthokeratotic scale. This crater is in most cases partially enclosed by a well defined lip that forms the superficial border of the neoplasm. The epithelium of the lip may be hyperplastic, but there is usually no evidence of dysplasia or actinic keratosis in the epithelium adjacent to the tumor.^{9,4,25}

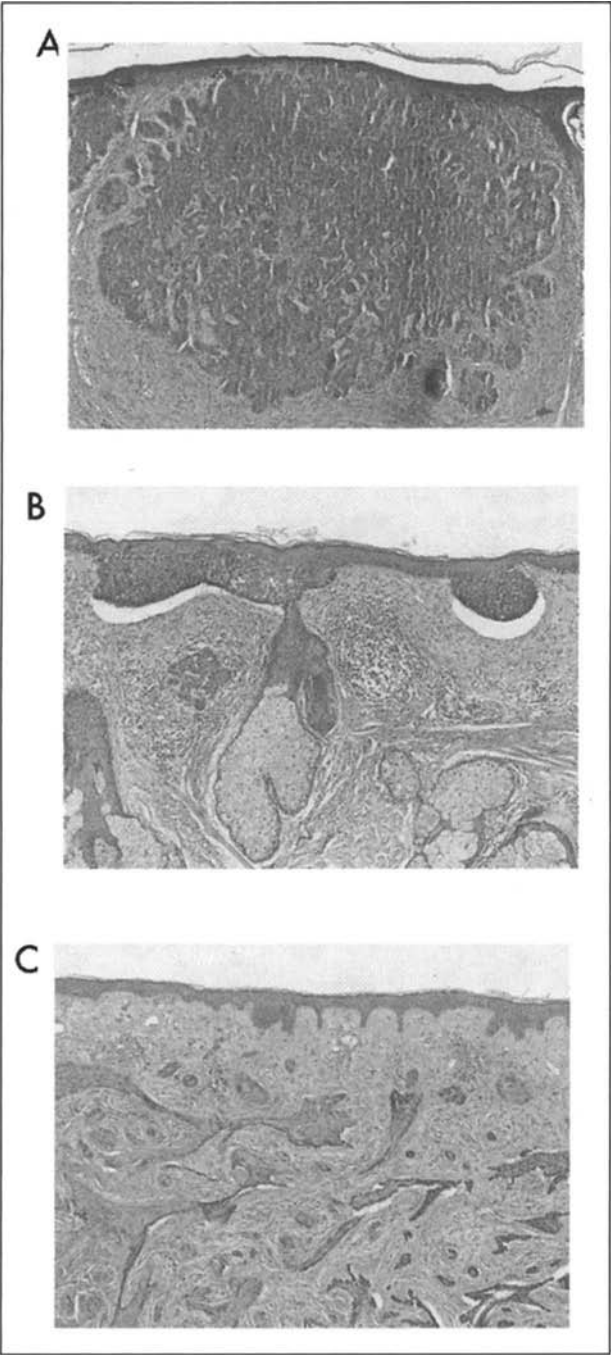


Figure 4. Basal cell carcinoma (HE-stain, original magnification x100; A: nodular, B: superficial, C: sclerosing variants).

Basal Cell Carcinoma

Basal cell carcinomas (Fig. 4) are tumors with in general nonmetastasizing behavior that derive from undifferentiated pluripotent epithelial stem cell. They are typically characterized by a fibrous stroma surrounding islands of dependent tumor cells that resemble keratinocytes of the basal layer of the epidermis or hair follicle (Fig. 4). Usually, these tumor cells are fairly regular with rounded haematoxyphilic nuclei and little cytoplasm. Typically, the proliferating cell component of the tumor is found predominantly in so called peripheral "palisades" of cells around the margins of each tumor nest. It has been shown that this phenomenon corresponds to the way -in which basal cell carcinomas grow by slow progressive, local invasion.^{31,32} Proliferation of basal cell carcinoma cells has been analyzed immunohistochemically.³³ The Ki-67-positive growth fraction displays great variation between tumors belonging to the same subtype (nodular type, 7-67%; superficial type, 18-49%; fibrosing type 4-33%). It has been demonstrated that areas with a high Ki-67 labelling index often occur adjacent to rather quiescent strands, suggesting that an individual tumor is not in a uniform state of proliferation. In view of the fact that BCCs are rather slow-growing tumors, the large Ki-67 growth fractions indicate a prolonged duration of the cell cycle or a considerable continuous loss of cells.³³ As the microarchitecture of BCCs is much more complex than would be expected from the location of their Ki-67-positive cells, the growth pattern is probably determined to a high degree by the adjacent connective tissue (physical properties and texture of collagen and elastic fibres, enzyme activity of fibroblasts). The close relationship between the tumor cell component and the surrounding fibrous stroma is a very interesting aspect of the growth behavior of basal cell carcinomas. It is well known that the tumor cells cannot develop without the surrounding stroma. This stroma, that is usually loose and rich in mucin (predominantly hyaluronic acid), is particularly abundant in sclerosing basal cell carcinoma and constitutes the major part of the volume of the tumors. One important clue to the diagnosis of basal cell carcinoma is the presence of a constant retraction artefact: the separation of the tumor cells from the underlying stroma. It has been speculated that this effect may be due to defective production of hemidesmosomes,³⁴ reduced numbers of anchoring fibrils, and diminished expression of bullous pemphigoid antigen by these tumor cells.³⁵

Variants of basal cell carcinoma include five main clinical subtypes: nodular/ulcerative (solid) (45-60%), diffuse (infiltrating and morphoeic, sclerosing) (4-17%), superficial (multicentric) (15-35%), pigmented variant (1-7%), and the fibroepithelioma of Pinkus. Rare basal cell carcinomas that exhibit significant nuclear anaplasia and infiltrative growth characteristics have been referred to in the past as metatypical basal cell carcinomas, although the use of this term is now discouraged.⁹ Neuroendocrine differentiation has been described as well, but is uncommon.^{13,35} Pigmentation in basal cell carcinomas may be evident in macrophages and dendritic cells. Haemosiderin may also be present in some cases.

Basal cell carcinomas are characterized by a nonmetastasizing behavior. Apoptotic cells are present in these tumors.¹⁸ The integrin profile of basal cell carcinomas does not differ essentially from that of metastasizing tumor varieties and cannot be regarded as a major reason for the nonmetastasizing phenotype of basal cell carcinomas.³⁶ However, it has been suggested that the very low expression of the receptor for hyaluronic acid (CD44std) may be one of the factors which block the formation of metastases from basal cell carcinomas.³⁷

Increasing evidence indicates that the vitamin D system is of critical importance for growth characteristics in basal cell carcinomas. RNA expression of vitamin D receptor (VDR) and of main enzymes involved in synthesis and metabolism of calcitriol was detected in basal cell carcinomas and normal skin. Increased VDR-immunoreactivity was demonstrated in basal cell carcinomas using a streptavidin-peroxidase technique.^{32,38} In conclusion, these findings provide supportive evidence for the concept that endogeneous synthesis and metabolism of vitamin D metabolites as well as VDR expression may regulate growth characteristics of basal cell carcinomas.^{32,38}

Recently, the expression and distribution of the DNA mismatch repair enzyme *h*MSH-2 in normal skin and basal cell carcinomas was investigated immunohistochemically.³⁹ All basal cell carcinomas analysed revealed strong nuclear immunoreactivity that was pronounced in peripheral tumour cells and cells of the palisade. Expression of *h*MSH-2 protein was consistently and strongly upregulated in tumour cells of the carcinomas as compared to adjacent unaffected epidermis or epidermis of normal human skin. These findings indicate that upregulation of *h*MSH-2 protein expression may be of importance for the genetic stability of basal cell carcinomas in vivo.³⁹

Basosquamous Carcinoma

Basosquamous carcinoma of the skin is a very rare malignancy with specific histopathological features of both basal cell carcinoma and squamous cell carcinoma.^{13,40} Some authors believe that basosquamous carcinoma is a variant of basal cell carcinoma, while others suggest that this tumour may behave more aggressively and represents a distinct entity.⁴⁰ In general, the predominant expression is of a basal cell carcinoma with squamous differentiation occurring in larger groups of tumor cells. These tumors are unlikely to metastasize and should therefore be regarded as variants of basal cell carcinoma from the point of view of clinical management.¹³

References

1. Ackerman AB. Solar keratosis is squamous cell carcinoma. *Arch Dermatol* 2003; 139(9):1216-7.
2. Fu W, Cockerell CJ. The actinic (solar) keratosis. *Arch Dermatol* 2003; 139:66-70.
3. Lober BA, Lober CW. Actinic keratosis is squamous cell carcinoma. *Southern Medical Journal* 2000; 93(7):650-655.
4. Stadler R, Hartig C. Epidermale Tumoren. In: Kerl, Garbe, Cerroni, Wolff, eds. *Histopathologie der Haut*. 1st ed. Berlin, Heidelberg, New York: Springer, 2003.
5. Marks R, Foley P, Goodman G et al. Spontaneous remission of solar keratoses: The case for conservative management. *Br J Dermatol* 1986; 115:649-656.
6. Marks R, Rennie G, Selwood TS. Malignant transformation of solar keratoses to squamous cell carcinoma. *Lancet* 1988; 1(8589):795-797.
7. Kirkham N. Intraepidermal keratoses and tumours. In: Kirkham N, ed. *Biopsy pathology of the skin*. 1st ed. London, New York, Tokyo, Melbourne, Madras: Chapman and Hall Medical, 1991a:32-53.
8. McKee PH. Tumours of the surface epithelium. In: McKee, ed. *Pathology of the skin*. 2nd ed. London, Philadelphia, St. Louis, Sydney, Tokyo: Mosby International 1999a:14.1-14.28.
9. Murphy GF, Elder DE. Nonmelanocytic tumors of the skin. In: Rosai, Sobin, eds. *Atlas of tumour pathology*. Third series, fascicle 1. Washington, DC: American Registry of Pathology, 1991.
10. Kaye V, Zhang G, Dehner LP et al. Carcinoma in situ of penis. Is distinction between erythroplasia of Queyrat and Bowen's disease relevant? *Urology* 1990; 33:479-482.
11. Graham JH, Helwig EB. Erythroplasia of Queyrat. A clinicopathologic and histochemical study. *Cancer* 1973; 32:1396-1414.
12. Broders AC. Practical points on the microscopic grading of carcinoma. *NY State J Med* 1932; 32:667-671.
13. Kirkham N. Epidermal tumours. In: Kirkham N, ed. *Biopsy pathology of the skin*. 1st ed. London, New York, Tokyo, Melbourne, Madras: Chapman and Hall Medical, 1991b:67-79.
14. Goepfert H, Dichtel W, Medina JE et al. Perineural invasion of squamous cell carcinoma of the head and neck. *Am J Surg* 1984; 148:542-547.
15. Giglia-Mari G, Sarasin A. TP53 mutations in human skin cancers. *Hum Mutat* 2003; 21(3):217-28.
16. Mercurio AM. Invasive skin carcinoma—Ras and alpha6beta4 integrin lead the way. *Cancer Cell* 2003; 3(3):201-2.
17. Backvall H, Wolf O, Hermelin H et al. The density of epidermal p53 clones is higher adjacent to squamous cell carcinoma in comparison with basal cell carcinoma. *Br J Dermatol* 2004; 150(2):259-66.
18. Jackson S, Ghali L, Harwood C et al. Reduced apoptotic levels in squamous but not basal cell carcinomas correlates with detection of cutaneous human papillomavirus. *Br J Cancer* 2002; 87(3):319-23.

19. Reichrath J, Welter C, Mitschele T et al. Different expression patterns of calpain isozymes 1 and 2 (CAPN1 and 2) in squamous cell carcinomas (SCC) and basal cell carcinomas (BCC) of human skin. *J Pathol* 2003; 199(4):509-16.
20. Reichrath J, Rafi L, Rech M et al. Analysis of the vitamin D system in cutaneous squamous cell carcinomas. *J Cutan Pathol* 2004; 31(3):224-31.
21. Godbolt AM, Sullivan JJ, Weedon D. Keratoacanthoma with perineural invasion: A report of 40 cases. *Australas J Dermatol* 2001; 42(3):168-71.
22. Gottfarstein-Maruani A, Michenet P, Kerdraon R et al. Keratoacanthoma: Two cases with intravascular spread. *Ann Pathol* 2003; 23(5):438-42.
23. Balasubramaniam N, Resnick KS, Ackerman AB. What is your diagnosis? (keratoacanthoma with metastasis). *Dermatopathol Pract Concept* 1999; 5:51.
24. Hodak E, Jones RE, Ackerman AB. Solitary keratoacanthoma is a squamous-cell carcinoma: Three examples with metastases. *Am J Dermatopathol* 1993; 15:332, (discussion 343-352).
25. Kane CL, Keehn CA, Smithberger E et al. Histopathology of cutaneous squamous cell carcinoma and its variants. *Semin Cutan Med Surg* 2004; 23(1):54-61.
26. Putti TC, Teh M, Lee YS. Biological behavior of keratoacanthoma and squamous cell carcinoma: Telomerase activity and COX-2 as potential markers. *Mod Pathol* 2004; 17(4):468-75.
27. Billings SD, Southall MD, Li T et al. Amphiregulin overexpression results in rapidly growing keratinocytic tumors: An in vivo xenograft model of keratoacanthoma. *Am J Pathol* 2003; 163(6):2451-8.
28. Melendez ND, Smoller BR, Morgan M. VCAM (CD-106) and ICAM (CD-54) adhesion molecules distinguish keratoacanthomas from cutaneous squamous cell carcinomas. *Mod Pathol* 2003; 16(1):8-13.
29. Mukunyadzi P, Sanderson RD, Fan CY et al. The level of syndecan-1 expression is a distinguishing feature in behavior between keratoacanthoma and invasive cutaneous squamous cell carcinoma. *Mod Pathol* 2002; 15(1):45-9.
30. Biesterfeld S, Josef J. Differential diagnosis of keratoacanthoma and squamous cell carcinoma of the epidermis by MIB-1 immunohistometry. *Anticancer Res* 2002; 22(5):3019-23.
31. Grimwood RE, Ferris CF, Mercill DB et al. Proliferating cells of human basal cell carcinoma are located on the periphery of tumor nodules. *J Invest Dermatol* 1986; 86(2):191-4.
32. Mitschele T, Diesel B, Friedrich M et al. Analysis of the vitamin D system in basal cell carcinomas (BCCs). *Lab Invest* 2004; 84(6):693-702.
33. Baum HP, Meurer I, Unteregger G. Ki-67 antigen expression and growth pattern of basal cell carcinomas. *Arch Dermatol Res* 1993; 285(5):291-5.
34. Jones JC, Steinman HK, Goldsmith BA. Hemidesmosomes, collagen VII, and intermediate filaments in basal cell carcinoma. *J Invest Dermatol* 1989; 93(5):662-71.
35. McKee PH. Tumours of the epidermal appendages. In: McKee, ed. *Pathology of the skin*. 2nd ed. London, Philadelphia, St. Louis, Sydney, Tokyo: Mosby International, 1999b:15.32-15.40.
36. Baum HP, Schmid T, Reichrath J. Integrin molecules: A clue to the nonmetastasizing behaviour of basal cell carcinomas? *Acta Derm Venereol* 1996b; 76(1):24-7.
37. Baum HP, Schmid T, Schock G et al. Expression of CD44 isoforms in basal cell carcinomas. *Br J Dermatol* 1996a; 134(3):465-8.
38. Mitschele T, Diesel B, Friedrich M et al. Analysis of the vitamin D system in basal cell carcinomas (BCCs). *Lab Invest* 2004; 84(6):693-702.
39. Rass K, Gutwein P, Muller SM et al. Immunohistochemical analysis of DNA mismatch repair enzyme hMSH-2 in normal human skin and basal cell carcinomas. *Histochem J* 2000; 32(2):93-7.
40. Sendur N, Karaman G, Dikicioglu E et al. Cutaneous basosquamous carcinoma infiltrating cerebral tissue. *J Eur Acad Dermatol Venereol* 2004; 18(3):334-336.

Molecular Mechanisms of Basal Cell and Squamous Cell
Carcinomas

Reichrath, J. (Ed.)

2006, XVII, 137 p., Hardcover

ISBN: 978-0-387-26046-4