

2

Anatomy and Physiology of the Respiratory Tract

Anna Person and Matthew L. Mintz

CONTENTS

INTRODUCTION
ANATOMY
PHYSIOLOGY
SOURCES

INTRODUCTION

The anatomy and physiology of the respiratory tract is quite complex. Each anatomic segment performs in concert with the others and is accountable for a wide variety of physiological responsibilities. These responsibilities vary with rest or exercise, disease or health. Throughout this book, the reader will discover that the respiratory tract is a delicate and complicated system that can be involved in a number of disease processes. An understanding of the anatomy and physiology of the respiratory tract is critical to understanding this elaborate system to maintain respiratory health and treat respiratory diseases.

ANATOMY

The respiratory system is comprised of several elements including the central nervous system, the chest wall, the pulmonary circulation, and the respiratory tract. The respiratory tract can be divided into four distinct segments: the nasopharynx, the conducting airways, the respiratory bronchioles, and the alveoli. The lungs can also be divided into the conducting airways and the units of respiration. The trachea, bronchi, and bronchioles conduct and transport air from the outside world and deliver it to the respiratory units—the alveoli. Gas

From: *Current Clinical Practice: Disorders of the Respiratory Tract:
Common Challenges in Primary Care*

By: M. L. Mintz © Humana Press, Totowa, NJ

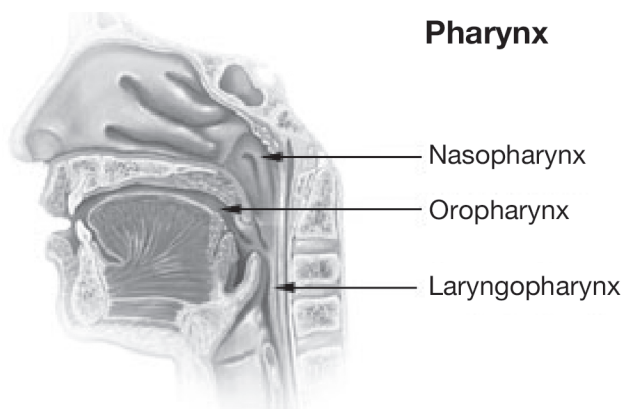


Fig. 1. The nasopharynx.

exchange occurs at the level of the alveoli, providing the necessary oxygen for the body's daily functions. Malfunction of any of these components can lead to the myriad respiratory disorders discussed in this book.

The first segment of the respiratory tract is the naso-oropharynx (*see* Fig. 1), which begins with the nostrils and lips, and includes the nasal passage, sinuses, and glottis until reaching the trachea. The purpose of the naso-oropharynx is to filter out any large particles and to humidify and warm the air that is delivered to the respiratory units. The epiglottis and muscles of the larynx coordinate the passage of food and air, and generally assure that food reaches the esophagus and air reaches the trachea.

The next segment is the conducting airways, beginning with the trachea, which branches repeatedly to form approximately 14 generations of conduits for air reaching several distinct pulmonary segments. The trachea bifurcates at the carina into the right and left mainstem bronchi. Aspiration occurs more commonly at the right main bronchus because of its gentler angle off the trachea. The right lung is divided into upper, middle, and lower lobes, each of which is further subdivided into segments and each with its own conducting airway. The upper lobe contains three segments: the apical, posterior, and anterior. The middle lobe consists of the lateral and medial segments. The lower lobe has five segments: the superior, medial basal, anterior basal, lateral basal, and posterior basal. The right lung has 10 segments, as opposed to 8 found in the left lung. The left main bronchus has two divisions serving the left upper lobe. The superior division of the bronchus leads to the apical–posterior and anterior segments. The inferior division of the bronchus leads to the superior and inferior lingular segments. The left lower lobe consists of the superior, anteromedial basal, lateral basal, and posterior basal segments. Each bronchopulmonary segment is supplied by an individual branch of the pulmonary artery.

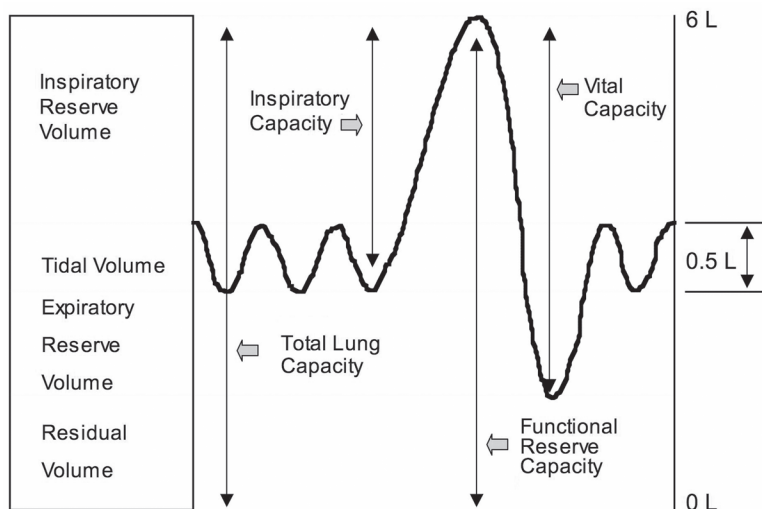


Fig. 2. Lung volumes.

The respiratory bronchioles are the last bronchioles before reaching the alveoli. Smaller foreign particles may be trapped here, and lymphatic channels are found as well. The solitary layer of epithelial cells that compose the surface of the respiratory tract gives way to the cells that comprise the lining of alveoli. The warriors of the immune system are found at this level; macrophages, neutrophils, and eosinophils are poised to act should unknown antigens be found. Once the air reaches the alveoli, type I epithelial cells allow for gas exchange, and create a total surface area of around 130 sq ft among all alveoli. The millions of alveoli are embedded among capillaries to create an air–blood interface.

PHYSIOLOGY

The physiological makeup of the lungs maintains the delicate balance between these disparate anatomic entities. Several terms have been developed to describe the various physiological capacities of the respiratory tract (Fig. 2). Total lung capacity is defined as the volume of gas in the lungs following maximal inspiration. Functional residual capacity is the volume of gas in the lungs at the end of normal expiration. The functional residual capacity is comprised of the expiratory reserve volume (the amount of air that can be expelled with maximal expiratory effort) and the residual volume (the volume of air in the lungs after maximal expiration). Tidal volume is the volume of gas in any normal breath (generally around 500–800 mL), whereas vital capacity is the maximal volume of air that can be expelled following maximal inspiration. These volumes can be measured by spirometry (*see* Chapter 3).

The three main physiological functions of the respiratory tract are ventilation, perfusion, and diffusion. Ventilation is the process of procuring air from the external environment via inspiration to supply the alveolus, after which it is subsequently returned to the outside of the body through expiration. The elastic nature of the lungs and chest wall permit pressure differentials without which inspiration and expiration could not occur. The lungs are distended by pressure exerted by the airways and alveoli (positive internal pressure) or by pressure outside the lungs (negative external pressure). The chest wall's elasticity allows it to act as a spring. When the pressures exerted on it are altered, the chest wall moves and breathing occurs. The stimulus for respiration comes mainly from the medulla and pons, which constantly receive neural inputs from several sources. The carotid bodies detect changes in PaO_2 , PaCO_2 , and pH, whereas the medullary chemoreceptor monitors PaCO_2 and pH alone. Muscle spindles and Golgi tendon organs monitor chest wall muscles and stretch. All of this information is combined to determine ventilatory needs, which increase in illness, exercise, or other physiological states in which tissue oxygen needs are increased. The responses of these receptors can be blunted and lead to decreased ventilation as well. This can occur with obesity, severe chronic bronchitis, or severe metabolic alkalosis.

The ventilatory drive is stimulated by PaO_2 and PaCO_2 levels, although the body demonstrates far greater sensitivity to PaCO_2 levels. In normal individuals at rest, the PaCO_2 level is tightly controlled. If the PaCO_2 level raises slightly, to 42 mmHg, the rate of ventilation quickly increases. However, the PaO_2 generally must decrease to around 65 mmHg for a similar ventilatory response to be initiated via hypoxemic stimulus. Hypercapnia is therefore the primary drive for ventilation.

Distribution of inhaled air also varies. In a normal, upright individual intrapleural pressure is most negative at lung apices and least negative at lung bases. At rest, therefore, the alveoli are least distended at the bases of the lungs, and this area receives greater ventilation as a result.

Another main physiological responsibility of the respiratory tract is diffusion (Fig. 3). This is measured by diffusion capacity for carbon monoxide, which tests how well the gas in inspired air can cross the wall of the alveolus and enter the capillary. This entails crossing the alveolar type 1 epithelial cells, the interstitial space, and the vascular endothelial cells. Carbon monoxide is used for measuring the diffusing capacity of the lung, generally by use of the single breath determination. Adjustments must be made for those with altered lung volumes, those with increased carbon monoxide levels (such as smokers), and those who are anemic or who are being tested at high altitudes. Elevated values may be found in asthmatics or those with pulmonary hemorrhage, whereas decreased values are found in emphysema, interstitial lung diseases, or any other process that may disturb the integrity of the alveoli.

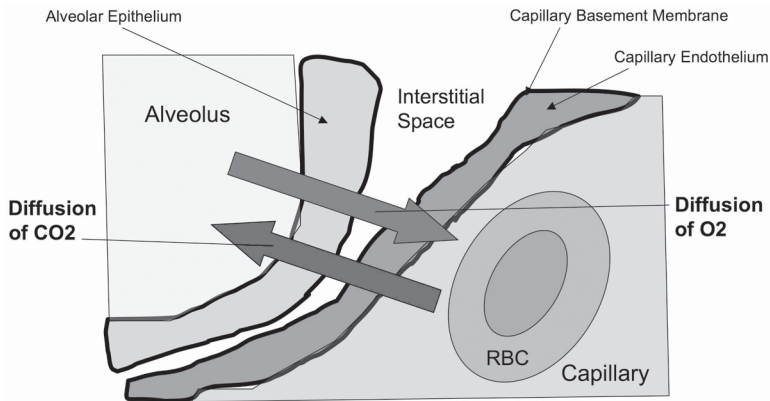


Fig. 3. Diffusion of gases across the alveolar–capillary membrane. RBC, red blood cell.

Perfusion is the final responsibility of the respiratory tract, and is necessary to maintain ventilation and diffusion of its anatomical components. Each division and subdivision of the respiratory tract has its own blood supply. Perhaps most valuable, however, are the pulmonary artery capillaries that surround the alveoli and provide the physiological proximity necessary for the transport of oxygen and other gases into the blood supply and carbon dioxide from the blood back into the lungs for expulsion. Because of gravitational forces, perfusion is greater at the lung bases than at the lung apices, leading to a slight normal physiological mismatch of perfusion compared with ventilation.

SOURCES

- Kochar R. Anatomy, physiology and pulmonary function testing. In: Kutty K, Kochar MS, Schapira R, Van Ruiswyk J. *Kochar's Concise Textbooks of Medicine*, 4th Ed. Baltimore, MD, Lippincott, Williams and Wilkins, 2002, p. 481.
- Myers AR. Pulmonary function studies. In: *National Medical Series for Independent Study: Medicine*, 4th ed. Lippincott, Williams and Wilkins, Baltimore, MD, 2001; pp. 63–69.
- Reynolds HY. Respiratory structure and function. In: Goldman L, Ausiello D, eds. *Cecil Textbook of Medicine*, 22nd ed. W. B. Saunders, Philadelphia, 2004, pp. 485–501.
- Weinberger SE, Drazen JM. Disturbances of respiratory function. In: Kasper DL, Braunwald E, Fauci AS, et al., eds. *Harrison's Principles of Internal Medicine*, 16th Ed. McGraw-Hill, New York, 2005, pp. 1498–1521.



<http://www.springer.com/978-1-58829-556-9>

Disorders of the Respiratory Tract
Common Challenges in Primary Care

Mintz, M.L.

2006, XI, 343 p., Hardcover

ISBN: 978-1-58829-556-9

A product of Humana Press