

11

PET and PET/CT Imaging in Esophageal and Gastric Cancers

Farrokh Dehdashti and Barry A. Siegel

Esophageal and gastric cancers are significant health problems. In the United States, it is estimated that 36,960 patients will be diagnosed in the year 2004 with esophageal or gastric cancer and that these cancers will be responsible for 4.5% of all cancer-related deaths (1). The incidence of gastric cancer is decreasing, whereas the incidence of esophageal cancer is increasing, mainly because of the increase in the frequency of adenocarcinoma of the distal esophagus.

Surgery is the mainstay of treatment of both esophageal and gastric cancer. Despite recent advances in surgical treatment, the overall prognosis of patients with esophageal or gastric cancer has not improved significantly because the neoplasm is often diagnosed at an advanced stage of the disease. Local and systemic recurrences are common, even after complete resection of the primary tumor and regional lymph nodes. Multimodality therapy, consisting of surgery with adjuvant or neoadjuvant radiotherapy, chemotherapy, or both, has been used recently as a means to improve survival of patients with esophageal or gastric cancer. Randomized clinical trials have shown that concurrent chemotherapy and radiotherapy are more effective than radiotherapy alone in treating advanced esophageal cancer (2). Current data suggest that these cancers are best managed with a tailored therapeutic regimen, based on thorough preoperative staging of the tumor and an understanding of established prognostic factors (3).

The TNM staging system is used for staging of both esophageal and gastric cancers: T stage refers to the depth of the invasion of the primary tumor, N stage refers to the extent of lymph node involvement, and M stage indicates the presence or absence of systemic metastases (Tables 11.1, 11.2). Current preoperative staging techniques, such as computed tomography (CT), are of limited accuracy, and invasive procedures often are used for better assessment of the stage of the disease. Beginning in the mid-1990s, positron emission tomography (PET) has been evaluated as a method for the staging of esophageal and gastric cancer. In the past few years, combined PET/CT

scanners have been rapidly replacing conventional PET for the evaluation of oncologic patients. Although there are still only limited data regarding the use of PET/CT in esophageal and gastric cancers, the combination of these two modalities is expected to improve the accuracy of image interpretation, and thus lead to better management of cancer patients (4, 5).

Esophageal Cancer

Over the past two decades in Western countries, the incidence of esophageal adenocarcinoma has increased and is currently higher than that of squamous cell carcinoma (2). Effective treatment and prediction of outcome in esophageal cancer are based on accurate tumor staging. Patients with early-stage disease may benefit from esophagectomy alone, whereas multimodality therapy with surgery and adjuvant or neoadjuvant chemotherapy and/or radiation may be indicated in patients with advanced locoregional disease. Nonsurgical palliative therapy is indicated in patients with distant metastatic disease because these patients have a poor prognosis regardless of the type of treatment. Cancer of the esophagus is most often diagnosed by endoscopic biopsy or brushing, and the size, location, and morphology of the tumor are evaluated by endoscopy and barium esophagography. Currently used staging methods include CT, endoscopic ultrasonography (EUS), and magnetic resonance imaging (MRI). However, these anatomic imaging techniques have significant limitations. EUS has been reported to have an accuracy of 85% for assessment of the depth of tumor invasion and 75% for detection of regional lymph node metastases (6). CT has also been found to have limited accuracy of 50% to 60% for staging esophageal cancer (7-9), and MRI has not significantly improved these staging results. The main shortcoming of these imaging modalities is their reliance on detection of structural changes for diagnosis of disease. The high rate of treatment failure after surgery with curative intent in patients with imaging

Table 11.1. TNM staging for esophageal carcinoma.

Primary Tumor (T)	
Tis	= carcinoma in situ
T1	= tumor invades into but not beyond the submucosa
T2	= tumor invades into but not beyond the muscularis propria
T3	= tumor invades into the adventitia
T4	= tumor invades adjacent structures
Regional Lymph Nodes (N)	
N0	= regional nodes not involved
N1	= regional nodes involved
Distant Metastasis (M)	
M0	= no distant metastasis
M1	= distant metastasis (including nodal involvement outside the mediastinum)
Stage Grouping	
Stage 0	= Tis, N0, M0
Stage 1	= T1, N0, M0
Stage II	= T1-2, N0-1, M0
Stage III	= T3-4, N0-1, M0
Stage IV	= Any T, Any N, M1

Source: From Valk PE, Bailey DL, Townsend DW, Maisey MN. Positron Emission Tomography: Basic Science and Clinical Practice. Springer-Verlag London Ltd 2003, p. 571.

evidence of only localized disease is likely related to current inaccurate staging procedures.

The addition of PET with 2-¹⁸F]fluoro-2-deoxy-D-glucose (FDG) to the current imaging techniques that are used for staging significantly improves accuracy. The use of FDG-PET in esophageal cancer was approved for reimbursement by the U.S. Medicare program in 2001. In many institutions, FDG-PET is now routinely employed for staging of esophageal cancer (10–17). There is very limited experience in the application of PET with other radiopharmaceuticals (e.g., ¹¹C-choline) for the evaluation of esophageal cancer (18). Accordingly, this chapter exclusively describes clinical results obtained with FDG.

Primary Tumor Staging (T Stage)

The T stage is determined by the depth of tumor infiltration into or through the esophageal wall, and this is one of the most important prognostic factors in esophageal cancer. Because of the ability of the esophagus to distend, dysphagia, which is a common presenting symptom, does not occur until the disease is advanced and the tumor bulk compromises the esophageal lumen. EUS is useful for accurate evaluation of the depth of primary tumor penetration within the wall and the invasion of periesophageal tissues. However, EUS is operator dependent and is unable to distinguish tumor from inflammation, so that tumor stage may be overestimated in the presence of peritumoral inflammation. The major limita-

Table 11.2. TNM sStaging for gastric carcinoma.

Primary Tumor (T)	
Tis	= carcinoma in situ
T1	= tumor invades lamina propria or submucosa
T2	= tumor invades muscularis propria
T3	= tumor invades adventitia
T4	= tumor invades adjacent structures
Regional Lymph Nodes (N)	
N0	= regional nodes not involved
N1	= Metastasis in perigastric lymph nodes(s) within 3 cm of edge of primary tumor
N2	= Metastasis in perigastric lymph nodes(s) more than 3 cm of edge of primary tumor, or in lymph nodes along left gastric, common hepatic, splenic, or celiac arteries
Distant Metastasis (M)	
M0	= no distant metastasis
M1	= distant metastasis (including nodal involvement outside the mediastinum)
Stage Grouping	
Stage 0	= Tis, N0, M0
Stage 1	= T1-2, N0-1, M0
Stage II	= T1-3, N0-2, M0
Stage III	= T2-4, N0-2, M0
Stage IV	= Any T, Any N, M1

Source: From Valk PE, Bailey DL, Townsend DW, Maisey MN. Positron Emission Tomography: Basic Science and Clinical Practice. Springer-Verlag London Ltd 2003, p. 572.

tion of EUS is its inability to evaluate tumors that have caused stenosis of the esophageal lumen, thereby preventing passage of the endoscope. CT complements EUS in detecting macroscopic invasion of mediastinal fat and infiltration into the adjacent organs, particularly the trachea and bronchi (T3 and T4 stage). However, CT is limited for detection of early-stage (T1 and T2) tumors and for differentiating malignant from benign causes of esophageal wall thickening. The accuracy of CT is further limited by the diminished amount of mediastinal fat in many patients with esophageal cancer, who often have sustained significant weight loss by the time of presentation. In addition, accurate assessment of the local extent of the tumor may be hindered by partial-volume averaging consequent to the close proximity of the tumor to the pulsating aorta or heart (19).

FDG-PET can detect esophageal cancer before it becomes evident on CT, but PET is limited in its ability to determine the extent of tumor spread through the esophageal wall or tumor invasion of the adjacent structures. This limitation results chiefly from the poorer resolution of PET by comparison with anatomic imaging methods and its limited delineation of normal anatomic structures. In our experience, a heterogeneous pattern of FDG uptake at the primary site, especially when it has irregular margins, is suggestive of local extension of the

tumor into the surrounding soft tissues. Several investigators have shown that FDG-PET has a higher sensitivity than CT for detection of primary esophageal cancer (83%–100% versus 67%–92%) (10–13, 15–17, 20, 21). The one exception was a study utilizing a partial-ring PET scanner without attenuation correction of images, where PET was found to have a lower sensitivity than CT (84% versus 97%) (22). In most studies, false-negative results of PET occurred in patients with small T1 lesions. Physiologic uptake of FDG in the normal esophagus also may be a limitation in detection of small or well-differentiated tumors.

FDG uptake in primary esophageal tumors has been assessed mainly by qualitative visual analysis. Yeung et al. (16) also assessed the FDG uptake in esophageal tumors by determination of the standardized uptake value (SUV) and found no difference in FDG uptake in adenocarcinomas and squamous cell carcinomas. Fukunaga et al. (23) found that 47 of 48 patients with esophageal cancer had a primary tumor SUV greater than 2.0 (sensitivity of 98%). The mean SUV in primary esophageal cancers (6.99 ± 3.05 ; $n = 48$) was greater than that of either normal esophagus (1.34 ± 0.37 ; $n = 10$) or a single benign esophageal tumor (0.86) (23). Flamen et al. (17) compared the primary tumor SUV with the T stage in 50 patients and found no correlation. In contrast, Kato et al. (24) reported a significant association between FDG uptake of the primary tumor, as measured by the SUV, and the depth of tumor invasion (P less than 0.05), tumor dimensions (P less than 0.01), the occurrence of lymph node involvement (P less than 0.01), and lymphatic invasion (P less than 0.01).

All currently used imaging techniques are limited in differentiating tumor from inflammatory disease and in detecting microscopic disease, so that histopathologic examination of the resected specimen remains the criterion standard for T-stage determination.

Regional Lymph Node Metastases (N Stage)

The status of regional lymph nodes is the most important prognostic factor in patients with esophageal cancer: patients with nodal metastases have a higher likelihood of systemic spread of the disease and a worse prognosis (25–27). Lymph node status has a major impact on treatment selection. Lymph node involvement, either regional or distant, commonly occurs before involvement of other distant organs. The high prevalence of lymph node involvement in esophageal cancer is the result of the rich network of lymphatics, which extends along the entire esophagus. The limitations of the current imaging techniques, CT and EUS, in accurate detection of lymph node involvement are related to their inability to detect tumor involvement in normal-sized lymph nodes and to differentiate whether lymph node enlargement is caused by metastatic or inflammatory disease. Although multidetector CT has better resolution and improved ability to

detect small lymph nodes, it has not been shown to improve the accuracy of esophageal cancer staging; this is no doubt related to the size criterion used by CT for detection of lymph node metastasis. To increase the accuracy of preoperative staging, the use of minimally invasive surgical staging, consisting of thoracoscopy with or without abdominal staging laparoscopy, has been recommended. However, because of their invasiveness, morbidity, and high cost, these procedures are not used routinely in clinical practice.

Clinical studies have shown that FDG-PET can significantly improve preoperative nodal staging (Table 11.3). Although most of these studies were retrospective and the studies employed different imaging protocols, the results demonstrate an important role for FDG-PET in staging esophageal cancer. In early work at Washington University, we studied 36 patients with esophageal cancer. In 29 patients who underwent esophagectomy with curative intent, we found that the accuracy for detection of nodal disease was 76% (22/29) for FDG-PET and 45% (13/29) for CT (10). Most subsequent studies including our own have demonstrated slightly lower sensitivity, with similar or higher specificity for detection of locoregional nodal disease by PET. The reported sensitivities have ranged from 22% to 71% (with one report of 92%) for PET, compared to 0% to 87% for CT (10–13, 15–17, 21, 22, 28–31) (Figure 11.1). Specificities ranged from 78% to 100% for PET and from 73% to 100% for CT (see Table 11.3) (10–13, 15–17, 21, 22, 28–32). A recent meta-analysis of 12 studies reported in the literature has demonstrated that the overall pooled sensitivity and specificity of FDG-PET for detection of locoregional disease were 51% [95% confidence interval (CI), 34%–69%] and 84% (95% CI, 76%–91%), respectively (33).

Although these reports suggest that FDG-PET may produce some small improvement in locoregional staging, the sensitivity of both PET and CT is too low for use in clinical decision making, and nodal sampling is used in all patients who are otherwise considered to be surgical candidates. False-negative results are chiefly found in nodes with small tumor burden (especially nodes less than 1 cm in diameter) and involved lymph nodes that lie in close proximity to the primary tumor. These adjacent lymph nodes are typically resected with the primary tumor, and their involvement usually does not alter management. False-positive results are chiefly caused by inflammatory disease or heterogeneous uptake in the primary tumor simulating periesophageal nodal metastasis. Inflammatory adenopathy should be suspected when there is other evidence of granulomatous disease on CT imaging (e.g., nodal calcification).

Distant Metastatic Disease (M Stage)

The prognosis for patients with metastatic esophageal cancer is very poor, and major surgery is not justified in

Table 11.3. Comparison of FDG-PET and CT for detection of regional lymph node involvement in esophageal cancer.

Study (year)	Number of patients	Sensitivity (%)		Specificity (%)	
	Biopsy or surgery/total ^a	PET	CT	PET	CT
Flanagan et al. (1997)	29/36	72	28	82	73
Block et al. (1997) ^b	35/58	52	28	78	78
Luketich et al. (1997)	21/35	45	NA	100	NA
Kole et al. (1998)	22/26	92	38	88	100
Rankin et al. (1998)	18/25	37	50	90	80
Yeung et al. (1999)	NA/67	28	25	99	98
Flamen et al. (2000)	39/74	33	0	89	100
Lerut et al. (2000) ^c	42/74	22	83	91	45
Meltzer et al. (2000)	37/47	41	87	88	43
Kim et al. (2001)	50/53	52	15	94	97
Himeno et al. (2002)	31/36	37	31	96	88
Kato et al. (2002)	32/32	78	61	93	71
Wren et al. (2002)	21/24	71	57	86	71
Räsänen et al. (2003)	19/42	37	89 ^d	100	54 ^d
Yoon et al. (2003)	81/136	30	11	90	95
Liberale et al. (2004)	8/24	38	25	81	50

NA, information not available.

^aNumber of patients who underwent surgical resection of esophageal cancer.^bThe PET and CT results of some of these patients are also reported in Flanagan et al. (1997).^cReanalysis of 42 of 74 patients reported in Flamen et al. (2000).^dEndoscopic ultrasonography.

Source: Updated from Valk PE, Bailey DL, Townsend DW, Maisey MN. Positron Emission Tomography: Basic Science and Clinical Practice. Springer-Verlag London Ltd 2003, p. 574.

these patients. Therefore, it is essential to identify patients with advanced disease accurately to permit selection of the most effective and rational management approach and to avoid subjecting them to ineffective costly and debilitating therapeutic procedures. Esophageal cancer typically metastasizes to distant lymph nodes, liver, and lung, before metastasizing to other organs, such as bone and adrenal glands. Although evaluations of FDG-PET for detection of distant metastatic disease in patients with esophageal cancer have included only limited patient numbers, the results of these studies have demonstrated an important role for PET in pretreatment staging.

Clinical studies have shown that FDG-PET is more sensitive than conventional imaging such as CT, ultrasonography, and bone scintigraphy for demonstrating the true extent of metastatic disease (Table 11.4). In our initial study, we demonstrated that FDG-PET was superior to CT, detecting distant metastatic disease in 5 of 7 versus 0 of 7 patients (10). The positive PET findings were confirmed histologically in all 5 of these patients. The 2 patients with false-negative PET results were respectively found at laparotomy to have a small hepatic metastasis and a small pancreatic metastasis. Our subsequent evaluation of a larger patient group confirmed these findings, demonstrating a sensitivity of 100% (17/17) for PET versus 29% (5/17) for CT in detection of distant metastatic disease (11). Eleven of these 17 patients subsequently underwent

minimally invasive staging procedures, such as percutaneous biopsy or mediastinoscopy, with confirmation of the PET results in every case (Figure 11.2).

Luketich et al. (13) studied 35 patients with esophageal cancer and demonstrated that FDG-PET had a sensitivity of 88% (7/8) and specificity of 93% (25/27) for detection of distant metastatic disease. FDG-PET was falsely negative in 1 patient with a 2-mm hepatic lesion. CT demonstrated small (less than 1 cm) pulmonary lesions in 6 patients, all of whom had negative PET studies. Video-assisted thoracotomy confirmed the PET results in all 6 patients showing benign hamartoma in 2 patients and benign granuloma or fibrosis in 4. These investigators reported that FDG-PET results facilitated treatment planning by demonstrating unsuspected distant metastatic disease in up to 20% of patients with negative results by conventional imaging. In a later evaluation, Luketich et al. (14) prospectively compared PET and CT with minimally invasive staging in 91 patients (100 PET scans) with esophageal cancer. Seventy distant metastatic lesions in 39 patients were confirmed clinically or by biopsy. Sensitivity and specificity were 69% and 93%, respectively, for FDG-PET and 46% and 74%, respectively, for CT. Similar results are reported by others (12, 15).

In a prospective study of 74 patients, Flamen et al. (17) found that FDG-PET was superior to CT and EUS in detection of stage IV disease. The sensitivity and specificity

Figure 11.1. Staging esophageal cancer: 65-year-old man with an esophageal cancer. Coronal (top) computed tomography (CT), positron emission tomography (PET)-CT fusion, and PET images demonstrate intense ¹⁸F-2-deoxy-D-glucose (FDG) uptake within the thickened distal esophagus, consistent with primary esophageal cancer. Transaxial (middle and bottom) CT, PET/CT fusion, and PET images demonstrate intense FDG uptake in an enlarged gastrohepatic ligament lymph node (2.0 × 2.5 cm) (curved arrow; middle images) and a small (7 mm) lymph node (arrow, bottom images), which showed increased FDG uptake, suspicious for metastatic disease.

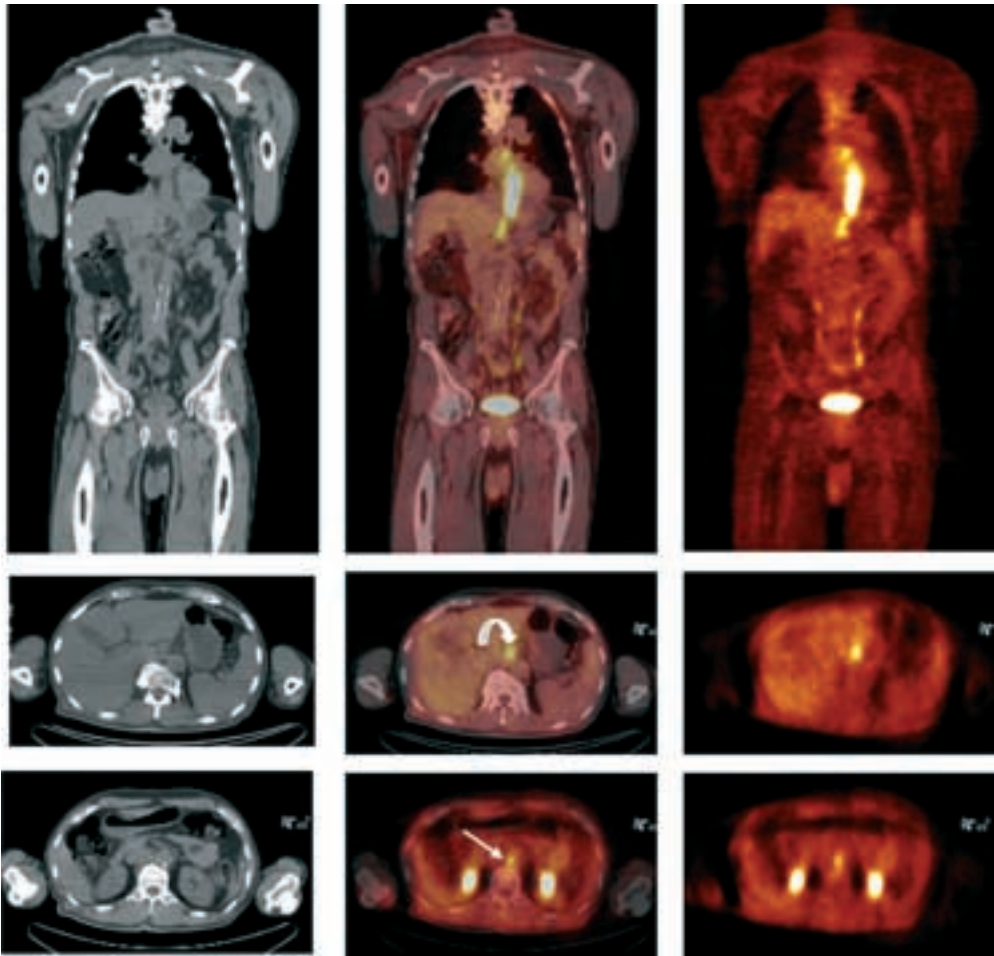


Table 11.4. Comparison of FDG-PET and CT for detection of distant metastatic disease in esophageal cancer.

Study (year)	Number of patients	Sensitivity (%)		Specificity (%)	
	Biopsy or surgery/total ^a	PET	CT	PET	CT
Flanagan et al. (1997)	7/36	71	0	NA	NA
Block et al. (1997) ^a	17/58	100	29	NA	NA
Luketich et al. (1997)	7/35	88	0	93	70
Kole et al. (1998)	8/26	100	62	92	92
Luketich et al. (1999)	39/91	69	46	93	74
Flamen et al. (2000)	34/74	74	47	90	78
Lerut et al. (2000) ^b	13/42	77	83	90	69
Meltzer et al. (2000)	10/47	71	57	93	93
Wren et al. (2002)	12/24	67	83	92	75
Räsänen et al. (2003)	15/42	47	33	89	96
Heeren et al. (2004)	24/74	78	37	98	87
Liberale et al. (2004)	7/58	88	44	88	95

CI, conventional imaging [CT and/or ultrasound (US)].

^aThe PET and CT results of some of these patients are also reported in Flanagan et al. (1997).

^bReanalysis of 42 of 74 patients reported in Flamen et al. (2000).

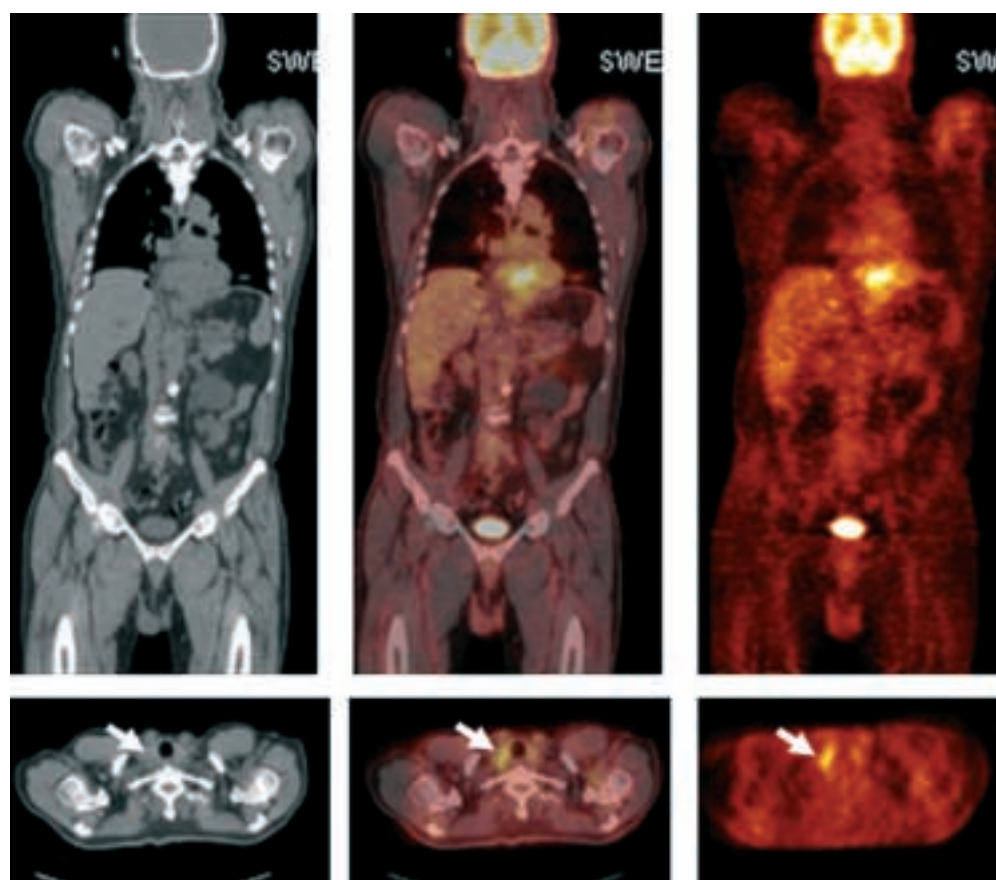


Figure 11.2. Staging esophageal cancer: 62-year-old man with adenocarcinoma of the distal esophagus and gastroesophageal junction. Coronal (*top*) CT, PET/CT fusion, and PET images demonstrate intense FDG uptake within the primary tumor mass. Transaxial (*bottom*) CT, PET/CT fusion, and PET images show intense FDG uptake in a normal size (1 cm) right supraclavicular lymph node (*arrows*), which was easily accessible for biopsy to confirm inoperable disease.

for detection of stage IV disease were 74% and 90%, respectively, for FDG-PET, 41% and 83%, respectively, for CT, and 42% and 94%, respectively, for EUS. Combined use of CT and EUS had a sensitivity of 47% and a specificity of 78% in this group of patients with advanced disease. FDG-PET upstaged the tumor in 11 patients (15%) by detecting unsuspected metastatic disease and downstaged disease in 5 patients (7%). In a subsequent reanalysis of data in 42 of these 74 patients (28), these investigators also showed that FDG-PET had higher sensitivity (77% versus 83%) and specificity (90% versus 69%) than the combination of CT and EUS, specifically for detection of distant nodal disease. Similar results have been reported by others (22, 34, 35). For detection of metastatic disease, the reported sensitivities have ranged from 47% to 100% for PET, compared with 0% to 83% for CT (10–14, 17, 18, 22, 28, 31, 34, 35). Specificities ranged from 89% to 98% for PET and from 69% to 96% for CT [Table 11.4 (10–14, 17, 18, 22, 28, 31, 34, 35); Figure 11.3]. The recent meta-analysis by van Westreenen et al. (33) demonstrated that the overall pooled sensitivity and specificity of FDG-PET for detection of distant metastatic disease were 67% (95% CI, 58%–76%) and 97% (95% CI, 90%–100%), respectively.

Currently, there are no data available from multicenter trials that assess the role of PET in staging esophageal cancer, and the results of a recently completed multicenter trial (American College of Surgeons Oncology Group

Study Z0060) are not expected to be available until 2005. The current literature demonstrates that FDG-PET at initial diagnosis assists in selection of the most appropriate mode of therapy for esophageal cancer. In particular, some patients with advanced disease, who are deemed to have resectable tumors on the basis of conventional imaging results, are excluded from attempted curative surgical procedures. However, because the positive predictive value of FDG-PET is less than 100%, histologic confirmation of PET findings indicating nonresectability is necessary before a patient is denied potentially curative surgery. FDG-PET diagnosis of nonresectable disease has the added advantage of also identifying the local or distant metastatic sites that are the most accessible to confirmation by minimally invasive surgical procedures (see Figure 11.3) (10, 11, 13, 14, 36). Therefore, the use of PET for staging esophageal cancer can reduce both the cost and morbidity of surgical management by reducing the number of ineffective surgical procedures. This practice may also be expected to increase the percentage cure rate of the resections that are undertaken.

It is expected that the interpretation accuracy of PET and CT will improve with the use of PET/CT scanners. These scanners provide accurately fused functional and morphologic data in a single examination (4, 5, 37). It also is expected that this improved accuracy will translate into improved patient management. There are only limited data yet available regarding the use of PET/CT in

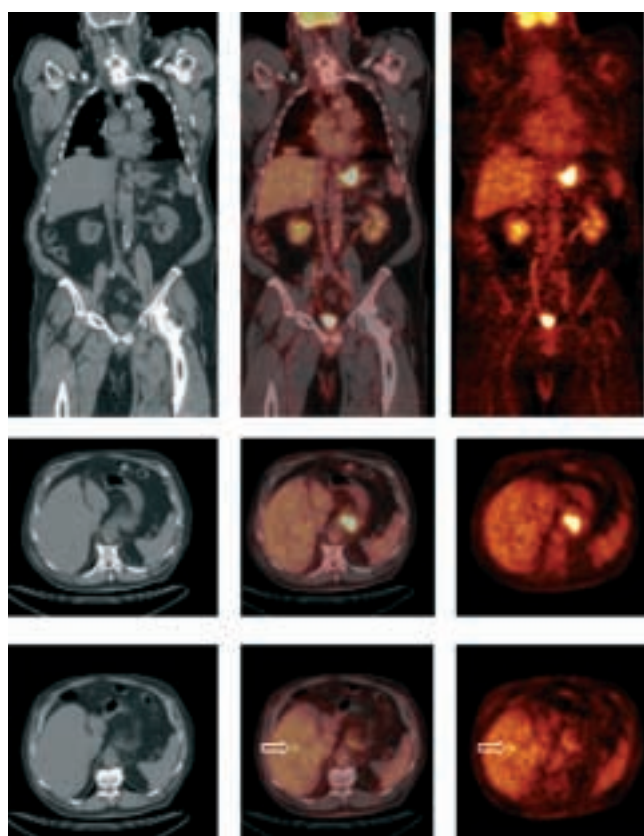


Figure 11.3. Staging esophageal cancer: 68-year-old man with adenocarcinoma of the gastroesophageal junction. Coronal (*top*) and transaxial (*middle*) CT, PET/CT fusion, and PET images demonstrate intense FDG uptake within the primary tumor mass. Transaxial (*bottom*) CT, PET/CT fusion, and FDG-PET images demonstrate a small focal area of increased FDG accumulation within a 1-cm metastasis in the right lobe of the liver (*open arrows*). The diagnosis of metastatic disease was confirmed by sonographically guided biopsy of the hepatic lesion.

esophageal cancer. Bar-Shalom et al. (38) studied 18 patients with esophageal cancer with PET/CT and demonstrated improved detection and characterization of 35% of suspicious lesions in 89% of patients. In addition, the PET/CT results affected management of 22% of patients.

In a recent study, Wallace et al. (39) compared the effectiveness of several different strategies for preoperative staging of patients with esophageal cancer. They compared the following six strategies: CT alone; CT + EUS with fine-needle aspiration biopsy; CT + thoracoscopy and laparoscopy (TL); CT + EUS with fine-needle aspiration biopsy + TL; CT + PET + EUS with fine-needle aspiration biopsy; and PET + EUS with fine-needle aspiration biopsy. The model was based on a third-party payer perspective and incorporated the following: the test characteristics for each staging technique; prevalence of local, regional, and distant disease; life expectancies and cost associated with the treatment for patients with local, regional, and distant disease; and probability of death for patients undergoing TL and those undergoing resection. The investigators found the combination of PET + EUS with fine-needle aspiration biopsy to be the most effective strategy.

Assessment of Prognosis with FDG-PET

Fukunaga et al. (23, 40) showed that semiquantitative and quantitative measures of FDG uptake in primary esophageal cancer can provide prognostic information. They found that patients with a primary tumor with SUV greater than 7.0 had a worse prognosis than those with SUV less than 7.0 (23). They also demonstrated a good correlation between hexokinase activity, assessed histochemically in the resected tumor specimens, and the preoperative tumor FDG uptake measured as SUV and as k_3 , the rate constant for phosphorylation of FDG. Kato et al. (24) also demonstrated that SUV for tumor FDG uptake can be used to predict prognosis. They reported that patients with a primary tumor with SUV greater than 3 had a worse prognosis than did those with SUV less than 3. The 2-year survival rate in the patients with high tumor FDG uptake was 48% versus 91% in those with low uptake.

Luketich et al. (14) reported that FDG-PET demonstration of local or distant metastatic disease at initial presentation was highly predictive of survival. The 30-month survival of patients with PET evidence of local disease only ($n = 64$) was 60% versus 20% for patients with PET evidence of distant disease ($n = 27$; $P = 0.01$). By comparison, when CT was used to stage the tumor, there was a lesser, but statistically insignificant, correlation between survival and CT findings: the 30-month survival of patients with CT evidence of local disease only ($n = 58$) was 52% versus 38% for patients with CT evidence of distant disease ($n = 33$). Choi et al. (41) recently demonstrated that several features of esophageal cancer on FDG-PET such as SUV of the primary tumor, the number of positive lymph nodes, the length of the tumor, and stage are independent prognostic predictors over other clinical features of patients with esophageal cancer who were undergoing curative surgery. The investigators studied 69 such patients, who were followed for disease recurrence and cancer-related death to assess survival. In univariate survival analysis, they found that the presence of adjuvant therapy, pathologic stage, number of CT-positive lymph nodes (0, 1, =2), tumor length on PET (cutoff: 3 cm, 5 cm), the number of PET-positive lymph nodes (0, 1, =3), and PET stage (N0M0, N1M0, M1) were significant prognostic predictor for disease-free survival. However, on multivariate survival analysis, only the number of PET-positive lymph nodes was an independent significant prognostic predictor for disease-free survival (hazard ratio, 1.87; P less than 0.001). These investigators suggested that a revised TNM staging system for esophageal cancer should be considered to include tumor length and the number of positive lymph nodes as important prognostic factors.

Assessment of Response to Therapy

The treatment for localized esophageal cancer is surgery; however, the long-term outcome for patients treated with

surgery alone is very poor. Despite recent advances in surgical techniques and decreasing operative mortality, 5-year survival rates have remained low (5% to 23%) in patients treated by surgery alone (42–44). Recently, multimodality therapeutic approaches, combining surgery with neoadjuvant or adjuvant chemotherapy, radiation therapy, or both, have been used in patients with resectable and unresectable disease.

It has been shown that one of the strong predictors of long-term survival is the degree of response to chemotherapy and radiation therapy (45). Longer survival has been reported in patients showing complete response to chemotherapy and radiation than in patients with partial or no response. Conventional imaging techniques are limited for assessing the effectiveness of therapy, and a delay of several weeks after completion of therapy is necessary for evaluating response. Early assessment of tumor response during treatment would be valuable if nonresponders could be identified reliably, so that alternative treatment could be substituted in these patients and morbidity associated with ineffective treatment could be avoided. The role of PET in monitoring therapy of esophageal cancer has not been studied extensively, but FDG-PET has been used effectively to monitor therapy of several other cancers. Typically, a decrease in tumor FDG uptake is seen early during effective treatment whereas no significant decrease or even an increase is noted with ineffective therapy (46). The changes in FDG uptake generally occur earlier than corresponding anatomic changes on CT. It has been shown that FDG accumulates in sites of inflammation; thus, for assessment of response after therapy, a delay of several weeks or months after completion of therapy is believed to be needed to avoid false-positive results, although the optimal timing of such studies is still being investigated. There are two principal approaches for the use of FDG-PET in monitoring response to therapy in esophageal cancer. One approach involves the use of PET after completion of therapy to identify suitable candidates for surgical resection of esophageal cancer. The other approach involves the use of FDG-PET during the course of therapy to predict response to therapy and identify nonresponders so that an alternative therapy can be initiated.

Several studies have used FDG-PET at the completion of neoadjuvant therapy to assess response to therapy before surgical resection of esophageal cancer. Brücher et al. (47) correlated histopathologic tumor response to neoadjuvant radiation therapy and chemotherapy with changes in tumor FDG uptake, determined 3 weeks after completion of therapy in patients with esophageal carcinoma. The tumors of 13 patients showed a histopathologic response, defined as less than 10% residual viable tumor cells, whereas the tumors in 11 patients did not respond and had 10% or more residual viable tumor cells. The reduction in tumor FDG uptake was significantly more marked in responders than in nonresponders (mean \pm standard deviation, $-72\% \pm 11\%$ versus $-42\% \pm 22\%$; P

$= 0.002$). With a 52% reduction in tumor FDG uptake from baseline defined as the cutoff value, the sensitivity and specificity of FDG-PET for detection of response to neoadjuvant therapy were 100% and 55%, respectively. The positive predictive value and negative predictive value were 72% and 100%, respectively. After surgery, patients without evidence of response by PET had a significantly shorter survival (P less than 0.0001) (47). Similar results have been described by others (48). However, conflicting results were reported by Brink et al. (49), who demonstrated that the percent decrease in tumor FDG uptake 2.7 ± 0.6 weeks after neoadjuvant chemoradiotherapy did not correlate with tumor regression. Downey et al. (50) prospectively studied 24 patients with esophageal cancer before and after completion of neoadjuvant therapy. They demonstrated that patients with a median posttherapy decrease greater than 60% in primary tumor FDG uptake, as measured by the SUV, had better survival than did patients with a median decrease less than 60%. The 2-year disease-free survival in these two groups was 67% and 38%, respectively (P less than 0.05). In this relatively small study, the posttherapy FDG-PET study did not add to the assessment of locoregional resectability and did not detect new distant metastases. In our own experience, FDG-PET performed after induction therapy detected new metastatic disease, precluding resection, in about 10% of patients (Figure 11.4) (R. Battafarano et al., unpublished data). Swisher et al. (51) retrospectively studied 100 patients with PET, CT, and EUS before and 3 to 5 weeks after completion of neoadjuvant therapy. Fifty-eight patients had a pathologic response ($=10\%$ viable cells) to neoadjuvant chemoradiotherapy. After completion of therapy, the sensitivity, specificity, and accuracy were 51%, 69%, and 62%, respectively, for CT (response defined as esophageal thickness less than 14.5 mm); 56%, 75%, and 68%, respectively, for EUS (response defined as mucosal mass length less than 1 cm); 62%, 84%, and 76%, respectively, for PET of the primary tumor (response defined as SUV less than 4); and 69%, 78%, and 75%, respectively, for PET of primary tumor, regional, and distant metastatic disease (response defined as SUV less than 6). The investigators reported that only posttherapy SUV of the primary tumor predicted long-term survival. The 18-month survival of patients with posttherapy SUV of 4 or more was 34% compared with 77% for patients with an SUV less than 4.0 ($P = 0.01$).

Increased FDG uptake in inflamed tissue shortly after completion of therapy makes evaluation of response to cancer therapy by FDG-PET difficult. In a recent study, we found that the change in tumor FDG uptake 3 to 4 weeks after completion of neoadjuvant chemoradiotherapy was not reliable in distinguishing posttreatment inflammation from residual tumor (52). The time interval between chemoradiation therapy and follow-up PET should be carefully selected in future prospective studies to minimize false-positive results. It also is possible that differences in the false-positive rates between various studies

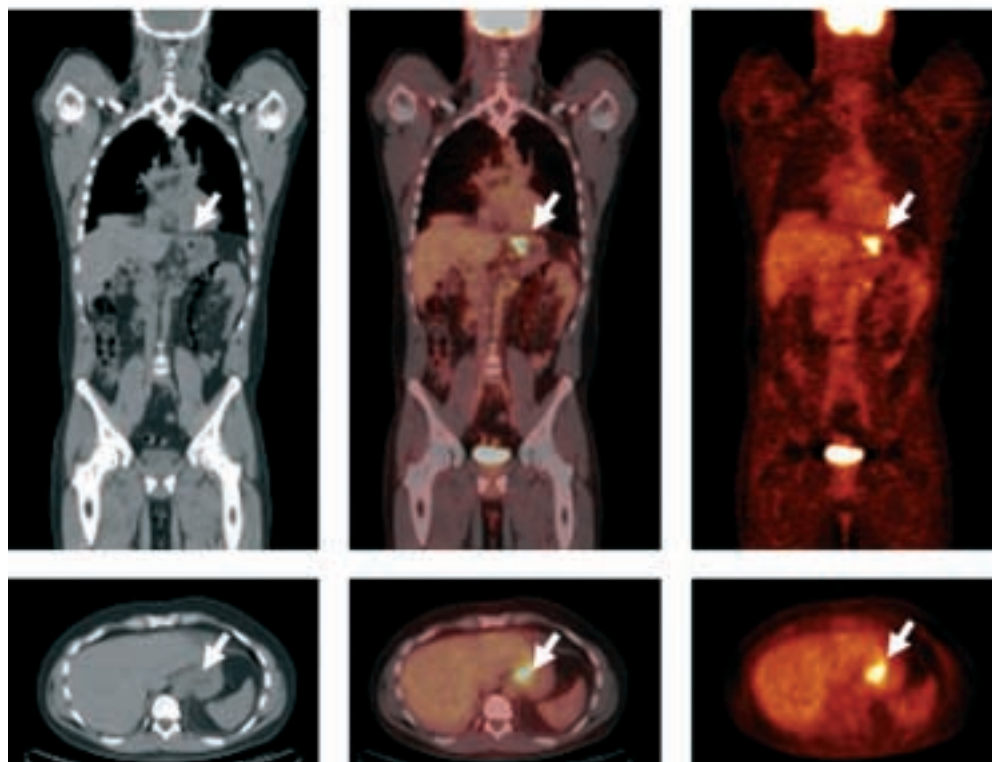
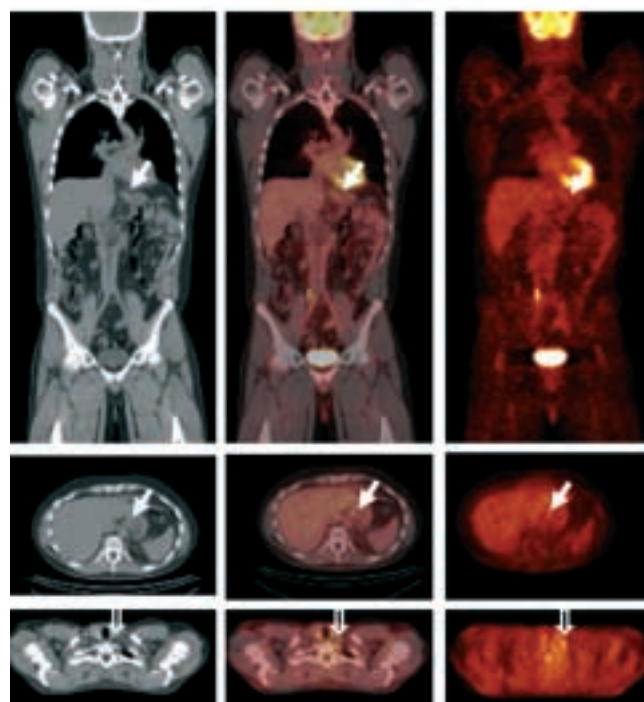
a Initial staging**b Restaging**

Figure 11.4. Response to therapy of esophageal carcinoma. (a) Coronal (*top*) and transaxial (*bottom*) CT, PET/CT fusion, and PET images demonstrate intense FDG uptake within the primary tumor mass (*solid arrows*). (b) Approximately 4 weeks after completion of chemoradiation, similar images show complete resolution of abnormally increased FDG uptake in the primary cancer (*solid arrows*). However, there is a new focal area of increased FDG uptake in the left supraclavicular region (*open arrows*), suspicious for interval development of distant metastatic disease. The diagnosis of metastatic disease was confirmed by biopsy of the left supraclavicular lymph node.

could be related to the dose of radiation therapy or the type of chemotherapeutic agents.

There is evidence that response to therapy can be predicted by PET as soon as 14 days after initiation of chemotherapy or chemoradiotherapy in esophageal

cancer. Weber et al. (53), in a prospective study of 37 patients with locally advanced cancer of the esophagogastric junction, demonstrated that FDG-PET performed 14 days after the first cycle of cisplatin-based polychemotherapy was useful in predicting response to neoadjuvant

chemotherapy. Clinical response was defined as a 50% reduction of tumor length and wall thickness as assessed by endoscopy and standard imaging techniques after 3 months of therapy. Histopathologic tumor response also was assessed in 32 patients who underwent surgery; complete response was defined as either no or a few scattered residual tumor cells. The decrease in tumor FDG uptake was significantly more marked in responders than in nonresponders (mean \pm standard deviation, $-54\% \pm 17\%$ versus $-15\% \pm 21\%$; P less than 0.001). When a 35% reduction in tumor FDG uptake relative to baseline was defined as the cutoff value between response and nonresponse, the early PET findings predicted clinical response with a sensitivity of 93% (14/15 patients) and a specificity of 95% (21/22 patient). Eight of 15 patients with a metabolic response, but only 1 of 22 patients without a metabolic response, had histologically complete or subtotal tumor regression. In addition, patients without evidence of response on PET had significantly shorter progression-free survival ($P = 0.01$) and overall survival ($P = 0.04$) (53). Wieder et al. (54), in a prospective study of 38 patients with intrathoracic esophageal cancer, demonstrated that the change in tumor FDG uptake at 14 days after initiation of neoadjuvant chemoradiotherapy was predictive of subsequent response to therapy and of survival. They observed that the decrease in tumor SUV was significantly higher in responders (defined as less than 10% viable cells in the resected specimen) than in nonresponders (decrease of $44\% \pm 15\%$ in responders versus $21\% \pm 14\%$ in nonresponders) ($P = 0.0055$). In addition, the change in tumor FDG uptake at this time point correlated with patient survival ($P = 0.011$). Using a 30% decrease of FDG uptake from baseline as the cutoff value, FDG-PET had a sensitivity of 93% and a specificity of 88% for distinguishing responders from nonresponders. Similarly, 3 to 4 weeks after completion of therapy, responders had greater reduction in tumor SUV than did nonresponders ($70\% \pm 11\%$ versus $51\% \pm 21\%$) (54). These investigators also reported that a radiation dose of 40 Gy and administration of fluorouracil as a continuous infusion causes a mild increase in FDG uptake in normal esophageal tissue during and early after completion of therapy (54).

These findings suggest that FDG-PET early during treatment or after completion of therapy has the potential to monitor response to therapy. It appears that the magnitude of the change in tumor FDG uptake after therapy in esophageal cancer is predictive of pathologic response and has long-term prognostic significance. With increasing use of multimodality therapy, such non-invasive assessment of tumor response has become more important. Further evaluations are required to define fully the role of PET in assessing response to therapy in esophageal cancer and to show that the use of PET to guide treatment decisions will result in improved patient outcomes.

Detection of Recurrent Disease

The long-term survival of patients with esophageal cancer remains poor despite aggressive therapy. Recurrence is common following presumed curative resection, mainly because of micrometastatic disease; thus, recurrence at distant sites is more common than local recurrence. Patients with recurrent disease have a poor prognosis, and the survival benefit of early detection of recurrent disease is uncertain. However, aggressive therapy of local recurrence may prolong disease-free survival or occasionally be curative. Although anatomic imaging modalities are limited in differentiating scar from recurrent disease, FDG-PET has the ability to detect and differentiate recurrent disease from posttherapy changes when disease has altered metabolism without any structural changes. Thus, PET is more suitable for early detection of recurrent disease.

Fukunaga et al. (40) studied 13 patients with suspected recurrent esophageal cancer; increased FDG uptake was noted in 6 of 7 patients with proven recurrent disease, whereas no significant FDG uptake was seen in the 6 patients who did not have recurrence. Flamen et al. (55) assessed the utility of FDG-PET in diagnosis of suspected recurrent esophageal cancer after initial curative resection in a study of 41 patients. Thirty-three patients proved to have recurrent disease. Forty lesions were identified: 9 local recurrences at the anastomotic site, 12 regional nodal metastases, and 19 distant metastatic lesions. For detection of local recurrence, the sensitivity and specificity were 100% and 43%, respectively, for PET and 100% and 93%, respectively, for conventional imaging (CT and EUS). For detection of metastatic disease, the sensitivity and specificity were 96% and 67%, respectively, for PET and 85% and 67%, respectively, for conventional imaging. FDG-PET provided additional information in 11 of 41 patients (27%); PET correctly detected recurrent disease in 5 patients with equivocal or negative conventional imaging results and demonstrated distant metastasis in 5 patients who had local recurrence. In another patient with equivocal conventional findings, PET correctly excluded recurrent disease. False-positive results attributable to inflammation were found in 4 patients with progressive anastomotic stenoses requiring repetitive dilatations. Thus, the patient's clinical history has to be considered to minimize false-positive results. Kato et al. (56) retrospectively compared PET and CT for detection of recurrent disease in 55 patients who had undergone esophagectomy for esophageal cancer. The sensitivity, specificity, and accuracy for detection of locoregional and distant metastatic disease were 96%, 68%, and 82%, respectively, for PET and 89%, 79%, and 84%, respectively for CT. PET had higher sensitivity but lower specificity than did CT for detection of locoregional recurrence. In addition, PET had higher sensitivity for detection of bone

metastasis than did CT, but had lower sensitivity than did CT for detection of lung metastasis. This study suggests that a combined PET/CT study will be the most sensitive tool for detection of recurrent disease.

Gastric Cancer

The incidence of gastric cancer has declined in the United States, but it is still the second most common cancer (57) and the second most common cause of cancer-related death in the world (58). Because of distensibility of the stomach, gastric cancers often become symptomatic only when the tumor is advanced and unresectable. Ninety-five percent of gastric cancers are adenocarcinomas, and the remaining 5% consist of leiomyosarcomas, lymphomas, carcinoids, squamous cell carcinomas, and other less-common tumors. Gastric cancers arising outside of the cardia have been classified by Lauren into intestinal and diffuse types. Intestinal-type cancers typically form gland-like structures and primarily involve the distal stomach (59). They typically occur in elderly individuals of low socioeconomic status and are believed to develop in a step-wise transition from normal mucosa to atrophic gastritis, intestinal metaplasia, dysplasia, and, finally, adenocarcinoma. The diffuse-type cancer is a poorly differentiated tumor that lacks glandular structures. This lesion is found more often in younger individuals and there appears to be a genetic predisposition (60, 61). Despite their differences, both types of gastric cancers are strongly associated with *Helicobacter pylori* infection (62). Over the past three decades, there has been a decrease in cancer of the antrum and an increase in cancer of the cardia and proximal stomach. Approximately 10% of gastric cancers involve the submucosa throughout the entire stomach, resulting in a rigid nondistendable organ (linitis plastica).

Surgical resection is the only curative therapy for gastric adenocarcinoma, and typically involves en bloc resection of the entire tumor and regional lymph nodes. Patients with early gastric cancer who are treated surgically have an excellent 5-year survival rate of approximately 90% (63). Limited surgery, such as endoscopic mucosal resection and laparoscopic wedge resection, are used in some patients with well-differentiated tumors of less than 2 cm that involve only the mucosal layer without nodal spread. Lymphatic involvement is a major determinant of prognosis in gastric cancer. Unfortunately, gastric cancer is all too often detected when the tumor is advanced and unresectable. Advanced disease is treated with neoadjuvant chemotherapy and has a very poor prognosis; the 5-year survival rate in the United State is reported to be 3% to 13% (63).

Gastric cancer is usually diagnosed by endoscopy or barium studies. These techniques provide excellent evalu-

ation of the mucosal surface of the stomach but are unable to determine the depth of mural invasion by tumor or the extent of metastatic disease. CT and EUS are the most common imaging methods used to determine the locoregional extent of disease. EUS is particularly useful for assessment of the depth of tumor invasion, but both imaging techniques are insufficiently accurate for nodal staging. Staging laparoscopy is performed routinely in patients who are thought to have resectable tumor on the basis of imaging findings to avoid surgery in patients with nonresectable tumor.

Several studies have evaluated the role of FDG-PET in gastric cancer (20, 64–67). Yeung et al. (65) studied 23 patients with gastric cancer. FDG-PET correctly identified all but 1 primary tumor (12/13) and identified recurrent disease at the anastomotic site in 2 patients. FDG-PET had a sensitivity of 93% and specificity of 100% for detection of tumor at the primary site (Figure 11.5). However, for detection of metastatic disease in intraabdominal lymph node stations, FDG-PET had a sensitivity of only 22% (2/9) with a specificity of 97% (32/33). FDG-PET correctly identified distant metastatic disease in 4 patients and was falsely negative in 4 additional patients who had peritoneal tumor spread. Stahl et al. (64) correlated tumor FDG uptake with histopathologic and endoscopic features of gastric cancer in 40 patients with locally advanced

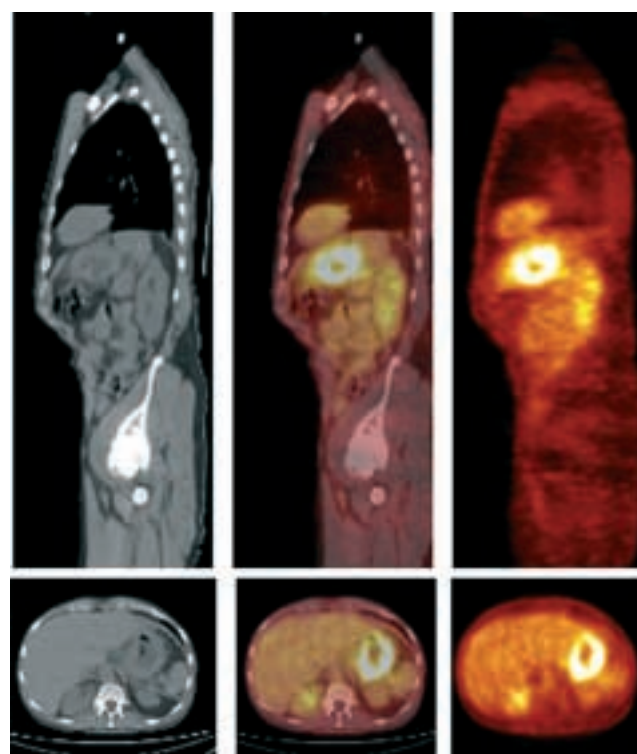


Figure 11.5. Staging of gastric cancer: 62-year-old woman with adenocarcinoma of the stomach. Coronal (*top*) and transaxial (*bottom*) CT, PET/CT fusion, and PET images of the torso demonstrate intense increased FDG uptake in the wall of the stomach. There is no evidence of locoregional or distant metastatic disease.

cancer and 10 controls. FDG-PET detected 24 of the 40 patients (60%) with gastric cancer, and the detection rate was significantly higher for intestinal-type tumors than for nonintestinal-type lesions (83% versus 41%; $P = 0.01$). The mean SUV was significantly different between the intestinal and nonintestinal types (6.7 ± 3.4 versus 4.8 ± 2.8 ; $P = 0.03$), between nonmucinous and mucinous cancers (2/18 intestinal type and 17/22 nonintestinal type contained extra- and intracellular mucin) (7.2 ± 3.2 versus 3.9 ± 2.1 ; P less than 0.01) and between grade 2 and grade 3 tumors (7.4 ± 2.3 versus 5.2 ± 3.3 ; $P = 0.02$). The survival rate was not significantly different between patients with PET-positive and PET-negative tumors ($P = 0.85$). The authors concluded that the low detection rate of gastric cancers by FDG-PET in their series was likely due to the greater number of nonintestinal-type tumors with high mucin content, which typically have lower FDG uptake than intestinal-type tumors. More recently, Mochiki et al. (66) studied 85 patients with gastric cancer with FDG-PET at initial diagnosis. FDG-PET detected the primary tumor in 75% (64/85) of the patients, and a significant correlation was noted between the primary tumor SUV and the depth of invasion (P less than 0.05), the size of the tumor (P less than 0.05), and the presence of lymph node metastasis (P less than 0.05). The primary tumor was not detected on FDG-PET in 21 patients; 15 patients of these patients had T1 primary lesions. The histology of the primary tumors (intestinal versus nonintestinal histology) did not significantly influence tumor detectability by PET ($P = 0.5$) in this study. CT was more sensitive (65% versus 23%) but less specific (77% versus 100%) than FDG-PET for detecting locoregional lymph node metastasis. This result was attributed to the difficulty of distinguishing FDG uptake in locoregional lymph nodes from that in the adjacent primary tumor on PET images. The intensity of FDG uptake was predictive of survival; patients with primary tumor SUVs greater than 4 had significantly poorer 2-year survival (51%) than did those with SUVs less than 4 (81%) (P less than 0.05). In addition, the 2-year survival of patients with PET-positive cancers was 66% and that for patients with PET-negative cancers was 94%. Yoshioka et al. (67) reported that FDG uptake in the primary tumor and in metastatic foci in the liver, lymph nodes, and lung is greater than that in bone metastases or peritoneal or pleural carcinomatosis. They also reported higher primary tumor FDG uptake in well-differentiated and moderately differentiated adenocarcinoma than in poorly differentiated adenocarcinoma and signet ring cell carcinoma (13.2 ± 6.3 versus 7.7 ± 2.6 ; P less than 0.05).

As in esophageal cancer, patients with gastric cancer who respond to neoadjuvant therapy have a more-favorable outcome. However, only 30% to 40% of patients respond to neoadjuvant therapy. Thus, the large fraction of patients with nonresponding tumors undergo several months of ineffective, toxic therapy without a survival benefit. Ott et al. prospectively evaluated 44 patients with

locally advanced gastric cancer with FDG-PET before therapy and 14 days after initiation of cisplatin-based polychemotherapy (68); 35 of the 44 tumors had sufficient uptake on the PET images for quantitative analysis. Metabolic response was defined as a decrease of tumor FDG uptake by 30% or more. The PET findings after 14 days of therapy correctly predicted histopathologic response after 3 months of neoadjuvant therapy in 10 of 13 responders (77%) and in 19 of the 22 nonresponders (86%). Metabolic response also was predictive of survival. The median overall survival was 19 months for patients without a metabolic response (2-year survival of 25%) and had not been reached for patients with a metabolic response (2-year survival of 90%) ($P = 0.002$). If confirmed in larger studies, these results suggest that PET will be quite valuable for guiding the management of patients with locally advanced disease and for sparing nonresponders unnecessary morbidity and expenses of ineffective therapy.

The limitations of FDG-PET for evaluation of gastric cancer are similar to the limitations encountered in esophageal cancer and include poor sensitivity for detecting small tumor deposits. Sensitivity for detection of diffuse-type gastric cancer with high mucin content is lower than for detection of the intestinal type of gastric cancer (64, 68). Normal, moderately intense physiologic FDG uptake in the stomach may obscure tumors with low-level FDG uptake.

Gastrointestinal Stromal Tumors

Gastrointestinal stromal tumors (GISTs) are the most common mesenchymal tumors of the gastrointestinal tract and account for approximately 0.1% to 3% of all gastrointestinal (GI) tract tumors. GISTs are defined as immunohistochemically Kit-positive primary mesenchymal tumors of the GI tract. Approximately 95% of GISTs stain positively for Kit (CD117), a tyrosine kinase growth factor receptor (69). These tumors are thought to arise from Cajal cells in the gut wall, which are important for gut motor function. The majority of tumors previously diagnosed as GI smooth muscle tumors, such as leiomyoma, leioblastoma, or leiomyosarcoma, are now thought to have been GISTs. However, differentiation of leiomyosarcoma from GIST is important to determine prognosis and the appropriateness of Kit-inhibitor therapy. Mature smooth muscle tumors have negligible mitotic activity and have benign behavior and do not express Kit. GISTs occur throughout the entire GI tract and also may arise from the omentum, mesentery, and retroperitoneum. GISTs arise predominantly in the stomach (60%) and small intestine (25%) and rarely in the rectum (5%), esophagus (2%), and a variety of other locations (5%) in the abdomen (69). They can be small benign tumors or sarcomas. Benign GISTs are more common in the

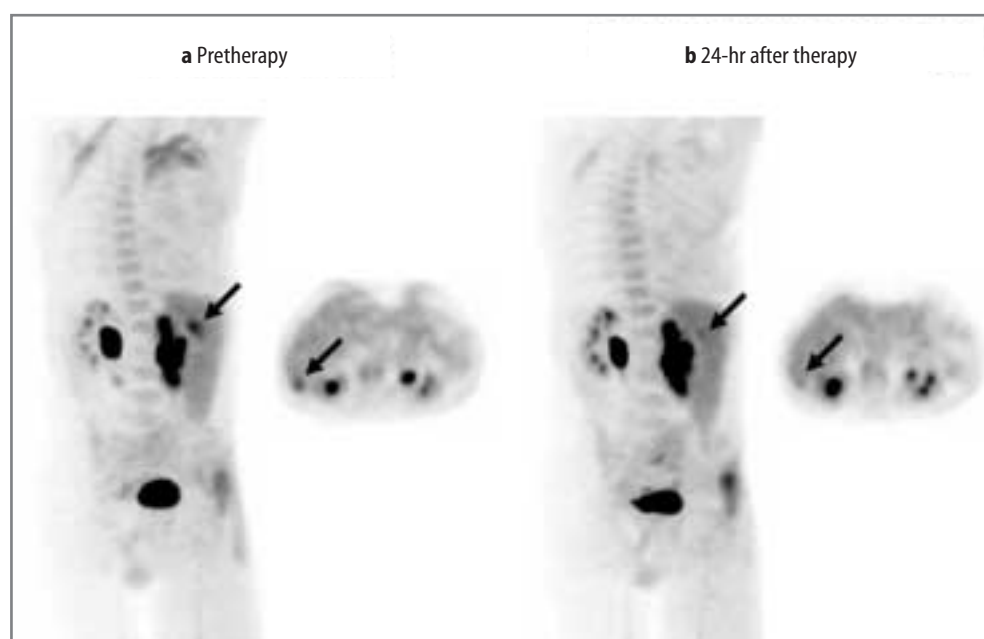
stomach whereas malignant GISTs are more common in the intestines. Tumors that have metastasized at presentation have a very poor prognosis (70). Thirty percent of GISTs are malignant and 70% are benign. Mitotic rate, tumor size, and tumor site are three important prognostic factors. Tumors that are small (≤ 2 cm) and show fewer than 5 mitotic figures per 50 high-power fields have an excellent prognosis, likely independent of site. Malignant GISTs tend to recur, and they metastasize commonly to the liver and peritoneum and less commonly to lung, pleura, peritoneum, bone, and subcutaneous tissues (71). Patients with metastatic or recurrent disease have a median overall survival in the range of 12 to 19 months (72, 73).

Radiologic features of GIST vary depending on their size and organ of origin. Most GIST that arise within the muscularis propria of the gut wall commonly manifest as dominant masses outside the organ of origin. Dominant intramural and intraluminal masses are less common. GISTs that occur in the GI tract and mesentery have areas of low attenuation on CT attributable to hemorrhage, necrosis, or cyst formation (74). After successful therapy, there is a significant decrease in CT attenuation values (75, 76).

Surgery is the mainstay of therapy for GISTs. These tumors are insensitive to conventional chemotherapy and radiation. GISTs are generally characterized by a gain-of-function mutation of the Kit receptor and, occasionally, of the platelet-derived growth factor (PDGF) receptor α . Mutant isoforms of the Kit or PDGF receptors uniformly expressed by GIST are considered the therapeutic targets for imatinib mesylate (STI571, Gleevec), a specific inhibitor of these tyrosine kinase receptors (77). This mutant receptor is thought to be the main reason for malignant transformation as well as for tumor growth in these patients (79). Imatinib inhibits tumor growth in GIST by competitive interaction at the adenosine triphos-

phate-binding site of the *c-kit* receptor (80). However, imatinib therapy is quite costly and is associated with several side effects, including anemia, periorbital edema, skin rash, fatigue, granulocytopenia, and diarrhea (81). The type of KIT or PDGFR- α mutation in advanced GIST is predictive of the response to imatinib therapy. Most GISTs express kinase oncoproteins that are intrinsically sensitive to imatinib and have an excellent overall clinical response to this drug. However, a minority of GISTs express kinase oncoproteins that are either intrinsically resistant to imatinib or are associated with a poor clinical response despite in vitro sensitivity to the drug (82). The response rates in GIST patients are 4% complete remission, 67% partial remission, 18% stable disease, and 11% progression, and 73% of GIST patients are free from progression at 1 year (81). It is important to assess response to therapy early to identify those patients with stable disease or disease progression, who can then be treated more aggressively with a higher dosage of imatinib or be considered for treatment with other investigational agents. FDG-PET has been shown to be superior to CT in detection of early metabolic changes indicative of tumor response induced by imatinib therapy. Gayed et al. (71) studied 54 patients with GIST and showed that FDG-PET detected 110 and CT detected 114 involved sites and/or organs, respectively, before initiation of therapy. The sensitivity and positive predictive values were 93% and 100%, respectively for CT and 86% and 98%, respectively, for FDG-PET. At 2 months after therapy, PET and CT findings agreed in 71% of patients (57% responders and 14% nonresponders). FDG-PET predicted response to therapy earlier than did CT in 22.5% of patients whereas CT predicted lack of response in 4% of the patients earlier than did PET (Figure 11.6). Stroobants et al. (83) studied 21 patients with GIST before and 8 days after initiation of

Figure 11.6. Response to therapy of gastrointestinal stromal tumor: 64-year-old man with metastatic gastrointestinal stromal tumor undergoing therapy with imatinib mesylate. (a) Left posterior oblique reprojection image (left) and a transaxial image (right) demonstrate a focal area (arrows) of increased FDG uptake in the posterior segment of the right lobe of the liver, consistent with hepatic metastasis. (b) Twenty-four hours after initiation of imatinib therapy: left posterior oblique reprojection image (left) and a transaxial image (right) show almost complete resolution (arrows) of the FDG uptake in the hepatic metastasis.



Gleevec therapy. PET response based on the European Organization for Research and Treatment (EORTC) criteria (84) was compared with clinical response based on the RECIST criteria (85). PET response was associated with a longer progression-free survival (PFS) by comparison with PET nonresponse (92% versus 12% at 1 year; $P = 0.00107$).

In a recent study, Goerres et al. (86) evaluated 28 patients with PET/CT after treatment with imatinib. Patients without FDG uptake after the start of treatment had a better prognosis than did patients with residual activity. However, contrast-enhanced CT alone provided insufficient prognostic power. In another study, Antoch et al. (5) compared the value of PET alone, CT alone, and combined PET/CT for assessment of response to imatinib therapy in 20 patients with GIST. When patients were evaluated with FDG-PET/CT before and 1, 3, and 6 months after initiation of therapy, 135 lesions were detected by PET alone, 249 by CT alone, 279 by PET and CT side-by-side evaluation, and 282 lesions by fused PET/CT. PET/CT correctly determined tumor response in 95% of the patients after 1 month and in 100% after 3 months and 6 months of therapy. PET and CT images viewed side-by-side correctly determined response in 90% of the patients at 1 month and 100% at 3 and 6 months after therapy. PET alone correctly diagnosed response in 85% of the patients at 1 month and 100% at 3 and 6 months after therapy. CT was accurate in 44% of the patients at 1 month and 60% at 3 and 57% at 6 months after therapy. It appears that the combination of functional and anatomic imaging has the best performance for assessment of response to imatinib therapy in patients with GIST.

References

1. Jemal A, Tiwari RC, Murray T, et al. Cancer Statistics, 2004. *CA Cancer J Clin* 2004;54:8-29.
2. Koshy M, Esiashvili N, Landry JC, Thomas CR Jr, Matthews RH. Multiple management modalities in esophageal cancer: epidemiology, presentation and progression, work-up, and surgical approaches. *Oncologist* 2004;9:137-146.
3. Stein HJ, Sendler A, Fink U, Siewert JR. Multidisciplinary approach to esophageal and gastric cancer. *Surg Clin N Am* 2000;80:659-682.
4. Bar-Shalom R, Yefremov N, Guralnik L, et al. Clinical performance of PET/CT in evaluation of cancer: additional value for diagnostic imaging and patient management. *J Nucl Med* 2003;44:1200-1209.
5. Antoch G, Saoudi N, Kuehl H, et al. Accuracy of whole-body dual-modality fluorine-18-2-fluoro-2-deoxy-D-glucose positron emission tomography and computed tomography (FDG-PET/CT) for tumor staging in solid tumors: comparison with CT and PET. *J Clin Oncol* 2004;22:4357-4368.
6. Röscher T. Endosonographic staging of esophageal cancer: a review of literature results. *Gastrointest Endosc Clin N Am* 1995;5:537-547.
7. Halvorsen RA Jr, Magruder-Habib K, Foster WL Jr, Roberts L Jr, Postlethwait RW, Thompson WM. Esophageal cancer staging by CT: long-term follow-up study. *Radiology* 1986;161:147-151.
8. Inculet RI, Keller SM, Dwyer A, Roth JA. Evaluation of noninvasive tests for the preoperative staging of carcinoma of the esophagus: a prospective study. *Ann Thorac Surg* 1985;40:561-565.
9. Urmacher C, Brennan MF. Preoperative staging of esophageal cancer: comparison of endoscopic US and dynamic CT. *Radiology* 1991;181:419-425.
10. Flanagan FL, Dehdashti F, Siegel BA, et al. Staging of esophageal cancer with FDG-PET. *AJR* 1997;168:417-424.
11. Block MI, Sundaresan SR, Patterson GA, et al. Improvement in staging of esophageal cancer with the addition of positron emission tomography. *Ann Thorac Surg* 1997;64:770-777.
12. Kole AC, Plukker JT, Nieweg OE, et al. Positron emission tomography for staging oesophageal and gastroesophageal malignancy. *Br J Cancer* 1998;74:521-527.
13. Luketich JD, Schauer P, Meltzer CC, et al. The role of positron emission tomography in staging esophageal cancer. *Ann Thorac Surg* 1997;64:765-769.
14. Luketich JD, Friedman DM, Weigel TL, et al. Evaluation of distant metastases in esophageal cancer: 100 consecutive positron emission tomography scans. *Ann Thorac Surg* 1999;68:1133-1137.
15. Rankin SC, Taylor H, Cook GJR, et al. Computed tomography and positron emission tomography in the pre-operative staging of oesophageal carcinoma. *Clin Radiol* 1998;53:659-665.
16. Yeung HWD, Macapinlac HA, Mazumdar M, Bains M, Finn RD, Larson SM. FDG-PET in esophageal cancer: incremental value over computed tomography. *Clin Posit Imaging* 1999;5:255-260.
17. Flamen P, Lerut A, Van Cutsem E, et al. Utility of positron emission tomography for the staging of patients with potentially operable esophageal carcinoma. *J Clin Oncol* 2000;18:3202-3210.
18. Kobori O, Kirihaara Y, Kosaka N, Hara T. Positron emission tomography of esophageal carcinoma using ^{11}C -choline and ^{18}F -fluorodeoxyglucose. A novel method of preoperative lymph node staging. *Cancer (Phila)* 1999;86:1638-1648.
19. Duignan JP, McEntee GP, O'Connell DJ, Bouchier-Hayes DJ, O'Malley E. The role of CT in the management of carcinoma of the oesophagus and cardia. *Ann R Coll Surg Engl* 1987;69:286-288.
20. McAteer D, Wallis F, Couper G, et al. Evaluation of ^{18}F -FDG positron emission tomography in gastric and oesophageal carcinoma. *Br J Radiol* 1999;72:525-529.
21. Räsänen JV, Sihvo EIT, Knuuti J, et al. Prospective analysis of accuracy of positron emission tomography, computed tomography, and endoscopic ultrasonography in staging of adenocarcinoma of the esophagus and the esophagogastric junction. *Ann Surg Oncol* 2003;10:954-960.
22. Meltzer CC, Luketich JD, Friedman D, et al. Whole-body FDG positron emission tomographic imaging for staging esophageal cancer comparison with computed tomography. *Clin Nucl Med* 2000;25:882-887.
23. Fukunaga T, Okazumi S, Koide Y, Isono K, Imazeki K. Evaluation of esophageal cancers using fluorine-18-fluorodeoxyglucose PET. *J Nucl Med* 1998;39:1002-1007.
24. Kato H, Kuwano H, Nakajima M, et al. Comparison between positron emission tomography and computed tomography in the use of the assessment of esophageal carcinoma. *Cancer (Phila)* 2002;94:921-928.
25. Ellis FH, Eatkin E, Krasna MJ, Heatley GH, Balogh K. Staging of carcinoma of esophagus and gastric cardia: a comparison of different staging criteria. *J Surg Oncol* 1993;52:231-235.
26. Peters JH, Hoefft SF, Heimbucher J, et al. Selection of patients for curative or palliative resection of esophageal cancer based on pre-operative endoscopic ultrasonography. *Arch Surg* 1994;129:534-539.
27. Skinner DB, Little AG, Ferguson MK, Soriano A, Statszak VM. Selection of operation for esophageal cancer based on staging. *Ann Surg* 1986;204:391-401.
28. Lerut T, Flamen P, Ectors N, et al. Histopathologic validation of lymph node staging with FDG-PET scan in cancer of esophagus and gastroesophageal junction: a prospective study based on primary surgery with extensive lymphadenectomy. *Ann Surg* 2000;232:743-752.
29. Kim K, Park SJ, Kim B-T, Lee KS, Shim YM. Evaluation of lymph node metastases in squamous cell carcinoma of the esophagus with

- positron emission tomography. *Ann Thorac Surg* 2001;71:1290-1294.
30. Himeno S, Yasuda S, Shimada H, Tajima T, Makuuchi H. Evaluation of esophageal cancer by positron emission tomography. *Jpn J Clin Oncol* 2002;32(9):340-346.
 31. Wren SM, Stijns P, Srinivas S. Positron emission tomography in the initial staging of esophageal cancer. *Arch Surg* 2002;137:1001-1007.
 32. Yoon YC, Lee KS, Shim YM, Kim B-T, Kim K, Kim TS. Metastasis to regional lymph nodes in patients with esophageal squamous cell carcinoma: CT versus FDG PET for presurgical detection—prospective study. *Radiology* 2003;227:764-770.
 33. van Westreenen HL, Westertep M, Bossuyt PMM, et al. Systematic review of the staging performance of ¹⁸F-fluorodeoxyglucose positron emission tomography in esophageal cancer. *J Clin Oncol* 2004;22:3805-3812.
 34. Heeren PAM, Jager PL, Bongaerts F, van Dullemen H, Sluiter W, Plukker JTM. Detection of distant metastases in esophageal cancer with ¹⁸F-FDG PET. *J Nucl Med* 2004;45:980-987.
 35. Liberale, Van Laethem JL, Gay F, et al. The role of PET scan in the preoperative management of esophageal cancer. *Eur J Surg Oncol* 2004;30:942-947.
 36. Luketich JD, Schauer P, Urso K, et al. Future directions in esophageal cancer. *Chest* 1998;113:120S-122S.
 37. Schöder H, Erdi YE, Larson SM, et al. PET/CT: a new imaging technology in nuclear medicine. *Eur J Nucl Med* 2003;30:1419-1437.
 38. Leiderman M, Gaitini D, Keidar Z, et al. The value of PET/CT using FDG in patients with esophageal cancer. *J Nucl Med* 2003;44:21P.
 39. Wallace MB, Nietert PJ, Earle C, et al. An analysis of multiple staging management strategies for carcinoma of the esophagus: computed tomography, endoscopic ultrasound, positron emission tomography, and thoracoscopy/laparoscopy. *Ann Thorac Surg* 2002;74:1026-1032.
 40. Fukunaga T, Enomoto K, Okazumi S, et al. Analysis of glucose metabolism in patients with esophageal cancer by PET: estimation of hexokinase activity in the tumor and usefulness for clinical assessment using FDG. *Nippon Geka Gakka Zasshi* 1994;95:317-325.
 41. Choi JY, Jang H-J, Shim YM, et al. ¹⁸F-FDG PET in patients with esophageal squamous cell carcinoma undergoing curative surgery: prognostic implications. *J Nucl Med* 2004;45:1843-1850.
 42. Orringer M. Transhiatal esophagectomy with thoracoscopy. In: Zuidema G (ed). *Surgery of the Alimentary Tract*, 3rd ed. Philadelphia: Saunders, 1991:408-433.
 43. Katlic MR, Wilkins EW, Grillo HC. Three decades of treatment of esophageal squamous carcinoma at Massachusetts General Hospital. *J Thorac Cardiovas Surg* 1990;99:929-938.
 44. Roder JT, Busch R, Stein HJ, et al. Ratio of invaded to removed lymph nodes as a predictor of survival in squamous cell carcinoma of esophagus. *Br J Surg* 1994;81:410-413.
 45. Thomas CR. Biology of esophageal cancer and the role of combined modality therapy. *Surg Clin N Am* 1997;77:1139-1167.
 46. Smith TAD. FDG uptake, tumour characteristics and response to therapy: a review. *Nucl Med Commun* 1998;19:97-105.
 47. Bücher BLD, Weber W, Bauer M, et al. Neoadjuvant therapy of esophageal squamous cell carcinoma: response evaluation by positron emission tomography. *Ann Surg* 2001;233:300-309.
 48. Kato H, Kuwano H, Nakajima M, et al. Usefulness of positron emission tomography for assessing the response of neoadjuvant chemoradiotherapy in patients with esophageal cancer. *Am J Surg* 2002;184:279-283.
 49. Brink I, Hentschel M, Bley TA, et al. Effects of neoadjuvant radiochemotherapy on ¹⁸F-FDG-PET in esophageal carcinoma. *Eur J Surg Oncol* 2004;30:544-550.
 50. Downey RJ, Akhurst T, Ilson D, et al. Whole body ¹⁸F-FDG-PET and the response of esophageal cancer to induction therapy: results of a prospective trial. *J Clin Oncol* 2003;21:428-432.
 51. Swisher SG, Maish M, Erasmus JJ, et al. Utility of PET, CT, and EUS to identify pathologic responders in esophageal cancer. *Ann Thorac Surg* 2004;78:1152-1160.
 52. Arslan N, Miller TR, Dehdashti F, Siegel BA, Battafarano RJ. Evaluation of response to neoadjuvant therapy by quantitative 2-deoxy-2-[¹⁸F]fluoro-D-glucose with positron emission tomography in patients with esophageal cancer. *Mol Imaging Biol* 2002;4:320-329.
 53. Weber WA, Ott K, Becker K, et al. Prediction of response to preoperative chemotherapy in adenocarcinomas of esophagogastric junction by metabolic imaging. *J Clin Oncol* 2001;19:3058-3065.
 54. Wieder HA, Brücher BLD, Zimmermann F, et al. Time course of tumor metabolic activity during chemoradiotherapy of esophageal squamous cell carcinoma and response to treatment. *J Clin Oncol* 2004;22:900-908.
 55. Flamen P, Lerut A, Van Cutsem E, et al. The utility of positron emission tomography for the diagnosis and staging recurrent esophageal carcinoma. *J Thorac Cardiovasc Surg* 2000;120:1085-1092.
 56. Kato H, Miyazaki T, Nakajima M, Fukuchi M, Manda R, Kuwano H. Value of positron emission tomography in the diagnosis of recurrent oesophageal carcinoma. *Br J Surg* 2004;91:1004-1009.
 57. Landis S, Murray T, Bolden S, et al. Cancer statistics. *CA Cancer J Clin* 1999;49:8-31.
 58. Neugut AI, Hayek M, Howe G. Epidemiology of gastric cancer. *Semin Oncol* 1996;23:281-291.
 59. Lauren P. The two histological types of gastric carcinoma: diffuse and so-called intestinal-type carcinoma. *Acta Pathol Microbiol Scand* 1965;64:31-49.
 60. Fuch CS, Meyer RJ. Gastric carcinoma. *N Engl J Med* 1995;333:32-41.
 61. Hohenberger P, Gretscher S. Gastric cancer. *Lancet* 2003;362:305-315.
 62. Zinvy J, Wang TC, Yantiss R, Kim KK, Houghton JM. Role of therapy or monitoring in preventing progression to gastric cancer. *J Clin Gastroenterol* 2003;36:S50-S60.
 63. Roukos DH. Current advances and changes in treatment strategy may improve survival and quality of life in patients with potentially curable gastric cancer. *Ann J Surg Oncol* 1999;6:46-56.
 64. Stahl A, Ott K, Weber WA, et al. FDG PET imaging of locally advanced gastric carcinomas: correlation with endoscopic and histopathologic findings. *Eur J Nucl Med* 2003;30:288-295.
 65. Yeung HWD, Macapinlac HA, Karpeh M, Finn RD, Larson SM. Accuracy of FDG-PET in gastric cancer: preliminary experience. *Clin Posit Imaging* 1999;4:213-221.
 66. Mochiki E, Kuwano H, Katoh H, Asao T, Oriuchi N, Endo K. Evaluation of ¹⁸F-2-deoxy-2-fluoro-D-glucose positron emission tomography for gastric cancer. *World J Surg* 2004;28:247-253.
 67. Yoshioka T, Yamaguchi K, Kubota K, et al. Evaluation of ¹⁸F-FDG PET in patients with advanced, metastatic, or recurrent gastric cancer. *J Nucl Med* 2003;44:690-699.
 68. Ott K, Fink U, Becker K, Stahl A, et al. Prediction of response to preoperative chemotherapy in gastric carcinoma by metabolic imaging: results of a prospective trial. *J Clin Oncol* 2003;21:4604-4610.
 69. Corless CL, Fletcher JA, Heinrich MC. Biology of gastrointestinal stromal tumors. *J Clin Oncol* 2004;22:3813-3825.
 70. Miettinen M, Lasota J. Gastrointestinal stromal tumors (GISTs): definition, occurrence, pathology, differential diagnosis and molecular genetics. *Pol J Pathol* 2003;54:3-24.
 71. Gayed I, Vu T, Iyer R, et al. The role of ¹⁸F-FDG PET in staging and early prediction of response to therapy of recurrent gastrointestinal stromal tumors. *J Nucl Med* 2004;45:17-21.
 72. Casper ES. Gastrointestinal stromal tumors. *Curr Treat Options Oncol* 2000;1:267-273.
 73. Dematteo RP, Maki RG, Antonescu C, Brennan MF. Targeted molecular therapy for cancer: the application of STI571 to gastrointestinal stromal tumor. *Curr Probl Surg* 2003;40:144-193.
 74. Levy AD, Remotti HE, Thompson WM, Sobin LH, Miettinen M. Gastrointestinal stromal tumors: radiologic features with pathologic correlation. *RadioGraphics* 2003;23:283-304.
 75. Choi H, Faria SC, Benjamin RS, Podoloff DA, Macapinlac HA, Charnsangavej C. Monitoring treatment effects of STI-571 on gastrointestinal stromal tumors (GIST) with CT and PET: a quantitative analysis [abstract]. *Radiology* 2002;225(suppl):583.

76. Chen MYM, Bechtold RE, Savage PD. Cystic changes in hepatic metastases from gastrointestinal stromal tumors (GISTs) treated with Gleevec (imatinib mesylate). *Am J Radiol* 2002;179:1059–1062.
77. Borg C, Terme M, Taïeb J, et al. Novel mode of action of *c-kit* tyrosine kinase inhibitors leading to NK cell-dependent antitumor effects. *J Clin Invest* 2004;114:379–388.
78. Lasota J, Jasinski M, Sarlomo-Rikala M, Miettinen M. Mutations in exon 11 of *c-kit* occur preferentially in malignant versus benign gastrointestinal stromal tumors and do not occur in leiomyomas or leiomyosarcomas. *Am J Pathol* 1999;154:53–60.
79. Taniguchi M, Nishida T, Hirota S, et al. Effect of *c-kit* mutation on prognosis of gastrointestinal stromal tumors. *Cancer Res* 1999;59:4297–4300.
80. Heinrich MC, Griffith DJ, Druker BJ, Wait CL, Ott KA, Zigler AJ. Inhibition of *c-kit* receptor tyrosine kinase activity by STI 571, a selective tyrosine kinase inhibitor. *Blood* 2000;96:925–932.
81. Verweij J, van Oosterom A, Blay J-Y, et al. Imatinib mesylate (STI-571 Glivec®, Gleevec™) is an active agent for gastrointestinal stromal tumours, but does not yield responses in other soft-tissue sarcomas that are unselected for a molecular target: results from an EORTC soft tissue and bone sarcoma group phase II study. *Eur J Cancer* 2003;39:2006–2011.
82. Heinrich MC, Corless CL, Demetri GD, et al. Kinase mutations and imatinib response in patients with metastatic gastrointestinal stromal tumor. *J Clin Oncol* 2003;21:4342–4349.
83. Stroobants S, Goeminne J, Seegers M, et al. ¹⁸F-DG-positron emission tomography for the early prediction of response in advanced soft tissue sarcoma treated with imatinib mesylate (Glivec). *Eur J Cancer* 2003;39:2012–2020.
84. Young H, Baum R, Cremerius U, et al. Measurement of clinical and subclinical tumour response using [¹⁸F]-fluorodeoxyglucose and positron emission tomography: review and 1999 EORTC recommendations. European Organization for Research and Treatment of Cancer (EORTC) PET Study Group. *Eur J Cancer* 1999;35:1773–1782.
85. Therasse P, Arbuck SG, Eisenhauer EA, et al. New guidelines to evaluate the response to treatment in solid tumors. *J Natl Cancer Inst* 2000;92:205–216.
86. Goerres GW, Stupp R, Barghouth G, et al. The value of PET, CT and in-line PET/CT in patients with gastrointestinal stromal tumours: long-term outcome of treatment with imatinib mesylate. *Eur J Nucl Med Mol Imaging* 2004 Sept 4 (online).

Positron Emission Tomography

Clinical Practice

Valk, P.E.; Delbeke, D.; Bailey, D.L.; Townsend, D.W.;

Maisey, M.N. (Eds.)

2006, XIV, 475 p., Hardcover

ISBN: 978-1-85233-971-5