

## 8 Microsurgical Treatment of Odontoid Fractures

P. Klimo Jr, G. Rao, R. I. Apfelbaum

### 8.1 Terminology

The first two cervical vertebrae, *C1* and *C2*, are also known as the *atlas* and *axis*, respectively.

The *odontoid process of C2*, also known as the *dens*, is the superiorly projecting bony prominence from the body of *C2* that sits within the anterior portion of the ring of *C2*. *C1* rotates around this.

*Anterior odontoid screw fixation* involves the reduction and stabilization of an odontoid fracture using a screw that extends from the inferior anterior aspect of the *C2* body, across the fracture line, and through the tip of the odontoid process.

#### 8.1.1

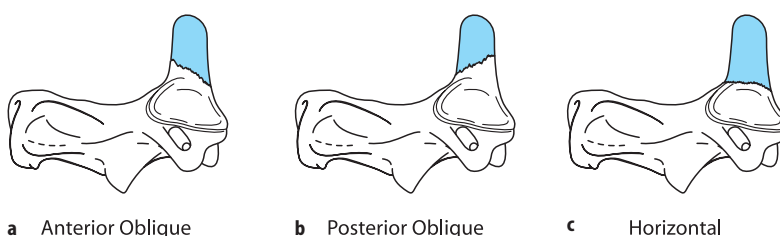
##### Classification of odontoid fractures [5, 9, 35]

A *type I* fracture is a rarely occurring fracture of the apical portion of the odontoid process. A *type II* fracture is a fracture through the base or waist of the dens. These are the most common and may be either anterolisthesed or retrolisthesed. Type II and “shallow” type III fractures have been further classified, based on the anterior–posterior direction of the fracture line, as anterior oblique, posterior oblique, or horizontal fractures (Fig. 8.1). Anterior oblique fractures slope inferiorly from posterior to anterior, whereas posterior oblique fractures slope inferiorly from anterior to posterior and horizontal fractures slope minimally or not at all. *Type IIa* fractures are type II fractures with a comminuted base and *type III* fractures extend into the body of *C2*.

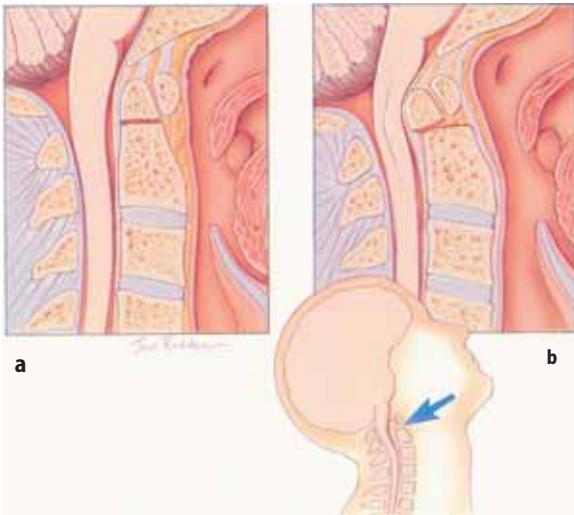
### 8.2 Surgical Principle

The *C1-2* articulation is one of the most complex joints in the spine. It allows a significant amount of motion while still protecting the spinal cord. Approximately 50% of cervical rotation occurs at this joint. The rotation that occurs around the odontoid process is facilitated by the unique anatomy of this region [63]. Both articular surfaces of the *C1* and *C2* lateral masses have a convex orientation in the sagittal plane and are sloped upward from lateral to medial. Capsular ligaments are weak, strong posterior ligaments are absent (the strong ligamentum flavum is replaced by the thin atlantoaxial and atlanto-occipital membranes), and an intervertebral disc and its restricting annulus fibrosis are also absent. As *C1* rotates on *C2*, the sloping joint surfaces allow *C2* to rise upward. This allows greater excursion before the alar ligaments connecting the dens to the occiput tighten and restrict this motion than would be allowed if the surfaces had a horizontal orientation. Other important adaptations are that the space available for the cord is generous, the instantaneous axis of rotation (IAR) is close to the spinal cord, and the vertebral arteries loop laterally. These features allow rotation without jeopardizing the neural and vascular elements.

Translation anteriorly and posteriorly must of course be avoided to protect the spinal cord. This is achieved by having the odontoid process or dens, the superior osseous protrusion of the body of *C2*, contained within the anterior portion of the ring of *C1* by the transverse ligament (transverse portion of the cruciate ligament). The transverse ligament is one of the strongest ligaments in the human body. Disruption of



**Fig. 8.1.** Schematic illustrations of the anterior oblique (a), posterior oblique (b), and horizontal (c) fracture classification. This classification scheme is based on the inferior direction of the slope of the fracture, as demonstrated on lateral radiographs. In our series [9], horizontal fractures occurred in 49%, posterior oblique in 34%, and anterior oblique in 16% of the cases



**Fig. 8.2.** Type II odontoid fracture in a neutral position (a) and extension (b). Note the retroolisthesis with extension causing spinal cord compression (*inset in b*)

either the transverse ligament or odontoid process will result in instability, with the patient no longer protected from potential neurologic damage under physiologic loads (Fig. 8.2). This is true even if no motion is seen on flexion and extension radiographs because the other supporting structures may prevent motion under relatively mild stresses. The supporting structures are not capable, however, of resisting larger forces that may be experienced in minor traumas such as falls or low-impact motor vehicle accidents. If the instability is due solely to failure of the bony elements, healing is possible with external immobilization. If the transverse ligament is disrupted, however, surgery is required to achieve bony fusion.

Odontoid fractures are common cervical spine injuries and account for 10–20% of all cervical spine fractures [9, 15, 24, 30, 39, 53, 57]. Most of these odontoid fractures involve the odontoid process at the base or extend into the body of C2 (59%). Odontoid fractures are usually precipitated by a blow to the vertex or upper portion of the skull [51]. Because of the mechanics of the C1-2 articulation as described above, odontoid process fractures usually cause atlantoaxial instability, placing the patient at significant risk for immediate or delayed catastrophic spinal cord compromise [20]. Thus, accurate diagnosis and spinal stabilization, when needed, is imperative. The treatment strategies for odontoid process fractures vary from external stabilization to various internal fixation techniques.

### 8.3 History

Surgical options for treating type II and shallow type III odontoid process fractures include posterior atlantoaxial fusion and direct anterior dens screw fixation. Historically, posterior cervical fusion was the primary operative treatment when external immobilization failed or was considered unsuitable. Various wiring techniques combined with bone grafting, including those described by Brooks, Gallie, and later Dickman and Sonntag, have been used to achieve posterior cervical fusion [16, 23, 31, 49]. Successful fusion when these are combined with a rigid orthosis is in the 80–90% range.

In 1992, Jeanneret and Magerl reported their experience treating odontoid fractures with C1-2 transarticular screw fixation, which is used for internal fixation and combined with a posterior bony fusion [40]. A number of authors have reported successful fusion rates approaching 100% using transarticular screws [22, 33, 47, 60]. However, certain conditions can make C1-2 transarticular screw placement difficult. These conditions include insufficient space for screw placement in the isthmus of C2 or an anomalous course of the vertebral artery.

Fusion of the C1-2 joint eliminates 50% of the rotation of the head, a significant loss of motion. Consequently, an alternative technique for treating odontoid fractures has been developed that attempts to preserve the normal motion of the C1-2 joint. This technique is the anterior odontoid screw fixation.

Several authors have described surgical techniques for anterior odontoid screw fixation [13, 15, 28, 32, 44]. Nakanishi first described the technique in 1980 in the Japanese literature [52]. In 1982, Bohler independently reported on the development of the technique in Vienna [13]. Although the initial techniques of anterior screw fixation were complex, the procedure has gained increased acceptance as improved instrumentation has allowed a minimally invasive approach [61] and improvements in fluoroscopic guidance have been made [1, 8]. Direct anterior screw fixation is an osteosynthetic technique that provides immediate spinal stabilization.

### 8.4 Advantages

Anterior odontoid fixation has several advantages over posterior C1-2 fusion. The dissection is less invasive and takes advantage of natural tissue planes. It poses less risk of damage to the neural structures and the anatomy of the vertebral artery is such that it is not at risk. As stated previously, this procedure does not re-

quire atlantoaxial arthrodesis; therefore, cervical mobility, especially rotation, is maintained. Reported perioperative morbidity appears to be less with the anterior fixation technique than with the posterior fusion. The technique may also be used in patients who have a concomitant C1 ring fracture but an intact transverse ligament. It is also applicable in those patients, especially elderly patients, who refuse or are unable to tolerate a halo.

## 8.5 Disadvantages

Anterior odontoid screw fixation has two main disadvantages. If the transverse portion of the cruciate ligament is disrupted in addition to the odontoid fracture, stabilizing the fracture will not result in atlantoaxial stability. As discussed in the "Surgical Principle" section, atlantoaxial stability is dependent on an intact dens *and* transverse ligament. Disruption of the transverse ligament is most often caused by a C1 ring fracture (Jefferson fracture).

Patients with chronic fractures (greater than 6 months old) or with os odontoideum should not usually be treated with an odontoid screw. Long-term stability of the odontoid is dependent on the ingrowth of new bone across the fracture line. The purpose of any hardware is to achieve immediate stabilization so that such fusion may occur, but the hardware is not expected to provide the long-term stability by itself. Because the mating surfaces of the odontoid fragment and body of C2 are usually corticated and widely separated in patients with chronic fractures or os odontoideum, fusion is less likely to occur.

## 8.6 Indications

The initial evaluation of odontoid fractures should begin with careful clinical evaluation and examination of cervical spine plain radiographs. Any evidence suggesting an odontoid fracture should prompt the clinician to perform serial thin-slice CT scanning from the skull base through to the top of C3. Reconstructed CT images allow the surgeon to identify the injury and assess the fracture type, the orientation, and the degree of dens displacement. As discussed previously, concerns about the integrity of the transverse ligament can be addressed by MRI studies. In patients with combined C1 and C2 fractures involving the ring of C1 (Jefferson fracture), a combined left and right overhang of the C1 lateral masses on C2 of greater than 7 mm on an open-mouth view (Rule of Spence) suggests disruption of the transverse ligament [59]. On a lateral cervical spine X-

ray, the atlanto-dental interval (ADI) is the distance between the anterior margin of the dens and the closest point of the anterior arch of C1. Fielding et al. [29] demonstrated that an ADI of 4 mm or more suggests a disrupted transverse ligament. Finally, separation of the tubercle on the interior surface of the ring of C1, where the transverse ligament attaches, is also usually indicative of transverse ligament incompetence.

Non-operative management will be mentioned briefly because it directly pertains to the selection of patients who require surgery. Multiple studies have reported rates of successful fusion using a halo vest immobilization with the success rates ranging from 7% to 100% [4, 6, 10, 12, 17–19, 24–26, 30, 34, 35, 38, 43, 45, 46, 54, 55, 57, 58, 62]. When these rates were combined in a review article, the overall fusion rate with halo immobilization was about 65% [42]. Attempts to define factors that predispose to a non-union with external immobilization have suggested the following contradictory indications: (1) anterior fracture displacement greater than 4 mm [10]; (2) displacement in any direction of greater than 5 mm [18] or 6 mm [34]; (3) fracture angulation greater than 10° [18]; (4) fracture comminution (type IIa) [35]; (5) patient age greater than 40 years [10], greater than 50 years [43], or greater than 65 years [6, 25]; and (6) posterior fracture displacement [25, 34]. The variation in these studies may be due to the fact that plain films are used for many of the criteria. A plain film is a "snapshot in time" and does not indicate the full extent of displacement possible or whether additional angulation or displacement in a different direction will occur. Thus, one patient with 3 mm of anterolisthesis may not move further and would likely heal with immobilization, whereas another patient with the same 3 mm of anterolisthesis on a plain film might be capable of 10 mm of antero- *and* retrolisthesis. Such a patient has a low likelihood of healing with immobilization. Because of the uncertain rate of fusion with halo immobilization alone, as well as the burden of halo fixation and significant loss of cervical motion seen with posterior fusion techniques, we believe that all recent (less than 6-month-old) type II or shallow type III odontoid fractures with an intact transverse ligament should be offered treatment with direct anterior screw fixation.

## 8.7 Contraindications

Contraindications to anterior odontoid screw fixation include patients with concomitant C2 body fractures, a disrupted transverse ligament, or chronic non-unions. Relative contraindications are anterior oblique fracture orientation and severe osteopenia. Advanced age has not proved to be a contraindication.

## 8.8

### Patient's Informed Consent

All patients should be counseled regarding the usual potential complications associated with any invasive spinal procedure, such as bleeding, infection, malpositioned hardware, and failure to achieve fusion. Neurologic injury is very rare because even if the screw extends past the apical cortex of the dens, the screw trajectory and regional anatomy is such that vital neural structures are still some distance away. Patients should also be informed that failure to achieve adequate reduction of their fracture or premature failure of their hardware could result in the need for a posterior C1-2 fusion. Dysphagia, usually temporary, is a frequent occurrence. Persistent dysphagia requiring placement of a feeding tube is a fairly infrequent complication but is more commonly encountered in the elderly [21]. We generally do not put patients in external orthosis postoperatively. However, in situations where a suboptimal reduction and fixation was achieved or when the patient has poor bone quality, external orthosis, usually in the form of a rigid cervical collar, may be needed.

## 8.9

### Surgical Technique

Our technique for direct anterior screw fixation of odontoid fractures has been described and illustrated in several publications [7, 8]. It is a straightforward procedure that uses the familiar standard anterior approach to the midcervical spine. The procedure, which we will describe in detail below, can be summarized as follows. After accessing the midcervical spine, a working tunnel is created superiorly, anterior to the longus colli muscles, to the C1-2 region and secured with a special retractor. A pilot hole is drilled and tapped through specially designed concentric guide tubes, and then a screw is placed, all under biplanar fluoroscopic control. The outer guide tube is unique in that it has small spikes that anchor it to C3. This allows translation of C3 and the body of C2 either anteriorly or posteriorly relative to the odontoid process and C1 to realign them in the proper anatomic relationship. Thus, optional alignment can be obtained and a retrolisthesed odontoid is not a contraindication to the procedure.

The treatment goals for odontoid fractures are to restore normal alignment, achieve bony fusion, and prevent future neurologic compromise. The first step in the acute management of these fractures is to stabilize the neck to prevent additional subluxation and restore normal alignment. This generally can be accomplished preoperatively with Gardner-Wells traction using a light weight, initially 5 pounds or less, or intraoperatively when positioning the patient.

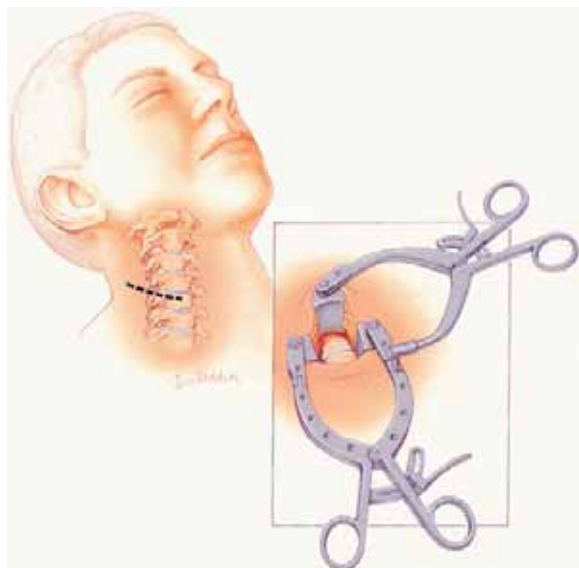
Preoperative positioning of the patient and the C-arm fluoroscopes is the key to success with this procedure. The patient is placed supine on a standard operating table. To achieve a satisfactory trajectory to the odontoid, the patient's neck must usually be extended. However, this can be dangerous if the patient has a retrolisthesed odontoid. As mentioned above, the guide tube system can be used to correct misalignment and this will allow extension of the neck prior to drilling and screw placement. To allow for such extension, a folded sheet or blanket, about 2–4 inches thick, is placed on the table to support the patient's shoulders. The head is initially supported on padding to keep the neck in a neutral position until the lateral fluoroscope is in place.

General endotracheal anesthesia is then induced. If the patient reduces in extension, intubation with a laryngoscope is safe and usually employed. Alternatively, fiberoptic techniques can be used, and are usually preferable, if the fracture is retrolisthesed or if extension results in such retrolisthesis.

Holter traction with 5 pounds of weight is placed, and, under fluoroscopic monitoring, the patient's head is gently allowed to extend and the padding under the head removed if doing so does not result in additional retrolisthesis of the odontoid. If such motion does occur, the padding under the head is left in place until after the guide tube is placed later in the procedure. For the AP fluoroscopic view (transoral), a second fluoroscope is placed. We rotate the lateral fluoroscope C-arm arc to a position that places it about 30° above the horizontal. This allows the anesthesiologist good access to the patient and allows the AP fluoroscope, if the two fluoroscopes have the same size arc, to be positioned at about a 45° diagonal to the head with the generator and image intensifier above and below the patient, respectively. The use of two C-arms allows the surgeon to check lateral and AP views by merely selecting the proper foot pedal. The patient's mouth is held open with a radiolucent mouth gag. A wine bottle cork, notched for the teeth or alveolar ridges, is excellent for this. Although less preferable, if only a single fluoroscope is available, it can be positioned to allow frequent swinging from the lateral to AP position and back. Making a tunnel by strategically placing IV poles and drapes helps, as then only one side of the C-arm needs to be redraped with each change of orientation. Using one C-arm can give satisfactory results although it is more demanding of time and patience.

The patient's neck is prepared and draped, and a unilateral horizontal incision is made at approximately C5 (Fig. 8.3). The platysma is then elevated and divided, and the fascia of the sternocleidomastoid is sharply incised along its medial border. Blunt dissection is used to expose the anterior surface of the vertebral column at the midcervical level by opening the natural tissue





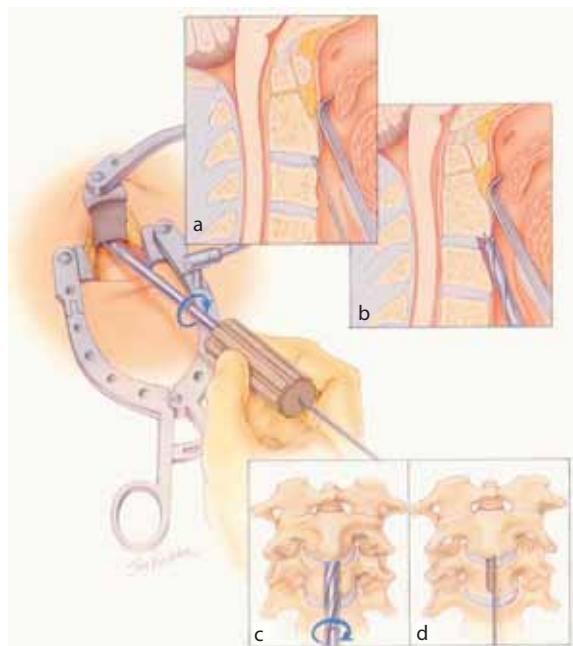
**Fig. 8.3.** Illustration showing location of neck incision. Inset Illustration of retractor in place

planes medial to the carotid artery sheath and lateral to the trachea and esophagus. The fascia of the musculus longus colli is then incised in the midline, and the muscle is elevated cleanly from the vertebral bodies at the C5-6 level.

Sharp, large-toothed Caspar retractor blades are then inserted beneath the musculus longus colli bellies bilaterally and secured with a special lateral self-retaining retractor. This forms a stable base, anchoring the retractor and countering the rostral retraction forces from the cranial retractor that will attach to this base. Blunt dissection in the retropharyngeal space anterior to the longus colli muscle using a Kitner or peanut dissector is then used to open a path in front of the vertebral bodies to the C1-2 level. An angled retractor of the appropriate size is then inserted into this space and coupled to the lateral retractors to create a working tunnel up to C2 (Fig. 8.3). The trajectory needed to access the anterior inferior edge of C2 and continuing upward to the odontoid apex is a very shallow one. This retractor system has been designed to help achieve this trajectory by eliminating any inferior components.

A K-wire is then inserted through the incision, up to the inferior edge of C2 and impacted a few millimeters into the body of C2. If a single screw is to be placed, a midline entry site is chosen (Fig. 8.4). A paramedian position, approximately 2–3 mm off midline, is used if two screws are to be placed.

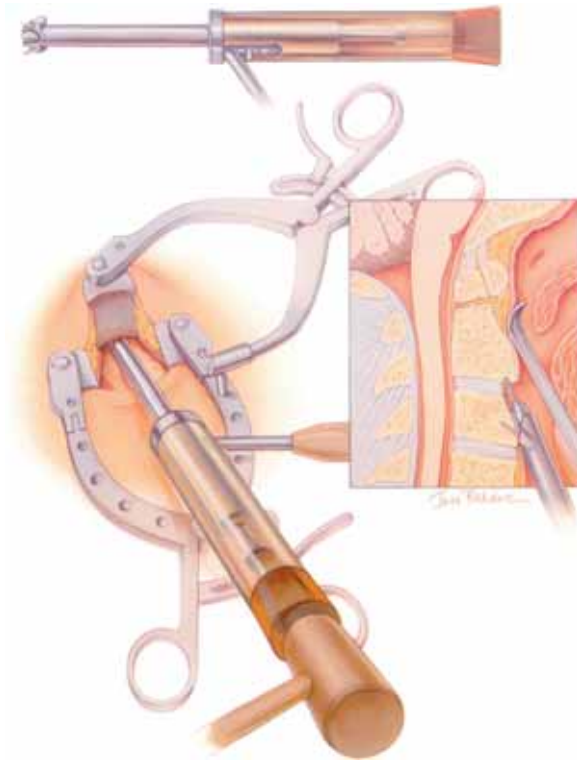
A hollow 8-mm drill is placed over the K-wire and rotated by hand to create a shallow groove in the face of C3 and the C2-3 disc and annulus to the inferior border of C2 without removing any of C2 (Fig. 8.4). This groove will accommodate the drill guide to allow for in-



**Fig. 8.4.** A hollow hand drill is placed over the K-wire to create a trough in the face of C3 and the C2-3 disc. The position of the K-wire with respect to the superior retractor blade is shown in inset **a**, and then with the drill placed over the wire (inset **b**). Inset **c** depicts the creation of the trough, which is seen in inset **d**

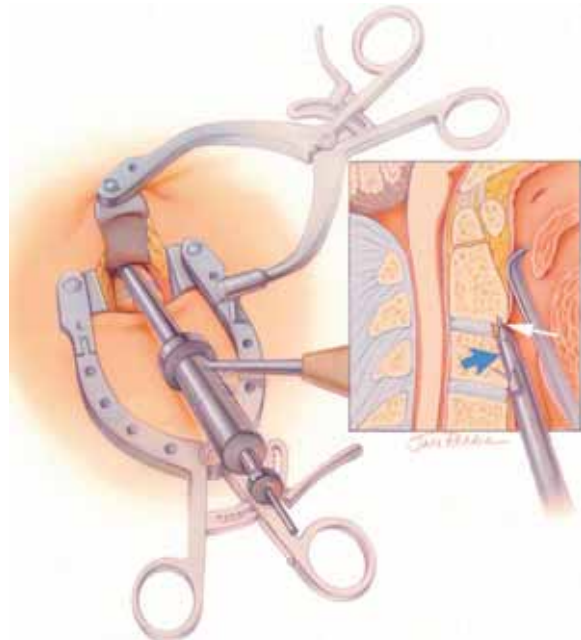
section of the tools and screw at the anterior inferior edge of C2. The drill guide system consisting of outer and inner guide tubes that mate together (Fig. 8.5) is then placed over the K-wire. The outer drill guide has forward-projecting spikes. By locking the handle of the guide tube, these spikes are walked up the face of the vertebral column with small rotating movements of the guide tube until they are over C3. A plastic impactor cover is placed over the drill guide system after shortening the K-wire as necessary, and the spikes of the outer drill guide tube are firmly set into C3 under fluoroscopic guidance by tapping on the impactor with a mallet (Fig. 8.6). The inner drill guide is then extended in the previously created groove to contact the inferior edge of C2 (Fig. 8.7). As has been emphasized, the alignment of the C2 and C3 vertebrae, relative to the odontoid and C1, is controlled by the drill guide, which is kept firmly fixed to C3 by maintaining forward pressure on its handle (unlock handle and place it in the most comfortable position). Alignment can now be optimized in either direction by lifting or depressing C3 and the body of C2 relative to the odontoid. In the case of a retrolisthesed odontoid, further extension of the neck is achieved by removing the padding under the head after translating C2 and C3 posteriorly, realigning the odontoid to the body of C2. Using fluoroscopy, correction of the alignment can be perfected and maintained in this manner.

**Fig. 8.5.** Drill guide system. Inner and outer guide tubes mate together and are placed over the K-wire



**Fig. 8.6.** After the drill guide system is walked up the front of the vertebral column to the C3 level, the K-wire is shortened and the plastic impactor sleeve is used to set the spikes of the outer drill guide into C3

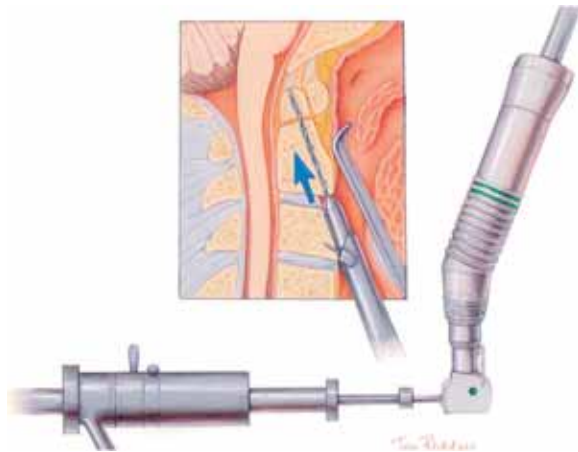
Once the guide tubes are secured and alignment is achieved, the K-wire is removed and replaced with a drill bit, which engages the starter hole made by the K-wire (Fig. 8.8). A right-angle drive is available to clear the thoracic region if needed. A hole is drilled under careful biplanar fluoroscopic control from the inferior anterior edge of C2, through the body of C2, and into the odontoid to its apex. It is important to drill fully through the odontoid tip. Because the trajectory to do this is very tangential to the spinal canal, the thecal sac is not in jeopardy. It is usually possible to extend more than a centimeter from the odontoid tip before encountering the dura in most patients, so penetrating the apex of the odontoid by a few millimeters is not risky. The drill is calibrated to allow accurate depth measurement from the end of the inner drill guide. After noting this measurement and saving the fluoroscopic picture on the adjacent storage screen of the fluoroscope, the



**Fig. 8.7.** The drill guide system is in place with the inner guide tube (blue arrow) advanced to the inferior end of C2 (white arrow) in the previously created groove

pilot hole is then tapped (threaded) by removing the drill and the inner drill guide and replacing them with the tap, which is manipulated by hand while its progress is monitored fluoroscopically. It too has a depth calibration to verify the proper screw length (Fig. 8.9).

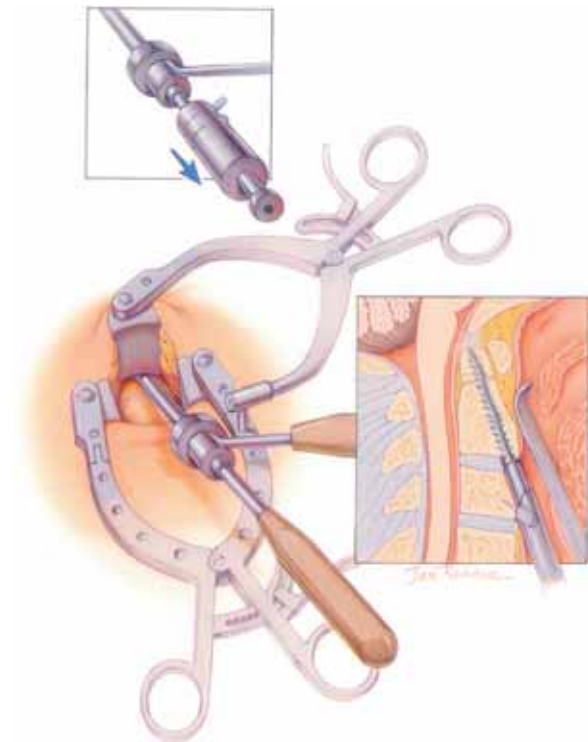
The screw is selected based on the measured depth. If the inner drill guide does not touch the bottom of C2 and/or a gap is present between the odontoid and body of C2, the measured screw length should be reduced by a few millimeters. The screw is placed through the outer guide tube and into the C2 body through the drilled and tapped hole (Fig. 8.10a). Lag screws are used with a non-threaded proximal shaft to allow the distal fragment to be pulled down to the body of C2 (Fig. 8.10b). As the screw is being placed, its progress is monitored fluoroscopically. It is very easy to match the alignment precisely when tapping and placing the screws by comparing the live fluoroscopic image with the image of the drilling saved on the fluoroscope. The head of the screw should be recessed into the C2-3 annulus/disc edge or slightly into the inferior edge of C2, and the screw tip should be fully engaged into the apex of the odontoid when it is tight (Fig. 8.10b). Traction can be removed as



**Fig. 8.8.** The K-wire is removed and replaced with the drill, which is guided fluoroscopically to the apex of the odontoid after reducing the odontoid dislocation. Calibration marks on the shaft indicate the depth of penetration beyond the inner drill guide

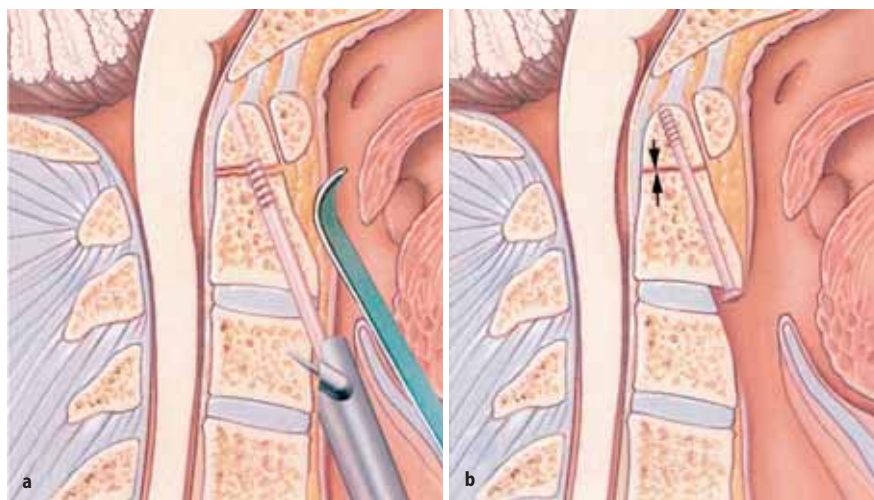
the screw is fully tightened. Extension by several millimeters beyond the tip is safe, as this will result in the screw tip being within the apical ligaments. The angle of placement is such that the neural elements are not jeopardized. Screws that fail to engage the apical cortex fully have backed out in some cases, so this should be avoided.

The issue of whether to place one or two odontoid screws is controversial. Some patients do not have an odontoid process large enough to accommodate two screws [56]. Two-screw constructs have been advocated to prevent rotation of the dens around a single screw. We generally advocate placement of two screws if an odontoid fracture will accept two screws. However, clinical success appears to be similar with the one- and two-screw constructs [9, 41, 48].



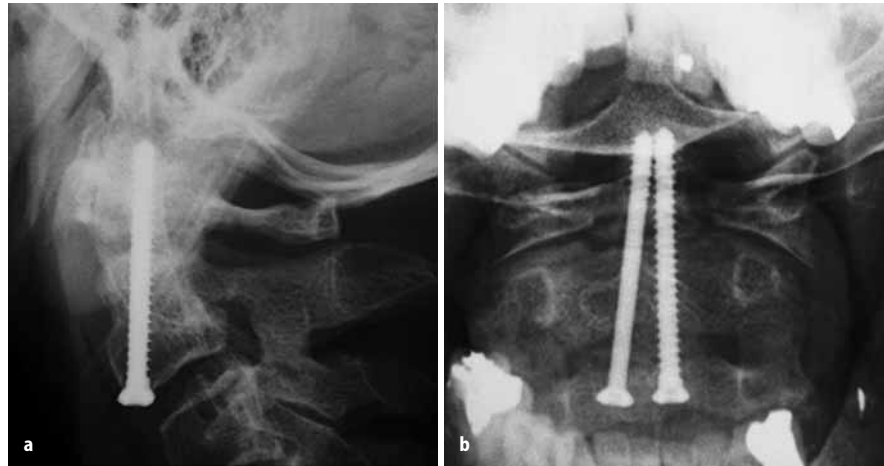
**Fig. 8.9.** Inner guide is removed (*inset*) and the tap is used to cut threads into pilot hole to the apex of the odontoid

Placement of a second screw, if desired, is accomplished in a similar manner using an entry site a few millimeters from the first screw. The K-wire is used for initial guidance, and an 8-mm drill is used to cut a groove in the anterior surface of C3 and the C2-3 disc. As in cases in which a single screw is used, the surgeon places the drill guide, drills the hole, taps the hole, and places the screw. The second screw can be either a lag screw or a fully threaded one (Fig. 8.11).

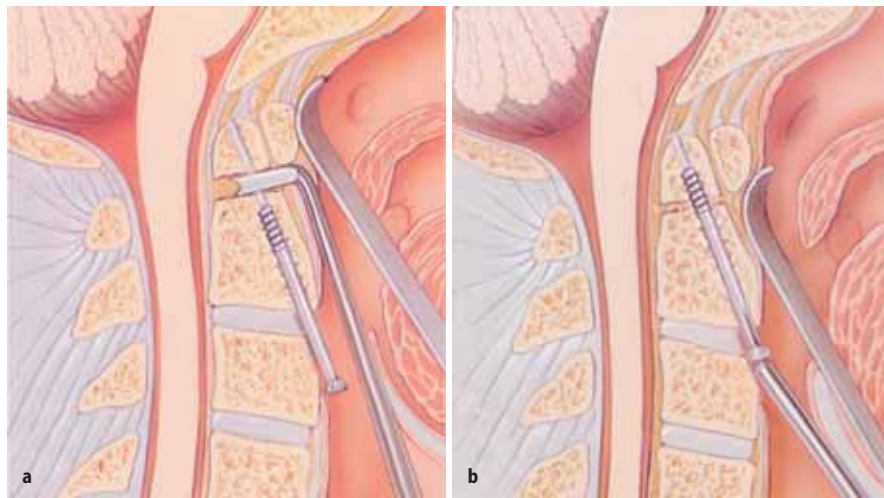


**Fig. 8.10.** The screw is inserted through the guide tube system and advanced through the threaded pilot hole (a). The final position of the screw should be just past the apical cortex of the odontoid (b). By using a lag screw (partially threaded with smaller proximal shaft), the odontoid fragment may be reapproximated to the body of C2 (arrows)





**Fig. 8.11.** Plain lateral (a) and anteroposterior (b) radiographs showing good placement of two odontoid screws, one a fully threaded and the other a lag screw



**Fig. 8.12.** For chronic fractures, the first screw is placed just below the fracture line initially and then the guide tube is removed. Special bifaced curettes are used to freshen the fractures site (a). The screw is then advanced to its final position using the ball driver (b)

If attempting screw placement in a chronically non-united fracture, the screw can be inserted into the body of C2 until just below the fracture site. The drill guide is then removed and special bisurfaced, angled curettes are used to freshen the fracture site and remove fibrous tissue (Fig. 8.12a). This is performed by forcing the tip of the smaller curette through the weak anterior longitudinal ligament at the fracture site (as monitored fluoroscopically) and rotating the handle. It is then replaced with the second small curette angled in the opposite direction, which is manipulated similarly. Two larger curettes are then sequentially introduced and manipulated in the same manner. The screw head is then reengaged by the ball driver (Fig. 8.12b), which can be inserted at an angle of  $\pm 15^\circ$  to the long axis of the screw and fully tightened. Because success with chronic non-union has been low, we do not recommend this except in special circumstances.

After screw placement, flexion-extension of the patient's neck under fluoroscopy is used to confirm spinal stability. The retractors are removed and the wound is

checked for hemostasis. Most bone bleeding from the drilling is stopped when the screw is placed, but occasionally bone wax is needed. Bipolar cautery can be helpful in controlling bleeding from the longus colli muscle edges. Closure is then completed in layers. We use interrupted absorbable sutures in the sternocleidomastoid muscle fascia, platysma muscles, and subcutaneous tissues and use sterile adhesive strips on the skin.

## 8.10

### Postoperative Care and Complications

Odontoid screw fixation is a well-tolerated procedure, even in the elderly population that makes up a large proportion of our patients. We routinely keep patients in the ICU for the first night, primarily to monitor their airway closely. On postoperative day one, plain X-rays are performed. Dysphagia is not an uncommon complication, especially in the elderly. It is often transient,



but in some cases, temporary feeding tubes must be placed to provide nutrition. Patients usually are not required to wear cervical collars unless we are concerned about their bone density or they have an anterior oblique fracture. Patients frequently can be discharged from the hospital within 24–48 hours after their surgery. Patients typically return for a clinic visit and imaging studies at 1, 3, 6, and 12 months postoperatively, or sooner if necessary. Late complications will be discussed in the next section.

## 8.11 Results

We recently reviewed a two-center experience with direct anterior screw fixation for recent (fractures less than 6 months old) and remote (fractures greater than 18 months old) type II and shallow type III fractures [9]. Patients that underwent direct anterior screw fixation for recent type II and shallow type III fractures had successful stabilization in 91 % of the cases (88 % bony union) compared with 69 % (25 % bony union) in the remote group (Table 8.1). The only factor associated with statistically significantly higher rates of non-union, fibrous union, or non-anatomic union in recent fractures was an anterior oblique fracture orientation. Other factors such as age, sex, number of screws (one versus two), and direction and degree of fracture displacement did not have a significant effect on fusion in this patient population (Table 8.2). Although we would not have anticipated it, patients who underwent a trial of immobilization and failed did as well with surgery performed 3–6 months after their injury as did those

operated on closer to their date of injury. The cases of non-anatomic union in our series occurred when the guide tube system was not used. In most cases, the fused position was within 1–3 mm of normal alignment. These were without neurologic sequelae and the patients did not require further treatment.

Despite having a lower rate of anatomic bony union, anterior oblique-oriented fractures still had a bone stabilization rate of 75 % (50 % anatomic bone union and 25 % non-anatomic union), which compares favorably with results obtained using most external immobilization modalities. We therefore continue to employ anterior screw fixation in this patient subpopulation. To avoid non-anatomic union with this fracture orientation type, we consider placing these patients in a hard cervical collar postoperatively until evidence of fibrous or bony union occurs. In addition, fixation of the anterior oblique fractures in a 1- to 2-mm posteriorly displaced position may compensate for anterior movement of the odontoid during the healing process and reduce non-anatomic outcome.

Attempts to apply odontoid screw fixation in 18 patients with chronically non-united odontoid fractures (more than 18 months after the injury) did not result in satisfactory outcomes. These patients had a significantly higher rate of failure to achieve bony union (75 %) and more complications (Table 8.2). The complications in this remote fracture group were primarily hardware related as no hardware can be expected to succeed if bony fusion is not achieved. The most common hardware complications were screw fracture (19 %) and screw pull-out of the odontoid (6 %). We therefore recommend treating these lesions with posterior C1-2 fixation and fusion. A select subgroup of patients who have relatively large odontoid processes, which are not ankylosed to either the arch of C1 or the clivus, and who have a small gap (less than 2 mm) between the odontoid and the body of C2 may remain potential candidates for direct screw fixation if they wish to try to retain C1-2 mobility. They are cautioned that successful fusion is achieved less often and that, if a fusion is not achieved, they will subsequently require posterior stabilization. Because we did not have any patient present with an odontoid fracture between 6 and 18 months after their injury, we are not able to draw any conclusions about the expected fusion rates for patients operated on during this period.

The complication rate for this method of fixation in recent fractures is similar to that seen with posterior fixation techniques (Table 8.2). The most common complications were hardware related and included screw cut-out anteriorly through the body of C2 (4 %), screw back-out (3 %), and C2 subluxation (1 %). Screw cut-out usually occurred in patients with concomitant C2 body fractures, which were recognized but were thought to be located laterally and thus unlikely to af-

**Table 8.1.** Postoperative fusion status in patients with recent and remote fractures [9]

Fusion status	Number of patients (%)	
	Recent group ( $< 6$ months)	Remote group ( $> 18$ months)
Anatomic bony union	99 (85)	4 (25)
Non-anatomic bony union	4 (3)	0 (0)
Fibrous union	4 (3)	7 (44)
Non-union	10 (9)	5 (31)
Total	117 (100)	16 (100)

**Table 8.2.** Complications after direct anterior screw fixation in recent and remote groups [9]

Complication	Number of complications (%)		
	Both groups ( $n = 133$ )	Recent group ( $n = 117$ )	Remote group ( $n = 16$ )
Hardware	14 (11)	10 (9)	4 (25)
Medical morbidity	3 (3)	2 (2)	1 (6)
Mortality	1 (1)	1 (1)	0 (0)
Total	18 (14)	13 (12)	5 (31)

fect odontoid screw performance. Often, however, the scans underestimate the extent of such fracturing so we now believe that concomitant fractures in the C2 body should be seriously considered as a possible contraindication to anterior odontoid screw fixation. Patients with hardware failure were subsequently fused successfully by screw revision, halo orthosis, or posterior C1-2 fusion. Medical complications were rare and included only two (2%) cases of superficial wound infection that were treated successfully with oral antibiotics. There was one (1%) death in this series. A patient became quadriplegic and had a respiratory arrest after the distal fragment (odontoid) became dislocated subsequent to screw back-out 3 weeks after surgery.

## 8.12

### Critical Evaluations

Numerous recent case series in the literature have evaluated anterior screw fixation of odontoid fractures with healing rates generally ranging from 80% to 100% [2, 3, 6, 11, 14, 27, 37, 41, 50, 61]. Morandi et al. treated 17 cases in which adequate reduction and fixation was obtained in all cases except one [50]. They placed a single screw in all of their patients. The average surgical time was only 40 minutes, and much of the actual intraoperative time was spent positioning the patient and the fluoroscopes. ElSaghir and Böhm [27] used two screws in 30 patients with type II odontoid fractures. Reduction and stabilization was achieved in all patients. The authors did remove the screws in 8 patients to avoid mechanical insult to the C2-3 disc by the head of the screw. Within this group of 8 patients, 1 patient did develop circumferential fusion at C2-3 even after the screws were removed. Subach et al. [61] treated 26 patients with a single screw. Unlike most other surgeons, they placed all of their patients in external orthoses postoperatively. Fusion, as defined by the presence of bridging bone, was present in 25 of 26 patients. The authors had 1 patient with a suboptimal screw placement who was placed in a halo with subsequent fusion and another patient that required a posterior fusion because of an inability to reduce the fracture adequately.

Jenkins et al. [41] provided clinical evidence that one- and two-screw fixations were equivalent in terms of union rates. They had 20 patients treated with a single screw and 22 treated with two. The union rate, as defined as the absence of dens movement independent of the C2 vertebral body with or without evidence of trabecular bone spanning the previous fracture line, in the single and double screw groups was 81% and 85%, respectively.

Some authors have investigated whether age is a factor in determining outcome following anterior screw

fixation. Harrop et al. found stable union in 8 patients and concluded that odontoid screw fixation can be performed safely in patients [36]. Börm et al. [14] found similar fusion rates for patients aged 70 years or older (group 1) compared with patients less than 70 (group 2). However, medical complications not related to surgical technique occurred more frequently in the group 1 patients (20% vs 8%). Conversely, Andersson et al. [6] found an unacceptably high rate of problems in their 11 patients aged 65 or older and recommended posterior C1-2 fusion as the treatment of choice for the elderly. An analysis of 40 patients over the age of 70 treated in our institution over a 10-year interval showed fusion rates equal to the overall series (88%), but the elderly patients did have a higher incidence of dysphagia, which often was more protracted [21].

In conclusion, odontoid fractures are common cervical spine injuries. They render the spine unstable and put the patient at significant risk for potentially catastrophic spinal cord injury. Rapid and precise diagnosis is essential and leads to one of several options to stabilize the spine. Though some odontoid fractures, notably type I and III fractures, can be treated with external immobilization, growing evidence suggests that treatment of recent type II and shallow type III fractures by direct anterior screw fixation may be preferable. This easily learned and relatively straightforward minimally invasive method of treatment has a high rate of fusion and confers immediate stability, usually obviating the need for external halo vest immobilization. It provides an optimal milieu for bone fusion by eliminating motion at the fracture site and by keeping the odontoid tightly opposed to the body of C2 in its normal anatomic position. If successful, it preserves normal C1-2 motion, which accounts for one-half of the rotatory excursion of the head.

## References

1. Aebi M, Etter C, Coscia M (1989) Fractures of the odontoid process. Treatment with anterior screw fixation. *Spine* 14:1065–1070
2. Agrillo U, Mastronardi L, Puzzilli F (2000) Management of acute odontoid fractures with single-screw anterior fixation. *Neurosurgery* 47:794
3. Alfieri A (2001) Single-screw fixation for acute type II odontoid fracture. *J Neurosurg Sci* 45:15–18
4. Althoff B (1979) Fracture of the odontoid process. An experimental and clinical study. *Acta Orthop Scand Suppl* 177:1–95
5. Anderson LD, D'Alonzo RT (1974) Fractures of the odontoid process of the axis. *J Bone Joint Surg Am* 56:1663–1674
6. Andersson S, Rodrigues M, Olerud C (2000) Odontoid fractures: High complication rate associated with anterior screw fixation in the elderly. *Eur Spine J* 9:56–59; discussion 60
7. Apfelbaum RI (1992) Anterior screw fixation for odontoid fractures. In: Camins MB, O'Leary PF (eds) *Disorders of the*

- cervical spine, 2nd edn. Williams and Wilkins, Baltimore, pp 603–608
8. Apfelbaum RI (1992) Anterior screw fixation of odontoid fractures. In: Rengachary SS, Wilkins RH (eds) *Neurosurgical operative atlas*, 2nd edn, vol 2. Williams and Wilkins, Baltimore, pp 189–199
  9. Apfelbaum RI, Lonser RR, Veres R, Casey A (2000) Direct anterior screw fixation for recent and remote odontoid fractures. *J Neurosurg* 93:227–236
  10. Apuzzo ML, Heiden JS, Weiss MH, Ackerson TT, Harvey JP, Kurze T (1978) Acute fractures of the odontoid process. An analysis of 45 cases. *J Neurosurg* 48:85–91
  11. Berlemann U, Schwarzenbach O (1997) Dens fractures in the elderly. Results of anterior screw fixation in 19 elderly patients. *Acta Orthop Scand* 68:319–324
  12. Blockley N, Purser D (1956) Fractures of the odontoid process of the axis. *J Bone Joint Surg Br* 38:794–817
  13. Bohler J (1982) Anterior stabilization for acute fractures and non-unions of the dens. *J Bone Joint Surg Am* 64:18–27
  14. Börm W, Kast E, Richter HP, Mohr K (2003) Anterior screw fixation in type II odontoid fractures: is there a difference in outcome between age groups? *Neurosurgery* 52:1089–1092; discussion 1092–1094
  15. Borne GM, Bedou GL, Pinaudeau M, Cristino G, Hussein A (1988) Odontoid process fracture osteosynthesis with a direct screw fixation technique in nine consecutive cases. *J Neurosurg* 68:223–226
  16. Brooks AL, Jenkins EB (1978) Atlanto-axial arthrodesis by the wedge compression method. *J Bone Joint Surg Am* 60:279–284
  17. Chan R, Schweigel J, Thompson G (1983) Halo-thoracic brace immobilization in 188 patients with acute cervical spine injuries. *J Neurosurg* 58:508–515
  18. Clark CR, White AA 3rd (1985) Fractures of the dens. A multicenter study. *J Bone Joint Surg Am* 67:1340–1348
  19. Cooper P, Maravilla K, Sklar F, Moody S, Clark W (1979) Halo immobilization of cervical spine fractures. *J Neurosurg* 50:603–610
  20. Crockard HA, Heilman AE, Stevens JM (1993) Progressive myelopathy secondary to odontoid fractures: clinical, radiological, and surgical features. *J Neurosurg* 78:579–586
  21. Dailey AT, Hart DJ, Apfelbaum RI (2003) Anterior fixation of odontoid fractures in the elderly. Presented at the Richard Lende Winter Neurosurgery Conference, Snowbird, Utah, 31 January–6 February 2003
  22. Dickman CA, Sonntag VK (1998) Posterior C1–C2 transarticular screw fixation for atlantoaxial arthrodesis. *Neurosurgery* 43:275–280; discussion 280–281
  23. Dickman CA, Sonntag VK, Papadopoulos SM, Hadley MN (1991) The interspinous method of posterior atlantoaxial arthrodesis. *J Neurosurg* 74:190–198
  24. Dickson H, Engel S, Blum P, Jones RF (1984) Odontoid fractures, systemic disease and conservative care. *Aust N Z J Surg* 54:243–247
  25. Dunn M, Seljeskog E (1986) Experience in the management of odontoid process injuries: an analysis of 128 cases. *Neurosurgery* 18:306–310
  26. Ekong CE, Schwartz ML, Tator CH, Rowed DW, Edmonds VE (1981) Odontoid fracture: management with early mobilization using the halo device. *Neurosurgery* 9:631–637
  27. ElSaghir H, Böhm H (2000) Anderson type II fracture of the odontoid process: results of anterior screw fixation. *J Spinal Disord* 13:527–530; discussion 531
  28. Esses SI, Bednar DA (1991) Screw fixation of odontoid fractures and nonunions. *Spine* 16:S483–S485
  29. Fielding J, Cochran G, Lawsing J, Mabie KN (1974) Tears of the transverse ligament of the atlas: a clinical and biomechanical study. *J Bone Joint Surg Am* 56:1683–1691
  30. Fujii E, Kobayashi K, Hirabayashi K (1988) Treatment in fractures of the odontoid process. *Spine* 13:604–609
  31. Gallie W (1939) Fractures and dislocation of the cervical spine. *Am J Surg* 46:495–499
  32. Geisler FH, Cheng C, Poka A, Brumback RJ (1989) Anterior screw fixation of posteriorly displaced type II odontoid fractures. *Neurosurgery* 25:30–37; discussion 37–38
  33. Grob D, Jeanneret B, Aebi M, Markwalder TM (1991) Atlanto-axial fusion with transarticular screw fixation. *J Bone Joint Surg Br* 73:972–976
  34. Hadley MN, Browner C, Sonntag VK (1985) Axis fractures: a comprehensive review of management and treatment in 107 cases. *Neurosurgery* 17:281–290
  35. Hadley MN, Browner CM, Liu SS, Sonntag VK (1988) New subtype of acute odontoid fractures (type IIa). *Neurosurgery* 22:67–71
  36. Harrop JS, Przybylski GJ, Vaccaro AR, Yalamanchili K (2000) Efficacy of anterior odontoid screw fixation in elderly patients with type II odontoid fractures. *Neurosurg Focus* 8: Article 7
  37. Henry AD, Bohly J, Grosse A (1999) Fixation of odontoid fractures by an anterior screw. *J Bone Joint Surg Br* 81: 472–477
  38. Hentzer L, Schalimtzek M (1971) Fractures and subluxations of the atlas and axis. A follow-up study of 20 patients. *Acta Orthop Scand* 42:251–258
  39. Husby J, Sorensen KH (1974) Fracture of the odontoid process of the axis. *Acta Orthop Scand* 45:182–192
  40. Jeanneret B, Magerl F (1992) Primary posterior fusion C1/2 in odontoid fractures: indications, technique, and results of transarticular screw fixation. *J Spinal Disord* 5:464–475
  41. Jenkins JD, Coric D, Branch CL Jr (1998) A clinical comparison of one- and two-screw odontoid fixation. *J Neurosurg* 89:366–370
  42. Julien TD, Frankel B, Traynelis VC, Ryken TC (2000) Evidence-based analysis odontoid fracture management. *Neurosurg Focus* 8 (article 1):1–6
  43. Lennarson PJ, Mostafavi H, Traynelis VC, Walters BC (2000) Management of type II dens fractures: a case-control study. *Spine* 25:1234–1237
  44. Lesoin F, Autricque A, Franz K, Villette L, Jomin M (1987) Transcervical approach and screw fixation for upper cervical spine pathology. *Surg Neurol* 27:459–465
  45. Lind B, Nordwall A, Sihlbom H (1987) Odontoid fractures treated with halo-vest. *Spine* 12:173–177
  46. Maiman DJ, Larson SJ (1982) Management of odontoid fractures. *Neurosurgery* 11:471–476
  47. Marcotte P, Dickman CA, Sonntag VK, Karahalios DG, Drabier J (1993) Posterior atlantoaxial facet screw fixation. *J Neurosurg* 79:234–237
  48. McBride AD, Mukherjee DP, Kruse RN, Albright JA (1995) Anterior screw fixation of type II odontoid fractures. A biomechanical study. *Spine* 20:1855–1859; discussion 1859–1860
  49. McGraw R, Rusch R (1973) Atlanto-axial arthrodesis. *J Bone Joint Surg Br* 55:482–489
  50. Morandi X, Hanna A, Hamlat A, Brassier G (1999) Anterior screw fixation of odontoid fractures. *Surg Neurol* 51: 236–240
  51. Mouradian W, Fietti V, Cochran G (1978) Fractures of the odontoid: a laboratory and clinical study of mechanisms. *Orthop Clin North Am* 9:985–1001
  52. Nakanishi T (1980) Internal fixation of the odontoid fracture. *Cent Jpn J Orthop Traumatic Surg* 23:399–406
  53. Paradis GR, Janes JM (1973) Posttraumatic atlantoaxial instability: the fate of the odontoid process fracture in 46 cases. *J Trauma* 13:359–367
  54. Pepin JW, Bourne RB, Hawkins RJ (1985) Odontoid frac-

- tures, with special reference to the elderly patient. *Clin Orthop*:178–183
55. Ryan M, Taylor T (1982) Odontoid fractures. *J Bone Joint Surg Br* 64:416–421
56. Schaffler MB, Alson MD, Heller JG, Garfin SR (1992) Morphology of the dens. A quantitative study. *Spine* 17:738–743
57. Schatzker J, Rorabeck CH, Waddell JP (1971) Fractures of the dens (odontoid process). An analysis of thirty-seven cases. *J Bone Joint Surg Br* 53:392–405
58. Sears W, Fazl M (1990) Prediction of stability of cervical spine fracture managed in the halo vest and indications for surgical intervention. *J Neurosurg* 72:426–432
59. Spence KF, Decker S, Sell KW (1970) Bursting atlantal fracture associated with rupture of the transverse ligament. *J Bone Joint Surg Am* 52:543–549
60. Stillerman CB, Wilson JA (1993) Atlanto-axial stabilization with posterior transarticular screw fixation: technical description and report of 22 cases. *Neurosurgery* 32:948–954; discussion 954
61. Subach BR, Morone MA, Haid RW Jr, McLaughlin MR, Rodts GR, Comey CH (1999) Management of acute odontoid fractures with single-screw anterior fixation. *Neurosurgery* 45:812–819; discussion 819–820
62. Wang GJ, Mabie KN, Whitehill R, Stamp WG (1984) The nonsurgical management of odontoid fractures in adults. *Spine* 9:229–230
63. White A, Panjabi M (1990) *Clinical biomechanics of the spine*, 2nd edn. Lippincott, Philadelphia





<http://www.springer.com/978-3-540-21347-5>

Minimally Invasive Spine Surgery

A Surgical Manual

Mayer, M. (Ed.)

2006, XX, 492 p., Hardcover

ISBN: 978-3-540-21347-5