

Repair of Involutional Ectropion and Entropion: Transconjunctival Surgery of the Lower Lid Retractors

1

Markus J. Pfeiffer

Core Messages

- Vertical deviation of the orbicularis muscle plays the most important role in entropion and ectropion formation.
- The orbicularis muscle is controlled by translamellar connections between the lower lid retractors and the anterior lamella.
- In ectropion, retractor laxity causes an absence of the angle at the lacrimal punctum.
- In entropion, retractor laxity produces a loss of the lid crease.
- Ectropion and entropion can be corrected by transconjunctival advancement of the retractors without excision of tissue.
- Horizontal lid laxity also requires correction.

1.1 Introduction

The opposite conditions of ectropion and entropion are caused by a similar pathogenesis and can be treated with similar principles. Therefore, they are presented in this chapter as two variations of the same entity. The traditional concept of inverting surgery for ectropion or everting surgery for entropion does not take into account that the most adequate procedure should simply aim to repair involutional pathology and try to restore

normal anatomy. Both ectropion and entropion can be treated by transposition of the lower lid retractors, without excision of tissue or rotating sutures. Retractor surgery has been introduced more widely over the last 20 years [2, 4, 6, 7]. This chapter is an attempt to analyze why the backward-directed vector of the retractors can effectively correct vertical deviations, even though this may appear paradoxical at first sight. Many modifications of retractor manipulations are possible. The modified techniques described in this chapter have proved their value over 20 years in a great number of patients.

1.2 Surgical Anatomy of the Lower Lid

Lower lid surgery requires a profound knowledge of palpebral and orbital anatomy. A basic knowledge can be obtained from anatomical studies of anatomical drawings and from anatomical specimens. As the tissues look very different during surgery, it is necessary to give names to some peroperative observations that are not listed in anatomical textbooks. Bloodless surgery achieved with the carbon dioxide laser provides a far better differentiation of the structures. The laser is combined with hydrodissection by injecting an anesthetic solution under the layer and thus making the structures more visible below. The following anatomical observations have been selected according to their surgical relevance to lower lid surgery.

1.2.1 Lower Lid Position and the Intercanthal Line

The lower lid position has to be evaluated in association with the spherical surface of the globe. The lower lid tends to follow the intercanthal line, the shortest line that can be drawn on the globe surface from the medial to the lateral canthal attachments. Note that medially at the lacrimal punctum, the intercanthal line is directed backward close to the globe's surface to join the posterior limb of the medial canthal tendon, while the lid margin forms an angle parallel to the anterior limb (Fig. 1.1). Medial ectropion is equivalent to the loss of the medial angle (Fig. 1.2). In ideal and stable conditions, the intercanthal line of the lower lid is identical to an equatorial line drawn through the medial and lateral canthus. In this case, the tension of the pretarsal orbicularis muscle will keep the lid margin in this position. In cases of a low lateral canthus, the intercanthal line is lower than the equatorial line, creating a tendency toward an even more inferior position of the lower lid and developing scleral show or even a lateral ectropion (Fig. 1.3). The effect of the low lateral canthus can be demonstrated using the model of a rubber band around a ping-pong ball. If the rubber band is moved away downward from the equator, it tends to slip off. In cases of a low lateral canthus or of exophthalmos, the intercanthal line is lower than the equatorial line and the lid cannot be raised by any tightening procedures. In these cases, the position of the lateral canthus has to be moved upward or the exophthalmos has to be corrected before any further surgery can be considered.

1.2.2 Posterior Lamella of the Lower Lid

The posterior lid lamella is an essential structure, because it provides a mucous interface, the fornix. The conjunctival lining of the fornix allows independent movements of the eyeball and the eyelid. Vertical incisions into the fornix should be avoided because scarring may produce an inhibition of the movement of the

tarsal and bulbar conjunctiva. We recommend horizontal incisions to expose the tarsal muscle and the lower lid retractors. The lower lid retractors (fascia capsulopalpebralis) are formed by a shell shaped fascia that covers the inferior hemisphere of the globe. Medially and laterally the fibers continue into the canthal tendons. The lateral fusion with the canthal tendon is obvious when we perform a lateral tarsal strip procedure and have to dissect the lateral retractors to be able to elevate the lid laterally. The medial fusion of the retractors and the posterior limb of the medial canthal tendon is found between the inferior lacrimal punctum and the caruncle. The vector of these fibers is directed posteriorly and is essential for the proper position of the lacrimal punctum.

1.2.3 Anterior Lamella of the Lower Lid

The pretarsal and preseptal skin is the thinnest of the body. Chronic epiphora induces skin irritation and shrinking. Any loss of skin surface must be ruled out. A certain skin redundancy is not only normal, but necessary to permit an elevation of the lower lid above the level of the intercanthal line. This extra elevation can be observed in forced closure, when the contracted preseptal orbicularis muscle slides below the inferior edge of the tarsus and lifts the tarsus over the intercanthal line. The orbicularis muscle plays an important role in the pathogenesis of ectropion and entropion. In both conditions the orbicularis muscle loses its control over the position of the posterior lamella by an upward dislocation in entropion or a downward dislocation in ectropion.

1.2.4 Relationship Between the Anterior and Posterior Lamellae

The relationship between the two lower lid lamellae is most important for the pathomechanism of involutional ectropion and entropion. In the tarsal area, the layers of the anterior and the pos-

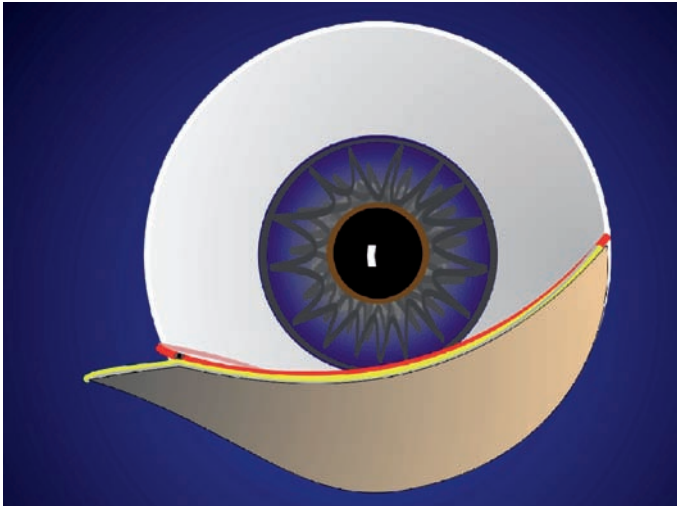


Fig. 1.1 The intercanthal line (red line) runs close to the globe's surface from the lateral canthus to the lacrimal punctum, where it continues into the posterior limb of the medial canthal tendon creating an angle with the lid margin (yellow line)

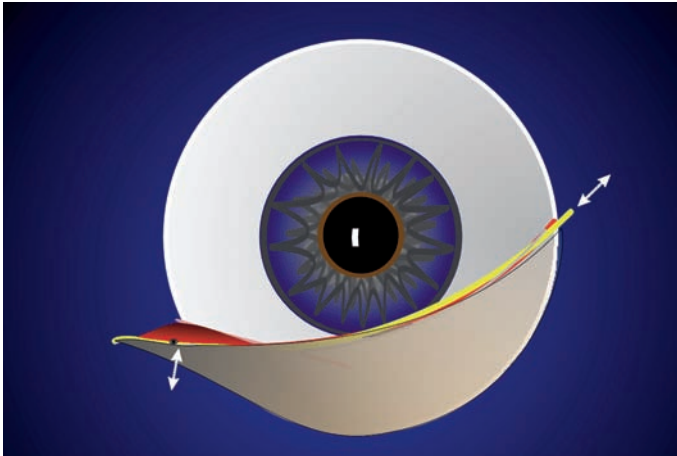


Fig. 1.2 Medial ectropion is equivalent to the loss of the angle at the lacrimal punctum caused by the laxity of the posterior medial fixation

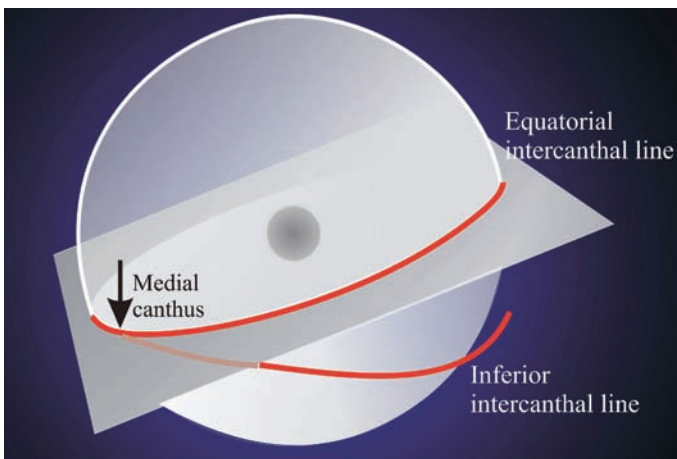


Fig. 1.3 In ideal and stable conditions, the intercanthal line of the lower lid is identical to an equatorial line drawn through the medial and lateral canthus. In this case, the tension of the pretarsal orbicularis muscle will keep the lid margin in this position. In cases of a low lateral canthus, the intercanthal line is lower than the equatorial line. Increasing horizontal tension will cause lower lid retraction.

terior lamellae are united by close attachments. Thus, the pretarsal orbicularis muscle acts like a belt on the tarsus. Involutional changes induce a laxity of these attachments and enable the muscle to become detached. In the septal area both lamellae are separated. If both lamellae are dissected by a transconjunctival approach, the pre-retractor space, where reticular adhesions connect to the anterior lamella, is exposed. These translamellar fibrous insertions are important for the control of the preseptal muscle and the formation of the lower lid crease. An involutional laxity of these translamellar fibers will allow the pretarsal muscle to glide upward and is considered to be the main mechanism of entropion formation.

1.2.5 Lower Lid Crease

The lower lid crease forms between the tarsal and the septal area. It is present in the majority of younger individuals and tends to disappear in the aging eyelid. Unlike the upper lid crease, the lower lid crease is aesthetically less appreciated. The formation of a lower lid crease is, however, an important sign of a functioning posterior attachment of the orbicularis muscle and offers the best protection from entropion. The translamellar fibers of the lower lid retractors insert into the preseptal orbicularis muscle. Entropion repair is much more effective and lasting if this translamellar connection is restored.

1.2.6 Orbital Septum and the Orbitomalar Septum

Involutional changes not only cause lid laxity in horizontal, vertical, and anteroposterior directions, but also induce a weakening of the orbital septum and a displacement of orbital fat anteriorly. Orbital fat protrusion contributes to a further separation of the lamellae and detachment of the orbicularis muscle from the posterior lamella [1] creating an additional factor of ectropion or entropion formation. The malar area of the midface is suspended by the orbitomalar septum connecting the inferior orbital rim with the malar fat pad. The laxity of the orbitomalar

septum causes drooping of the malar fat pad and downward traction of the anterior lamella of the lower lid. For this reason, we always take advantage of the lateral canthoplasty incision for a simultaneous section and superolateral transposition of the orbitomalar septum.

1.2.7 Lid Margin Shape and the Lid Margin Angle at the Lacrimal Punctum

Lower lid function is closely related to the correct position of the lid margin. Deviations of only 1 mm can cause functional problems such as punctal eversion or trichiasis. The stability of the tarsus determines the position of the mucocutaneous junction at the interior edge and the lash line at the exterior edge of the lid margin. Deformities of the lid margin's shape are signs of complicated entropion and ectropion and have to be addressed with additional procedures.

Summary for the Clinician

- The lower lid position depends on the intercanthal line.
- Translamellar connections between the anterior and posterior lamellae are responsible for the control of the orbicularis fibers.
- The presence of a lower lid crease is a sign of a functioning retractor attachment to the anterior lamella.
- Medially and laterally the retractor fibers continue into the canthal tendons.

1.3 Preoperative Evaluation and Surgical Planning

This is the most important step of the treatment, because an incomplete evaluation or inadequate planning cannot be compensated by the best surgical performance. The following important details should be checked before planning the procedure.

1.3.1 Evaluation of the Intercanthal Line

Check the shortest line between the medial and the lateral canthus on the globe and compare this line with the equatorial line between the two canthi. Take into account that a horizontal shortening of the lower lid by a tarsal strip procedure or full thickness excision will lower the lid if the equatorial line is higher than the intercanthal line. An elevation of the lateral canthus should be planned to raise the intercanthal line up to the level of the equatorial line (Fig. 1.4).

1.3.2 Evaluation of the anterior and posterior Surface

Check the conjunctival surface and the skin surface carefully. A minimal deficit of only 1 mm may be sufficient for surgical failure. Plan the replacement of skin or mucous membrane by grafts and do not rely on the less obvious skin deficit when the patient is in a supine position on the operating table.

1.3.3 Evaluation of the Three Vectors Influencing Lid Function

Check the lid motility for laxity or restriction in three directions (vertical, horizontal, and sagittal). The simple snap-back test is only the first step in checking lid laxity. The lower lid should

be examined by pushing it upward over the limbus to rule out vertical retraction and by lateral and medial stretching to test the condition of the canthal fixations. The sagittal vector (antero-posterior or translamellar attachments) can be evaluated by checking whether or not the lid crease is present.

1.3.4 Evaluation of the Lid Margin and the Punctum

Check the shape of the lid margin with the slit lamp. Deformation of the lid margin tends to occur in longstanding chronic ectropion and entropion. The “classic” rectangular shape of the margin is deformed to a “gothic” arch in entropion or to a “roman” arch in ectropion. Lid margin deformities contribute to complicated ectropion or entropion. They can be corrected with additional “shaping” procedures or lamellar repositioning surgery.

Summary for the Clinician

- Exclude the following signs of complicated ectropion and entropion, because they require additional surgery:
- Inferior position of the lateral canthus or a low intercanthal line.
- Deficit of skin surface or conjunctival surface.
- Deformity of the lid margin.

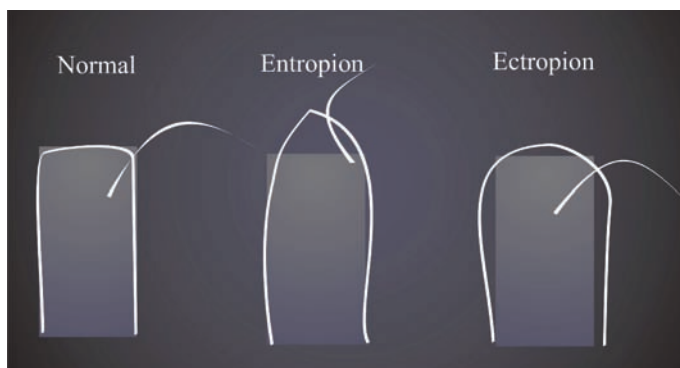


Fig. 1.4 Section of the lid margin. The normal “classic” rectangular shape of the margin is deformed into a “gothic” arch in complicated entropion or into a “roman” arch in complicated ectropion. Lid margin deformities can be corrected with additional “shaping” procedures or lamellar repositioning surgery

1.4 Surgical Technique for Ectropion Repair

The following technique avoids excision of tissue. The correction is obtained by separation, transposition, and fixation of the lid lamellae.

1.4.1 Principle of Retractor Fixation

The action of the retractors is composed of a “backward” and a “downward” vector. In the center of the lower lid both vectors are equivalent. Near the lacrimal punctum, the backward vector is dominant and is useful for correcting medial ectropion by pulling the lid margin backward in the direction of the posterior limb of the medial canthal tendon. The advancement of the retractors forms the posterior component. Alone it would be insufficient, because it only approximates the lower border of the tarsal plate to

the globe. Therefore, a second anterior component is needed to lift the anterior lamella (orbicularis muscle) upward in an inverting manner (Fig. 1.5).

1.4.2 Access to the Medial Retractors

The conjunctival incision begins close to the caruncle and ends laterally 3–4 mm below the lacrimal punctum, near the medial edge of the tarsal plate. This incision will expose some fibers of the tarsal muscle. If the inferior lip of the conjunctival incision is pushed downward, the whitish layer of the retractors is exposed underneath. The retractors are transected horizontally parallel to the conjunctival incision. Thus, the preretractor space is opened and the orbital septum can be seen. The retractors are mobilized bluntly backward and downward with a cotton tip (Fig. 1.6).

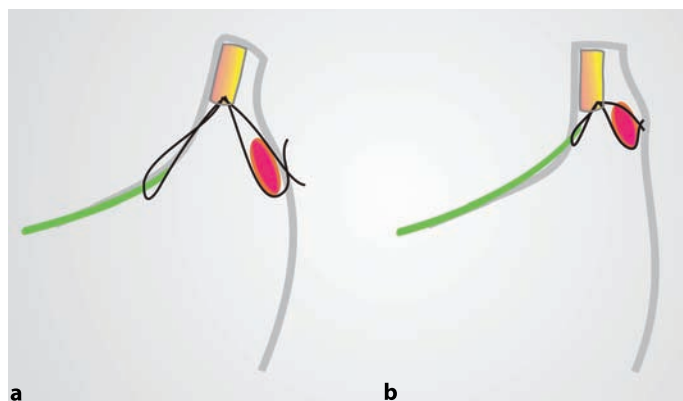


Fig. 1.5 **a** The posterior component of the retractor fixation advances the retractors (green) to the tarsus (yellow). **b** The anterior component lifts the anterior lamella (orbicularis muscle, red) upward, and the two components have an inverting effect

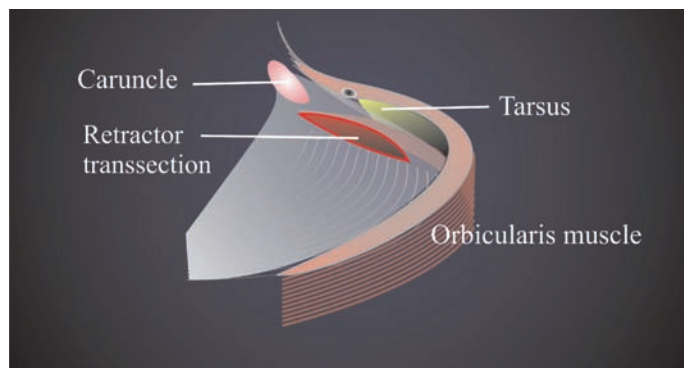


Fig. 1.6 The conjunctival incision begins close to the caruncle and ends laterally 3–4 mm below the lacrimal punctum, near the medial edge of the tarsal plate. The retractors are transected horizontally parallel to the conjunctival incision

1.4.3 Access to the Central Retractors

In cases of pronounced medial and central ectropion, the retractor exposure has to be extended horizontally over the entire lower lid. The conjunctival incision runs from the caruncle laterally, parallel to the tarsus, and 2 mm below the inferior border. The inferior lip of the conjunctival incision is pushed bluntly downward together with the tarsal muscle to expose the retractors, which are transected horizontally. Thus, the pre-retractor space is exposed, showing the typical reticular adhesions between the posterior and anterior lamella. These reticular adhesions can be separated by blunt dissection down to the orbital septum.

1.4.4 Exposure of the Inferior Tarsal Border

In order to place the retractor advancement sutures, the inferior tarsal border has to be exposed at the site where the bite is planned. In medial ectropion a single suture is placed at the medial and inferior border of the tarsus, approximately 2 mm lateral from the lacrimal punctum. In pronounced central ectropion two additional sutures are placed at the borders of the central third of the lid. Some caution is needed not to injure the vascular arcade at the lower tarsal border.

1.4.5 Suture Technique

The posterior component of the suture advances the retractors to the medial inferior border of the tarsal plate. A double-armed 6-0 nylon suture with a small half circle needle is used to grasp first the retractors and then the inferior tarsal border (Fig. 1.7). Medially, the retractors can be caught just below the punctum if the posterior limb of the medial canthal tendon is intact. If the medial canthal fixation is insufficient, the retractors are grasped half way between the punctum and the caruncle to improve the medial posterior attachment (Fig. 1.8). According to the laxity of the retractors, the suture has to be passed in at the appropriate level to create sufficient support of the posterior component and to avoid excessive tightness. The adjustment of retractor advancement is much less difficult than the advancement of the aponeurosis in ptosis surgery. It is recommended to begin with minimal or moderate advancement and only change to further advancement if the effect is insufficient. The anterior component of the suture is equally as important as the posterior component. After having been passed through the inferior border of the tarsus (Fig. 1.9), the suture runs downward to lift the preseptal orbicularis muscle fibers. Small horizontal skin incisions are necessary to grasp the needles over the anterior surface of the preseptal orbicularis muscle, where the suture is tied and the knot buried under the skin. This crane-like

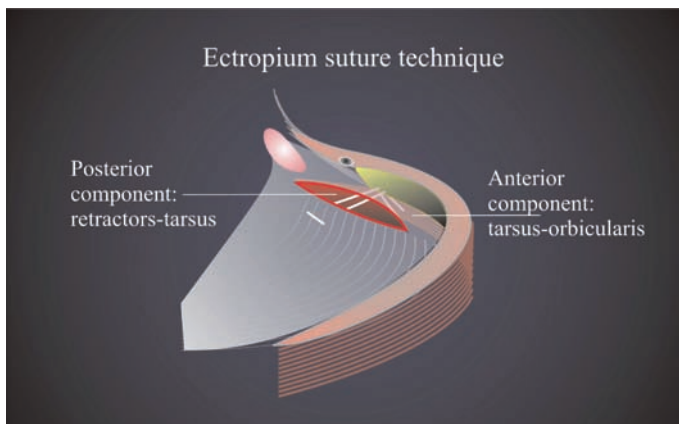


Fig. 1.7 The posterior component of the suture advances the retractors to the medial inferior border of the tarsal plate. The anterior component lifts the orbicularis muscle upward

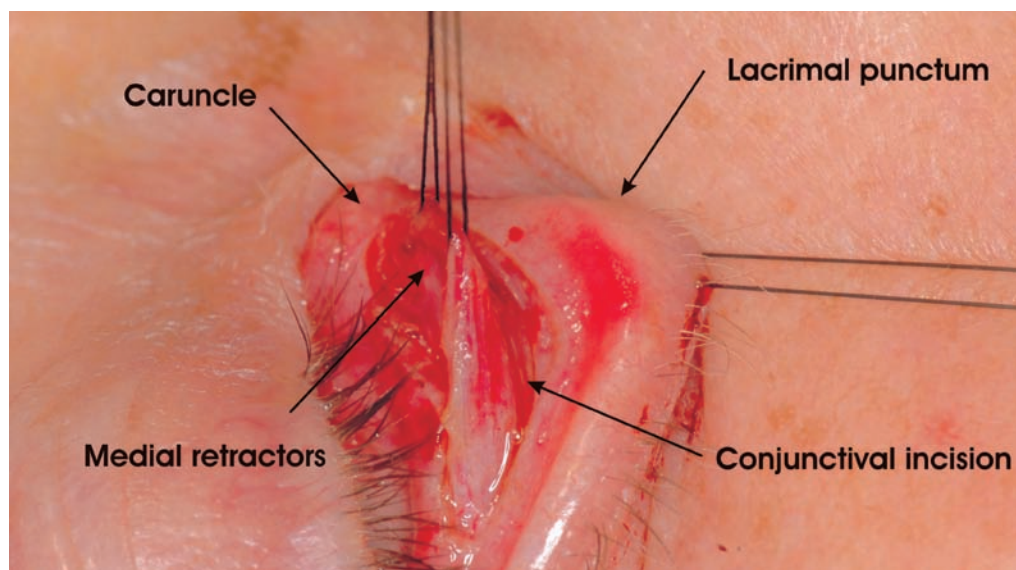


Fig. 1.8 The conjunctival incision runs from the caruncle to the medial inferior border of the tarsus. The medial lower lid retractors are exposed and grasped half way between the caruncle and the lacrimal punctum with a 6-0 non resorbable suture.

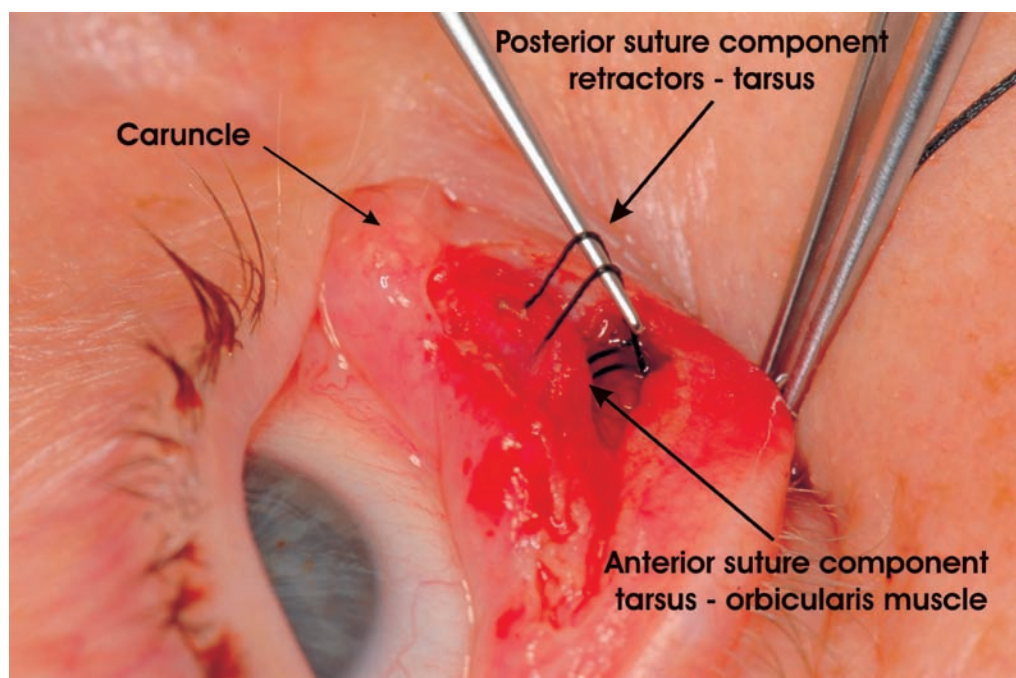


Fig. 1.9 The thin forceps lifts up the posterior component of the suture, that runs from the retractors to the inferior edge of the tarsal plate. The anterior component of the same suture is passed downward to perforate the orbicularis muscle before it is tied on its anterior surface (shown by the thicker forceps).

mechanism of the suture provides an upward directed vector and a lifting of the anterior lamella toward the lid margin with vertical effect. The sutures are not removed (Figs. 1.10, 1.11).

directly after retractor surgery without producing any tissue loss [2, 3].

1.4.6 Correction of Horizontal Laxity

Most cases of involutional ectropion will also require a horizontal tightening procedure to correct lid laxity. In patients with a low lateral canthus and a low intercanthal line, the lateral tarsal strip procedure can be combined with repositioning of the lateral canthus at a higher level and a lifting of the entire anterior lamella. The standard lateral tarsal strip procedure can be performed

Summary for the Clinician

- The posterior component of the suture approximates the tarsus to the globe.
- The anterior component of the suture lifts the orbicularis muscle upward.
- The medial fixation near the lacrimal punctum is the most important step, because it provides medial canthal fixation.
- In pronounced ectropion additional sutures are placed lateral to the punctum.

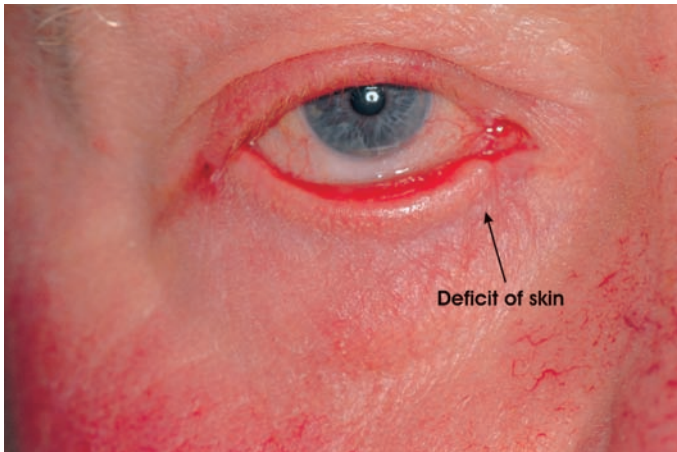


Fig. 1.10 Preoperative ectropion with a moderate deficit of medial eyelid skin and moderate lid margin deformity.

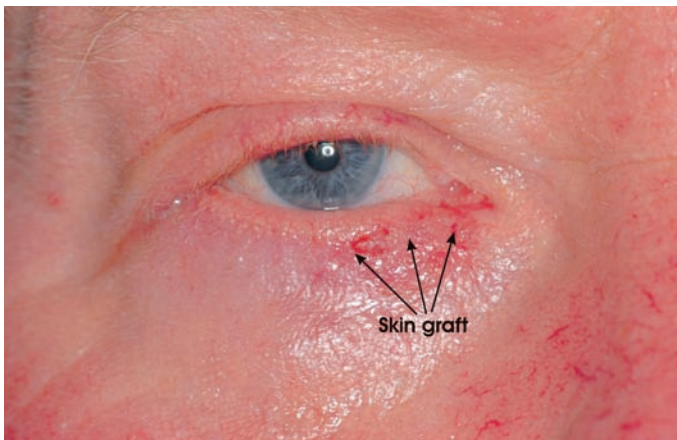


Fig. 1.11 Ten days postoperatively, after medial retractor fixation and a lateral tarsal strip procedure. The medial skin deficit had to be corrected by a free skin graft.

1.5 Surgical Technique for Entropion Repair

As in the ectropion repair procedure described above, the following technique for treating entropion avoids excision of tissue. The correction is obtained by separation, transposition, and fixation of the lid lamellae.

1.5.1 Principle of Retractor Fixation

The “backward” and “downward” vector of the retractor action can be used to attach and control overriding orbicularis muscle fibers in involuntary entropion. A sagittal translamellar connection of the posterior and anterior lid lamellae is created. The principle was described by Wies 50 years ago. His technique created a translamellar scar by a simple, horizontal, full-thickness transection in the lid crease level [9]. The translamellar connection reforms the natural attachments of the retractor fibers into the orbicularis muscle to form the lower lid skin crease (Fig. 1.12).

1.5.2 Access to the Lower Lid Retractors

The horizontal conjunctival incision is placed 2 mm below the inferior border of the tarsus. The inferior lip of the conjunctival incision is pushed bluntly downward, together with the tarsal muscle, to expose the retractors, which are transected horizontally. Thus, the preretractor space is exposed, showing the typical reticular adhesions between the posterior and anterior lamellae. The posterior aspect of the preseptal orbicularis muscle is exposed. If a blepharoplasty is planned in the same session, the reticular adhesions can be separated by blunt dissection downward to open the orbital septum.

1.5.3 Suture Technique

Two braided 5-0 nylon sutures with a 3/5 circle needle are passed through the retractors at the medial and the central third of the lid. Two small

horizontal skin incisions are placed over the upper preseptal muscle, where the new lid crease is to be created. The sutures are passed directly from the posterior position through the orbicularis muscle and appear anteriorly in the skin incisions where they are tied and buried under the skin. The sutures are not removed (Figs. 1.13, 1.14).

Summary for the Clinician

- Translamellar retractor advancement restores physiologic attachments between the anterior and the posterior lamellae.
- Lid crease formation after suture placement is a sign that the preseptal orbicularis muscle is prevented from sliding upward.
- Horizontal shortening can be performed in the same session.

1.6 Repair of Complicated Cases and Complications of Retractor Surgery

1.6.1 Complicated Involuntary Ectropion

Complicated involuntary ectropion develops after longstanding chronic ectropion with secondary deformation of eyelid tissue. Chronic epiphora causes chronic skin eczema and shrinking of the skin. It can best be corrected by free skin grafting in the subciliary area. Longstanding eversion of the lid also causes keratinization of the tarsoconjunctiva with deformation of the lid margin. These cases will need additional “shaping” procedures or complete separation and repositioning of the anterior and posterior lamellae.

1.6.2 Complicated Involuntary Entropion

After longstanding chronic involuntary entropion, the lid margin can suffer a “gothic arch”

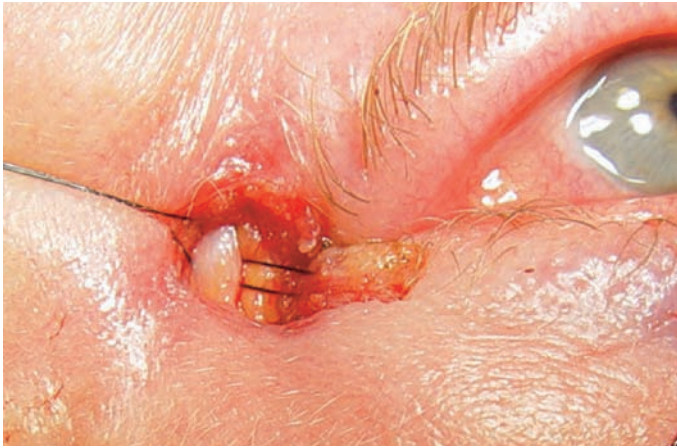

Fig 1.12 Most cases of involutional ectropion and entropion will also need a horizontal tightening procedure to correct lid laxity. In cases of low lateral canthus and low intercanthal line, the lateral tarsal strip procedure can be combined with repositioning of the lateral canthus to a higher level

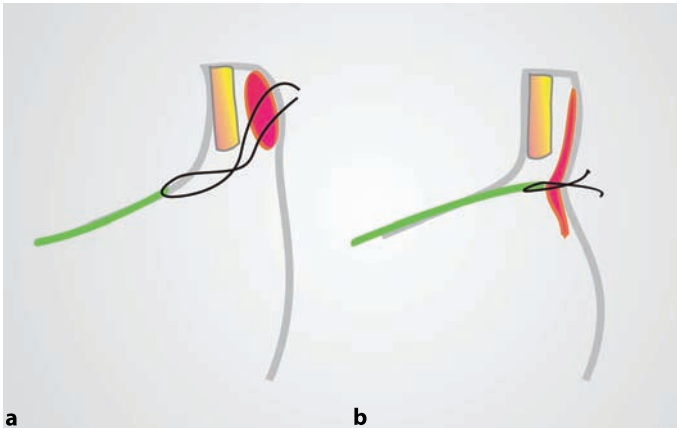


Fig 1.13 **a** The “backward” and “downward” vector of the retractor action (*green*) can be used to attach overriding orbicularis muscle fibers (*red*) in involutional entropion. **b** A sagittal translamellar connection of the posterior and anterior lid lamellae is created to attach the orbicularis muscle and to restore the lower lid crease

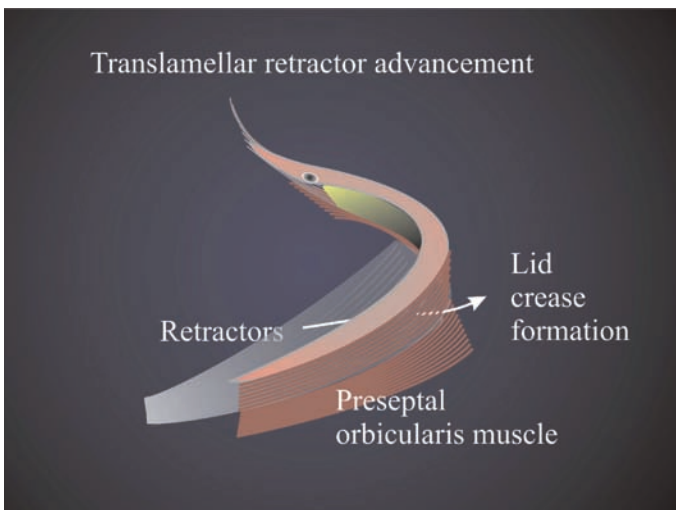


Fig. 1.14 The horizontal conjunctival incision is placed 2 mm below the inferior border of the tarsus. The inferior lip of the conjunctival incision is pushed bluntly downward together with the tarsal muscle to expose the retractors, which are transected horizontally and advanced toward the anterior lamella with penetrating sutures that are tied subcutaneously over the preseptal orbicularis muscle

deformity where the lash line is displaced to the apex and the inner and outer edges of the margin are absent. In mild cases, the condition can be corrected by additional shaping of the lid margin. With the high frequency needle, a sulcus can be created posterior to the lash line in the area of conjunctivalization. If the retractor sutures are placed at a higher pretarsal level of the orbicularis muscle, they act in a more pronounced everting manner and can be used to open the sulcus. In severe cases, complete separation and repositioning of the anterior and posterior lamellae are necessary.

1.6.3 Complications of Retractor Surgery

Under-correction of entropion or ectropion is probable after retractor surgery without correction of the horizontal laxity. The lateral tarsal strip procedure can, however, be performed at a later stage. Under-correction can also occur after incorrect placement of the retractor sutures. In these cases, repeat suturing should be planned as early as possible. Results after ectropion surgery can appear over-corrected when the lash line is directed upward or even inward, due the deformity of the lid margin. We have often observed a spontaneous normalization of the lash line orientation after a few weeks. If this does not occur, we can split the lid margin at the gray line in order to evert the lash line. In entropion surgery excessive tightening of the retractors can cause a retraction or eversion. To avoid severe lid retraction, the retractors have to be released as early as possible.

References

1. Beigi B (2001) Orbicularis oculi muscle stripping and tarsal fixation for recurrent entropion. *Orbit* 20(2):101–105
2. Collin JRO (2005) Manual of systematic eyelid surgery. Butterworth Heinemann/Elsevier, Amsterdam
3. Corin S, Veloudios A, Harvey JT (1991) A modification of the lateral tarsal strip procedure with resection of orbicularis muscle for entropion repair. *Ophthalmic Surg* 22:606–608
4. Dresner SC, Karesh JW (1993) Transconjunctival entropion repair. *Arch Ophthalmol* 111:1144–1148
5. Khan SJ, Meyer DR (2002) Transconjunctival lower eyelid involutional entropion repair: long-term follow-up and efficacy. *Ophthalmology* 109:2112–2117
6. Pfeiffer MJ (2004) Involutives Unterlidektropium: Chirurgische Therapie. *Ophthalmochirurgie* 16:89–96
7. Pfeiffer MJ (2005) Involutives Unterlidentropion: Chirurgische Therapie. *Ophthalmochirurgie* 17:23–28
8. Quickert MH, Rathburn JE (1971) Suture repair of entropion. *Arch Ophthalmol* 85:304–305
9. Wies FA (1954) Surgical treatment of entropion. *J Int Coll Surg* 21:758–760

Summary for the Clinician

- Identify complicated cases because they will need additional surgery.
- Try to avoid excision of tissue.
- Do not exaggerate the tightening or advancement.
- Try to restore a normal flexible tone to the three vectors of fixation.

<http://www.springer.com/978-3-540-33675-4>

Oculoplastics and Orbit

Guthoff, R.; Katowitz, J.A. (Eds.)

2007, XX, 282 p. 301 illus., 273 illus. in color.,

Hardcover

ISBN: 978-3-540-33675-4