

15.9 Urethral Trauma

L. MARTÍNEZ-PIÑEIRO

15.9.1	Anatomical and Etiological Considerations	276
15.9.1.1	Posterior Urethral Injuries	276
	Stable Pelvic Fracture	277
	Unstable Pelvic Fractures	277
	Urethral Injuries in Children	278
	Urethral Injuries in Women	278
	Penetrating Injuries to the Perineum	279
15.9.1.2	Anterior Urethral Injuries	279
	Blunt Trauma	279
	Intercourse-Related Trauma	279
	Penetrating Trauma	280
	Constriction Band-Related Trauma	280
	Iatrogenic Trauma	280
15.9.2	Diagnosis: Initial Emergency Assessment	282
15.9.2.1	Clinical Assessment	282
15.9.2.2	Radiographic Examination	283
15.9.2.3	Endoscopic Examination	284
15.9.3	Management	284
15.9.3.1	Anterior Urethral Injuries	284
	Blunt Injuries	284
	Open Injuries	284
15.9.3.2	Posterior Urethral Injuries	286
	Partial Urethral Rupture	287
	Complete Urethral Rupture	287
	Primary Realignment	287
	Immediate Open Urethroplasty (< 48 h After Injury)	289
	Delayed Primary Urethroplasty (2 – 14 Days After Injury)	290
	Delayed Urethroplasty (3 – 6 Months After Trauma)	290
	Reconstruction of Failed Repair of Posterior Urethral Rupture	292
	Delayed Endoscopic Optical Incision	292
15.9.4	Recommendations for Treatment: Algorithms	293
	References	295

15.9.1

Anatomical and Etiological Considerations

The male urethra is divided into the anterior and posterior sections by the urogenital diaphragm. The posterior urethra consists of the prostatic and the membranous urethra (Fig. 15.9.1). The anterior urethra consists of the bulbar and penile urethra. Only the posterior urethra exists in the female; the anterior urethra corre-

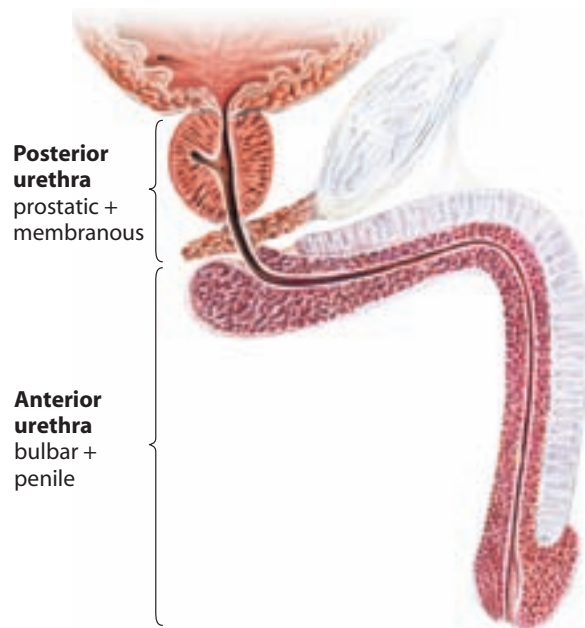


Fig. 15.9.1. Anatomy of the male urethra (© Hohenfellner 2007)

sponds to the labia minora, which results from persistent separation of the urethral folds on the ventral surfaces of the genital tubercle.

15.9.1.1

Posterior Urethral Injuries

Injuries to the posterior urethra occur with pelvic fractures, which are commonly caused by road traffic accidents, crush injuries, or falls from height. Approximately two-thirds (70%) of pelvic fractures occur as a result of motor vehicle accidents, with an incidence of 20% in fatal motor accidents, as a driver or passenger, and nearly 50% in fatal pedestrian accidents. Twenty-five per cent of cases present as a result of a fall from a height (Koraitim et al. 1996; Sevvitt 1968). Altogether, blunt trauma accounts for more than 90% of urethral injuries (Dixon 1996). Overall, the male posterior urethra is concomitantly injured in approximately 3.5%–19% and the female urethra in 0%–6% of all

pelvic fractures (Carlin and Resnick 1995; Clark and Prudencio 1972; Colapinto 1980; Hemal et al. 2000; Koraitim et al. 1996; Lowe et al. 1988; Palmer et al. 1983; Perry and Husmann 1992; Pokorny et al. 1978; Webster et al. 1983). The female urethra is rarely injured, except by contusion or laceration by bone fragments.

Specifically with a crush or deceleration impact injury, the severe shearing forces necessary to fracture the pelvis are transmitted to the prostatomembranous junction, resulting in disruption of the prostate from its connection to the anterior urethra at the prostatic apex. Retrograde urethrography and magnetic resonance imaging have been correlated with this location of the injury (Colapinto and McCallum 1977; Dixon et al. 1992). Recent cadaveric anatomic studies suggest that in most cases the membranous urethra is torn distally to the urogenital diaphragm (Mouraviev and Santucci 2005).

Accurate knowledge of the functional anatomy of the sphincter mechanism is essential to the success of posterior urethral surgery. The feasibility of anastomotic reconstruction of subprostatic pelvic fracture urethral distraction defects depends upon the independent function of the proximal bladder neck and of the distal urethral sphincter mechanism, each of which is competent and independently capable of maintaining continence in the absence of the other (Turner-Warwick 1973).

In order to accurately diagnose and treat pelvic ring disruptions, the surgeon must have a concept of pelvic stability, which should be determined in both the horizontal and vertical planes. A mechanically stable pelvis is defined as one that can withstand normal physiological forces without abnormal deformation (Tile and Pennal 1980). The degree of instability is best indicated by the disruption and posterior displacement at the sacroiliac area and is of extreme importance as a prognostic indicator for the general resuscitation of the patient (Pennal et al. 1980). The anteroposterior and lateral compression types of fracture, while vastly different, may be associated with both stable and unstable subtypes.

The vertical shear fracture is always unstable. The latter described by Malgaigne in 1855 consists of a fracture anteriorly through both rami of the symphysis pubis, in association with massive posterior disruption, either through the sacrum, the sacroiliac joint, or the ilium.

Stable Pelvic Fracture

In a stable pelvic fracture, urethral disruption can occur when the large external force, which has fractured two or all four pelvic rami (straddle fracture), propels the resultant butterfly fragment backward together with the prostate, which is fixed to the back of the pubic

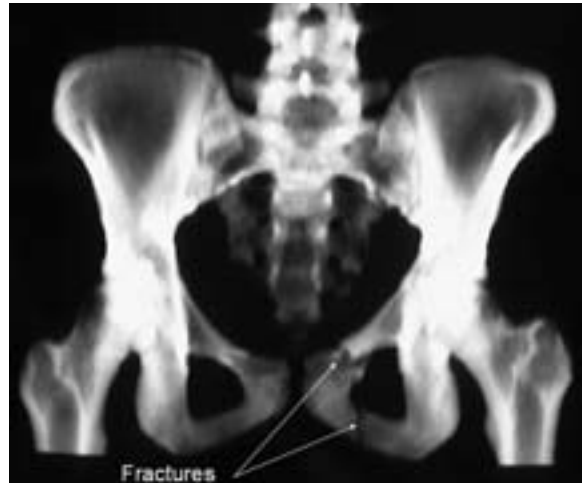

Fig. 15.9.2. Example of stable pelvic fracture. Both pubic rami of the left side are fractured. A mechanically stable pelvis is defined as one that can withstand normal physiological forces without abnormal deformation

bone (Fig. 15.9.2). The shearing force that results disrupts the membranous urethra, as it passes through the perineum and inevitably destroys the distal urethral sphincter mechanism in almost all such cases.

Unstable Pelvic Fractures

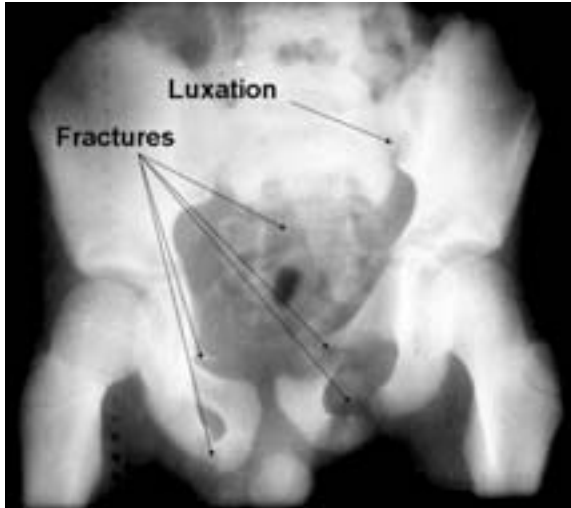
Unstable fractures that involve the anterior part of the pubic ring and the sacroiliac joint, ileum, or sacrum can also cause injuries to the posterior urethra, either as a result of tears by bony fractures or, more commonly, as a result of disruptions of the urethra caused by distortions of the bony pelvis during major trauma.

This distortion is thought to result in lateral shearing forces, acting on the membranous urethra, as the puboprostatic ligaments and the membranous urethral area are pulled in opposite directions (Pokorny et al. 1978). Unstable diametric pelvic fractures (Conolly and Hedbert 1969; Devine and Devine 1982; Flaherty et al. 1968; Palmer et al. 1983; Pokorny et al. 1978) or bilateral ischiopubic rami fractures have the highest likelihood of injuring the posterior urethra. In particular, the combination of straddle fractures with diastasis of the sacroiliac joint has the highest risk of urethral injury; the odds ratio is about seven times higher than for straddle or Malgaigne fractures (Table 15.9.1) (Fig. 15.9.3) (Koraitim et al. 1996).

Lower urinary tract injury has been reported in about 16% of patients with unilateral rami fractures, but in 41% of patients with bilateral rami fractures (Zorn 1960). Anteroposterior compression injuries from frontal crushes produce more severe pelvic fractures, major retroperitoneal bleeding, and more frequent injury to the lower urinary tract than do lateral crashes (Siegel et al. 1990).

Table 15.9.1. Odds ratio of urethral injury with different types of pelvic fracture

Type of fracture	Odds ratio
Single ramus	0.64
Ipsilateral rami	0.76
Malgaigne's	3.40
Straddle	3.85
Straddle plus sacroiliac	24.02

**Fig. 15.9.3.** Example of unstable pelvic fracture. Unstable fractures involve the anterior part of the pubic ring and the sacroiliac joint, ileum, or sacrum

Prostatomembranous urethral injuries can vary from simple stretching (25%) to partial rupture (25%) or complete disruptions (50%) (Koraitim et al. 1996). The more severe injuries result in prostatourethral displacement, with progressive scar formation encompassing the rupture defect. The incidence of double injuries involving the urethra and the bladder ranges between 10% and 20% of males, and may be intraperitoneal (17%–39%) or extraperitoneal (56%–78%), or both (Carlin and Resnick 1995; Koraitim et al. 1996).

Urethral injuries, by themselves, are never life-threatening, except as a consequence of their close association with pelvic fractures and multiple organ injuries, which occur in about 27% of cases. Initially, the assessment and management of other associated injuries are usually far more important than the assessment and management of the urethral injury (Chapple and Png 1999).

Colapinto and McCallum (1977) classified posterior urethral injuries on the basis of radiographic appearance into three types, depending on the integrity of the membranous urethra and extension of the disruption into the bulbar and membranous urethra. The American Association for Surgery of Trauma (AAST) later proposed the classification given in Table 15.9.2.

Table 15.9.2. Organ injury scaling III classification of urethral injuries

Type	Description	Appearance
I	Contusion	Blood at the urethral meatus; normal urethrogram
II	Stretch injury	Elongation of the urethra without extravasation on urethrography
III	Partial disruption	Extravasation of contrast at injury site with contrast visualized in the bladder
IV	Complete disruption	Extravasation of contrast at injury site without visualization in the bladder; <2 cm of urethral separation
V	Complete disruption	Complete transection with >2 cm urethral separation, or extension into the prostate or vagina

From Moore et al. 1992

Table 15.9.3 presents a summary of the different types of blunt trauma of the posterior and anterior urethra, along with their radiographic appearance and different treatment alternatives.

Urethral Injuries in Children

Urethral injuries in children tend to follow the same mechanism of injury as in adults. The only significant difference is that straddle pelvic fractures, Malgaigne's fractures, or the association of straddle plus sacroiliac joint fracture are more common in children than in adults. In addition, posterior urethral injuries can involve the prostatic urethra and the bladder neck, as well as the membranous urethra. The tear is often in the prostatic urethra or at the bladder neck because of the rudimentary nature of the prostate and is more likely to be a complete rupture (69% vs 42%). Urethral stretching is less common than in adults. It has been shown that the more proximal the injury, the greater the risk of incontinence, impotence, and stricture formation in the long term (Chapple and Png 1999; Koraitim 1997, 1999; Koraitim et al. 1996).

Urethral Injuries in Women

These are rare events since the female urethra is short and mobile, without any significant attachments to the pubic bone. They usually occur in children and are accompanied by severe pelvic fractures, where bony fragments of the fractured pelvis provoke lacerations of the urethra, frequently extending into the bladder neck or vagina, and disrupting the normal continence mechanism (Hemal et al. 2000; Perry and Husmann 1992). Injury to the female urethra is usually a partial tear of the anterior wall and is rarely a complete disruption of the proximal or distal urethra (Koraitim 1999).

Table 15.9.3. Different types of blunt trauma of the posterior and anterior urethra, their radiographic appearance and different treatment alternatives

	Description	Management
I	Stretch injury. Elongation of the urethra without extravasation on urethrography	No treatment required
II	Contusion. Blood at the urethral meatus; no extravasation on urethrography	Conservative management with suprapubic cystostomy or urethral catheterization
III	Partial disruption of anterior or posterior urethra. Extravasation of contrast at injury site with contrast visualized in the proximal urethra or bladder	Conservative management with suprapubic cystostomy or urethral catheterization
IV	Complete disruption of anterior urethra. Extravasation of contrast at injury site without visualization of proximal urethra or bladder	Conservative management with suprapubic cystostomy. Open or endoscopic treatment, primary or delayed
V	Complete disruption of posterior urethra. Extravasation of contrast at injury site without visualization of bladder	Conservative management with suprapubic cystostomy. Open or endoscopic treatment, primary or delayed
VI	Complete or partial disruption of posterior urethra with associated tear of the bladder neck or vagina	Primary open repair

Penetrating Injuries to the Perineum

These can occur involving the urethra, as well as being iatrogenic injuries caused by endoscopic instrumentation or during surgery for vaginal repair. In developing countries, urethral and bladder neck damage occur quite often as a result of ischemic injury during obstructed labor.

15.9.1.2

Anterior Urethral Injuries

Anterior urethral injuries result from blunt trauma more frequently than from penetrating trauma (Table 15.9.4).

Blunt Trauma

Most anterior urethral injuries are caused by vehicular accidents, falls, or blows; in contrast to posterior urethral trauma, they are rarely associated with pelvic fractures. They are usually straddle-type injuries caused by blows of blunt objects against the perineum, such as bicycle handlebars or the top of a fence. In this type of accident, the relatively immobile bulbar urethra is trapped and compressed by a direct force on it against the inferior surface of the symphysis pubis. These injuries are more common in children than adults (Koraitim 1997).

Intercourse-Related Trauma

Another less frequent cause of blunt anterior urethral trauma occurs in association with ruptures of the corpora cavernosa, which usually occur with an erect penis,

Table 15.9.4. Etiology of anterior urethral injuries

Causes
Blunt trauma Vehicular accidents Fall astride Kicks in the perineum Blows in the perineum from bicycle handlebars, tops of fences, etc.
Sexual intercourse Penile fractures Urethral intraluminal stimulation Constriction bands
Penetrating trauma Gunshot wounds Stab wounds Dog bites External impalement Penile amputations
Constriction bands Paraplegia
Iatrogenic injuries Endoscopic instrumentations Urethral catheters, dilators

often during intercourse (Fig. 15.9.4). In these injuries, the urethra is involved in 20 % of the cases (Nicolaisen et al. 1983). Intraluminal stimulation of the urethra with foreign objects has also been reported to cause anterior urethral trauma. Most are short and incomplete and occur in the distal penile urethra. Surgery is rarely indicated and depends on the degree and extent of injury to the urethra.

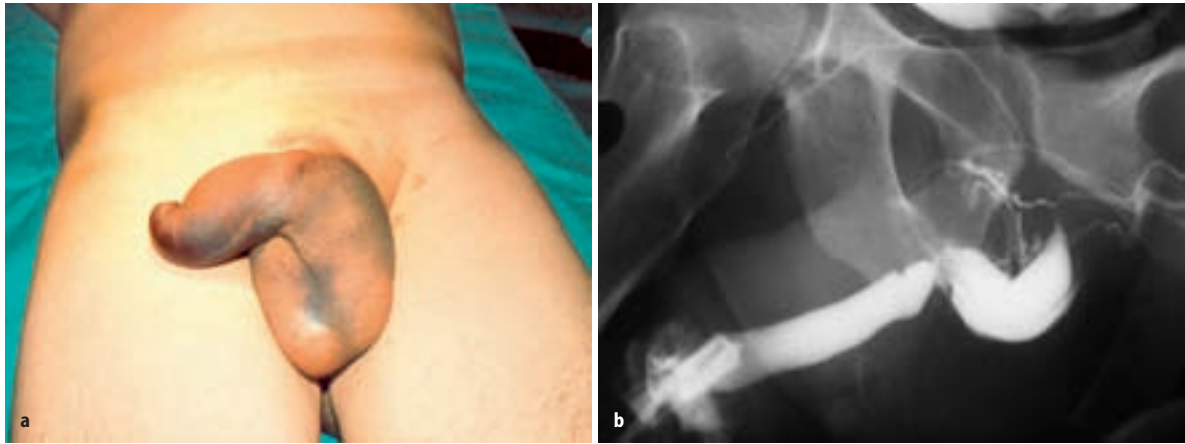


Fig. 15.9.4. **a** Typical aspect of genitalia after rupture of corpora cavernosa during sexual intercourse. **b** In 20% of the cases, the urethra is involved, suffering partial or complete rupture

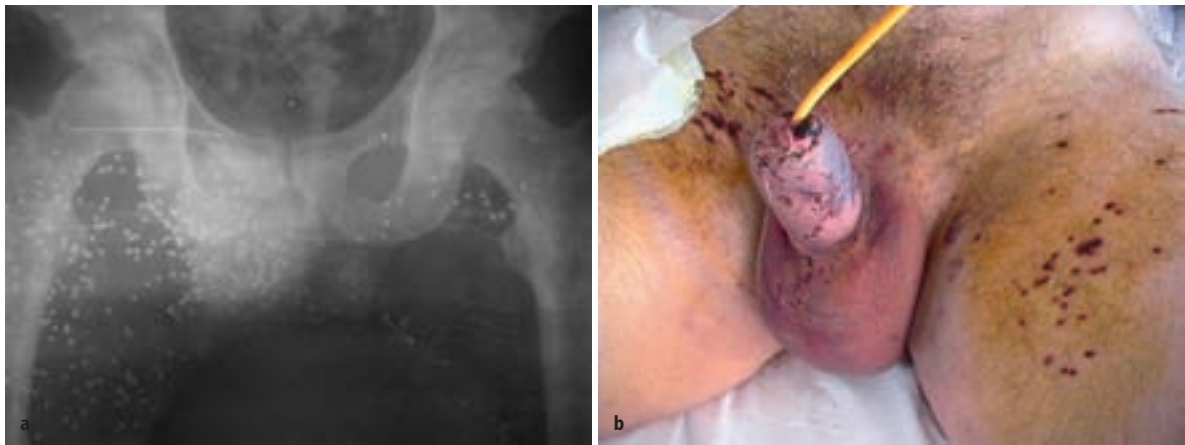

Fig. 15.9.5a, b. Gunshot wound to the genitalia. Penile urethra was involved with only a few pellets and was managed conservatively

Penetrating Trauma

Penetrating injuries to the anterior urethra usually occur from gunshot wounds and involve the pendulous and bulbar urethral segments equally; these injuries are often found with penetrating penile or testicular trauma, depending on the missile tract (Figs. 15.9.5, 15.9.6). These can involve the rectum, which may result in pelvic abscesses and fistulae formation. (Gomez et al. 1993; Pontes and Pierce 1978). Other less frequent causes of external anterior urethral injuries include stab wounds, animal bites (Fig. 15.9.7), penile amputation, and external impalement.

Constriction Band-Related Trauma

Individuals with paraplegia, who use a constriction device for urinary incontinence and forget to release the band due to the lack of sensation, can cause severe ischemic injuries involving the penis and urethra (Fig. 15.9.8).

Iatrogenic Trauma

Iatrogenic urethral injuries caused by instrumentation are by far the most common cause of urethral trauma. Urethral ischemic injuries related to cardiac bypass procedures are not infrequent and can result in long and fibrotic strictures.

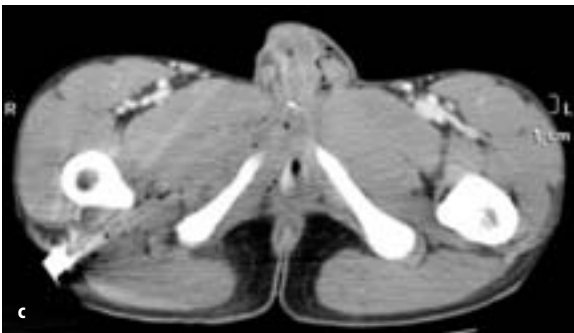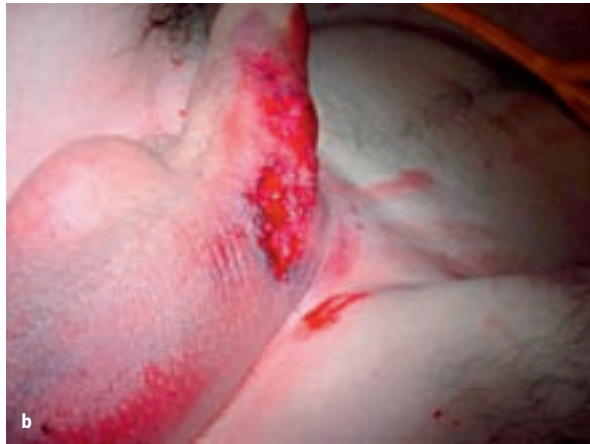

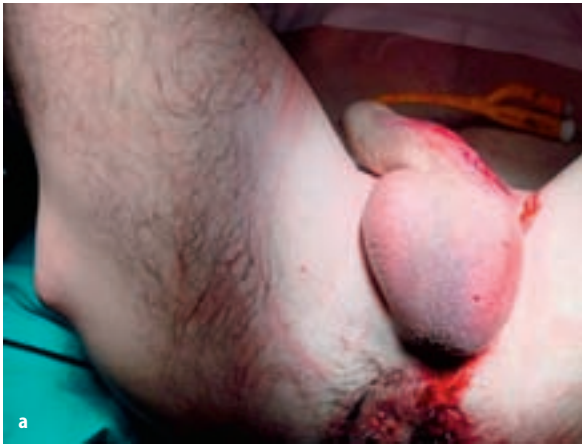
Fig. 15.9.6a–c. Gunshot wound to the penis. The bullet went through the corpora cavernosa, superficially damaged the urethral spongy tissue, and ended in the subcutaneous tissue of the right thigh. Urethroplasty was not required. **a** and **b** Show external aspect at admission. **c** CT scan showing bullet in the posterior aspect of the right thigh. (Courtesy of Dr. J.J. López-Tello)

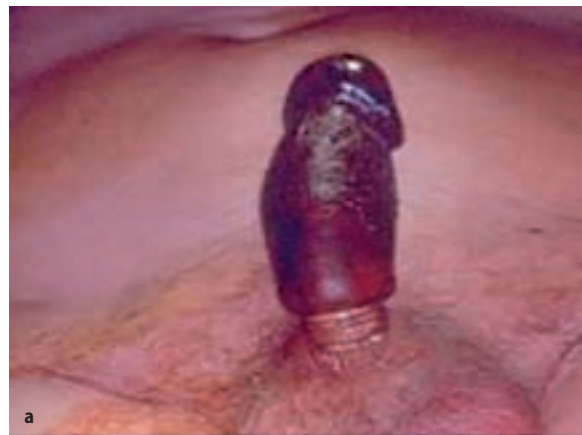
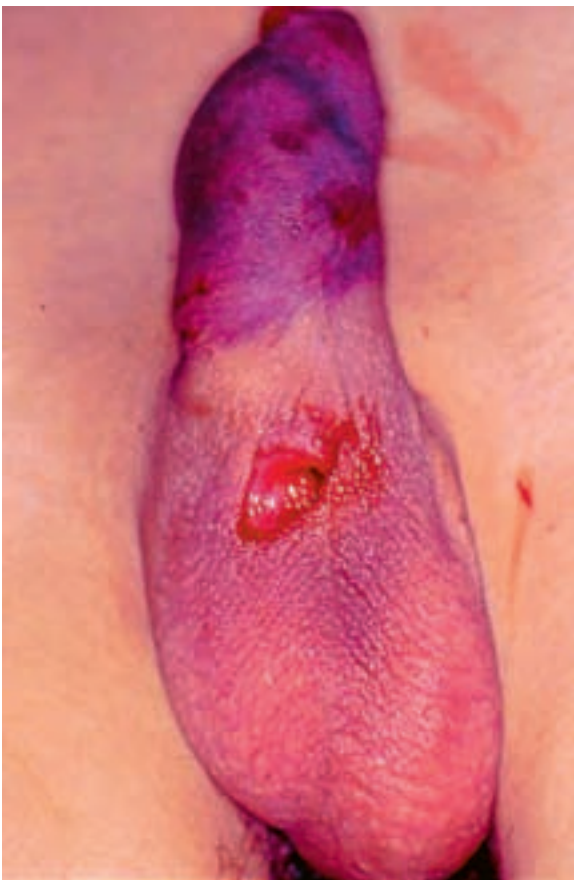
Fig. 15.9.8a, b. Ischemic necrosis of penis due to plastic constriction device (neck of a plastic bottle) used to improve erections (Courtesy of Dr. S. Luengo)

◁

Fig. 15.9.7. Dog bite with urethral laceration at the penoscrotal angle that required immediate open repair.

15.9.2

Diagnosis: Initial Emergency Assessment

15.9.2.1

Clinical Assessment

The initial management of all urethral injuries is resuscitation of the patient as a result of associated possibly life-threatening injuries. In the absence of blood at the meatus or hematoma, a urological injury is very unlikely and will be rapidly excluded by catheterization that promptly occurs in all major trauma victims as part of the process of resuscitation. Airway and respiratory function are maintained, the cervical spine secured in case of polytraumatism, and excessive hemorrhage addressed. This is particularly important in posterior urethral injuries because of their close association with pelvic fractures.

The next step includes taking a complete history and carrying out physical, laboratory, and radiographic evaluations in order to identify all injuries accurately. A diagnosis of acute urethral trauma should be suspected from the history. A pelvic fracture, or any external penile or perineal trauma, can be suggestive of urethral trauma (Armenakas and McAninch 1994, 1996).

For penetrating injuries, the type of weapon used, including the caliber of the bullet with gunshot wounds, is helpful in assessing potential tissue damage. In the conscious patient, a thorough voiding history should be obtained to establish the time of last urination, force of urinary stream, painful urination, and presence of hematuria. The following clinical indicators of acute urethral trauma warrant a complete urethral evaluation:

- **Blood at the meatus**
Blood at the meatus is present in 37%–93% of patients with posterior urethral injury and at least 75% of patients with anterior urethral trauma (Lim and Chng 1989; McAninch 1981). Its presence should preclude any attempts at urethral instrumentation, until the entire urethra is adequately imaged. In an unstable patient, an attempt can be made to pass a urethral catheter, but if there is any difficulty a suprapubic catheter is inserted and a retrograde urethrogram performed when appropriate. It is extremely unlikely that gentle passage of a urethral catheter will do any additional damage to that caused by a fracture of the pelvis (Mundy 1996; Venn and Mundy 1998), although it has been suggested that this may convert a partial tear into one that is complete (Corriere and Harris 1981). There are no convincing data indicating a higher rate of infection or urethral stricture after a single attempt at catheterization (Dixon 1996). Indeed, if a urethral injury is suspected, urethrography prior to attempted catheterization is the most prudent approach.

- **Blood at the vaginal introitus**
Blood at the vaginal introitus is present in more than 80% of female patients with pelvic fractures and co-existing urethral injuries (Perry and Husmann 1992).
- **Hematuria**
Although nonspecific, hematuria on a first voided specimen may indicate urethral injury. The amount of urethral bleeding correlates poorly with the severity of injury, as a mucosal contusion or small partial tear may be accompanied by copious bleeding, while total transection of the urethra may result in little bleeding (Antoci and Schiff 1982).
- **Pain on urination or inability to void**
The inability to void suggests urethral disruption.
- **Hematoma or swelling**
With anterior urethral trauma, the pattern of the hematoma can be useful in identifying the anatomical boundaries violated by the injury. Extravasation of blood or urine in a sleeve distribution along the penile shaft indicates that the injury is confined by Buck's fascia. Disruption of Buck's fascia results in a pattern of extravasation limited only by Colles fascia, extending therefore up to the coracoclavicular fascia superiorly and the fascia lata inferiorly (Fig. 15.9.9). This results in a characteristic butterfly pattern of bruising in the perineum. In female patients with severe pelvic fractures, the presence

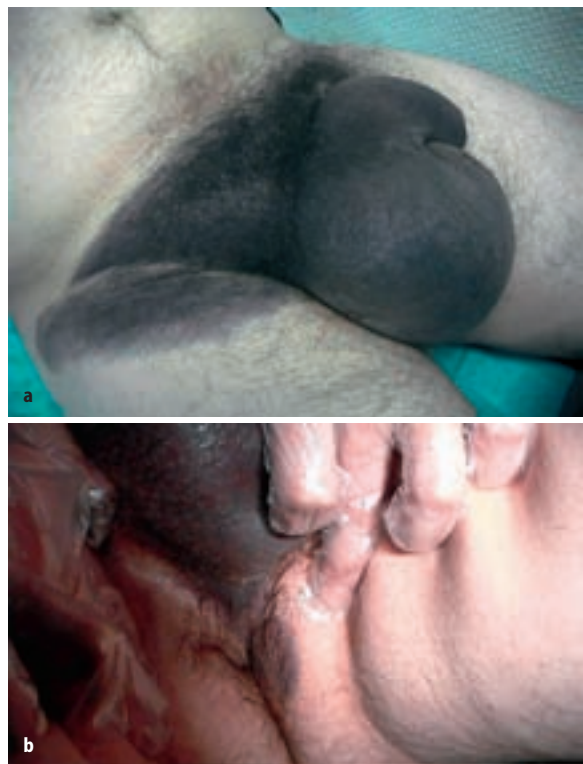

Fig. 15.9.9a, b. Large genital hematoma limited by Colles fascia

of labial swelling may be an indicator of urethral injury. It can be caused by urinary extravasation from a urethral fistula and warrants immediate attention.

- High-riding prostate

This is a relatively unreliable finding in the acute phase, since the pelvic hematoma associated with pelvic fractures often precludes the adequate palpation of a small prostate, particularly in younger men (Dixon 1996). A boggy mass is usually palpated without recognition of a prostate gland (Fallon et al. 1984). Rectal examination is more important as a tool to screen for rectal injuries, which can be associated with pelvic fractures. Blood on the examination finger is highly suggestive of such an injury. Assessment of concomitant genital injuries is mandatory in every case of external urethral trauma as well.

15.9.2.2

Radiographic Examination

Retrograde urethrography is considered the gold standard for evaluating urethral injury. A scout film should be taken first to assess the radiographic technique and to detect pelvic fractures, as well as the presence of any foreign bodies such as bullets or stones, which may not be delineated once the contrast material has been given. This is taken using a 12- or 14-F Foley catheter in the fossa navicularis, with the balloon inflated using 1–2 ml of saline to occlude the urethra. Then, 20–30 ml of undiluted contrast material is injected and films taken during the injection in a 30° oblique position. When severe pelvic fractures and associated patient discomfort are present, the oblique position may not always be possible. Radiographic appearance of the urethra permits classification of the injury and facilitates subsequent management.

If posterior urethral injury is suspected, a suprapubic catheter is inserted; a simultaneous cystogram and ascending urethrogram can be carried out at a later date to assess the site, severity, and length of the urethral injury. This is usually done within 1 week of injury, if primary repair is contemplated, or after 3 months if a delayed or late repair is considered (Fig. 15.9.10).

When the proximal urethra is not visualized in a simultaneous cystogram and urethrogram, either magnetic resonance imaging (MRI) of the posterior urethra (McAninch 1996) or endoscopy through the suprapubic tract can be used (Fig. 15.9.11) to define the anatomy of the posterior urethra. Since manipulation in the bladder can cause the bladder neck to open and give the false impression of incompetence; consequently, the endoscopic appearance of the bladder neck should be noted immediately on placing the scope into the bladder (Jordan 1996).

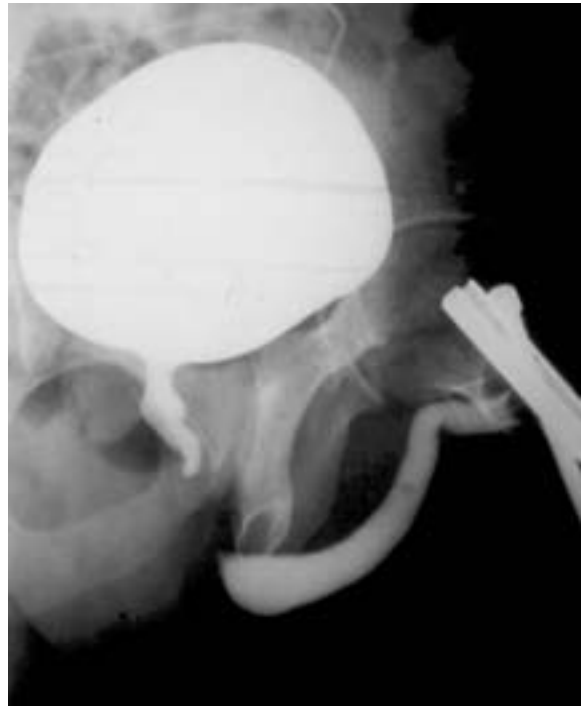

Fig. 15.9.10. Combined micturition and retrograde urethrography to assess the length of the distraction defect after posterior urethral fracture

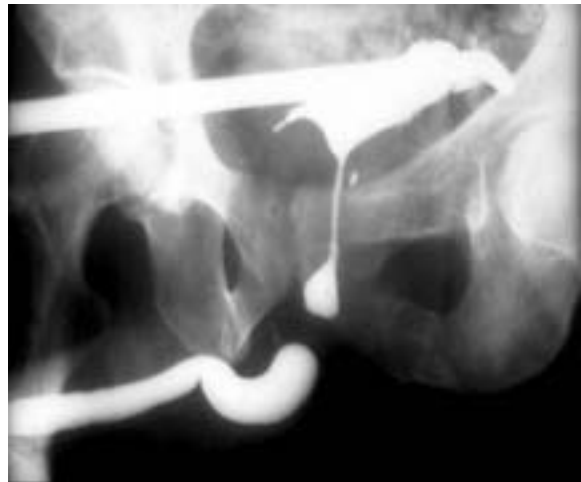

Fig. 15.9.11. After filling the bladder through the suprapubic tube with contrast material, the patient was asked to urinate, but the prostatic urethra was not filled up with contrast. A conventional cystoscope was introduced through the suprapubic tract, the bladder neck inspected and the posterior urethra filled by means of a ureteral catheter introduced into the prostatic urethra. This can be done also with a flexible cystoscope

After assessing the endoscopic appearance of the bladder neck, the flexible endoscope can be advanced through the bladder neck into the posterior urethra to the level of obstruction. If there is a question regarding the length of the distraction, a simultaneous retrograde

urethrogram can be performed while the endoscope is in the posterior urethra. The radiographic appearance of the bladder neck is important but not as reliable an indicator of continence as the endoscopic appearance. Furthermore, there are patients who, despite evidence of an open bladder neck or a scar at the bladder neck, will have acceptable continence after reconstruction. For this reason, concomitant bladder neck surgery at the time of urethral reconstruction is debatable (Iselin and Webster 1999; Jordan 1996).

Ultrasonography is not a routine investigation in the initial assessment of urethral injuries but can be very useful in determining the position of the pelvic hematomas and the high-riding bladder when a suprapubic catheter is indicated.

Computed tomography and MRI have no place in the initial assessment of urethral injuries. However, they are useful in defining the distorted pelvic anatomy after severe injury and assessing associated injuries of penile crura, bladder, kidneys, and intraabdominal organs (Dixon et al. 1992; Kane et al. 1989).

15.9.2.3

Endoscopic Examination

Urethroscopy has no role in the initial diagnosis of urethral trauma in males. In females, however, where the short urethra precludes adequate retrograde urethrography, urethroscopy is an important adjunct to the physical examination for the identification and staging of urethral injuries (McAninch 1992).

15.9.3

Management

The management of urethral injuries remains controversial due to the variety of injury patterns, associated injuries, and treatment options available. In addition, urethral injuries are relatively uncommon; hence the limited experience of most urologists worldwide and absence of randomized prospective studies.

15.9.3.1

Anterior Urethral Injuries

Blunt Injuries

Partial tears can be managed with a suprapubic catheter or with urethral catheterization. Suprapubic cystostomy has the advantage of not only diverting the urine away from the site of injury, but also avoiding urethral manipulation (Glassberg et al. 1979). In addition, it allows for a simultaneous study to be carried out at a later date. If the bladder is not easily palpable suprapubically, transabdominal sonography should be used to guide the placement of the catheter. The cystostomy tube is

maintained for approximately 4 weeks to allow urethral healing. Voiding cystourethrography is then performed and if normal voiding can be reestablished and no contrast extravasation nor subsequent stricture is present, then the tube can be safely removed.

The potential early complications of acute urethral injuries include strictures and infections. Extravasated blood or urine from the urethral tear produces an inflammatory reaction that can progress to the formation of an abscess. Extension of the infection depends on the fascial planes violated (see Sect. 15.9.2.1 above). Potential sequelae of these infections include urethrocutaneous fistulae, periurethral diverticula, and, rarely, necrotizing fasciitis. Prompt urinary diversion coupled with the appropriate administration of antibiotics decreases the incidence of these complications.

After the patient has adequately recovered from any associated injuries, and the urethral injury has stabilized, the urethra can be thoroughly reevaluated radiographically and, when necessary, the appropriate reconstructive procedure planned. Blunt anterior urethral injuries are associated with important spongiosa contusion, which makes it more difficult to evaluate the limits of urethral debridement in the acute phase. Therefore, acute or early urethroplasty is not indicated and the best management is simply suprapubic diversion. Satisfactory urethral luminal recanalization occurs in approximately 50% of partial anterior urethral disruptions (Cass and Godec 1978; Jackson and Williams 1974). Short and flimsy strictures can be managed with optical urethrotomy or urethral dilation. Denser strictures require formal urethral reconstruction. Anastomotic urethroplasty is indicated in strictures less than 1 cm in length.

Longer strictures of the anterior urethra should not be repaired by an end-to-end anastomosis to avoid chordee. In these cases, flap or graft urethroplasty is indicated. Almost all complete ruptures of the anterior urethra require anastomotic or patch urethroplasty at 3–6 months (Figs. 15.9.12, 15.9.13). The only exception to this is urethral injury associated with penile fracture, which usually results in partial urethral disruption and can be repaired at the time of cavernosal closure.

Open Injuries

Male Urethral Injuries

Stab wounds, gunshot wounds, and dog bites to the urethra often involve the penis and testes, necessitating immediate exploration (Figs. 15.9.5–15.9.7). During this procedure, the urethral injury can be surgically evaluated and repaired as needed, limiting subsequent stricture formation to less than 15% (Husmann et al. 1993).

Primary urethral suturing involves direct visualization of the severed urethral ends, with creation of a wa-

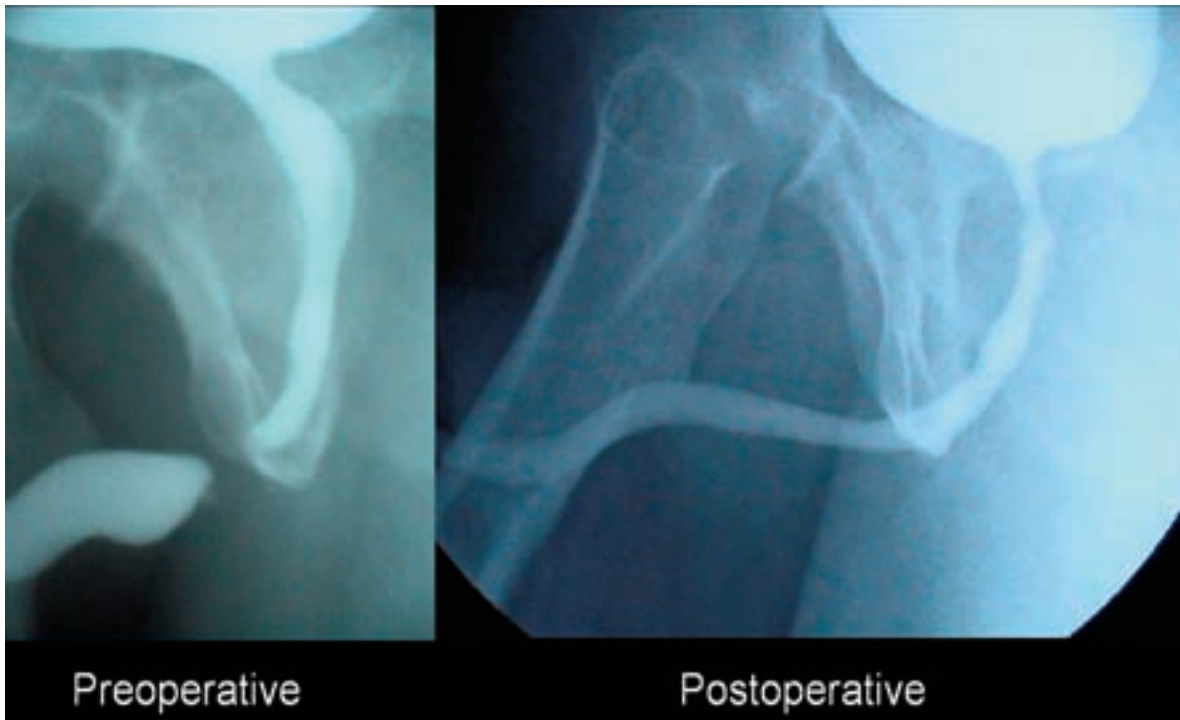


Fig. 15.9.12. Complete bulbar urethral stricture after a straddle injury. Result after delayed end-to-end anastomosis

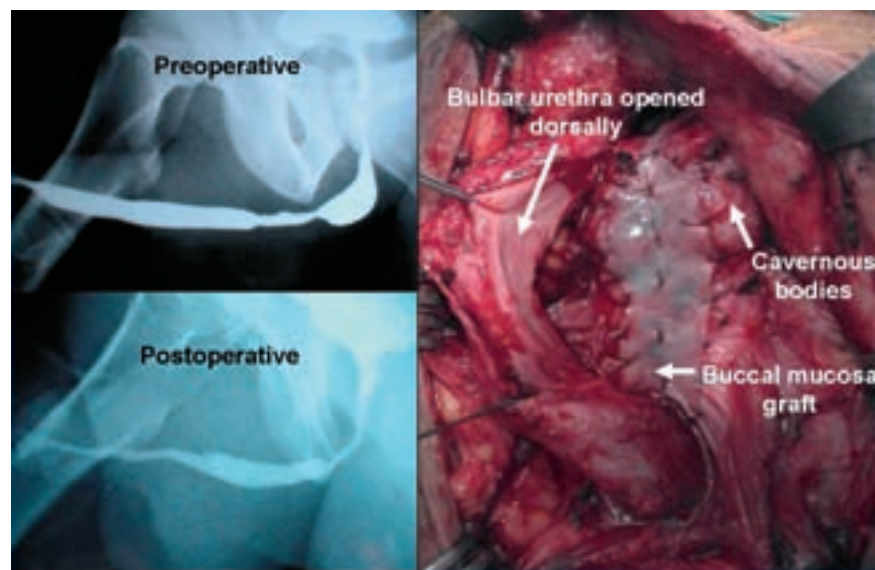


Fig. 15.9.13. Partial traumatic bulbar urethral stricture treated unsuccessfully with internal visual urethrotomy in another center. Dorsal buccal mucosa graft urethroplasty gave good results. The stricture is too long for an end-to-end urethroplasty

ter-tight, tension-free repair. The exposure is obtained using a circumferential subcoronal incision to deglove the penis with the patient in the supine position. In complete disruptions, the corpus spongiosum is mobilized at the level of the injury and the urethral ends dissected distally and proximally. Urethral ends are spatulated and end-to-end anastomosis is fashioned over a 14-F Foley catheter. Small lacerations can be sutured with fine absorbable material. Attention is directed to

overclosure of the corpus spongiosum and overlying tissues to minimize subsequent fistulae formation (Chapple and Png 1999). Urethral debridement should be kept to a minimum since the vascular characteristics of the corpus spongiosum will permit excellent healing with a properly performed urethrospongiosal repair.

Perioperative prophylactic antibiotics should be used to avoid infections. At 10 days to 2 weeks, a cystourethrogram should be obtained with the urethral cath-

ter in situ. Provided there is no leakage at the anastomotic site, the urethral catheter can be removed. If there is leakage, then the catheter is left longer and the cystourethrogram should be repeated 1 week later.

If at the time of initial exploration, the urethra is found to be so extensively disrupted that primary anastomosis is not feasible – this occurs with defects over 1–1.5 cm length – the procedure should be aborted. The surgeon should marsupialize the urethra preparatory to a two-stage urethral repair with proximal suprapubic urinary diversion. A delayed elective procedure is usually carried out after a minimum of 3 months after injury. There is no role for urethral substitution, with either a graft or flap, in the initial management of any urethral injury, since contamination or decreased blood supply can compromise such a repair (Armenakas and McAninch 1996).

Female Urethral Injuries

Most female urethral disruptions can be sutured primarily. This is because these injuries occur more frequently in association with bladder ruptures, necessitating prompt exploration. For proximal urethral injuries, urethral exposure is best obtained transvesically, permitting direct visualization of the bladder, bladder neck, and proximal urethra. Distal urethral injuries can be approached via the vaginal route (Koraitim 1999). Early repair of posttraumatic urethral fistulas can be accomplished using a transvaginal approach (Hemal et al. 2000; Perry and Husmann 1992).

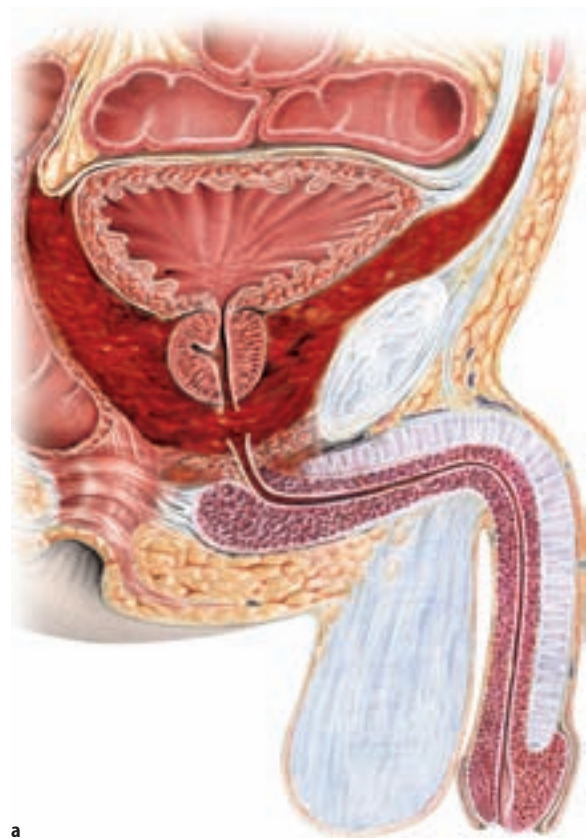
15.9.3.2

Posterior Urethral Injuries

It is important to make a distinction between posterior urethral stricture and a subprostatic pelvic fracture urethral distraction defect, as the principles of their surgical management are entirely different. Urethral stricture should be used to indicate a narrowing of the urethral continuity, such as sphincter strictures due to instrumentation or partial urethral tears. In subprostatic complete urethral fractures, a urethral distraction defect exists and there is a gap between the prostatic apex or membranous urethra and the bulbar urethral end. The dismembered end of the urethra retracts and the space between them is filled with fibrous tissue, resulting from organization and healing of the hematoma and urinary extravasation. There is no urethral wall in the scarred space and any lumen represents merely a fistulous tract between the urethral ends. A further difference with inflammatory strictures is that urethral ends, regardless of the length of the distraction defect, present very limited fibrosis and when reanastomosed without tension, usually heal with little potential for restricturing (Fig. 15.9.14) (Martínez-Piñero et al. 1997).

Erectile dysfunction occurs in 20%–60% of patients after traumatic posterior urethral rupture. (Corriere 2001; Dhabuwala et al. 1990; Gibson 1970; King 1975; Martínez-Piñero et al. 1997). Available data suggest that the severity of the initial injury is the most important determining factor associated with impotence. Only 5% of complete erectile dysfunction follows as a consequence of open surgical repair (Martínez-Piñero et al. 1997; Webster 1990). King reported an incidence of 42% in cases of pelvic fracture and urethral injury, but only 5% when the urethra was not injured (King 1975). Barbagli et al. reported an incidence of 60% in patients with posterior urethral injury compared with 14% in patients with bulbar injury (Barbagli et al. 1987).

Factors that correlate with the development of impotence are age, defect length, and the type of fracture; bilateral pubic rami fractures are the most frequent cause of impotence, which is almost always of neurogenic etiology due to bilateral damage of the cavernous nerves at the prostatomembranous urethra behind the symphysis pubis (Mark et al. 1995). Associated vasculogenic erectile failure may occur in up to 80% of cases (Armenakas et al. 1993). Dixon et al. presented evidence that impotence may also be a consequence of avulsion



a

Fig. 15.9.14a, b. Difference between urethral distraction defect and urethral stricture. **a** Urethral distraction defect

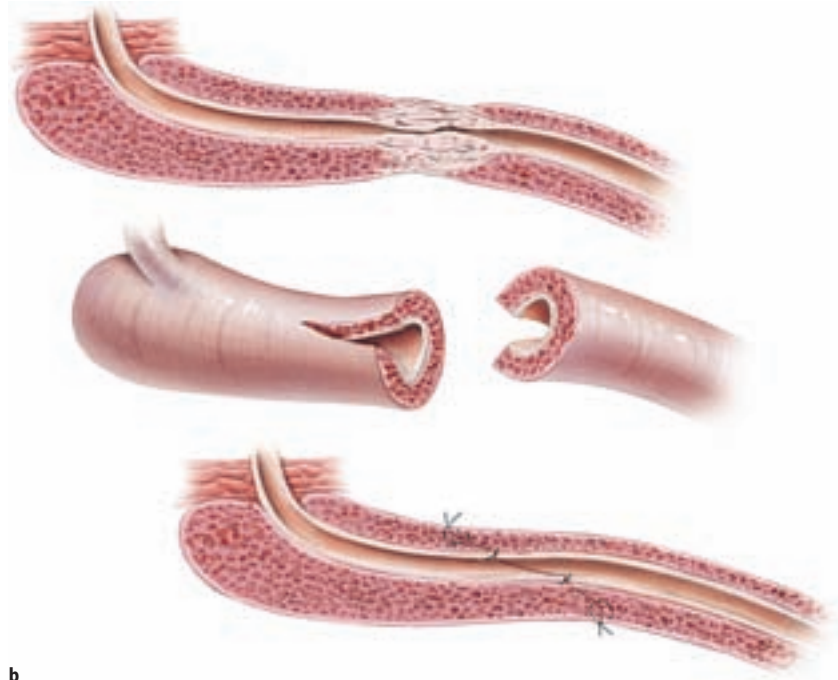

Fig. 15.9.14b. Urethral stricture
(© Hohenfellner 2007)

b

of the corpora cavernosa from the ischium (Dixon et al. 1992). Five of six patients in this series, with avulsion of the corpora cavernosa off the inferior pubic ramus, were impotent. Spontaneous return of potency may occur up to 2 years after injury (McAninch 1996). Gibson reported an incidence of improved sexual function after 18 months in 21 % of patients (Gibson 1970).

Partial Urethral Rupture

Partial tears of the posterior urethra can be managed in most cases with a suprapubic or urethral catheter and repeat retrograde urethrography at 2-week intervals until healing has occurred (Koraitim 1999; Venn and Mundy 1998). They may heal without significant scarring or obstruction if managed by diversion alone (Glassberg et al. 1979; Kielb et al. 2001). Any residual or subsequent stricture can be managed with urethral dilation or optical urethrotomy, if short and flimsy, or by anastomotic urethroplasty if denser (Chapple and Png 1999; Venn and Mundy 1998).

Complete Urethral Rupture

The treatment options available include primary realignment, immediate open urethroplasty, delayed primary urethroplasty, delayed urethroplasty, and delayed endoscopic incision.

Primary Realignment

Urethral realignment can be achieved either transpubically (open realignment) or with endoscopic techniques (endoscopic realignment).

Primary Open Realignment

In posterior urethral injuries associated with concomitant bladder neck or rectal injuries, immediate open exploration, repair and urethral realignment is advisable. Bladder neck injury risks incontinence and infection of the pelvic fractures. Rectal injury carries the obvious risk of sepsis and fistula, and early exploration is indicated to evacuate contaminated hematoma and perform colostomy. Urethral realignment over a stenting catheter is appropriate in such cases (Antoci and Schiff 1982; Berman and Tom 1974; Koraitim 1999; Muhlbaier and Bard 1980; Turner-Warwick 1989).

Primary Endoscopic Realignment

The overall condition of the patient and the extent of associated injuries greatly affect the decision to proceed with primary endoscopic realignment. Most patients with pelvic crush injuries have multiple organ injuries. Associated lower extremity fractures can prevent placement in the lithotomy position, which is often required for primary endoscopic realignment, while head injuries increase the adverse risks of anesthesia. If these conditions are controlled, such that a hemodynamically stable patient can safely undergo a lengthier anesthesia and can be placed in the lithotomy

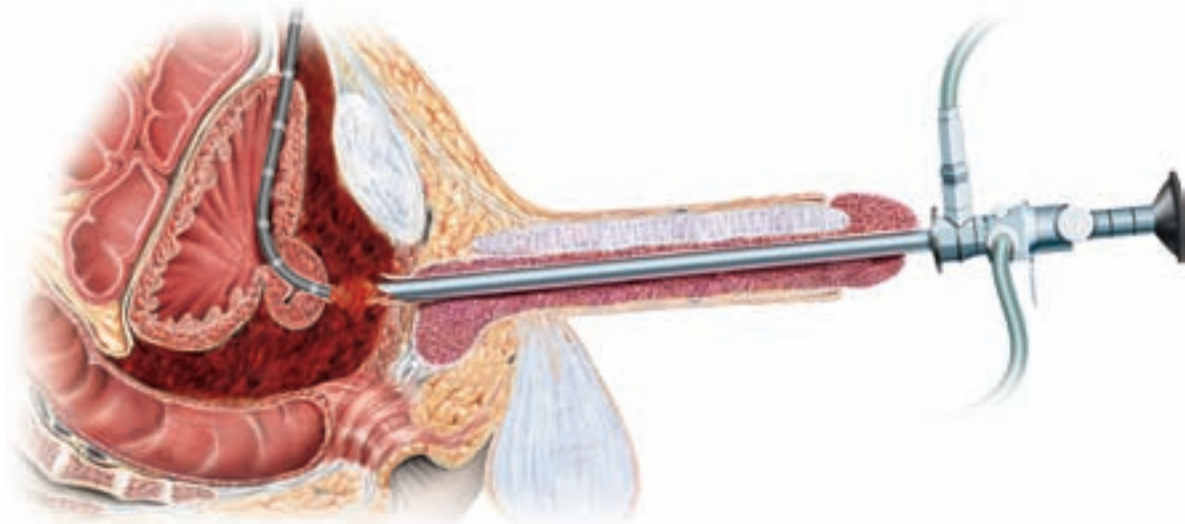


Fig. 15.9.15. Endoscopic realignment in posterior urethral distraction defect by means of a flexible and rigid cystoscope (© Hohenfellner 2007)

position, endoscopic urethral realignment may be considered during the first 2 weeks after trauma (Fig. 15.9.15).

The proposed benefits of primary open or endoscopic alignment follow:

1. There is a lower stricture rate than with suprapubic catheter placement alone (69% vs 10%) (Webster et al. 1983). This avoids a second operation for urethral reconstruction in about one-third of patients (Dixon 1996).
2. If scarring occurs, restoration of urethral continuity is simplified and may be accomplished by endoscopic procedures or dilation.
3. If a urethroplasty is required later, it is technically easier when the prostate and urethra are well aligned.

The disadvantage of open realignment may be a higher incidence of erectile dysfunction and incontinence when compared to delayed reconstruction (Koraitim 1996; Webster et al. 1983). Webster studied 301 patients from 15 series in which primary realignment (open and endourologic) was used, and compared the incontinence, impotence, and stricture rates to those in 236 patients from five series, in which cystostomy and delayed repair was performed (Webster et al. 1983). In this series, primary realignment was performed with different endourologic and open techniques and cannot be used as a valid comparison between open and endoscopic primary realignment. Overall, impotence occurred in 44% of patients treated with primary alignment compared with 11% of patients treated with delayed repair. Incontinence was also higher after primary alignment (20% vs 2%). Stricture rates after cystostomy tube placement approach 100%, whereas after

primary realignment, strictures occurred in 64% of patients. In most cases of delayed repair, a stricture-free anastomosis can be achieved with success rates greater than 90% (Coffield and Weems 1977; McAninch 198; Morehouse and Mackinnon 1980; Webster 1989; Webster et al. 1983). In an extensive review of the English literature for the last 50 years, Koraitim came to a similar conclusion. Primary realignment was found to double the incidence of impotence (36% vs 19%) and to have the incidence of stricture compared to suprapubic cystostomy and delayed repair (53% vs 97%) (Koraitim 1999). The implication was that primary realignment led to higher impotence and incontinence rates because of iatrogenic factors and thus should be avoided.

However, the series of primary realignment reviewed by Webster and Koraitim encompassed a number of techniques (open and endourologic), which may explain the poor results of their analysis, compared with those reported by other authors (Elliott and Barret 1997). Recent publications show that the injury itself and not the type of management is probably responsible for the loss of potency and continence after urethral trauma (Asci et al. 1999; Husmann et al. 1990; McAninch 1997; Morey and McAninch 1997). Elliott and Barret (1997) have reported on a series of 57 patients who underwent primary endoscopic urethral realignment, with a mean follow-up of 10.5 years: 21% had some degree of erectile dysfunction, 3.7% had mild stress incontinence, 68% had postalignment strictures. The effects on continence and potency with immediate endourologic realignment following urethral disruption were also reviewed by Kotkin and Koch (1996) in 20 nearly case-matched patients with posterior urethral injuries treated by primary surgical realignment

or catheter placement. Continence was preserved in 83% and 80% of patients, respectively, while erectile function returned in 76% and 70%, respectively. A recent series reported by Mouraviev et al. (2005) has also shown a lower incidence of impotence and incontinence in patients treated with early realignment than with delayed open reconstruction.

The great variation of techniques used in the past for primary realignment procedures confuses any comparison with delayed repair procedures (Follis et al. 1992; Herschorn et al. 1992; Porter et al. 1997). Primary realignment techniques have included:

- Simple passage of a catheter across the defect (Herschorn et al. 1992)
- Endoscopically assisted catheter realignment using flexible, rigid endoscopes and biplanar fluoroscopy (Gelbard et al. 1989; Guille et al. 1991)
- Use of interlocking sounds ("railroading") or magnetic catheters to place the catheter (Porter et al. 1997)
- Pelvic hematoma evacuation and dissection of the prostatic apex (with or without suture anastomosis) over a catheter
- Catheter traction or perineal traction sutures to pull the prostate back to its normal location (Turner-Warwick 1977)

Realignment, even with traction, may be insufficient to join completely the margins of the severed urethra and 1.5- to 4-cm defects have been observed (Ragde and

McInnes 1969). This finding agrees with experimental animal data, which show that when the urethra is transected and apparently good urethral junction is achieved by catheter traction, there is no evidence of epithelialization of the mucosal gap but rather that the intervening area is filled with fibrous tissue (McRoberts and Radge 1970). Moreover, sustained traction on the balloon catheter has been noted to damage the only remaining sphincter mechanism at the bladder neck from pressure necrosis (Dixon 1996; Turner-Warwick 1989). If series that use true immediate urethral realignment with minimal traction and without suture repair bolsters only are included, the results with immediate realignment are much more favorable (Table 15.9.5).

This type of summary of the literature suggests that immediate realignment is associated with an impotence rate of approximately 35%, an incontinence rate of 5%, and a resticture rate of 60%.

Immediate Open Urethroplasty (<48 h After Injury)

Immediate open urethroplasty of posterior injuries is not indicated because of poor visualization and the inability to assess accurately the degree of urethral disruption during the acute phase, characterized by extensive swelling and ecchymosis. The difficulty in identifying structures and planes hamper adequate mobilization and subsequent surgical apposition (Chapple and Png 1999). Incontinence and impotence rates are high-

Table 15.9.5. Results of immediate realignment in complete urethral disruption

Series	No. of patients	Follow-up months (range)	Erectile dysfunction N (%)	Incontinence N (%)	Resticture rate N (%) ^a
Gibson 1974	35 ^b	NA	12 (34)	1 (3)	26 (74.3)
Crassweller et al. 1977	38	24–240	19/42 (45)	NA	12 (31.6)
Malek et al. 1977 ^c	7	168 (96–264)	0	0	1 (14.3)
Gelbard et al. 1989	7	10.2 (2–24)	1/6 (16.7)	0	2 (33)
Cohen et al. 1991	4	28 (17–35)	2 (50)	0	2 (50)
Melekos et al. 1992	4	NA	0	0	4 (100)
Follis et al. 1992	20	42 (1–36)	4 (20)	2 (10)	12 (60)
El-Abd 1995	44	NA	35 (79.5)	0	44 (100)
Gheiler and Frontera 1997	3	6 (5–9)	0	0	1 (33.3)
Londergan et al. 1997	4	20.2 (12–35)	1 (25)	0	3 (75%)
Elliott and Barret 1997	53	126 (1–>120)	11 (21)	2 (3.8)	36 (68)
Porter et al. 1997	10	10.9 (2–31)	1/7 (14)	0	5 (50)
Rehman et al. 1998	3	(11–26)	1 (16.7)	0	2 (66.7)
Sahin et al. 1998	5	31 (21–53)	1 (20)	1 (20)	4 (80)
Tahan et al. 1999	13	29	3 (23)	0	5 (38.5)
Jepson et al. 1999	8	50.4 (35–85)	3 (37.5)	1 (12.5)	5 (62.5)
Asci et al. 1999	20	39 (19–78)	4 (20)	2 (10)	9 (45)
Ying-Hao et al. 2000	4	56 (39–85)	0	0	1 (25)
Moudouni et al. 2001	23	68 (18–155)	4/29 (14)	0	16 (69.5)
Mouraviev et al. 2005	57	<24 (2–15)	19/57 (34)	10/57 (10)	28/57 (49)
Totals	362		130/368 (35.3)^d	19/362 (5.2)	218/362 (60.2)

^a Stricture that requires internal urethrotomy or open urethroplasty or more than 1 dilation

^b Five patients with partial rupture, ^c Children, ^d Some partial ruptures included

er than with the other techniques described in this chapter (impotence 56%, incontinence 21%, stricture 49%) (Cass and Godec 1978; Koraitim 1996, 1999; Mundy 1991; Webster et al. 1983; Weems 1979).

Delayed Primary Urethroplasty (2–14 Days After Injury)

The management of complete posterior rupture of the urethra has changed in recent years. There is now more active orthopedic management of pelvic fractures with immediate external and internal fixation, and this has led to an option for early repairs of urethral injuries (Venn and Mundy 1998).

In the absence of indications for immediate exploration, the management of posterior urethral disruption can be in a delayed primary fashion. The delayed primary approach requires placement of a suprapubic tube at the time of initial injury, with repair undertaken when the patient is stable, usually within 10–14 days. This is a time when patients are stable and most pelvic bleeding has resolved. The aim of the delayed primary repair is to correct severe distraction injuries rather than to prevent a stricture occurring; however, it will also ensure that if it does occur it is easily treatable (Mundy 1991). Hematomas preventing adequate pelvic descent can be evacuated at this point. Repair at this time can be performed endoscopically, as well as through an abdominal or perineal approach (Cohen et al. 1991; Mundy 1991). Urethral repairs using one-stage perineal anastomotic urethroplasty offer a stricture-free rate of 80% (Mundy 1996). The progressive perineal technique usually employed in a delayed fashion after 3 or more months of suprapubic drainage is equally useful in the immediate postinjury period for delayed primary repair if the patient is able to tolerate the lithotomy position.

In female urethral disruption, delayed primary urethroplasty is probably the best approach, though no large experience exists. Fewer than 50 cases have been reported so far, with most reports being simple case reports (Hemal et al. 2000). Delayed primary repair tries to preserve as much urethral length as possible and to avoid the urethra being embedded in dense scar, thus trying to avoid subsequent incontinence. Surgical exploration should be attempted via the retropubic route for proximal injuries and the vaginal route for distal injuries (Koraitim 1999).

Delayed Urethroplasty (3–6 Months After Trauma)

The most common end result of a subprostatic urethral injury managed by delayed repair is the development of a relatively short prostatobulbar urethral gap. Such a simple short gap defect can generally be resolved by a relatively simple perineal approach anastomotic repair, provided that it is not associated with extensive hema-

toma and fibrosis and the bladder neck mechanism is occlusive and competent.

After division of the bulbar urethra at the distal point of obliteration, mobilization of a normal bulbar urethra to the base of the penis generally achieves 4–5 cm of elastic lengthening. This is usually sufficient to achieve a tension-free, 2 cm spatulated overlap anastomosis with the apical prostatic urethra, after bridging a gap of 2–2.5 cm without rerouting (Chapple and Png 1999).

This technique has the advantage that most associated injuries and damaged skin and tissues, in addition to the pelvic hematoma, have resolved by the time it is performed. The only problem with this approach would be the length of the period that the patient must have a suprapubic catheter before definitive treatment.

When the prostatobulbar gap is longer than 2–3 cm as a result of a high dislocation of the prostate, or when the available elongation of the mobilized urethra has been foreshortened by damage caused by a previous surgical procedure, the following maneuvers are carried out sequentially to gain sufficient anterior urethral mobility to bridge up to 8 cm of separation (Mark and Webster 1996; Webster and Ramon 1991): midline separation of the proximal corporal bodies, inferior pubectomy and supracorporal urethral rerouting (Fig. 15.9.16).

In addition to its use as initial therapy for posterior urethral distraction injuries, the progressive perineal approach can be applied successfully to salvage procedures following failed repair. There are a number of circumstances that may preclude successful perineal anastomotic repair as either initial or salvage therapy. This group probably represents less than 5% of cases and includes the following (Mark and Webster 1996; Webster 1987; Webster et al. 1990):

Distraction Defects Longer than 7–8 cm. A tubed interposition flap of penile or perineoscrotal skin can be used for reconstruction.

Fistulae. These may require a combined abdominoperineal approach to secure adequate closure.

Synchronous Anterior Urethral Stricture. The presence of associated spongiofibrosis in the anterior urethra may compromise the blood supply to the bulbar urethra following division of the bulbar arteries.

Urinary Incontinence. As the distal urethral sphincter mechanism is usually defunctionalized by urethral distraction, urinary continence must be maintained primarily by the proximal bladder neck sphincter. Concomitant bladder neck injury with the likelihood of incontinence may warrant a combined abdominoperineal procedure to enable simultaneous bladder neck and

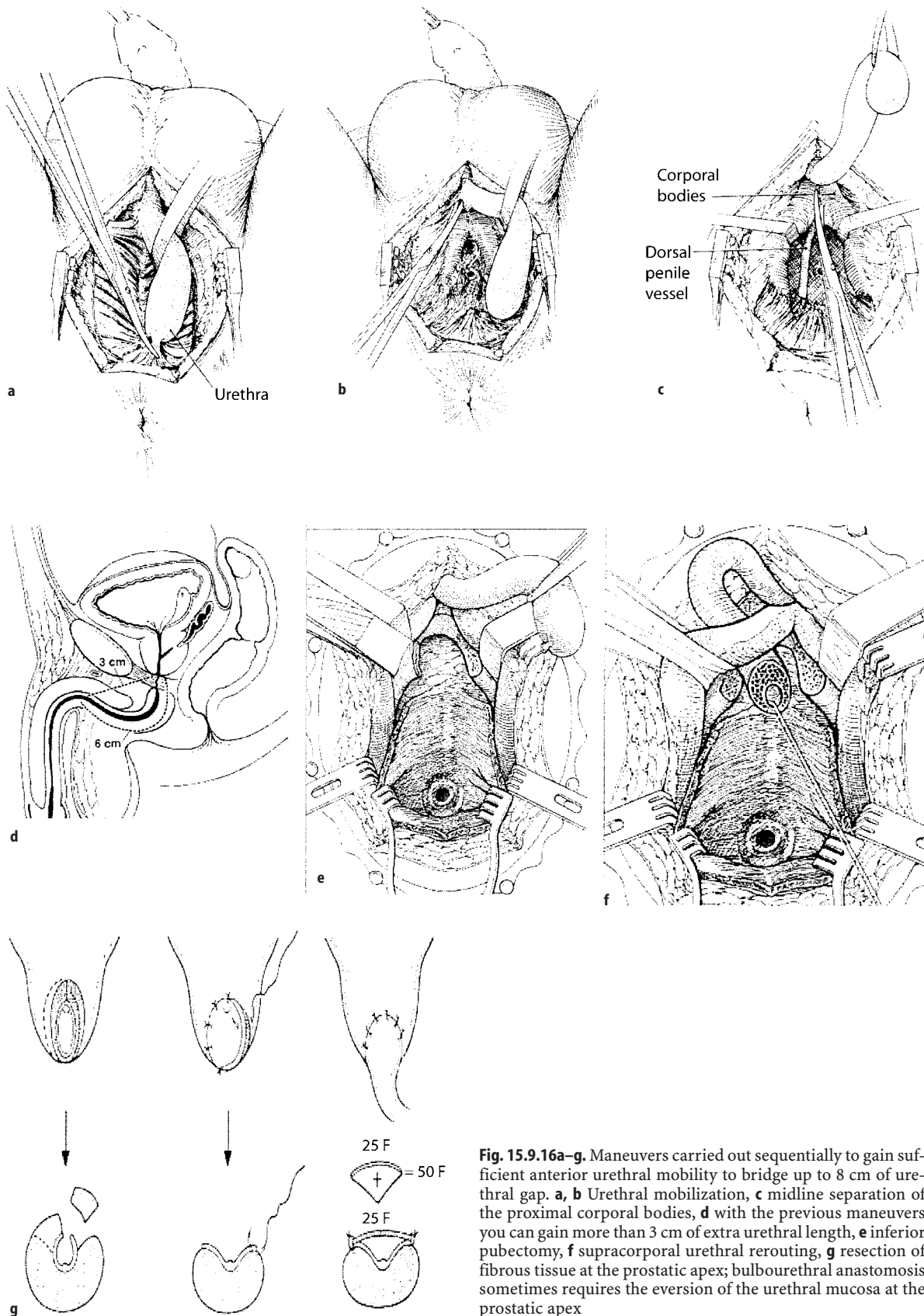


Fig. 15.9.16a–g. Maneuvers carried out sequentially to gain sufficient anterior urethral mobility to bridge up to 8 cm of urethral gap. **a, b** Urethral mobilization, **c** midline separation of the proximal corporal bodies, **d** with the previous maneuvers you can gain more than 3 cm of extra urethral length, **e** inferior pubectomy, **f** supracorporal urethral rerouting, **g** resection of fibrous tissue at the prostatic apex; bulbourethral anastomosis sometimes requires the eversion of the urethral mucosa at the prostatic apex

urethral reconstruction. The most common cause of bladder neck incompetence is the circumferential tethering of an uninjured mechanism by the natural shrinkage or replacement of an extensive pelvic floor hematoma by fibrosis. In such cases, it is usually possible to restore functional competence of the bladder neck by mobilizing it meticulously. This can be accomplished by removal of the dense hematoma/fibrosis anchoring the bladder neck to the pubis, anteriorly and laterally, and prevention of secondary fibrotic reimmobilization by occluding the consequent paraprostatic dead-space cavity with a supple omental pedicle graft, thus preserving the functional mobility of the liberated sphincter mechanism (Iselin and Webster 1999; MacDiarmid et al. 1995).

The results of various techniques are reviewed by Koraitim (1996) in a personal series of 100 patients combined with a review of 771 patients from published reports. Immediate and early realignment ($n = 326$) was associated with a 53 % stricture rate, a 5 % incontinence rate, and a 36 % impotence rate. Of the patients successfully managed with immediate realignment, 42 % needed subsequent instrumentation to attempt stricture stabilization. Urethroplasty was ultimately necessary in 33 %. Primary suturing ($n = 37$) was associated with a 49 % stricture rate, a 21 % incontinence rate, and a 56 % impotence rate. In comparison, inserting a suprapubic catheter before delayed repair ($n = 508$) was associated with a 97 % stricture rate, a 4 % incontinence rate, and a 19 % impotence rate. The restricture rate after delayed anastomotic urethroplasty was less than 10 % (Corriere 2001; Jordan 1996; Koraitim 1997; Martínez-Piñero et al. 1997; Mundy 1993, 1996; Santucci et al. 2002; Zinman 1997), and the risk of impotence caused by delayed urethroplasty was approximately 5 % (Corriere 2001; Corriere et al. 1994; Fiala et al. 2001; Koraitim 1995, 1996; Martínez-Piñero et al. 1997; Mundy 1996; Webster 1990). On the basis of such results, it is evident that the gold standard remains delayed urethral repair at a minimum of 3 months after trauma, using a one-stage perineal approach.

In children, similar results are obtained as in adults (Podesta et al. 2005); the higher incidence of abdominal surgery simply reflects the greater propensity to damage of the bladder neck in children.

Reconstruction of Failed Repair of Posterior Urethral Rupture

When restenosis occurs after delayed urethral repair, it is identified usually within 6 months. If the anastomosis has a normal caliber at 6 months, then it is extremely unlikely that the patient will develop further stricturing (Mundy 1996).

The principles of a salvage repair are similar to those of the initial procedure. Progressive perineal anasto-

motomic repair alone can be successful in 95 % of salvage urethroplasties. If an anastomotic repair cannot be performed, a one-stage substitution urethroplasty using a pedicle island of penile skin may be possible and may be more desirable than the final alternative, a two-stage scrotourethral inlay procedure or mesh split-thickness skin graft urethroplasty (Mark and Webster 1996; Wadhwa et al. 1998). The presence of fistulous tracts to the bladder base, abdominal wall, or rectum; periurethral epithelialized cavities; and an ability to achieve the lithotomy position are the leading indications for a combined abdominoperineal surgical approach (Webster et al. 1990).

Restenosis to a luminal caliber of 12-F Foley catheter or less is required before a reduction in the urinary flow is perceived as abnormal (Smith 1968). A wide-caliber stricture may be followed expectantly or gently dilated. Optical urethrotomy is an alternative, particularly for a short, narrow stricture.

Delayed Endoscopic Optical Incision

The principles of the procedure were described by Sachse in 1974 (Sachse 1974). A curved metal sound was passed through the suprapubic cystostomy into the blindly ending proximal urethra, the direct vision urethrotome was inserted into the urethra, and cuts were made toward the sound. Blandy subsequently described the suprapubic passage of a cystoscope for transillumination of the thin perineal membrane associated with short urethral defects and transurethral "cutting to the light" with an electrode (Fig. 15.9.17) (Blandy 1980). Today, the cut-to-the-light technique is performed more effectively using c-arm fluoroscopy for stereotactic guidance. The urethral catheter is left in place for between 1 and 3 weeks, and the suprapubic drainage for 2 additional weeks to confirm consistent voiding (Lieberman and Barry 1982).

Results of several small series have been reported and are summarized in Table 15.9.6.

The procedure is only indicated if the urethral defect is short, the bladder neck is competent, and there is minimal displacement of the prostate and proximal bulbous urethra (Barry 1989). Although restoration of urethral continuity is common, and potency is not affected by the procedure, urethral dilation, repeat optical urethrotomy, and transurethral resection of stricture are common and will be required in about 80 % of patients. Most repeat urethrotomies are performed in the 1st year of follow-up. It should be noted that after failure of the initial urethrotomy, alternative treatments should be considered, as repeat urethrotomy achieves only temporary improvement (Pansadoro and Emiliozzi 1996). Urethral false passage and rectal perforation have been reported (De Vries and Anderson 1990; Gupta and Gill 1986; Yasuda et al. 1991). Stents are

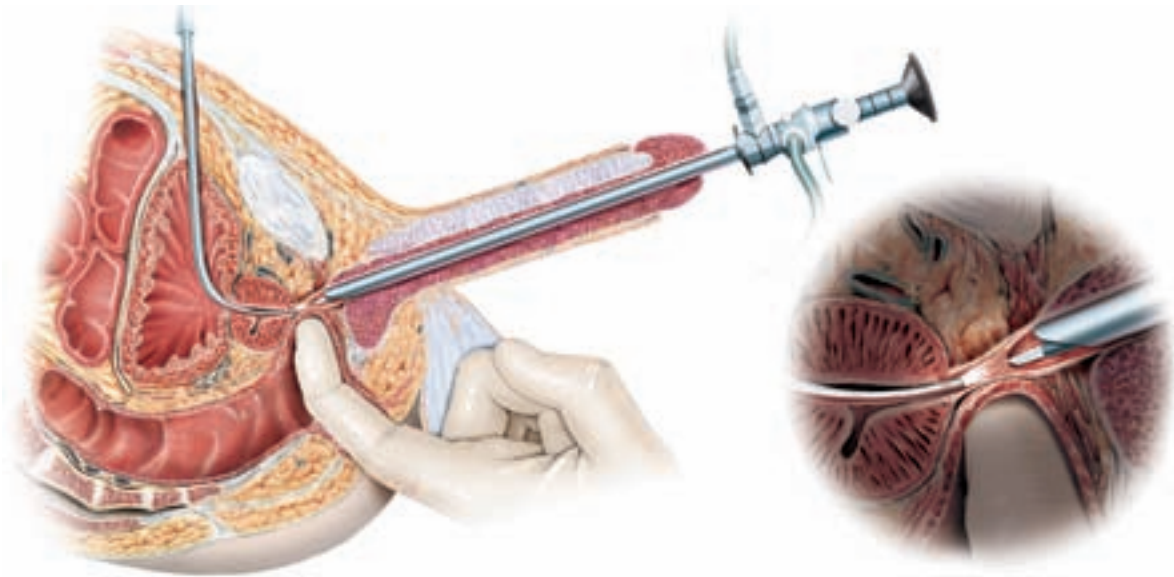


Fig. 15.9.17. Transurethral cutting-to-the-light procedure (© Hohenfellner 2007)

Table 15.9.6. Results of optical urethrotomy for traumatically obliterated pelvic urethra

Series	No. patients	Follow-up months (range)	No. (%) requiring repeat urethrotomy	Erectile dysfunction
Gupta and Gill 1986	10	15.1 (6–24)	10 (100)	0
Chiou et al. 1988	8	43 (12–79)	7 (87.5)	0
Marshall 1989	10	NA	10 (100)	0
Barry 1989	12	22 (1.5–85)	6 (50)	0
DeVries and Anderson 1990	4	<4	1 (25)	0
Leonard et al. 1990	3	31 (13–51)	1 (33.3)	0
Kernohan et al. 1991	7	35 (21–84)	7 (100)	0
Yasuda et al. 1991	17	44 (12–96)	7 (41.2)	0
Quint & Staniscic 1993	10	43 (7–108)	6 (60)	0
El-Abd 1995	284	NA	272 (95.8)	0
Goel et al. 1997	13	17.7 (11–24)	10 (76.9)	NA
Levine and Wessells 2001	6	60	6 (100)	NA
Dogra and Nabi 2002 ^a	61	30 (9–44)	11 (18)	NA
Totals	445		354 (79.5)	

^a Laser urethrotomy

not currently recommended for patients with strictures following pelvic trauma, as fibrotic tissue tends to grow through into the lumen of the stent (Baert et al. 1993; Jordan 1996; Milroy et al. 1989; Williams 1993).

15.9.4 Recommendations for Treatment: Algorithms

The optimal management of patients with prostatomembranous disruptions should not be thought of as delayed repair vs other types of treatment modalities. Each patient should be assessed and managed according to the initial clinical circumstances. It is impractical to suggest that all patients be managed by one single method, due to the variability of cases and the severity

of associated injuries. The intervention should be guided by the clinical circumstances. The following algorithms taken from the European Association of Urology Guidelines (Lynch et al. 2005) are suggested for the treatment of urethral injuries in males and females (Figs. 15.9.18–15.9.20).

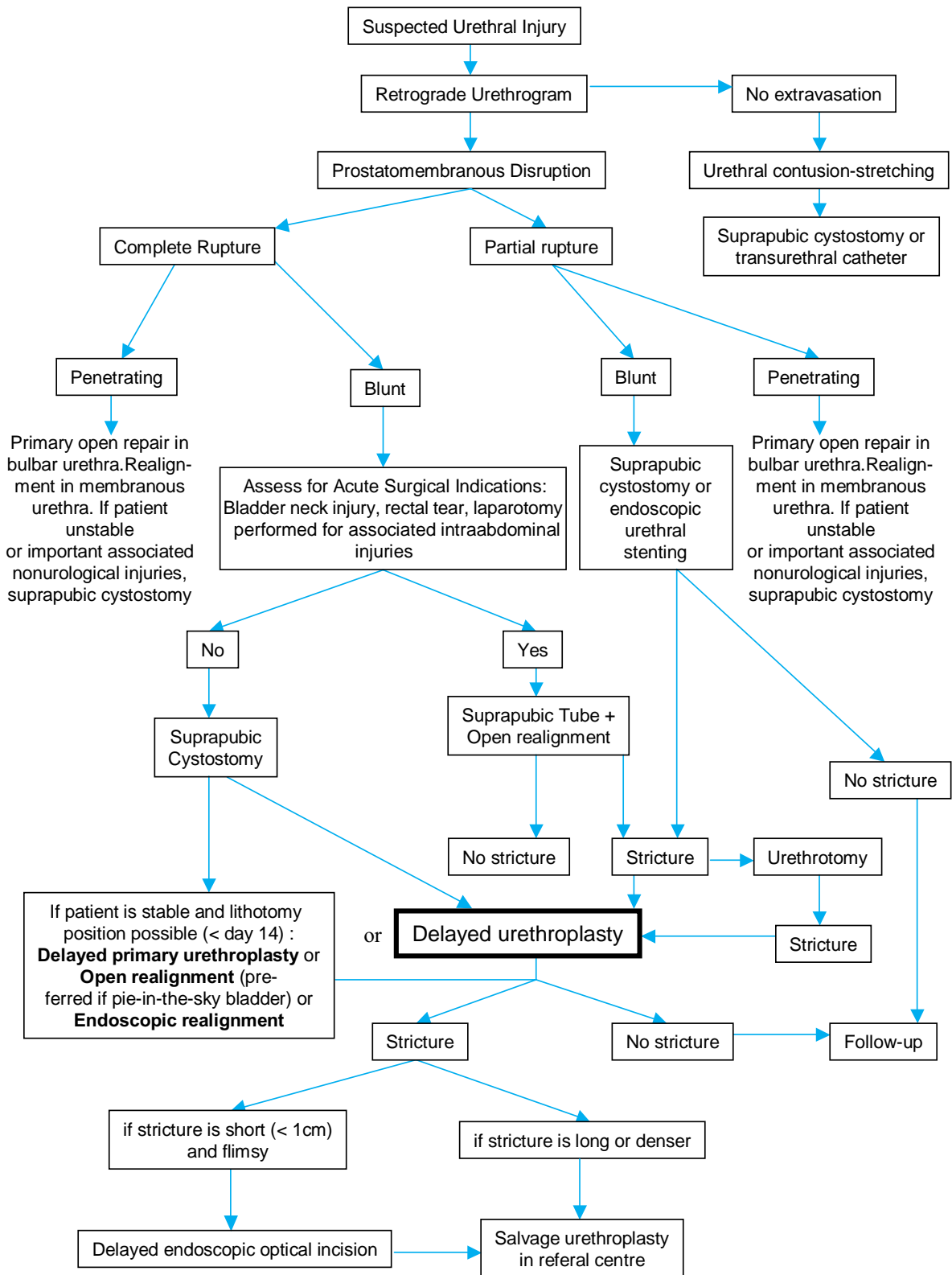


Fig. 15.9.18. Management of posterior urethral injuries in men

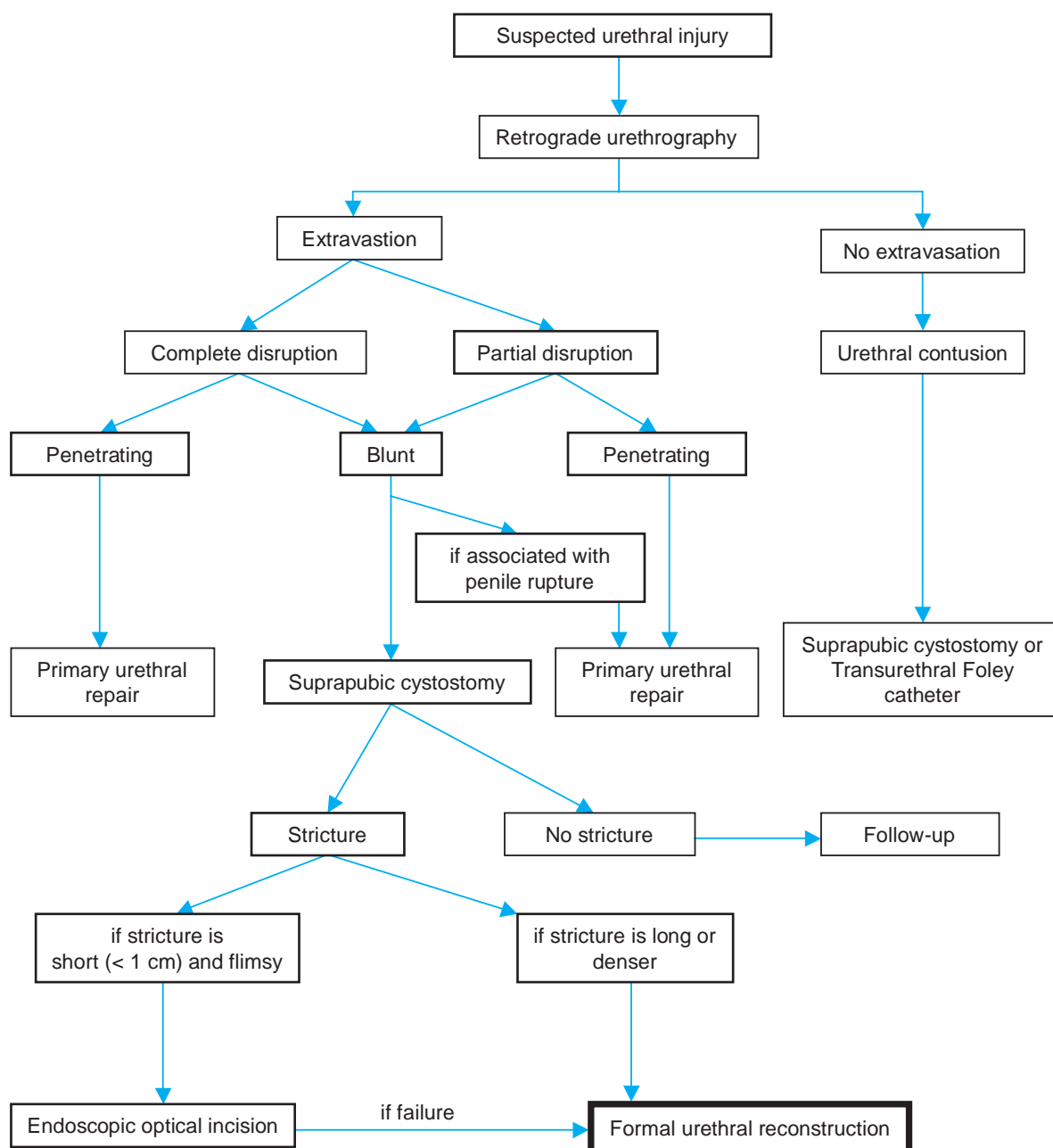


Fig. 15.9.19. Management of anterior urethral injuries in men

References

- Antoci JP, Schiff MJ (1982) Bladder and urethral injuries in patients with pelvic fractures. *J Urol* 128:25
- Armenakas NA, McAninch JW (1994) A uniform approach to urethroplasty. *Prob Urology* 8:254
- Armenakas NA, McAninch JW (1996) Acute anterior urethral injuries. In: McAninch JW (ed) *Traumatic and reconstructive urology*. WB Saunders Philadelphia, p 543
- Armenakas NA, McAninch JW, Lue TF, Dixon CM (1993) Post-traumatic impotence: MRI and duplex ultrasound in diagnosis and management. *J Urol* 149:1272

- Asci R, Sarikaya S, Buyukalpelli R, Saylik A, Yilmaz AF, Yildiz S (1999) Voiding and sexual dysfunctions after pelvic fracture urethra injuries treated with either initial cystostomy and delayed urethroplasty or immediate primary urethral realignment. *Scand J Urol Nephrol* 33:228
- Baert L, Verhamme L, Poppel Hv Vandeursen H, Baert J (1993) Long term consequences of urethral stents. *J Urol* 150:853
- Barbagli G, Selli C, Stomaci N, Delle-Rose A, Trippitelli A, Lenzi R (1987) Urethral trauma: radiological aspects and treatment options. *J Trauma* 27:256
- Barry JM (1989) Visual urethrotomy in the management of the obliterated membranous urethra. *Urol Clin North Am* 16:319

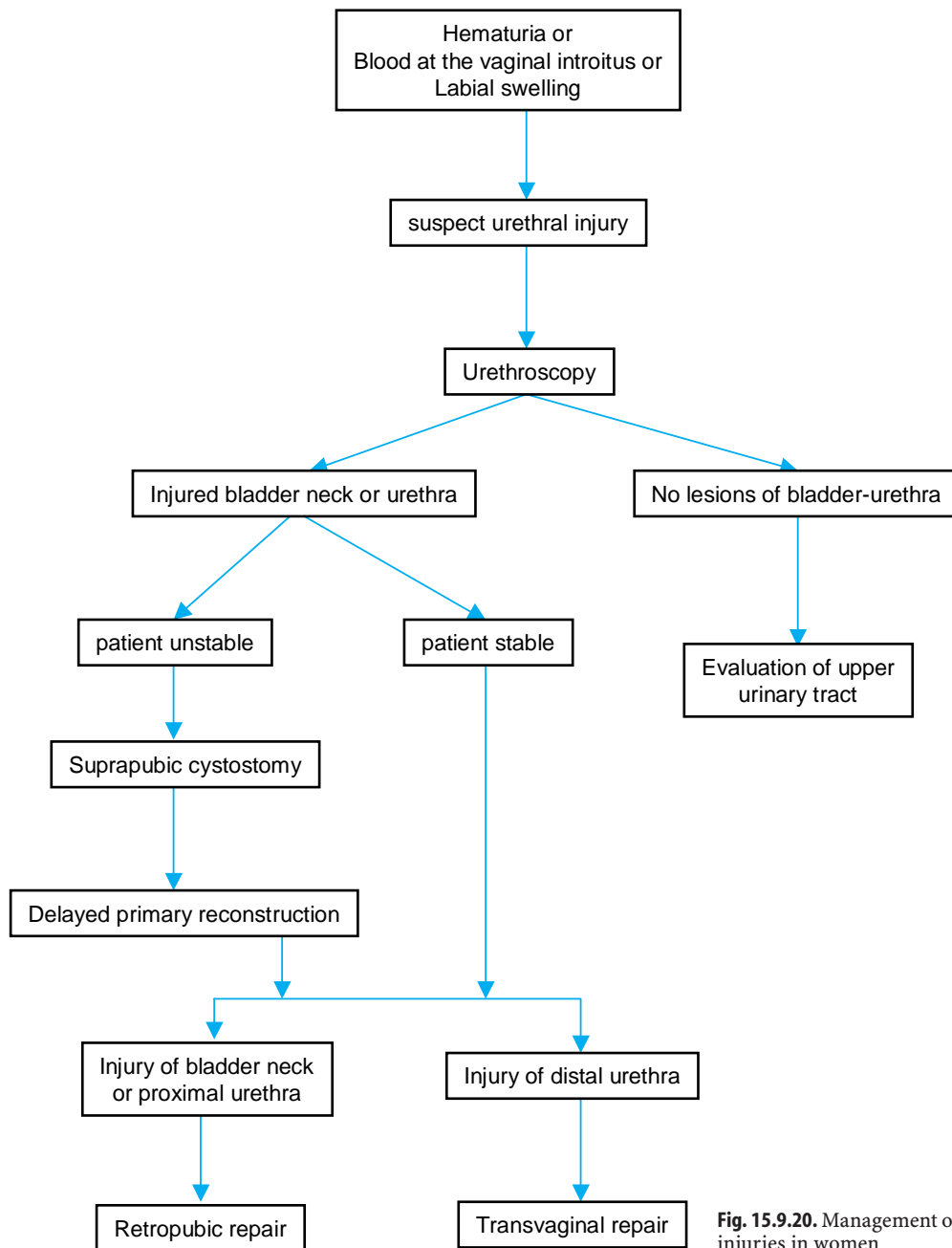


Fig. 15.9.20. Management of urethral injuries in women

Berman AT, Tom L (1974) Traumatic separation of the pubic symphysis with associated fatal rectal tear: A case report and analysis of mechanism of injury. *J Trauma* 14:1060
 Blandy JP (1980) Urethral stricture. *Postgrad Med* 56:383
 Carlin BI, Resnick MI (1995) Indications and techniques for urologic evaluation of the trauma patient with suspected urologic injury. *Semin Urol* 13:9
 Cass AS, Godec CJ (1978) Urethral injury due to external trauma. *Urology* 11:607
 Chapple CR, Png D (1999) Contemporary management of urethral trauma and the post-traumatic stricture. *Curr Opin Urol* 9:253

Chiou RK, Gonzalez R, Ortlip S, Fraley EE (1988) Endoscopic treatment of posterior urethral obliteration: Long-term follow-up and comparison with transpubic urethroplasty. *J Urol* 140:508
 Clark SS, Prudencio RF (1972) Lower urinary tract injuries associated with pelvic fractures. *Surg Clin North Amer* 52:183
 Coffield KS, Weems WL (1977) Experience with management of posterior urethral injury associated with pelvic fractures. *J Urol* 117:722
 Cohen JK, Berg G, Carl GH, Diamond DD (1991) Primary endoscopic realignment following posterior urethral disruption. *J Urol* 146:1548

- Colapinto V (1980) Trauma to the pelvis: urethral injury. *Clin Ortho Rel Res* 151:46
- Colapinto V, McCallum RW (1977) Injury to the male posterior urethra in fractured pelvis: a new classification. *J Urol* 118:575
- Conolly WB, Hedbert EA (1969) Observations on fractures of the pelvis. *J Trauma* 9:104
- Corriere JN Jr (2001) 1-Stage delayed bulboprostatic anastomotic repair of posterior urethral rupture: 60 patients with 1-year followup. *J Urol* 165:404
- Corriere JN Jr, Harris JD (1981) The management of urological injuries in blunt pelvic trauma. *Radiol Clin North Am* 19:187
- Corriere JN Jr, Rudy DC, Benson GS (1994) Voiding and erectile dysfunction after delayed one-stage repair of posterior urethral disruption in 50 men with fractured pelvis. *J Trauma* 37:587
- Crassweller PO, Farrow GA, Robson CJ, Russell JL, Colapinto V (1977) Traumatic rupture of the supramembranous urethra. 118:770
- Devine PC, Devine CJ (1982) Posterior urethral injuries associated with pelvic fractures. *Urology* 20:467
- DeVries CR, Anderson RU (1990) Endoscopic urethroplasty: An improved technique. *J Urol* 143:1225
- Dhabuwala CB, Hamid S, Katsikas DM, Pierce J (1990) Impotence following delayed repair of prostate membranous urethral disruption. *J Urol* 144:677
- Dixon CM, Hricak H, McAninch JW (1992) Magnetic resonance imaging of traumatic posterior urethral defects and pelvic crush injuries. *J Urol* 148:1162
- Dixon MD (1996) Diagnosis and acute management of posterior urethral disruptions. In: McAninch JW (ed) *Traumatic and reconstructive urology*. WB Saunders Philadelphia
- Dogra PN, Nabi G (2002) Core-through urethrotomy using the neodymium yag laser for obliterative urethral strictures after traumatic urethral disruption and/or distraction defects: long-term outcome. *J Urol* 167:543
- El-Abd S (1995) Endoscopic treatment of posttraumatic urethral obliteration: experience in 396 patients. *J Urol* 153:67
- Elliott DS, Barret DM (1997) Long-term follow-up and evaluation of primary realignment of posterior urethral disruptions. *J Urol* 157:814
- Fallon B, Wendt JC, Hawtrey CE (1984) Urological injury and assessment in patients with fractured pelvis. *J Urol* 131:712
- Fiala R, Zatura F, Vrtal R (2001) Personal experience with treatment of posttraumatic urethral distraction defects. *Acta Chir Orthop Traumatol Cech* 68:99
- Flaherty JJ, Kelley R, Burnett B, Bucy J, Surian M, Schildkraut D, Clark BG (1968) Relationship of pelvic bone fracture patterns to injuries of urethra and bladder. *J Urol* 99:297
- Follis WH, Koch MO, McDougal WS (1992) Immediate management of prostatic membranous urethral disruptions. *J Urol* 147:1259
- Gelbard MK, Heyman AM, Weintraub P (1989) A technique for immediate realignment and catheterization of the disrupted prostatic membranous urethra. *J Urol* 142:52
- Gheiler EL, Frontera JR (1997) Immediate primary realignment of prostatic membranous urethral disruptions using endourologic techniques. *Urology* 49:596
- Gibson GR (1970) Impotence following fractured pelvis and ruptured urethra. *Br J Urol* 42:86
- Gibson GR (1974) Urological management and complications of fractured pelvis and ruptured urethra. *J Urol* 111:353
- Glassberg KI, Tolete-Velcek F, Ashley R, Waterhouse K (1979) Partial tears of prostatic membranous urethra in children. *Urology* 13:500
- Goel MC, Kumar M, Kapoor R (1997) Endoscopic management of traumatic posterior urethral stricture: early results and follow-up. *J Urol* 157:95
- Goldman SM, Sandler CM, Corriere-Jr, JN, McGuire EJ (1997) Blunt urethral trauma: a unified, anatomical mechanical classification. *J Urol* 157:85
- Gomez RG, Castanheira ACC, McAninch JW (1993) Gunshot wounds to the male external genitalia. *J Urol* 150:1147
- Guille F, Cipolla B, Leveque JM, Guirassy S, Olivo JF, Lobel B (1991) Early endoscopic realignment of complete traumatic rupture of the posterior urethra. *Br J Urol* 68:178
- Gupta NP, Gill IS (1986) Core-through optical internal urethrotomy in management of impassable traumatic posterior urethral strictures. *J Urol* 136:1018
- Hemal AK, Dorairajan LN, Gupta NP (2000) Posttraumatic complete and partial loss of urethra with pelvic fracture in girls: an appraisal of management. *J Urol* 163:282
- Herschorn S, Thijssen A, Radomski SB (1992) The value of immediate or early catheterization of the traumatized posterior urethra. *J Urol* 148:1428
- Husmann DA, Wilson WT, Boone TB, Allen TD (1990) Prostatic membranous urethral disruptions: Management by suprapubic cystostomy and delayed urethroplasty. *J Urol* 144:76
- Husmann DA, Boone TB, Wilson WT (1993) Management of low velocity gunshot wounds to the anterior urethra: the role of primary repair versus urinary diversion alone. *J Urol* 150:70
- Iselin CE, Webster GD (1999) The significance of the open bladder neck associated with pelvic fracture urethral distraction defects. *J Urol* 162:347
- Jackson DH, Williams JL (1974) Urethral injury: a retrospective study. *Br J Urol* 46:665
- Jepson BR, Boullier JA, Moore RG, Parra RO (1999) Traumatic posterior urethral injury and early primary endoscopic realignment: evaluation of long-term follow-up. *Urology* 53:1205
- Jordan GH (1996) Management of membranous urethral distraction injuries via the perineal approach. In: McAninch JW (ed) *Traumatic and reconstructive urology*. WB Saunders, Philadelphia, p 393
- Kane NM, Francis IR, Ellis JH (1989) The value of CT in the detection of bladder and posterior urethral injuries. *AJR Am J Roentgenol* 153:1243
- Kernohan RM, Anwar KK, Johnston SR (1991) Complete urethral stricture of the membranous urethra: A different perspective. *Br J Urol* 65:51
- Kielb SJ, Voeltz ZL, Wolf JS (2001) Evaluation and management of traumatic posterior urethral disruption with flexible cystourethroscopy. *J Trauma* 50:36
- King J (1975) Impotence after fractures of the pelvis. *J Bone Joint Surg* 57:1107
- Koraitim MM (1995) The lessons of 145 posttraumatic posterior urethral strictures treated in 17 years. *J Urol* 153:63
- Koraitim MM (1996) Pelvic fracture urethral injuries: evaluation of various methods of management. *J Urol* 156:1288
- Koraitim MM (1997) Post-traumatic posterior urethral strictures in children: A 20 year experience. *J Urol* 157:641
- Koraitim MM (1999) Pelvic fracture urethral injuries: the unresolved controversy. *J Urol* 161:1433
- Koraitim MM, Marzouk ME, Atta MA, Orabi SS (1996) Risk factors and mechanism of urethral injury in pelvic fractures. *Br J Urol* 77:876
- Kotkin L, Koch MO (1996) Impotence and incontinence after immediate realignment of posterior urethral trauma: results of injury or management? *J Urol* 155:1600
- Leonard MP, Emtaje J, Perez R, Morales A (1990) Endoscopic management of urethral stricture: Cut-to-the-light procedure. *Urology* 35:117
- Levine J, Wessells H (2001) Comparison of open and endoscopic treatment of posttraumatic posterior urethral strictures. *World J Surg* 25:1597

- Lieberman SF, Barry JM (1982) Retreat from transpubic urethroplasty for obliterated membranous urethral strictures. *J Urol* 128:379
- Lim PHC, Chng HC (1989) Initial management of acute urethral injuries. *Br J Urol* 64:165
- Londergan TA, Gundersen LH, Every MJv (1997) Early fluoroscopic realignment for traumatic urethral injuries. *Urology* 49:101
- Lowe MA, Mason JT, Luna GK, Maier RV, Copass MK, Berger RE (1988) Risk factors for urethral injuries in men with traumatic pelvic fractures. *J Urol* 140:506
- Lynch T, Martínez-Piñero L, Plas E, Serafetinides E, Türkeri L, Santucci RA, Hohenfellner M (2005) EAU Guidelines on urological trauma. *Eur Urol* 47:1
- MacDiarmid S, Rosario D, Chapple CR (1995) The importance of accurate assessment and conservative management of the open bladder neck in patients with pelvic fracture membranous urethral distraction defects. *Br J Urol* 75:65
- Malek RS, ODea MJ, Kelalis PP (1977) Management of ruptured posterior urethra in childhood. *J Urol* 117:105
- Mark SD, Webster GD (1996) Reconstruction of the failed repair of posterior urethral rupture. In: McAninch JW (ed) *Traumatic and reconstructive urology*. WB Saunders, Philadelphia
- Mark SD, Keane TE, Vandemark RM, Webster GD (1995) Impotence following pelvic fracture urethral injury: incidence, aetiology and management. *Br J Urol* 75:62
- Marshall FF (1989) Endoscopic reconstruction of traumatic urethral transections. *Urol Clin North Am* 16:313
- Martínez-Piñero JA, Carcamo P, García-Matres MJ, Martínez-Piñero L, Iglesias JR, Rodríguez-Ledesma JM (1997) Excision and anastomotic repair for urethral stricture disease: experience with 150 cases. *Eur Urol* 32:433
- McAninch JW (1989) Pubectomy in repair of membranous urethral stricture. *Urol Clin North Am* 16:297
- McAninch JW (1992) Urethral injuries in female subjects following pelvic fractures (Editorial Comment) *J Urol* 147:143
- McAninch JW (1996) Pubectomy in repair of membranous urethral strictures. In: McAninch JW (ed) *Traumatic and reconstructive urology*. WB Saunders, Philadelphia
- McAninch JW (1997) Editorial: Scars in the urinary system. *J Urol* 157:817
- McAninch JW (1981) Traumatic injuries to the urethra. *J Trauma* 21:291
- McRoberts JW, Radge H (1970) The severed canine posterior urethra: a study of two distinct methods of repair. *J Urol* 104:724
- Melekos MD, Pantazakos A, Daouaher H, Papatsoris G (1992) Primary endourologic re-establishment of urethral continuity after disruption of prostatomembranous urethra. *Urology* 39:135
- Milroy EJG, Chapple CR, Eldrin A, Wallsen N (1989) A new treatment for urethral strictures – A permanently implanted stent. *J Urol* 141:1120
- Moore EE, Cogbill TH, Jurkovich GJ, McAninch JW, Champion HR, Gennarelli TA, Malangoni MA, Shackford SR, Trafton PG (1992) Organ injury scaling III: chest wall, abdominal vascular, ureter, bladder, and urethra. *J Trauma* 33:337
- Morehouse DD, Mackinnon KJ (1980) Management of prostatomembranous urethral disruption: a 13-year experience. *J Urol* 123:173
- Morey AE, McAninch JW (1997) Reconstruction of posterior urethral disruption injuries: outcome analysis in 82 patients. *J Urol* 157:506
- Moudouni SM, Patard JJ, Manuta A, Guiraud P, Lobel B, Guille F (2001) Early endoscopic realignment of post-traumatic posterior urethral disruption. *Urology* 57:628
- Mouraviev V, Santucci R (2005) Cadaveric anatomy of pelvic fracture urethral distraction injury: most injuries are distal to the external urinary sphincter. *J Urol* 173:869
- Mouraviev V, Coburn M, Santucci R (2005) The treatment of posterior urethral disruption associated with pelvic fractures: comparative experience of early realignment versus delayed urethroplast. *J Urol* 173:873
- Muhlbauer S, Bard R (1980) Early definitive urologic management of patient with crush pelvic trauma and deep perineal laceration. *Urology* 15:56
- Mundy AR (1993) Results and complications of urethroplasty and its future. *Br J Urol* 71:322
- Mundy AR (1991) The role of delayed primary repair in the acute management of pelvic fracture injuries to the urethra. *Br J Urol* 68:273
- Mundy AR (1996) Urethroplasty for posterior urethral strictures. *Br J Urol* 78:243
- Nicolaisen G, Melamud A, Williams RD, McAninch JW (1983) Rupture of the corpus cavernosum: surgical management. *J Urol* 130:917
- Palmer KJ, Benson GS, Corriere JN Jr (1983) Diagnosis and initial management of urological injuries associated with 200 consecutive pelvis fracture. *J Urol* 130:712
- Pansadoro V, Emiliozzi P (1996) Internal urethrotomy in the management of anterior urethral strictures: long-term follow-up. *J Urol* 156:73
- Pennal GF, Tile M, Waddell JP, Garside H (1980) Pelvic disruption: assessment and classification. *Clin Orthop* 151:12
- Perry MO, Husmann DA (1992) Urethral injuries in female subjects following pelvic fractures. *J Urol* 147:139
- Podesta A, Hafez A, El-Assmy A, Sarhan O, El-Hefnawy A, Ghoneim M (2005) Perineal anastomotic urethroplasty for managing post-traumatic urethral strictures in children: the long-term outcome. *BJU Int* 95:403
- Pokorny M, Pontes JE, Pierce JM Jr (1978) Urological injuries associated with pelvic trauma. *J Urol* 121:455
- Pontes JE, Pierce JM Jr (1978) Anterior urethral injuries: four years of experience at the Detroit General Hospital. *J Urol* 120:563
- Porter JR, Takayama TK, Defalco AJ (1997) Traumatic posterior urethral injury and early realignment using magnetic urethral catheters. *J Urol* 158:425
- Quint JH, Stanicic TH (1993) Above and below delayed endoscopic treatment of traumatic posterior urethral disruption. *J Urol* 149:484
- Ragde H, McInnes GF (1969) Transpubic repair of the severed prostatomembranous urethra. *J Urol* 101:335
- Rehman J, Samadi D, Ricciardi R Jr, Kreutzer E (1998) Early endoscopic realignment as primary therapy for complete posterior urethral disruptions. *J Endourol* 12:283
- Sachse H (1974) Zur Behandlung der Harnröhrenstruktur: Die transurethrale Schlitzung unter Sicht mit scharfem Schnitt. *Fortschr Med* 92:12
- Sahin H, Bircan MK, Akay AF, Gocmen M, Bilici A (1998) Endoscopic treatment of complete posterior urethral obliteration. *Acta Urol Belg* 66:21
- Santucci RA, Mario LA, McAninch JW (2002) Anastomotic urethroplasty for bulbar urethral stricture: analysis of 168 patients. *J Urol* 167:1715
- Sevitt S (1968) Fatal road accidents. Injuries, complications, and causes of death in 250 subjects. *Br J Surg* 55:481
- Siegel JH, Dalal SA, Burgess AR (1990) Pattern of organ injuries in pelvic fracture: Impact force implications for survival and death in motor vehicle injuries. *Accid Anal Prev* 22:457
- Smith J (1968) The measurement and significance of the urinary flow rate. *Br J Urol* 38:701
- Tahan H, Randrianantenaina A, Michel F (1999) Treatment of complete rupture of the posterior urethra by endoscopic treatment. *Prog Urol* 9:489

- Tile M, Pennal GF (1980) Pelvic disruptions: Principles of management. *Clin Orthop* 151:56
- Turner-Warwick R (1973) Observations on the treatment of traumatic urethral injuries and the value of the fenestrated urethral catheter. *Br J Surg* 60:775
- Turner-Warwick R (1977) Complex traumatic posterior urethral strictures. *J Urol* 118:564
- Turner-Warwick R (1989) Prevention of complications resulting from pelvic fracture urethral injuries – and from their surgical management. *Urol Clin North Am* 16:335
- Venn SN, Mundy AR (1998) Immediate management of major trauma to the urinary tract. *Eur Urol* 33:1
- Wadhwa SN, Chahal R, Hemal AK, Gupta NP, Dogra PN, Seth A (1998) Management of obliterative posttraumatic posterior urethral strictures after failed initial urethroplasty. *J Urol* 159:1898
- Webster GD (1990) Impotence following delayed repair of prostatic membranous urethral disruption. Editorial comment. *J Urol* 144:678
- Webster GD (1987) The management of complex posterior urethral strictures. *Prob Uro* 1:226
- Webster GD (1989) Perineal repair of membranous urethral stricture. *Urol Clin North Am* 16:303
- Webster GD, Ramon J (1991) Repair of pelvic fracture posterior urethral defects using an elaborated perineal approach. *J Urol* 145:744
- Webster GD, Ramon J, Kreder K (1990) Salvage posterior urethroplasty after failed initial repair of pelvic fracture membranous urethral defects. *J Urol* 144:1370
- Webster GD, Mathes GL, Selli C (1983) Prostatomembranous urethral injuries. A review of the literature and a rational approach to their management. *J Urol* 130:898
- Weems WL (1979) Management of genitourinary injuries in patients with pelvic fractures. *Ann Surg* 189:717
- Williams G (1993) Stents in the lower urinary tract. *Am Urol Assoc Update Ser* 12:26
- Yasuda T, Yamanishi T, Isaka S, Okano T, Masai M, Shimazaki J (1991) Endoscopic re-establishment of membranous urethral disruption. *J Urol* 145:977
- Ying-Hao S, Chuan-Liang X, Xu G, Guo-Qiang L, Jian-Guo H (2000) Urethroscopic realignment of ruptured bulbar urethra. *J Urol* 164:1543
- Zinman LN (1997) The management of traumatic posterior urethral distraction defects. Editorial. *J Urol* 157:511
- Zorn G (1960) Beckenbrüche mit Harnröhrenverletzungen, ihre Behandlung und Ergebnisse. *Beitr Klin Chir* 1960:147

Education by Humiliation

By Far the Best Way of Learning!

A.R. MUNDY

Roughly 10 years ago, I was invited to operate in Iran to treat a number of urological problems relating to war wounds during the Iran–Iraq war. On the first day, I was taken on a ward round and the first patient I saw was standing smartly to the side of his bed holding a urine drainage bag on the end of a suprapubic catheter. I was told that he had a prostatorectal fistula as a result of a gunshot wound and was shown an x-ray with a bullet perfectly in place between his rectum and bladder. Contrast studies confirmed that the bullet was in a cavity that communicated with the rectum and the prostate. I was told that everything else was normal. He told me he had feces in his urine and he was very glad that I had come over from England to fix it, as he had had three failed operations over the previous 4 years.

We went to the operating room that afternoon and I did a transperineal excision of the cavity and closure of the fistula, removing the bullet and interposing a gracilis flap between the two closure lines. The following day, I went to see him to see how he was and he said he was very well indeed and that he was very grateful to me for doing his operation but why was he still passing feces in his urine. We obtained another contrast study and I was told that there was another fistula slightly higher up, this one into the bladder, presumably from one of the previous attempts to close his fistula; and so we took him back to the operating room later that same day and closed that fistula, transperineally as before.

The following day, I went back to see him again and was again pleased to see him standing by his bed, although not quite as robust as the previous day. “Thank you so much,” he said, “I am very grateful to you for doing the operation but why am I still passing feces in my urine?” A further contrast study showed a second vesicocolic fistula higher up than the other. We went back to the operating room and this time did a transabdominal closure of that fistula. The following morning I went back to see him. This time he was unable to stand by his bed, not surprisingly, and when he said “Thank you very much for doing the operation,” I was terrified he was going to tell me about feces in his urine again, but on that third occasion we had finally dealt with the problem – at last.

I learned two lessons from that experience. Firstly, if somebody has had an injury and has one problem as a consequence of it he may well have a second or third problem as well: I have come across this situation several times. The second lesson I learned was never to trust other people’s results or reports of x-ray studies without the images. I have experienced this type of problem many times. An investigator, when he is a surgeon, and particularly when he is not, never has quite the same attitude toward an investigation and its interpretation, if he himself is not going to be doing the surgery. Get your own investigations and review them carefully yourself.



<http://www.springer.com/978-3-540-48603-9>

Emergencies in Urology

Hohenfellner, M.; Santucci, R.A. (Eds.)

2007, XXVIII, 659 p., Hardcover

ISBN: 978-3-540-48603-9