

10

Echocardiographic Assessment of Diastolic Function and Diagnosis of Diastolic Heart Failure

Grace Lin and Jae K. Oh

Introduction

Asymptomatic diastolic dysfunction in the general population is common, even in patients without congestive heart failure,^{1,2} and the prevalence of moderate to severe diastolic dysfunction in asymptomatic patients increases in patients >65 years old with associated hypertension and coronary artery disease.² The presence of diastolic dysfunction alone predicts worse outcome, with worse prognosis as the degree of diastolic dysfunction increases.² Thus, it is important to identify and treat underlying problems (most frequently, hypertension) in patients with diastolic dysfunction.

In population-based studies, diastolic heart failure (DHF) accounts for up to half of patients with the diagnosis of congestive heart failure [2–6]. Although DHF can be diagnosed clinically by documenting the presence of signs and symptoms of heart failure and preserved systolic function ($EF \geq 50\%$), objective evidence of diastolic dysfunction and increased filling pressure should also be demonstrated.^{7–9}

Evaluation of diastolic function consists of assessing myocardial relaxation, filling pressures, and left ventricular (LV) compliance. Although diastolic dysfunction can be diagnosed invasively by cardiac catheterization,¹⁰ this is not always feasible or practical. Both two-dimensional and Doppler echocardiography can be used to non-invasively assess diastolic function. Although systolic function and major cardiac structures are usually normal in patients with DHF, two-dimensional echocardiography is useful in

identifying changes, although subtle, associated with cardiac diseases that result primarily in diastolic dysfunction. These changes include reduced motion of the mitral annulus, increased left atrial size, and frequently increased LV wall thickness. Left ventricular diastolic function is more objectively characterized by the mitral inflow pattern, pulmonary and hepatic vein Doppler velocities, tissue Doppler imaging of the mitral annulus, and color flow imaging of mitral inflow.

Two-Dimensional Echocardiography

Two-dimensional echocardiography can be used to evaluate anatomic changes of diseases that cause diastolic dysfunction, including hypertension, hypertrophic cardiomyopathy, infiltrative diseases, and restrictive cardiomyopathy. Left ventricular wall thickness is frequently increased in patients with primary diastolic dysfunction or heart failure. Myocardial relaxation is usually decreased when LV wall thickness is increased unless it is related to conditioning and exercise. However, most patients with increased wall thickness do not experience heart failure symptoms. Another important point is that increased wall thickness does not always indicate LV hypertrophy and may represent infiltrative cardiomyopathy. In cardiac amyloid, the electroencephalographic voltage is low despite increased LV wall thickness. Diastolic dysfunction results in chronically elevated LV filling pressures that lead to increased left atrial enlargement. Thickened pericardium and abnormal ventricular septal

motion associated with respiratory changes in ventricular filling are features of constrictive pericarditis, another cause of DHF, which are readily identified by two-dimensional echocardiography (see Chapter 21). Right atrial pressures can be increased in diastolic dysfunction, causing inferior vena cava and hepatic vein dilatation. In addition, systolic dysfunction, valvular heart disease, LV dilatation, and other structural heart diseases can be excluded with two-dimensional echocardiography.

The atria remodel and enlarge with systolic heart failure and DHF.¹¹ With progressive degrees of diastolic dysfunction, left atrial size and volume increase,¹² and increased left atrial volume indexed to body surface area is predictive of future cardiovascular events, including atrial fibrillation, heart failure, myocardial infarction, stroke, and cardiovascular death, independent of other clinical and echocardiographic risk factors.^{13,14}

Most commonly, left atrial volume is measured by the biplane area–length method. The left atrial area obtained by planimetry in the apical four-chamber (A1) and apical two-chamber views (A2), and the left atrial length measured from the mitral annulus to the posterior left atrial wall in either view are used in the calculation of left atrial volume¹⁵:

$$\text{Left atrial volume} = (0.85 \times A1 \times A2) / \text{Length}$$

The resulting left atrial volume is then indexed to body surface area. Normal left atrial volume usually excludes clinically important diastolic dysfunction, and, conversely, left atrial enlargement indicates presence of diastolic dysfunction unless it is related to increased stroke volume in individuals with trained bradycardic heart.

Doppler Echocardiography

Left Ventricular Diastolic Function

Mitral Inflow Velocities

Assessment of the transmitral velocities is usually the first Doppler evaluation of LV diastolic function and filling. At the onset of diastole, LV pressure falls below left atrial pressure during active relaxation, followed by mitral valve opening and early diastolic filling. Mitral inflow decelerates as

LV pressure rises and exceeds left atrial pressure with rapid filling and then increases again with atrial contraction. Normally, early diastolic filling accounts for 70%–80% of filling, with atrial contraction accounting for 20%–30%. Changes in the transmitral pressure gradient during diastole are demonstrated by the mitral inflow peak velocities recorded by pulsed wave Doppler and consist of early rapid filling (E wave) and late filling due to atrial contraction (A wave; Figure 10.1).^{16,17} The deceleration time is the time interval from the peak E velocity until it declines to baseline, extrapolated to zero velocity. Different degrees of diastolic dysfunction correspond to specific mitral inflow patterns, which demonstrate the relationship between LV and left atrial pressures.^{16,17} In normal, healthy individuals, the E/A ratio is >1.0. With delayed relaxation, the E/A ratio is reduced and deceleration time is prolonged due to slower equilibration of left atrial and LV pressures. In a noncompliant ventricle with elevated filling pressure, the E/A ratio is increased with a shorter deceleration time (see Figure 10.1).

To measure mitral inflow velocities, the ultrasound transducer is placed at the apex, and a 1–2-mm sample volume is placed at the tip of the mitral valve leaflets in the apical four-chamber view during diastole. Accurate measurement of the mitral inflow velocities is dependent on appropriate placement of the sample volume as well as the heart rate. The maximal mitral flow velocity occurs at the tips of the mitral valve; placement of the sample volume at sites other than the mitral leaflet tips may result in underestimation of the flow velocities. At higher heart rates and with first degree atrioventricular block, the mitral inflow velocities may be fused. In this situation, the deceleration time is difficult to determine, and the A velocity may be increased. If the E velocity has not declined to baseline and remains higher than 0.2 m/s, measurement of the A velocity and the E/A ratio may be inaccurate. The mitral A wave duration may also be useful in determining LV end-diastolic pressure.^{18,19} In atrial fibrillation, the A wave is absent.

Pulmonary Vein Flow Velocity

Pulmonary vein flow velocity reflects left atrial filling, pressures, and compliance and can also be

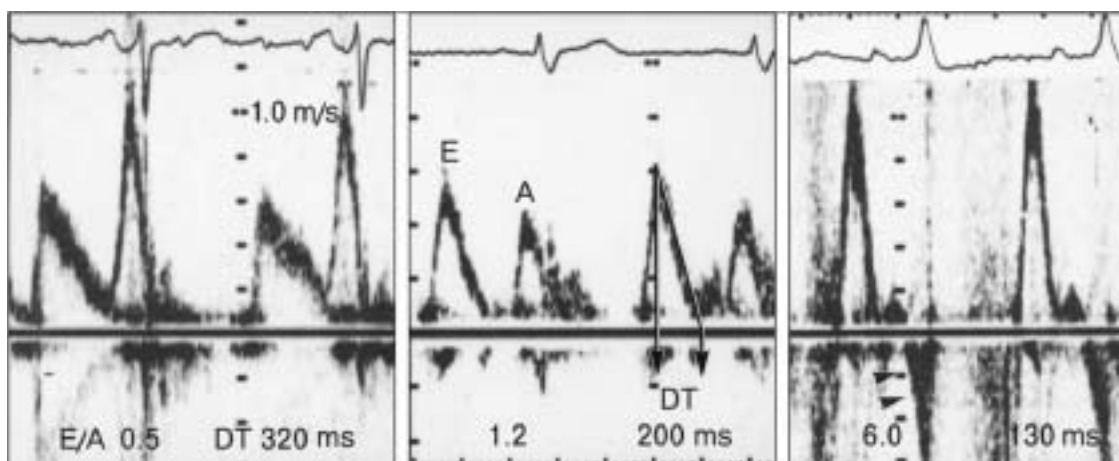


FIGURE 10.1. Pulsed wave Doppler recordings of mitral inflow velocity to determine diastolic filling pattern. These Doppler recordings represent impaired myocardial relaxation (**left**), normal (**center**), and restrictive diastolic filling pattern (**right**). In impaired relaxation pattern, which is an initial diastolic dysfunction, early diastolic velocity (E) is reduced and deceleration (DT) time is prolonged, usually longer than 240 ms. The late diastolic filling velocity at the time of atrial contraction (A) is augmented and higher than E. In normal mitral inflow velocity, E velocity is equal to or

higher than A velocity, and deceleration time ranges from 160 to 240 ms. In the restrictive filling pattern, early diastolic velocity (E) is increased, usually higher than 1 m/s with short deceleration time of less than 160 ms, and A velocity is reduced with a resulting E/A ratio >2 . Frequently, we see diastolic mitral regurgitation in the restrictive filling pattern due to increased diastolic filling pressure (arrowheads). (Reprinted with permission from Oh J, et al. *Echo Manual*, 2nd ed. Philadelphia: Lippincott Williams & Wilkins; 1999.)

recorded by pulsed wave Doppler. Of the four pulmonary veins, the right upper pulmonary vein is the most readily seen by transthoracic echocardiography in the apical four-chamber view (Figure 10.2A). Color flow imaging of the posterior left atrium may help visualize the color flow into the left atrium at the orifice of the right upper pulmonary vein, and a 5-mm sample volume is placed in the pulmonary vein 1 to 2 cm from the orifice, where pulmonary vein pressure begins to approximate left atrial pressures.²⁰ Normal pulmonary vein flow consists of biphasic systolic forward flow (PVs1, PVs2), diastolic forward flow (PVd), and atrial reversal due to atrial contraction (PVa; Figure 10.2B). The two components of systolic flow correspond to early systolic flow due to atrial relaxation (PVs1), followed by mid to late systolic flow due to increasing pulmonary venous pressure (PVs2). The two pulmonary vein systolic velocities may not be distinct even in normal patients. Diastolic forward flow occurs with the fall in left atrial pressure after mitral valve opening. Atrial reversal is a low velocity waveform that reflects flow reversal in the pulmonary vein due to atrial contraction in late diastole.²⁰

Although pulmonary vein flow velocity patterns cannot be used alone to characterize diastolic function, they complement mitral inflow patterns. In normal patients, pulmonary vein systolic velocity is equal to or higher than diastolic velocity. With impaired ventricular relaxation, pulmonary vein systolic forward flow is blunted, and the majority of forward flow into the left atrium occurs during diastole, resulting in a relatively higher PVd than PVs2 (Figure 10.3). When LV filling pressures are increased, peak PVd is increased and the deceleration time of PVd is shortened.²¹ Together with the mitral inflow A velocity duration, PVa reflects LV end-diastolic pressure. A PVa duration greater than the mitral A velocity predicts an LV end-diastolic pressure of 15–20 mm Hg or greater.^{18,19}

Tissue Doppler Imaging of Mitral Annular Velocity

Mitral annular motion during early diastole reflects LV relaxation and is useful in the assessment and classification of diastolic dysfunction.^{22–25}

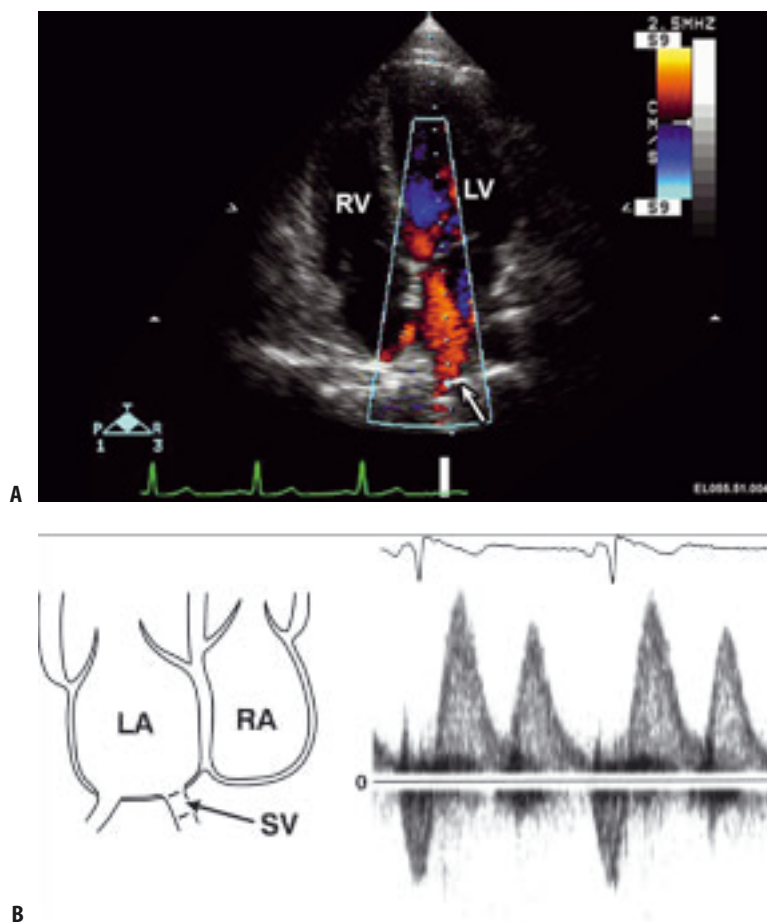


FIGURE 10.2. (A) Apical four-chamber view with color flow imaging demonstrating pulmonary venous flow from the right paraseptal vein. Sample volume (arrow) is placed in the pulmonary vein guided by the color flow imaging. RV, right ventricle; LV, left ventricle. (B) Diagram of the atria (LA, left atrium; RA, right atrium)

and pulmonary vein demonstrating the optimal location of sample volume (SV) placement. See text for details. (Reprinted with permission from Oh J, et al. *Echo Manual*, 2nd ed. Philadelphia: Lippincott, Williams & Wilkins; 1999.)

Longitudinal mitral annular velocities can be recorded with tissue Doppler imaging from the apical four-chamber view, with a 2–5-mm sample volume placed at the medial or lateral aspect of the mitral annulus. Interrogation of the mitral annulus usually results in three waveforms, the systolic (S') velocity of systolic annular motion, and two diastolic velocities, reflecting early (E') and late (A') diastolic annular motion (Figure 10.4A). Normally, the E' velocity is equal to or higher than A' , and this ratio reverses with diastolic dysfunction as E' decreases with impaired relaxation and in all stages of diastolic dysfunction

(Figure 10.4B). E' is less dependent on volume and loading conditions than transmitral flow velocities, although, with normal myocardial relaxation, E' increases with higher preload. However, in patients with impaired relaxation, E' is reduced and affected less by changes in preload.²³ Thus E' may be combined with transmitral flow velocities to further define diastolic function. The ratio of early transmitral velocity and early diastolic mitral annular velocity, E/E' , correlates with pulmonary capillary wedge pressure measurements and is not affected by sinus tachycardia or the presence of atrial fibrillation.^{25–28}

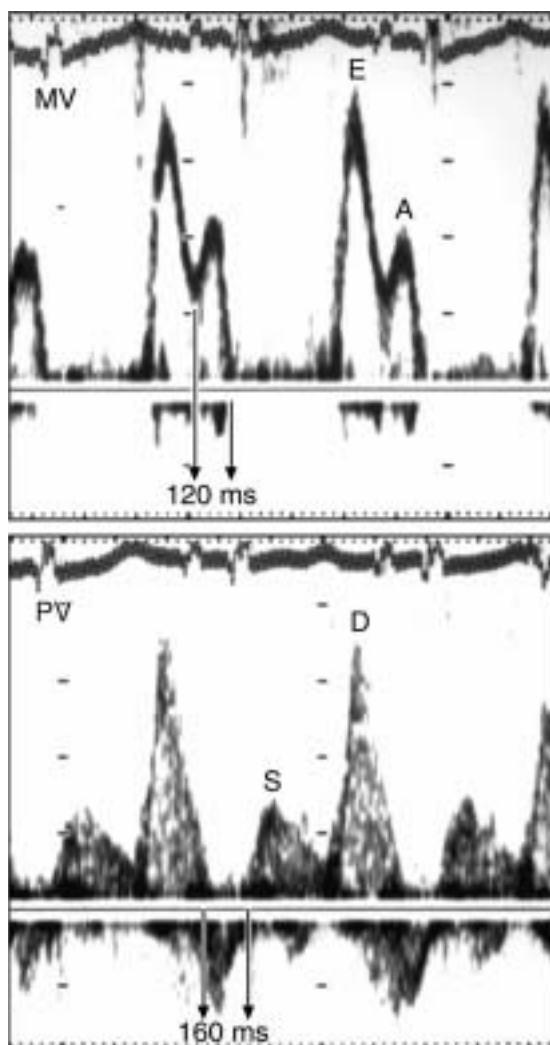


FIGURE 10.3. Pulsed wave Doppler recording of mitral inflow (MV) (**top**) and pulmonary vein (PV) (**bottom**) flow velocities. The E/A ratio is slightly less than 2 and deceleration time is 180 ms. The PV flow velocity shows predominant diastolic forward flow velocity, which indicates increased left atrial pressure. The PV atrial flow reversal is also longer (160 ms) than the duration of the A wave (120 ms), indicating that mitral flow velocity is “pseudonormalized.” (Reprinted with permission from Oh J, et al. *Echo Manual*, 2nd ed. Philadelphia: Lippincott, Williams & Wilkins 1999.)

Propagation Velocity by Color M-Mode Echocardiography

As blood moves from the base of the left ventricle to the apex during diastole the velocity of blood flow decreases. This change in velocity of blood flow through the ventricle is called the *mitral*

inflow propagation velocity and can be demonstrated by measuring the slope of the color M-mode pattern from the mitral annulus to the apex (Figure 10.5A).^{29–31} With narrow sector color Doppler imaging in the apical four-chamber view, the M-mode cursor is placed in the center of the mitral inflow blood column. The color flow baseline is adjusted so that the central, highest velocity jet is blue, and color aliasing occurs at the edges of the blood column. The slope of the edge of the color M-mode, where the first aliasing velocity occurs, is measured from the mitral annulus to 4 cm from the apex. In normal hearts, early diastolic filling is rapid and the change in mitral inflow velocity from the mitral annulus to the apex is minimal, resulting in a steep slope and higher propagation velocity. In diastolic dysfunction, early diastolic filling is slower, and the slope of the color M-mode is prolonged and propagation velocity is reduced (Figure 10.5B). A propagation velocity of ≥ 50 cm/s is considered normal.^{29–30} An abnormal propagation velocity indicates impaired relaxation.²⁹ Propagation velocity can also be used to estimate pulmonary capillary wedge pressure when combined with isovolumic relaxation time or transmitral E velocity.^{32,22} However, measurement of propagation velocity may be affected by cardiac size and preload.³⁴ An E to propagation velocity ratio of ≥ 2.5 predicts a pulmonary capillary wedge pressure of >15 mm Hg.³³

Right Ventricular Diastolic Function

Tricuspid Inflow Velocity

Right ventricular diastolic function can be measured by recording tricuspid inflow velocities.³⁵ The transtricuspid gradient creates a similar inflow pattern to mitral inflow. Right ventricular diastolic filling pattern may be different from the mitral inflow pattern in the same patient. Tricuspid inflow velocities are typically lower than mitral inflow velocities, and, unlike mitral flow, tricuspid flow velocities normally vary with respiration.

Hepatic Vein Velocities

Hepatic vein velocities reflect right atrial filling, volume, and compliance. Using pulsed wave Doppler, a 2–5-mm pulsed wave sample volume

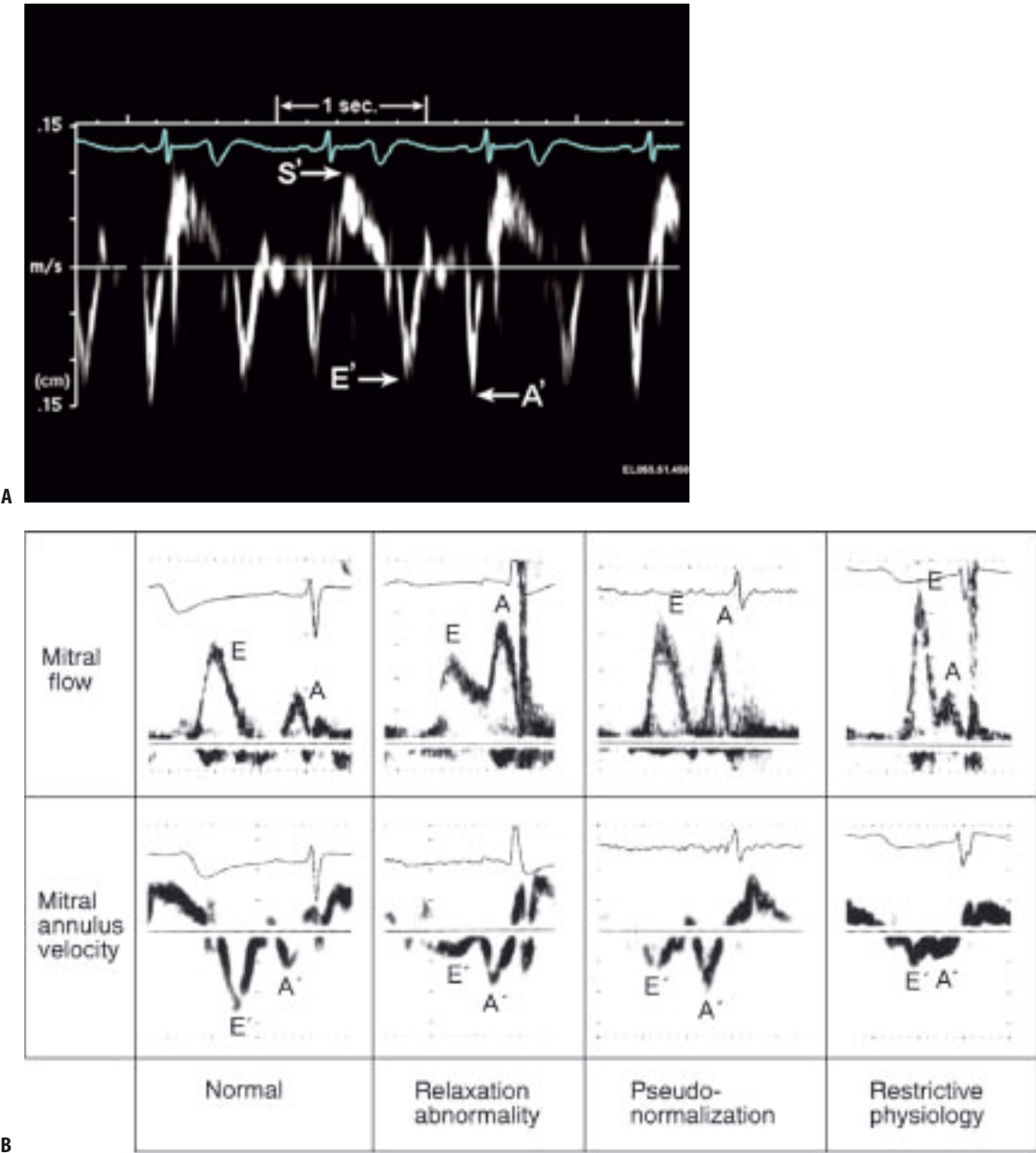


FIGURE 10.4. (A) Recording of pulsed tissue Doppler velocity from the septal mitral annulus. There are three major velocity components: S' , systolic velocity; E' , early diastolic velocity of the mitral annulus, which reflects myocardial relaxation; and A' , late diastolic mitral annulus velocity with atrial contraction. The peak velocity of each component is used for measurement. Each small horizontal bar indicates 200 ms, and large bar indicates 1 s. **(B)** Patterns of mitral inflow and mitral annulus velocities in various stages of diastolic dysfunction. Mitral annulus velocity was obtained from the septal side of the mitral annulus using Doppler tissue imaging. Each calibration mark in the recording of the mitral annulus

velocity represents 5 cm/s. Early diastolic annulus velocity (E') is greater than late diastolic annulus velocity (A') in a normal pattern. In all other patterns, E' is reduced and lower than the A' velocity. In relaxation abnormality, E' and A' have a change similar to that of the E and A velocities of mitral inflow. However, when diastolic filling pressures increase (pseudonormalized and restrictive physiology), E' remains reduced (i.e., persistent underlying relaxation abnormality) while mitral inflow E velocity increases. Hence, E/E' is useful for estimating left ventricular filling pressures. (Reprinted with permission from Sohn et al.²²).

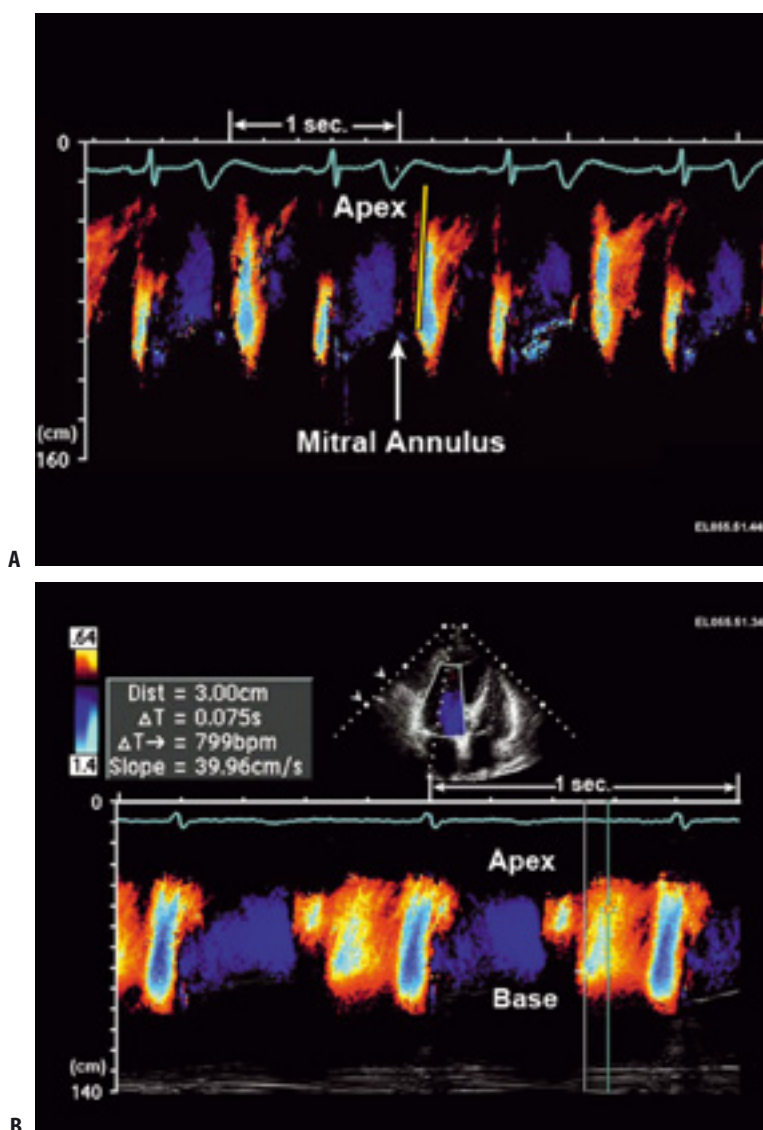


FIGURE 10.5. (A) Normal color flow propagation velocity of mitral inflow indicated by the yellow slope. (B) Color flow M-mode echocardiogram of mitral inflow velocity from a normal individual. Color flow map baseline was shifted upward to decrease the positive aliasing velocity. The manipulation of the color flow map allows demonstration of the highest velocity of the early diastolic

velocity of mitral inflow. The slope of the flow propagation of mitral inflow E is measured by calculating the slope of the highest velocity. In this case, the distance the blood traveled was 3 cm, and the time it took to travel from the annulus to 3 cm apically was 75 ms. Therefore, the slope was 40 cm/s ($3 \text{ cm}/0.075 \text{ s}$), which is reduced.

is placed in the hepatic vein in the subcostal view. Combined with inferior vena cava dimension, hepatic vein velocities can be used to assess right atrial pressure.³⁶ Normal hepatic vein flow consists of systolic forward flow, diastolic forward flow, systolic flow reversal, and diastolic flow reversal (Figure 10.6). In normal patients, systolic

forward flow velocity exceeds diastolic forward flow velocity, without significant reversal velocities.³⁷ The effect of elevated right ventricular filling pressure on hepatic vein flow velocities is analogous to the change in pulmonary vein flow velocity with elevated LV filling pressure. Hepatic vein systolic forward flow velocity is decreased and

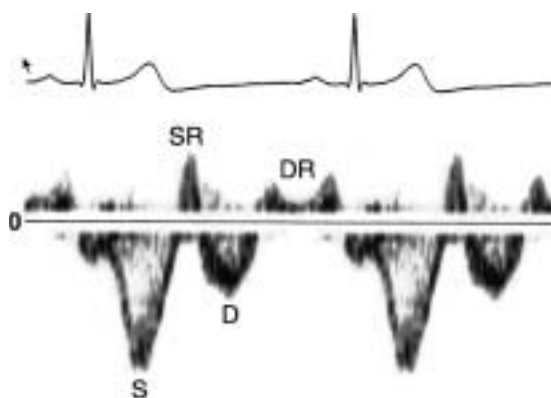


FIGURE 10.6. Pulse wave Doppler recording of hepatic vein flow velocity in a normal subject. Systolic velocity (S) is usually greater than diastolic velocity (D), with no prominent reversal flow velocity. SR, DR, systolic reversal and diastolic reversal, respectively.

diastolic forward flow velocity is increased with elevated right ventricular filling pressure. Changes in hepatic vein flow reversals and hepatic vein forward flow that occur with timing and respiration are important in the diagnosis of tricuspid regurgitation, constrictive pericarditis, tamponade, restrictive cardiomyopathy, and pulmonary hypertension.^{38,39} In constrictive pericarditis, diastolic forward flow is limited, with more prominent systolic forward flow and significant diastolic flow reversal, especially during expiration. Diastolic flow reversals are also seen in pulmonary hypertension but without significant respiratory variation. Restrictive cardiomyopathy is characterized by decreased systolic forward flow and increased systolic and diastolic flow reversals with inspiration. Systolic flow reversals may occur with severe tricuspid regurgitation but is not diagnostic of severe tricuspid regurgitation.

Superior Vena Cava Velocities

Superior vena cava velocities also reflect right atrial filling and are obtained from the right supraclavicular window. A 2–5-mm pulsed wave Doppler sample volume is placed at a depth of 5–7 cm. Systolic forward flow velocity is higher than diastolic forward flow velocity in normal patients and is decreased with increasing right atrial pressure. Superior vena cava velocity is increased with inspiration, but this respiratory variation is less prominent with increased right atrial pressure.

Classification of Diastolic Function

Grading of Diastolic Dysfunction

Diastolic function is graded from 1 to 4 based on the severity of the diastolic filling pattern reflected by the mitral inflow velocities.⁴⁰ Further classification may require supplementation of the mitral inflow pattern by additional Doppler echocardiographic parameters of diastolic function, including pulmonary vein flow velocity, mitral annular velocity, and color M-mode echocardiography (Figure 10.7). Normally, diastolic filling is affected by variations in heart rate, respiration, loading conditions, and atrioventricular conduction. Impaired relaxation is usually the first manifestation of diastolic dysfunction. As diastolic function worsens, left atrial pressure rises and deceleration time shortens, giving a pseudonormalized pattern. Restrictive filling occurs as LV compliance is affected. Irreversible restrictive filling is the final stage of diastolic dysfunction. Grading of diastolic function is discussed below.

Normal

In normal patients, most of diastolic filling occurs during early diastole, with minimal contribution from atrial contraction. The E/A ratio is ≥ 1.5 , deceleration time ranges from 160 to 230 ms, E' is ≥ 10 cm/s, E/E' is < 8 , and propagation velocity is ≥ 50 cm/s. Mitral annular velocities parallel the mitral inflow pattern such that E' is higher than A' . The E/A and E/E' ratios are unaffected by the Valsalva maneuver or exercise. With aging, the E velocity decreases and the A velocity increases as late diastolic filling becomes more prominent (E/A ratio < 1). Similarly, changes are seen in the pulmonary vein flow velocities: diastolic forward flow decreases and more flow occurs during systolic forward flow because of atrial contraction in late diastole.^{41–44}

Grade 1 Diastolic Dysfunction

With a relaxation abnormality, deceleration time and isovolumic relaxation time are prolonged. Relaxation continues into mid to late diastole and results in a lower initial transmitral gradient with subsequent relative increase in transmitral gradient at the time of atrial contraction in late diastole

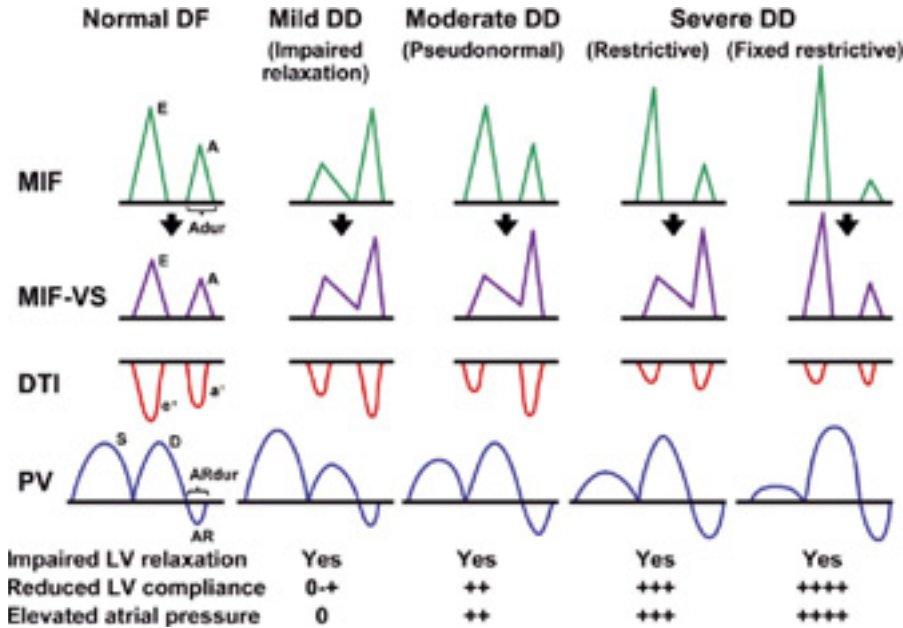


FIGURE 10.7. Schematic diagram of mitral inflow (MIF), mitral inflow with the Valsalva maneuver (MIF-VS), Doppler tissue imaging (DTI), and pulmonary vein velocities (PV) in normal dia-

stolic function and in different stages of diastolic dysfunction. (Reprinted with permission from Redfield et al.²)

due to higher residual left atrial pressure. Thus, E velocity is lower and the E/A ratio is <1 . As with age-related changes, pulmonary diastolic forward flow decreases and pulmonary systolic forward flow increases. Mitral annular velocity (E') decreases with a relaxation abnormality, to <7 cm/s, and propagation velocity also decreases to <50 cm/s. If LV filling pressures are normal, E/E' is ≤ 8 , as in normal patients.²³ As filling pressures increase, E velocity increases while E' is not affected so that E/E' is ≥ 15 . If LV end-diastolic pressure is elevated in the setting of normal mean left atrial pressure, the E/A ratio is still <1 , but the duration of mitral flow during atrial contraction (A wave) is shorter than the duration of the pulmonary vein atrial flow reversal.

Grade 2 (Pseudonormalized Pattern) Diastolic Dysfunction

Grade 2 diastolic dysfunction occurs when increased left atrial pressure is added to a myocardial relaxation abnormality. In this situation, E/A is >1 , and deceleration time is normal, giving

the appearance of normal mitral inflow. However, other features of diastolic dysfunction are present. Left atrial volume is increased, suggesting chronically elevated LV filling pressures. Markers of myocardial relaxation, E' and propagation velocity, are abnormal, with E' being <7 cm/s (using pulsed Doppler recording from tissue Doppler imaging) and propagation velocity being <50 cm/s. With elevated filling pressures, E/E' is >15 , and pulmonary venous A duration is longer than mitral A duration.

A pseudonormalized pattern of diastolic dysfunction can also be distinguished from a normal diastolic filling pattern by the Valsalva maneuver (see Figure 10.7). A Valsalva maneuver involves forced expiration against a closed mouth and nose that decreases LV preload. In normal patients, E and A velocity are equally diminished by decreased preload and resultant lower transmitral gradient, while deceleration time is prolonged. However, a relaxation abnormality is unmasked in patients with a pseudonormalized pattern, and the mitral inflow pattern with a Valsalva maneuver resembles grade 1 diastolic

dysfunction: E/A ratio decreases by ≥ 0.5 .⁴⁵ It should be noted, however, that an adequate Valsalva maneuver may not be possible in some patients.

Grades 3 and 4 (Restrictive Physiology) Diastolic Dysfunction

Restrictive filling occurs when there is reduced LV compliance accompanied by severely increased left atrial pressure. The changes seen in the mitral inflow pattern are due to early filling into a non-compliant left ventricle. Pressure in the stiff left ventricle rises quickly, causing a rapid deceleration of a high E velocity. There is rapid equilibration of left atrial and LV pressure, which shortens the deceleration time (<160 msec). Mitral valve opening is earlier because of high left atrial pressure, which shortens the isovolumic relaxation time (<70 msec). The contribution of atrial contraction in late diastole is limited because of the rapidly increasing LV pressure, giving a short mitral A duration and a decreased A velocity. The E/A ratio is usually >2.0 , which may be even more exaggerated by low A velocity.

Pulmonary vein systolic flow is also affected. Systolic forward flow is decreased because of high left atrial pressure and diastolic forward flow is blunted by the sharp increase in LV pressure in mid to late diastole. Atrial reversal is prominent, during atrial contraction LV pressure is high, and the pulmonary venous atrial reversal duration is prolonged with a higher velocity.

Although both myocardial relaxation and compliance are abnormal, relaxation abnormalities are masked by the hemodynamic changes of the noncompliant left ventricle and elevated left atrial pressure. Again, E' is <7 cm/s and propagation velocity is reduced, reflecting slow flow propagation, although propagation velocity may be preserved if the LV cavity size and systolic function are normal. E/E' is generally >15 , reflecting high filling pressures. A Valsalva maneuver may be attempted to lower preload and demonstrate reversibility of the restrictive filling pattern, but reversibility should not be excluded if there are no changes with this maneuver. Irreversible restrictive physiology should only be diagnosed by documentation of a persistent restrictive filling pattern.

Triphasic Mitral Inflow Pattern

Markedly prolonged myocardial relaxation can produce a triphasic mitral inflow pattern (Figure 10.8), with forward flow (L wave) during mid diastole.⁴⁶ This typically occurs in severe LV hypertrophy, such as in patients with hypertrophic cardiomyopathy and hypertension, but also in patients with ischemic heart disease. The mid diastolic relaxation abnormality is also seen by mitral annular tissue Doppler imaging (see Figure 10.8), where an L' velocity wave occurs after E'.^{46,47} It is also associated with left atrial enlargement, elevated E/E' (>15) and increased brain natriuretic peptide, suggesting high filling pressures and significant diastolic dysfunction.^{46,47}

Atrial Fibrillation

Characterization of diastolic dysfunction in atrial fibrillation is difficult, because the usual classifications based on mitral inflow pattern do not apply. The mitral E wave peak velocity and deceleration time vary with the variable cardiac cycle lengths, and the mitral A wave is absent. Pulmonary vein flow velocities are also affected; systolic forward flow is absent.

Most of the echocardiographic parameters that can be used to describe diastolic function in atrial fibrillation relate to elevated filling pressure. Peak acceleration of the mitral E velocity and shortened deceleration time are associated with increased filling pressures.^{48,49} The deceleration time of the mitral E wave, E/E', duration of the pulmonary diastolic forward flow, and deceleration time of the flow correlate with pulmonary artery wedge pressure by catheterization.^{27,50} However, if the E velocity is terminated early by a shorter cardiac cycle, measurement of deceleration time may not be reliable.

Time Interval Between Onset of Mitral Inflow and Onset of Early Diastolic Mitral Annular Velocity

In normal individuals, mitral valve E velocity and mitral annular E' velocity occur simultaneously. Normally, the mitral valve opens with rapid suction of the left ventricle so that early diastolic

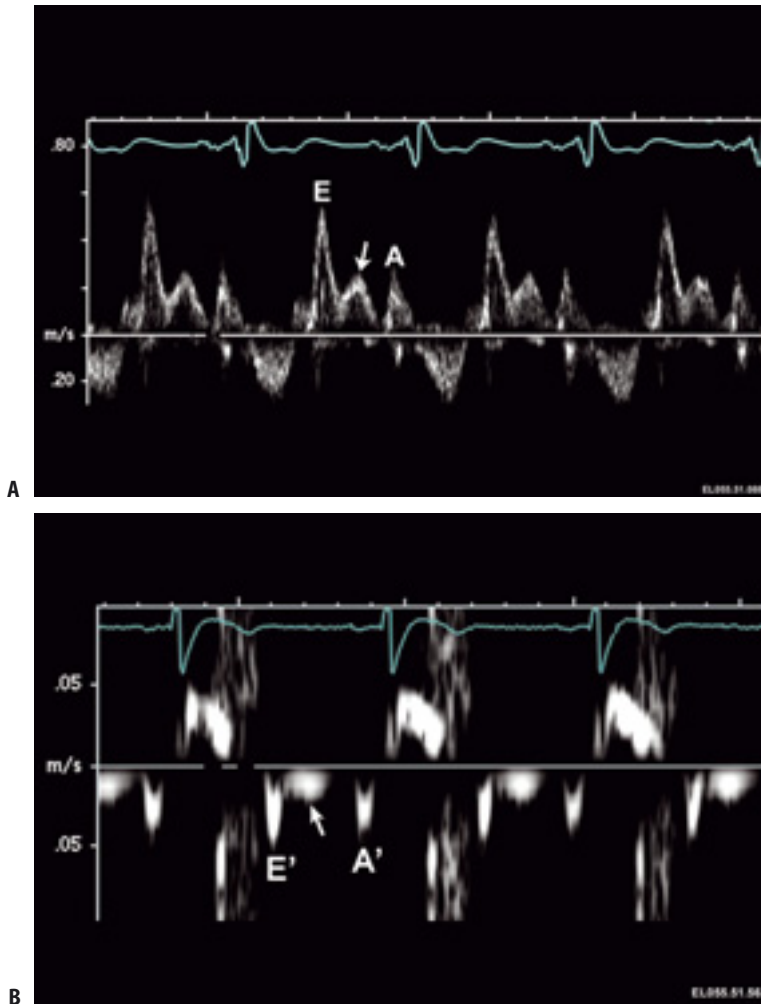


FIGURE 10.8. (A) Pulsed wave Doppler recording of mitral inflow velocity demonstrating mid diastolic flow (arrow) between E and A velocities. Mid diastolic flow velocity represents markedly delayed myocardial relaxation. This pattern usually indicates advanced diastolic dysfunction with at least moderately increased

filling pressures. (B) Tissue Doppler imaging of septal mitral annulus demonstrating a mid diastolic mitral annulus velocity (arrow) that corresponds to the mid diastolic velocity shown in the mitral inflow velocity recording.

filling occurs with mitral annular motion. With impaired relaxation, mitral annular motion begins after the onset of mitral inflow, and thus E' is delayed. Therefore, the delay between E' and mitral E velocity can be used to characterize diastolic dysfunction, with that time delay increasing with worsening diastolic function.^{51,52} The time interval between onset of mitral inflow and onset of early diastolic mitral annular velocity also correlates with pulmonary capillary wedge pressure.

Diagnosis of Diastolic Heart Failure

If a patient presents with symptoms of heart failure and systolic function is normal, DHF should be considered. It has been well demonstrated that impaired myocardial relaxation due to various causes is a major reason for DHF. This entity is distinctly different from systolic heart failure. The size of the myocytes in patients with DHF is larger than that of patients with systolic heart failure,

although the fraction of collagen and fibrosis is similar in both conditions,⁵³ which suggests that there is concentric myocyte hypertrophy in patients with DHF. This finding is consistent with the idea that DHF is related to an abnormality of an intrinsic myocardial diastolic property.⁵⁴

To establish the diagnosis of DHF, we need to demonstrate increased diastolic filling pressure as well as an abnormality in diastolic function. Myocardial relaxation is the initial property to become abnormal, and its impairment is usually necessary to develop increased filling pressure and DHF. Increased filling pressure and impaired myocardial relaxation can be reliably identified by comprehensive echocardiography using two-dimensional, Doppler, color flow imaging, and tissue Doppler imaging.⁵⁵ Recent advances in speckle tracking echocardiography and analysis of myocardial torsion^{56,57} will undoubtedly improve our ability to evaluate diastolic as well as systolic function by echocardiography. One important clinical mimicker for myocardial DHF is constrictive pericarditis. Diastolic heart failure due to myocardial dysfunction can also be reliably differentiated from clinically similar heart failure from constrictive pericarditis by echocardiography, as discussed in Chapter 21.

Patients with diastolic dysfunction remain asymptomatic for a long period of time. Before clinically apparent heart failure, they develop symptoms only with exertion because of the increased filling pressure with exercise. Doppler echocardiographic parameters that have been shown to correlate well with pulmonary capillary wedge pressure at resting stage also estimate filling pressure with exercise. A restrictive mitral inflow filling pattern corresponds to increased filling pressures, and an E/E' of ≥ 15 suggests pulmonary capillary wedge pressure >20 mm Hg. In normal individuals with well-maintained diastolic function, mitral E and A velocities and mitral annular E' and A' increase proportionally with exercise with no change in the E/A or E/E' ratio, because filling pressures do not increase much with exercise.^{58,59} However, patients with diastolic dysfunction usually develop a higher filling pressure with exercise and experience exertional dyspnea. The E/E' measured noninvasively during exercise has been correlated well with filling pressures measured by cardiac catheterization

simultaneously with measurement of E/E' by echocardiography.^{60,61} Estimation of filling pressure and evaluation of diastolic function with exercise as well as at resting stage will help identify patients with diastolic dysfunction earlier to prevent or at least slow down its progression to symptomatic DHF.

References

1. Fischer M, et al. Prevalence of left ventricular diastolic dysfunction in the community: results from a Doppler echocardiographic-based survey of a population sample. *Eur Heart J* 2003;24(4):320–328.
2. Redfield MM, et al. Burden of systolic and diastolic ventricular dysfunction in the community: appreciating the scope of the heart failure epidemic. *JAMA* 2003;289(2):194–202.
3. Hogg K, Swedberg K, McMurray J. Heart failure with preserved left ventricular systolic function: epidemiology, clinical characteristics, and prognosis. *J Am Coll Cardiol* 2004;43(3):317–327.
4. Vasan RS, et al. Congestive heart failure in subjects with normal versus reduced left ventricular ejection fraction: prevalence and mortality in a population-based cohort. *J Am Coll Cardiol* 1999;33(7):1948–1955.
5. Senni M, et al. Congestive heart failure in the community: a study of all incident cases in Olmsted County, Minnesota, in 1991. *Circulation* 1998;98(21):2282–2289.
6. Dauterman K, Massie B, Gheorghiade M. Managing the patient with advanced heart failure. *Am H J* 1998;135:S310–S319.
7. Hunt SA. ACC/AHA 2005 Guideline Update for the Diagnosis and Management of Chronic Heart Failure in the Adult: A Report of the American College of Cardiology/American Heart Association Task Force on Practice Guidelines (Writing Committee to Update the 2001 Guidelines for the Evaluation and Management of Heart Failure). *J Am Coll Cardiol* 2005;46(6):e1–82.
8. European Study Group on Diastolic Heart Failure. How to diagnose diastolic heart failure. *Eur Heart J* 1998;19(7):990–1003.
9. Vasan RS, Levy D. Defining diastolic heart failure: a call for standardized diagnostic criteria. *Circulation* 2000;101(17):2118–2121.
10. Zile MR, et al. Heart failure with a normal ejection fraction: is measurement of diastolic function necessary to make the diagnosis of diastolic heart failure? *Circulation* 2001;104(7):779–782.

11. Khan A, et al. The cardiac atria are chambers of active remodeling and dynamic collagen turnover during evolving heart failure. *J Am Coll Cardiol* 2004;43(1):68–76.
12. Tsang TSM, et al. Left atrial volume as a morpho-physiologic expression of left ventricular diastolic dysfunction and relation to cardiovascular risk burden. *Am J Cardiol* 2002;90(12):1284–1289.
13. Liang H, et al. Comparison of usefulness of echocardiographic Doppler variables to left ventricular end-diastolic pressure in predicting future heart failure events. *Am J Cardiol* 2006;97(6):866–871.
14. Tsang TSM, et al. Prediction of risk for first age-related cardiovascular events in an elderly population: the incremental value of echocardiography. *J Am Coll Cardiol* 2003;42(7):1199–1205.
15. Ren J, et al. Two-dimensional echocardiographic determination of left atrial emptying volume: a noninvasive index in quantifying the degree of nonrheumatic mitral regurgitation. *J Am Coll Cardiol* 1983;729–736.
16. Appleton C, Hatle L, Popp R. Relation of trans-mitral flow velocity patterns to left ventricular diastolic function: new insights from a combined hemodynamic and Doppler echocardiographic study. *J Am Coll Cardiol* 1988;12:426–440.
17. Oh JK, et al. The noninvasive assessment of left ventricular diastolic function with two-dimensional and Doppler echocardiography. *J Am Soc Echocardiogr* 1997;10:246–270.
18. Yamamoto K, et al. Assessment of left ventricular end-diastolic pressure by Doppler echocardiography: contribution of duration of pulmonary venous versus mitral flow velocity curves at atrial contraction. *J Am Soc Echocardiogr* 1997; 10(1):52–59.
19. Rossvoll O, Hatle L. Pulmonary venous flow velocities recorded by transthoracic Doppler ultrasound: relation to left ventricular diastolic pressures. *J Am Coll Cardiol* 1993;21(7):1697–1700.
20. Appleton C. Hemodynamic determinants of Doppler pulmonary venous flow velocity components: new insights from studies in lightly sedated dogs. *J Am Coll Cardiol* 1997;30:1562–1574.
21. Kinnaird T, Thompson C, Munt B. The deceleration time of pulmonary venous diastolic flow is more accurate than the pulmonary artery occlusion pressure in predicting left atrial pressure. *J Am Coll Cardiol* 2001;37:2025–2030.
22. Sohn D, et al. Assessment of mitral annular velocities by Doppler tissue imaging in the evaluation of left ventricular diastolic function. *J Am Coll Cardiol* 1997;30:474–480.
23. Nagueh S, et al. Hemodynamic determinants of the mitral annulus diastolic velocities by tissue Doppler. *J Am Coll Cardiol* 2001;37:278–285.
24. Nagueh S, et al. Doppler tissue imaging: a noninvasive technique for evaluation of left ventricular relaxation and estimation of filling pressures. *J Am Coll Cardiol* 1997;30:1527–1533.
25. Ommen S, et al. Clinical utility of Doppler echocardiography and tissue Doppler imaging in the estimation of left ventricular filling pressures. *Circulation* 2000;102:1788–1794.
26. Sohn D, et al. Evaluation of left ventricular diastolic function when mitral E and A waves are completely fused: role of assessing mitral annulus velocity. *J Am Soc Echocardiogr* 1999;12(3):203–208.
27. Sohn D, et al. Mitral annulus velocity in the evaluation of left ventricular diastolic function in atrial fibrillation. *J Am Soc Echocardiogr* 1999;12(11):927–931.
28. Nagueh SF, et al. Doppler estimation of left ventricular filling pressure in sinus tachycardia: a new application of tissue Doppler imaging. *Circulation* 1998;98(16):1644–1650.
29. Brun P, et al. Left ventricular flow propagation during early filling is related to wall relaxation: a color M-mode Doppler analysis. *J Am Coll Cardiol* 1992;20:420–432.
30. Takatsuji H, et al. A new approach for evaluation of left ventricular diastolic function: Spatial and temporal analysis of left ventricular filling flow propagation by color M-mode Doppler echocardiography. *J Am Coll Cardiol* 1996;27(2):365–371.
31. de Boeck B, et al. Colour M-mode velocity propagation: a glance at intra-ventricular pressure gradients and early diastolic ventricular performance. *Eur J Heart Fail* 2005;7(1):19–28.
32. Gonzales-Vilchez F, et al. Comparison of Doppler echocardiography, color M-mode Doppler, and Doppler tissue imaging for the estimation of pulmonary capillary wedge pressure. *J Am Soc Echocardiogr* 2002;15:1245–1250.
33. Gonzales-Vilchez F, et al. Combined use of pulsed and color M-mode Doppler echocardiography for the estimation of pulmonary capillary wedge pressure: an empirical approach based on an analytical relation. *J Am Coll Cardiol* 1999;34:515–523.
34. Takeda K, et al. Dependence of flow propagation velocity on cardiac size: observations from patients with dilated cardiomyopathy and hypertrophic cardiomyopathy [abstr]. *J Am Coll Cardiol* 2002;39:383A–384A.
35. Spencer K, Weinert L, Lang R. Effect of age, heart rate, and tricuspid regurgitation on the Doppler echocardiographic evaluation of right ventricular diastolic function. *Cardiology* 1999;92(1):59–64.
36. Ommen S, et al. Assessment of right atrial pressure with 2-dimensional and Doppler echocardiography: a simultaneous catheterization and

- echocardiographic study. *Mayo Clin Proc* 2000; 75(1):24–9.
37. Appleton C, Hatle L, Popp R. Superior vena cava and hepatic vein Doppler echocardiography in healthy adults. *J Am Coll Cardiol* 1987;10(5):1032–1039.
 38. Burstow D, et al. Cardiac tamponade: characteristic Doppler observation. *Mayo Clin Proc* 1989;64(3): 312–324.
 39. Mancuso L, et al. Constrictive pericarditis versus restrictive cardiomyopathy: the role of Doppler echocardiography in differential diagnosis. *Int J Cardiol* 1991;31(3):319–327.
 40. Nishimura R, Tajik AJ. Evaluation of diastolic filling of the left ventricle in health and disease: Doppler echocardiography is the clinician's Rosetta stone. *J Am Coll Cardiol* 1997;30(1):8–18.
 41. Kitzman DW, et al. Age-related alterations of Doppler left ventricular filling indexes in normal subjects are independent of left ventricular mass, heart rate, contractility and loading conditions. *J Am Coll Cardiol* 1991;18(5):1243–1250.
 42. Spirito P, Maron BJ. Influence of aging on Doppler echocardiographic indices of left ventricular diastolic function. *Br Heart J* 1988;59(6):672–679.
 43. Klein AL, et al. Effects of age on left ventricular dimensions and filling dynamics in 117 normal persons. *Mayo Clinic Proc* 1994;69(3):212–224.
 44. Oh J, et al. Diastolic heart failure can be diagnosed by comprehensive two-dimensional and Doppler echocardiography. *J Am Coll Cardiol* 2006;47(3):500–506.
 45. Hurrell D, et al. Utility of preload alteration in assessment of left ventricular filling pressure by Doppler echocardiography: a simultaneous catheterization and Doppler echocardiographic study. *J Am Coll Cardiol* 1997;30(2):459–467.
 46. Ha J-W, et al. Triphasic mitral inflow velocity with mid diastolic filling: clinical implications and associated echocardiographic findings. *J Am Soc Echocardiogr* 2004;17(5):428–431.
 47. Ha J-W, et al. Triphasic mitral inflow velocity with mid-diastolic flow: the presence of mid-diastolic mitral annular velocity indicates advanced diastolic dysfunction. *Eur J Echocardiogr* 2006;7(1):16–21.
 48. Nagueh SF, Kopelen HA, Quinones MA. Assessment of left ventricular filling pressures by Doppler in the presence of atrial fibrillation. *Circulation* 1996;94(9):2138–2145.
 49. Hurrell D, et al., Short deceleration time of mitral inflow E velocity: prognostic implication with atrial fibrillation from transthoracic Doppler indexes of mitral and pulmonary venous flow velocity. *J Am Coll Cardiol* 1998;30:19–26.
 50. Chirillo M, et al. Estimating mean pulmonary wedge pressure in patients with chronic atrial fibrillation from transthoracic Doppler indexes of mitral and pulmonary venous flow velocity. *J Am Coll Cardiol* 1997;30(1):19–26.
 51. Rivas-Gotz C, et al. Time interval between onset of mitral inflow and onset of early diastolic velocity by tissue Doppler: a novel index of left ventricular relaxation: experimental studies and clinical application. *J Am Coll Cardiol* 2003;42(8):1463–1470.
 52. Hasegawa H, et al. Diastolic mitral annular velocity during the development of heart failure. *J Am Coll Cardiol* 2003;41(9):1590–1597.
 53. van Heerebeek L, et al. Myocardial structure and function differ in systolic and diastolic heart failure. *Circulation* 2006;113:1966–1973.
 54. Zile M, et al. Diastolic heart failure—abnormalities in active relaxation and passive stiffness of the left ventricle. *N Engl J Med* 2004;350(19):1953–1959.
 55. Oh J, Hatle L, et al. Diastolic heart failure can be diagnosed by comprehensive two-dimensional and Doppler echocardiography. *J Am Coll Cardiol* 2006;47(3):500–506.
 56. Helle-Valle T, et al. New noninvasive method for assessment of left ventricular rotation: speckle tracking echocardiography. *Circulation* 2005;112:3149–3156.
 57. Notomi Y, et al. Assessment of left ventricular torsional deformation by Doppler tissue imaging: validation study with tagged magnetic resonance imaging. *Circulation* 2005;111:1141–1147.
 58. Ha J-W, et al. Effects of treadmill exercise on mitral inflow and annular velocities in healthy adults. *Am J Cardiol* 2003;91(1):114–115.
 59. Ha J-W, et al. Diastolic stress echocardiography: a novel noninvasive diagnostic test for diastolic dysfunction using supine bicycle exercise Doppler echocardiography. *J Am Soc Echocardiogr* 2005; 18(1):63–68.
 60. Talreja D, Nishimura R, Oh J. Noninvasive parameters of diastolic function reflect invasively measured filling pressures during exercise [abstr 2235]. *Circulation* 2004;110(17):III-474.
 61. Burgess MI, Jenkins C, Sharman JE, Marwick TH. Diastolic stress echocardiography: hemodynamic validation and clinical significance of estimation of ventricular filling pressure with exercise. *J Am Coll Cardiol* 2006;47(9):1891–1900.



<http://www.springer.com/978-1-84628-890-6>

Diastolic Heart Failure

Smiseth, O.A.; Tendera, M. (Eds.)

2008, XIII, 349 p., Hardcover

ISBN: 978-1-84628-890-6