

Neuroacanthocytosis in Japan – Review of the Literature and Cases

G. Hirose

1	Introduction and Historical Review	76
2	Epidemiology and Genetic Inheritance of Probable Chorea-Acanthocytosis.....	77
3	Clinical Characteristics of Probable Chorea-Acanthocytosis from 25 Early Cases	79
4	Further Neurobiologic Studies.....	80
5	Contemporary Neurobiological Studies of Neuroacanthocytosis.....	81
	References.....	82

Abstract Since the first case report of this disease in 1974, a total of 71 cases of probable chorea-acanthocytosis (ChAc) were collected in Japan up to the end of 2006. These reports were reviewed for their clinical features and to document research achievements in Japan in this field. Whilst the clinical phenotype of these patients was typical of ChAc, most of these cases were diagnosed clinically without molecular diagnosis, so the diagnosis of McLeod syndrome cannot be completely excluded.

The mean age of onset was 30.5 (range 18–42) years and the male:female ratio was 18:7. Involuntary movements consisting of oro-lingual-facial dyskinesias and choreiform limb movements were seen in over 90% of cases. Self-mutilation of the lower lip was also seen with the same incidence. Depression or absence of deep tendon reflexes was noted in almost all cases. Cognitive impairment with or without psychiatric symptoms was noted in 40% of cases. The degree of acanthocytosis of peripheral red blood cells varied from 6 to 80% (mean value 24%). Serum creatine phosphokinase activity was increased in 86%. Computed tomography of the brain revealed symmetrical atrophy of the caudate nuclei in almost all cases examined. Forty percent of patients had seizures. The mode of transmission was predominantly autosomal recessive, but four families have been reported with apparent dominant inheritance. Sural nerve biopsy showed evidence of chronic denervation with axonopathy. Grouped atrophy of muscle fibers was also reported, but recent studies suggest a primary disorder of the muscle membrane or muscle fibers as a

G. Hirose

Department of Neurology, Neurological Center, Asanogawa General Hospital, Japan
Mailing address: Naka 83, Kosaka-cho, Kanazawa City, Ishikawa Prefecture, 920-8621, Japan
ghirose@asanogawa-gh.or.jp

cause of elevated creatine kinase. *Post mortem* examination of the brain revealed marked neuronal loss and gliosis affecting the caudate nucleus and pallidum. The cerebral cortex and substantia nigra seemed to be spared. 15 cases of McLeod syndrome were identified in Japan between 1994 and 2006.

Many scientific advances were made in Japan with respect to ChAc. The red cell membrane pathology was studied morphologically as well as biochemically. Abnormal conformation of the red cell membrane was found, with an increase of palmitic and docosahexaenoic acids and a decrease of stearic acid. A mutation in the gene coding for a protein designated “chorein” was found and reported in a Japanese family with autosomal recessive inheritance, and a new single heterozygous frame shift mutation was also found from a family with apparent autosomal dominant inheritance. In addition, a gene-targeted mouse model of ChAc was reported from our country. The future of research in the area of ChAc in Japan is very promising.

1 Introduction and Historical Review

Levine and his colleagues [19] and Critchley and his associates [5] independently published a new syndrome of hereditary neurological disease with acanthocytosis in two different families, the Goode family from New England and the Stevens family from Eastern Kentucky in 1968. Thereafter another three families were reported, two from England and one family from the United States. However, recognition of the disease in Japan was delayed for about 10 years.

The first case of probable ChAc was reported in a local medical journal of Hiroshima Prefecture, the Journal of the Hiroshima Medical Association, in 1978 by Professor Kito and colleagues [11] of Hiroshima University Medical School. Clinical studies were reported, in addition to scanning microscopic findings of acanthocytes, neurogenic atrophy of muscle fibers, and caudate nucleus atrophy, in a 50-year-old man with a family history of a similar neurological disease in his younger brother and paternal uncle. The authors published a detailed family pedigree with apparent autosomal dominant inheritance in 1980 [16]. The authors claimed that their family was the first with this disorder in Japan and the sixth family in the world. However, looking back at previous reports of this disorder in our country, there is an earlier case report by Shimizu et al. [32] in 1974. These authors described an adult patient with self-mutilation, choreoathetosis, hypotonia, areflexia and normouricemia. They considered this patient to have a new disease, distinct from Lesch–Nyhan syndrome, without recognising acanthocytosis. In 1978 [33], however, they found acanthocytes in the patient’s younger brother in addition to the patient. The authors subsequently reported the family in more clinical detail, and also found a reduced ratio of C24:1/C24:0 fatty acids in sphingomyelin from red cell membranes [14].

During the following 10 years, 25 well-studied cases of probable ChAc were rapidly accumulated with salient clinical features [1, 2, 8, 11, 15, 17, 18, 21, 22, 28, 32–34, 41], including our familial cases. The clinical characteristics, family history, neuroimaging and hematological results, of these earlier fully reported 25 cases, are summarized in Table 1.

Japanese cases of probable ChAc were further identified by search of the Japana Centro Revuo Medicina (JCRV), the Japanese version of Index Medicus, a collection of abstract-form reports from about 4700 Japanese journals and periodicals, established in 1903 by Dr. Shiro Amako. By the end of 2006, a total of at least 71 cases were collected. In addition to the 25 cases from 1974 to 1983, reported above, 25 cases were reported from 1984 to 1990, 10 cases from 1991 to 2000, and 11 cases from 2001 to 2006. This abundance of reports has facilitated the progress of molecular biological studies of these disorders.

Cases of MLS were also identified from the same source (JCRV) and PubMed. The first case of MLS in Japan was reported in 1994 by Takashima et al. with molecular genetic diagnosis [35]. Since then, 12 cases of molecularly-diagnosed MLS were published, with three cases of chronic granulomatous disease associated with acanthocytosis. In addition to these 13 cases, two cases of Japanese patients were reported in the Western literature [40]. No cases of Huntington's disease-like 2 have yet been reported in our country among patients referred for Huntington's disease testing [20].

2 Epidemiology and Genetic Inheritance of Probable Chorea-Acanthocytosis

From 1974 to 2005, at least 71 cases of probable ChAc were reported in Japan, according to this search of the Japanese literature. Most cases were diagnosed clinically without any molecular studies, except for the most recent five cases of ChAc. Without definitive molecular testing, McLeod syndrome or other diseases with acanthocytosis and choreiform involuntary movements cannot be excluded. The patients were widely distributed throughout Japan, including Hokkaido, Honshu, Sikoku and Kyushu islands, with some preponderance of the western part of Japan, but without any endemic areas (Fig. 1).

The mode of transmission seems to be predominantly autosomal recessive. Among the early well-studied 25 cases, 20 cases occurred in 14 families. There was autosomal recessive inheritance in 12 families and autosomal dominant (AD) inheritance in 2 families. In these two AD families, a paternal uncle and paternal grandfather suffered a similar neurodegenerative disease, excluding X-linked inheritance. No X-linked pedigree was reported in these cases. Five cases were apparently sporadic in this series. Recently two more families of molecularly confirmed ChAc were reported with an inheritance pattern strongly suggestive of AD inheritance [10, 26].

Table 1 Summary of clinical features of 25 early Japanese cases of probable chorea-acanthocytosis

References	Age	Sex	Age of onset (year)	IVM	Self-mutil.	DTR	Sz	IQ < 80	Acanthocytes (%)	Caudate atrophy	CPK	FH Inherit
[32]	22	M	18	+	+	hypo	-	98	6-7	+	high	+AR
[33]	34	F	20	+	+	hypo	GM	72	6-7	+	NL	-
[11]	50	M	36	+	ND	hypo	-	104	+	+	ND	+AD
[22]	38	F	29	+	+	NL	GM	90	30	+	high	+AR
[15]	44	M	34	+	+	hypo	-	NL	8	-	high	+AR
	47	F	25	+	+	hypo	+	NL	6-7	+	high	+AR
	45	F	31	+	-	ND	+	ND	bizarre E	ND	ND	+AR
[41]	41	M	34	+	+	hypo	-	low	30-35	+	high	+AR
	40	F	34	+	+	hypo	+	low	6-7	+	high	+AR
[18]	36	M	32	+	+	hypo	+	76	40-50	+	high	+AR
	37	M	34	+	+	hypo	GM	90	10-20	+	high	+AR
[8]	50	M	35	+	+	hypo	GM	73	20	+	NL	+AR
[21]	35	F	31	+	+	ND	GM	ND	10	ND	ND	+AR
[2]	38	M	24	+	+	hypo	-	NL	10-20	+	high	+AD
[29]	31	M	28	+	+	hypo	-	NL	30-80	+	high	+AR
	47	M	27	+	+	hypo	-	NL	50-80	+	high	+AR
	37	M	34	+	+	hypo	-	90	20-30	+	high	-
[17]	37	M	32	-	+	hypo	-	low	45	+	high	+AR
	30	F	27	+	+	hypo	-	81	26	+	high	+AR
	46	M	42	+	+	hypo	GM	88	26	+	high	-
	47	M	40	-	+	hypo	-	97	15	+	high	-
	28	M	28	+	+	hypo	-	64	57	+	high	+AR
	22	M	ND	+	-	hypo	-	90	58	+	high	+AR
[34]	26	M	21	+	+	hypo	-	72	6	+	high	+AR
[1]	46	F	37	+	+	hypo	-	NL	20	+	NL	-
Total 25 cases	-	18:7	30.5	23/25	22/24	22/23	10/25	10/25	6-80%	23/23	19/22	AR:AD=18:2
Mean value	38.2	-	-	-	-	-	-	-	24%	-	-	-

AD autosomal dominant, AR autosomal recessive, *bizarre E* bizarre erythrocytes, CPK creatine phosphokinase, DTR deep tendon reflexes, F female, FH inherit family history and inheritance pattern, GM grand mal type of seizure, hypo hypoactive, IVM involuntary movements, M male, ND not described, NL normal, trait, Sz seizure, Self mutil. self-mutilation

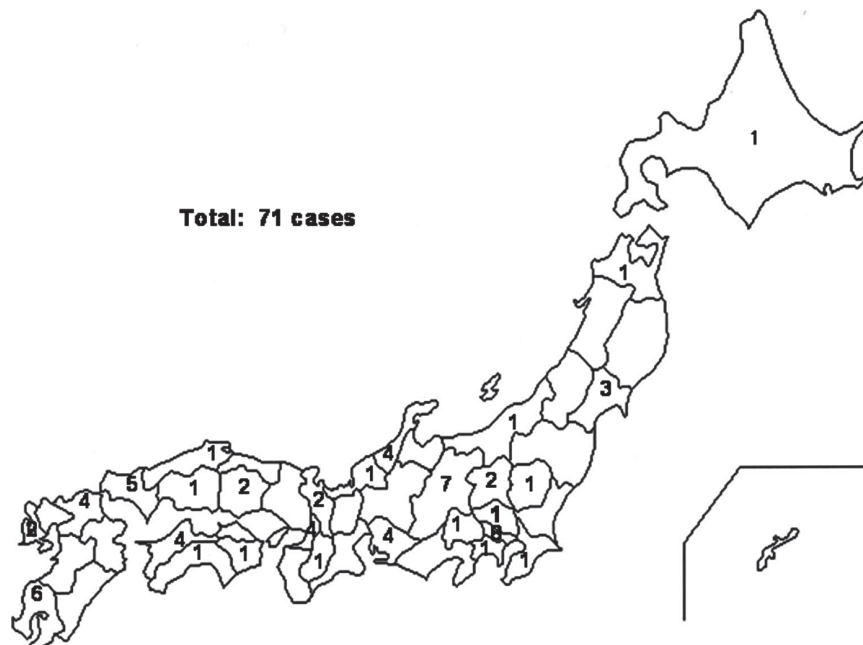


Fig. 1 Distribution of patients with probable chorea-acanthocytosis in Japan

3 Clinical Characteristics of Probable Chorea-Acanthocytosis from 25 Early Cases

The disease onset varied from 18 to 42 years old with the mean age of onset at 30.5 years. The male:female ratio was 18:7. No X-linked family pedigree of disease inheritance was reported in these male patients. Choreiform involuntary movements were noted in 23 of 25 cases, with mainly oro-lingual-buccal dyskinesia and choreiform limb movements. The knee-buckling gait (flamingo-like walk), often seen in patients with Huntington's disease (HD), was noted in four cases among 25 [22, 33, 42]. Twenty-two patients of 23 had decreased deep tendon reflexes suggesting polyneuropathy. Self-mutilation was noted in 22 patients of 24. Among 14 cases of MLS reported in Japan, self-mutilation was not noted except for one patient with a tongue scar due to a bite [35]. Severe oro-facial dyskinesia with lip-biting was considered to most likely indicate a diagnosis of ChAc. WAIS-IQ less than 80 was reported in ten cases of 25. Seizures were seen in ten, and of those, generalized seizures of the grand mal type were reported in six, complicated in one by additional psychomotor seizures.

The clinical characteristics of the involuntary movements (IVM) in probable ChAc included orolingual choreic movements associated with vocalization, biting

of the lower lip and tongue, and facial grimacing, dysphagia with bird-like drinking, choreiform limb and trunk movements, and postural lapse with abrupt buckling of the knees occasionally seen in patients with HD [42]. When 14 molecularly diagnosed MLS cases were compared to patients with ChAc, choreiform limb movements were milder, and no lip self-mutilations, facial tics or dysphagia were noted. In general, these differences appear to clinically differentiate ChAc from MLS in most cases of neuroacanthocytosis (NA).

Polygraphic and jerk-locked averaging techniques revealed different characteristics of IVM between patients with probable ChAc and HD [31]. Slow negativity before IVM, similar to the *Bereitschaftspotential* was seen only in the patients with probable ChAc, but not in those with HD.

Neuroimaging studies in these disorders were usually performed by computed tomography (CT) of the brain, but single photon emission computed tomography (SPECT) and positron emission tomography (PET) were also used on rare occasions. Brain CT was reported in 23 cases and atrophy of the caudate nucleus was noted in all. ¹⁸Fluoro-deoxyglucose-PET study in five patients with choreiform syndromes, including probable ChAc, revealed hypometabolism in the striatum bilaterally, similar to that seen in HD [9].

Laboratory examinations including routine blood and urine analyses were unremarkable. The most important hematological finding was of acanthocytes in the peripheral wet smear preparation, with a range of 6–80% of red blood cells and a mean value of 24%. Markedly raised serum creatine phosphokinase (CPK) was noted in 19 cases out of 22. These characteristics were quite similar to the clinical data described among cases from England by Hardie and associates [7].

4 Further Neurobiologic Studies

Based on the abundant reports of probable ChAc in Japan, basic scientific studies were performed in a number of institutions. A number of erythrocyte membrane studies were carried out [3, 24, 38]. A study using freeze-fracture electron microscopy showed a significant increase of the intramembranous particle free areas in both P and F faces [38]. The fluidity deep inside the red cell membrane in this disorder was studied using a spin labeling technique, and low fluidity was found when compared to that of normal red blood cells [24]. The same group also studied the capacity of self-digestion of red blood cells and reported easily self-digestible conformation of the red cell membrane in patients with probable ChAc [3]. Sakai et al. reported the abnormal membrane property of acanthocytes in patients with probable ChAc [29]. Analysis of covalently (tightly) bound fatty acids in erythrocyte membrane proteins after alkaline hydrolysis disclosed an increase of palmitic and docosahexaenoic (C22:6) acids and a decrease of stearic acid in this disease.

Muscle biopsy examination in the patients with distal amyotrophy due to probable ChAc revealed a typical neurogenic grouped atrophy with fibre-type grouping, suggestive of chronic polyneuropathy [11, 17]. Histological studies of the sural

nerve biopsy showed axonal degeneration associated with secondarily demyelinating changes. The density of total myelinated fibers was slightly decreased with more involvement of large myelinated fibers [22, 23].

In addition to neurogenic changes in muscle biopsy, evidence now supports a primary muscle fiber or membrane disorder to explain elevated CPK in this disease. Nemaline rods were noted in the subsarcolemmal and paranuclear locations of the muscle biopsy of probable ChAc [36]. This strongly suggests a primary disorder in the muscle membranous structure in this disease. Dilated cardiomyopathy with skeletal myopathy was also reported in a case of ChAc in which MLS was definitively excluded [13]. We also have an evidence of abnormally disrupted ChAc expression in the muscle membrane, stained histochemically with the anti-chorein antibody (in preparation).

Post mortem neuropathological studies of probable ChAc were reported by Iwata et al. [12] and Sato et al. [30]. These authors found atrophy and gliosis of the caudate nuclei and putamen, with no neuronal loss in the cerebral cortex or other parts of the brain, including the substantia nigra. Degeneration and gliosis was the most marked in the head of the caudate, followed in the body and the tail. The numbers of small neurons in the caudate nucleus and putamen were greatly reduced to 1% and 20% of each healthy control respectively. On the other hand, large neurons of the caudate decreased in diameter but not in number. The ventral portion of the putamen was also moderately degenerated. These findings are quite similar to those reported by Bird et al. [4] and Hardie et al. [7]. Sato's group also studied biochemical changes of the striatum in their autopsy case. They found marked a decrease of substance P (SP) level without any changes of choline acetyltransferase or glutamic acid decarboxylase (GAD) in both the caudate nucleus and putamen [30]. However, GAD and SP activity were decreased in the substantia nigra where there were no histopathological abnormalities.

Neurosurgical management of probable ChAc with posteroventral pallidotomy (PVP) was reported in one case with severe intractable involuntary movements [6] and see chapter by Yokochi and Burbaud. A 41-year-old man suffered from marked oro-lingual dyskinesia which gave him marked difficulty with eating and swallowing. A left PVP was done initially with a marked reduction of oro-lingual dyskinesia and chorea of the right limbs. Subsequently he had a PVP of the right side with reduction of the left-sided choreo-ballistic movements. The same authors have performed a bilateral PVP for another patient with ChAc with a complete remission of involuntary movements (see chapter by Yokochi and Burbaud). The exact mechanism of the effect by this surgical procedure has not yet been clearly explained.

5 Contemporary Neurobiological Studies of Neuroacanthocytosis

The heterogeneous group of NA disorders can now be clearly classified on the basis of molecular genetic studies. The principal NA syndromes are autosomal recessive ChAc and X-linked McLeod syndrome, but now Huntington's disease-like 2 and

pantothenate kinase-associated neurodegeneration can be included. All of these diseases share common neurological manifestations with involuntary movements, progressive deterioration of the higher cortical function, and can be diagnosed by clinical, laboratory and imaging techniques as well as by detecting gene mutations.

A number of highly significant advances in autosomal recessive ChAc have recently been reported from Japan. The disease has been linked in most families to chromosome 9q21, where Ueno and colleagues found a mutation in the gene encoding a large (3100 amino acids) protein designated “*chorein*” in 2001 [39]. A deletion was found in the coding region of the cDNA leading to a frame shift, resulting in the production of a truncated protein in both alleles of the patients and single alleles of the obligate carriers. This protein is thought to be an evolutionarily conserved protein that is probably involved in the cellular protein sorting and trafficking [25]. We have also reported a family with apparent autosomal dominant inheritance. From this family, our group found a novel single heterozygous frame shift mutation in the last nucleotide of exon 57 of the ChAc gene in 2003 [26]. In order to rule out Huntington’s disease-like 2, in which autosomal dominant inheritance is seen, expansion of the CTG/CAG repeat within junctophilin-3 gene was excluded [27]. Our findings confirm that clinical features in patients with ChAc with apparent autosomal dominant inheritance does not differ from those in a recessive form. It remains unclear why one mutation in the ChAc gene causes recessive inheritance in one family and another mutation within the same gene causes an apparent autosomal dominant inheritance of ChAc.

Tomemori and colleagues produced a gene-targeted mouse model for ChAc in 2005 [37]. They identified the mouse ChAc cDNA sequence and the exon–intron structures of the gene, and produced a ChAc model mouse by introducing a deletion of 60–61 exons, using a gene-targeting technique. Hematological study of this model revealed typical acanthocytes in the peripheral blood with a marked increase of the osmotic fragility of red blood cells. Motor evaluation of these animals during late adult stages showed statistically significant changes with a shorter stride length, poorly coordinated balance in the Rotarod test, and decreased locomotor activity as compared to control animals. No involuntary movements were observed in this mouse model. Histopathological study also confirmed striatal degeneration with gliosis, consistent with the findings in humans with ChAc.

As a number of important neuroscientific advances in ChAc have come from Japan in recent years, we anticipate that this is a most promising arena for further developments in the study of NA syndromes, in particular ChAc.

References

1. Araki J, Tatsumi Y, Sannomiya Y et al. (1983) A case of chorea-acanthocytosis. *Jpn J Clin Hematol* 24:1055–1059
2. Arima S, Mori R, Kato N (1980) A case of the familial chorea with acanthocytosis. *Clin Neurol (Rinsho Shinkeigaku)* 20:1069–1070

3. Asano K, Osawa Y, Yanagisawa N et al. (1985) Erythrocyte membrane abnormalities in patients with amyotrophic chorea with acanthocytosis. Part 2. Abnormal degradation of membrane protein. *J Neurol Sci* 68:161–173
4. Bird TD, Cederbaum S, Valpey RW et al. (1978) Familial degeneration of the basal ganglia with acanthocytosis: a clinical, neuropathological, and neurochemical study. *Ann Neurol* 3:253–258
5. Critchley EMR, Clark DB, Wikler A (1968) Acanthocytosis and neurological disorder without abetalipoproteinemia. *Arch Neurol* 18:134–140
6. Fujimoto Y, Isozaki E, Yokochi F et al. (1997) A case of chorea-acanthocytosis successfully treated with posteroventral pallidotomy. *Clin Neurol (Rinsho Shinkeigaku)* 37:891–894
7. Hardie RJ, Pullon HW, Harding AE et al. (1991) Neuroacanthocytosis. A clinical, haematological and pathological study of 19 cases. *Brain* 114:13–49
8. Hirayama K, Yamada T (1980) Familial neuro-acanthocytosis in adult. Special consideration on symptomatology of involuntary movements. *Clin Neurol (Rinsho Shinkeigaku)* 20:1064–1066
9. Hosokawa S, Ichiya Y, Kuwabara Y et al. (1987) Positron emission tomography in cases of chorea with different underlying diseases. *J Neurol Neurosurg Psychiatry* 50:1284–1287
10. Ichiba M, Muroya S, Mizuno E et al. (2005) A CHAC-pedigree of with semi-dominant inheritance. *Ann Rep Mitsubishi Pharma Res Found* 37:35–41
11. Itoga E, Kito S, Tsubota W et al. (1978) A case of amyotrophic chorea with acanthocytosis. *J Hiroshima Med Ass* 31:772–775
12. Iwata M, Toyokura Y, Sakuta M et al. (1981) Neuropathology of chorea-acanthocytosis (Levine–Critchley syndrome). *Neurol Med* 15:132–145
13. Kageyama Y, Kodama Y, Tadano M et al. (2000) A case of chorea-acanthocytosis with dilated cardiomyopathy and myopathy. *Clin Neurol (Rinsho Shinkeigaku)* 40:816–820
14. Kamakura K, Shimizu T, Toyokura Y et al. (1981) Chorea-acanthocytosis (Levine–Critchley syndrome). Report of a family with biochemical study. *Neurol Med* 15:1–7
15. Kawazawa S, Kashiwamura K, Takamatsu S et al. (1979) Self-mutilation, choreiform movement, areflexia and acanthocytosis. Report of three cases. *Neurol Med* 10:486–488
16. Kito S, Itoga E, Hiroshige Y et al. (1980) A pedigree of amyotrophic chorea with acanthocytosis. *Arch Neurol* 37:514–517
17. Kondo K, Yanagisawa N (1981) Familial chorea with neuropathy and acanthocytosis. Report of six cases with special reference to its clinical variety. *Neurol Med* 15:118–127
18. Kooriyama T, Yoshida Y, Nakamura N et al. (1980) Pathogenesis of chorea with acanthocytosis. *Clin Neurol (Rinsho Shinkeigaku)* 20:1076–1078
19. Levine IM, Estes JW, Looney JM (1968) Hereditary neurological disease with acanthocytosis. *Arch Neurol* 19:403–409
20. Margolis RL, Holmes SE, Rosenblatt A et al. (2004) Huntington's disease-like 2 in North America and Japan. *Ann Neurol* 56:670–674
21. Mori K, Ide Y, Haku R et al. (1980) A case with choreic involuntary movement and acanthocytosis, who responded to steroid treatment. *Clin Neurol (Rinsho Shinkeigaku)* 20:1071–1072
22. Nagashima T, Iwashita H, Kuroiwa Y et al. (1979) Chorea-acanthocytosis. A report of a family. *Clin Neurol (Rinsho Shinkeigaku)* 19:609–615
23. Ohnishi A, Sato Y, Nagara H et al. (1981) Neurogenic muscular atrophy and low density of large myelinated fibers of sural nerve in chorea-acanthocytosis. *J Neurol Neurosurg Psychiatry* 44:645–648
24. Oshima M, Osawa Y, Asano K et al. (1985) Erythrocyte membrane abnormalities in patients with amyotrophic chorea with acanthocytosis. Part 1. Spin labeling studies and lipid analysis. *J Neurol Sci* 68:147–160
25. Rampoldi L, Dobson-Stone C, Rubio JP et al. (2001) A conserved sorting-associated protein is mutant in chorea-acanthocytosis. *Nat Genet* 28:119–120
26. Saiki S, Sakai K, Kitagawa Y et al. (2003) Mutation in the CHAC gene in a family of autosomal dominant chorea-acanthocytosis. *Neurology* 61:1614–1616

27. Saiki S, Sakai K, Saiki M et al. (2004) Huntington's disease-like 2 can present as chorea-acanthocytosis. *Neurology* 63:939–940
28. Sakai T, Iwashita H, Sato Y et al. (1980) Chorea-acanthocytosis: familial and sporadic case. *Clin Neurol (Rinshou Shinkeigaku)* 20:1062–1063
29. Sakai T, Antoku Y, Iwashita H et al. (1991) Chorea-acanthocytosis: abnormal composition of covalently bound fatty acids of erythrocyte membrane proteins. *Ann Neurol* 29:664–669
30. Sato Y, Ohnishi A, Tateishi J et al. (1984) An autopsy case of chorea-acanthocytosis. Special reference to the histopathological and biochemical findings of basal ganglia. *Brain Nerve* 36:105–111
31. Shibasaki H, Sakai T, Nishimura H et al. (1982) Involuntary movements in chorea-acanthocytosis: a comparison with Huntington's chorea. *Ann Neurol* 12:311–314
32. Shimizu T, Inoue K, Sugita H et al. (1974) Self-mutilation, choreoathetosis, muscular hypotonia, absence of deep tendon reflexes and normouricemia. Report of adult case. *Neurol Med* 1:135–136
33. Shimizu T, Kamakura K (1978) A new acanthocytosis syndrome associated with self-biting, choreoathetosis, epilepsy and peripheral neuropathy. *Neurol Med* 9:206
34. Takahashi Y, Kojima T, Atsumi Y et al. (1983) A case of chorea-acanthocytosis with various psychotic symptoms. *Psychiat Neurol Japonicum* 85:457–472
35. Takashima H, Sakai T, Iwashita H et al. (1994) A family of McLeod syndrome, masquerading as chorea acanthocytosis. *J Neurol Sci* 124:56–60
36. Tamura Y, Matsui K, Yaguchi H et al. (2005) Nemaline rods in chorea acanthocytosis. *Muscle Nerve* 31:516–519
37. Tomemori Y, Ichiba M, Kusumoto A et al. (2005) A gene-targeted mouse model for chorea-acanthocytosis. *J Neurochem* 92:759–766
38. Ueno E, Oguchi K, Yanagisawa N (1982) Morphological abnormalities of erythrocyte membrane in the hereditary neurological disease with chorea, areflexia and acanthocytosis. A study with freeze-fracture electron microscopy. *J Neurol Sci* 56:89–97
39. Ueno S, Maruki Y, Nakamura M et al. (2001) The gene encoding a newly discovered protein, chorein, is mutated in chorea-acanthocytosis. *Nat Genet* 28:121–122
40. Wada M, Kimura M, Daimon M et al. (2003) An unusual phenotype of McLeod syndrome with late onset axonal neuropathy. *J Neurol Neurosurg Psychiatry* 74:1697–1699
41. Yamamoto T, Hirose G, Takado M et al. (1980) A familial neurological disorder with acanthocytosis. Special reference to movement disorders. *Clin Neurol (Rinsho Shinkeigaku)* 20:1067–1068
42. Yamamoto T, Hirose G, Shimazaki K et al. (1982) Movement disorders of familial neuroacanthocytosis syndrome. *Arch Neurol* 39:298–301

Neuroacanthocytosis Syndromes II

Walker, R.H.; Saiki, S.; Danek, A. (Eds.)

2008, XXVI, 295 p., Hardcover

ISBN: 978-3-540-71692-1