

## CASE 1

# **New Dual-energy X-ray Absorptiometry Machines (iDXA) and Vertebral Fracture Assessment (VFA)**

## **History and Examination**

Your wealthy friend who is a banker brings his 62-year-old mother to your office one day with worries concerning his mother Jenny's progressive height loss over the past year. Her recent dual-energy X-ray absorptiometry (DXA) report showed a T-score of  $-2.0$  and on and off dull back aches. Jenny has no history of previously documented fragility fractures, no maternal history of such fractures, and no chronic use of drugs. Your banker friend has consulted two clinicians before consulting you: One suggested prophylactic bisphosphonates based on the DXA report, and the other suggested only a high calcium diet, paying attention to life-style factors like adequate exercise and sunshine, with no need for treatment.

After educating your banker friend that nowadays our tendency to treat osteoporosis relies more on risk calculation rather than on a number known as the T-score, you refer Jenny to have the new vertebral fracture (VFA) assessment after noting local tenderness at the thoracolumbar junction and around the L4 vertebra, as well as somewhere near the mid-thoracic spine.

Your banker friend agrees to the arrangement and is pleased to note that the amount of radiation dose will be significantly lower than that of conventional radiographs. The VFA was performed by a new center that is equipped with a state-of-the-art high-resolution new iDXA machine, and the report shows grade 2 vertebral collapse on the Genant scale at T7, T12 and L4 multiple vertebral levels. Based on these important new findings, you decide to treat Jenny with a combination of calcium, and the newer weekly bisphosphonates (that has incorporated vitamin D

inside the tablets), as well as referring her to the physical therapists for postural training and lumbar stabilization exercise. Describe how the newer popular VFA assessments can be of help in these common case scenarios seen almost daily in our orthopedic clinics.

## Discussion

This case scenario illustrates clearly the current worldwide tendency to refrain from relying too heavily on a mere number known as the T-score (named after a researcher whose name begins with the letter “T”), but rather concentrate on the calculation of the risk profile of the individual of suffering from fragility fractures. In fact, the WHO is fully aware of this modern trend and has just published revised guidelines for the management of osteoporosis, not just based on a number (T-score), but with stresses on risk calculation and assessment (Iki, Clin Calcium, 2007).

Some of us may ask why we should rely on risk calculation rather than a number (or bone mass) to which we have grown accustomed. This is because if one refers to the definition of osteoporosis, we notice that these individuals have *concomitant* deterioration in bone architecture, not just loss in bone mass. Thus, some patients with documented fragility fractures after very low energy injury to their skeleton do not have a T-score of  $-2.5$  or lower; in these individuals, it is believed that the significant deterioration in the bony micro-architecture is at work here, and this definitely warrants treatment. For these cases, it is the bony architecture or quality that is mainly at fault.

### **Disadvantage of Conventional X-ray in Assessing the Presence of Vertebral Fractures in the Thoracic and Lumbar Spine**

Even conventional radiographs of the thoracic and lumbar spines long films can be subject to diminished quality owing to different soft tissue envelope thickness, the X-ray angle of the radiographic machine, and the dose of radiation is also much higher than VFA by 15–20 times: 600  $\mu\text{Sv}$  vs. 30  $\mu\text{Sv}$  (teachings of ISCD Course 2007).

### **Advantages of Using VFA Instead of Conventional X-ray**

Advantages include no parallax error, dual energy imaging equalizes the soft tissue variations mentioned above, and the analysis can be semi-quantitative using the guidelines of Genant reported previously in J Bone Miner Res. Most importantly, with the advent of newer high resolution DXA can reflect on morphometry, and the accuracy of detecting both clinical as well as silent thoraco-lumbar fractures will increase. Besides, there is the added advantage of much less radiation, which appeals to many patients including Jenny in the current case scenario.

### **The Term Vertebral Fracture Assessment**

Vertebral fracture assessment (VFA) is the correct term that should be used to denote densitometric spine imaging performed for the purpose of detecting vertebral fractures.

### **Indication for VFA (According to ISCD Position Statement)**

When BMD measurement is indicated, performance of VFA should be considered in clinical situations that may be associated with vertebral fractures (as determined by the attending clinician).

Common examples include:

- Documented height loss of greater than 2 cm (0.75 in) or historical height loss greater than 4 cm (1.5 in) since young adulthood
- History of fracture after age 50
- Commitment to long-term oral or parenteral glucocorticoid therapy
- History and/or findings suggestive of vertebral fracture not documented by prior radiologic study

### **Pitfalls**

- The methodology utilized for vertebral fracture identification should be similar to standard radiological approaches and be provided in the report.
- Fracture diagnosis should be based on visual evaluation and include assessment of grade/severity. Morphometry *alone* is not recommended because it is unreliable for diagnosis.


- The severity of vertebral fractures may be determined using the semi-quantitative assessment criteria developed by Genant (J Bone Miner Res, 1993). Severity of the deformity may be confirmed by morphometric measurement if desired.
- For example, additional imaging can be considered when there are equivocal fractures, unidentifiable vertebrae between T7 and L4, sclerotic or lytic changes, or findings suggestive of conditions other than osteoporosis. VFA is designed to detect vertebral fracture and not other abnormalities.

### Newer High-resolution DXA Machines

One high-resolution DXA machine that is ideal for assessing VFA is the iDXA, a product by GE Healthcare. According to GE, iDXA (Fig. 1) can produce sharper images and with the best precision and accuracy. It was FDA-approved in 2005.

Main features of iDXA include:

- Improved precision in the measurement of the bone that is brought about by the CZT-HD detector, allowing clinicians to track changes previously too minor to detect, faster than before. This allows physicians to better manage osteoporosis treatment plans by offering feedback faster.
- The six-point calibration technique eases assessment of vertebral shape and morphology (Fig. 2).
- Besides the capability of non-invasive measurement of skeletal bone status, the new product can also measure lean and fat tissue components including percentage fat, lean tissue mass.



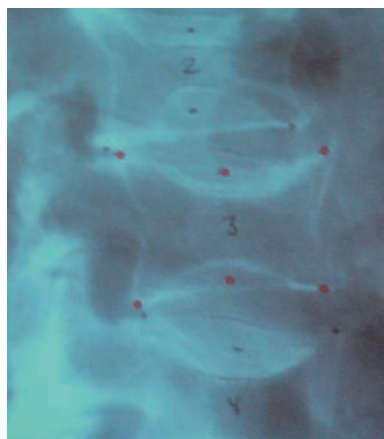
**Fig. 1** The iDXA machine, an example of a newer generation of DXA machine (courtesy of General Electric)

## Biomechanics of Height Loss in Elders

The biomechanics of age-related spinal deformity of vertebral bone loss and disc degeneration associated with aging causes bone and disc structures to weaken and deform as a result of gravity and postural stresses.

Recently, an anatomically accurate sagittal-plane, upright-posture biomechanical model of the anterior spinal column (C2–S1) was created by digitizing lateral full-spine radiographs of 20 human subjects with a mean height of 176.8 cm and a mean body weight of 76.6 kg. Body weight loads were applied to the model, after which intervertebral disc and vertebral body forces and deformation were computed and the new spine geometry was calculated. The strength and stiffness of the vertebral bodies were reduced according to an osteopenic aging model and modulus reduction algorithm respectively.

It was found that the most osteopenic model produced gross deformities of the spine, including anterior wedge-like fracture deformities at T7 and T8. In this model, increases in thoracic kyphosis and decreases in vertebral body height resulted in a 25% decrease in spinal height (C2–S1), an 8% decrease in total body height, and a 15.1-cm anterior translation of the C2 spine segment centroid. The resulting deformity qualitatively resembled deformities observed in elderly individuals with osteoporotic compression fractures.



**Fig. 2** Six-point calibration method

The findings suggest that postural forces are responsible for the initiation of osteoporotic spinal deformity in elderly subjects. Vertebral deformities are exacerbated by anterior translation of the upper spinal column, which increases compressive loads in the thoraco-lumbar region of the spine (Keller et al., Spine, 2003).

However, it was pointed out in other recent studies that height loss in the elderly is *not* invariably due to osteoporotic vertebral collapse at one or more level and that there are other possibilities. But owing to the disadvantages of conventional radiographs in screening the whole spine, the new high-resolution DXA machine such as iDXA from GE will prove to be a very useful screening tool and will help the orthopedic surgeon in determining the status of the vertebral column as well as aid in the decision-making process concerning the management of osteoporosis.

## Present Case Scenario

Jenny was found to have multiple levels of relatively silent vertebral collapse, coupled age and T-score considerations; you started Jenny on bisphosphonates therapy.

### Learning Point

The use of VFA is expected to increase in the coming years for several reasons:

- The paradigm shift in measuring absolute fracture risk besides treating a number (bone mass) as in the past.
- Newer high resolution DXA mentioned provides the needed resolution for detecting vertebral collapse fracture over the whole thoraco-lumbar region and help in many cases the decision-making process of whether to start as well as how to give anti-osteoporosis treatment.
- Much less radiation and the same machine investigates not only bone mass but vertebral details of the whole spine.

## References

1. Keller TS, Harrison DE, et al. (2003) Prediction of osteoporotic spinal deformity. *Spine*, 28(5):455–62
2. Iki M (2007) Absolute risk for fracture and WHO guideline: WHO model for assessing absolute risk of fractures. *Clin Calcium* 17:7, 1015–21



<http://www.springer.com/978-3-540-74426-9>

Casebook of Orthopedic Rehabilitation  
Including Virtual Reality

Ip, D.

2008, XII, 330 p., Softcover

ISBN: 978-3-540-74426-9