

Section I

General Laparoscopic Information

Fundamentals of Laparoscopic Surgery

Contents

Introduction	3
General Considerations	3
Physiologic Effects of Pneumoperitoneum ..	3
Pneumoperitoneum	
and Potential Clinical Outcomes	4
General Advantages of Laparoscopy	4
Laparoscopic Contraindications	5
Special Considerations	6
Anesthesia Problems in Laparoscopic Surgery	6
Technical Considerations	7
Preinsufflation Checklist	7
Insufflator Checklist	8
Insufflator Tips	8
Electrosurgical Unit Settings	9
Instruments for Laparoscopic Surgery	9
Veress Needle Introduction (Closed Access)	11
Technique of Laparoscopic Trocar	
Introduction	13
Laparoscopic Suturing Techniques	15
Suggested Readings	17

Introduction

The use of laparoscopic surgery has rapidly expanded since the laparoscope merged with the video camera in the mid-1980s. Since then, significant developments of laparoscopic equipment and instruments have been made. Along with the technology, surgical skills have also improved with the incorporation of advanced laparoscopic techniques, allowing surgeons to safely perform a multitude of laparoscopic interventions. Apart from the state-of-the-art equipment and surgical expertise, laparoscopic procedures are usually technically demanding, requiring well-trained operative teams and good coordination with an anesthesiologist well versed in laparoscopy. Putting everything to work in perfect combination can make the difference between a safe, efficient operation and a long, difficult procedure that will increase the risk of perioperative and postoperative complications.

General Considerations

Physiologic Effects of Pneumoperitoneum

Carbon dioxide (CO₂) is the gas commonly used for inflating the abdomen. Once inside the abdominal space, it is rapidly absorbed across the peritoneal membrane into the circulatory system. In the blood, carbonic acid is produced leading to respiratory acidosis, but this condition is attenuated due to the absorption of the CO₂ by body buffers. However, during long laparoscopic procedures, body buffers become saturated and hypercapnia or respiratory acidosis develops. At this point, the lungs become responsible for the absorption and release of CO₂ from the body buffers. Although this condition

can be corrected by the anesthesiologist, the associated effects of pneumoperitoneum pressure on the different organ systems can potentiate significant clinical disturbances (see Pneumoperitoneum and Potential Clinical Outcomes).

The pressure effects of pneumoperitoneum:

- Increases intra-abdominal pressure
- Decreases cardiac output and stroke volume
- Decreases femoral venous blood flow and venous return
- Reduces renal perfusion and intraoperative urine output
- Decreases respiratory compliance and increases airway pressure
- Increases intracranial pressure

Pneumoperitoneum and Potential Clinical Outcomes

Pulmonary System

- High peak airway pressures leading to an increased risk of barotrauma and/or pneumothorax
- Superior displacement of the diaphragm leading to an increase in P_{CO_2} and/or a decrease in P_{O_2} levels
- Decreased pulmonary compliance and vital capacity leading to an increase in P_{CO_2} and/or a decrease in P_{O_2} levels

Circulatory System

- Increased central venous pressure, systemic vascular resistance, capillary wedge pressure, and mean arterial pressure leading to an increase in cardiac work
- Indirect effects on the sympathetic system, renin-angiotensin system, and vasopressin leading to an increase in blood pressure and cardiac output
- Indirect effects of hypercapnia, such as arteriolar dilation and myocardial depression leading to a decrease in blood pressure
- Vasovagal response caused by a rapid stretch of the peritoneum leading to bradycardia and occasionally a decrease in blood pressure

- Coagulation disturbances, such as lower extremity venous stasis leading to deep venous thrombosis (DVT) and pulmonary embolism (PE)

Renal System

- Reduced renal blood flow and glomerular filtration rate leading to a diminished urine output (direct pressure on kidney and renal vein)
- Increased release of renin with sodium retention
- Release of antidiuretic hormone (ADH), increasing water reabsorption in the distal tubules

Gastrointestinal System

- Decreased sympathetic response leading to less ileus paralyticus

Central Nervous System

- Increased intracranial pressure leading to reduced central perfusion pressure

Immunologic System

- Less pronounced immune suppression
- Fast return of cytokine levels to normal values

General Advantages of Laparoscopy

- Small incision
- Minimal pain
- Attenuated stress response
- Earlier return to ambulation
- Reduced hospital stay
- Fast recovery

Laparoscopic Contraindications

Intraperitoneal Access

Absolute Contraindications

- Acute peritonitis
- Severe chronic pulmonary obstructive disease
- Congestive heart failure
- Abdominal wall infections
- Bleeding diatheses
- Intestinal obstruction
- Malignant ascites
- Acute glaucoma
- Increased cranial pressure
- Ventriculoperitoneal and peritoneojugular shunts (increased CO₂ absorption and acidosis)

Relative Contraindications

- Severe chronic pulmonary obstructive disease
- Extensive prior abdominal surgery
- Aneurysms of the aorta or iliac arteries
- Intestinal obstruction
- Pelvic fibrosis (previous radiation therapy and previous hip replacement surgery due to sealant leakage)
- Organomegaly
- Severe diaphragmatic hernia (risk of CO₂ leakage into the mediastinum)
- Pregnancy

Extraperitoneal Access

Relative Contraindications

- Prior lower abdominal surgery
- Prior pelvic surgery
- Prior inguinal hernia surgical repair

General Complications of Laparoscopy

Injury to Adjacent Organs

- Bowel puncture (see Veress Needle Introduction)
- Bowel wall thermal injury
- Bleeding from solid organs (liver and spleen)
- Bladder perforation
- Uterus puncture

Vascular Injuries

- Abdominal wall vessels

TIP

An injury to the abdominal wall vessels is usually visible as blood dripping from one of the trocars and/or blood seen on the surface of abdominal structures. The usual cause of the bleeding is an iatrogenic injury to the inferior epigastric artery or one of its branches. The bleeding can be controlled with the application of direct pressure using the involved trocar, coagulation of the vessel with the bipolar grasper, or a laparoscopic-guided or open suture ligation tied over a gauze bolster to tamponade the bleeding site.

- Intra-abdominal large and small vessels

TIP

The right common iliac artery lies directly below the umbilicus. (see Veress Needle Introduction)

Access Complications

- Port site hernia
- Wound infection

- Port site seeding of tumor cells

Pneumoperitoneum Complications

- Pneumothorax
- Pneumomediastinum
- Subcutaneous emphysema
- Gas embolus

Special Considerations

Anesthesia Problems in Laparoscopic Surgery

Trendelenburg Position

- Increases intracranial and intraocular pressures, which may lead to cerebral edema, retinal detachment, and even blindness (especially the long-lasting extreme head-down position for pelvic and lower abdominal procedures)
- Increases intrathoracic pressure, central venous pressure, capillary wedge pressure, and mean arterial pressure leading to an increase in cardiac work
- Increases venous return, which in combination with pneumoperitoneum may lead to congestive heart failure and even acute myocardial infarction

Hypercapnia

When hypercapnia occurs:

- Reduce the intra-abdominal pressure or stop the procedure until P_{CO_2} decreases
- Decrease the angle of the Trendelenburg position
- Increase the minute volume of ventilation

TIP

To avoid the risk of subcutaneous emphysema and hypercapnia, never suture the skin around the trocar when fixing it.

CO₂ Embolism

Usually occurs due to misplacement of the Veress needle:

- Into a vessel
- Into a parenchymal organ (mainly the liver)
- Hypovolemia is a risk factor

Signs of CO₂ Embolism

- Profound hypotension
- Cyanosis
- Arrhythmias
- Asystole
- Immediate increase of end-tidal CO₂ accompanied by a sudden decline in oxygen saturation and then a marked decrease in end-tidal CO₂ due to cardiovascular collapse

When a CO₂ embolism is suspected, the following measures must be taken immediately:

- Stop insufflation and deflate the pneumoperitoneum
- Place the patient in a left lateral head-down position (this will enable the gas embolus to move into the right ventricular apex, preventing its entry into the pulmonary artery)
- Increase minute ventilation and 100% in-tidal O₂ administration
- Introduce a central venous catheter to enable aspiration of the gas
- Administer cardiopulmonary resuscitation in case of asystole
- Administer hyperbaric oxygen therapy, if available

TIP

Most cases of suspected gas embolism will resolve with the first two measures above.

Recovery Period

Extended postoperative mechanical ventilation may sometimes be needed until all extra CO₂ has been eliminated:

- Following prolonged laparoscopic procedures
- When high intra-abdominal insufflation pressure is applied
- When extensive subcutaneous emphysema is present

Urine output must be carefully controlled:

- Following prolonged laparoscopic procedures
- When high intra-abdominal insufflation pressure is applied

Postoperative Nausea and Vomiting

Etiology

- Mechanical pressure to gut and stomach
- Stretching of vagal nerve endings in the peritoneum
- Vasodilatation of the cerebral vessels by CO₂, consequently raising the intracranial pressure

Prophylaxis

- Antiemetics
- Ondansetron, 4 mg administered intravenously just before the end of surgery
- Dexamethasone in combination with Ondansetron to extend the duration of antiemesis

Pain Management

- Evacuation of residual gas before trocar removal
- Opioid analgesia
- Local anesthetic infiltration of port sites

- Preemptive analgesia

Technical Considerations

Preinsufflation Checklist

- CO₂ tank is full or an extra tank is available
- Gas valve on the cylinder is open
- Laparoscopic tower is switched on and equipment is operational
- Insufflator is operational and settings are correct (see Insufflator Checklist)
- In-line filter is connected between insufflator and insufflation tubing
- Electrosurgical unit is operational and settings are correct
- Instruments are compatible with electrocautery and adequately insulated
- Bipolar and monopolar scissor pedals are connected and operational
- Laparoscope image is white balanced
- Suction device is operational (suction and irrigation tubing are connected and working)
- Veress needle tip retracts properly

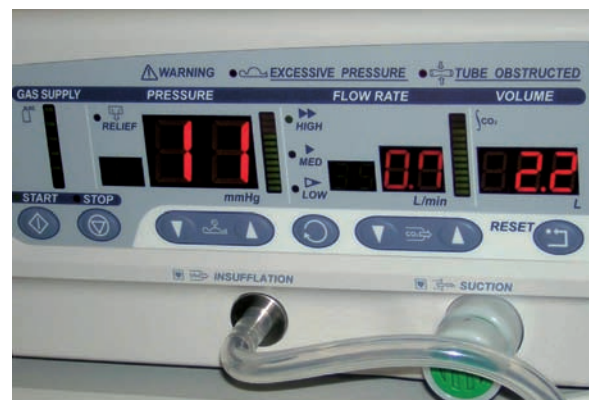

FIG. 1

Insufflator settings



FIG. 2

Electrosurgical unit

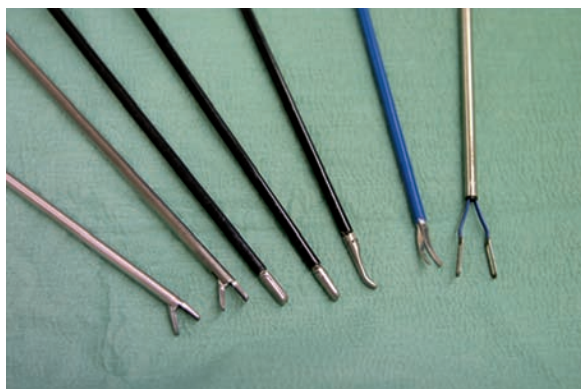

FIG. 3

Instruments for laparoscopic surgery

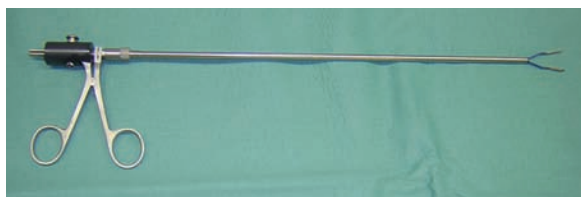

FIG. 4

Bipolar grasper

- An extra pair of scissors is available

Insufflator Checklist

- Maximum pressure on the insufflator is set to 12 mmHg
- Pressure is set according to the following:
 - Initiate with high pressure when performing an extraperitoneal laparoscopic radical prostatectomy or when using the open access technique
 - Initiate with low pressure when using the Veress needle (closed access) technique
- CO₂ flow rate is set to 35 L/min (Fig. 1)
- Safety valve pressure is set to 35 mmHg

Insufflator Tips

- Intra-abdominal pressure for safe trocar introduction should be equal to or higher than 10 mmHg.

TIP

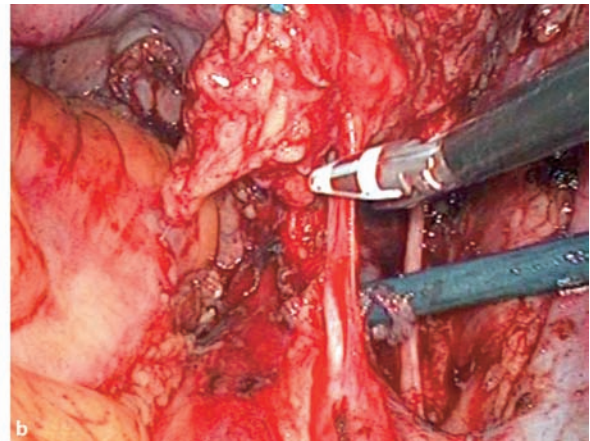
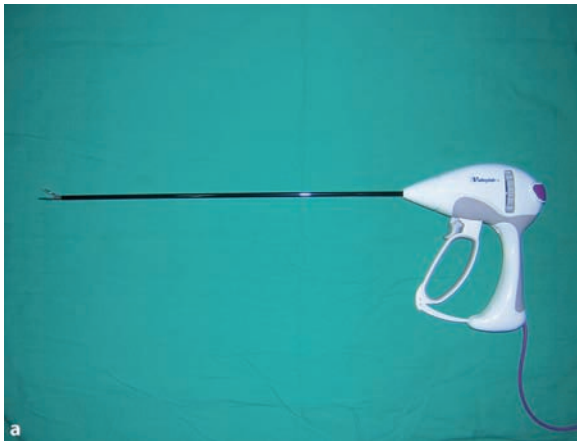Pressure is the most important parameter.

- Intra-abdominal volume for safe trocar introduction should be equal to or higher than 2.5 L.



FIG. 5

Ethicon™ clip applicator (10 mm) and clips

**FIG. 6**

a LigaSure™ 5 mm (Tyco Healthcare). b LigaSure at bladder pedicle

TIP

Disconnecting the insufflation line to the Veress needle can cause the gas to leak, resulting in false readings.

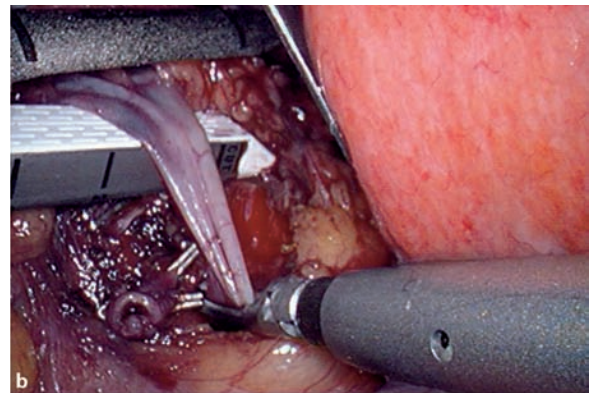
Electrosurgical Unit Settings

- Monopolar Coagulation set to 50 Watts (Fig. 2)
- Cutting set to 0
- Bipolar Coagulation set to 50 Watts
- Auto stop set to Off

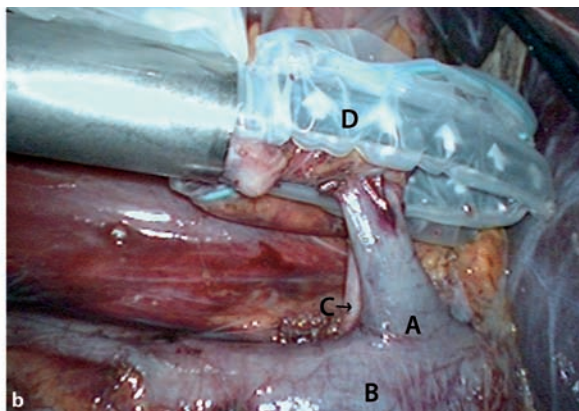
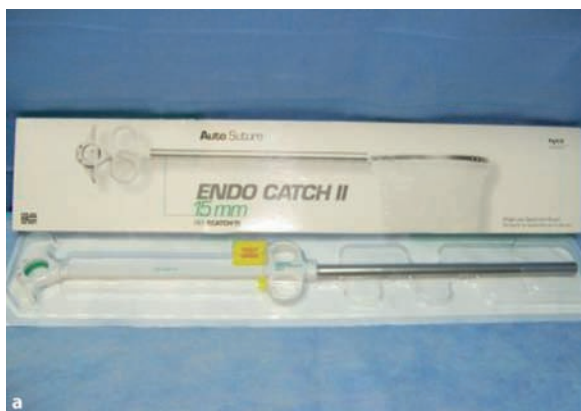Instruments for Laparoscopic Surgery

Basic Instruments (see Fig. 3)

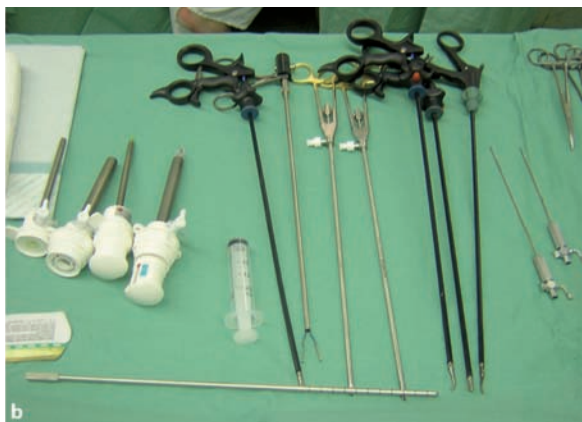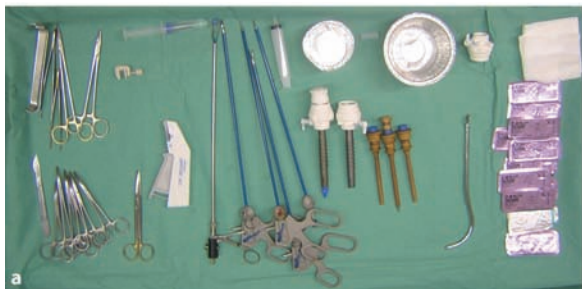- Needle holder
- Bipolar grasper (Fig. 4)
- Monopolar scissors

**FIG. 7**

a Multifire Endo GIA™ 30 12-mm stapler. b Endo GIA stapling renal vein

**FIG. 8**

a Endo Catch II 15 mm (Autosuture). b Renal vein (A); V. cava (B); Right renal artery (C); Kidney inside Endobag (D)

**FIG. 9**

a Laparoscopic instruments/trocars for radical prostatectomy. b Laparoscopic instruments/trocars for promontory fixation

- Graspers

Other Instruments for Vessel and Tissue Ligation

- Clip applier forceps (non-disposable) (Fig. 5)
- Laparoscopic sealer/divider instrument

TIP

The LigaSure™ 5 mm (Tyco Healthcare) has a small tip suitable for tissue dissection, and the sealing and dividing function is hand-controlled. (Fig. 6a,b)

- Endo GIA™ 30 12-mm stapler (Autosuture) (Fig. 7a,b)

Specimen Retrieval Device

- Endobag (Fig. 8a,b)




FIG. 10

Disposable Veress needle

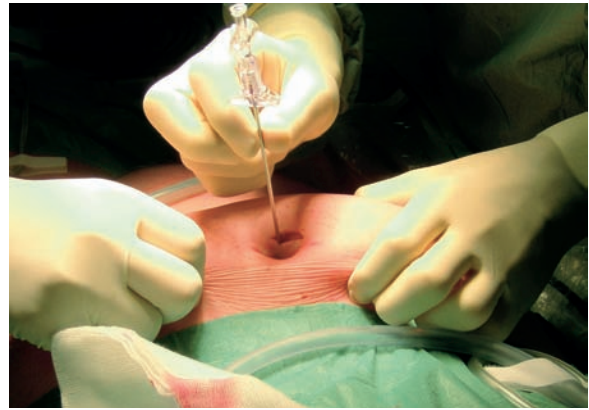


FIG. 11

Veress needle introduction

Laparoscopic Instruments Table (see Fig. 9a,b)

Veress Needle Introduction (Closed Access)

The Veress needle can be disposable or reusable (Fig. 10).

The blunt tip of the needle retracts when it is pressed against a tough structure, exposing its sharp edge. After the needle passes through the abdominal wall layers, the blunt tip is deployed, preventing damage to the abdominal structures. The CO₂ gas for the abdominal insufflation passes through the hollow cannula of the Veress needle.

TIP

The maximum flow through the needle is 0.2 L/min due to its internal diameter.

While introducing the needle, it is important to feel it passing through the layers of the abdominal wall. The initial thrust is at the level of the external oblique/rectus fascia, followed by the transversalis fascia and peritoneum.

TIP

As the needle enters the peritoneal cavity, a click sound can often be heard, meaning the blunt tip has sprung forward.

It is preferable to avoid introduction of the Veress needle in the vicinity of a previous abdominal scar.

TIP

When bowel adhesions are suspected, the Veress needle is not used, and the fascia is opened under direct vision (i.e., open access); the peritoneum should be digitally entered and the adhesions carefully released with gentle digital movements.

Introduction Technique for Pelvic Laparoscopic Procedures

A subumbilical incision is made 50% larger than the diameter of the trocar that will be inserted. The abdominal

wall is elevated by manually grasping the skin and subcutaneous tissue (Fig. 11).

The Veress needle is grasped by the shaft like a dart and then passed into the incision perpendicularly to the abdominal wall. Following introduction, two tests are performed in sequence to confirm that the needle is inside the peritoneal cavity (Fig. 12).

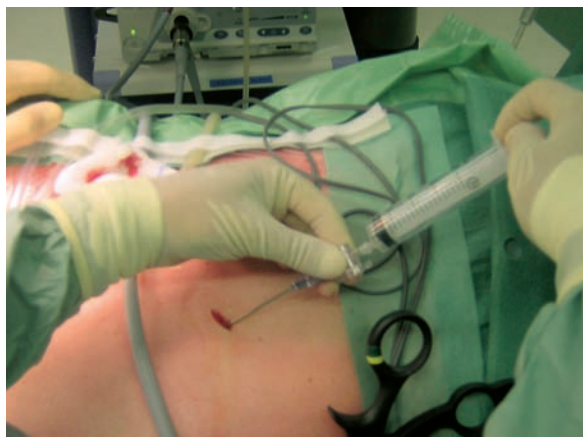

FIG. 12

Syringe is connected to Veress needle

1. Initially, a 20-mL syringe is connected to the needle, and the plunger is drawn out to test for the presence of air or blood. If blood is aspirated, a vessel was punctured and conversion to open surgery should be done without removal of the Veress needle. In the case that gas and/or a yellow or cloudy fluid are aspirated, the needle is placed inside the lumen of the bowel. The needle is then removed and replaced in the correct position. The optic is reintroduced, and the puncture of the bowel must be found and laparoscopically repaired. In this particular situation, a prosthesis should not be placed due to the risk of bacterial contamination.
2. Then, the syringe is filled with 20 mL of air. It is re-connected to the Veress needle, the air is injected, and the plunger is drawn out to test for the presence of air. *No air* should return to the syringe (if air returns, the needle is placed in a closed location and most probably in the preperitoneal space). The insufflation tubing is connected to the Veress needle, the stopcock is opened, and the abdomen is insufflated. Initiating with a low flow is recommended to avoid damage to a vital structure in case the needle is mispositioned. Switch to high flow if the intra-abdominal pressure is low and the insufflation pressure is increasing at a steady and normal level along with a tympanic percussion of the liver area. Then, the needle is removed and the primary trocar is introduced perpendicularly to the abdominal wall.

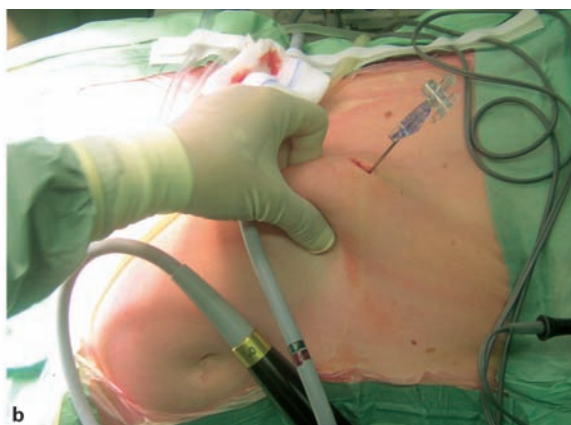
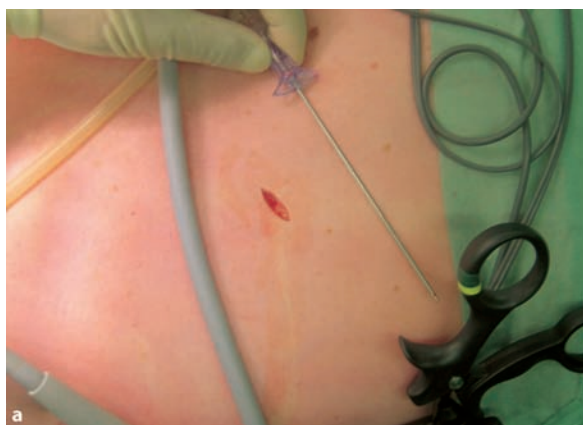
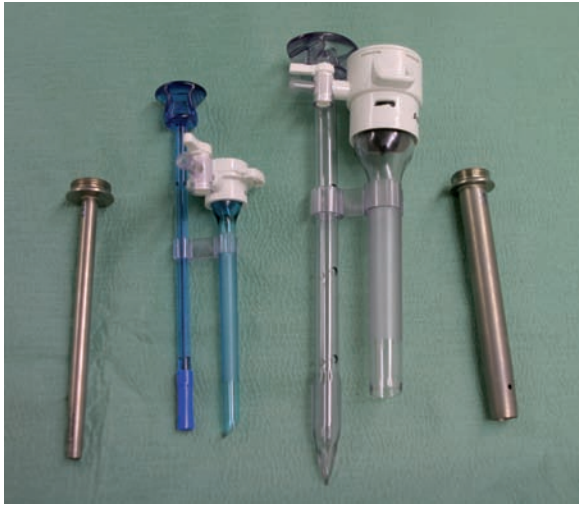FIG. 13

a Subcostal incision. **b** Needle introduction through the incision

**FIG. 14**

Disposable blunt tip and reusable trocars

Technique of Laparoscopic Trocar Introduction

Types of Trocars

Trocars can be disposable or reusable and are available in different sizes (2 mm, 5 mm, 10 mm, 12 mm, and 15 mm). The obturator tip may be bladed or blunt, and the blunt tip may be associated with a lower incidence of injury to intraperitoneal structures and vessels of the abdominal wall (Fig. 14).

TIP

Always check for a sharp tip on reusable trocars; unsharpened tips will result in a forceful thrust, increasing the risk of vessel or organ injury during laparoscopic access.

Introduction Technique for Upper Tract Laparoscopic Procedures

A cutaneous incision is made 50% larger than the diameter of the trocar that will be inserted. This is done two fingerbreadths below the costal margin arch, at the level of the lateral border of the rectus muscle. The abdominal wall is elevated by manually grasping the skin and subcutaneous tissue, and the Veress needle is introduced through the incision (Fig. 13a,b).

The Veress needle must be introduced perpendicularly to the plane of the patient

TIP

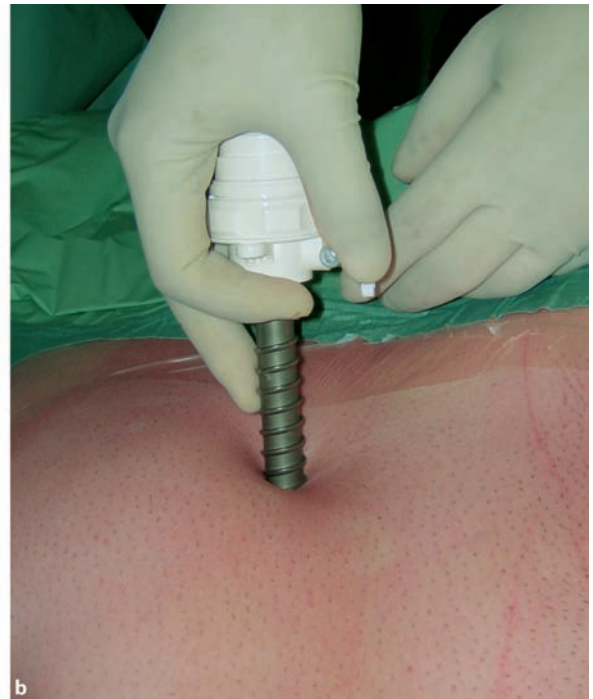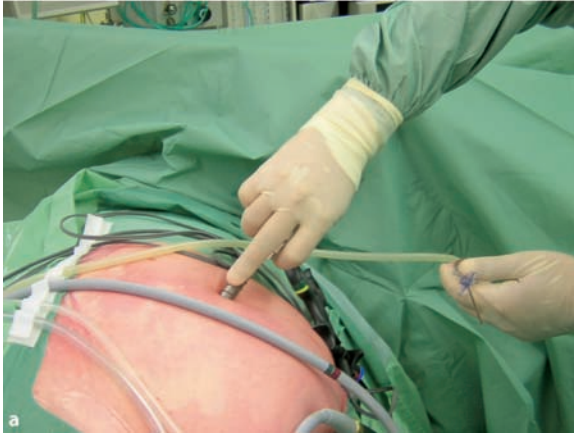For the right side, the needle can be introduced at an angle of 30° caudally to the abdominal wall to avoid liver puncture.

After introduction, the procedures to confirm the correct placement of the needle are the same as for the pelvic laparoscopic surgery.

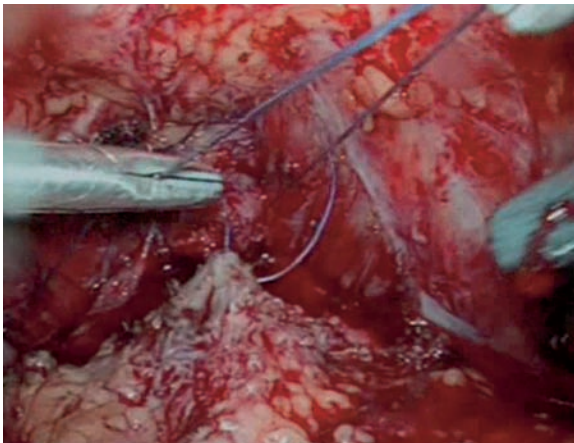
At the end of the laparoscopic procedure, the aponeurosis of trocar sites 10 mm or larger should be closed to avoid the occurrence of incisional hernias. The risk of hernias may be reduced by the utilization of the blunt tip trocar.

Trocar Positioning

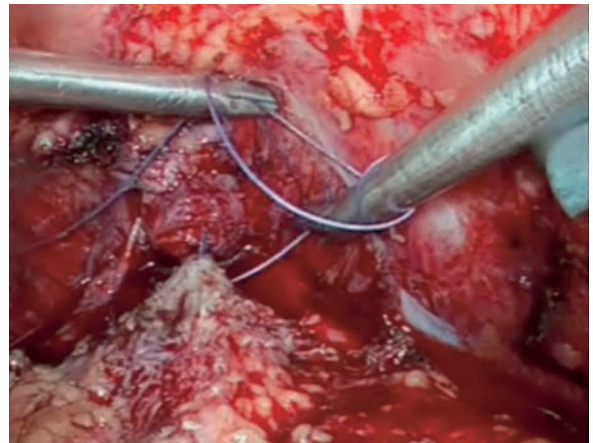
The primary camera port preferably should be in line with the structure of interest (for example, the renal hilum during a laparoscopic nephrectomy), and at a 45° angle to the area of interest. The working ports (right and left hand) should be on either side of the camera port and at an adequate distance from each other and from the camera, preventing the crossing of the instruments. The smaller diameter trocar is usually positioned at the surgeon's dominant hand side, and the larger trocar is for the nondominant one. This is to prevent instrument shaking while performing sensitive tasks, which are usually exerted by the dominant hand. The secondary trocar placement site is marked by pressing a finger on the abdominal wall, and the indentation is internally viewed with the optic, allowing the insertion of all secondary trocars under direct laparoscopic visualization.

**FIG. 15**

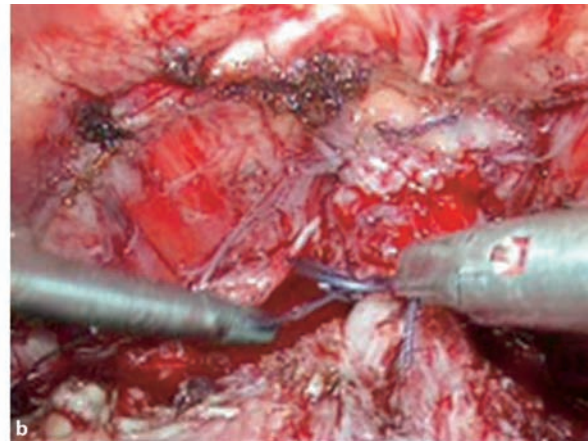
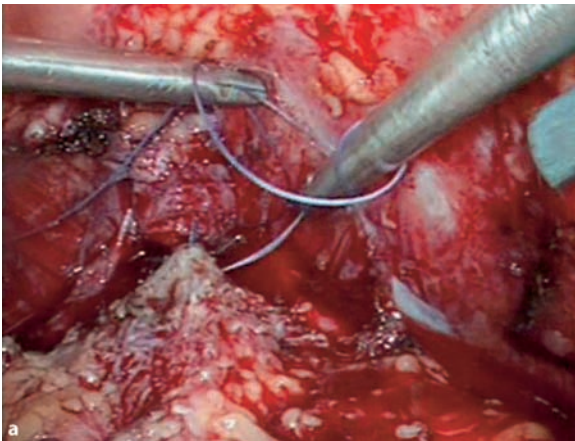
a Trocar introduction (see middle finger position). b Trocar introduction

**FIG. 16**

The thread is straightened out

**FIG. 17**

Half loop open with both needle holders in close proximity

**FIG. 18**

a Left needle holder advances. **b** Right needle holder moves out of the loop

Trocar Introduction

Pneumoperitoneum should be adequate. The skin incision is made 50% larger than the diameter of the trocar. The trocar is firmly grasped against the palm of the hand to arm the device; the middle finger is extended for further insertion control, and the trocar is introduced with a firm and constant screwing motion (Fig. 15a,b).

The trocar should be inserted perpendicularly to the abdominal wall, and the insertion angle can be changed as soon as the tip pierces the peritoneum.

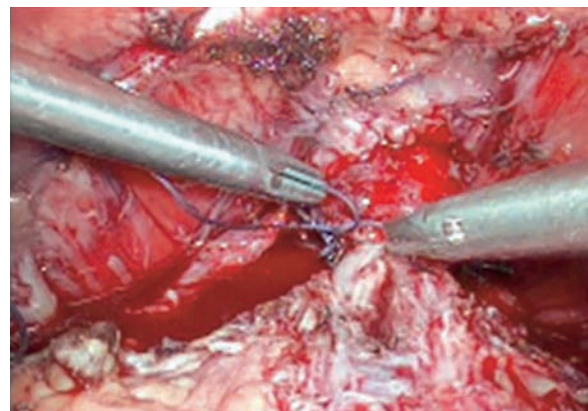
Following trocar placement and obturator removal, the trocar valve is briefly opened to check for egress of gas, confirming it is correctly placed inside the abdomen. The insufflator line is then connected to the trocar.

Laparoscopic Suturing Techniques

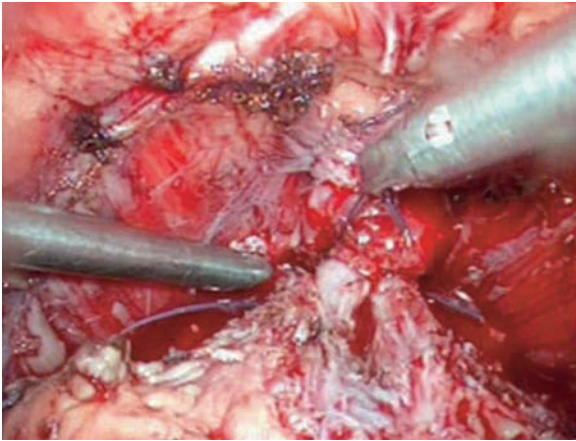
Basic Suturing

- The left needle holder grasps the thread.
- The thread is straightened out by pulling with the right needle holder.

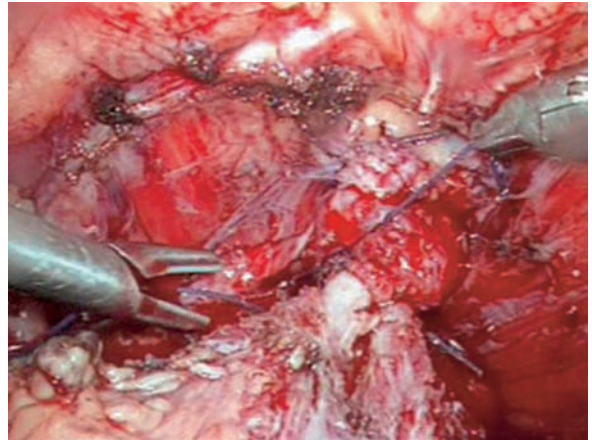
- The axis of the thread is kept perpendicular to the left needle holder to facilitate loop construction (Fig. 16).
- A half loop is made.
- The left needle holder stays in close proximity to the right one to keep the loop opened (Fig. 17).
- The left needle holder advances forward, and the right needle holder moves out of the half loop (Fig. 18a,b).

**FIG. 19**

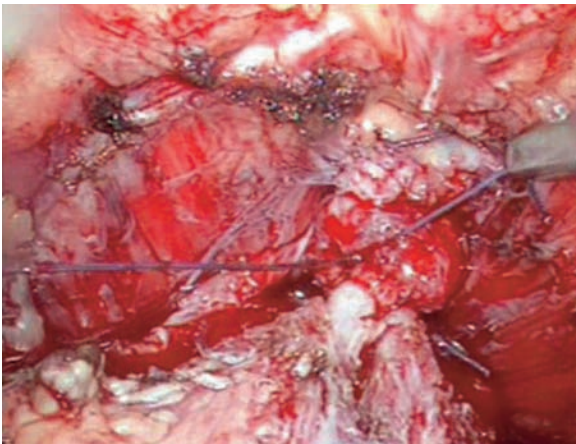
Left needle holder grabs the open loop

**FIG. 20**

The knot is closed

**FIG. 21**

Left needle holder swiftly grabs proximal thread

**FIG. 22**

Threads are pulled out, and the knot is tied

TIP

Do not pull with the right needle holder before the second knot is tied to avoid loosening the knot.

- The knot is completed by advancing the right needle holder forward, and the left needle holder pulls in toward the trocar.

TIP

To avoid intra-abdominal injuries, never pull the thread by the needle.

Advanced Suturing

- When the first knot loosens, the left needle holder grabs the open loop, and the right needle holder grabs the distal thread (Fig. 19).
- The left needle holder gently pulls the loop to close the knot (Fig. 20).
- The left needle holder swiftly grabs the proximal thread while the right needle holder keeps the distal thread tensioned (Fig. 21).
- Both thread ends are pulled out to tie the knot (Fig. 22).

Suggested Readings

1. Sriprasad S, Yu DF: Positional anatomy of vessels that may be damaged at laparoscopy: new access criteria based on CT and ultrasonography to avoid vascular injury. *J Endourol* 2006 Jul; 20(7):498–503.
2. Hamade AM, Butt I: Closed blunt-trocar 5 mm-port for primary cannulation in laparoscopic surgery: a safe technique. *Surg Laparosc Endosc Percutan Tech* 2006 Jun; 16(3):156–160.
3. Jean JMCH de la Rosette, Inderbir SG: *Laparoscopic Urologic Surgery in Malignancies*. Springer, 2005.
4. Saber AA, Mesleman AM: Safety zones for anterior abdominal wall entry during laparoscopy: a CT scan mapping of epigastric vessels. *Ann Surg* 2004 Feb; 239(2):182–185.
5. Shalhav AL, Barret E: Transperitoneal laparoscopic renal surgery using blunt 12-mm trocar without fascial closure. *J Endourol* 2002 Feb; 16(1):43–46.
6. Rist M, Hemmerling TM: Influence of pneumoperitoneum and patient positioning on preload and splanchnic blood volume in laparoscopic surgery of the lower abdomen. *J Clin Anesth* 2001; 13:244–249.
7. Philips PA, Amaral JF: Abdominal access complications in laparoscopic surgery. *J Am Coll Surg* 2001; 19:525–536.
8. Odeberg-Wernerman S: Laparoscopic surgery – effects on circulatory and respiratory physiology: an overview. *Eur J Surg Suppl* 2000; 585:4–11.
9. Kashtan J, Green JF: Hemodynamic effects of increased abdominal pressure. *J Surg Res* 1981; 30:249–255.
10. Chapron CM, Pierre F: Major vascular injuries during gynecologic laparoscopy. *J Am Coll Surg* 1997; 185:461–465.
11. Riza ED, Deshmukh AS: An improved method of securing abdominal wall bleeders during laparoscopy. *J Laparoendosc Surg* 1995; 5:37–40.
12. Vasquez JM: Vascular complications of laparoscopic surgery. *J Am Assoc Gynecol Laparosc* 1994; 1:163–167.
13. Loris J: *Anesthetic Management of Laparoscopy*, 4th ed.. New York, Churchill Livingstone, 1994.

Manual of Laparoscopic Urology

Rosenblatt, A.; Bollens, R.; Espinoza Cohen, B.

2008, XII, 226 p. 334 illus., 320 illus. in color.,

Hardcover

ISBN: 978-3-540-74726-0