

# Overall Introduction, Problem Definition, Incidence

BRANISLAV JEREMIĆ and SUSANNE PITZ

## CONTENTS

1.1	Introduction	1
1.2	Incidence	4
	References	5

## KEY POINTS

ONSM is a rare tumour. It is usually separated into the primary ONSM (pONSM) (intraorbital or intracanalicular) and secondary (sONSM) (intracranial). The tumour can also originate within the optic nerve sheath in the orbit or optic canal and may grow intracranially to involve various structures there. ONSM can also present in a bilateral form. pONSM represent approximately 96% of all intraorbital and approximately 1%–2% of all intracranial meningiomas. It is the second most common orbital tumour after optic nerve gliomas, but represents only 10% of all ONSM, all the others (90%) being secondary ONSM. Of the pONSM, approximately 96% are true pONSM and only 4% were considered ectopic; pONSM typically develop in middle aged women with the proportion of females ranging from 70 to 80, although they do occur in children as well.

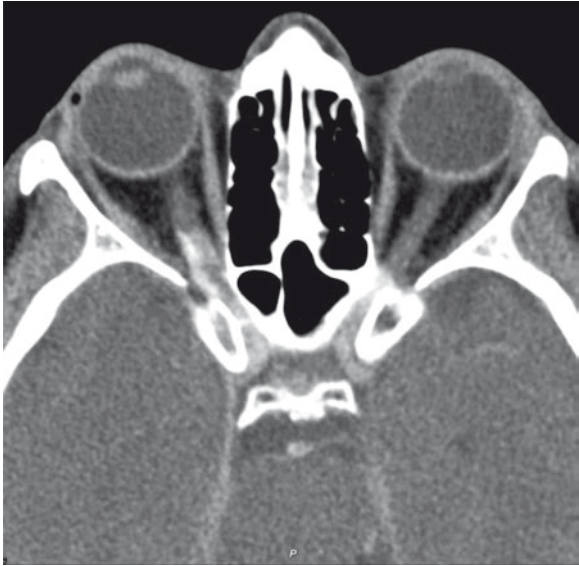## 1.1

### Introduction

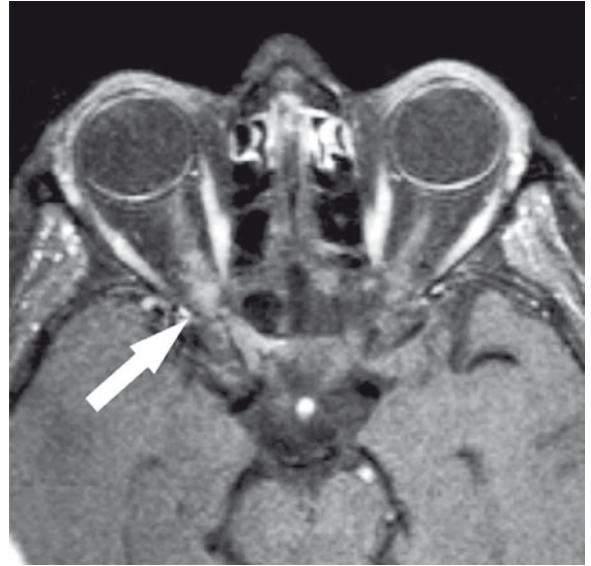Optic nerve sheath meningioma (ONSM) is a rare tumour. It is usually separated into the primary ONSM (pONSM) which arise from the cap cells of the arachnoid surrounding the intraorbital (Figs. 1.1–1.3) or, less commonly, the intracanalicular portions of the optic nerve (Figs. 1.4–1.7), and secondary (sONSM), which

arise intracranially, usually from the sphenoid ridge or tuberculum sellae and subsequently invade the optic canal and orbit by extending between the dura and arachnoid of the optic nerve in these regions. The term ONSM thus does not imply a definite site of origin. Nevertheless, once this type of tumour gains access to the subdural space of the intracanalicular or intraorbital optic nerve, the tumour grows up and down the sheath, invading the dura and obliterating the pial blood supply. In most instances, the tumour encircles the optic nerve without invading it. In other cases, the tumour may invade the nerve by growing along the fibrovascular septa (SAMPLES et al. 1983; PROBST et al. 1985). Such a tumour may eventually surround and obstruct the central retinal vein, central retinal artery, or both

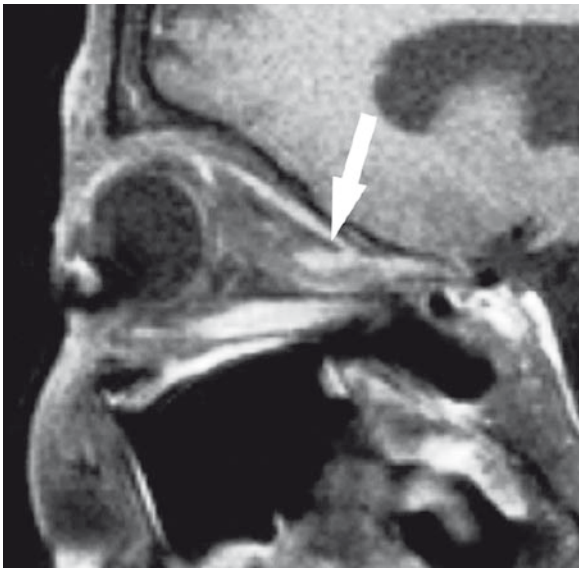B. JEREMIĆ, MD, PhD  
International Atomic Energy Agency, Wagramer Strasse 5, P.O.  
Box 100, 1400 Vienna, Austria  
S. PITZ, MD, PhD  
University Eye Hospital, Langenbeckstrasse 1, 55101 Mainz,  
Germany



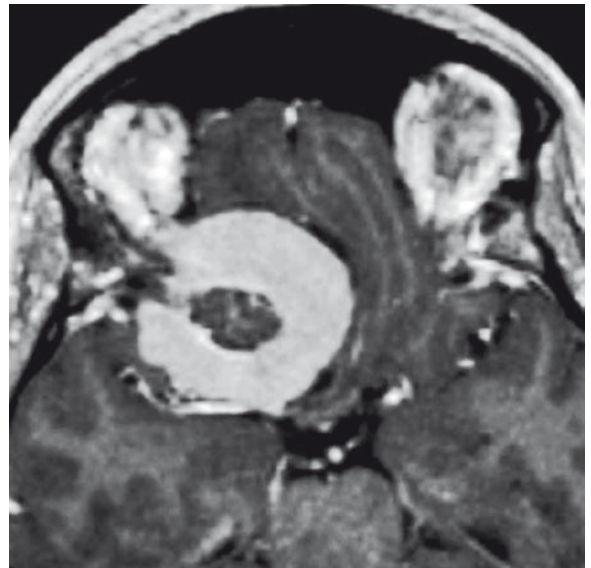
**Fig. 1.1.** Axial, contrast enhanced CT with demarcation of the (primarily calcified) tram-track-like tumor in the precanicular part of the right intraorbital optic nerve



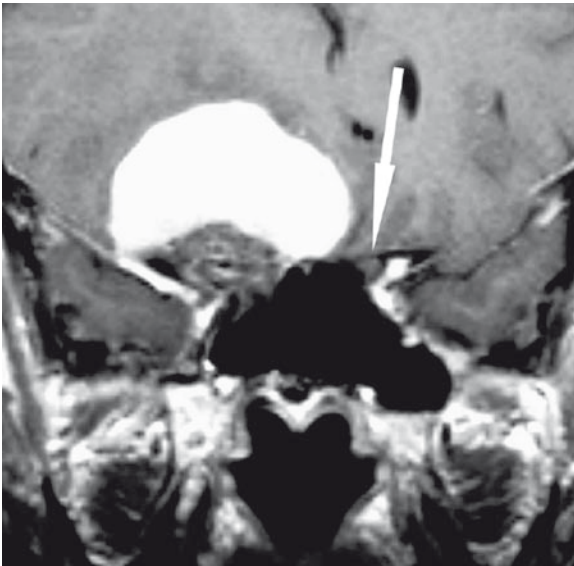
**Fig. 1.2.** Corresponding axial T1-weighted (T1w), contrast enhanced, fat-suppressed view with signal, enhancement of the tumor (*white arrow*)



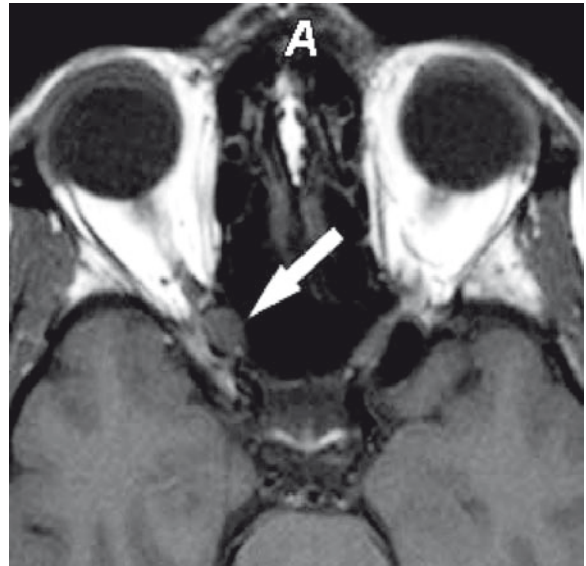
**Fig. 1.3.** Corresponding sagittal T1-weighted (T1w), contrast enhanced, fat-suppressed view with signal enhancement of the tumor (*white arrow*)



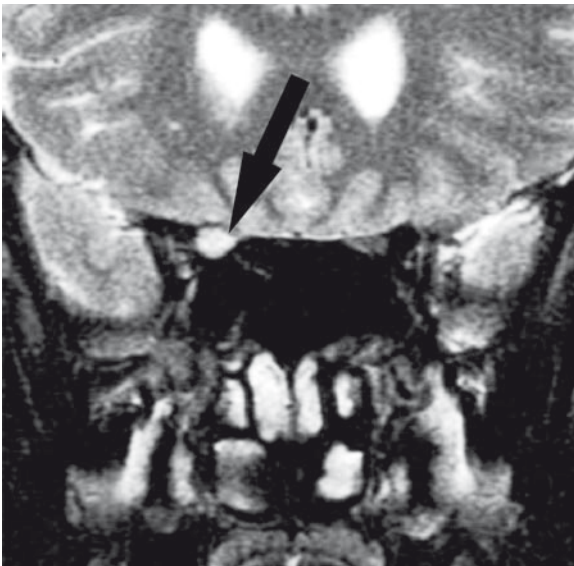**Fig. 1.4.** Axial T1w, contrast-enhanced view at the level of the clinoid process



**Fig. 1.5.** Coronal T1w, contrast enhanced view at the level of the optic canal. No differentiation of the right optic nerve due to tumor compression. Note the corresponding left optic nerve in the optic canal (*white arrow*)



**Fig. 1.6.** Axial T1w, native view of the intracanalicular part of the optic nerve demonstrating a slight enlargement



**Fig. 1.7.** Coronal, T2w view, showing the dislocation and compression of the right optic nerve (*black arrow*) by the inferiorly excentric (hyperintense) meningioma

vessels. Rarely, a tumour will break through the dural sheath of the optic nerve to invade other orbital structures. Finally, a tumour that originates within the optic nerve sheath in the orbit or optic canal may grow intracranially to involve the optic chiasm, contralateral optic nerve, and internal carotid artery. It may even invade the cavernous sinus or the sella turcica.

ONSM can also present in a bilateral form (DANDY 1922; CRAIG and GOGELA 1949; SALAZAR et al. 1977; HOLLENHURST et al. 1977; TROBE et al. 1978; HART et al. 1980; WILSON 1981; COHN 1983), featuring invasion of both optic canals by one or several meningiomas. In some cases extended periods of time separating the involvement of the first eye from that of the second have been reported, casting some doubt on the causes of visual loss in the first eye (TROBE et al. 1978). Other authors (HART et al. 1980) suggested that the tumour may in fact have arisen multifocally, simultaneously involving both optic nerves in their intraorbital and intracanalicular portions. The near simultaneous involvement of both optic nerves and the symmetric clinical course,

accompanied by the surgical finding of an absence of tumour within the prechiasmal space, supports this conclusion (HART et al. 1980).

Although these (ONSM) tumours are frequently discussed together, due to different clinical characteristics, treatment, and outcome, all of which may have implications for the future strategies; they will *not* be discussed together in this book. This book focuses on the primary ONSM, in which both intraorbital and intracanalicular ONSM will be placed. The aim of this book is to summarize pretreatment and treatment characteristics of pONSM, putting a special emphasis on the use of external beam radiation therapy (RT) in the management of this disease, in particular stereotactic fractionated radiation therapy (SFRT).

## 1.2

### Incidence

There has been some controversy regarding the incidence of pONSM because of their infrequent occurrence, the difficulty of determining the actual site of origin of large tumours (SPENCER 1972; ALPER 1981) and the possible confusion between meningiomas and the arachnoid hyperplasia that often accompanies optic gliomas (COOLING and WRIGHT 1979). In the Harvey Cushing's series of 313 meningiomas (CUSHING and EISENHARDT 1938), there was only one which arose from the sheath of the optic nerve. Other series of both meningiomas and orbital tumours support this rarity; various series have shown their incidence to vary between 2% and 6% (CRAIG and GOGELA 1949; DANDY 1941; INGALLS 1953; SHIELDS et al. 2004). In addition, the majority of the data come from ophthalmological literature (CRAIG and GOGELA 1949; KARP et al. 1974; WRIGHT 1977; MARK et al. 1978; ALPER 1981; SAMPLES et al. 1983), which may not be easily available to physicians from other specialties.

It is now established that primary ONSM represent approximately 96% of all intraorbital and approximately 1%–2% of all intracranial meningiomas (DUTTON 1992). It thus is the second most common orbital tumour, after optic nerve gliomas (CRAIG and GOGELA 1949; D'ALENA 1964; WRIGHT et al. 1980; SIBONY et al. 1984; ROOTMAN 1988; GABIBOV et al. 1988; DUTTON 1992). However, it represents only 10% of all ONSM, all other (90%) being the secondary ONSM. Of the pONSM, it is said that approximately 96% are true pONSM and only 4% were considered ectopic, i.e. those arising from ectopic arachnoid cells within the orbital

interstitial tissues or along the orbital nerves (CRAIG and GOGELA 1949; ROOTMAN 1988). These ectopic, extradural meningiomas do not appear to have a connection to the optic sheath or the optic canal and do not have an intracranial origin. They probably arise from congenitally displaced nests of meningotheelial cells along the orbital wall or within the muscle cone and have been named "extradural orbital meningioma" (CRAIG and GOGELA 1949; ALPER 1981). Of all pONSMs, 92% arise intraorbitally and only 8% intracanalicularly (DUTTON 1992). Most of these tumours are unilateral, with 5% presenting bilaterally. They typically affect middle-aged women. There is no strong evidence for predilection for left or right laterality (DUTTON 1992). Interestingly, canalicular meningiomas had a higher incidence of bilaterality (38%) than ONSMs within the orbit (DUTTON 1992). In a subsequent series (SAEED et al. 2003), half of the patients with bilateral ONSMs had tumours along the planum sphenoidale in continuity with the lesions in both optic canals. Thus, it would appear that some cases of apparently bilateral ONSMs are truly bilateral, whereas others represent either the spread of a planum sphenoidale meningioma to both optic canals or of a unilateral ONSM across the planum to the contralateral optic canal.

Recent study from Denmark (LINDEGAARD et al. 2002) showed that frequency of ONSM increased significantly during the last 25 years. A significant difference in the mean ages of men and women with ONSM was found ( $p < 0.05$ , Student's *t*-test). The mean age for women was calculated at 48.8 years, being higher than the mean age calculated in the series of DUTTON (1992) (40.8 years) both being higher than that for men, calculated at 29.7 years in the Danish study (LINDEGAARD et al. 2002). This increase in incidence may have been the result of the development of better imaging techniques for investigation of lesions involving the optic nerve which became available in the recent years. However, in the same time period there was no significant increase in the incidence of malignant tumours invading the optic nerve, challenging improvement in imaging as the likely reason for such an increase in the incidence of optic nerve sheath meningiomas. The reasons for this increase, therefore, remain currently unknown; however it may reflect an overall increase of meningiomas which has been otherwise reported from Scandinavia, but not for other European countries (LOUIS et al. 2007).

As with other meningiomas, pONSM typically develop in middle-aged women (WRIGHT 1977; WRIGHT et al. 1980; ALPER 1981; SIBONY et al. 1984), with remarkably consistent gender ratio with the proportion of females in several series ranging from 70% to 80%

(CRAIG and GOGELA 1949; KARP et al. 1974; REESE 1976; WRIGHT 1977; WRIGHT et al. 1980; ALPER 1981; SIBONY et al. 1984). Nonetheless, they do occur in children as well. VALLAT et al. (1981) described a 2-year old girl in whom such a tumour occurred, and other investigators have described similar cases (DANDY 1941; OFFRET 1951; DUNN and WALSH 1956). The youngest patient in the series reported by ALPER (1981) was 3 years of age. KARP et al. (1974) found that 10 of their 25 (40%) patients were less than 20 years of age. However, although the true incidence in young patients remains difficult to determine (KARP et al. 1974; HENDERSON 1980; ALPER 1981) it is estimated to occur in 4%–7% of all ONSM. Childhood ONSM may differ from adult form. Unlike ONSMs in adults, there is no gender predilection. They are said to be more commonly associated with neurofibromatosis type 2. pONSMs in children often behave more aggressively, are characterized by faster growth, tend to be bilateral and show intracranial involvement in comparison to adults (LISTERNICK et al. 1997) and exhibit a more invasive growth (WALSH 1970; KARP et al. 1974; HENDERSON 1980; ALPER 1981). Moreover, bilateral cases appear to have an earlier mean age of onset of symptoms at 12.8 years (DUTTON 1992). pONSM may also occur in older individuals. Five of the patients examined by WRIGHT et al. (1980) were over 60 years of age, and one of them was a man. The oldest patient evaluated by SIBONY et al. (1984) was a 66-year-old man. The oldest patient of ALPER (1981) was 83 years old. Nevertheless, when these tumours present in middle age, the prognosis is much better (WRIGHT 1977; WRIGHT et al. 1980; CLARK et al. 1989). It has also been noted that pONSM appear at an earlier age than secondary orbital meningiomas or other intracranial meningiomas (CRAIG and GOGELA 1949; McNAB and WRIGHT 1989). It is speculated that some or all of this age difference is presumably due to relatively smaller tumours in the orbit producing symptoms earlier than a similarly sized intracranial meningioma, especially in the region such as the sphenoid ridge.

These rare tumours have attracted a considerable amount of professional attention, including reports of ONSM being reported in association with prior radiation therapy (RT) (NEWMAN and JANE 1991). In addition, rare cases of adenocarcinoma of the lung metastatic to optic nerve sheath meningioma (ARNOLD et al. 1995) have been previously published.

Though difficult to judge conclusively from the current literature, there has been a substantial shift in treatment from surgery to “intelligent neglect” to – most recently – fractionated stereotactic radiotherapy. While a comprehensive evaluation of radiotherapy is not yet

at hand, due to the benign nature of pONSM and thus decades of follow-up needed, it seems that this treatment option might in future represent the mainstay of therapy for pONSM.

## Acknowledgements

Imaging kindly provided by Prof. Wibke Müller-Forell, Institute for Neuroradiology, University Hospital, Mainz.

## References

- Alper MG (1981) Management of primary optic nerve meningiomas. Current status – therapy in controversy. *J Clin Neuroophthalmol* 1:101–117
- Arnold AC, Hepler RS, Badr MA, Lufkin RB, Anzai Y, Konrad PN, Vinters HV (1995) Metastasis of adenocarcinoma of the lung to optic nerve sheath meningioma. *Arch Ophthalmol* 113:346–351
- Clark WC, Theofilos CS, Fleming JC (1989) Primary optic nerve sheath meningiomas. Report of nine cases. *J Neurosurg* 70:37–40
- Cohn EM (1983) Optic nerve sheath meningioma: neuroradiologic findings. *J Clin Neuro-Ophthalmol* 3:85–89
- Cooling RJ, Wright JE (1979) Arachnoid hyperplasia in optic nerve glioma: confusion with orbital meningioma. *Br J Ophthalmol* 63:596–599
- Craig WMK, Gogela LJ (1949) Intraorbital meningiomas. *Am J Ophthalmol* 32:1663–1680
- Cushing H, Eisenhardt L (1938) Meningiomas: their classification, regional behaviour, life history and surgical end results. Springfield, Ill. Charles C Thomas, pp 250–282
- D’Alena PR (1964) Primary orbital meningioma. *Arch Ophthalmol* 71:832–836
- Dandy WE (1922) Prechiasmal intracranial tumors of the optic nerves. *Am J Ophthalmol* 5:169–188
- Dandy WE (1941) Orbital tumors: results following the transcranial operative attack. Oskar Piest, New York, pp 70–130
- Dunn SN, Walsh FB (1956) Meningioma (dural endothelioma) of the optic nerve; report of a case. *AMA Arch Ophthalmol* 56:702–707
- Dutton JJ (1992) Optic nerve sheath meningioma. *Surv Ophthalmol* 37:167–183
- Gabibov G, Blinkov SM, Tcherkayev VA (1988) The management of optic nerve meningiomas and gliomas. *J Neurosurg* 68:889–893
- Hart WM Jr, Burde RM, Klingele TG, Perlmutter JC (1980) Bilateral optic nerve sheath meningioma. *Arch Ophthalmol* 98:149–151
- Henderson JW (1980) Orbital tumors, 2nd edn. Brian C. Decker, New York, pp 472–496

- Hollenhorst RW Jr, Hollenhorst RW Sr, MacCarthy CS (1977) Visual prognosis of optic nerve sheath meningioma producing shunt vessels on the optic disk: the Hoyt-Spencer syndrome. *Trans Am Ophthalmol Soc* 75:141–163
- Ingalls RG (1953) Tumors of the orbit and allied pseudo tumors: an analysis of 216 cases. Springfield III. Charles C Thomas, pp 129–148
- Karp LA, Zimmerman LE, Borit A, Spencer W (1974) Primary intraorbital meningiomas. *Arch Ophthalmol* 91:24–28
- Lindgaard J, Heegaard S, Prause JU (2002) Histopathologically verified non-vascular optic nerve lesions in Denmark 1940–1999. *Acta Ophthalmol Scand* 80:32–37
- Listernick R, Louis DN, Packer RJ, Guttmann DH (1997) Optic pathway gliomas in children with neurofibromatosis type I: consensus statement from the NF1 Optic Glioma Task Force. *Ann Neurol* 41:143–149
- Louis DN, Ohgaki H, Wiestler OD, Cavenee WK (2007) WHO classification of tumours of the central nervous system. IARC, Lyon
- Mark LE, Kennerdell JS, Maroon JC, Rosenbaum AE, Heinz R, Johnson BL (1978) Microsurgical removal of a primary intraorbital meningioma. *Am J Ophthalmol* 86:704–709
- McNab AA, Wright JE (1989) Cysts of the optic nerve three cases associated with meningioma. *Eye* 3:355–359
- Newman SA, Jane JA (1991) Meningiomas of the optic nerve, orbit, and anterior visual pathways. In: Al-Mefty O (ed) *Meningiomas*. Raven Press, New York, pp 461–494
- Offret G (1951) Exophthalmos. *Gaz Med Fr* 58:1003–1004
- Probst C, Gessaga E, Leuenberger AE (1985) Primary meningioma of the optic nerve sheaths: case report. *Ophthalmologica* 190:83–90
- Reese AB (1976) *Tumors of the eye*, 3rd edn. Harper and Row, New York, pp 148–153
- Rootman J (1988) *Diseases of the orbit. A multidisciplinary approach*, JB Lippincott, London, pp 281–285
- Saeed P, Rootman J, Nugent RA, White VA, Mackenzie IR, Koornneef L (2003) Optic nerve sheath meningiomas. *Ophthalmology* 110:2019–2030
- Salazar JL, Bauer J, Frenkel M, Sugar O (1977) Bilateral optic canal meningioma. *Surg Neurol* 8:11–14
- Samples JR, Robertson DM, Taylor JZ, Waller RR (1983) Optic nerve meningioma. *Ophthalmology* 90:1591–1594
- Shields JA, Shields CL, Scartozzi R (2004) Survey of 1264 patients with orbital tumors and simulating lesions. The 2002 montgomery lecture, part 1. *Ophthalmology* 111:997–1008
- Sibony PA, Krauss HR, Kennerdell JS, Maroon JC, Slamovits TL (1984) Optic nerve sheath meningioma: clinical manifestations. *Ophthalmology* 91:1313–1324
- Spencer WH (1972) Primary neoplasms of the optic nerve and its sheaths: clinical features and current concepts of pathogenetic mechanisms. *Trans Am Ophthalmol Soc* 70:490–528
- Trobe JD, Glaser JS, Post JD, Page LK (1978) Bilateral optic canal meningiomas: a case report. *Neurosurgery* 3:68–74
- Vallat WM, Robin A, Bokor J, Catanzano G, De Laval M, Ronayette JP (1981) Meningioma of the optic nerve in a 2-year-old child. Apropos of a case. *Bull Soc Ophthalmol Fr* 81:351–353
- Walsh FB (1970) Meningiomas, primary within the orbit and optic canal. In: Smith JL (ed) *Neuro-Ophthalmology Symposium of the University of Miami and the Bascom Palmer Eye Institute*, St. Louis, vol 5. CV Mosby, pp 240–266
- Wilson WB (1981) Meningioma of the anterior visual system. *Surv Ophthalmol* 26:109–127
- Wright JE (1977) Primary optic nerve meningiomas: clinical presentation and management. *Trans Am Acad Ophthalmol Otolaryngol* 83:617–625
- Wright JE, Call NB, Liaricos S (1980) Primary optic nerve meningioma. *Br J Ophthalmol* 64:553–558

Primary Optic Nerve Sheath Meningioma

Jeremic, B.; Pitz, S. (Eds.)

2008, XII, 139 p., Hardcover

ISBN: 978-3-540-77557-7