

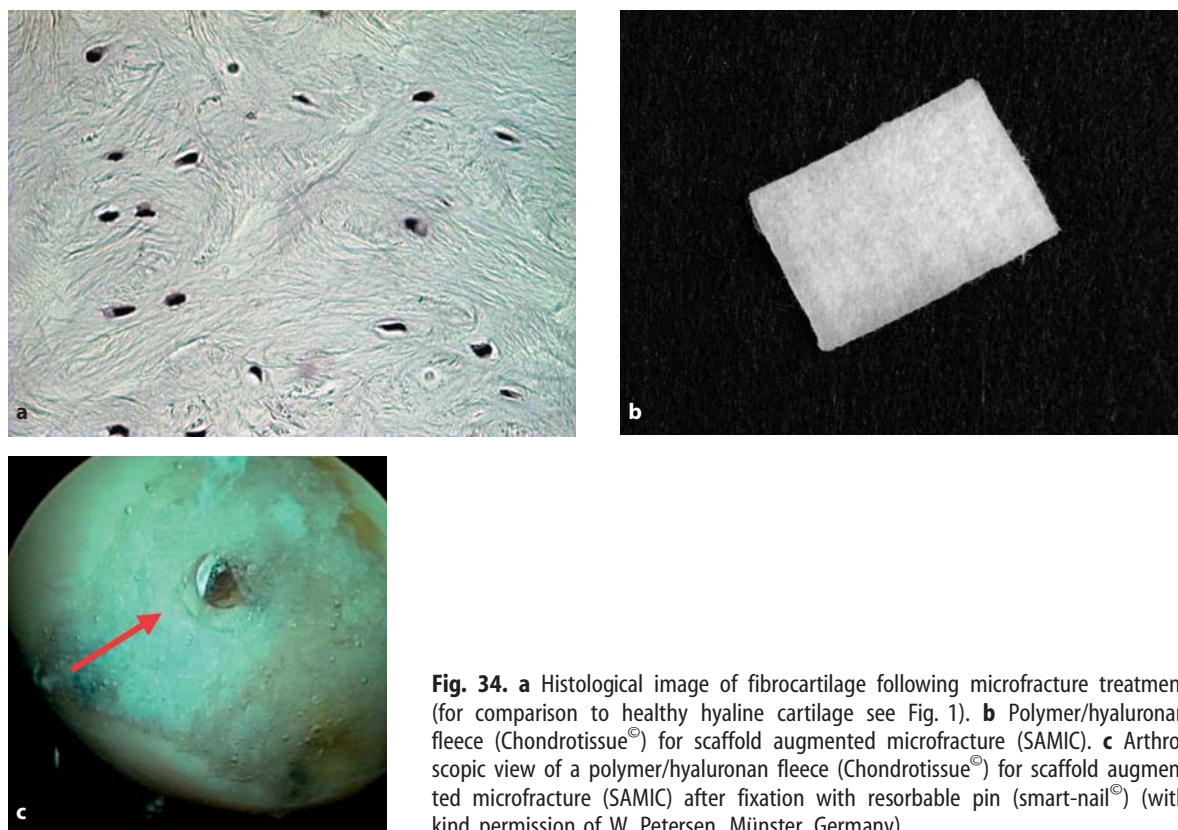Fig. 34. **a** Histological image of fibrocartilage following microfracture treatment (for comparison to healthy hyaline cartilage see Fig. 1). **b** Polymer/hyaluronan fleece (Chondrotissue®) for scaffold augmented microfracture (SAMIC). **c** Arthroscopic view of a polymer/hyaluronan fleece (Chondrotissue®) for scaffold augmented microfracture (SAMIC) after fixation with resorbable pin (smart-nail®) (with kind permission of W. Petersen, Münster, Germany).

- Histological: Histological processing of regenerates shows characteristic fibrocartilaginous structure (Fig. 34) even under ideal conditions, differing significantly from hyaline cartilage.

A 3D porous and resorbable matrix for the treatment of smaller cartilage defects in combination with microfracture called Chondrotissue® demonstrated better and histologically superior coverage of the defect site in preclinical studies. The scaffold is augmented with autologous serum in a one stage procedure and fixated intraosseously with vicryl or pins.

Augmented microfracture techniques

In order to enhance cartilage regeneration after microfracture and stabilize the defect site resorbable scaffolds are used to cover a cartilage lesion after penetration of the subchondral space.

The AMIC® technique (Autologous Matrix Induced Chondrogenesis) uses a collagen membrane which is sutured to the perifocal cartilage. That way the lesion is well protected but animal studies have shown no benefit in comparison to microfracture alone.

Osteochondral transplantation

Transplantation of articular cartilage in shape of osteochondral plugs has been proven to be useful both experimentally and clinically. One has to differentiate between autologous and allogenic transplants. The availability of osteochondral allografts might be problematic in some countries.

Use of autografts in cartilage repair and its results have long since been described.

Modern sets of instruments with thin-walled core cutters allow gentle acquisition of cylindrical osteochondral transplants (“plugs”). This allows transfer of cartilage autografts in standardized sizes into marginally smaller holes within the defect for *press-fit* fixation. Harvest areas for osteochondral donor plugs are located in areas of lesser weight-bearing and also in the contralateral

knee joint. Development of advanced arthroscopic techniques made osteochondral transplantations widely accepted and used.

■ **Principle.** Transplantation of osteochondral plugs from joint compartments of lesser weight-bearing into cartilage defects for the reconstruction of an intact cartilage surface (Fig. 35).

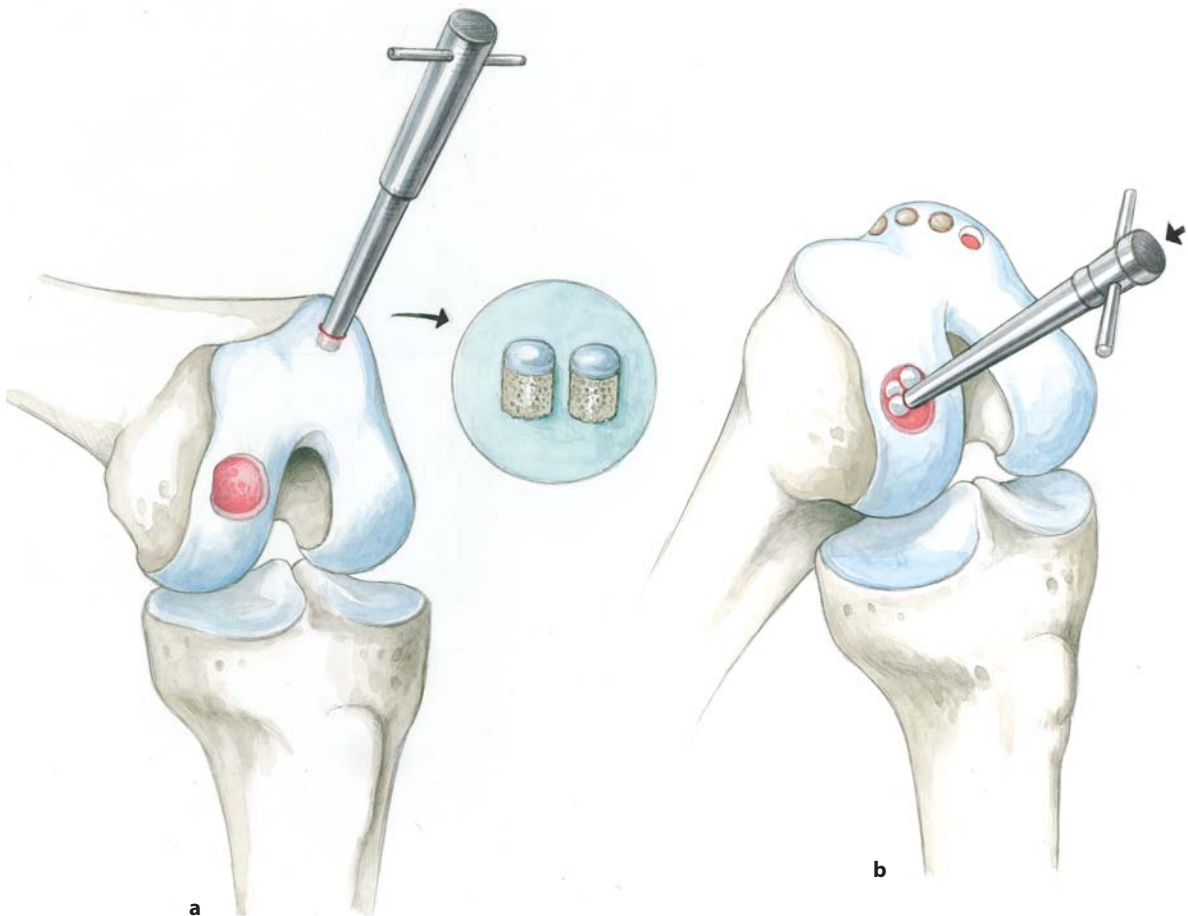
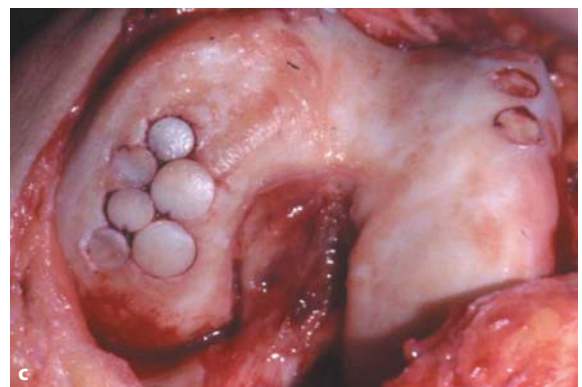

Fig. 35 a–c. Treatment of a cartilage defect on the femoral condyle using osteochondral plugs. **a** Debridement of the defect and harvesting of osteochondral plugs from areas of lesser weight-bearing. **b** Implantation of osteochondral plugs into the defect. **c** Defect on the femoral condyle after implantation of osteochondral plugs. Plugs overlap to achieve better defect coverage.



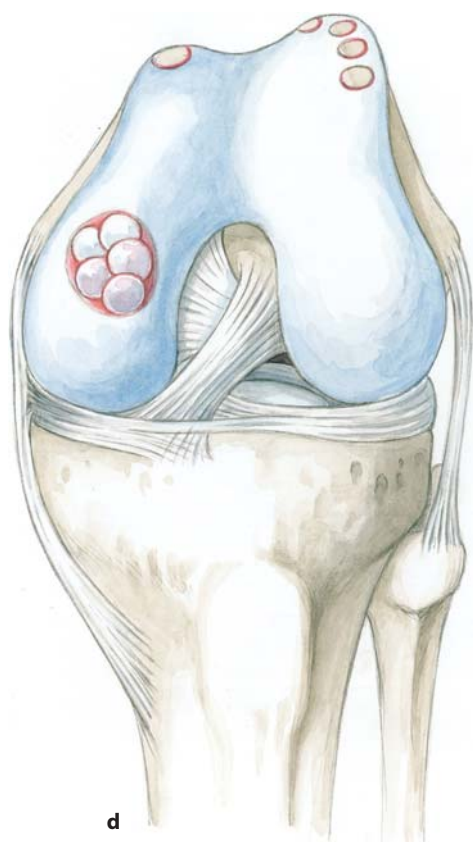

Fig. 35 d. Intraoperative image of a cartilage defect on the femoral condyle after implantation of osteochondral plugs.

■ Surgical procedure

- Exposure of the cartilage defect, debridement if necessary and determination of exact defect measures. Single-use trial cylinders allow determination of needed number and size of plugs for a complete coverage of the defect.

Note: Not all available instrument sets allow arthroscopic use!

- Arthroscopic transfer of more than three plugs should remain within hands of highly specialized and well-trained orthopaedic surgeons.
- Donor plugs are harvested according to the measured size of the defect. Core cutters are usually marked as *donor*. Preferable donor sites are medial and lateral margins of the trochlea and a smaller margin around the intercondylar notch. It is of special importance to insert core cutters perpendicu-

larly to the cartilage surface. Bone bridges between two harvest sites shall not be smaller than 3 mm to maintain stability.

Diamond cutters are available alternatively to standard stainless steel core cutters. Depending on instrument sets, recipient sites will be cut out, milled down or chiselled. Instruments are usually marked as *recipient*. Again, harvesting should be performed perpendicularly to the joint surface.

Note: It has been proven to be useful to insert plugs one by one. Plugs are to be inserted by gently pushing them out of the core cutter with a small mallet or operating a threaded mechanism. Then gently push plugs into the recipient site with using a small pestle until joint surfaces level is reached. This procedure may be repeated several times with different plug diameters until defect is completely covered.

- Harvest sites may be retrofilled with plugs from recipient sites. Thorough lavage and flexion of the joint is followed by a final control of secure plug insertion.

■ **Postoperative treatment.** Passive motion therapy immediately after surgery with unlimited range of motion (exception: flexion limitation in case of retropatellar and trochlear cartilage lesions), limited weight bearing for 6 weeks.

■ Pitfalls

– Problem 1:

Donor plug is too long with incongruent cartilage surfaces

– Solution 1:

Do not force plugs in as this usually injures the cartilage surface. Deepen the recipient site carefully with a small burr (Fig. 36 a, b)

– Problem 2:

Donor plug is inserted too deep

– Solution 2:

Do not let the plug “float” within the recipient site, but back the bottom with spongia harvested from a donor site (Fig. 36 c, d)

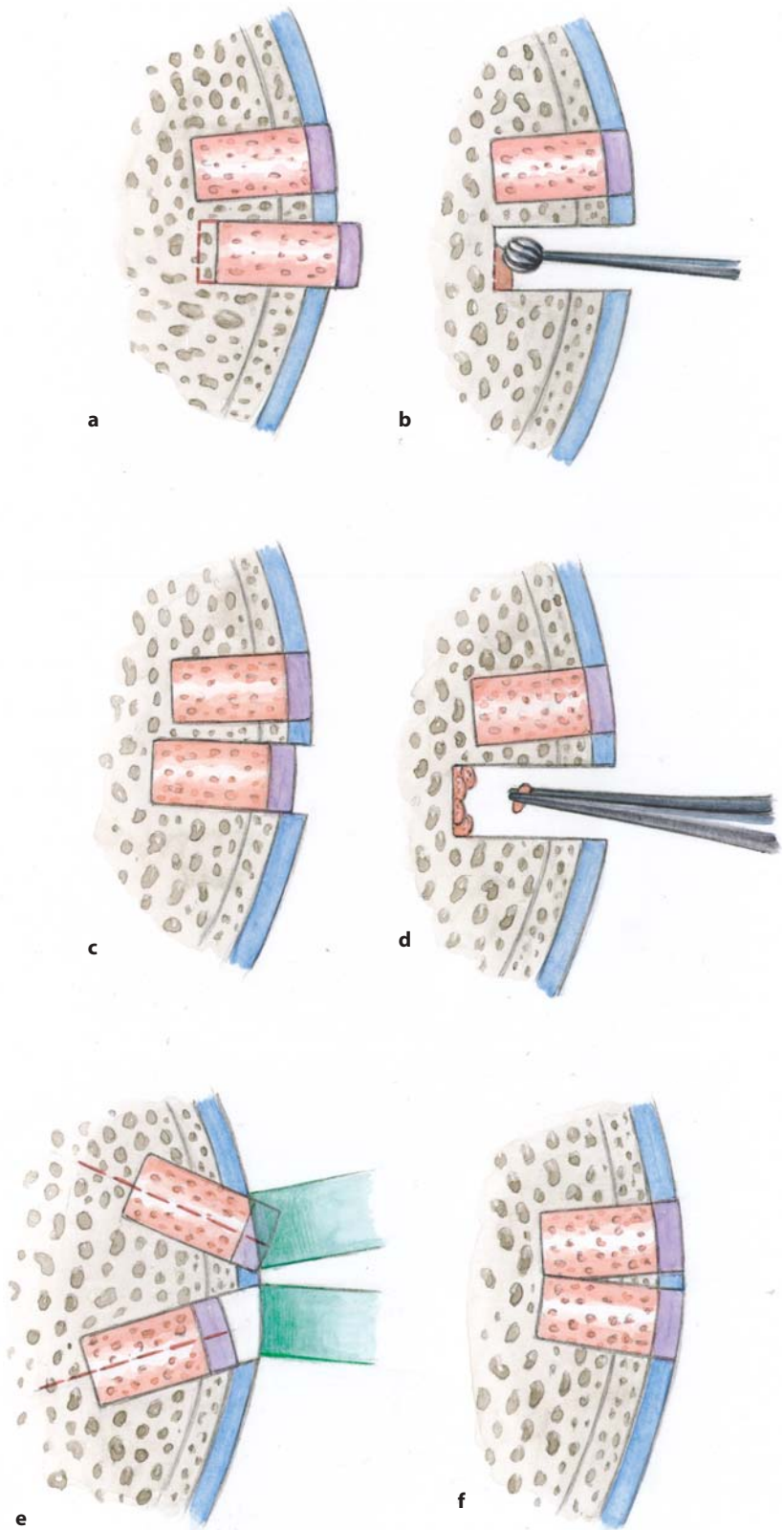


Fig. 36 a–f. Pitfalls of implantation of osteochondral plugs (for explanation see text).

– **Problem 3:**

Rotation of the plug does not match (in case of non-orthograde plug or recipient site)

– **Solution 3:**

Prior to final impaction try to achieve best alignment using two cannulae (Fig. 36 e, f).

Note:

Defect covering cannot exceed 70%, even with closely inserted plugs. Defect cover may be improved by harvesting donor plugs in an overlapping manner or by microfracturing the small spaces between plugs (Fig. 37).

Removal of incorrectly inserted plugs without destroying them is very difficult. “Mini-corkscrews” are available for this purpose but tend to be torn out of the plug.

The so called “Mosaicplasty-System” with many small core cutters of diameters ranging from 4 to 8 mm is frequently recommended. The “Mega-OATS-System” achieves defect coverage by implanting a single plug with a diameter of 12 to 16 mm. This technique offers the advantage of improved defect coverage but bears the disadvantage of producing joint surface incongruity due to grossly different convexity of surfaces. The natural history of a Mega-OATS donor site is similar to that of an articular cartilage defect of the same size and therefore is recommended under special circumstances or when allograft is used.

Positioning, potential displacement or necrosis of transplants may be made identified by MRI. Osseous alterations and oedemas may be seen for a prolonged time in MRI-images. However, clinical outcome might still be positive (Figs. 39, 41).

Osteochondral transplantations have also been proven to be successful in other joints. Cartilage defects in shoulder, elbow, and femoral head may be covered if enough donor material is available. It might be necessary to harvest donor plugs from the knee joint. Plugs may also be harvested from to front margin of the talus (Fig. 40).

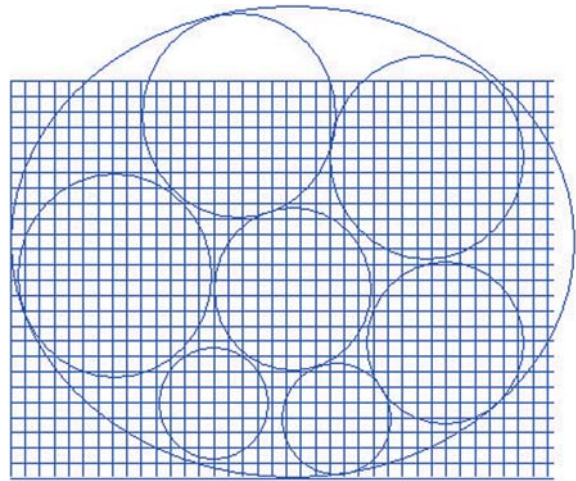


Fig. 37. Schematic image of an elliptic cartilage defect: even very tight implantation of plugs may only reach incomplete defect coverage.

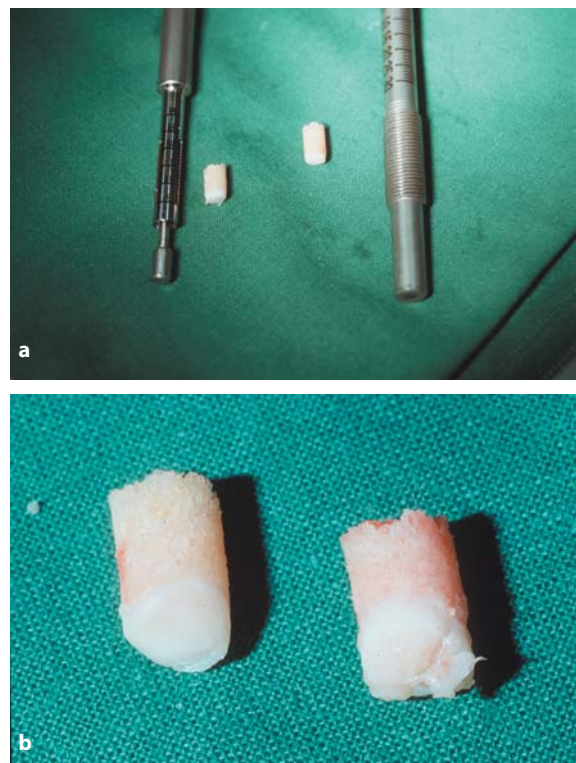


Fig. 38. **a** Core cutter (cannulated, round chisel) set for harvest and implantation of osteochondral plugs (Aesculap). **b** Osteochondral plugs after explantation from a defect (with injured cartilage, right) and prior to implantation (with intact cartilage, left).

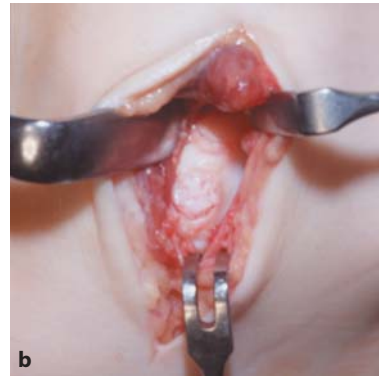
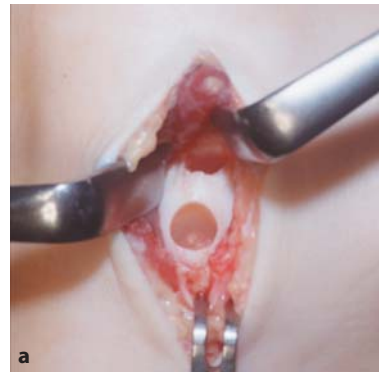
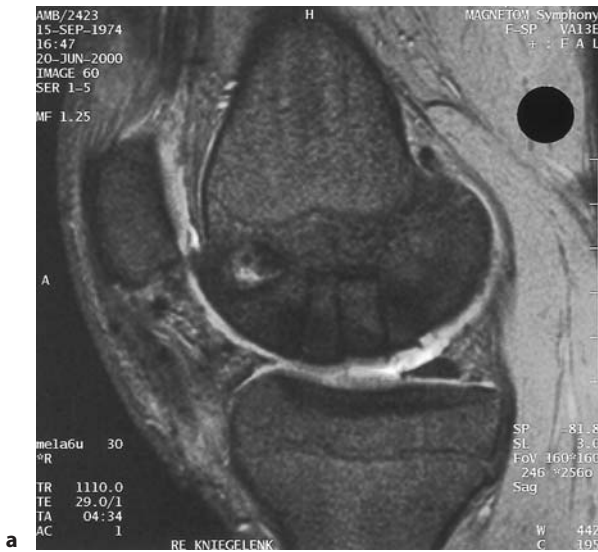

Fig. 40 a, b. Intraoperative view of the treatment of a cartilage defect on the talus' shoulder with osteochondral plugs. Ventral approach without medial malleolar osteotomy. **a** Harvesting of both recipient (top) and donor plug (bottom) with intact articular cartilage. **b** Implantation of donor plug into the lesioned weight-bearing area (top) and filling of the harvest site with the plug from the recipient site to minimize subchondral bleeding (bottom).

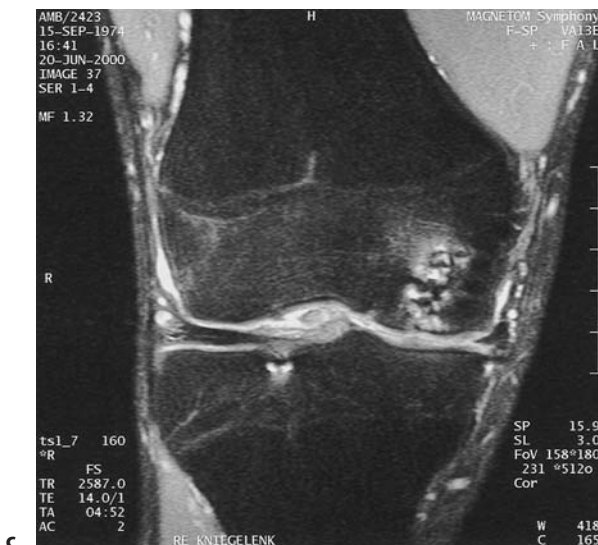
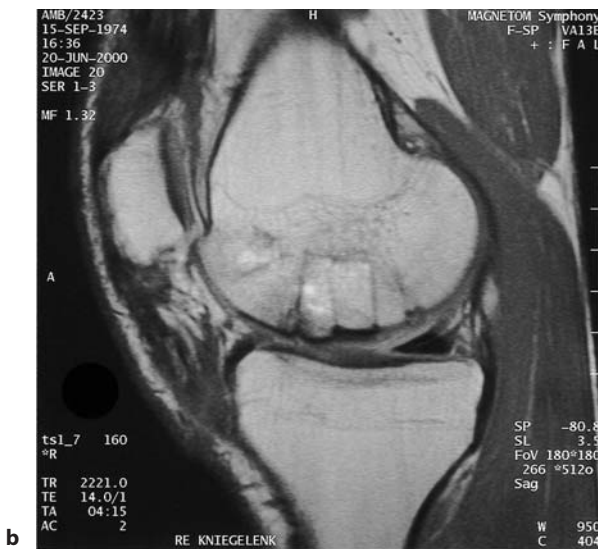
Fig. 39 a-c. MRI of the knee with a cartilage lesion on the femoral condyle after treatment with osteochondral plugs. **a, b** Osteochondral plugs can easily be identified. Subchondral bone plate appears irregular. **c** Development of a subchondral bone necrosis.

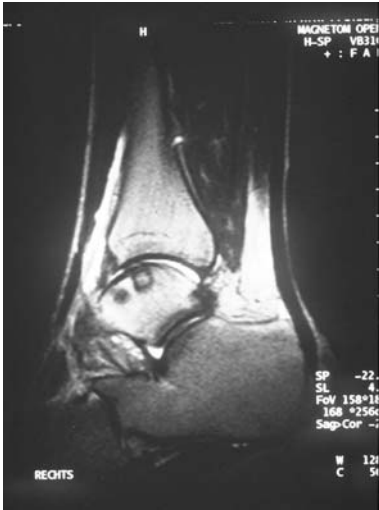

Fig. 41. MRI image of the ankle after implantation of osteochondral plugs for the treatment of a cartilage defect on the talus.

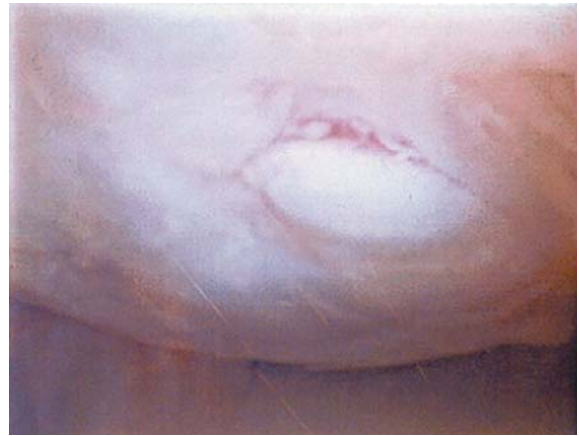

Fig. 42. Arthroscopic view 10 months after treatment of cartilage lesion on the femoral condyle with an osteochondral plug.

■ Advantages

- Autologous tissue, no artificial materials used
- Comparably cost-effective procedure (*cave*: several sets of instruments contain single-use articles)
- Arthroscopic technique may be used with restrictions
- Transplantation of hyaline articular cartilage.

■ Disadvantages

- Incomplete coverage of the defect
- Morbidity of donor site
- Limited availability of donor plugs
- Potential necrosis of centrally placed plugs
- Lesioning of the subchondral bone plate
- Irregular cartilage surface (Fig. 42).

To fill donor sites after osteochondral transplantation various materials have been used with no obvious advantage in comparison to empty donor sites. The morbidity of harvesting healthy cartilage from the trochlea is proven as well as the incomplete bonding between transplant and perifocal cartilage.

For retrofill and potentially for primary filling of osteochondral defects a resorbable bi-phasic polymer/calcium sulfate device was developed (TruFit[®]) as an *off the shelf* solution. Cylinders with a diameter from 5–11 mm actively incorporate spongy blood and elements to restore osteochondral defects. Pre-clinical studies showed next to complete osseous restoration the regeneration of a cartilage phase with a high content of collagen II. Specifically shaped implants will be available for treatment of patella/tibia or ankle lesions.

Principles of Cartilage Repair
Erggelet, C.; Mandelbaum, B.R.
2008, VIII, 121 p., Hardcover
ISBN: 978-3-7985-1590-1