

# 2

---

## Carotid Revascularization: Carotid Endarterectomy

---

*Marlene Grenon, MD, FRCSC*

*and Ravi S. Sidhu, MD, MEd, FRCSC, FACS*

### *CONTENTS*

INTRODUCTION  
PREOPERATIVE ASSESSMENT  
INDICATIONS FOR CEA  
SURGICAL TECHNIQUE  
COMPLICATIONS  
CONCLUSIONS  
REFERENCES

---

### ABSTRACT

Carotid endarterectomy (CEA) is a procedure that has reliably decreased the risk of cerebrovascular events and death in patients with severe carotid stenosis. In this chapter, important concepts in the preoperative assessment of patients undergoing CEA will be reviewed. An overview of the clinical trials highlighting current indications will be provided, followed by a discussion of the surgical technique, complications, and controversies related to CEA.

**Keywords:** Carotid endarterectomy; Technique; Patch

### INTRODUCTION

Stroke is the third leading cause of death in the United States, and the second leading cause of death worldwide (1). It is the most common cause of death as a result of a neurological disorder. About 750,000 patients are diagnosed with this entity yearly in the United States and more than 15 million around the globe (2), which corresponds to an incidence of new stroke of approximately 160 per 100,000 population per year (3, 4).

From: *Contemporary Cardiology: Carotid Artery Stenting: The Basics*

Edited by: J. Saw, DOI 10.1007/978-1-60327-314-5\_2,

© Humana Press, a part of Springer Science+Business Media, LLC 2009

## PREOPERATIVE ASSESSMENT

The patient with carotid stenosis may be asymptomatic or symptomatic with different stroke syndromes. The stroke syndromes include transient ischemic attack (TIA), stroke (with or without recovery), stroke in evolution, crescendo TIA, and, as considered by some, progressive intellectual dysfunction. The patient suffering from a stroke syndrome will usually undergo work-up with one or more radiological modalities. The causes of stroke are generally classified as atherosclerotic (20–30%), cardioembolic (30%), or other origin (40%). Several diseases or presentations may come into play, including changes in hemodynamic parameters, hematologic diagnosis, hereditary or degenerative disorders, inflammatory diseases, infectious problems, metabolic issues, intoxications (e.g., amphetamine), and vasospasm seen with migraine, trauma, or dissection. Hence, it is essential that investigations rule out other causes for the presenting stroke syndrome. Depending on the clinical presentation, potential investigations include ECG, telemetry, carotid duplex ultrasound, echocardiography, CT scan of the head, and basic laboratory blood tests.

With respect to carotid stenosis and specifically carotid bifurcation disease, angiography and duplex ultrasound are established methods of investigation. In view of the rapidly changing radiological diagnostic tools and the emergence of computed tomography angiogram (CTA) and magnetic resonance angiogram (MRA), familiarity with interpretation, limitations, and advantages of these modalities is important. In addition to defining the presence of carotid stenosis, other anatomic details are important to guide therapeutic alternatives and approaches. For example, anatomy which is known to complicate CEA and which may warrant consideration for CAS include low lesions, high lesions (above C2), prior CEA, history of other major neck operation (radical neck, laryngectomy, tracheostomy, etc.), cervical fusion or immobility, and prior neck radiation (5).

In the preoperative work-up of a patient, it is also important to consider if the patient is at “physiological” high risk for surgery, which may also warrant consideration for other alternatives such as carotid artery stenting or medical management. These factors include, but are not restricted to, advanced age, contralateral carotid occlusion, cardiac disease, and renal insufficiency (6).

It is of utmost importance in the evaluation of the patient who has recently suffered a stroke and has not recovered completely to assess whether he or she is a candidate for surgery. This requires considerable experience and judgment. Likewise, the timing of surgery is another controversial topic. It has been suggested that patients should wait 4–6 weeks after the event prior to proceeding with CEA (7, 8). However, the patient may be at high risk of a recurrent neurologic event during that period (9–11). After an ischemic event, the 30-day risk of stroke is 4.9% in the presence of severe carotid stenosis (12). On the other hand, the mortality and risk of stroke at CEA is 20% in the presence of stroke in evolution or crescendo TIA (13). Hence, this remains a subject of debate.

Particular steps in the preoperative management of patients planning to undergo CEA include the appropriate antiplatelet medication. Aspirin therapy is continued in the perioperative period. Anticoagulation with heparin should be considered prior to CEA for high-grade stenosis and symptoms (acute stroke or crescendo TIA) to prevent another ischemic episode or complete arterial occlusion (14, 15).

## INDICATIONS FOR CEA

The objective of CEA is the prevention of strokes. Carotid artery operations should be considered for patients where surgery will improve the natural history of the disease more than the corresponding medical treatment, if it can be done in a safe manner. The section below reviews conclusions made from the randomized trials conducted to compare CEA and medical management in patients with symptomatic and asymptomatic carotid stenosis.

### *Symptomatic Carotid Artery Stenosis*

The first study involving patients with symptomatic carotid stenosis was the Joint Study of Extracranial Arterial Occlusion (16), which began in 1959. This study randomized 1,225 patients to either CEA (621 patients) or medical management (604 patients). The survival rate at 43 months follow-up was significantly different, being 80% in the surgical group and 50% in the medical group. There were also less neurological events among the surgical group. This was the first strong evidence of the advantage of CEA over medical therapy in symptomatic carotid stenosis patients.

In the 1990s, three major studies were published which furthered the evidence for CEA: the North American Symptomatic Carotid Endarterectomy Trial (NASCET), the European Carotid Surgery Trial (ECST), and the Veterans Affairs Symptomatic Trial (VAST). Several problems remain with comparison of these studies because of the diagnostic measures used. For example, ultrasound exams were not standardized and the criteria used for severity of the carotid lesion were based on different catheter angiographic criteria.

NASCET enrolled from 50 centers in North America and segregated patients according to stenosis of 30–69% and 70–99% (angiographically). To be eligible to enter the study, the centers had to demonstrate CEA combined mortality and morbidity of <5%. Patients were eligible if they had a TIA or minor stroke within 3 months of randomization. In the group with 70–99% stenosis, 328 were randomized to CEA and 331 to medical therapy (which included aspirin and control of other risk factors). The study was stopped prematurely because of the superiority of CEA over medical therapy, and patients in the medical therapy group were advised to undergo CEA. Overall, the cumulative ipsilateral stroke risk was 9% in the surgical group and 26% in the medical group at 2 years ( $p < 0.001$ ). This corresponded to an absolute risk reduction of 17% and relative risk reduction of 65%. Numbers needed to treat were six patients at 2 years (12). For the group with 50–70% stenosis, there was moderate benefit of CEA over medical treatment (17). This corresponded to a relative risk reduction of 39%. The study however demonstrated no definite survival benefits for women and patients with retinal symptoms over hemispheric symptoms.

The ECST trial took place over 10 years and recruited 2,518 patients from 14 countries within 6 months of a stroke, TIA, or retinal infarction (18). Patients were divided into three groups, including carotid stenosis of 70–99, 30–69, and 0–29%, respectively. Randomization ratio was 1:2 for medical vs. surgical, and medical management was left to the treating physician. Patients with 70–99% stenosis had a lower risk of ipsilateral stroke (2.8% for CEA vs. 16.8% medical management) and lower risk of combined death, ipsilateral stroke, or any other stroke (12.3% CEA vs. 21.9% medical treatment) at 3 years with CEA. There was no significant advantage with CEA among the mild or moderate stenosis groups (18, 19).

The VAST trial was published in 1991 and included 189 symptomatic patients with carotid stenosis >50% from 16 centers. TIA was included in the primary end point (which also consisted of death and stroke). Overall, the risk of neurological event among patients randomized to CEA was 7.7 vs. 19.4% in the medical group at 12 months ( $p=0.011$ ) (20). A subgroup analysis of patients with greater severity of carotid stenosis >70% showed a larger proportional reduction in neurologic events with CEA. Thus, the study investigators concluded that CEA was more effective than medical management for patients with high-grade stenosis.

### *Asymptomatic Carotid Stenosis Trials*

Overall, five randomized trials had addressed the role of CEA among patients with asymptomatic carotid stenosis. These are the Carotid Surgery versus Medical Therapy in the Asymptomatic Carotid Stenosis (CASANOVA) trial, the Mayo Clinic Asymptomatic Carotid Endarterectomy trial, the Veterans Affairs Asymptomatic Trial (VAAT), the Asymptomatic Carotid Atherosclerosis Study (ACAS), and the Asymptomatic Carotid Surgery Trial (ACST) Collaborative Study.

The CASANOVA trial randomized patients with asymptomatic carotid stenosis (50–90%) to CEA (260 patients) or medical management (204 patients) which included aspirin. One hundred and eighteen patients in the medical arm crossed over to CEA because of pre-elected criteria of treating patients with bilateral stenosis >50% or unilateral stenosis >90% surgically. The analysis, which was done in an intention-to-treat manner, demonstrated no benefit of CEA over medical management (21). The study raised several criticisms related to the trial design, and thus the results should be interpreted with caution.

The Mayo Clinic study was a small study that randomized 71 patients with asymptomatic carotid stenosis. The study was terminated early because of high number of cardiac events among patients undergoing CEA, which had been attributed to the absence of aspirin in the surgical group (22). Too few neurological events occurred in the study, which prevented any meaningful conclusions.

The VAAT study included 444 men with internal carotid stenosis >50%. Two hundred and eleven patients were randomized to surgery and 233 to medical therapy alone (23). The combined ipsilateral neurological events were 8% among surgical patients and 20.6% among medically treated patients on Kaplan–Meier analysis ( $p<0.001$ ). The incidence of ipsilateral stroke alone was 4.7% in the surgical group and 9.4% in the medical group, with borderline significance ( $p=0.056$ ).

The ACAS study was the first influential trial for asymptomatic carotid stenosis up until the most recent ACST trial (19). This study randomized 1,662 men and women with asymptomatic (>60%) carotid stenosis to medical or surgical management. Overall, the ipsilateral stroke rate at 5 years from Kaplan–Meier analysis was 5.1% in the surgical group and 11% in the medical group ( $p=0.004$ ), which corresponded to a relative risk reduction of 53% and an absolute risk reduction of 1% per year.

The most recent and largest asymptomatic carotid stenosis randomized trial published is the Asymptomatic Carotid Surgery Trial (ACST) Collaborative Study (24). In this study, 3,120 asymptomatic patients with substantial carotid narrowing (>60%) were randomized between immediate CEA and indefinite deferral of any CEA. They were followed for up to 5 years. In the surgical group, the 5-year all-stroke risk was 6.4% compared to 11.8% in the deferral group ( $p<0.0001$ ), reducing the net 5-year risk of stroke by half in the population studied.

Lesions that may cause particular surgical dilemma are bilateral carotid lesions, contralateral carotid occlusion (with ipsilateral stenosis), and tandem lesions. At the present time, if bilateral carotid stenoses are found, two options are present. The first is to repair only the symptomatic side and follow the contralateral side. The other option is to treat both (usually at 6 weeks interval), proceeding first with CEA on the side with the higher degree of stenosis. It is not considered a safe option to address both sides simultaneously because of increased mortality and morbidity, particularly in the presence of tissue swelling, airway obstruction, or possibilities of bilateral palsies of the recurrent laryngeal nerve (25). In the presence of one occluded carotid artery and a contralateral carotid stenosis, the occluded side should obviously be left alone and the stenotic side addressed only if the intervention is thought to impact natural history (as the risk of surgery is increased with contralateral occlusion). Lastly, it is felt that in the presence of a tandem lesion, if the intracranial portion has a higher degree of stenosis than the extracranial portion, then it is best to treat it medically.

Ulcerated lesions are also a controversial issue. They are classified as type A if the length is  $<10\text{ mm}^2$ , type B if  $10\text{--}40\text{ mm}^2$ , and type C if  $>40\text{ mm}^2$  (26). Type C lesions are thought to have an associated risk of stroke of 7.5%/year (27). At the present time, it is thought that asymptomatic type A should be left alone. If a type C is present and the patient has acceptable risk, this may warrant prophylactic CEA. The decision for type B relies much on the surgeon's individual conviction and the experience of the operating team (26). These criteria for ulcerated lesions have not been subject to the same scientific scrutiny as the criteria for symptomatic and asymptomatic stenosis; hence, considerable surgical judgment is required.

### *Summary of the Indications*

The general indications for CEA are thus summarized in Table 1, adapted from reference (28).

**Table 1**  
**Indications for CEA in Patients with Carotid Artery Stenosis**

<i>Symptomatic patients (CEA morbidity and mortality <math>&lt;6\%</math>)</i>	
Proven indications	$\geq$ TIA in the last 6 months and carotid stenosis $\geq 70\%$ Mild stroke with carotid stenosis $\geq 70\%$
Acceptable indications	TIA in the past 6 months with stenosis 50–69%  Progressive stroke and stenosis $\geq 70\%$ Mild or moderate stroke in the past 6 months and stenosis 50–69% CEA ipsilateral to TIA and stenosis $\geq 70\%$ , combined with required coronary artery bypass grafting
Uncertain indications	TIA with stenosis $<50\%$  Mild stroke with stenosis $<50\%$ Symptomatic acute carotid artery thrombosis
Inappropriate indications	Moderate stroke with stenosis $<50\%$ , not receiving aspirin  Single TIA, stenosis $<50\%$ , not receiving aspirin High-risk patient, mild or moderate stroke, stenosis $<50\%$ , not receiving aspirin Global ischemic symptoms with stenosis $<50\%$ Acute internal carotid dissection, asymptomatic, receiving heparin

(Continued)

**Table 1**  
(Continued)

---

<i>Asymptomatic patients (CEA morbidity and mortality &lt;3%)</i>	
Proven indications	Stenosis $\geq 60\%$
Acceptable indications	None defined
Uncertain indications	High-risk patient or surgeon with a morbidity–mortality risk $>3\%$ Combined CEA and coronary artery bypass surgery Non-stenotic ulcerative lesions
Inappropriate indications	CEA combined stroke morbidity–mortality rate $>5\%$

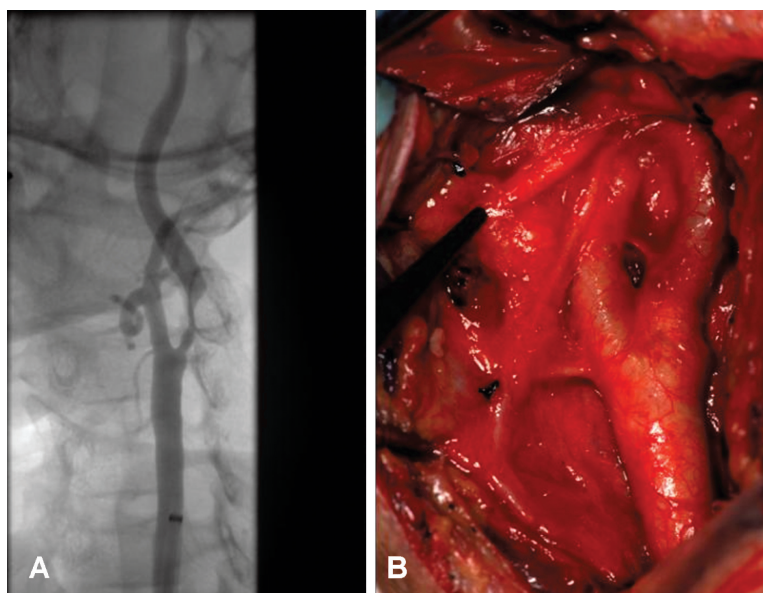
---

## SURGICAL TECHNIQUE

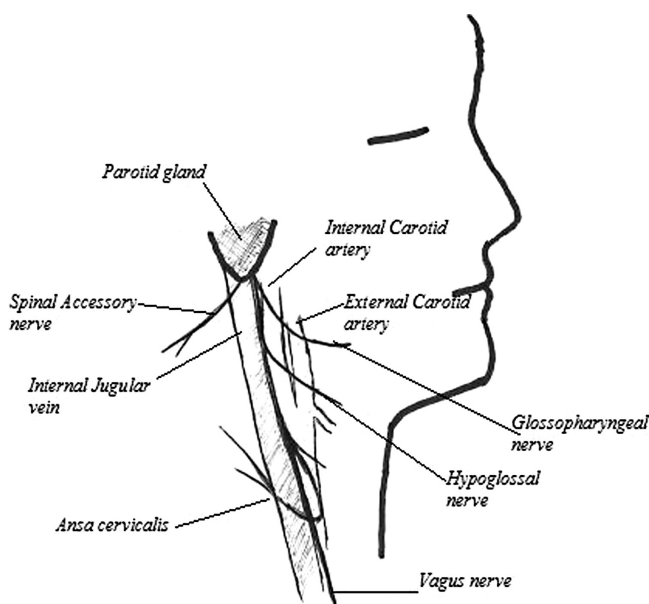
Patients undergoing CEA are kept NPO after midnight the day before surgery. They are taken to the operating room where a cervical block is done if local anesthesia is planned, or alternatively, they are placed under general anesthesia (see below for “*CEA Under Local Anesthesia vs. General Anesthesia*”). The patient is positioned with the neck slightly hyperextended and the head slightly turned away from the side to be operated on. The endarterectomy site is prepped and draped from the midline, in an area encompassing the clavicle, sternal notch, and mandible. The incision can be vertical along the anterior border of the sternocleidomastoid (SCM), on an imaginary line connecting the sternoclavicular junction and the mastoid process, or an oblique incision (across the skin crease over the side of the neck). The subcutaneous tissues are divided and the anterior border of the SCM identified. The dissection continues anterior to SCM until the facial vein, a tributary of the internal jugular vein, is encountered and ligated. The internal jugular vein is then usually retracted laterally and the carotid artery is identified (Fig. 1). Proximal control is obtained at the common carotid artery (CCA) proximal to the level of disease (usually at the level of the omohyoid muscle) by surrounding it with a vessel loop. If sinus bradycardia arises, 1–2 ml of 1% lidocaine is injected in the tissues between the external carotid artery (ECA) and the internal carotid artery (ICA).

Once proximal control is obtained, dissection is continued more distally around the ECA where vascular control is gained of the external carotid artery and its first branch, the superior thyroid artery. Subsequently, control should be gained distally at the ICA. Careful attention throughout the dissection is important to minimize manipulation of the carotid artery. Extreme care must be exerted during the dissection not to injure surrounding nerves, such as the vagus or hypoglossal nerves (Fig. 2). Dissection may lead to division of the ansa cervicalis, a branch of the hypoglossal nerve, which is acceptable. Some challenges may be encountered during the case, such as high ending of the plaque in the ICA or high bifurcation. If additional exposure is needed of the ICA, the first maneuver is to extend the skin incision all the way up to the mastoid process, which will allow division of the posterior belly of the digastric muscle. If further exposure is needed, the styloid process can be divided and the mandible displaced anteriorly.





**Fig. 1.** (A) Normal bifurcation of the left internal carotid artery at C4 as shown on angiography and (B) surgical appearance of the carotid bifurcation after cut-down during carotid endarterectomy.



**Fig. 2.** Surrounding nerves of the carotid artery.

Once proximal and distal control of the vessel is obtained, heparin is given intravenously (5,000 units). If it is decided to use shunting, the type and size of shunt should be decided upon prior to clamping the vessel. The vessel is clamped and/or loops tightened proximally and distally. A longitudinal arteriotomy is made from the CCA to the ICA. The plaque is endarterectomized using a small flat

surgical instrument by elevating the diseased plaque off the normal remaining arterial wall in a transmedial plane. It is critical to choose the optimal plane of dissection between the diseased intima and the circular fibers of the media. It is recommended to complete the endarterectomy proximally first (sharply), then to proceed to the distal portion of the vessel, which will often “flake away”. The vessel is then closed primarily or with a patch (see below, “*Patch vs. Primary Closure*”) using 6.0 polypropylene suture. Prior to unclamping, it is important to flush. The ICA is unclamped last.

Completion study may be performed as per the surgeons’ preference. This may include a completion angiogram or B-mode ultrasound with waveform analysis and continuous Doppler. If a defect or intimal flap is found, it should be corrected to prevent any thromboembolic complications. Once hemostasis is achieved, a soft drain may be left in place (to be removed the day after surgery). Protamine may be given at the surgeon’s discretion, keeping in mind possible hypotension and anaphylactic reactions. The platysma is closed with a running suture and the skin is approximated with clips or a subcuticular suture.

Patients are awakened in the operating room, where the surgeon ensures that no neurological deficit is present. They are then transferred to the recovery room where they are observed for a period of approximately 6 hours. Patients are usually discharged home on the first or second postoperative day if no complication occurs. They are continued on their antiplatelet and secondary preventative therapy.

Postoperatively, a carotid duplex should be performed at 2–6 weeks after CEA. If satisfactory, another duplex should be done 6 months to 1 year later, then every year subsequently. If there is evidence of moderate contralateral disease or recurrent stenosis, scanning may be performed at 6–12 month intervals (29).

### ***Shunting or Not***

No randomized trials have been conducted that demonstrate superiority of shunting (30), although routine shunt insertion is known to have low perioperative death and stroke rates (31). Even though some centers and surgeons recommend routine shunting, it is important to be aware that a shunt may be cumbersome during performance of the endarterectomy and closure of the vessel. Furthermore, there is a risk of plaque dislodgement and air embolization distal in the ICA. For those who do not perform routine shunting, the tolerance to cerebral clamping may be evaluated in several ways. If the operation is done under local anesthesia, 1–3 minutes after clamping is performed, the patient is asked to talk and perform a few mathematical tasks. Another approach is electroencephalographic monitoring, which has resurged recently after a period of disfavor. Lastly, others have advocated the assessment of back-bleeding, which may require considerable experience and judgment. Parameters that are evaluated include a back-bleeding pressure less than 25 mmHg (32).

### ***CEA Under Local Anesthesia vs. General Anesthesia***

CEA under local anesthesia allows evaluation of cerebral tolerance to clamping; however, it does add challenges to the operation. For example, anxious patients may add to the stress of the surgical team, especially if the case is protracted. Hence, it should be reserved for patients who are felt to be able to tolerate the psychological stress of the procedure. If the local anesthesia approach is chosen, collaboration is



needed between the anesthetist and the surgical team. A superficial cervical plexus block or a combination of superficial and deep cervical block may be used (33, 34) in combination with local anesthesia. Studies have suggested that stroke and death rates may be reduced by local anesthesia (35, 36). The frequency of arrhythmias and acute myocardial infarction also appears to be reduced (37). A randomized controlled trial (The General Anaesthetic versus Local Anaesthetic for Carotid Surgery Trial – GALA) is presently enrolling patients to assess this question.

In contrast, CEA under general anesthesia is felt to provide better control of the airway and ventilator mechanics. Furthermore, there may be improved cerebral blood flow and better tolerance to clamping with halogenated anesthetic agents (38). Lastly, it results in less stress to the surgical team compared to an awake patient, with easier control of intra-operative complications.

### ***Patch vs. Primary Closure***

Once endarterectomy is performed, the surgeon is confronted with the choice of primary closure of the carotid artery or the use of a patch material. The traditional approach is to patch patients believed to be at high risk of recurrence, such as women and those with small carotid arteries. Several randomized controlled trials (39–46) and meta-analyses (47–49) have been conducted that evaluated the outcomes of patch closure vs. primary closure during CEA. In a meta-analysis conducted in 2,000, patching was superior to primary closure (47). An update of the analysis performed by Bond in 2004 demonstrated that patching, with vein or prosthetic materials, significantly reduced the risk of ipsilateral stroke (1.6 vs. 4.5%) at 30 days (48). This benefit persisted over the long term, with a lower risk of carotid restenosis (18.6 vs. 4.8%). With regard to selective or “discretionary” patching, there have been a few reports to date (50–52). Pappas et al. (50) reported lower rates of stroke among primary closure patients but no long-term difference in restenosis. The authors concluded that selective patching was advocated. The other two studies reported no significant difference between patch closure and primary closure. These studies remain retrospective in nature. Based on these data, it appears that perhaps more evidence exists for routine patching, although it remains justifiable to use primary closure in large-caliber ICA (>6 mm diameter) (53).

### ***Type of Patch***

The different materials available for patching include autologous vein graft, Dacron, ePTFE, and bovine pericardium. Surgeons may have their preference based on the malleability or other characteristics of the material. A meta-analysis of seven randomized controlled trials reported little difference between the types of patch material (54). Hence, at the present moment, there is no consensus that any particular type of patch material is better than the other. A possible disadvantage of vein patch is patch disruption (55–58), and that of prosthetic material is infection.

### ***A Variant Approach: Eversion Endarterectomy***

Although most surgeons perform open CEA, some prefer the eversion endarterectomy technique. This involves a similar dissection as the standard endarterectomy. However, the origin of the ICA is then transected and the ICA is “rolled” up distally while removing the diseased plaque in the transmedial plane. At the end of the diseased plaque, the artery is “rolled back” and sewn to the carotid bifurcation.

This suture line is purported to be less prone to restenosis compared to closure of a longitudinal arteriotomy as is performed in a standard CEA. A randomized study has been conducted, followed by a Cochrane database review, which suggested that eversion endarterectomy may carry equivalent death and stroke rate (59–62). Downfalls of the technique are that not all patients are suitable, and the insertion of a shunt may be more difficult if it is needed. At the present time, however, it is still felt that the evidence is uncertain to firmly recommend one technique or another.

COMPLICATIONS

Complications related to CEA can be classified as early or late, and local or systemic (Table 2). Some of the most devastating complications involve the neurological system. These tend to occur early, within the first 30 days after surgery.

Early Complications

STROKE OR DEATH

Although most strokes are delayed (the patient initially wakes up postoperatively with normal neurological function), they tend to happen within the first 24 hours of surgery. These are usually due to endarterectomy site thrombosis and/or embolism. Death can also result from surgery, often in combination with a neurological event. Studies have reported a 30-day mortality of 1–3% in patients with symptomatic carotid stenosis (20, 63, 64) and 0.1–2% in patients with asymptomatic carotid stenosis (64, 65). The combined incidence of stroke and death in the same time period is 5.5–7.0% in the symptomatic patients and 1.5–4.5% in the asymptomatic patients. Community-based surveys follow these results closely (66–73).

HYPERPERFUSION/CEREBRAL HEMORRHAGE

The classic presentation of hyperperfusion and cerebral hemorrhage syndrome is unilateral headache, seizure, and cerebral hemorrhage, which peaks at postoperative

Table 2  
Complications Related to CEA

Early complications	Incidence
Stroke or death	5.5–7% symptomatic patients 1.5–4.5% asymptomatic patients
Hyperperfusion syndrome	2–3%
Cerebral hemorrhage	0.2–0.8%
Cranial nerve injury	8.6%
Hemorrhage requiring surgery	1–3%
Cardiac events	
– Cardiac death	0.4%
– Non-fatal myocardial infarction	0.8%
– Cardiac arrhythmias	1.6%
– Congestive heart failure	1.0%
– Angina	1.3%
Late complications	
Recurrent stenosis	10% at 2 years, 17% at 10 years
False aneurysm	Rare

days 2–7. The incidence of hyperperfusion is 2–3% (74–76), which in 0.2–0.8% progresses to cerebral hemorrhage (64, 77–79). The syndrome is thought to be secondary to changes in autoregulation in the cerebral territory of the endarterectomized carotid stenosis. It is critical to promptly and aggressively investigate and treat this complication.

### CRANIAL NERVE INJURIES

In the NASCET trial, the incidence of cranial nerve injury was 8.6%, with the hypoglossal being injured in 3.7% of cases, the vagus in 2.5%, and the marginal mandibular branch of the facial nerve in 2.2% (12, 80). Injury to the vagus nerve usually manifests as dysfunction of the recurrent laryngeal nerve and is noted by ipsilateral vocal cord paralysis with hoarseness of the voice, impaired phonation, and ineffective cough. Although the ansa cervicalis, a branch of the hypoglossal nerve, can be divided without much noticeable neurological deficit, division of the hypoglossal nerve itself will result in tongue palsy with impaired annunciation and deglutition. Injury to the marginal branch of the facial nerve will lead to drooping of the corner of the mouth and drooling.

Cranial nerve injuries that are less common include injury to the superior laryngeal nerve, spinal accessory nerve, glossopharyngeal nerve, and the sympathetic chain. Injury to the superior laryngeal nerve may result in voice fatigue and alteration, although it is mostly asymptomatic. Injury to the sympathetic chain may lead to Horner's syndrome. If the glossopharyngeal nerve is affected, impairment in swallowing and recurrent aspiration may occur. Spinal accessory injury may lead to shoulder pain and dropping and winging of the scapula. The greater auricular nerve may also be injured during the superficial part of the dissection. This will usually result in paresthesia and hyperesthesia around the ear.

### HEMORRHAGE AND INFECTION

Hemorrhage requiring surgical intervention occurs in about 1–3% of patients (64, 72, 81, 82). It is critical to be aware of this complication in order to avoid airway compromise. Disruption of the venous patch may happen in 0.1–0.7% of cases (55–58) and is usually due to poor quality of vein which leads to necrosis. Infection rarely occurs, but could lead to hemorrhage if situated in the deep tissues.

### SYSTEMIC COMPLICATIONS

Hemodynamic instability may be seen after CEA. Hypotension and bradycardia are usually related to hyperactivity of the carotid baroreceptor because of restoration of compliance of the vessel wall. Hypertension is secondary to absent or decreased baroreceptor activity. Cardiac complications reported in the NASCET trial (80) include perioperative cardiac deaths (0.4%), non-fatal myocardial infarctions (0.8%), arrhythmias (1.6%), congestive heart failure (1.0%), or angina (1.3%).

### *Late Complications*

#### RECURRENT STENOSIS

The meta-analysis by Frericks et al. demonstrated a rate of recurrence of 10% at 2 years and 17% at 10 years (83). It is important to distinguish recurrent stenosis from residual stenosis in the early postoperative period. During the first 2 years

post-CEA, the cause of recurrent stenosis is intimal hyperplasia, which often regresses. After several years post-CEA, progressive atherosclerosis is the usual cause.

### FALSE ANEURYSM

False aneurysms at the endarterectomy sites are extremely rare. Their incidence has decreased since monofilament sutures have been used for arteriotomy closure, which decrease the risk of infection.

## CONCLUSIONS

Carotid stenosis remains a major public health issue with an important burden on the population. Although CEA has demonstrated its efficacy over several decades now, a few controversies still remain with regard to the technical approaches. It will be interesting to see future long-term outcomes in comparison to carotid artery stenting. At the moment, it remains the gold standard to treat most patients with a high-grade carotid stenosis.

## REFERENCES

1. World Health Organization (WHO). Surveillance in brief: Update of noncommunicable diseases and mental health surveillance activities. Issue No. 5 Geneva, WHO, 5:1–5, 2003. Available at [www.who.int/entity/ncd\\_surveillance/media.org](http://www.who.int/entity/ncd_surveillance/media.org)
2. American Heart Association. Heart and Stroke Facts Statistics-1999: Statistical Supplement. American Heart Association, Dallas, TX.
3. Kannel WB. Epidemiology of cerebrovascular disease: an epidemiologic study of cerebrovascular disease. In American Neurological Association and American Heart Association: Cerebral Vascular Diseases. Grune & Stratton, New York, 1966, pp. 53–66.
4. Kuller LH, Cook LP, Friedman GD. Survey of stroke epidemiology studies: Committee on Criteria and Methods, Council of Epidemiology, American Heart Association. *Stroke* 1972;3: 579–85.
5. Schneider PA, Kasirajan K. Difficult anatomy: what characteristics are critical to good outcomes of either CEA or CAS? *Semin Vasc Surg* 2007;20:216–25.
6. Landis GS, Faries PL. A critical look at “high-risk” in choosing the proper intervention for patients with carotid bifurcation disease. *Semin Vasc Surg* 2007;20:199–204.
7. Caplan LR, Skillman J, Ojemann R, Fields WS. Intracerebral hemorrhage following carotid endarterectomy: a hypertensive complication? *Stroke* 1978;9:457–460.
8. Giordano JM, Trout HH, 3rd, Kozloff L, DePalma RG. Timing of carotid artery endarterectomy after stroke. *J Vasc Surg* 1985;2:250–255.
9. Dosick SM, Whalen RC, Gale SS, Brown OW. Carotid endarterectomy in the stroke patient: computerized axial tomography to determine timing. *J Vasc Surg* 1985;2:214–219.
10. Khanna HL, Garg AG. 774 carotid endarterectomies for strokes and transient ischemic attacks: comparison of results of early vs. late surgery. *Acta Neurochir Suppl (Wien)* 1988;42:103–106.
11. Gasecki AP, Ferguson GG, Eliasziw M, Clagett GP, Fox AJ, Hachinski V, Barnett HJ. Early endarterectomy for severe carotid artery stenosis after a non disabling stroke: results from the North American Symptomatic Carotid Endarterectomy Trial. *J Vasc Surg* 1994;20:288–295.
12. Beneficial effect of carotid endarterectomy in symptomatic patients with high-grade carotid stenosis. North American Symptomatic Carotid Endarterectomy Trial Collaborators. *N Engl J Med* 1991;325:445–453.
13. Nehler MR, Moneta GL, McConnell DB, Edwards JM, Taylor LM, Jr., Yeager RA, Porter JM. Anticoagulation followed by elective carotid surgery in patients with repetitive transient ischemic attacks and high-grade carotid stenosis. *Arch Surg* 1993;128:1117–1121; discussion 1121–1123.
14. Inzitari D, Eliasziw M, Gates P, Sharpe BL, Chan RK, Meldrum HE, Barnett HJ. The causes and risk of stroke in patients with asymptomatic internal-carotid-artery stenosis. North American Symptomatic Carotid Endarterectomy Trial Collaborators. *N Engl J Med* 2000;342:1693–1700.

15. Eckstein HH, Schumacher H, Dorfler A, Forsting M, Jansen O, Ringleb P, Allenberg JR. Carotid endarterectomy and intracranial thrombolysis: simultaneous and staged procedures in ischemic stroke. *J Vasc Surg* 1999;29:459–471.
16. Bauer RB, Meyer JS, Fields WS, Remington R, Macdonald MC, Callen P. Joint study of extracranial arterial occlusion. 3. Progress report of controlled study of long-term survival in patients with and without operation. *JAMA* 1969;208:509–518.
17. Barnett HJ, Taylor DW, Eliasziw M, Fox AJ, Ferguson GG, Haynes RB, Rankin RN, Clagett GP, Hachinski VC, Sackett DL, Thorpe KE, Meldrum HE, Spence JD. Benefit of carotid endarterectomy in patients with symptomatic moderate or severe stenosis. North American Symptomatic Carotid Endarterectomy Trial Collaborators. *N Engl J Med* 1998;339:1415–1425.
18. MRC European Carotid Surgery Trial: interim results for symptomatic patients with severe (70–99%) or with mild (0–29%) carotid stenosis. European Carotid Surgery Trialists' Collaborative Group. *Lancet* 1991;337:1235–1243.
19. Endarterectomy for asymptomatic carotid artery stenosis. Executive Committee for the Asymptomatic Carotid Atherosclerosis Study. *JAMA* 1995;273:1421–1428.
20. Mayberg MR, Wilson SE, Yatsu F, Weiss DG, Messina L, Hershey LA, Colling C, Eskridge J, Deykin D, Winn HR. Carotid endarterectomy and prevention of cerebral ischemia in symptomatic carotid stenosis. Veterans Affairs Cooperative Studies Program 309 Trialist Group. *JAMA* 1991;266:3289–3294.
21. Carotid surgery versus medical therapy in asymptomatic carotid stenosis. The CASANOVA Study Group. *Stroke* 1991;22:1229–1235.
22. Results of a randomized controlled trial of carotid endarterectomy for asymptomatic carotid stenosis. Mayo Asymptomatic Carotid Endarterectomy Study Group. *Mayo Clin Proc* 1992; 67:513–518.
23. Hobson RW, 2nd, Weiss DG, Fields WS, Goldstone J, Moore WS, Towne JB, Wright CB. Efficacy of carotid endarterectomy for asymptomatic carotid stenosis. The Veterans Affairs Cooperative Study Group. *N Engl J Med* 1993;328:221–227.
24. Mohammed N, Anand SS. Prevention of disabling and fatal strokes by successful carotid endarterectomy in patients without recent neurological symptoms: randomized controlled trial. MRC asymptomatic carotid surgery trial (ACST) collaborative group. *Lancet* 2004; 363: 1491–1502. *Vasc Med* 2005;10:77–78.
25. Betterman K, Toole JF. Diagnostic Evaluation of and Medical Management of Patients with Ischemic Cerebrovascular Disease. Rutherford Textbook of Vascular Surgery. 6th ed. W.B. Saunders, Philadelphia, PA; 2005, p.1906.
26. Moore WS, Boren C, Malone JM, Roon AJ, Eisenberg R, Goldstone J, Mani R. Natural history of nonstenotic, asymptomatic ulcerative lesions of the carotid artery. *Arch Surg* 1978;113: 1352–1359.
27. Dixon S, Pais SO, Raviola C, Gomes A, Machleder HI, Baker JD, Busuttill RW, Barker WF, Moore WS. Natural history of nonstenotic, asymptomatic ulcerative lesions of the carotid artery. A further analysis. *Arch Surg* 1982;117:1493–1498.
28. Moore, WS. Extracranial Cerebrovascular Disease: The Carotid Artery. Vascular and Endovascular Surgery. A Comprehensive Review. 7th ed. W.B. Saunders, Philadelphia, PA; 2006, p.634.
29. Ricotta JJ, DeWeese JA. Is routine carotid ultrasound surveillance after carotid endarterectomy worthwhile? *Am J Surg* 1996;172:140–142; discussion 143.
30. Counsell C, Salinas R, Naylor R, Warlow C. Routine or selective carotid artery shunting for carotid endarterectomy (and different methods of monitoring in selective shunting). *Cochrane Database Syst Rev* 2000;CD000190.
31. Naylor AR, Hayes PD, Allroggen H, Lennard N, Gaunt ME, Thompson MM, London NJ, Bell PR. Reducing the risk of carotid surgery: a 7-year audit of the role of monitoring and quality control assessment. *J Vasc Surg* 2000;32:750–759.
32. Moore WS, Hall AD. Carotid artery back pressure: a test of cerebral tolerance to temporary carotid occlusion. *Arch Surg* 1969;99:702–710.
33. Stoneham MD, Doyle AR, Knighton JD, Dorje P, Stanley JC. Prospective, randomized comparison of deep or superficial cervical plexus block for carotid endarterectomy surgery. *Anesthesiology* 1998;89:907–912.
34. Pandit JJ, Bree S, Dillon P, Elcock D, McLaren ID, Crider B. A comparison of superficial versus combined (superficial and deep) cervical plexus block for carotid endarterectomy: a prospective, randomized study. *Anesth Analg* 2000;91:781–786.



35. Fiorani P, Sbarigia E, Speciale F, Antonini M, Fiorani B, Rizzo L, Massucci M. General anaesthesia versus cervical block and perioperative complications in carotid artery surgery. *Eur J Vasc Endovasc Surg* 1997;13:37–42.
36. Tangkanakul C, Counsell C, Warlow C. Local versus general anaesthesia for carotid endarterectomy. *Cochrane Database Syst Rev* 2000;CD000126.
37. Allen BT, Anderson CB, Rubin BG, Thompson RW, Flye MW, Young-Beyer P, Frisella P, Sicard GA. The influence of anesthetic technique on perioperative complications after carotid endarterectomy. *J Vasc Surg* 1994;19:834–842; discussion 842–843.
38. Christensen MS, Hoedt-Rasmussen K, Lassen NA. Cerebral vasodilatation by halothane anaesthesia in man and its potentiation by hypotension and hypercapnia. *Br J Anaesth* 1967;39:927–934.
39. De Vleeschauwer P, Wirthle W, Holler L, Krause E, Horsch S. Is venous patch grafting after carotid endarterectomy able to reduce the rate of restenosis? Prospective randomized pilot study with stratification. *Acta Chir Belg* 1987;87:242–246.
40. Al-Rawi PG, Turner CL, Waran V, Ng I, Kirkpatrick PJ. A randomized trial of synthetic patch versus direct primary closure in carotid endarterectomy. *Neurosurgery* 2006;59:822–828; discussion 828–829.
41. Eikelboom BC, Ackerstaff RG, Hoeneveld H, Ludwig JW, Teeuwen C, Vermeulen FE, Welten RJ. Benefits of carotid patching: a randomized study. *J Vasc Surg* 1988;7:240–247.
42. Lord RS, Raj TB, Stary DL, Nash PA, Graham AR, Goh KH. Comparison of saphenous vein patch, polytetrafluoroethylene patch, and direct arteriotomy closure after carotid endarterectomy. Part I. Perioperative results. *J Vasc Surg* 1989;9:521–529.
43. Ranaboldo CJ, Barros D'Sa AA, Bell PR, Chant AD, Perry PM. Randomized controlled trial of patch angioplasty for carotid endarterectomy. The Joint Vascular Research Group. *Br J Surg* 1993;80:1528–1530.
44. Myers SI, Valentine RJ, Chervu A, Bowers BL, Clagett GP. Saphenous vein patch versus primary closure for carotid endarterectomy: long-term assessment of a randomized prospective study. *J Vasc Surg* 1994;19:15–22.
45. Katz D, Snyder SO, Gandhi RH, Wheeler JR, Gregory RT, Gayle RG, Parent FN, 3rd. Long-term follow-up for recurrent stenosis: a prospective randomized study of expanded polytetrafluoroethylene patch angioplasty versus primary closure after carotid endarterectomy. *J Vasc Surg* 1994;19:198–203; discussion 204–205.
46. AbuRahma AF, Khan JH, Robinson PA, Saiedy S, Short YS, Boland JP, White JF, Conley Y. Prospective randomized trial of carotid endarterectomy with primary closure and patch angioplasty with saphenous vein, jugular vein, and polytetrafluoroethylene: perioperative (30-day) results. *J Vasc Surg* 1996;24:998–1006; discussion 1006–1007.
47. Counsell C, Salinas R, Warlow C, Naylor R. Patch angioplasty versus primary closure for carotid endarterectomy. *Cochrane Database Syst Rev* 2000;CD000160.
48. Bond R, Rerkasem K, Naylor AR, Aburahma AF, Rothwell PM. Systematic review of randomized controlled trials of patch angioplasty versus primary closure and different types of patch materials during carotid endarterectomy. *J Vasc Surg* 2004;40:1126–1135.
49. Counsell CE, Salinas R, Naylor R, Warlow CP. A systematic review of the randomised trials of carotid patch angioplasty in carotid endarterectomy. *Eur J Vasc Endovasc Surg* 1997;13:345–354.
50. Pappas D, Hines GL, Yoonah Kim E. Selective patching in carotid endarterectomy: is patching always necessary? *J Cardiovasc Surg (Torino)* 1999;40:555–559.
51. Golledge J, Cumming R, Davies AH, Greenhalgh RM. Outcome of selective patching following carotid endarterectomy. *Eur J Vasc Endovasc Surg* 1996;11:458–463.
52. Cikrit DF, Larson DM, Sawchuk AP, Thornhill C, Shafique S, Nachreiner RD, Lalka SG, Dalsing MC. Discretionary carotid patch angioplasty leads to good results. *Am J Surg* 2006;192:e46–e50.
53. Byrne J, Feustel P, Darling RC, 3rd. Primary closure, routine patching, and eversion endarterectomy: what is the current state of the literature supporting use of these techniques? *Semin Vasc Surg* 2007;20:226–235.
54. Bond R, Rerkasem K, Naylor R, Rothwell PM. Patches of different types for carotid patch angioplasty. *Cochrane Database Syst Rev* 2004;CD000071.
55. Riles TS, Lamparello PJ, Giangola G, Imparato AM. Rupture of the vein patch: a rare complication of carotid endarterectomy. *Surgery* 1990;107:10–12.
56. Tawes RL, Jr., Treiman RL. Vein patch rupture after carotid endarterectomy: a survey of the Western Vascular Society members. *Ann Vasc Surg* 1991;5:71–73.
57. O'Hara PJ, Hertzner NR, Krajewski LP, Beven EG. Saphenous vein patch rupture after carotid endarterectomy. *J Vasc Surg* 1992;15:504–509.

58. Yamamoto Y, Piepgras DG, Marsh WR, Meyer FB. Complications resulting from saphenous vein patch graft after carotid endarterectomy. *Neurosurgery* 1996;39:670–675; discussion 675–676.
59. Cao P, Giordano G, De Rango P, Zannetti S, Chiesa R, Coppi G, Palombo D, Spartera C, Stancanelli V, Vecchiati E. A randomized study on eversion versus standard carotid endarterectomy: study design and preliminary results: the Everest Trial. *J Vasc Surg* 1998;27:595–605.
60. Cao P, Giordano G, De Rango P, Zannetti S, Chiesa R, Coppi G, Palombo D, Peinetti F, Spartera C, Stancanelli V, Vecchiati E. Eversion versus conventional carotid endarterectomy: late results of a prospective multicenter randomized trial. *J Vasc Surg* 2000;31:19–30.
61. Cao P, Giordano G, De Rango P, Caporali S, Lenti M, Ricci S, Moggi L. Eversion versus conventional carotid endarterectomy: a prospective study. *Eur J Vasc Endovasc Surg* 1997;14:96–104.
62. Cao P, De Rango P, Zannetti S. Eversion vs conventional carotid endarterectomy: a systematic review. *Eur J Vasc Endovasc Surg* 2002;23:195–201.
63. Randomised trial of endarterectomy for recently symptomatic carotid stenosis: final results of the MRC European Carotid Surgery Trial (ECST). *Lancet* 1998;351:1379–1387.
64. Ferguson GG, Eliasziw M, Barr HW, Clagett GP, Barnes RW, Wallace MC, Taylor DW, Haynes RB, Finan JW, Hachinski VC, Barnett HJ. The North American Symptomatic Carotid Endarterectomy Trial: surgical results in 1415 patients. *Stroke* 1999;30:1751–1758.
65. Towne JB, Weiss DG, Hobson RW, 2nd. First phase report of cooperative Veterans Administration asymptomatic carotid stenosis study – operative morbidity and mortality. *J Vasc Surg* 1990;11:252–258; discussion 258–259.
66. Bratzler DW, Oehlert WH, Murray CK, Bumpus LJ, Moore LL, Piatt DS. Carotid endarterectomy in Oklahoma Medicare beneficiaries: patient characteristics and outcomes. *J Okla State Med Assoc* 1996;89:423–429.
67. Karp HR, Flanders WD, Shipp CC, Taylor B, Martin D. Carotid endarterectomy among Medicare beneficiaries: a statewide evaluation of appropriateness and outcome. *Stroke* 1998;29:46–52.
68. Cebul RD, Snow RJ, Pine R, Hertzner NR, Norris DG. Indications, outcomes, and provider volumes for carotid endarterectomy. *JAMA* 1998;279:1282–1287.
69. Kucey DS, Bowyer B, Iron K, Austin P, Anderson G, Tu JV. Determinants of outcome after carotid endarterectomy. *J Vasc Surg* 1998;28:1051–1058.
70. Kresowik TF, Bratzler DW, Kresowik RA, Hendel ME, Grund SL, Brown KR, Nilasena DS. Multistate improvement in process and outcomes of carotid endarterectomy. *J Vasc Surg* 2004;39:372–380.
71. Kresowik TF, Hemann RA, Grund SL, Hendel ME, Brenton M, Wiblin RT, Adams HP, Ellerbeck EF. Improving the outcomes of carotid endarterectomy: results of a statewide quality improvement project. *J Vasc Surg* 2000;31:918–926.
72. Kresowik TF, Bratzler DW, Karp HR, Hemann RA, Hendel ME, Grund SL, Brenton M, Ellerbeck EF, Nilasena DS. Multistate utilization, processes, and outcomes of carotid endarterectomy. *J Vasc Surg* 2001;33:227–234; discussion 234–235.
73. Bond R, Rerkasem K, Rothwell PM. Systematic review of the risks of carotid endarterectomy in relation to the clinical indication for and timing of surgery. *Stroke* 2003;34:2290–2301.
74. Ascher E, Markevich N, Schutzer RW, Kallakuri S, Jacob T, Hingorani AP. Cerebral hyperperfusion syndrome after carotid endarterectomy: predictive factors and hemodynamic changes. *J Vasc Surg* 2003;37:769–777.
75. Coutts SB, Hill MD, Hu WY. Hyperperfusion syndrome: toward a stricter definition. *Neurosurgery* 2003;53:1053–1058; discussion 1058–1060.
76. Ogasawara K, Yukawa H, Kobayashi M, Mikami C, Konno H, Terasaki K, Inoue T, Ogawa A. Prediction and monitoring of cerebral hyperperfusion after carotid endarterectomy by using single-photon emission computerized tomography scanning. *J Neurosurg* 2003;99:504–510.
77. Solomon RA, Loftus CM, Quest DO, Correll JW. Incidence and etiology of intracerebral hemorrhage following carotid endarterectomy. *J Neurosurg* 1986;64:29–34.
78. Schroeder T, Sillesen H, Boesen J, Laursen H, Sorensen P. Intracerebral haemorrhage after carotid endarterectomy. *Eur J Vasc Surg* 1987;1:51–60.
79. Piepgras DG, Morgan MK, Sundt TM, Jr., Yanagihara T, Mussman LM. Intracerebral hemorrhage after carotid endarterectomy. *J Neurosurg* 1988;68:532–536.
80. Paciaroni M, Eliasziw M, Kappelle LJ, Finan JW, Ferguson GG, Barnett HJ. Medical complications associated with carotid endarterectomy. North American Symptomatic Carotid Endarterectomy Trial (NASCET). *Stroke* 1999;30:1759–1763.

81. Kunkel JM, Gomez ER, Spebar MJ, Delgado RJ, Jarstfer BS, Collins GJ. Wound hematomas after carotid endarterectomy. *Am J Surg* 1984;148:844–847.
82. Welling RE, Ramadas HS, Gansmuller KJ. Cervical wound hematoma after carotid endarterectomy. *Ann Vasc Surg* 1989;3:229–231.
83. Frericks H, Kievit J, van Baalen JM, van Bockel JH. Carotid recurrent stenosis and risk of ipsilateral stroke: a systematic review of the literature. *Stroke* 1998;29:244–250.



<http://www.springer.com/978-1-60327-313-8>

Carotid Artery Stenting: The Basics

Saw, J. (Ed.)

2009, X, 264 p., Hardcover

ISBN: 978-1-60327-313-8

A product of Humana Press