

2

Laparoscopic Anatomy of the Pelvis

Intra-Abdominal Anatomy of the Male Pelvic Region

- Bladder
- Medial Umbilical Ligaments
- Lateral Umbilical Ligaments
- Spermatic Cords
- Iliac Vessels
- Ureters
- Seminal Vesicular Complex
- Rectum and Sigmoid Colon
- Retropubic Space
 - Pubis
- Obturator Muscles
- Bladder
- Endopelvic Fascia
- Santorini's Plexus
- Prostatic Fascia and Prostatic Pedicles

Prostatic Fascia

- Denonvilliers' Fascia
- Rectourethralis Muscle
- Prostatic Neurovascular Plexus
- Accessory Pudendal Arteries
- Sphincteric Complex
 - Urethra
 - Rhabdomyosphincter

Intra-Abdominal Anatomy of the Female Pelvic Region

- Overview and Compartments
- Bladder and Urethra
- Vagina, Cervix, and Uterus
- Ovaries and Fallopian Tubes
- Ureters
- Vascular and Lymphatic Supplies
- Nerve Supply

Intra-Abdominal Anatomy of the Male Pelvic Region

A view of the anterior pelvic wall within the abdomen shows three cord-like peritoneal folds that appear to attach the bladder to the umbilicus: the median umbilical ligament (or median umbilical fold) and two medial umbilical ligaments (or medial umbilical folds). The median umbilical ligament extends from the dome of the bladder to the umbilicus and corresponds to the remnants of the fetal urachus. The medial umbilical ligaments arise from the pelvis as a continuation of the internal iliac artery and extend to the umbilicus. These are the obliterated segments of the fetal hypogastric arteries. More laterally, the lateral umbilical ligaments consist of peritoneal folds covering the epigastric vessels. Further laterally, the

spermatic vessels can be visualized entering the deep inguinal ring (Figure 2.1).

Bladder

The dome of the bladder is the mobile portion of the bladder, and it stands out centrally. The anatomic relationships of the bladder change according to its level of fullness. Because a Foley catheter must be inserted into the bladder before the pneumoperitoneum is created, the bladder is initially empty and its limits are not clearly demarcated. As the bladder fills, its limits become more clearly delineated. Laterally, it expands toward the medial umbilical ligaments; anterior and superiorly, it expands toward the median umbilical ligament and the umbilicus, to which it is attached through the urachus.

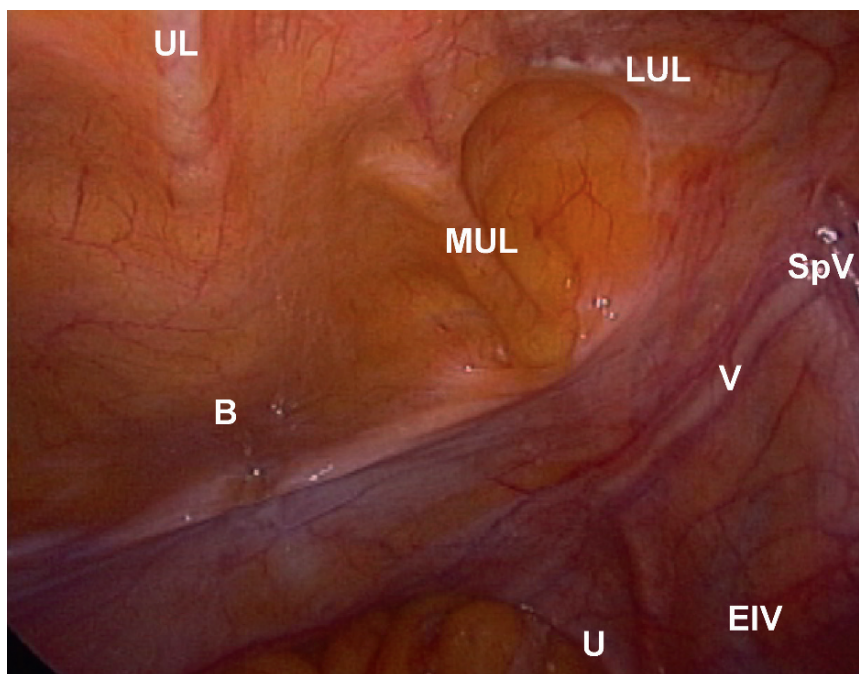


FIGURE 2.1. Umbilical ligaments (transperitoneal view of right hemipelvis). UL = median umbilical ligament, MUL = medial umbilical ligament, LUL = lateral umbilical ligament, B = bladder, V = vas deferens, SpV = spermatic vessels, EIV = external iliac vein, U = ureter

The median umbilical ligament (urachus) constitutes a fibromuscular cord, broad at its attachment to the bladder but narrowing as it ascends. It is a vascularized structure with few vessels that need to be controlled during dissection of the bladder. This fulguration can be avoided in case the urachus is spared. Laterally, the median umbilical ligament is separated from the medial umbilical ligament by the medial umbilical fossa, an anatomic landmark to access the space of Retzius.

It is important to emphasize the coalescence of the urachus and medial umbilical ligaments to the anterior parietal peritoneal wall during embryologic development to understand the planes that need to be incised during avascular access to the space of Retzius. Similar to the coalescence of the colonic gutters to the parietal peritoneal wall to form the fascias of Toldt, both the urachus and umbilical ligaments coalesce to the anterior parietal peritoneal wall; this is the plane that must be identified and developed to dissect the bladder off the anterior wall in a bloodless field (see LAPAROSCOPIC RADICAL PROSTATECTOMY, Chapter 9).

The pouch of Douglas ([Figure 2.2](#)) appears as a cul-de-sac between the bladder anteriorly and the rectum posteriorly. Its depth varies among patients, and it is used to make a posterior approach to the seminal vesicles. The exact location of the seminal vesicles cannot be readily visualized, but they are often found about 2 cm above the deepest part of the pouch of Douglas. The outline of the seminal vesicles and the distal portions of the vas deferens are occasionally visible in thin patients.

The visceral peritoneum and the underlying fat, which compose the anterior aspect of the pouch of Douglas that covers the bladder posteriorly, are rich in small vessels that should be fulgurated when incised to gain access to the seminal vesicles so that the surgical field is kept as bloodless as possible.

Medial Umbilical Ligaments

In the fetus, the hypogastric artery is twice as large as the external iliac artery, and it is the direct continuation of the common iliac artery. It ascends

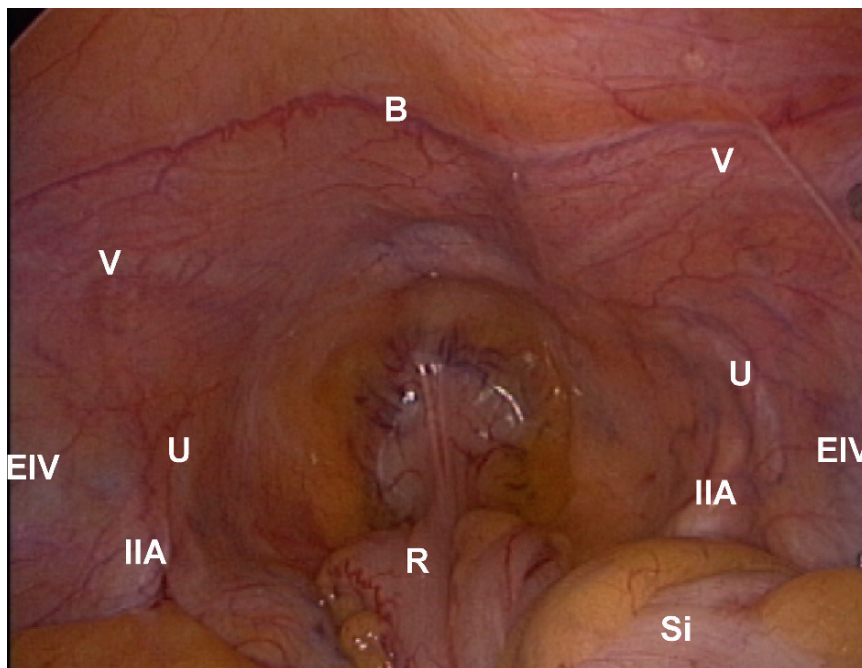


FIGURE 2.2. Pouch of Douglas. B = bladder, V = vas deferens, U = ureter, IIA = internal iliac artery, EIV = external iliac vein, R = rectum, Si = sigmoid colon

along the side of the bladder and runs upward on the back of the anterior abdominal wall to converge at the umbilicus with the hypogastric artery of the opposite side. Having passed through the umbilical opening, the two arteries, now termed umbilical, enter the umbilical cord, where they are coiled around the umbilical vein, and ultimately ramify in the placenta.

At birth, when the placental circulation ceases, only the pelvic portion of the artery remains patent and constitutes the hypogastric and the first part of the superior vesical artery in the adult; the remainder of the umbilical artery is converted into a solid fibrous cord, the medial umbilical ligament. This ligament is rarely vascularized and most often completely obliterated. The prominence of the medial umbilical ligaments varies depending on the amount of adipose tissue around it. The medial umbilical ligaments are particularly easy to see in laparoscopy and represent an important anatomic landmark for dissection not only of the pelvic lymph nodes but also of Retzius' space.

The ureter travels over the iliac vessels to run medial and deep to the medial umbilical ligament. Therefore, as long as the surgeon is able to visualize the umbilical ligament during pelvic lymph node dissection and dissect lateral to it, the ureter will not be at risk (see Chapter 7).

Laterally, the medial umbilical ligament is separated from the lateral umbilical ligament (the fold of peritoneum covering the inferior epigastric artery) by the medial umbilical fossa. This fossa is transversely divided into two portions by the vas deferens to form a quadrangle anteriorly and a triangle posteriorly. While the anterior quadrangle delimits an avascular access to Retzius' space, the posterior triangle is crucial to gain access to the obturator fossa for pelvic lymph node dissection. The vas deferens forms its base anteriorly, the external iliac vein laterally, and the medial umbilical ligament medially; the ureter can be visualized at the apex of the triangle (as it crosses over the iliac vessels) as well as deep on its medial aspect (Figure 2.3).

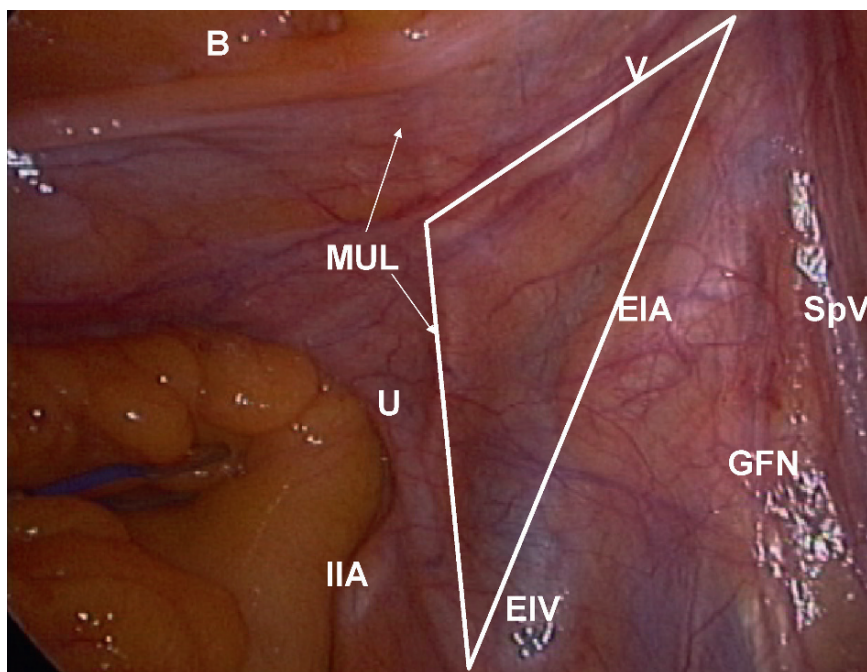


FIGURE 2.3. Base of vasculodeferential triangle composed of vas deferens (V) anteriorly, of medial umbilical ligament (MUL) medially, and of medial aspect of external iliac vein (EIV) laterally; triangle contains obturator lymph nodes along with obturator nerve and vessels (not visible). SpV = spermatic vessels, EIA = external iliac artery, GFN = genitofemoral nerve, B = bladder, U = ureter, IIA = internal iliac artery

Lateral Umbilical Ligaments

The inferior epigastric artery is a medial branch of the distal segment of the external iliac artery. It ascends along the medial margin of the deep inguinal ring, continues between the rectus abdominis muscle and the posterior lamina of its sheath, and then abuts on the anterior parietal peritoneum to create the lateral umbilical ligament. This ligament is the least pronounced of the three aforementioned peritoneal folds, and it is not always readily visualized. However, knowledge of its location is important to avoid injury to these vessels during either insertion of the lateral trocars or dissection of the space of Retzius.

Spermatic Cords

The spermatic cord is formed by the convergence of the lymphovascular packet draining the testes, the vas deferens, the corresponding nerves (the genital branch of the genitofemoral nerve and the

ilioinguinal and sympathetic spermatic plexus), and the gonadal vessels. The gonadal artery runs over the iliopsoas muscle and joins the vas deferens before entering the deep inguinal ring. The gonadal veins ascend on the psoas major, behind the peritoneum, lying on each side of the gonadal artery. They unite to form a single vein, which opens on the right side at an acute angle into the inferior vena cava, and on the left side at a right angle into the left renal vein.

The vas deferens is rarely visible at the postero-lateral aspect of the prostate but becomes more visible as its course becomes more superficial laterally as it crosses over the external iliac vessels.

Again, the vas deferens and the medial umbilical ligament are major landmarks for pelvic lymph node dissection: the vertical incision of the parietal peritoneum lateral to the medial umbilical ligament and posterior to the vas deferens provides the initial access to the obturator fossa. The external iliac vein can be immediately identified laterally, with the external iliac artery located further anterolaterally.

Iliac Vessels

The external iliac artery is easily recognized pulsating below the overlying parietal peritoneum fold at the level where the vas deferens joins the gonadal vessels.

Lateral to the external iliac artery is the genitofemoral nerve, which can eventually be used for nerve grafting after resection of the prostatic neurovascular bundle. The genitofemoral nerve descends on the surface of the psoas major, under cover of the peritoneum, and divides into the external spermatic and lumboinguinal nerves. The external spermatic nerve (the genital branch of the genitofemoral nerve) descends behind the spermatic cord to the scrotum, supplies the cremaster muscle, and provides a few filaments to the skin of the scrotum. The lumboinguinal nerve (the femoral branch of the genitofemoral), which descends superficial and lateral to the femoral artery, pierces the anterior layer of the sheath of the vessels and the fascia lata. It supplies the skin of the anterior surface of the upper part of the thigh.

The external iliac vein is medial and posterior to the external iliac artery. It can be masked by an aneurysmal or tortuous iliac artery. Furthermore, the pressure of the pneumoperitoneum compressing the vein can sometimes obscure its visualization. In this situation, delineation of the vein may be improved by decreasing the intra-abdominal pressure.

Longitudinal incision of the peritoneum lying over the medial umbilical ligament posterior to the vas deferens exposes the external iliac vein. Its medial aspect can be easily and safely dissected, except for its most distal segment where one or two veins branching medially can be identified. The first one is the accessory obturator vein, which comes off the obturator foramen to drain into the external iliac vein just posterior to Cloquet's node. The second is the venous component of the corona mortis, which is an anastomotic artery and vein between the epigastric and the obturator vessels. Proximally, the internal iliac or hypogastric vein, which composes the superior limit of the pelvic lymph node dissection, is identified going posteriorly. Dissection at the confluence of the internal and external iliac veins allows access first to the obturator nerve and, more posteriorly, to the superior vesical artery and superior gluteal vessels. The external iliac vessels are located more anteriorly on the right side than on the left.

The obturator nerve is located posterior and medial to the external iliac vein. It appears as a white, shining, striated, usually flattened cord that enters the obturator fossa distally. Proximally, it is located at the convergence of the internal and external iliac veins. The obturator artery, a primary or secondary branch of the internal or even external iliac artery, usually runs posterior to the obturator nerve, and the obturator vein is commonly located further posteriorly. Anatomic variations of the pelvic vessels are common, and careful dissection is always required to avoid their inadvertent injury.

The limits of the pelvic lymph node dissection are formed by the external iliac vein laterally, the medial umbilical ligament medially, the pelvic floor and the anterior surface of the hypogastric artery posteriorly, Cooper's ligament distally, and the bifurcation of the iliac vein proximally. In other words, the lymph nodes around both the obturator artery and external iliac vein are removed as well as those lying on the anterior aspect of the hypogastric artery (see Chapter 7).

Ureters

The ureters can be easily identified in two locations as soon as the pelvis is entered. The clearest one is where they cross over the common iliac vessels to then form the posteromedial limit of the pelvic lymph node dissection. Identification of the left ureter can be difficult when the sigmoid colon is adhered to the parietal peritoneum. In rare cases, depending on the patient's distribution of adipose tissue, the ureters can also be seen through the transparent lateral walls of the pouch of Douglas as they go below the vas deferens.

For this reason, the initial transverse incision on the anterior aspect of the pouch of Douglas to gain access to the seminal vesicles posteriorly should be no longer than 2 cm laterally to avoid any damage to the ureters as they pass below the vas deferens. In theory, the ureters should not be seen at this level; if they can be visualized, the incision has been continued too far laterally.

Seminal Vesicular Complex

The seminal vesicular complex is composed of the distal portion of the two vas deferens prolonged by the ampullae, and the two seminal vesicles. The entire complex is rarely visible through the visceral

Laparoscopic Techniques in Uro-Oncology

Guillonneau, B.; Gill, I.S.; Janetschek, G.; Türk, I.A.

2009, XI, 163 p., Hardcover

ISBN: 978-1-84628-521-9