



The Assessment of Thyroid Nodules

Klaus-Martin Schulte

Introduction

The assessment of a thyroid nodule serves several purposes. The patient may experience symptoms from a functional or sizable lesion, or may be at risk of cancer. A thorough history and blood test for TSH, eventually combined with a technetium (Tc) scan, will promptly identify a hyperfunctioning nodule. Symptoms related to the size of a nodule are usually indicated by the patient, and may be crucial in the treatment-making process.

Determining the risk of cancer in a nodule can be a more difficult concept, and the approach involves medical, rational, economic, and cultural considerations. It should be remembered that in dealing with a thyroid nodule, the evidence with regard to outcome, including the prevention of death, and morbidity, from thyroid cancer, is sparse. The natural course of a micro-cancer or small cancer is not known. They are both frequent findings in postmortem examinations that seem to have caused no morbidity to those who died from natural or other causes. Therefore neither common sense nor evidence supports the assumption that the health of a population or of an individual benefits from an overly aggressive approach to early or small cancers.

For example; in the commonest cancer, papillary thyroid cancer (PTC), there is no evidence that treatment in the earliest stage offers a

significant benefit compared with treatment at a slightly later point, when the increase in size of a suspicious nodule has provided evidence that the lesion is dynamically growing. In other words, while the patient may have a risk of cancer, indeed even in the presence of cancer, it is important to avoid causing undue fear to patients, and harm from invasive or unnecessary investigations. The appropriate timing of the assessment for a suspect follicular thyroid cancer (FTC) is equally unclear but is complicated by the fact that undue delay may lead to a scenario where distant metastases have become established from early haematogenous spread. For the less common medullary thyroid cancer (MTC) there is overwhelming evidence that early detection and treatment results in an improved outcome. For anaplastic thyroid cancer (ATC) only early treatment provides a chance of survival.

Based on the enormous variety of biological behaviors and clinical significance of the different forms of thyroid cancer we should question, what we hope to achieve, in assessing a thyroid nodule. Do we want to exclude all risk of cancer? (i.e., histologically classify every lesion). Or do we want to reduce the actual risks of cancer by detecting and treating those cancers, which have a likely or proven propensity to damage the patient? These questions are of both academic, and more importantly, practical relevance. The attempt to exclude all risk of cancer would require an algorithm that enables the fail-safe

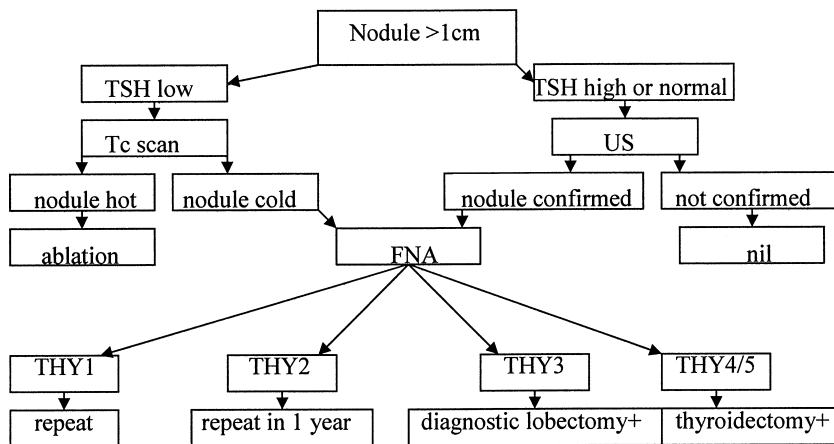


Fig. 2.1. Algorithm for oligosymptomatic and slow-growing solitary or dominant nodules >1 cm.

work-up of every lesion, in a given short time period. The key questions relating to the malignant risk of a thyroid nodule are:

- Do we need to work up every nodule, or target a subgroup?
- To what degree of certainty do we need to exclude malignancy?
- What is the timeline for coming to a definitive diagnosis?

Neither of these key questions can be answered with certainty based on current data, and much of the matter is one of opinion. This should be kept in mind when guidelines and recommendations are read and interpreted. It is a matter of concern that recommendations are not infrequently considered absolute whilst their evidence base is recognizably poor.

Whilst the question of which nodules need to be targeted, is subject to debate, there are many indications that narrow timelines for arriving at a diagnosis are unlikely to benefit the majority of patients, whilst may be vital for some. There is little evidence of clinical benefit for the approach chosen by a number of policy makers and by entire health systems such as the National Health System of England, where the "Improvement of Outcome Guidelines" prescribes narrow timelines for any "suspicious" lesion. These guidelines administer a complex and highly prescriptive referral and deadline system, regardless of the type of cancer and our understanding of tumor biology and its clinical impact. The physician-led attempt to

reduce the actual risks of cancer should take a more considered approach and target those lesions with an adverse clinical potential (Fig. 2.1). Growing functional or symptomatic lesions, those with loco-regional or distant metastasis and those of dangerous nature, such as medullary and anaplastic cancer and lymphoma, need to be assessed with urgency and sometimes immediate treatment, whilst those of an obviously less-aggressive nature need a thorough though more delicate approach.

The Rapidly Growing Nodule

The rapidly growing thyroid nodule can rarely be life threatening. These are almost always malignant unless they have grown within minutes or hours, in which case they are usually due to haemorrhage into a cyst. Rapid fluctuant growth of a neck nodule can also relate to sepsis within the oropharyngeal cavity with abscess formation. Clinical examination and inflammatory parameters will rapidly clarify this. Rapid growth of a solid thyroid mass within days or weeks almost always corresponds to ATC or lymphoma. In both conditions the diagnostic work-up needs to be performed with urgency (Fig. 2.2). Complex imaging with CT or MRI scans is of secondary importance and may be postponed for hours or days. The vital first step is to obtain a core needle biopsy (rather than a fine needle aspiration) with urgent processing.

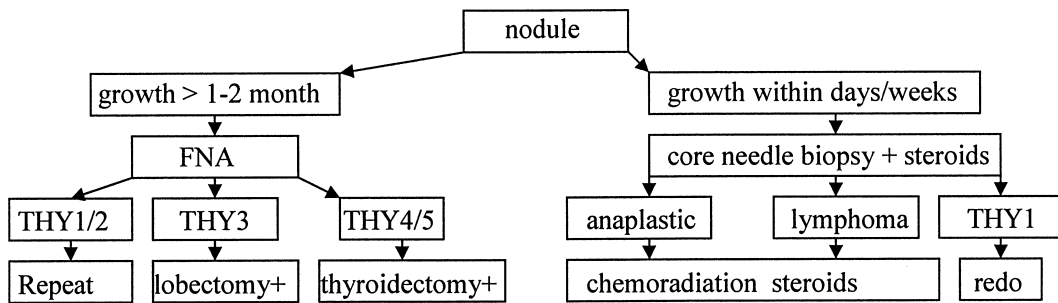


Fig. 2.2. Algorithm for symptomatic and fast-growing nodules.

It is crucial that the receiving pathologist is made aware of the urgency and the clinical differential diagnosis. Given the infiltrative nature of these tumors it may be advantageous to perform an ultrasound (US)-guided biopsy. Lack of availability of such technique must not delay diagnosis, however, and one should then proceed to an immediate palpation-guided biopsy. In our experience there are no reliable parameters to differentiate between ATC and lymphoma on clinical grounds. The course of patients with fulminating lymphoma of the neck can be dramatically changed with intravenous high-dose steroid therapy, which can produce effects within hours, and has few relevant side effects. In this scenario any demands for an urgent tracheostomy should be countered with calm. Such an undertaking is surgically hazardous and may obstruct rational pathways of local external beam radiation. The sequence of action for these nodules is clinical assessment, core needle biopsy with rapid processing of samples, ad hoc start of high-dose intravenous steroid therapy and only then further assessment of the extent of disease followed by specific therapy.

Definition of a Thyroid Nodule

A thyroid nodule is a distinct lesion within the thyroid gland. It may be palpated and/or defined by US. Not all nodules found by palpation actually relate to discrete nodules as defined by US. Not all nodules found by US are palpable since they may be either too small, inaccessible, or of similar consistency to the surrounding tissue. Impalpable nodules have the same risk of malignancy as palpable nodules of the same size [1].

History and Clinical Examination

In patients presenting with local symptoms or a relevant family history, the mainstay of initial diagnosis in any thyroid nodule is history taking and clinical examination (Table 2.1). A nodule must be considered with a high index of suspicion when it is

- fast growing;
- associated with voice change or stridor;
- seen in a patient with a family history of thyroid cancer;
- appears before the age of 14 years;
- appears after prior radiation or exposure to radioactive fallout;
- in a patient with flushing ;
- firm or immobile;
- associated with lymph node swelling in the neck;
- associated with palpable tumor elsewhere.

Nodule Size and Morphology

Size is the most intuitive of all criteria used to evaluate whether a thyroid nodule requires further work-up (Fig. 2.1). It is however amongst the most disputed [2]. Even a small thyroid cancer with a diameter of less than a centimetre can be associated with loco-regional and distant metastases. On the other hand, small thyroid cancers, called microcancers, have been reported at autopsy in around one third of the population who died from unrelated causes. This leaves us with the questions: 1. Which patients should have further investigations once a small thyroid

**Table 2.1.** Clinical history and examination

History		
Symptoms	Local	speed of growth, pain, swallowing difficulties, voice change, time course
	General	hypo-/hyperthyroidism, B-symptoms, lymphadenopathy, eye problems, vasculitis, gastrointestinal symptoms, bone pain, palpitation, high blood pressure, flushing, diarrhoea, skeletal symptoms
Family	Benign	Graves' disease or chronic thyroiditis, hypertension, pheochromocytoma, calcium excess
	Malignant	thyroid cancer, bowel cancer, other cancer, MEN
Inducing factors	General	country of origin, iodine supply, infectious conditions
	Individual	external beam radiation of local or neighbouring regions, whole whole-body radiation, exposure to radioactive fallout before age 14, work in poorly controlled areas with radiation
Physical examination		
Thyroid	Nodule	size, side, site, consistency, mobility, tenderness
	Other thyroid	other nodules, consistency of thyroid tissue, vibrancy,
Neck	Airway	voice quality, tracheal shift, stridor, positional airway obstruction
	Soft tissues	thyroid in upper thoracic aperture, central or lateral lymphadenopathy, inducibility of swallowing symptoms
General		eyes, signs of hyper/hypothyroidism, palpable masses, lymphadenopathy, dysmorphic findings

nodule is discovered? 2. How do we define “small”? A look at some published guidelines provides us with quite varied answers:

The American Thyroid Association (ATA) Thyroid Guidelines task force recommends that only nodules >1 cm diameter merit further work-up, unless there are specific suspicious features, such as a positive family history for thyroid cancer, history of radiation exposure, or suspicious US features [3]. The British Thyroid Association guidelines for thyroid cancer do not address the issue [4]. The American Association of Clinical Endocrinologists (AACE) guidelines state “an arbitrary diameter cut-off of 10 or 15 mm for cancer risk is not justified” [5]. The American Society of Radiologists in Ultrasound provides us with a consensus that only nodules >2 cm should routinely undergo fine needle aspiration (FNA) [6]. This chapter does not attempt to provide a valid answer. There is no conclusive evidence for any of these positions. In practical terms a cutoff is needed, and this could well vary with multiple factors. A nodule <1 cm in a young patient with a family history of thyroid cancer should trigger an in-depth investigation, whilst a 2-cm nodule may perhaps be disregarded in the 80-year old with multiple comorbidities effectively limiting

life expectation. Highly expensive imaging and work-up of all sub-centimetre nodules may be “affordable” for some societies, but the detection of malignancy is low and the cost high in terms of patient worry and morbidity. Size remains the most obvious criterion from clinical examination, but the clinical and to a certain degree the social and economic circumstances should also be taken into account.

A frequent and difficult problem is the assessment of several nodules in the setting of multinodular goiter. Under such conditions FNA may initially not target the relevant nodule because the choice is made on size criteria. Equally, the relevant nodule may be targeted, but missed due to insufficiencies of the approach. Furthermore multiple needle approaches may scare the patient and may prove time-consuming for the clinician. The problem is often dismissed, because no adequate resolution can be achieved or the patient is forwarded for a total thyroidectomy with the need for lifelong thyroid hormone replacement therapy and its surveillance. Since goiter is an extraordinarily frequent finding, specifically in areas of suboptimal iodine intake, the problem of multiple thyroid nodules of indeterminate nature is one of the most commonly encountered diagnostic problems. FNA is unable to



differentiate benign and malignant conditions in follicular neoplasm. The likelihood of finding thyroid cancer following an FNA suggestive of a follicular neoplasm, Hurthle cell lesion or indeterminate result, decreases with the increasing number of other thyroid nodules. In one large study the risk of malignancy in the target lesion was twice as high when the lesion was solitary as compared with those where 1–3 further nodules were present [7]. This author believes that individual nodules in a multinodular goiter should be specifically assessed if they are dominant, i.e., much larger or of different structure than the surrounding tissue and nodules, or if they show significant growth.

Thyroid Function

Hyperthyroidism (see also Chapter 6) in conjunction with a palpable or impalpable nodule is a frequent and functionally important condition, however, the thyroid nodule requires assessment out with the functional endocrine aspects. The guidelines provided by the British Thyroid Association shifts all patients with an abnormal TSH into routine endocrine referral pathways, whilst it recommends a speedier work-up through cancer-related pathways for many other scenarios [4]. This statement may be based on the long-held belief that thyroid cancer in toxic nodules is a rare event. However, this misses the point that the thyroids of many patients with hyperthyroidism harbor nodules, which are not related to excess hormone production and may be either nonfunctional or normally functioning. These nodules do not fall into a low-risk category because they occur in a thyroid which also produces excess hormone. They merit the same scrutiny as proposed for nodules in the euthyroid patient of the same size. A recent retrospective study on 2,449 patients with hyperthyroidism has found an astonishingly high rate of thyroid cancer [8]. Thyroid cancer was found in 6.5% of Graves' disease with one or more nodules, in 4.4% of those with a solitary toxic nodule and in 3.9% of those with a multinodular toxic goiter. Lymph node involvement was seen twice as frequently in the Graves group (56%). Based on these figures US-guided (USG)-FNA of all cold nodules in hyperthyroid patients with nodules has to be recommended.

Another useful though not fully explained finding, is that serum concentration of thyroid-stimulating hormone (TSH) also helps to determine the malignant risk of nodular lesions [9]. As a rule, the risk of cancer significantly and continuously increases with rising TSH levels even within the normal range of TSH. The risk of cancer was several-fold higher in patients with a TSH above the normal range compared with those with a low-normal TSH. Similar results were reported in a study which assessed the likelihood of cancer in 843 patients undergoing thyroid surgery [10]. Here again, the group with a high-normal TSH had a threefold increased risk of cancer compared with the group with a low-normal TSH.

In summary, an abnormal TSH increases the likelihood of finding a cancer in a patient with a thyroid nodule. Such patients should be viewed with a higher index of suspicion.

Fine Needle Aspiration

FNA is today the mainstay in the assessment of a thyroid nodule. It is a simple, fast, and inexpensive procedure, which obtains cellular material for cytological analysis. FNA is recommended as first-line test for almost all nontoxic nodular thyroid changes above a certain size and relevant guidelines coincide with this point.

Recently a series of 2,587 consecutive patients undergoing thyroid US found nodules larger than 1 cm in 14%. USG FNA was performed [11]. Cytology had a positive predictive value (PPV) of 97% and a negative predictive value (NPV) of 99.7%. The cancer rate in those referred for surgery was 56%, which is much higher than typical yields, which tend to stagnate around 20%. In general, the sensitivity and specificity of an FNA to predict malignancy is thought to be 80–95%.

There is enough study data to indicate that dismissal of a thyroid nodule based on the fact that it is impalpable may be inappropriate. A study of 494 consecutive cases [12] with impalpable nodules revealed thyroid malignancy in ~9% of solitary nodules, and in ~6% of multinodular goiters. Cancer prevalence was similar for nodules greater than, or smaller than, 10 mm (9.1 vs 7.0%).

Whilst there is consensus on the use of FNA for the primary assessment of thyroid nodules,



there is no agreed algorithm of what to do with those patients in whom one FNA is benign. There is considerable evidence that a repeat FNA would improve cancer detection. Overall, performance of a single-repeat FNA increased the sensitivity for malignancy from 81.7 to 90.4% and decreased the false-negative rate from 17.1 to 11.4%. With more than one repeat FNA, there was no further improvement in performance [13]. Repeat FNAs are most to be beneficial where a lack of experience or equipment leads to inadequacies in sampling or subsequent cytological assessment. The above quoted study delineates results at the upper range of FNA-proficiency. In clinical practice, repeated FNA during long-term follow-up may be needed to detect thyroid cancer in a suspicious nodule [14, 15].

Freehand and USG FNA

A lot has been said and written about the choice between USG and freehand FNA. Most studies demonstrate a significantly higher yield of diagnostic aspirates if US is used to guide the procedure. Danese [16] compared the diagnostic accuracy of palpation-guided, i.e., PG-FNA versus, USG-FNA on a large sample population of 9,683 patients. About 4,986 patients were investigated by PG-FNA and 4,697 underwent USG-FNA leading to a valid cytological diagnosis in 85.9 and 91.5%, respectively with a diagnosis of thyroid cancer in 1.6 and 2.1%, respectively. Specimens were cytologically inadequate in 433 PG-FNAs (8.7%) but only in 167 USG-FNA cases (3.5%). False-negative results occurred in seven PG-FNA nodules (2.3%) but only in three USG-FNA cases (1%). Sensitivity, specificity, and global diagnostic accuracy of PG-FNA compared with USG-FNA were 91.8 versus 97.1%, 68.8 versus 70.9%, and 72.6 versus 75.9%, respectively.

Generally, inadequacy rates are around 5–20%, and it is well documented that the experience of the performer seriously impacts on adequacy rates with up to tenfold difference in outcomes. However, conclusions should be drawn with common sense. Larger, well-palpable, easily located nodules can be well targeted with PG-FNA, whilst small, posterior, hardly palpable or impalpable nodules will require USG-FNA. If these rules are adhered to, it is

less the choice of guiding technique, but the presence of a cytologist at the sampling site, which determines the adequacy rate of FNAs. If smears are reviewed immediately, inadequate samples can be recognized and the test repeated [17]. The largest group of inadequate samples was obtained from cystic lesions, and of course these were best recognized and targeted using US.

The results of FNA are of varying quality depending on the type of lesion subjected to the test. It is worth reviewing the findings from more than two decades at the Mayo clinic. When cytology showed a follicular neoplasm the final histology was cancer in 15% (83/561); Hurthle cell neoplasm 14% (77/548); PTC 65% (318/489); with an overall rate of cancer of 29% (478/1,598) [18].

Although FNA is generally considered a very safe procedure, bleeding into cysts or even massive intrathyroid haemorrhage with acute airway obstruction can result from the procedure. It is important for the surgeon to know that FNA may result in temporary and rarely in permanent vocal cord palsy. A study on 10,974 patients undergoing FNA revealed four symptomatic cases of temporary recurrent nerve palsy amounting to about 0.04%. [19] However, there may be a higher rate of undetected asymptomatic paralyses, which when unmasked by surgery could be wrongly ascribed to the surgical intervention.

Ultrasound in Malignant and Benign Nodules

The yield of US is highly observer-dependent. It requires experience, time, and dedication as well as good equipment. The latter has recently become much more accessible in form of handheld devices coupled to laptop computers.

The main role of US is the identification of all thyroid nodules, their characterization (Fig. 2.3), and relative position to vascular and other structures. It has become clear that malignancy is as frequently found in impalpable, as in palpable lesions. A survey of the literature shows that the majority of reported thyroid cancers are small. US is the single most important gateway to discovery of such lesions. Screening US of 16,352 patients in one center

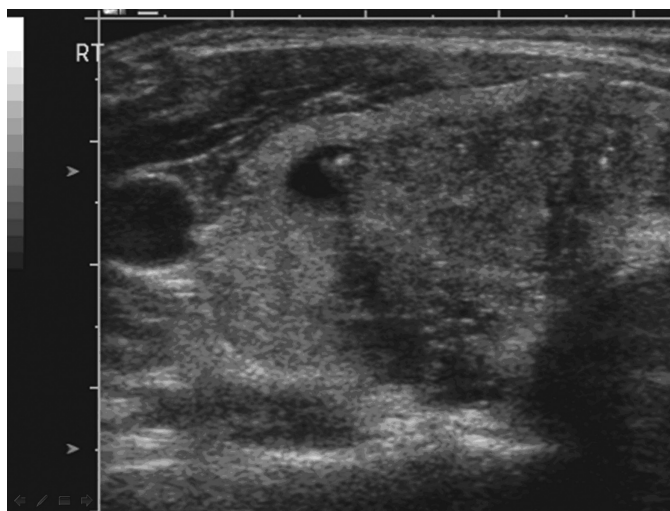

Fig. 2.3. Ultrasound of PTC with calcifications and irregular margins (courtesy of Dr PS Sidhu, Radiology, King's College Hospital, London).

[20] discovered 1,325 impalpable nodules. They were subjected to FNA, which revealed 150 malignant nodules. Features suggestive of malignant change were marked hypoechogenicity, an irregular shape, a taller-than-wide shape, a well-defined spiculated margin, absence of hypoechoic halo around the nodule, microcalcification, and an entirely solid nature ($p < .05$). A size cutoff of 1 cm in the longest diameter was not significant ($p = .184$), however, extracapsular invasion ($p = .024$) and lymph node metastasis ($p = .019$) were observed more frequently in carcinomas >1 cm (73 and 42%, respectively) than in microcarcinomas (38 and 13%). Microcalcifications are one of the most specific US findings of a thyroid malignancy [21]. In performing US it is important to examine the central and lateral compartments with utmost care and record the level-specific location of any enlarged lymph nodes. These may be infrequent findings, but their presence is important in the diagnosis of cancer as well as highly informative for the surgeon in planning surgery. Local invasion of adjacent structures is infrequent, but when detected is valuable information. The number, size, and interval growth of nodules are nonspecific. The interpretation of diffusely infiltrative thyroid carcinomas and multifocal carcinomas can be difficult based on US appearances. However, US robustly

describes the solid, cystic, or mixed nature of the lesion. As such, US is a powerful tool to exclude a huge group of nodules from further examination and work-up. Even in patients with an USG-FNA, the major reason for a missed diagnosis of PTC is inadequate tumor sampling due to the heterogeneity of the nodule [22].

CT and MRI

Computed tomography (CT) has no role in the routine assessment of thyroid nodules.

Recent studies have reported on the use of dynamic contrast-enhanced magnetic resonance imaging (DCE-MRI). Only small series are available so far. One has shown that the sensitivity and the NPV of DCE-MRI is superior to that of USG-FNA [23]. The data basis is not solid enough to give recommendations for a more widespread use of this potentially helpful but expensive screening method.

Nuclear Medicine

Nuclear medicine techniques remain paramount in the diagnosis and treatment of thyroid cancer. Their role in the work-up for thyroid nodules is much more limited today. Tc



scanning remains a first-line test in patients with a low or suppressed TSH, in whom the scan differentiates between focal and generally increased thyroid uptake or strongly contributes to the diagnosis of thyroiditis, when uptake is low.

Tc-99m scanning has long been used to evaluate the malignant potential of thyroid nodules. However, there is large variability in its use and recommendations around its use. These are related to the fact that there is relatively little hard data to indicate that it is a sensitive and specific test. The role of Tc scanning of the thyroid changed during the 1990s, and it is now considered a second-line tool in the evaluation of thyroid nodules and recommended only after thyroid function tests and FNA [24]. In clinical practice it may be used to help stratify the risk of malignancy in a nodule, when an FNA has failed. The assumption is that hot or warm nodules rarely harbor cancer, and that cold nodules alone would need more aggressive, e.g., surgical treatment. Malignancy is not less likely even in hyperthyroid patients. It is of note, however, that the largest retrospective study on cancer incidence in hyperthyroid patients used “cold nodules” as a trigger for surgical treatment and therefore for clarification with histology. [8]

Tc-99m methoxy isobutylisonitrate (MIBI) can be taken up by thyroid cancer. When used in cold solitary nodules it has a specificity of 95% and a PPV >90%, whilst the sensitivity is around 84%. Larger prospective studies are needed to evaluate the usefulness of such an approach.

A recent smaller study of delayed Tc-Tetrofosmin scintigraphy in the detection of thyroid cancer showed a sensitivity, specificity, PPV, and NPV of 86.6, 97.2, 92.8, and 94.7%, respectively [25]. It remains to be clarified whether such usefulness can be confirmed in larger cohorts and in the more common setting of multinodular goiter.

The Role of Calcitonin Screening

It has long been debated whether Calcitonin should be systematically measured in patients with thyroid nodules. Measurement of serum Calcitonin has a very high sensitivity and specificity for MTC, depending on the cutoff levels (Fig. 2.4).

Those in favor argue that such screening would detect a small but significant number of presymptomatic and hence likely curable MTCs and might detect a very small number of index cases with familial MTC and multiple endocrine neoplasia (MEN). Those against refer to the high cost of the assay and the low yield of the test. A large study published in 2007 obtained a baseline Calcitonin in 5,817 consecutive patients and identified 15 patients with MTC (0.26%) and 7 patients with C-cell hyperplasia (0.13%) [26]. PPV for basal CT levels in the diagnosis of MTC were 23.1% for values ≥ 20 pg/ml, 100% for values >100 pg/ml, 25% for levels between 50 and 100 pg/ml, and 8.3%

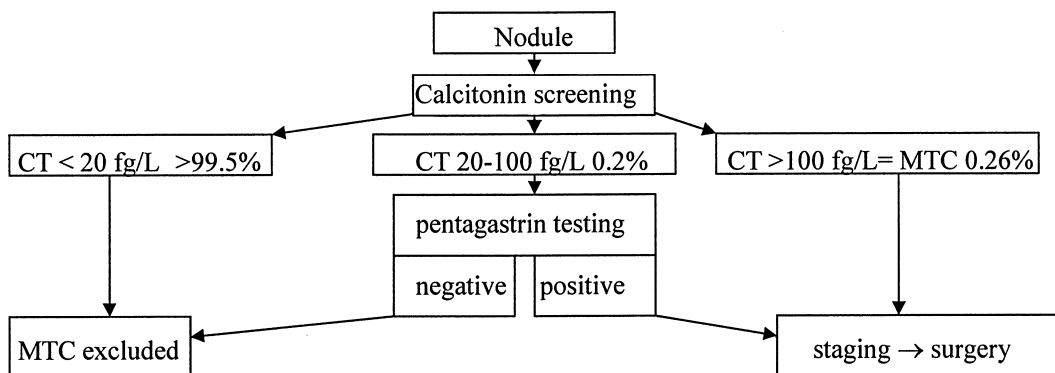


Fig. 2.4 Calcitonin screening for the detection of MTC.



for values between 20 and 50 pg/ml. PPV for the pentagastrin test (>100 pg/ml) was 40%.

Calcitonin screening of thyroid nodules is a highly sensitive test for early diagnosis of MTC, but confirmatory stimulation testing is necessary in most cases to identify a true-positive increase. We feel that exclusion of MTC and associated conditions specifically in the younger age group would lead to a significant reduction in life-years lost due to thyroid cancer in general, since survival rates of MTC are so much poorer than and PTC or FTC. When this endpoint is chosen, it is likely that Calcitonin testing may turn out to be more health-effective and cost-effective than the routine US and FNA of small thyroid nodules.

Thyroid Cancer Gene Expression Profiling and Proteomics

As details on gene expression patterns in thyroid cancers are gathered there is hope for the identification of novel diagnostic biomarkers. While individual studies have proposed hot candidates, none has yet been introduced into routine clinical practice. The reasons for delay include difficulties in achieving reproducible and reliable results from small samples and the lack of sensitivity and specificity of individual markers. A meta-analysis of gene expression-profiling studies has identified a dozen "hot" candidates such as MET, TFF3, SERPINA1, TIMP1, FN1, and TPO, as well as relatively novel or uncharacterized genes [27]. A recent study using differential gene expression has shown that a small set of 19 genes can be used to differentiate benign from malignant follicular neoplasms and other cancers based on FNA material [28]. These results await validation in a prospective clinical trial.

An alternative pathway to gene expression profiling is pattern analysis of proteins by proteomics. This technique faces specific problems in thyroid samples due to the huge fraction of thyroglobulin in specimen. However, prefractionation techniques now allow a much narrower analysis of samples, with clearly definable patterns for nodular versus normal thyroid tissue [29].

2-^[18F] fluoro-2-deoxy-D-glucose-Positron Emission Tomography (18)

A number of studies have evaluated the role of 2-^[18F] fluoro-2-deoxy-D-glucose-positron emission tomography (FDG-PET) for diagnosis and staging of thyroid cancer. A large survey in 2007 did not identify an established role for PET or PET-CT [30]. High costs, ranging between \$1,200 and \$2,600, make it an unlikely tool for primary assessment of thyroid nodules. However, some authors propose the use of FDG-PET in thyroid nodules in which FNA has failed to clarify the diagnosis [31]. The sensitivity for detection of malignancy with FDG-PET is high, but the specificity is <40%. The most remarkable feature of FDG-PET is the NPV. In most studies this approaches 100% [32]. Lesions without focal uptake are highly unlikely to be malignant. The presence of uptake, however, does not predict malignancy, and is a common feature of follicular lesions of any type [33]. This test, though expensive, could be useful in the minority of patients in whom FNA has repeatedly failed, and surgical risks are high, such as recurrent nodular changes or an increased general morbidity.

Relationship of Thyroid Nodules with Other Conditions, e.g., Systemic Cancer, Lymphoma, or Septic Diseases

Thyroid abscess is a rare pathology underlying a thyroid nodule. Today, a diagnostic needle aspiration may not only identify the causative agent, it may also be therapeutic, when followed by appropriate antibiotic therapy. Recent decades have seen a rise in tuberculosis (TB). Thyroid TB remains a rare condition with less than 100 reported cases [34]. The presentation ranges from a single nodule to TB thyroiditis. Diagnosis is achieved by culture of FNA aspirates, followed by conservative management with anti-TB drugs.



Specific Situations

Nodules Presenting in Pregnancy

There is no evidence that thyroid nodules diagnosed during pregnancy behave more aggressively. It is important that thyroid function tests are obtained and pregnancy-related iodine deficiency associated with rise in TSH is ruled out. Work-up is similar to that of the nodule in the general population. US and FNA are safe in pregnancy. Of course nuclear medicine scanning and X-ray exposure are contraindicated. There is hardly ever an indication for invasive diagnostic testing (e.g., by lobectomy) in the first trimester of pregnancy. Lobectomy is reasonably safe in the second trimester, but can, in almost all cases be safely postponed until after delivery and breastfeeding, unless there are convincing features of malignancy. In other cases, a follow-up US during pregnancy may be reassuring for mother and doctor. In general terms alarmism must be avoided and particular care needs to be taken to provide messages in the appropriate context.

Nodules Presenting in Childhood and Adolescence

Thyroid nodules in childhood and adolescence are rare. However, they have an increased risk of being malignant. PTC is the commonest cancer type. MTC in younger children is most commonly found in the context of MEN II, and FMTC. Although there is no firm evidence basis, we would recommend checking a serum Calcitonin in every child with a thyroid nodule. A family history is a clear risk factor for cancer, as is previous neck irradiation, the latter particularly in girls.

Thyroid nodules in children should be treated with a much higher index of suspicion, specifically when they are solitary. In our experience palpation is often a very revealing examination since the neck is amenable to palpation and subcutaneous tissue is mostly thin. The differential diagnosis comprises benign thyroid conditions such as congenital hypothyroidism, thyroid hemiagenesis, thyroglossal duct cyst, simple goiter, cystic lesion, nodular hyperplasia, follicular adenoma, nodular Graves' disease, and Hashimoto thyroiditis, which predisposes to the development of thyroid nodules

[35]. Scintigraphy alone or supported by US may help to identify thyroid dysgenesis.

Thyroid Nodules in Secondary Hyperparathyroidism

There is relatively little data on the prevalence of thyroid cancer in patients suffering from end-stage renal failure and secondary hyperparathyroidism (SHPT). One of the largest studies [36] describes simultaneous resection of some part of the thyroid mostly because of nodular disease in 133 (39%) of 339 of patients undergoing surgery for SHPT. PTC was found in eight patients (2.4%) and FTC in one patient. The cancers were all T1 tumors and many were only millimetres in diameter. The clinical relevance of these small incidental tumors is as uncertain as those found in autopsy studies.

The Nodule Detected on Whole-Body 18F-FDG-PET-CT

PET-CT is increasingly used for cancer staging and sometimes for screening. Based on more than 7,000 consecutive patients around 1.1% of such examinations discovered a focal thyroid uptake [37]. Further analysis revealed malignancy in roughly one third of such patients. The majority of lesions where PTCs, while rarely lymphoma or metastases from squamous cell cancer were found [37]. The amount of uptake does not allow a reliable differentiation between benign and malignant conditions in most published series.

References

1. Hagag P, Strauss S, Weiss M. Role of ultrasound-guided fine-needle aspiration biopsy in evaluation of nonpalpable thyroid nodules. *Thyroid*. 1998;8(11):989-995.
2. Burman KD. Micropapillary thyroid cancer: should we aspirate all nodules regardless of size? *J Clin Endocrinol Metab*. 2006;91(6):2043-2046.
3. Cooper DS, et al. Management guidelines for patients with thyroid nodules and differentiated thyroid cancer. *Thyroid*. 2006;16(2):109-142.
4. British Thyroid Association Royal College of Physicians, Guidelines for the management of thyroid cancer (Perros P, ed) 2nd edition. Report of the Thyroid Cancer Guidelines Update Group. , Available at http://www.british-thyroid-association.org/Thyroid_cancerguidelines2007.pdf. 2007.



5. American Association of Clinical Endocrinologists and Associazione Medici Endocrinologi medical guidelines for clinical practice for the diagnosis and management of thyroid nodules. *Endocr Pract.* 2006;12(1):63–102.
6. Frates MC. et al. Management of thyroid nodules detected at US: Society of Radiologists in Ultrasound consensus conference statement. *Radiology.* 2005; 237(3):794–800.
7. Sippel RS, Elaraj DM, Khanafshar E, Kebebew E, Duh QY, Clark OH. Does the presence of additional thyroid nodules on ultrasound alter the risk of malignancy in patients with a follicular neoplasm of the thyroid? *Surgery.* 2007;142(6):851–857.
8. Cappelli C et al. Outcome of patients surgically treated for various forms of hyperthyroidism with differentiated thyroid cancer: experience at an endocrine center in Italy. *Surg Today.* 2006;36(2):125–130.
9. Boelaert K, Horacek J, Holder RL, Watkinson JC, Sheppard MC, Franklyn JA. Serum thyrotropin concentration as a novel predictor of malignancy in thyroid nodules investigated by fine-needle aspiration. *J Clin Endocrinol Metab.* 2006;91(11):4295–4301.
10. Haymart MR, Repplinger DJ, Leverson GE, Elson DF, Sippel RS, Jaume JC, Chen H. Higher serum TSH level in thyroid nodule patients is associated with greater risks of differentiated thyroid cancer and advanced tumor stage. *J Clin Endocrinol Metab.* 2008;93(3): 809–814.
11. Yassa L, et al. Long-term assessment of a multidisciplinary approach to thyroid nodule diagnostic evaluation. *Cancer.* 2007;111(6):508–516.
12. Papini E, et al. Risk of malignancy in nonpalpable thyroid nodules: predictive value of ultrasound and color-Doppler features. *J Clin Endocrinol Metab.* 2002;87(5): 1941–1946.
13. Flanagan MB, Otori NP, Carty SE, Hunt JL. Repeat thyroid nodule fine-needle aspiration in patients with initial benign cytologic results. *Am J Clin Pathol.* 2006;125(5):698–702.
14. Illouz F, Rodien P, Saint-Andre JP, Triau S, Laboureaux-Soares S, Dubois S, Vielle B, Hamy A, Rohmer V. Usefulness of repeated fine-needle cytology in the follow-up of non-operated thyroid nodules. *Eur J Endocrinol.* 2007;156(3):303–308.
15. Menendez Torre E, Pineda Arribas J, Martinez de Esteban JP, Lopez Carballo MT, de Miguel C, Salvador P. Value of repeated fine needle aspiration cytology in patients with nodular goiter. *Acta Cytol.* 2007;51(6): 850–852.
16. Danese D, Sciacchitano S, Farsetti A, Andreoli M, Pontecorvi A. Diagnostic accuracy of conventional versus sonography-guided fine-needle aspiration biopsy of thyroid nodules. *Thyroid.* 1998;8(1):15–21.
17. Redman R, Zalaznick H, Mazzaferrri EL, Massoll NA. The impact of assessing specimen adequacy and number of needle passes for fine-needle aspiration biopsy of thyroid nodules. *Thyroid.* 2006;16(1):55–60.
18. Castro MR, Gharib H. Continuing controversies in the management of thyroid nodules. *Ann Intern Med.* 2005; 142(11):926–931.
19. Tomoda C, Takamura Y, Ito Y, Miya A, Miyauchi A. Transient vocal cord paralysis after fine-needle aspiration biopsy of thyroid tumor. *Thyroid.* 2006;16(7): 697–699.
20. Kim JY, Lee CH, Kim SY, Jeon WK, Kang JH, An SK, Jun WS. Radiologic and pathologic findings of nonpalpable thyroid carcinomas detected by ultrasonography in a medical screening center. *J Ultrasound Med.* 2008;27(2):215–223.
21. Hoang JK, Lee WK, Lee M, Johnson D, Farrell S. US Features of thyroid malignancy: pearls and pitfalls. *Radiographics.* 2007;27(3):847–860; discussion 861–845.
22. Siddiqui MA, Griffith KA, Michael CW, Pu RT. Nodule heterogeneity as shown by size differences between the targeted nodule and the tumor in thyroidectomy specimen: a cause for a false-negative diagnosis of papillary thyroid carcinoma on fine-needle aspiration. *Cancer.* 2008;114(1):27–33.
23. Tunca F, Giles Y, Salmaslioglu A, Poyanli A, Yilmazbayhan D, Terzioğlu T, Tezelman S. The preoperative exclusion of thyroid carcinoma in multinodular goiter: Dynamic contrast-enhanced magnetic resonance imaging versus ultrasonography-guided fine-needle aspiration biopsy. *Surgery.* 2007;142(6):992–1002.
24. Cases JA, Surks MI. The changing role of scintigraphy in the evaluation of thyroid nodules. *Semin Nucl Med.* 2000;30(2):81–87.
25. Sharma R, et al. Role of 99mTc-Tetrofosmin delayed scintigraphy and color Doppler sonography in characterization of solitary thyroid nodules. *Nucl Med Commun.* 2007;28(11):847–851.
26. Costante G, et al. Predictive value of serum calcitonin levels for preoperative diagnosis of medullary thyroid carcinoma in a cohort of 5817 consecutive patients with thyroid nodules. *J Clin Endocrinol Metab.* 2007;92(2): 450–455.
27. Griffith OL, Melck A, Jones SJ, Wiseman SM. Meta-analysis and meta-review of thyroid cancer gene expression profiling studies identifies important diagnostic biomarkers. *J Clin Oncol.* 2006;24(31):5043–5051.
28. Durand S, et al. Evaluation of gene expression profiles in thyroid nodule biopsy material to diagnose thyroid cancer. *J Clin Endocrinol Metab.* 2008;93(4): 1195–1202.
29. Krause K, Schierhorn A, Sinz A, Wissmann JD, Beck-Sickingher AG, Paschke R, Fuhrer D. Toward the application of proteomics to human thyroid tissue. *Thyroid.* 2006;16(11):1131–1143.
30. Facey K, Bradbury I, Laking G, Payne E. Overview of the clinical effectiveness of positron emission tomography imaging in selected cancers. *Health Technol Assess.* 2007;11(44):iii–iv, xi–267.
31. Sebastianes FM, et al. Role of 18F-fluorodeoxyglucose positron emission tomography in preoperative assessment of cytologically indeterminate thyroid nodules. *J Clin Endocrinol Metab.* 2007;92(11): 4485–4488.
32. de Geus-Oei LF, Pieters GF, Bonenkamp JJ, Mudde AH, Bleeker-Rovers CP, Corstens FH, Oyen WJ. 18F-FDG PET reduces unnecessary hemithyroidectomies for thyroid nodules with inconclusive cytologic results. *J Nucl Med.* 2006;47(5):770–775.
33. Kim JM et al. 18F-fluorodeoxyglucose positron emission tomography does not predict malignancy in thyroid nodules cytologically diagnosed as follicular neoplasm. *J Clin Endocrinol Metab.* 2007;92(5): 1630–1634.



34. Bulbuloglu E, Ciralik H, Okur E, Ozdemir G, Ezberci F, Cetinkaya A. Tuberculosis of the thyroid gland: review of the literature. *World J Surg.* 2006;30(2): 149–155.
35. Niedziela M. Pathogenesis, diagnosis and management of thyroid nodules in children. *Endocr Relat Cancer.* 2006;13(2):427–453.
36. Seehofer D, et al. Prevalence of thyroid nodules and carcinomas in patients operated on for renal hyperparathyroidism: experience with 339 consecutive patients and review of the literature. *World J Surg.* 2005;29(9):1180–1184.
37. Bogsrud TV, et al. The value of quantifying 18F-FDG uptake in thyroid nodules found incidentally on whole-body PET-CT. *Nucl Med Commun.* 2007;28(5): 373–381.

Endocrine Surgery

Principles and Practice

Hubbard, J.; Inabnet, W.B.; Lo, C.-Y. (Eds.)

2009, XX, 612 p. 215 illus., 116 illus. in color.,

Hardcover

ISBN: 978-1-84628-880-7