

# 2

## Disorders of the Pediatric Chest

Margaret A. Chase and Derek S. Wheeler

Introduction .....	13
Congenital Anomalies of the Tracheobronchial Tree.....	13
Congenital Anomalies of the Lung.....	14
Atelectasis .....	15
Pulmonary Edema .....	17
Diseases of the Pleural Space.....	19
Chest Tubes .....	22

### Introduction

The lungs are unique in that they are internal organs, yet they are constantly exposed to a barrage of foreign substances from both the internal environment—at any one point in time, they receive approximately half of the cardiac output—and the external environment—with each breath, they are exposed to pollens, viruses, bacteria, smoke, and so forth. There is a virtual cornucopia of diseases that affect the human respiratory tract, many of which are specific to the pediatric chest. According to the Centers for Disease Control and Prevention, chronic respiratory tract diseases and pneumonia were the seventh and eighth leading causes of deaths in children aged 1–19 years in 2002 [1]. Dr. George A. Gregory, one of the founding fathers of pediatric critical care medicine, once stated that acute respiratory failure accounts for approximately 50% of all admissions to the pediatric intensive care unit (PICU) [2]. Just as important are the myriad of respiratory disease processes that are not associated with acute respiratory failure but nevertheless constitute a major portion of the practice of pediatric critical care medicine, some of which result in significant morbidity and mortality [3]. In this chapter, we review some of these disease processes as a general introduction to the respiratory system in critical illness, and the remainder of these disorders are discussed in greater detail in subsequent chapters.

### Congenital Anomalies of the Tracheobronchial Tree

Congenital anomalies of the trachea (e.g., tracheomalacia, tracheal stenosis, tracheoesophageal fistula) are described in subsequent chapters in this textbook and are not discussed further here.

### Bronchomalacia

Bronchomalacia frequently coexists with tracheomalacia (some authors prefer the term *tracheobronchomalacia*) [4–8]. *Malacia* refers to an intrinsic defect of the cartilaginous support of the airway, causing the affected portion of the airway to collapse whenever the extraluminal pressure exceeds the intraluminal pressure (e.g., during forced exhalation, crying). Primary (congenital) and secondary (acquired) forms exist. Tracheobronchomalacia is frequently found in association with gastroesophageal reflux, cardiovascular anomalies (especially vascular rings, pulmonary slings, etc.), and tracheoesophageal fistula [5,7,8]. Affected children typically present with respiratory distress, wheezing, chronic cough, and recurrent pneumonia. Historically, tracheotomy and long-term mechanical ventilatory support have been the mainstays of treatment, although recent technologic improvements in noninvasive positive pressure ventilation will likely improve the outcome of children with this disease. Surgical treatment options include resection of affected segments, pexy procedures (aortopexy, bronchopexy, etc.), and stenting [9–13].

### Tracheal Bronchus

The *tracheal bronchus* (also commonly referred to as a *pig bronchus*) encompasses a variety of congenital bronchial anomalies, although an anomalous right upper lobe bronchus arising from the lateral wall of the trachea is most commonly described [14–16]. This anomaly occurs in 0.1%–5% of the population [17–19] and is frequently associated with other congenital anomalies, such as tracheoesophageal fistula, tracheal stenosis, and Down's syndrome [15,16,20–23]. Affected children are usually asymptomatic, although the diagnosis should be entertained for critically ill children with persistent or recurrent upper-lobe pneumonia, atelectasis, or air-trapping on chest radiograph [20]. Although most children can be managed conservatively, surgical resection of the involved lung segment may be necessary when symptoms are severe [14,16,20].

### Bronchial Atresia

Congenital bronchial atresia (CBA) is rare and most commonly affects the upper lobes of the lung. In most cases, the atresia affects either a proximal segmental or subsegmental bronchus. Development of the structures distal to the affected segment is unaffected,

however, and mucus often accumulates in the affected lung segments, leading to the formation of a bronchocele with surrounding areas of hyperinflation [24,25]. Although frequently detected as an incidental finding on chest radiograph, CBA occasionally results in recurrent infections of affected lung segments [24]. Lobectomy or segmentectomy of the affected areas is curative but only occasionally necessary [26,27].

### Bronchogenic Cysts

Bronchogenic cysts arise from abnormal budding of tracheobronchial tissue during embryogenesis. The respiratory system develops as an outpouching of the embryonic foregut. Therefore, histologically, bronchogenic cysts are lined with ciliated epithelium and frequently contain cartilage, smooth muscle, mucous glands, nerve tissue, and occasionally gastric epithelium. They may be air filled, mucus filled, or both [16,28]. These cysts are single, unilocular, and spherical in shape and are usually classified by their location in the thorax (central or mediastinal bronchogenic cysts and peripheral or pulmonary bronchogenic cysts) [16,28]. Most bronchogenic cysts are asymptomatic and are detected as an incidental finding on chest radiograph [16,28]. However, respiratory distress may be precipitated by enlargement of the cyst with subsequent airway compromise. Additional complications include rupture of the cyst into a bronchus or the pleura with hemorrhage, recurrent infections, and abscess formation. Surgery is indicated when these cysts are symptomatic, and most authors advocate surgical resection upon diagnosis because of the risk of associated complications [16,28–30].

## Congenital Anomalies of the Lung

### Congenital Lobar Emphysema

Congenital lobar emphysema (CLE) is characterized by massive distension of one or more affected lobes of the lung, most commonly the left upper lobe [16,28,30–33]. Congenital lobar emphysema is the most common congenital lung anomaly and is thought to arise from a ball-valve type of bronchial obstruction resulting in progressive air trapping and hyperinflation [16,28,33]. This bronchial obstruction is idiopathic in most cases, although extrinsic vascular compression and bronchomalacia have occasionally been implicated [34–38]. Congenital heart disease is present in 10% of affected infants [28]. Congenital lobar emphysema appears to be more common in males than in females and typically presents before 6 months of age. Respiratory distress is the most common clinical presentation [16,28,33,37,38]. Chest radiography will demonstrate hyperinflation of affected lobes, and CLE is frequently confused with pneumothorax [39]. Surgical resection of the affected lobe is curative [16,28–33,39].

### Congenital Cystic Adenomatoid Malformation

Congenital cystic adenomatoid malformations (CCAM) are the second most common congenital lung anomalies and represent maldevelopment of the terminal bronchiolar structures during early lung embryogenesis. Congenital cystic adenomatoid malformation consists of a multicystic, dysplastic mass of pulmonary tissue and typically presents either prenatally on routine ultrasound or during the neonatal period with severe respiratory dis-

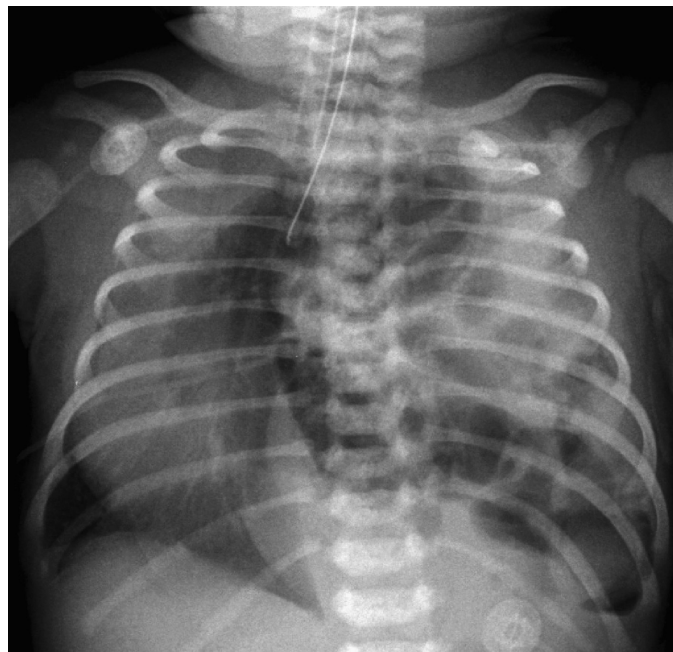
tress. Management depends on the extent of disease, and prognosis is variable [16,26,28–31,33,36,40]. Malignant transformation of CCAM (high incidence of rhabdomyosarcoma) has been described such that surgical resection is probably indicated even when the lesion is asymptomatic [41–44].

### Congenital Diaphragmatic Hernia

Congenital diaphragmatic hernia results from a defect in the diaphragm that allows evisceration of abdominal contents into the thorax (the left hemithorax in the vast majority of cases) (Figure 2.1). Congenital diaphragmatic hernia is frequently detected on prenatal ultrasound, and severely affected fetuses often die before birth. More than 50% of cases have additional congenital anomalies (i.e., cardiac, genitourinary, and chromosomal anomalies). Although the majority of cases present with severe respiratory compromise immediately after birth, late presentation beyond the immediate neonatal period occasionally occurs and is typically milder [16,28,45,46]. Definitive surgery includes decompression of the lungs by reduction of the abdominal viscera and primary closure of the diaphragmatic defect. The majority of affected children will have some degree of pulmonary hypoplasia as well as pulmonary artery hypertension resulting from increased muscularization of the intraacinar pulmonary arteries, a small cross-sectional area of the pulmonary vascular bed, and abnormal pulmonary vasoconstriction, all of which will impact long-term outcome [16,28,47,48].

### Pulmonary Sequestration

Pulmonary sequestration is defined as a lung segment that receives its blood supply from an anomalous systemic artery and does not communicate with the tracheobronchial tree [16,26,28,29,31,33,



**FIGURE 2.1.** Congenital diaphragmatic hernia in a term male newborn admitted to the neonatal intensive care unit with respiratory failure. (Courtesy of Corning Benton, MD, Cincinnati Children's Hospital Medical Center.)

49–51]. Traditionally, sequestrations are divided into *extralobar*, in which the abnormal lung segment lies within its own pleura and is located more posteriorly in the chest, and *intralobar*, in which the abnormal lung segment lies within the pleural cavity in close contact with the normal lung. Venous drainage of intralobar sequestrations is usually via the pulmonary veins, whereas extralobar sequestrations drain to the systemic venous circulation via the azygos vein, hemiazygos vein, or vena cava. The vast majority of sequestrations affect the lower lobes, usually on the left. Intralobar sequestrations are frequently acquired anomalies that arise from recurrent infections or bronchial obstruction. Extralobar sequestrations, on the other hand, are congenital and usually diagnosed at an earlier age because of a higher incidence of associated anomalies. There is a 4:1 male:female preponderance for extralobar sequestrations, whereas intralobar sequestrations affect both equally. Infants present with recurrent lower respiratory infections, reactive airway disease, and, occasionally, hemoptysis. Treatment of pulmonary sequestration is resection; extralobar tissue can be treated with resection alone, and intralobar lesions will usually require lobectomy [16,26,28,29,31,33,49–51].

### Scimitar Syndrome

The scimitar syndrome, also called *congenital venolobar syndrome*, is a rare congenital anomaly classically described by (1) partial or complete anomalous pulmonary venous drainage of the right lung to the inferior vena cava, (2) hypoplasia of the right lung, (3) hypoplasia of the right pulmonary artery, (4) dextrocardia, and (5) anomalous systemic arterial supply of the right lower lobe of the lung from the subdiaphragmatic descending aorta or its branches [16,52–55]. The majority of children are symptomatic; however, clinical presentation depends to a great extent on significance of the resulting left-to-right shunt. Two forms are commonly described [56–59]. The infantile form is usually associated with a variety of congenital anomalies, including additional congenital heart defects such as coarctation of the aorta, tetralogy of Fallot, and ventricular septal defect. Affected children are prone to recurrent pneumonia, congestive heart failure, and pulmonary hypertension [57–59]. The adult form is characterized by a small left-to-right shunt with minor symptoms and lack of associated anomalies [56,59]. Surgical management of the scimitar syndrome is often dependent on the clinical presentation and is therefore age dependent [59–61]. Indications for surgery include (1) the presence of a large left-to-right shunt with consequent pulmonary hypertension and heart failure and (2) recurrent pneumonia caused by pulmonary sequestration [61]. Surgical management includes ligation of the anomalous systemic artery, reimplantation of the scimitar vein to the left atrium, and resection of the sequestration [59–62]. Postoperative pulmonary venous obstruction or pulmonary hypertension is frequent and greatly impacts outcome.

### Pulmonary Agenesis, Aplasia, and Hypoplasia

Pulmonary underdevelopment is commonly classified into three groups: (1) pulmonary agenesis (complete absence of bronchus and lung), (2) pulmonary aplasia (rudimentary bronchus ends blindly without lung tissue), and (3) pulmonary hypoplasia (incomplete development of the bronchus with variable reduction in lung tissue) [16,26,28,47,48,63–69]. Associated congenital anomalies are frequently present [63,64,66,68]. Compensatory hyperinflation of the contralateral lung with herniation across the midline is typically

noted on chest radiograph. Additional findings include mediastinal shift toward the affected hemithorax, which is usually accentuated during inspiration. Management is largely supportive, as there are currently no acceptable long-term surgical options for management of these children [16,26,28,47,48]. Expandable prosthetic devices (including saline-filled prostheses, ping pong ball plom-bage, etc.) used for the postpneumectomy syndrome (dyspnea and respiratory distress occurring secondary to mediastinal shift into the empty hemithorax) [70–72] have been attempted recently with some success [73].

### Atelectasis

The term *atelectasis* is derived from the Greek words *ateles* and *ektasis*, which literally mean *incomplete expansion*. Atelectasis is associated with a variety of respiratory diseases and may be identified in as many as 15% of children admitted to the PICU [74–77]. Atelectasis occurs by three mechanisms: (1) compression of lung parenchyma by intrathoracic, chest wall, or extrathoracic disease processes (*compression atelectasis*); (2) obstruction of airways with subsequent gas resorption (*resorption atelectasis*); and (3) increased surface tension in small airways and alveoli (Table 2.1) [78–80]. *Compression atelectasis* occurs when the distending pressure (i.e., transmural pressure) that keeps an alveolus open is reduced below a certain threshold, allowing the alveolus to collapse. The dependent lung regions are the areas most commonly affected by this type of atelectasis.

*Resorption atelectasis* occurs via one of two possible mechanisms. In the first, complete airway obstruction creates a pocket of trapped gas in the alveoli distal to the obstruction. As the affected lung region is perfused, but not ventilated, gas is absorbed and the alveoli eventually collapse. The second mechanism is a conse-

**TABLE 2.1.** Causes of atelectasis in infants and children.

Compression atelectasis
Extrinsic bronchial compression
Tumors
Lymph nodes
Cardiomegaly (e.g., congenital heart disease, congestive heart failure)
Vascular rings
Congenital lobar emphysema
Compression of lung parenchyma
Chylothorax
Hemothorax
Pneumothorax
Tumors
Resorption atelectasis
Intrabronchial obstruction
Obstructive airways disease (e.g., asthma, cystic fibrosis, bronchiolitis)
Foreign body
Inspissated secretions and/or mucous plugs
Cystic fibrosis
Sickle cell disease and acute chest syndrome
Administration of High FiO <sub>2</sub> in the setting of low V <sub>A</sub> /Q
Surfactant deficiency or dysfunction
Infant respiratory distress syndrome (hyaline membrane disease)
Acute respiratory distress syndrome
Pneumonia
Pulmonary edema
Near-drowning

quence of oxygen being more readily absorbed than nitrogen. As a result, the rate of absorption of the gas increases with the fractional concentration of oxygen in the alveoli. Administration of either supplemental oxygen or mechanical ventilation with high fractional inspired oxygen ( $\text{FiO}_2$ ) can result in resorption atelectasis, especially in lung zones with low ventilation to perfusion ( $V_A/Q$ ) ratios. Finally, loss or dysfunction of surfactant results in increased surface tension in small airways and alveoli, leading to lung collapse. All three mechanisms likely contribute to atelectasis in acute lung injury and its more severe form, the acute respiratory distress syndrome [78–80].

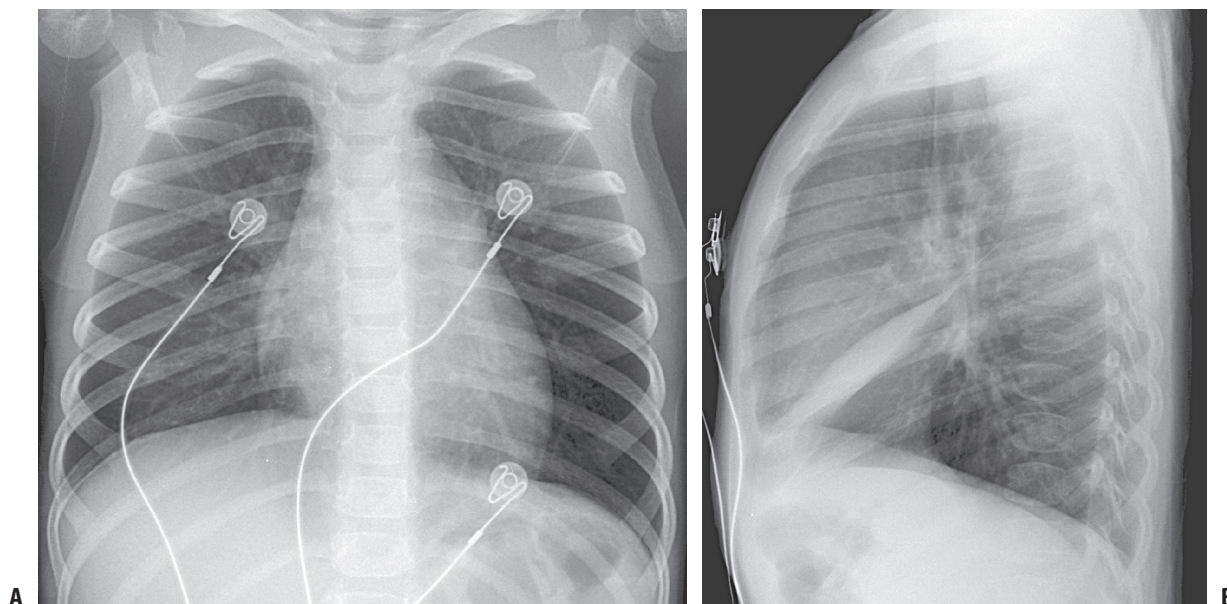
Young children are particularly susceptible to atelectasis compared with older children and adults [74,75,77,78,80]. As previously discussed, the child's airways are smaller than the adult's and have a higher peripheral airways resistance [81,82]. The child's airways are therefore more susceptible to obstruction by inspissated secretions or mucus. In addition, children are more susceptible to dynamic airway compression because of weak cartilaginous support [83,84]. Finally, the collateral pathways of ventilation (pores of Kohn and Lambert's canals) are less well developed in children than adults [78,80,83–86] such that airway obstruction leads to air trapping and subsequent collapse via *resorption atelectasis*. Children also appear to differ from adults with respect to the distribution of atelectasis as well. The upper lobes, especially the right upper lobe, appear to be more commonly affected in critically ill children admitted to the PICU [74–77]. Collapse of the lower lobes, especially the left lower lobe, appears to be more common in critically ill adults.

Atelectasis compromises pulmonary function by affecting both mechanical properties of the lung as well as gas exchange. According to the Laplace relationship, smaller alveoli (e.g., collapsed or atelectatic areas of lung) require a greater opening pressure to reinflate and reexpand. As the lung now requires higher pressures to inflate, atelectasis causes a significant reduction in lung compli-

ance. Atelectasis also leads to ventilation–perfusion mismatch, leading to gas exchange abnormalities and hypoxemia. Atelectasis may also result in a compensatory overdistention of adjacent alveoli, especially in the setting of airways obstruction and obstructive atelectasis [78,80,86]. Additional consequences of atelectasis can include bronchiectasis, pneumonia, and lung abscess, which result from retained, infected secretions within the collapsed lung and not atelectasis per se.

A chest radiograph is often required to document the presence, extent, and distribution of atelectasis (Figure 2.2). Opacification may represent areas of either collapse or consolidation. However, loss of lung volume with movement of the diaphragm, mediastinum, and major fissures toward the affected areas are highly suggestive of collapse (discussed later in the chapter on respiratory monitoring).

The management of atelectasis is tailored to the etiology as well as the prevention of subsequent complications (e.g., inspissated secretions and worsening airways obstruction, hypoxemia, infection). Several new modalities to facilitate reexpansion of atelectatic alveoli in the PICU are available, although few randomized, controlled clinical trials exist to support the merits of one modality over another [78,80,86,87]. Vigorous coughing, the use of incentive spirometry, and chest physiotherapy are frequently employed [88–91]. In recalcitrant cases, or those associated with neuromuscular disease or cystic fibrosis (CF), assisting devices such as intermittent positive pressure breathing [90,91], cough-assist insufflation/exsufflation therapy [92,93], or noninvasive bilevel positive pressure ventilation (BiPAP) [92–97] may be helpful. The use of recombinant DNase (rhDNase), which is approved for use in CF patients, has also been employed in persistent atelectasis, especially in those cases that are caused by resorption atelectasis secondary to obstruction by inspissated secretions. DNase is thought to improve atelectasis by decreasing the viscosity of secretions and assisting mucociliary clearance, thereby relieving airways obstruction [98–



**FIGURE 2.2.** Right middle lobe atelectasis in a 3-year-old child admitted to the pediatric intensive care unit with status asthmaticus. (A) Anteroposterior view. (B) Lateral view. (Courtesy of Corning Benton, MD, Cincinnati Children's Hospital Medical Center.)

107]. Finally, for those patients requiring ventilator support, atelectasis can necessitate a prolonged course on the ventilator and thus has increased risks of associated complications. For these patients, the use of positive end-expiratory pressure, often in increased levels, as well as increased inspiratory times may be necessary. If atelectasis is not resolved with these interventions, flexible bronchoscopy may be helpful for diagnosis as well as removal of inspissated secretions and reexpansion of collapsed alveoli [108–111].

## Pulmonary Edema

### Pathophysiology

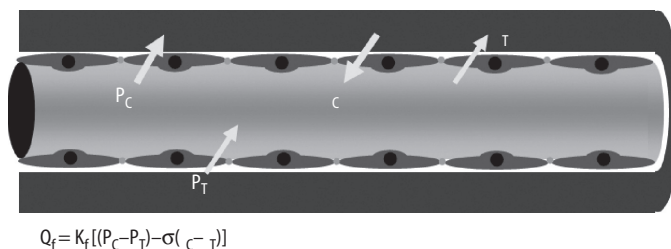
Pulmonary edema is defined simply as an abnormal accumulation of fluid in the lung. The net flow of fluid across the alveolar-capillary membrane is generally expressed using the Starling equation, as follows:

$$Q_f = K_f [(P_C - P_T) - \sigma (\pi_C - \pi_T)]$$

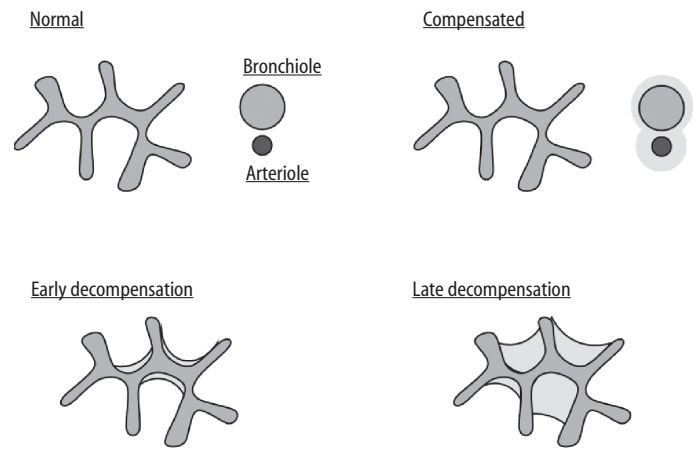
where  $Q_f$  is equal to the net flow across the alveolar-capillary membrane;  $K_f$  is the filtration coefficient, which takes into account the contribution of the permeability and surface area of the alveolar-capillary membrane;  $P_C$  is equal to the capillary hydrostatic pressure;  $P_T$  is equal to the interstitial fluid hydrostatic pressure;  $\sigma$  is the reflection coefficient of the alveolar-capillary membrane ( $\sigma = 1$  if the membrane is completely impermeable to protein, and  $\sigma = 0$  if the membrane is completely permeable to protein);  $\pi_C$  is the capillary oncotic pressure; and  $\pi_T$  is the interstitial oncotic pressure.

Under normal physiologic conditions,  $P_C$  is gravity dependent and ranges from 8 to 12 mm Hg, whereas  $P_T$  is estimated at  $-2$  to  $-10$  mm Hg. The balance of hydrostatic pressures therefore overwhelmingly favors net fluid movement *out* of the pulmonary capillary. Normally,  $\pi_C$  approximates 25 mm Hg, and  $\pi_T$  ranges between 10 and 15 mm Hg. Given that  $\sigma$  is between 0.7 and 0.95, the balance of oncotic pressures tends to favor a relatively small amount of net fluid movement into the pulmonary capillary. Therefore, under normal conditions, the balance of Starling forces across the alveolar-capillary membrane favors a net flow of fluid out from the microvascular space into the interstitium (Figure 2.3) [reviewed in 112–116].

Several factors protect against the development of pulmonary edema. If the alveolar-capillary membrane is able to retard the movement of proteins (i.e.,  $\sigma$  remains unchanged), the increased



**FIGURE 2.3.** Starling forces across the pulmonary capillary endothelium.  $Q_f$  is net flow across the alveolar-capillary membrane;  $K_f$  is filtration coefficient;  $P_C$  is capillary hydrostatic pressure;  $P_T$  is interstitial fluid hydrostatic pressure;  $\sigma$  is reflection coefficient of the alveolar-capillary membrane ( $\sigma = 1$  if the membrane is completely impermeable to protein, and  $\sigma = 0$  if the membrane is completely permeable to protein);  $\pi_C$  is capillary oncotic pressure; and  $\pi_T$  is interstitial oncotic pressure.



**FIGURE 2.4.** Pattern of alveolar fluid accumulation. (Adapted from Staub et al. [117].)

fluid that enters the interstitium will lower the interstitial osmotic pressure and thereby oppose interstitial fluid accumulation. In addition, the increased interstitial hydrostatic pressure that results from this fluid accumulation will abolish the normal hydrostatic pressure gradient and further oppose fluid movement into the interstitium. Finally, the lymphatics have a tremendous capacity to clear any fluid that accumulates within the lung interstitium. Once these defensive mechanisms are overcome, fluid begins to accumulate in a relatively predictable manner [117]. Fluid first accumulates in the loose interstitial tissue surrounding small blood vessels and airways. Alveolar fluid next accumulates in the corners of the alveolus, and, if edema persists, fluid eventually completely fills the alveolus (Figure 2.4).

The last decade has witnessed a dramatic increase in our understanding of the normal fluid clearance mechanisms of the lung. Importantly, the lung's ability to clear pulmonary edema (regardless of mechanism) correlates with improved survival in critical illnesses such as sepsis, acute lung injury, and congestive heart failure [118–120]. Under normal conditions, alveolar fluid clearance is dependent on the active transport of  $\text{Na}^+$  and  $\text{Cl}^-$  (with water following) across the lung epithelium, a process that depends on  $\text{Na}^+/\text{K}^+$  ATPase, intercellular tight junctions, and  $\text{Na}^+$  ion channels [reviewed in 115,116,121,122]. Recent evidence suggests that alveolar lung clearance is partly regulated by endogenous  $\beta$ -adrenergic receptors, leading some investigators to suggest that aerosolized  $\beta$ -adrenergic agonists may be helpful in patients with acute lung injury and acute respiratory distress syndrome [120,122–126].

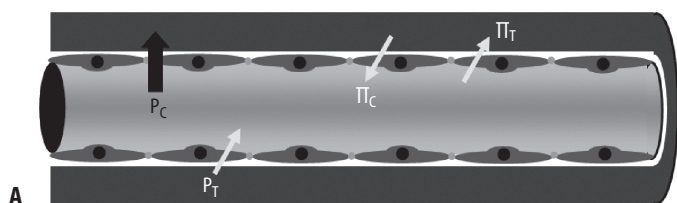
### Etiology

Factors that increase the pulmonary capillary pressure, such as left ventricular failure or valvular regurgitation, serve to increase the driving force through the capillary wall into the interstitium and lead to fluid accumulation. This aspect of fluid accumulation, however, is not limited to cardiogenic causes and can also be seen in pulmonary veno-occlusive disease and other processes impairing pulmonary venous drainage (Figure 2.5A). Plasma oncotic pressure, often reflected in the child's serum albumin level, can also play a role in the accumulation of pulmonary edema (Figure 2.5B). In illnesses such as protein losing enteropathy or nephrotic syndrome, with increased protein losses, or those with decreased



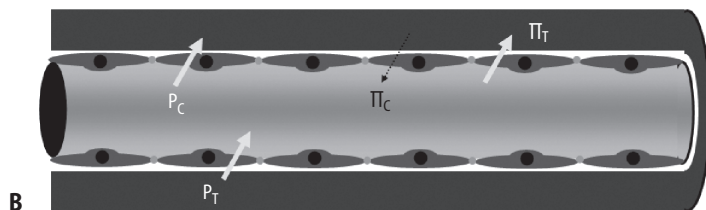
Three forms of pulmonary edema:

1.  $\uparrow P_{MV}$  (cardiogenic pulmonary edema)



Three forms of pulmonary edema:

2.  $\downarrow \pi_c$  (osmotic pulmonary edema)



Three forms of pulmonary edema:

3.  $\downarrow \sigma$  (capillary leak pulmonary edema)

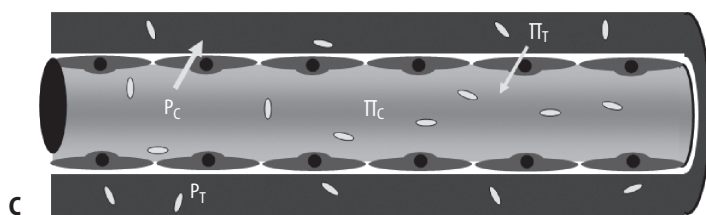


FIGURE 2.5. Mechanisms of pulmonary edema. (A)  $\uparrow P_c$ . (B)  $\downarrow \pi_c$ . (C)  $\downarrow \sigma$ .

protein production, such as hepatic disease or malnutrition, the forces promoting return of fluid into the vascular space are decreased. These children develop systemic extravascular fluid overload, of which pulmonary edema can be the most clinically significant. In general, alteration of capillary membrane permeability is seen as a result of insult to the membrane itself (Figure 2.5C). In the PICU population, this is frequently a consequence of infection (either pulmonary or systemic) or acute respiratory distress syndrome. *Leaky* capillaries can also be attributed to circulating toxins such as chemotherapy or even endogenous mediators of the immune system such as leukotrienes, tumor necrosis factor- $\alpha$ , or histamine. Similarly, direct toxins, such as smoke, chemical irritants, or even water in near-drowning can injure the endothelium and alter permeability, predisposing to pulmonary edema.

An additional but poorly understood mechanism of pulmonary edema is that resulting from increased negative interstitial pressure or *postobstructive pulmonary edema*. It is most often seen in those disorders associated with upper airway obstruction such as croup, foreign body aspiration, severe acute asthma, or laryngospasm after the obstruction is relieved. High negative intrathoracic pressure causes increases in cardiac preload, afterload, and pulmonary blood flow, which in turn increase the microvascular pressure driving fluid into the interstitium. This may be an additional etiology of edema in those children experiencing smoke inhalation or near-drowning.

*Neurogenic pulmonary edema* is similarly not fully understood but may be associated with a massive sympathetic discharge. This release in catecholamines and the subsequent increase in sympathetic tone that follows may increase pulmonary and systemic vasoconstriction, shifting blood to the pulmonary vasculature, increasing capillary pressure, and leading to edema formation. There may also be a component of increased capillary permeability from stress failure or hypoxia-related injury of the capillary endothelium contributing to pulmonary edema formation.

## Clinical Consequences

The presence of fluid in the interstitial and alveolar spaces serves to decrease lung compliance and increase atelectasis. Most commonly, children with pulmonary edema develop some component of respiratory distress. This may be seen through increased work of breathing in an attempt to maintain minute ventilation or desaturations as V/Q mismatch progresses or to increase ventilator requirements in those already with respiratory failure. Physical examination of the lung fields may reveal wheezing and fine crackles. Chest radiograph serves as the main diagnostic tool (Figure 2.6). Early in the process, peribronchial and perivascular cuffing may be observed, resulting from interstitial edema. Lung fields demonstrating increased pulmonary vascular markings and cardiomegaly may be seen with edema arising from left ventricular dysfunction. Progressively, as edema begins to fill the alveolar spaces, diffuse patchy densities may be appreciated.

## Management

Primary management of pulmonary edema should be directed at correcting the underlying disturbance that led to pulmonary edema. Often this is easier said than done, and supportive care of the patient focusing on respiratory stabilization and decreasing pulmonary edema is pursued. Removal of excessive interstitial and alveolar fluid can be attempted with diuretics [127]. However, diuretics such as furosemide probably work because of their effects on venous capacitance and not via the induced diuresis [112–116].

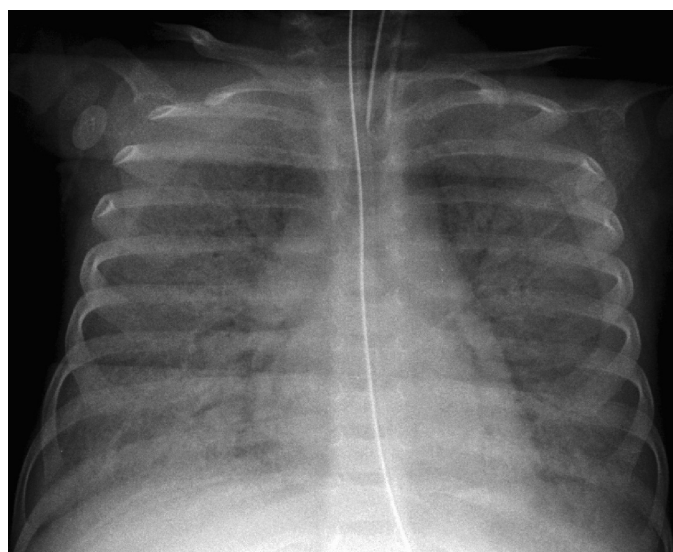


FIGURE 2.6. Pulmonary edema in an 11-month-old child with congestive heart failure. (Courtesy of Corning Benton, MD, Cincinnati Children's Hospital Medical Center.)

Supportive care with noninvasive ventilation is often helpful, as it decreases the work of breathing and provides a constant level of positive end-expiratory pressure, stenting open alveoli and forcing out excess fluid—although efforts to minimize further ventilator-induced lung injury are crucial as well. For those patients on the ventilator or with severe distress requiring ventilation, increased levels of positive end-expiratory should be employed for the same reasons. Additionally, dependent areas of the lung are at increased risk of developing pulmonary edema, and therefore frequent changes in patient position or even prone ventilation may help to mobilize fluid, resolve associated atelectasis, and redistribute areas of V/Q mismatch. For those patients with hypoalbuminemia and pulmonary edema, there may be some benefit of albumin supplementation in decreasing edema fluid [127]. Finally, as discussed earlier, aerosolized  $\beta$ -adrenergic agonists may help augment alveolar fluid clearance and relieve pulmonary edema [120,122–126].

## Diseases of the Pleural Space

### Pleural Effusions

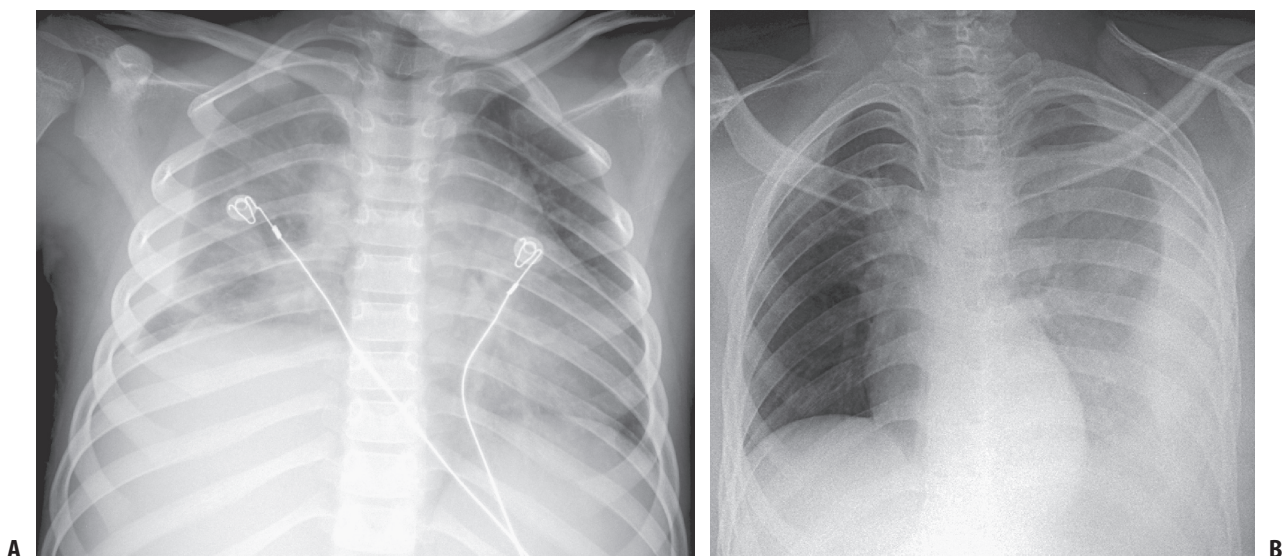
The pleural membrane is a thin, double-layered membrane that separates the lung from the chest wall, diaphragm, and mediastinum. The outer layer, called the *parietal pleura*, covers the inner surface of the chest wall, including the mediastinum, diaphragm, and ribs. The inner layer, called the *visceral pleura*, covers the entire surface of the lungs, including the interlobar fissures, except for the hilus, where the pulmonary blood vessels, bronchi, and nerves enter the lung tissue. The mediastinum completely separates the right and left pleural spaces. Under normal conditions, the two pleurae are separated by a thin space (pleural space) that contains a small amount of serous fluid. This fluid provides a frictionless surface between the two pleurae in response to changes in lung volume with respiration. Essentially an ultrafiltrate of plasma, normal pleural fluid is clear in appearance, with a pH of 7.60–7.64,

a protein content less than 2% (1–2 g/dL), fewer than 1,000 WBCs per cubic millimeter, a glucose content similar to that of plasma, and a lactate dehydrogenase level less than 50% of plasma [128,129].

A pleural effusion (Figure 2.7) is broadly defined as an abnormal collection of fluid in the space between the parietal and visceral pleurae and may arise from a variety of processes that alter the normal flow and absorption of pleural fluid. These can include changes in the permeability of the pleural membrane (e.g., pneumonia, malignancy), reduction in intravascular oncotic pressure (e.g., hypoalbuminemia), increased capillary hydrostatic pressure (e.g., congestive heart failure, SVC syndrome), or decreased lymph drainage or lymphatic obstruction (e.g., thoracic duct trauma) [128,129]. The most common causes of pleural effusions in children are pneumonia (parapneumonic effusion), congenital heart disease, and malignancy [128,129]. A diagnostic or therapeutic thoracentesis is usually indicated to determine the nature of the effusion as well as to relieve associated dyspnea and respiratory compromise.

When performing a thoracentesis, the child is seated, leaning over a table or supine if that is not possible. The preferred entry is at the seventh intercostal space along the posterior axillary line. This area is cleaned and draped in sterile fashion and local anesthesia provided to the subcutaneous tissue, rib periosteum, and pleura with 1% lidocaine. An 18–22 gauge intravenous catheter over a needle or large-bore needle is attached to a syringe and advanced with steady negative pressure through the skin, onto the rib, and guided over the superior aspect of the rib, taking care to avoid the neurovascular bundle running beneath. Advancement of the needle is halted once fluid is obtained, and, if an intravenous or pigtail catheter with guidewire is used, the catheter may be advanced into the pleural space. Fluid is removed, and, once drainage is complete, the needle or catheter is removed and an occlusive dressing placed over the site. A chest radiograph should be obtained after the procedure to rule out pneumothorax.

Depending on analysis of the fluid obtained, pleural effusions may be classified into either transudates or exudates. In transuda-



**FIGURE 2.7.** (A) Pleural effusion in a 9-year-old child with pneumonia (i.e., parapneumonic effusion). (B) Pleural effusion in a 19-year-old adolescent. (Courtesy of Corning Benton, MD, Cincinnati Children's Hospital Medical Center.)

**TABLE 2.2.** Evaluation of a pleural effusion: transudate versus exudates.

	Transudate	Exudate
pH	>7.4	<7.3
Protein (g/dL)	<3.0	>3.0
Lactate dehydrogenase (LDH)	<2/3 serum level	>2/3 serum level
Pleural fluid: serum protein	<0.5	>0.5
Pleural fluid: serum LDH	<0.6	>0.6
Red blood cell	<5,000	>5,000
White blood cell	<1,000	>1,000
Glucose	Equal to serum	Less than serum

tive effusions, the pleural membranes are intact and pleural permeability is normal. There is instead an imbalance of Starling forces along the pleural membrane from increased capillary hydrostatic pressure, decreased colloid oncotic pressure, or both. Examples of transudative effusions are those associated with congestive heart failure, cirrhosis, and nephrotic syndrome. Alternately, in exudative effusions, there is a disruption in the permeability of the pleural membrane, occasionally with coexisting lymphatic obstruction. This leads to a more viscous and tenacious fluid collection such as that associated with infection, malignancy, collagen vascular disease, or trauma. Transudative and exudative effusions are compared in Table 2.2. Distinguishing between transudative and exudative effusions can be helpful from a diagnostic standpoint and may also impact management of the effusion, as exudative fluid collections often need chest tube drainage, whereas transudates can often be managed without further invasive procedures.

### Parapneumonic Effusions and Empyema

Nearly one-half of all children with pneumonia will develop a parapneumonic effusion, although less than 5% of these effusions progress to empyema (see Chapter 17 for additional discussion). An otherwise uncomplicated parapneumonic effusion does not usually warrant immediate drainage. However, if the effusion persists despite antibiotic therapy, or certainly if the effusion is associated with respiratory compromise, drainage via tube thoracostomy is generally indicated.

Historically, the microorganisms most commonly isolated from parapneumonic effusions and empyemas during childhood have been *Staphylococcus aureus*, *Streptococcus pneumoniae*, *Streptococcus pyogenes*, and *Haemophilus influenzae*. Multiple modalities exist for the treatment of empyema, including thoracentesis, chest tube drainage, instillation of fibrinolytic therapy into the pleural cavity, video-assisted thoracic surgery (VATS), and open thoracotomy with decortication. Prospective studies evaluating the use of fibrinolytic therapy in the management of parapneumonic effusion in children suggest that treatment with fibrinolytic therapy increases pleural drainage and decreases the need for surgical intervention (via thoracotomy) [129–132], although a recent Cochrane Database review suggested that VATS may be superior to even fibrinolytic therapy [133]. If surgery is required, the less invasive nature of VATS coupled with excellent published results have led many experts to recommend this approach over thoracentesis, chest tube drainage, and open thoracotomy [128,133].

### Bronchopleural Fistula

A potential complication of empyema and lung abscess is the development of an abnormal connection between the airway and pleural

cavity, called a *bronchopleural fistula* (BPF). A BPF may result from the rupture of a lung abscess, cyst, or bulla or from injury to the bronchus or lung parenchyma from trauma or mechanical ventilation. Additional sources include erosion of the bronchus by carcinoma or chronic inflammation as well as the breakdown of suture lines after pulmonary resection (more common in adults). The presence of a BPF is typically heralded by the return or increase in the air leak of the chest tube system or, in the absence of a chest tube, the occurrence of a pneumothorax. Diagnosis may be confirmed by bronchoscopy, but occasionally additional radiologic or contrast studies are used. Bronchopleural fistulae are difficult to manage and are associated with a poor prognosis. Typically, patients are treated aggressively with antibiotics and continued drainage, but often surgical closure is required.

### Chylothorax

A chylothorax is defined as the accumulation of chyle within the pleural space, usually occurring because of injury to the thoracic duct or a derangement of lymphatic flow within the thorax. Chylothorax is the most common type of neonatal pleural effusion, often resulting from birth trauma, congenital malformations, or increased venous pressure from thrombosis of central venous catheters. Chyle is classically described as a white, milky, opaque fluid, although this appearance is seen in less than half of all patients with a chylothorax. In children, chylothorax is commonly iatrogenic, following surgical correction or palliation of congenital heart disease. Treatment includes drainage (via tube thoracostomy) and the institution of a low-fat (or medium-chain triglyceride)/high-protein diet. There are reports of successful treatment of chylothorax with the somatostatin analog octreotide; however, no controlled trials exist to document benefit [134–141]. For refractory cases, surgical ligation of the thoracic duct is indicated [142].

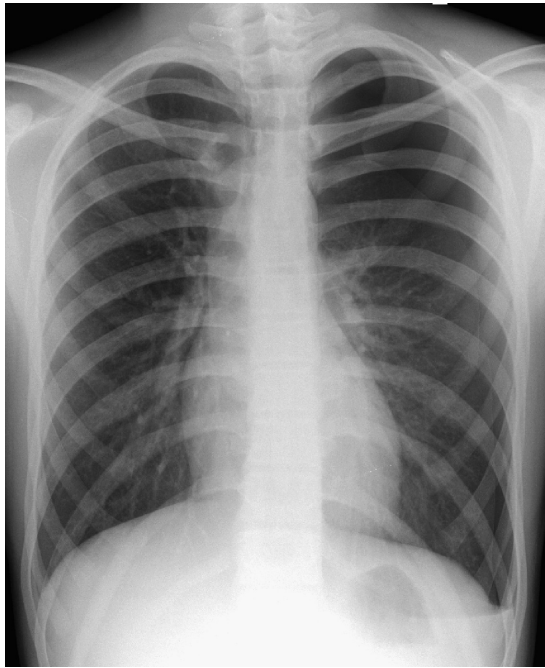
### Hemothorax

The presence of blood in the pleural space with a hematocrit equal to 50% of that of peripheral blood constitutes a hemothorax. Extensive bleeding into the pleural cavity is rare in children but may be seen after trauma or as a complication of surgery. Chest tube placement and surgical intervention to control active bleeding are required.

### Pneumothorax

A pneumothorax is defined as an accumulation of air in the pleural space. By convention, a small pneumothorax occupies 15% or less of the pleural space, a moderate pneumothorax occupies 15%–60% of the pleural space, and a large pneumothorax occupies more than 60% of the pleural space. Pneumothoraces are commonly classified into three types (*simple*, *communicating*, and *tension*). A simple (also called *closed* or *noncommunicating*) pneumothorax exists when there is no direct communication with the atmosphere. Additionally, there is no mediastinal shift resulting from the accumulated air (Figure 2.8). A simple pneumothorax is a common complication of nonpenetrating trauma to the chest in which one or more fractured ribs lacerates or punctures the visceral pleura and lung parenchyma, causing an escape of air from the lung into the pleural space. A pneumothorax in this setting may also occur in the absence of rib fracture when the impact is delivered at a full inspiration with the glottis closed, leading to a drastic increase in





**FIGURE 2.8.** Simple pneumothorax in a 15-year-old male (spontaneous pneumothorax). (Courtesy of Corning Benton, MD, Cincinnati Children's Hospital Medical Center.)

intraalveolar pressure and subsequent rupture of the alveoli. Finally, a simple pneumothorax may occur as a consequence of barotrauma or volutrauma during positive pressure mechanical ventilatory support.

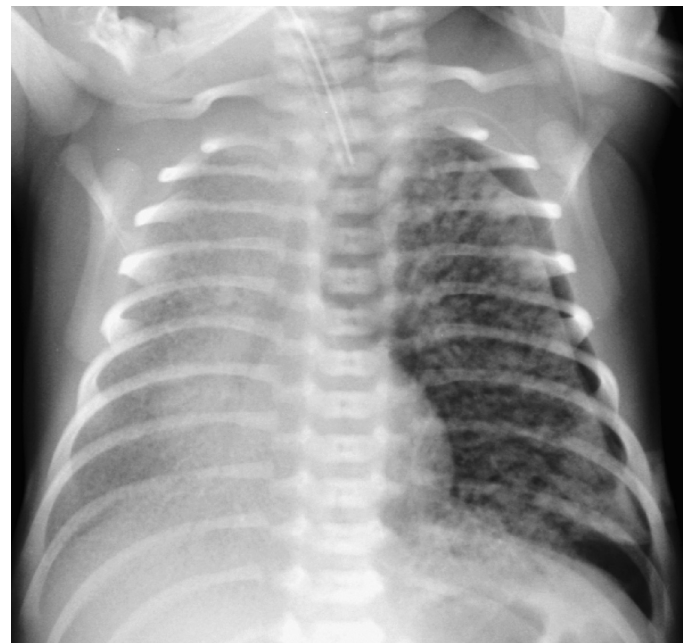
A communicating or open pneumothorax is associated with an open defect in the chest wall, most commonly occurring as a complication of penetrating chest trauma. As intrathoracic pressure is always less than atmospheric pressure (i.e., negative intrathoracic pressure) during spontaneous breathing, air rapidly accumulates in the pleural space. Loss of negative intrathoracic pressure results in varying degrees of lung collapse and further respiratory compromise.

A tension pneumothorax is caused by progressive accumulation of air in the pleural space (Figure 2.9). This collection of air shifts the mediastinum to the contralateral hemithorax and compresses the contralateral lung and great vessels, compromising both cardiovascular and respiratory function. Whether the air enters the pleural space through a defect in the chest wall, a lacerated or ruptured bronchus, or a ruptured alveolus, a one-way valve effect is created such that air enters during inhalation but cannot exit during exhalation. Accumulation of air continues until the intrathoracic pressure of the affected hemithorax equilibrates with atmospheric pressure. At this point, the accumulation of pressure within the thorax leads to depression of the ipsilateral hemidiaphragm and displacement of the mediastinum (and associated great vessels) toward the contralateral hemithorax. While the superior vena cava (SVC) is able to move to some extent, the inferior vena cava (IVC) is relatively fixed within the diaphragm and will be compressed (*kinked*). As two-thirds of the venous return in children comes from below the diaphragm, compression of the IVC leads to a drastic and profound reduction in venous return to the heart, leading to cardiovascular collapse (obstructive shock) [143].

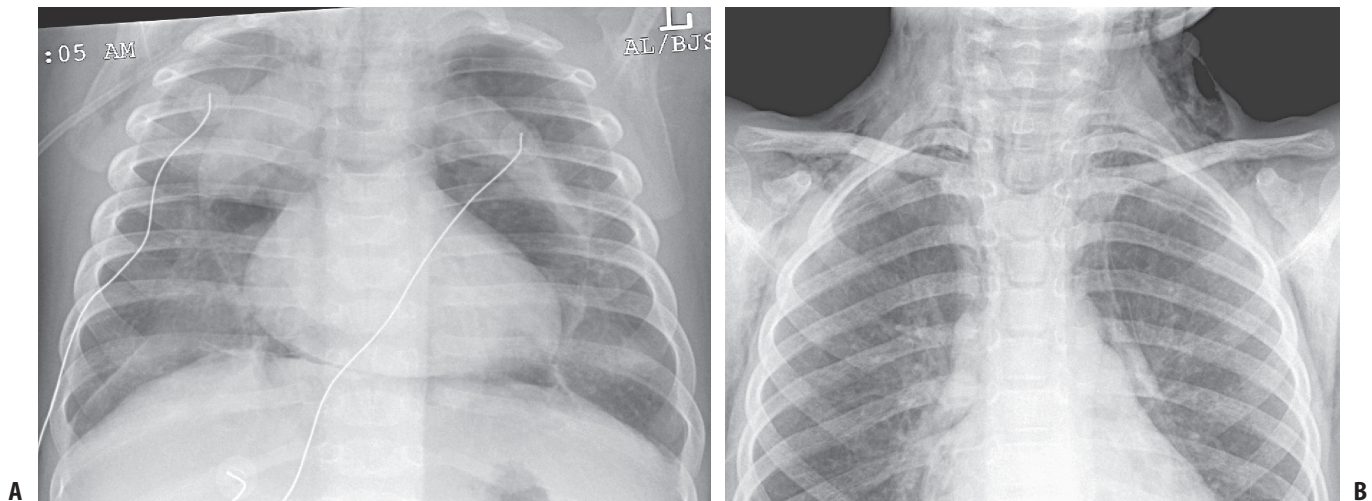
The clinical presentation of a pneumothorax will depend on its size, how rapidly it has accumulated, and whether or not it is under tension. Classic signs and symptoms include chest pain (often radiating to the tip of the ipsilateral shoulder), dyspnea, tachypnea, tachycardia, and cyanosis. Diminished or absent breath sounds on the involved side with displacement of the trachea toward the contralateral side are often detected on physical examination. A tension pneumothorax will present with cardiovascular collapse and profound respiratory distress. The chest radiograph is the preferred imaging study and should be obtained unless the clinical condition warrants immediate treatment, although small pneumothoraces are often missed on initial chest x-ray. Computed tomography is superior to plain x-ray for detecting small pneumothoraces, although many of these are clinically insignificant and do not require intervention. Decompression via needle thoracentesis or tube thoracostomy is the treatment of choice (see later).

### Pneumomediastinum

A pneumomediastinum is an abnormal collection of air within the mediastinal space. Most commonly, pneumomediastinum results from microscopic alveolar rupture. There is some evidence that this may occur earlier in the continuum of pressure-induced injury, with the majority of ventilated patients developing pneumomediastinum before pneumothorax. As with pneumothorax, those patients receiving high peak pressures on the ventilator are most at risk, but there may be spontaneous development as well [144–146]. Aside from alveolar disruption, however, pneumomediastinum can also result from air escaping from the esophagus, trachea, or upper respiratory tract. This free air may be the result of trauma [147–149], surgery, or iatrogenic injury during medical procedures such as tracheal intubation, upper GI endoscopy, and



**FIGURE 2.9.** Tension pneumothorax in a 9-day-old premature infant with pulmonary interstitial emphysema and iatrogenic barotraumas from ventilator-induced lung injury. (Courtesy of Corning Benton, MD, Cincinnati Children's Hospital Medical Center.)



**FIGURE 2.10. (A)** Pneumomediastinum in a 6-month-old baby with acute respiratory failure (secondary to bacterial pneumonia) and ventilator-induced lung injury. **(B)** Pneumomediastinum in an 8-year-old boy admitted to the pediatric intensive care unit with

status asthmaticus. (Courtesy of Corning Benton, MD, Cincinnati Children's Hospital Medical Center.)

so forth. Pneumomediastinum may also result from retropharyngeal abscesses or other dental or oropharyngeal infections, especially those from gas-producing bacteria [144].

Pneumomediastinum is often asymptomatic, but, as mediastinal air may track into the subcutaneous tissues of the neck and chest, crepitus may develop. The patient may complain of chest pain, neck pain, or dyspnea. Diagnosis is typically made by chest x-ray (Figure 2.10). Isolated pneumomediastinum usually resolves without treatment, but, if severe, with cardiac compromise, or as a consequence of tracheal or esophageal rupture, surgical intervention is required. Turlapati et al. described a technique for placement of mediastinal tubes at the bedside for emergency decompression of hemodynamically significant pneumomediastinum [150].

## Chest Tubes

### The Physics of Chest Tubes

Chest tubes have been employed since the days of Hippocrates. The chest tube and collecting system have undergone some changes since then, with the closed tube thoracostomy being put into widespread use for hemothorax following the Korean conflict. Currently, the indications for chest tube use include significant pleural effusion, hemothorax, chylothorax, pneumothorax, empyema, and malignant effusion. Although these conditions can occasionally be managed through observation and thoracentesis, often chest tube placement is required.

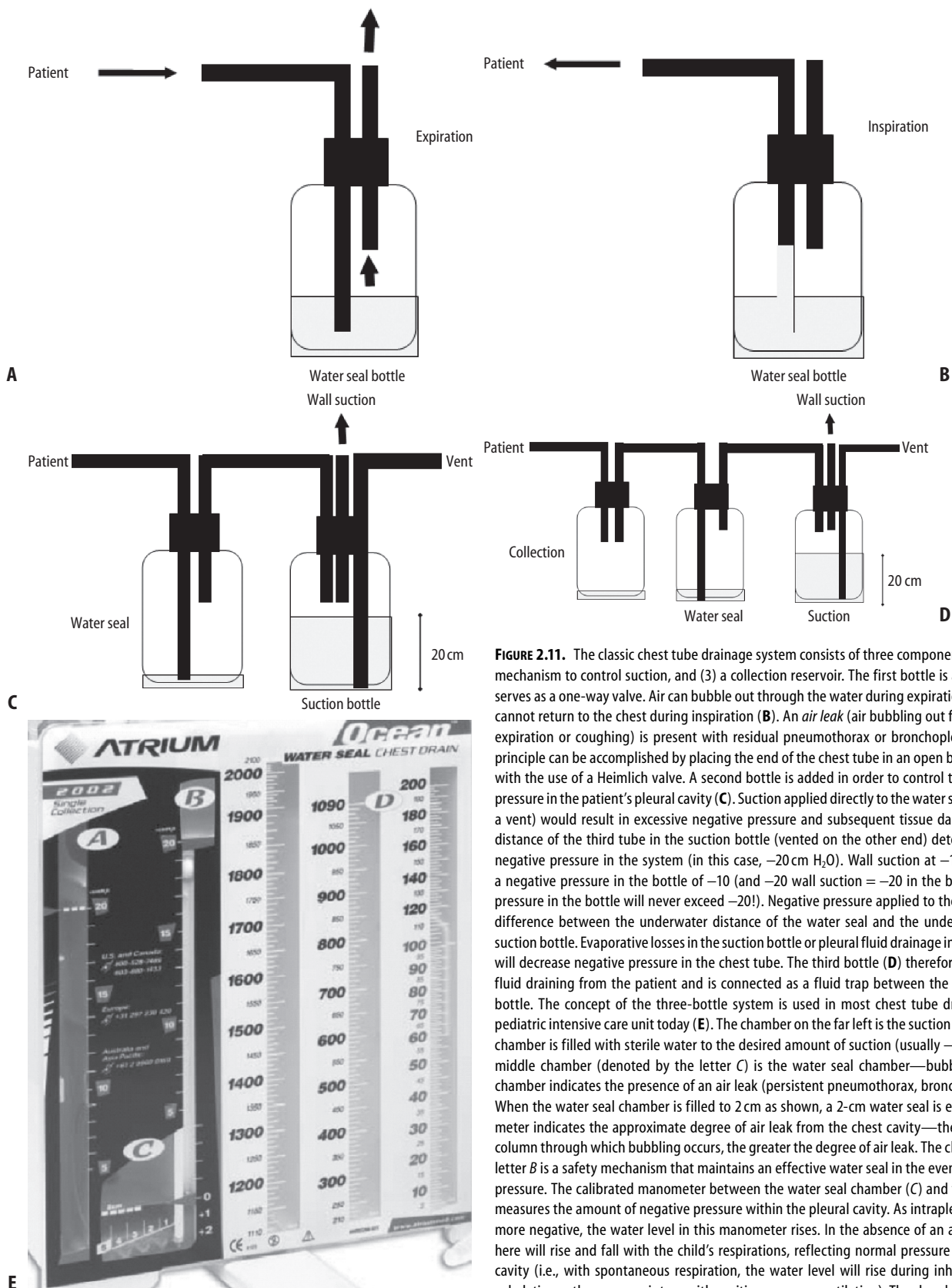
The closed tube system consists of three chambers. The collection chamber is connected to the patient through the chest tube and is also connected to a water seal chamber. A water seal chamber serves as a one-way valve, preventing return of the drained fluid to the patient. The water seal chamber is then connected to a third chamber that controls the amount of suction applied to the pleural space (Figure 2.11) [151,152].

### Placement of Chest Tubes

The placement of a thoracotomy tube varies somewhat on the medium that is to be drained. Pigtail catheters placed via Seldinger technique in the midaxillary line of the fifth intercostal space have become a common alternative to traditional, more invasive chest tubes, especially for the pediatric population [153]. These tubes are very useful in draining transudative effusions or air and can be placed with minimal sedation. Pigtail tubes, in general, are more comfortable for the patient while in place. They are, however, limited by their caliber and are more prone to clogging, especially with chylous, grossly bloody, or purulent pleural fluid collections. In those circumstances when pigtail catheters fail or are inappropriate because of more viscous media in the pleura, a traditional thoracostomy tube should be placed. Here, the patient is placed supine with the involved side elevated 10°–20° from the bed. The lateral chest wall is prepped and draped in a sterile fashion, and, after local anesthesia is administered, a small transverse incision is made at the intercostal space below that selected for the chest tube (typically the fifth intercostal space). With a clamp or scissors, blunt dissection is used to separate skin and chest wall. The intercostal muscles are then separated over the edge of the fifth rib with a blunt clamp, and the parietal pleura is penetrated. With the tip of a gloved finger, the tract and penetration of the pleural space is verified. The tip of the plastic catheter (size ranging from 20 to 36 F) is then inserted through the tract and directed toward the most dependent portion of the lung. The tube is then secured in place and attached to the collecting system as described earlier.

### Chest Tube Management

After insertion, chest tubes should be monitored daily to evaluate the amount and quality of the drainage, the presence of bubbling (i.e., air leak), and movement of the fluid with respiration to ensure patency and correct positioning. Reexpansion pulmonary edema has been reported after drainage of large effusions or



**FIGURE 2.11.** The classic chest tube drainage system consists of three components: (1) water seal, (2) a mechanism to control suction, and (3) a collection reservoir. The first bottle is a water seal bottle and serves as a one-way valve. Air can bubble out through the water during expiration or coughing (**A**), but cannot return to the chest during inspiration (**B**). An *air leak* (air bubbling out from the patient during expiration or coughing) is present with residual pneumothorax or bronchopleural fistula. The same principle can be accomplished by placing the end of the chest tube in an open bottle of sterile water or with the use of a Heimlich valve. A second bottle is added in order to control the amount of negative pressure in the patient's pleural cavity (**C**). Suction applied directly to the water seal bottle (and without a vent) would result in excessive negative pressure and subsequent tissue damage. The underwater distance of the third tube in the suction bottle (vented on the other end) determines the amount of negative pressure in the system (in this case,  $-20\text{ cm H}_2\text{O}$ ). Wall suction at  $-10\text{ cm H}_2\text{O}$  will result in a negative pressure in the bottle of  $-10$  (and  $-20\text{ wall suction} = -20$  in the bottle, but the negative pressure in the bottle will never exceed  $-20$ !). Negative pressure applied to the patient will equal the difference between the underwater distance of the water seal and the underwater distance in the suction bottle. Evaporative losses in the suction bottle or pleural fluid drainage into the water seal bottle will decrease negative pressure in the chest tube. The third bottle (**D**) therefore serves only to collect fluid draining from the patient and is connected as a fluid trap between the patient and water seal bottle. The concept of the three-bottle system is used in most chest tube drainage systems in the pediatric intensive care unit today (**E**). The chamber on the far left is the suction control chamber—this chamber is filled with sterile water to the desired amount of suction (usually  $-10$  to  $-20\text{ cm H}_2\text{O}$ ). The middle chamber (denoted by the letter **C**) is the water seal chamber—bubbling in the water seal chamber indicates the presence of an air leak (persistent pneumothorax, bronchopleural fistula, etc.). When the water seal chamber is filled to  $2\text{ cm}$  as shown, a  $2\text{-cm}$  water seal is established. The air leak meter indicates the approximate degree of air leak from the chest cavity—the higher the numbered column through which bubbling occurs, the greater the degree of air leak. The chamber denoted by the letter **B** is a safety mechanism that maintains an effective water seal in the event of excessive negative pressure. The calibrated manometer between the water seal chamber (**C**) and the safety chamber (**B**) measures the amount of negative pressure within the pleural cavity. As intrapleural pressure becomes more negative, the water level in this manometer rises. In the absence of an air leak, the water level here will rise and fall with the child's respirations, reflecting normal pressure changes in the pleural cavity (i.e., with spontaneous respiration, the water level will rise during inhalation and fall during exhalation—the converse is true with positive pressure ventilation). The chamber on the far right is the collection (chest tube drainage) chamber, denoted by the letter **D**.

pneumothoraces in both adults and children [154–156]. This potentially lethal complication of thoracostomy tube placement is fortunately quite rare. Young patients, especially those with spontaneous pneumothorax, appear to be at a greater risk [155,156]. Suggestions that have been proposed to minimize the risk of this rare complication include slow drainage of large pleural effusions, use of supplemental oxygen (if the patient is not on positive pressure ventilation), and avoiding or minimizing suction until the lung has reexpanded following placement of a chest tube for pneumothorax [155–157].

If the fluid drainage ceases suddenly, the tube may be kinked or blocked by exudative drainage. Evaluation of the drain especially at the exit site may alleviate the problem of kinking, and flushing the tube with a small amount (10 mL) of sterile normal saline may relieve blockage of pus or debris. If this does not restore fluid drainage and fluid persists by chest radiography, it may be that the tube has shifted, with its drainage ports resting outside the pleura, or that the fluid has become loculated and sequestered from drainage. In these instances the tube may need to be replaced or, in the case of loculations, fibrinolytics or VATS considered.

The timing of chest tube removal should be determined clinically, by resolution of symptoms and minimal chest tube drainage, commonly defined as 10–15 mL over 24 hr. Complete cessation of drainage should not be anticipated, as the presence of the chest tube itself may serve as a stimulus for fluid production. For those chest tubes placed for accumulation of air or pneumothorax, a period of observation after chest tube clamping is recommended to observe for reaccumulation of air or bronchopleural leak. It is often advisable to maintain pleural drainage in those patients who remain on positive pressure ventilation until they are weaned from the ventilator because of the increased risk of reaccumulation of air.

Once the decision to remove the chest tube has been made, the child should be provided with analgesia and sedation. Chest tube removal should be completed briskly, during the expiratory phase or with a Valsalva maneuver in a cooperative child. The site should be covered with an occlusive dressing and a chest x-ray obtained to evaluate for residual or recurrent pneumothorax.

## References

- Martin JA, Kochanek KD, Strobino DM, Guyer B, MacDorman MF. Annual summary of vital statistics—2003. *Pediatrics* 2005;115:619–634.
- Gregory GA, ed. *Clinics in Critical Care Medicine: Respiratory Failure in the Child*. New York: Churchill Livingstone; 1981:vii.
- Vidyasagar D. Clinical diagnosis of respiratory failure in infants and children. In: Gregory GA, ed. *Clinics in Critical Care Medicine: Respiratory Failure in the Child*. New York: Churchill Livingstone; 1981:1.
- Finder JD. Primary bronchomalacia in infants and children. *J Pediatr* 1997;130:59–66.
- Masters IB, Chang AB, Patterson L, et al. Series of laryngomalacia, tracheomalacia, and bronchomalacia disorders and their associations with other conditions in children. *Pediatr Pulmonol* 2002;34:189–195.
- Austin J, Ali T. Tracheomalacia and bronchomalacia in children: pathophysiology, assessment, treatment, and anaesthesia management. *Paediatr Anaesth* 2003;3–11.
- Boogard R, Huiksmans SH, Pijnenburg MW, Tiddens HA, de Jongste JC, Merkus PJ. Tracheomalacia and bronchomalacia in children: Incidence and patient characteristics. *Chest* 2005;128:3391–3397.
- Yalcin E, Dogru D, Ozcelik U, Kiper N, Aslan AT, Gozcan A. Tracheomalacia and bronchomalacia in 34 children: clinical and radiologic profiles and associations with other diseases. *Clin Pediatr (Phila)* 2005;44:777–781.
- Mair EA, Parsons DS, Lally KP. Treatment of severe bronchomalacia with expanding endobronchial stents. *Arch Otolaryngol Head Neck Surg* 1990;116:1087–1090.
- Mutabagani KH, Menke JA, McCoy KS, Besner GE. Bronchopexy for congenital bronchomalacia in the newborn. *J Pediatr Surg* 1999;34:1300–1303.
- Ahel V, Banac S, Rozmanic V, Vukas D, Drescik I, Ahel VA Jr. Aortopexy and bronchopexy for the management of severe tracheomalacia and bronchomalacia. *Pediatr Int* 2003;45:104–106.
- Pillai JB, Smith J, Hasan A, Spencer D. Review of pediatric airway malacia and its management, with emphasis on stenting. *Eur J Cardiothorac Surg* 2005;27:35–44.
- Valerie EP, Durrant AC, Forte V, Wales P, Chait P, Kim PC. A decade of using intraluminal tracheal/bronchial stents in the management of tracheomalacia and/or bronchomalacia: is it better than aortopexy? *J Pediatr Surg* 2005;40:904–907.
- Doolittle AM, Mair EA. Tracheal bronchus: classification, endoscopic analysis, and airway management. *Otolaryngol Head Neck Surg* 2002;126:240–243.
- Sanchez I, Navarro H, Mendez M, Holmgren N, Caussade S. Clinical characteristics of children with tracheobronchial anomalies. *Pediatr Pulmonol* 2003;35:288–291.
- Berrolcal T, Madrid C, Novo S, Gutierrez J, Arjonilla A, Gomez-Leon N. Congenital anomalies of the tracheobronchial tree, lung, and mediastinum: embryology, radiology, and pathology. *Radiographics* 2004;24:e17.
- Le Roux BT. Anatomical abnormalities of the right upper lobe bronchus. *J Thorac Cardiovasc Surg* 1962;44:225–227.
- Atwell SW. Major anomalies of the tracheobronchial tree: with a list of minor abnormalities. *Dis Chest* 1967;52:611–615.
- Barat M, Konrad HR. Tracheal bronchus. *Am J Otolaryngol* 1987;8:118–122.
- O'Sullivan BP, Frassica JJ, Rayder SM. Tracheal bronchus: a cause of prolonged atelectasis in intubated children. *Chest* 1998;113:537–540.
- Siegel MJ, Shackelford FG, Francis RS, et al. Tracheal bronchus. *Radiology* 1979;130:353–355.
- McLaughlin FJ, Strieder DJ, Harris GBC, et al. Tracheal bronchus: association with respiratory morbidity in childhood. *J Pediatr* 1985;106:751–755.
- Bertrand P, Navarro H, Caussade S, Holmgren N, Sanchez I. Airway anomalies in children with Down syndrome: endoscopic findings. *Pediatr Pulmonol* 2003;36:137–141.
- Jederlinic PJ, Sicilian LS, Baigelman W, Gaensler EA. Congenital bronchial atresia. A report of 4 cases and a review of the literature. *Medicine (Baltimore)* 1987;66:73–83.
- Ward S, Morcos SK. Congenital bronchial atresia—presentation of three cases and a pictorial review. *Clin Radiol* 1999;54:144–148.
- Shanmugam G, MacArthur K, Pollock JC. Congenital lung malformations—antenatal and postnatal evaluation and management. *Eur J Cardiothorac Surg* 2005;27:45–52.
- Morikawa N, Kuroda T, Honna T, et al. Congenital bronchial atresia in infants and children. *J Pediatr Surg* 2005;40:1822–1826.
- Krummel TK. Congenital malformations of the lower respiratory tract. In: Chernick V, Boat TF, eds. *Kendig's Disorders of the Respiratory Tract in Children*, 6th ed. Philadelphia: WB Saunders; 1998:305–307.
- Schwartz MZ, Ramachandran P. Congenital malformations of the lung and mediastinum—a quarter century of experience from a single institution. *J Pediatr Surg* 1997;32:44–47.
- Laberge JM, Puligandla P, Flageole H. Asymptomatic congenital lung malformations. *Semin Pediatr Surg* 2005;14:16–33.
- Ayed AK, Owayed A. Pulmonary resection in infants for congenital pulmonary malformations. *Chest* 2003;124:98–101.



32. Ozcelik U, Gocmen A, Kiper N, Dogru D, Dilber E, Yalcin EG. Congenital lobar emphysema: Evaluation and long-term follow-up of thirty cases at a single center. *Pediatr Pulmonol* 2003;35:384–391.
33. Mendeloff EN. Sequestrations, congenital cystic adenomatoid malformations, and congenital lobar emphysema. *Semin Thorac Cardiovasc Surg* 2004;16:209–214.
34. Sagy M, Silver P, Nimkoff L, Zahtz G, Amato JJ, Bierman FZ. Pediatric intrathoracic large airway obstruction: diagnostic and therapeutic considerations. *Pediatr Emerg Care* 1994;10:351–358.
35. Doull IJ, Connett GJ, Warner JO. Bronchoscopic appearance of congenital lobar emphysema. *Pediatr Pulmonol* 1996;21:195–197.
36. Al-Bassam A, Al-Rabeeah A, Al-Nassar S, et al. Congenital cystic disease of the lung in infants and children (experience with 57 cases). *Eur J Pediatr Surg* 1999;9:364–368.
37. Yoshioka H, Aoyama K, Iwamura Y, et al. Case of congenital lobar emphysema in an 18-month-old boy and review of earlier cases. *Pediatr Int* 2003;45:587–589.
38. Chao MC, Karamzadeh AM, Ahuja G. Congenital lobar emphysema: an otolaryngologic perspective. *Int J Pediatr Otorhinolaryngol* 2005;69:549–554.
39. Powers JE, Counselman FL. Congenital lobar emphysema: tube thoracostomy not the treatment. *Pediatr Emerg Care* 2005;21:760–762.
40. Khosa JK, Leong SL, Borzi PA. Congenital cystic adenomatoid malformation of the lung: indications and timing for surgery. *Pediatr Surg Int* 2004;20:505–508.
41. Ueda K, Gruppo R, Unger F, Martin L, Bove K. Rhabdomyosarcoma of lung arising in congenital cystic adenomatoid malformation. *Cancer* 1977;40:383–388.
42. Granata C, Gambini C, Balducci T, et al. Bronchioloalveolar carcinoma arising in congenital cystic adenomatoid malformation in a child: a case report and review on malignancies originating in congenital cystic adenomatoid malformation. *Pediatr Pulmonol* 1998;25:62–66.
43. Ozcan C, Celik A, Ural Z, Veral A, Kandiloglu G, Balik E. Primary pulmonary rhabdomyosarcoma arising within cystic adenomatoid malformation: a case report and review of the literature. *J Pediatr Surg* 2001;36:1062–1065.
44. Pai S, Eng HL, Lee SY, Hsiao CC, Huang WT, Huang SC. Rhabdomyosarcoma arising within congenital cystic adenomatoid malformation. *Pediatr Blood Cancer* 2005;45:841–845.
45. Singh S, Bhende MS, Kinnane JM. Delayed presentations of congenital diaphragmatic hernia. *Pediatr Emerg Care* 2001;17:269–271.
46. Elhalaby EA, Abo Sikeena MH. Delayed presentation of congenital diaphragmatic hernia. *Pediatr Surg Int* 2002;18:480–485.
47. Smith NP, Jesudason EC, Featherstone NC, Corbett HJ, Losty PD. Recent advances in congenital diaphragmatic hernia. *Arch Dis Child* 2005;90:426–428.
48. Gosche JR, Islam S, Boulanger SC. Congenital diaphragmatic hernia: searching for answers. *Am J Surg* 2005;190:324–332.
49. John PR, Beasley SW, Mayne V. Pulmonary sequestration and related congenital disorders. A clinico-radiological review of 41 cases. *Pediatr Radiol* 1989;20:4–9.
50. Horak E, Bodner J, Gassner I, et al. Congenital cystic lung disease: diagnostic and therapeutic considerations. *Clin Pediatr (Phila)* 2003;42:251–261.
51. Corbett HJ, Humphrey GM. Pulmonary sequestration. *Paediatr Respir Rev* 2004;5:59–68.
52. Woodring JH, Howard TA, Kanga JF. Congenital pulmonary venolobar syndrome revisited. *Radiographics* 1994;14:349–369.
53. Holt PD, Berdon WE, Marans Z, Griffiths S, Hsu D. Scimitar vein draining to the left atrium and a historical review of the scimitar syndrome. *Pediatr Radiol* 2004;34:409–413.
54. Rokade ML, Ranavavare RV, Shetty DS, Saifi S. Scimitar syndrome. *Indian J Pediatr* 2005;72:245–247.
55. Sehgal A, Loughran-Fowlds A. Scimitar syndrome. *Indian J Pediatr* 2005;72:249–251.
56. Dupuis C, Charaf LA, Breviere GM, Abou P, Remy-Jardin M, Helmius G. The “adult” form of the scimitar syndrome. *Am J Cardiol* 1992;70:502–507.
57. Dupuis C, Charaf LA, Breviere GM, Abou P. “Infantile” form of the scimitar syndrome with pulmonary hypertension. *Am J Cardiol* 1993;71:1326–1330.
58. Gao YA, Burrows PE, Benson LN, Rabinovitch M, Freedom RM. Scimitar syndrome in infancy. *J Am Coll Cardiol* 1993;22:873–882.
59. Najm HK, Williams WG, Coles JG, Rebeyka IM, Freedom RM. Scimitar syndrome: twenty years’ experience and results of repair. *J Thorac Cardiovasc Surg* 1996;112:1161–1169.
60. Torres AR, Dietl CA. Surgical management of the scimitar syndrome: an age-dependent spectrum. *Cardiovasc Surg* 1993;1:432–438.
61. Schramel FM, Westermann CJ, Knaepen PJ, van den Bosch JM. The scimitar syndrome: clinical spectrum and surgical treatment. *Eur Respir J* 1995;8:196–201.
62. Brown JW, Ruzmetov M, Minnich DJ, et al. Surgical management of scimitar syndrome: an alternative approach. *J Thorac Cardiovasc Surg* 2003;125:238–245.
63. Hoffman MA, Superina R, Wesson DE. Unilateral pulmonary agenesis with esophageal atresia and distal tracheoesophageal fistula: report of two cases. *J Pediatr Surg* 1989;24:1084–1085.
64. Kitagawa H, Nakada K, Fujioka T, et al. Unilateral pulmonary agenesis with tracheoesophageal fistula: a case report. *J Pediatr Surg* 1995;30:1523–1525.
65. Nowotny T, Ahrens BC, Bittigau K, et al. Right-sided pulmonary aplasia: longitudinal lung function studies in two cases and comparison to results from term healthy neonates. *Pediatr Pulmonol* 1998;26:138–144.
66. Thomas RJ, Lathif HC, Sen S, Zachariah N, Chacko J. Varied presentations of unilateral lung hypoplasia and agenesis: a report of four cases. *Pediatr Surg Int* 1998;14:94–95.
67. Bentsianov BL, Goldstein NA, Giuste R, Har-El G. Unilateral pulmonary agenesis presenting as an airway lesion. *Arch Otolaryngol Head Neck Surg* 2000;126:1386–1389.
68. Ootaki Y, Yamaguchi M, Yoshimura N, Oka S. Pulmonary agenesis with congenital heart disease. *Pediatr Cardiol* 2004;25:145–148.
69. Abrams ME, Ackerman VL, Engle WA. Primary unilateral pulmonary hypoplasia: Neonate through early childhood—case report, radiographic diagnosis, and review of the literature. *J Perinatol* 2004;24:667–670.
70. Rasch DK, Grover FL, Schnapf BM, Clarke E, Pollard TG. Right pneumonectomy syndrome in infancy treated with an expandable prosthesis. *Ann Thorac Surg* 1990;50:127–129.
71. Morrow SE, Glynn L, Ashcraft KW. Ping-pong ball plombage for right postpneumonectomy syndrome in children. *J Pediatr Surg* 1998;33:1048–1051.
72. Podevin G, Larroquet M, Camby C, Audry G, Plattner V, Heloury Y. Postpneumonectomy syndrome in children: advantages and long-term follow-up of expandable prosthesis. *J Pediatr Surg* 2001;36:1425–1427.
73. Dobremez E, Fayon M, Vergnes P. Right pulmonary agenesis associated with remaining bronchus stenosis, an equivalent of postpneumonectomy syndrome. Treatment by insertion of tissue expanders in the thoracic cavity. *Pediatr Surg Int* 2005;21:121–122.
74. Finer NN, Moriarty RR, Boyd J, Phillips HJ, Stewart AR, Ulan O. Postextubation atelectasis: a retrospective review and a prospective controlled study. *J Pediatr* 1979;94:110–113.
75. Rivera R, Tibballs J. Complications of endotracheal intubation and mechanical ventilation in infants and children. *Crit Care Med* 1992;20:193–199.
76. Boothroyd AE, Murthy BV, Darbyshire A, Petros AJ. Endotracheal suctioning causes right upper lobe collapse in intubated children. *Acta Paediatr* 1996;85:1422–1425.
77. Thomas K, Habibi P, Britto J, Owens CM. Distribution and pathophysiology of acute lobar collapse in the pediatric intensive care unit. *Crit Care Med* 1999;27:1594–1597.

78. Duggan M, Kavanagh BP. Pulmonary atelectasis: a pathogenic perioperative entity. *Anesthesiology* 2005;102:838–854.
79. Massard G, Wihlm JM. Postoperative atelectasis. *Chest Surg Clin North Am* 1998;8:503–528.
80. Peroni DG, Boner AL. Atelectasis: mechanisms, diagnosis, and management. *Paediatr Respir Rev* 2000;1:274–278.
81. Hogg JC, Williams J, Richardson JB, Macklem PT, Thurlbeck WM. Age as a factor in the distribution of lower-airway conductance and in the pathologic anatomy of obstructive lung disease. *N Engl J Med* 1970;282:1283–1287.
82. Mansell A, Bryan C, Levison H. Airway closure in children. *J Appl Physiol* 1972;33:711–714.
83. Berry FA, Yemen TA. Pediatric airway in health and disease. *Pediatr Clin North Am* 1994;41:153–180.
84. Stocks J. Respiratory physiology during early life. *Monaldi Arch Chest Dis* 1999;54:358–364.
85. Menkes H, Traystman R, Terry P. Collateral ventilation. *Fed Proc* 1979;38:22–26.
86. Hazinski TA. Atelectasis. In: Chernick V, Boat TF, eds. *Kendig's Disorders of the Respiratory Tract in Children*, 6th ed. Philadelphia: WB Saunders; 1998:634–641.
87. Krause MF, Hoehn T. Chest physiotherapy in mechanically ventilated children: a review. *Crit Care Med* 2000;28:1648–1651.
88. Krastins I, Corey ML, McLeod A, Edmonds J, Levison H, Moes F. An evaluation of incentive spirometry in the management of pulmonary complications after cardiac surgery in a pediatric population. *Crit Care Med* 1982;10:525–528.
89. Bellet PS, Kalinyak KA, Shukla R, Gelfand MJ, Rucknagel DL. Incentive spirometry to prevent acute pulmonary complications in sickle cell diseases. *N Engl J Med* 1995;333:699–703.
90. Reardon CC, Christiansen D, Barnett ED, Cabral HJ. Intrapulmonary percussive ventilation vs incentive spirometry for children with neuromuscular disease. *Arch Pediatr Adolesc Med* 2005;159:526–531.
91. Hsu LL, Batts BK, Rau JL. Positive expiratory pressure device acceptance by hospitalized children with sickle cell disease is comparable to incentive spirometry. *Respir Care* 2005;50:624–627.
92. Chatwin M, Ross E, Hart N, Nickol AH, Polkey MI, Simonds AK. Cough augmentation with mechanical insufflation/exsufflation in patients with neuromuscular weakness. *Eur Respir J* 2003;21:502–508.
93. Miske LJ, Hickey EM, Kolb SM, Weiner DJ, Panitch HB. Use of the mechanical in-exsufflator in pediatric patients with neuromuscular disease and impaired cough. *Chest* 2004;125:1406–1412.
94. Friedman O, Chidekel A, Lawless ST, Cook SP. Postoperative bilevel positive airway pressure ventilation after tonsillectomy and adenoidectomy in children—a preliminary report. *Int J Pediatr Otorhinolaryngol* 1999;51:177–180.
95. Jaarsma AS, Knoester H, van Rooyen F, Bos AP. Biphase positive airway pressure ventilation (PeV+) in children. *Crit Care* 2001;5:174–177.
96. Padman R, Henry M. The use of bilevel positive airway pressure for the treatment of acute chest syndrome of sickle cell disease. *Del Med J* 2004;76:199–203.
97. Tokuda Y, Matsumoto M, Sugita T, Nishizawa J. Nasal mask bilevel positive airway pressure ventilation for diaphragmatic paralysis after pediatric open-heart surgery. *Pediatr Cardiol* 2004;25:552–553.
98. Shah PL, Scott SF, Hodson ME. Lobar atelectasis in cystic fibrosis and treatment with recombinant human DNase I. *Respir Med* 1994;88:313–315.
99. Gershon WM, Rusakow LS, Chetty A, Splaingard ML. Resolution of chronic atelectasis in a child with asthma after aerosolized recombinant human DNase. *Pediatr Pulmonol* 1994;18:268–269.
100. Touleimat BA, Conoscenti CS, Fine JM. Recombinant human DNase in management of lobar atelectasis due to retained secretions. *Thorax* 1995;50:1319–1323.
101. Voelker KG, Chetty KG, Mahutte CK. Resolution of recurrent atelectasis in spinal cord injury patients with administration of recombinant human DNase. *Intensive Care Med* 1996;22:582–584.
102. Boeuf B, Prouix F, Morneau S, Marton D, Lacroix J. Safety of endotracheal rhDNase (Pulmozyme) for treatment of pulmonary atelectasis in mechanically ventilated children. *Pediatr Pulmonol* 1998;26:147.
103. Durward A, Forte V, Shemie SD. Resolution of mucus plugging and atelectasis after intratracheal rhDNase therapy in a mechanically ventilated child with refractory status asthmaticus. *Crit Care Med* 2000;28:560–562.
104. El Hassan NO, Chess PR, Huysman MW, Merkus PJ, de Jongste JC. Rescue use of DNase in critical lung atelectasis and mucus retention in premature neonates. *Pediatrics* 2001;108:468–470.
105. Merkus PJ, de Hoog M, van Gent R, de Jongste JC. DNase treatment for atelectasis in infants with severe respiratory syncytial virus bronchiolitis. *Eur Respir J* 2001;18:734–737.
106. Kupeli S, Teksam O, Dogru D, Yurdakok M. Use of recombinant human DNase in a premature infant with recurrent atelectasis. *Pediatr Int* 2003;45:584–586.
107. Riethmueller J, Borth-Bruhn T, Kumpf M, et al. Recombinant human deoxyribonuclease shortens ventilation time in young, mechanically ventilated children. *Pediatr Pulmonol* 2006;41:61–66.
108. Barbato A, Novello A Jr, Tormena F, Carra S, Malocco F. Use of fiberoptic bronchoscopy in asthmatic children with lung collapse. *Pediatr Med Chir* 1995;17:253–255.
109. Wood RE. The emerging role of flexible bronchoscopy in pediatrics. *Clin Chest Med* 2001;22:311–317.
110. Scolieri P, Adappa ND, Coticchia JM. Value of rigid bronchoscopy in the management of critically ill children with acute lung collapse. *Pediatr Emerg Care* 2004;20:384–386.
111. Bar-Zohar D, Sivan Y. The yield of flexible fiberoptic bronchoscopy in pediatric intensive care patients. *Chest* 2004;126:1353–1359.
112. Demling RH, LaLonde C, Ikegami K. Pulmonary edema: pathophysiology, methods of treatment, and clinical importance in acute respiratory failure. *New Horiz* 1993;1:371–380.
113. O'Brodovich H, Mellins RB. Pulmonary edema. In: Chernick V, Boat TF, eds. *Kendig's Disorders of the Respiratory Tract in Children*, 6th ed. Philadelphia: WB Saunders; 1998:653–675.
114. Deshpande JK, Wetzel RC, Rogers MC. Unusual causes of myocardial ischemia, pulmonary edema, and cyanosis. In: Rogers MC, ed. *Textbook of Pediatric Intensive Care*, 3rd ed. Baltimore: Williams & Wilkins; 1996:432–442.
115. Rosenberg AL. Fluid management in patients with acute respiratory distress syndrome. *Respir Care Clin North Am* 2003;9:481–493.
116. O'Brodovich H. Pulmonary edema in infants and children. *Curr Opin Pediatr* 2005;17:381–384.
117. Staub NC, Nagano H, Pearce ML. Pulmonary edema in dogs, especially the sequence of fluid accumulation in the lungs. *J Appl Physiol* 1967;22:227–240.
118. Verghese GM, Ware LB, Matthay BA, Matthay MA. Alveolar epithelial fluid transport and the resolution of clinically severe hydrostatic pulmonary edema. *J Appl Physiol* 1999;87:1301–1312.
119. Ware LB, Matthay MA. Alveolar fluid clearance is impaired in the majority of patients with acute lung injury and the acute respiratory distress syndrome. *Am J Respir Crit Care Med* 2001;163:1376–1383.
120. Flori HR, Glidden DV, Rutherford GW, Matthay MA. Pediatric acute lung injury: prospective evaluation of risk factors associated with mortality. *Am J Respir Crit Care Med* 2005;171:995–1001.
121. Berthiaume Y, Folkesson HG, Matthay MA. Lung edema clearance: 20 years of progress: invited review: alveolar fluid clearance in the injured lung. *J Appl Physiol* 2002;93:2207–2213.
122. Mehta D, Bhattacharya J, Matthay MA, Malik AB. Integrated control of lung fluid balance. *Am J Physiol Lung Cell Mol Physiol* 2004;287:L1081–L1090.

123. Morina P, Herrera M, Venegas J, Mora D, Rodriguez M, Pino E. Effects of nebulized salbutamol on respiratory mechanics in adult respiratory distress syndrome. *Intensive Care Med* 1997;23:58–64.
124. Atabai K, Ware LB, Snider ME, et al. Aerosolized beta(2)-adrenergic agonists achieve therapeutic levels in the pulmonary edema fluid of ventilated patients with acute respiratory failure. *Intensive Care Med* 2002;28:705–711.
125. McAuley DF, Frank JA, Fang X, Matthay MA. Clinically relevant concentrations of beta2-adrenergic agonists stimulate maximal cyclic adenosine monophosphate-dependent airspace fluid clearance and decrease pulmonary edema in experimental acid-induced lung injury. *Crit Care Med* 2004;32:1470–1476.
126. Perkins GD, McAuley DF, Thickett DR, Gao F. The beta-agonist lung injury trial (BALT): a randomized placebo controlled trial. *Am J Respir Crit Care Med* 2006;173:281–287.
127. Martin GS, Moss M, Wheeler AP, Mealer M, Morris JA, Bernard GR. A randomized, controlled trial of furosemide with or without albumin in hypoproteinemic patients with acute lung injury. *Crit Care Med* 2005;33:1681–1687.
128. Mocolin HT, Fischer GB. Epidemiology, presentation, and treatment of pleural effusion. *Paediatr Respir Rev* 2002;3:292–297.
129. Boyer DM. Evaluation and management of a child with a pleural effusion. *Pediatr Emerg Care* 2005;21:63–68.
130. Hawkins JA, Scaife ES, Hillman ND, Feola GP. Current treatment of pediatric empyema. *Semin Thorac Cardiovasc Surg* 2004;16:196–200.
131. Gates RL, Hogan M, Weinstein S, Arca MJ. Drainage, fibrinolytics, or surgery: a comparison of treatment options in pediatric empyema. *J Pediatr Surg* 2004;39:1638–1642.
132. Jaffe A, Balfour-Lynn IM. Management of empyema in children. *Pediatr Pulmonol* 2005;40:148–156.
133. Coote N, Kay E. Surgical versus non-surgical management of pleural empyema. *Cochrane Database Syst Rev* 2005;4:CD001956.
134. Chan EH, Russell JL, Williams WG, Van Arsdel GS, Coles JG, McCrindle BW. Postoperative chylothorax after cardiothoracic surgery in children. *Ann Thorac Surg* 2005;80:1864–1870.
135. Campbell RM, Benson LN, Williams WW, Adatia I. Chylopericardium after cardiac operations in children. *Ann Thorac Surg* 2001;72:193–196.
136. Le Coultre C, Oberhans I, Mossaz A, Bugmann P, Faidutti B, Belli DC. Postoperative chylothorax in children: differences between vascular and traumatic origin. *J Pediatr Surg* 1991;26:519–523.
137. Pratap U, Slavik Z, Ofue VD, Onuzo O, Franklin RC. Octreotide to treat postoperative chylothorax after cardiac operations in children. *Ann Thorac Surg* 2001;72:1740–1742.
138. Rosti L, Bini RM, Chessa M, Butera G, Drago M, Carminati M. The effectiveness of octreotide in the treatment of post-operative chylothorax. *Eur J Pediatr* 2002;161:149–150.
139. Mohseni-Bod H, Macrae D, Slavik Z. Somatostatin analog (octreotide) in management of neonatal postoperative chylothorax: is it safe? *Pediatr Crit Care Med* 2004;5:356–357.
140. Beghetti M, La Scala G, Belli D, Bugmann P, Kalangos A, Le Coultre C. Etiology and management of pediatric chylothorax. *J Pediatr* 2000;136:653–658.
141. Mohan H, Paes ML, Haynes S. Use of intravenous immunoglobulins as an adjunct in the conservative management of chylothorax. *Paediatr Anaesth* 1999;9:89–92.
142. Marts BC, Naunheim KS, Fiore AC, Pennington DG. Conservative versus surgical management of chylothorax. *Am J Surg* 1992;164:532–535.
143. Salim MA, DiSessa TG, Arheart KL, Alpert BS. Contribution of superior vena caval flow to total cardiac output in children: a Doppler echocardiographic study. *Circulation* 1995;92:1860–1865.
144. Damore DT, Dayan PS. Medical causes of pneumomediastinum in children. *Clin Pediatr (Phila)* 2001;40:87–91.
145. Newcomb AE, Clarke CP. Spontaneous pneumomediastinum: a benign curiosity or a significant problem? *Chest* 2005;128:3298–3302.
146. Nounla J, Trobs R, Bennek J, Lotz I. Idiopathic spontaneous pneumomediastinum: an uncommon emergency in children. *J Pediatr Surg* 2004;39:E23–E24.
147. Cooper A. Thoracic injuries. *Semin Pediatr Surg* 1995;4:109–115.
148. Inci I, Ozcelik C, Nizam O, Eren N, Ozgen G. Penetrating chest injuries in children: a review of 94 cases. *J Pediatr Surg* 1996;31:673–676.
149. Cotton BA, Nance ML. Penetrating trauma in children. *Semin Pediatr Surg* 2004;13:87–97.
150. Turlapati KM, Spear RM, Peterson BM. Mediastinal tube placement in children with pneumomediastinum: hemodynamic changes and description of technique. *Crit Care Med* 1996;24:1257–1260.
151. von Hippel A. Chest Tubes and Chest Bottles. Springfield, IL: Charles C. Thomas; 1970:1–96.
152. Brandt ML, Luks FI, Lacroix J, Guay J, Collin PP, Diloranzo M. The paediatric chest tube. *Clin Intensive Care* 1994;5:123–129.
153. Roberts JS, Bratton SL, Brogan TV. Efficacy and complications of percutaneous pigtail catheters for thoracostomy in pediatric patients. *Chest* 1998;114:1116–1121.
154. Jardine OS. Reexpansion pulmonary edema. *Am J Dis Child* 1991;145:1092–1094.
155. Dubin JS. Reexpansion pulmonary edema. *J Emerg Med* 2000;19:377–378.
156. Sherman SC. Reexpansion pulmonary edema: a case report and review of the current literature. *J Emerg Med* 2003;24:23–2427.
157. Baumann MH, Strange C, Heffner JE, et al. Management of spontaneous pneumothorax—an American College of Chest Physicians Delphi Consensus Statement. *Chest* 2001;119:590–602.

The Respiratory Tract in Pediatric Critical Illness and Injury

Wheeler, D.S.; Wong, H.R.; Shanley, Th.P. (Eds.)

2009, XIV, 254 p. 112 illus., 5 illus. in color., Softcover

ISBN: 978-1-84800-924-0