

Fetal Counselling for Surgical Congenital Malformations

2

Kokila Lakhoo

Contents

2.1	Introduction	9
2.2	Congenital Malformation	10
2.3	Prenatal Diagnosis	10
2.3.1	Ultrasound Examination	10
2.4	Invasive Diagnostic Tests	11
2.4.1	Amniocentesis.....	11
2.4.2	Chorionic Villous Sampling (CVS)	11
2.4.3	Prenatal Maternal Serum Screening	11
2.4.4	Fetal Blood Sampling (FBS).....	12
2.4.5	Fetal Surgery.....	12
2.4.6	Genetic Diagnoses	12
2.4.7	Future Developments	12
2.5	Specific Surgical Conditions	12
2.5.1	Congenital Diaphragmatic Hernia (CDH)	12
2.5.2	Cystic Lung Lesions	13
2.6	Abdominal Wall Defects	14
2.6.1	Exomphalos	14
2.6.2	Gastroschisis	15
2.7	Tracheo-Oesophageal Fistula (TOF) and Oesophageal Atresia (OA)	16
2.8	Gastrointestinal Lesions	16
2.9	Sacroccygeal Teratoma	16
2.10	Renal Anomalies	17
2.10.1	Upper Urinary Tract Obstruction.....	17
2.10.2	Lower Urinary Tract Obstruction	17
2.11	Conclusion	18
	Further Reading	18

2.1 Introduction

Paediatric surgeons are often called to counsel parents once a surgical abnormality is diagnosed on a prenatal scan. The referral base for a paediatric surgeon now includes the perinatal period. Expertise in surgical correction of congenital malformations may favourably influence the perinatal management of prenatally diagnosed anomalies by changing the site of delivery for immediate postnatal treatment; altering the mode of delivery to prevent obstructed labour or haemorrhage; early delivery to prevent ongoing fetal organ damage; or treatment in utero to prevent, minimise or reverse fetal organ injury as a result of a structural defect. Favourable impact of prenatal counselling has been confirmed to influence the site of delivery in 37% of cases, change the mode of delivery in 6.8%, reverse the decision to terminate a pregnancy in 3.6% and influence the early delivery of babies in 4.5%.

Counselling parents about prenatally suspected surgically correctable anomalies should not be solely performed by obstetricians or paediatricians. Similarly the paediatric surgeon performing these prenatal consultations must be aware of differences between the prenatal and postnatal natural history of the anomaly. There is often a lack of understanding of the natural history and prognosis of a condition presenting in the newborn and the same condition diagnosed prenatally.

The diagnosis and management of complex fetal anomalies require a team effort by obstetricians, neonatologists, genetecists, paediatricians and paediatric surgeons to deal with all the maternal and fetal complexities of a diagnosis of a structural defect. This team should be able to provide information to prospective parents on fetal outcomes, possible interventions, appropriate setting, time and route of delivery and

expected postnatal outcomes. The role of the surgical consultant in this team is to present information regarding the prenatal and postnatal natural history of an anomaly, its surgical management and the long-term outcome.

2.2 Congenital Malformation

Congenital malformations account for one of the major causes of perinatal mortality and morbidity. Single major birth defects affect 3% of newborns and multiple defects affect 0.7% of babies. The prenatal hidden mortality is higher since the majority abort spontaneously. Despite improvements in perinatal care, serious birth defects still account for 20% of all deaths in the newborn period and an even greater percentage of serious morbidity later in infancy and childhood. The major causes of congenital malformation are chromosomal abnormalities, mutant genes, multifactorial disorders and teratogenic agents.

2.3 Prenatal Diagnosis

Prenatal diagnosis has remarkably improved our understanding of surgically correctable congenital malformations. It has allowed us to influence the delivery of the baby, offer prenatal surgical management and discuss the options of termination of pregnancy for seriously handicapping or lethal conditions. Antenatal diagnosis has also defined an in utero mortality for some lesions such as diaphragmatic hernia and sacro-coccygeal teratoma so that true outcomes can be measured. Prenatal ultrasound scanning has improved since its first use 30 years ago, thus providing better screening programmes and more accurate assessment of fetal anomaly. Screening for Down's syndrome may now be offered in the first trimester (e.g. nuchal scan combined test) or second trimester (e.g. Triple blood test). Better resolution and increased experience with ultrasound scans has led to the recognition of ultrasound soft markers that have increased the detection rate of fetal anomalies but at the expense of higher false positive rates.

Routine ultrasound screening identifies anomalies and places these pregnancies in the high-risk categories

with maternal diabetes, hypertension, genetic disorders, raised alpha fetoprotein, etc. High-risk pregnancies may be offered further invasive diagnostic investigations such as amniocentesis or chorionic villous sampling. Structural abnormalities difficult to define on ultrasound such as hindbrain lesions or in the presence of oligohydramnios are better imaged on ultra fast magnetic resonance imaging. With the increasing range of options and sophistication of diagnostic methods, parents today are faced with more information, choice and decisions than ever before, which can create as well as help to solve dilemmas. The different tests and screening procedures commonly in use are outlined below.

2.3.1 Ultrasound Examination

Ultrasound scan is routinely performed at 18–20 weeks gestation as part of the prenatal screening for all pregnancies in England and Wales. Older mothers are routinely screened and in addition are offered invasive testing. Pregnancies with maternal risk factors such as raised alpha fetoprotein levels, genetic disorders and family history of chromosomal abnormalities or mono-chorionic twins that carry a high risk for chromosomal anomalies are offered scans in the first trimester. Abnormalities such as diaphragmatic hernia may be detected as early as 11 weeks of gestation. First trimester scans are also useful for accurately dating pregnancies and defining chorionicity in multiple pregnancies.

More recently, nuchal translucency (NT) measurements have emerged as an independent marker of chromosomal abnormalities with a sensitivity of 60%, structural anomalies (particularly cardiac defects) and for some rare genetic syndromes. It involves measuring the area at the back of the fetal neck at 11–14 weeks of gestation (Fig. 2.1). The mechanisms by which some abnormalities give rise to this transient anatomical change of nuchal translucency are poorly understood. Although some abnormalities can be seen at the time of the nuchal scan (11–14 weeks), most are detected at the 18–20 week anomaly scan. Some abnormalities such as gastroschisis have a higher detection rate on a scan than others, for example, cardiac abnormalities.

If the nuchal translucency measurement is increased and the karyotype is normal, there is a higher risk for a cardiac anomaly and these high-risk fetuses may be

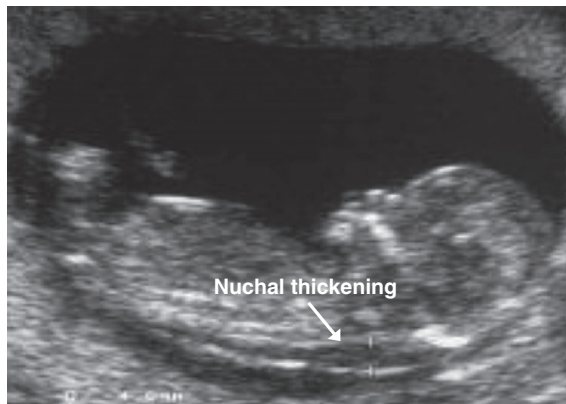


Fig. 2.1 Nuchal translucency scan

referred for fetal echocardiography, which provides better prenatal cardiac assessment than the routine screening scan. Ultrasound surveillance is essential during the performance of invasive techniques such as amniocentesis, CVS and shunting procedures. It is also useful for assessing fetal viability before and after such procedures. Some abnormalities such as tracheo-oesophageal fistula, bowel atresia, diaphragmatic hernia and hydrocephaly may present later in pregnancy and thereby may not be detected during the routine 18-weeks scan.

Overall, around 60% of structural birth defects are detected prenatally but the detection rate varies from 0% (isolated cleft palate) to close to 100% (gastroschisis) depending on the defect. True wrong diagnoses are rare but false positive diagnoses do occur; some are due to natural prenatal regression, but most are due to ultrasound “soft markers”.

Ultrasound “soft markers” are changes noted on prenatal scan that are difficult to define. Examples are echogenic bowel, hydronephrosis and nuchal thickening. Their presence creates anxiety among sonographers because the finding may be transient with no pathological relevance or may be an indicator of significant anomalies such as chromosomal abnormalities, cystic fibrosis (echogenic bowel), Down’s syndrome (nuchal thickening) or renal abnormalities (hydronephrosis). Once soft markers are detected, the dilemma faced by obstetricians is whether they should be reported or further invasive tests offered. Reporting these markers has increased detection rates at the expense of high false positive rates.

Ultrasound is routinely performed as a prenatal screening test. The reliability of the information

obtained is dependent on the expertise and experience of the person performing the scan. In a recent study, congenital anomalies noted at birth were diagnosed on prenatal scan in 64% of cases with 0.5% opting for termination.

2.4 Invasive Diagnostic Tests

Amniocentesis and chorionic villous sampling (CVS) are the two most commonly performed invasive diagnostic tests.

2.4.1 Amniocentesis

Amniocentesis is commonly used for detecting chromosomal abnormalities and less often for molecular studies, metabolic studies and fetal infection. It is performed after 15 weeks of gestation and carries a low risk of fetal injury or loss (0.5–1%). Full karyotype analysis takes approximately 2 weeks but newer RAPID techniques using FISH (fluorescent *in situ* hybridisation) or PCR (polymerase chain reaction) can give limited (usually for trisomies 21,18,13) results within 2–3 days.

2.4.2 Chorionic Villous Sampling (CVS)

CVS is the most reliable method for first trimester diagnosis and may be performed at 10–14 weeks of gestation. The test involves ultrasound-guided biopsy of the chorionic villi. The added risk for fetal loss is approximately 1–2%. The samples obtained may be subjected to a variety of tests including full karyotype, rapid karyotyping (FISH—PCR), enzyme analysis or molecular studies. Approximate timing of chromosomal results is 1–2 weeks for karyotyping and 2–3 days for FISH and PCR.

2.4.3 Prenatal Maternal Serum Screening

Interest in detecting circulating fetal cells in maternal blood for diagnostic purposes has grown since the

advent of fluorescence-activated cell sorting (FACS). The observation of high levels of AFP (alpha fetoprotein) in the amniotic fluid of pregnancies complicated by open neural tube defects (NTDs) popularised this test. However, with increasing accuracy of ultrasound diagnosis, maternal serum screening of AFP solely for identification of NTDs cannot be justified. The more popular maternal serum screening test is the triple test (HCG, AFP, oestrogen) used in combination with the nuchal scan.

2.4.4 Fetal Blood Sampling (FBS)

Rapid karyotyping of CVS and amniotic fluid samples FISH and PCR has replaced fetal blood sampling for many conditions. However, FBS is still required for the diagnosis and treatment of haematological conditions and some viral infections. When required it is best performed by ultrasound guided needle sampling after 18 weeks of gestation rather than the more invasive fetoscopic technique. Mortality from this procedure is reported to be 1–2%.

2.4.5 Fetal Surgery

There is a spectrum of interventions ranging from simple aspiration of cysts to open fetal surgery. Minimally invasive techniques such as ablation of vessels in sacrococcygeal teratoma, fetoscopic ablation of posterior urethral valves, tracheal occlusion for congenital diaphragmatic hernia, etc. are currently under trial. However, laser ablation in twin-to-twin transfusion is now well established.

2.4.6 Genetic Diagnoses

Antenatal detection of genetic abnormalities is increasing especially in high-risk pregnancies. Previously undiagnosed conditions such as cystic fibrosis, Beckwith-Wiedemann syndrome, Hirshsprung's disease, sickle cell disease, etc. may be detected prenatally following invasive testing and genetic counselling and assessment offered early in pregnancy.

2.4.7 Future Developments

The aim of prenatal diagnosis and testing is to ensure 100% accuracy without fetal loss or injury and no maternal risk. National plans to improve Down's screening using ultrasound and biochemical combination tests are now in place in the UK. Research into new markers for chromosomal abnormalities is ongoing. The fetal nasal bone is one such example, which may assist, in detecting babies with chromosomal abnormalities.

Management of Rhesus disease is showing promise whereby fetal blood groups may be determined from maternal blood samples through detection of free fetal DNA. The search for fetal components in maternal blood is an exciting and expanding field of research since past and present efforts to isolate and use them for diagnosis have met with little success. Rapid detection techniques versus traditional cultures for karyotyping are currently under debate.

Three-dimensional images from new ultrasound machines may have a useful role in diagnosis and assessment of facial deformities such as cleft lip and palate. Magnetic resonance imaging (MRI) may assist in better defining some lesions difficult to view on conventional prenatal scanning such as the presacral teratoma, posterior urethral valves in the presence of oligohydramnios and hindbrain lesions. At present, MRI is unlikely to replace conventional ultrasound scans.

2.5 Specific Surgical Conditions

2.5.1 Congenital Diaphragmatic Hernia (CDH)

CDH accounts for 1 in 3,000 live birth and challenges the neonatologist and paediatric surgeons in the management of this high-risk condition. Mortality remains high (more than 60%) when the "hidden" mortality of in utero death and termination of pregnancy are considered. Lung hypoplasia and pulmonary hypertension account for most deaths in isolated CDH newborns. Associated anomalies (30–40%) signify a grave prognosis with a survival rate of less than 10%.

In the UK, most CDHs are diagnosed at the 20-week anomaly scan with a detection rate approaching 60%.

although as early as 11 weeks gestation has been reported. Magnetic resonance imaging (MRI) has a useful role in accurately differentiating CDH from cystic lung lesions and may be useful in measuring fetal lung volumes as a predictor of outcome. Cardiac anomalies (20%), chromosomal anomalies of trisomy 13 and 18 (20%) and urinary, gastrointestinal and neurological (33%) anomalies can co-exist with CDH and should be ruled out by offering the patient fetal echocardiogram, amniocentesis and detailed anomaly scans. In these CDH patients, early detection, liver in the chest, polyhydramnios and fetal lung head ratio (LHR) of less than 1 are implicated as poor predictors of outcome. In these patients with poor prognostic signs, fetal surgery for CDH over the last 2 decades has been disappointing; however, benefit from fetal intervention with tracheal occlusion (FETO) awaits randomised studies. A favourable outcome in CDH with the use of antenatal steroids has not been resolved in the clinical settings. Elective delivery at a specialised centre is recommended with no benefit from caesarean section.

Post-natal management is aimed at reducing barotrauma to the hypoplastic lung by introducing high frequency oscillatory ventilation (HFOV) or permissive hypercapnea, and treating severe pulmonary hypertension with nitric oxide. No clear benefits for CDH with ECMO (extra corporeal membrane oxygenation) have been concluded in a 2002 Cochrane ECMO study.

Surgery for CDH is no longer an emergency procedure. Delayed repair following stabilisation is employed in most paediatric surgical centres. Primary repair using the trans-abdominal route is achieved in 60–70% of patients with the rest requiring a prosthetic patch. Complications of sepsis or reherniation with prosthetic patch requiring revision are recorded in 50% of survivors. Minimally invasive techniques have been successful in repairing diaphragmatic defects in “stable” infants.

Long-term survivors of CDH are reported to develop chronic respiratory insufficiency (48%), gastro-oesophageal reflux (89%) and neurodevelopment delay (30%).

2.5.2 Cystic Lung Lesions

Congenital cystic adenomatoid malformations (CCAMs), bronchopulmonary sequestrations (BPS) or “hybrid”

lesions containing features of both are common cystic lung lesions noted on prenatal scan. Less common lung anomalies include bronchogenic cysts, congenital lobar emphysema and bronchial atresia. Congenital cystic lung lesions are rare anomalies with an incidence of 1 in 10,000 to 1 in 35,000.

Prenatal detection rate of lung cysts at the routine 18–20 week scan is almost 100% and may be the commonest mode of actual presentation. Most of these lesions are easily distinguished from congenital diaphragmatic hernia; however, sonographic features of CCAM or BPS are not sufficiently accurate and correlate poorly with histology. Magnetic resonance imaging (MRI), though not routinely used, may provide better definition for this condition; however, inaccuracies were reported in 11% of cases.

Bilateral disease and hydrops fetalis are indicators of poor outcome, whereas mediastinal shift, polyhydramnios and early detection are not poor prognostic signs. In the absence of termination, the natural fetal demise of antenatally diagnosed cystic lung disease is 28%. It is well documented that spontaneous involution of cystic lung lesions can occur but complete post-natal resolution is rare, and apparent spontaneous “disappearance” of antenatally diagnosed lesions should be interpreted with care, as nearly half of these cases subsequently require surgery.

In only 10% of cases the need for fetal intervention arises. The spectrum of intervention includes simple centesis of amniotic fluid, thoracoamniotic shunt placement, percutaneous laser ablation and open fetal surgical resection. Maternal steroid administration has also been reported to have a beneficial effect on some CCAMs although the mechanism is unclear. A large cystic mass and hydrops in isolated cystic lung lesions are the only real indication for fetal intervention.

Normal vaginal delivery is recommended unless maternal conditions indicate otherwise. Large lesions are predicted to become symptomatic shortly after birth (as high as 45% in some series); thus, delivery at a specialised centre would be appropriate. However, smaller lesions are less likely to be symptomatic at birth and could be delivered at the referring institution with follow up in a paediatric surgery clinic.

Post-natal management is dictated by clinical status at birth. Symptomatic lesions require urgent radiological evaluation with chest radiograph and ideally CT scan (Fig. 2.2) followed by surgical excision. In asymptomatic cases, post-natal investigation consists of chest

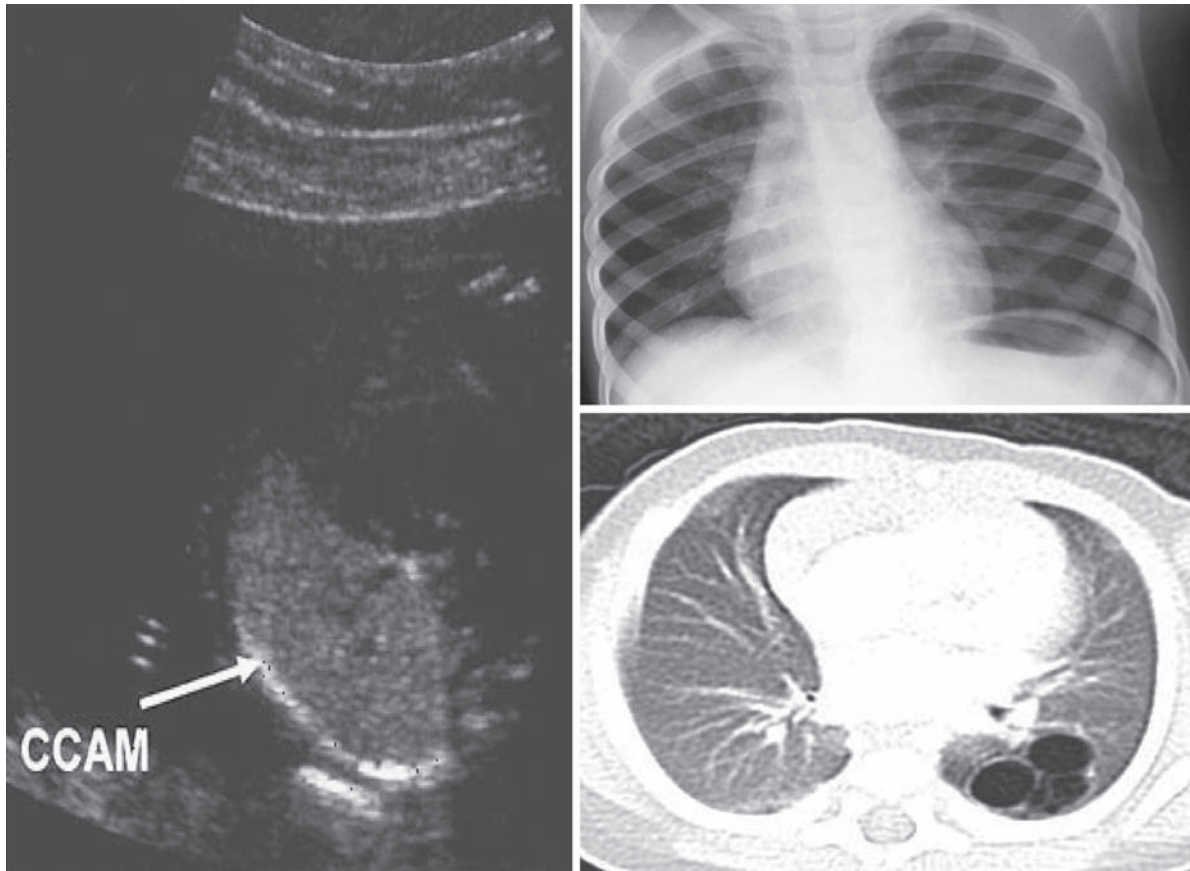


Fig. 2.2 Prenatal scan and post-natal radiological features of CCAM

CT scan within 1 month of birth, even if regression or resolution is noted on prenatal scanning. Plain radiography should not be relied on, because it will miss and underestimate many lesions.

Surgical excision of post-natal asymptomatic lesions remains controversial, with some centres opting for conservative management. The approach to treating this asymptomatic group has evolved in some centres, whereby a CT scan is performed within 1 month post birth, followed by surgery before 6 months of age due to the inherent risk of infection and malignant transformation. Small lesions less than 3 cm may be managed expectantly with annual CT scan, bearing in mind that the true resolution of these lesions is exceptional. Successful outcome of greater than 90% have been reported for these surgically managed asymptomatic lung lesions.

2.6 Abdominal Wall Defects

Exomphalos and gastroschisis are both common but distinct abdominal wall defects with an unclear aetiology and a controversial prognosis. Attention may be drawn to their presence during the second trimester because of raised maternal serum alpha-fetoprotein level or abnormal ultrasound scans.

2.6.1 Exomphalos

Exomphalos is characteristically a midline defect, at the insertion point of the umbilical cord, with a viable sac composed of amnion and peritoneum containing herniated abdominal contents. Incidence is known to

be 1 in 4,000 live births. Associated major abnormalities that include trisomy 13, 18 and 21, Beckwith-Wiedemann syndrome (macroglossia, gigantism, exomphalos), Pentology of Cantrell (sternal, pericardial, cardiac, abdominal wall and diaphragmatic defect), cardiac, gastrointestinal and renal abnormalities are noted in 60–70% of cases; thus, karyotyping, in addition to detailed sonographic review and fetal echocardiogram, is essential for complete prenatal screening. Fetal intervention is unlikely in this condition. If termination is not considered, normal vaginal delivery at a centre with neonatal surgical expertise is recommended and delivery by caesarean section only is reserved for large exomphalos with exteriorised liver to prevent damage.

Surgical repair includes primary closure or a staged repair with a silo for giant defects. Occasionally in vulnerable infants with severe pulmonary hypoplasia or complex cardiac abnormalities the exomphalos may be left intact and allowed to slowly granulate and epithelialise by application of antiseptic solution. Post-natal morbidity occurs in 5–10% of cases. Malrotation and adhesive bowel obstruction does contribute to mortality in isolated exomphalos; however, the majority of these children survive to live normal lives.

2.6.2 Gastroschisis

Gastroschisis is an isolated lesion that usually occurs on the right side of the umbilical defect with evisceration of the abdominal contents directly into the amniotic cavity. The incidence is increasing from 1.66 per 10,000 births to 4.6 per 10,000 births affecting mainly young mothers typically less than 20 years old. Associated anomalies are noted in only 5–24% of cases with bowel atresia the most common co-existing abnormality. On prenatal scan with a detection rate of 100%, the bowel appears to be free floating, and the loops may appear to be thickened due to damage by amniotic fluid exposure causing a “peel” formation. Dilated loops of bowel (Fig. 2.3) may be seen from obstruction secondary to protrusion from a defect or atresia due to intestinal ischaemia.

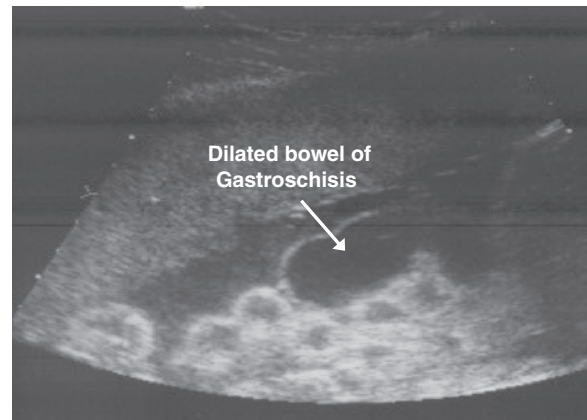


Fig. 2.3 Dilated bowel in gastroschisis

Predicting outcome in fetuses with gastroschisis based on prenatal ultrasound finding remains a challenge. There is some evidence that maximum small bowel diameter may be predictive; however, thickened matted bowel and Doppler measurements of the superior mesenteric artery are not accurate predictors of outcome. To reduce the rate of third trimester fetal loss, serial ultrasounds are performed to monitor the development of bowel obstruction and delivery around 37 weeks recommended at a centre with neonatal surgical expertise.

Recently a randomised control trial has challenged elective preterm delivery. Delivery by caesarean section has no advantage to normal vaginal route. Despite efforts to plan elective delivery, 50% of cases will require emergency caesarean section due to development of fetal distress.

Various methods of post-natal surgical repair include the traditional primary closure, reduction of bowel without anaesthesia, reduction by preformed silo, or by means of a traditional silo. Co-existing intestinal atresia could be repaired by primary anastomosis or staged with stoma formation. Variation in achieving full enteral feeding due to prolonged gut dysmotility is expected in all cases.

The long-term outcome in gastroschisis is dependent on the condition of the bowel. In uncomplicated cases the outcome is excellent in more than 90% of cases. The mortality of live born infants is 5% with further 5% suffering short bowel syndrome and 10% requiring surgery for adhesive bowel obstruction. Late third trimester fetal loss should always be mentioned during fetal counselling.

2.7 Tracheo-Oesophageal Fistula (TOF) and Oesophageal Atresia (OA)

Repair of TOF/OA is a condition that measures the skill of paediatric surgeons from trainees to independent surgeons. The incidence is estimated at 1 in 3,000 births. Prenatally, the condition may be suspected from maternal polyhydramnios and absence of a fetal stomach bubble at the 20-week anomaly scan. Prenatal scan diagnosis of TOF/OA is estimated to be less than 42% sensitive with a positive predicted value of 56%. Additional diagnostic clues are provided by associated anomalies such as trisomy (13,18,21), VACTERL sequence (vertebral, anorectal, cardiac, tracheo-oesophageal, renal, limbs) and CHARGE association (coloboma, heart defects, atresia choanae, retarded development, genital hypoplasia, ear abnormality). Associated anomalies are present in more than 50% of cases and worsen the prognosis; hence, prenatal karyotyping is essential. Duodenal atresia may co-exist with TOF/OA. The risk of recurrence in subsequent pregnancies for isolated TOF/OA is less than 1%. Delivery is advised at a specialised centre with neonatal surgical input.

Postnatal surgical management is dependent on the size and condition of the baby, length of the oesophageal gap and associated anomalies. Primary repair of the oesophagus is the treatment of choice; however, if not achieved, staged repair with upper oesophageal pouch care and gastrostomy or organ replacement with stomach or large bowel are other options. Associated anomalies require evaluation and treatment. Advanced paediatric endosurgical centres may offer minimally invasive thoracoscopic approach to the repair of TOF. Early outcome of a high leak rate and oesophageal stricture requiring dilatation in 50% of cases are expected where the anastomosis of the oesophagus is created under tension.

Improved perinatal management and inherent structural and functional defects in the trachea and oesophagus indicate long-term outcome. In early life, growth of the child is reported to be below the 25th centile in 50% of cases, respiratory symptoms in two-thirds of TOF/OA and gastro-oesophageal reflux recorded in 50% of patients. Quality of life is better in the isolated group with successful primary repair as compared to those with associated anomalies and delayed repair.

2.8 Gastrointestinal Lesions

The presence of dilated loops of bowel (>15 mm in length and 7 mm in diameter) on prenatal ultrasound scan is indicative of bowel obstruction.

Duodenal atresia has a characteristic “double bubble” appearance on prenatal scan, resulting from the simultaneous dilatation of the stomach and proximal duodenum. Detection rate on second trimester anomaly scan is almost 100% in the presence of polyhydramnios and the “double bubble” sign. Associated anomalies are present in approximately 50% of cases with most notably trisomy 21 in 30% of cases, cardiac anomalies in 20% and the presence of VACTERL association (vertebral, anorectal, cardiac, tracheo-oesophageal, renal and limbs).

The incidence of duodenal atresia is 1 in 5,000 live births. The postnatal survival rate is >95% with associated anomalies, low birth weight and prematurity contributing to the <5% mortality. Temporary delay in enteral feeding occurs due to the dysmotility in the dilated stomach and duodenum.

Many bowel abnormalities may be noted on prenatal scanning (dilated bowel, ascites, cystic masses, hyperparistalsis, polyhydramnios and echogenic bowel); however, none is absolutely predictive of postnatal outcome. Patients with obstruction frequently have findings (especially in the third trimester) of bowel dilatation, polyhydramnios and hyperparistalsis, but ultrasound is much less sensitive in diagnosing anomalies in the large bowel than those in the small bowel. Since the large bowel is mostly a reservoir, with no physiologic function in utero, defects in this region such as anorectal malformations or Hirschsprung's disease are very difficult to detect. Bowel dilatation and echogenic bowel may be associated with cystic fibrosis; therefore, all such fetuses should undergo postnatal evaluation for this disease. Prenatally diagnosed small bowel atresia does not select for a group with a worse prognosis and survival rates are 95–100%.

2.9 Sacrococcygeal Teratoma

Sacrococcygeal teratoma (SCT) is the commonest neonatal tumour accounting for 1 in 35,000 to 40,000 births. Four types have been defined:

Type 1 external tumour with a small presacral component

Type 2 external tumours with a large presacral component

Type 3 predominantly presacral with a small external component

Type 4 entirely presacral

The latter carry the worst prognosis due to delay in diagnosis and malignant presentation. Doppler ultrasound is the diagnostic tool; however, fetal MRI provides better definition of the intrapelvic component. SCT is a highly vascular tumour and the fetus may develop high cardiac output failure, anaemia and ultimately hydrops with a mortality of almost 100%. Fetal treatment of tumour resection or ablation of the feeding vessel has been attempted in hydropic patients. Caesarean section may be offered to patients with large tumours to avoid the risk of bleeding during delivery. Post-natal outcomes following surgery in type 1 and 2 lesions are favourable; however, type 3 and 4 tumours may present with urological problems and less favourable outcomes. Long-term follow up with alpha fetoprotein and serial pelvic ultrasounds are mandatory to exclude recurrence of the disease.

2.10 Renal Anomalies

Urogenital abnormalities are among the commonest disorders seen in the perinatal period and account for almost 20% of all prenatally diagnosed anomalies. The routine use of antenatal ultrasound scans has resulted in the early detection of these conditions and in selected cases has led to the development of management strategies including fetal intervention aimed at preservation of renal function. Two major issues are the indications for intervention in bladder outlet obstruction and early pyeloplasty in infancy in cases with hydronephrosis.

Prenatal evaluation of a dilated urinary tract is based on serial ultrasound scans as well as measurement of urinary electrolytes. Ultrasonography provides measurements of the renal pelvis, assessment of the renal parenchyma as well as the detection of cysts

in the cortex. In severe disease, lack of amniotic fluid may make ultrasound assessment of the renal tract difficult and MRI may be helpful. Oligohydramnios is indicative of poor renal function and poor prognosis owing to the associated pulmonary hypoplasia. Urogenital anomalies co-exist with many other congenital abnormalities and amniocentesis should be offered in appropriate cases. It is estimated that 3% of infants will have an abnormality of the urogenital system and half of these will require some form of surgical intervention.

2.10.1 Upper Urinary Tract Obstruction

Antenatal hydronephrosis accounts for 0.6–0.65% pregnancies. The most common cause of prenatal hydronephrosis is pelvi-ureteric junction obstruction (PUJ), others being transient hydronephrosis, physiological hydronephrosis, multicystic kidney, posterior urethral valves, ureterocele, ectopic ureter, etc. The prognosis of antenatally diagnosed hydronephrosis in unilateral disease and in renal pelvic diameter of <10mm is excellent. Spontaneous resolution is noted in 20% of patients at birth and 80% at 3 years of age. Only 17% of prenatally diagnosed hydronephrosis need surgical intervention. Post-natal management of hydronephrosis requires ultrasound at birth and at 1 month of age, and further evaluation with radiology and scintigraphy if an abnormality is suspected. The non-operative treatment of antenatally detected hydronephrosis has been carefully monitored over a 17-year period, and from an analysis of six patient series the conclusion is that this approach is safe.

2.10.2 Lower Urinary Tract Obstruction

Posterior urethral valves (PUV) are the most common cause for lower urinary tract obstruction in boys with an incidence of 1 in 2,000 to 4,000 live male births. The diagnosis of PUV is suspected on the pre-natal ultrasound finding of bilateral hydronephrosis associated with a thickened bladder and decreased amniotic fluid volume. Serial fetal urine analysis may provide prognostic information on renal function.

Prenatal diagnosis for patients with PUV is a poor prognostic sign with 64% incidence of renal failure and transient pulmonary failure, compared to 33% in the postnatally diagnosed patients. Pulmonary hypoplasia secondary to oligohydramnios largely contributes to the morbidity and mortality from fetal urethral obstruction. Outcomes of fetal intervention with vesicoamniotic shunting or fetal cystoscopic ablation of urethral valve are still under review and await a multi-center trial.

Postnatal management includes ultrasound confirmation of the diagnosis, bladder drainage via a suprapubic or urethral route and contrast imaging of the urethra. Primary PUV ablation, vesicostomy or ureterostomy are postnatal surgical options. The overall outcome from this disease is unfavourable.

2.11 Conclusion

The boundaries of paediatric surgical practice have been extended by prenatal diagnosis. The care of patients with surgically correctable defects can now be planned prenatally with the collaborative effort of obstetricians, geneticists, neonatologists and paediatric surgeons. The understanding of the specific surgical condition's prenatal

natural history, the limitations of prenatal diagnosis, the detection of associated anomalies, the risks and indications of fetal intervention programmes and postnatal outcomes are essential to prenatal counselling. Prenatal counselling is an essential component of paediatric surgical practice and should be ensured in the training programme for future paediatric surgeons.

Further Reading

- Black R, Boyd P (2004) What's new in prenatal diagnosis? *Trends Urol Gynaecol Sex Health* 9:9–11
- Boyd PA, Keeling JW (2007) Congenital abnormalities, prenatal diagnosis and screening. In JW Keeling (ed) *Fetal and Neonatal Pathology*, 4th edn. Springer-Verlag, New York
- Harrison MR (2006) The fetus as a patient. In JL Grosfeld, JA O'Neill, EW Fonkalsrud, AG Coran (eds) *Pediatric Surgery*. Mosby, Philadelphia, pp 77–88
- Lakhoo K (2007) Fetal counselling for congenital malformations. *PSI* 23:509–519
- Lakhoo K et al (2006) Best clinical practice: surgical conditions of the fetus and newborn. *Early Hum Dev* 82(5):281–324
- Puri P, Höllwarth ME (eds) (2006) *Pediatric Surgery*. Springer, Berlin, Heidelberg
- Sylvester K, Albanese CT (2005) The fetus as a patient. In KT Oldham, PM Colombani, RP Foglia, MA Skinner, (eds) *Principles and Practice of Pediatric Surgery*. Lippincott Williams & Wilkins, Philadelphia, PA, pp 27–47



<http://www.springer.com/978-3-540-69559-2>

Pediatric Surgery

Diagnosis and Management

Puri, P.; Höllwarth, M.E. (Eds.)

2009, XXIV, 998 p., Hardcover

ISBN: 978-3-540-69559-2