

Oropharynx:

Epidemiology and Treatment Outcome

EDITH FILION and QUYNH-THU LE

CONTENTS

2.1	Introduction	16
2.2	Epidemiology	16
2.3	Staging	17
2.3.1	The Role of ¹⁸ Fluoro Deoxy-Glucose Positron Emission Topography in OPSCC Management	17
2.4	Treatment by Stages	18
2.4.1	Early Stage (Stages I–II)	18
2.4.2	Locally Advanced Stage (Stages III–IV)	19
2.4.2.1	Surgery and Adjuvant Radiotherapy vs. Radiotherapy or Chemoradiotherapy	19
2.4.2.2	Radiation Fractionation	19
2.4.2.3	Chemotherapy and Radiation Therapy	19
2.4.2.4	Targeted Therapy	20
2.4.2.5	Postoperative Treatment: Radiation and Chemoradiation	20
2.5	Radiation Therapy Technique: Three-Dimensional Conformal Radiation Therapy vs. Intensity-Modulated Radiotherapy	21
2.6	Treatment-Related Toxicities	22
2.6.1	Acute Toxicities	22
2.6.2	Late Toxicities	23
2.7	Conclusion	26
	Abbreviations	26
	References	26

KEY POINTS

- Oropharyngeal (OP) carcinoma comprises over half of all head and neck cancers in the United States.
- While the incidence of squamous cell carcinoma (SCC) in the other head and neck sites has been steadily declining in association with smoking cessation, the incidence of SCC in the OP is rising, especially in younger patients and has been linked to the exposure of the human papilloma-virus (HPV).
- The treatment of OP carcinoma is complex because of the intricate anatomy of the involved organs, their rich lymphatic networks, and their critical function in the activities of daily living. Such treatment therefore requires a multidisciplinary approach.
- This chapter focuses on the epidemiology of OP squamous cell carcinoma, specifically looking at the emerging role of HPV virus in their development.
- It also describes the different treatment options for these tumors with a focus on those for organ preservation.
- Finally, it highlights recent advances in treatment using molecularly targeted therapies and modern radiation delivery using intensity-modulated approach with the goal to minimize treatment-related toxicity in these highly curable patients.

EDITH FILION, MD
Department of Radiation Oncology, Stanford University Cancer
Center, 875 Blake Wilbur Drive, Stanford, CA 94305-5847, USA
QUYNH-THU LE, MD
Department of Radiation Oncology, Stanford University Cancer
Center, 875 Blake Wilbur Drive, Stanford, CA 94305-5847, USA

2.1

Introduction

Oropharynx squamous cell carcinoma (OPSCC) has emerged as one of the most common malignancies in the head and neck (HN) sites. Around 123,000 new cases of oropharyngeal (OP) cancers are estimated to occur annually worldwide, resulting in 79,000 annual deaths (PARKIN et al. 2001). In the United States, the incidence of OP cancers in 2008 is estimated to be 35,310 new cases, from which 7,590 deaths will occur (JEMAL et al. 2008). The oropharynx, which comprises of the soft palate, uvula, tonsillar fossa and pillars, glossotonsillar sulci, lateral and posterior pharyngeal wall, vallecula, and base of tongue, harbors a rich lymphatic network. Therefore, tumors arising from this region are likely to have early nodal involvement and ~60% of these patients present with stage III–IV tumors at diagnosis (GREENE et al. 2002). The treatment of OP cancers has evolved over time. Although either surgery or radiation therapy (RT) remains the main treatment modality for early-stage OP cancers, concurrent chemoradiation therapy (CRT) has largely replaced RT alone for locally advanced neoplasms. Recent advances in RT techniques and molecular technologies have ushered in a new age of novel therapy for OP cancers, which holds promise for a better outcome with potentially less normal tissue toxicity. In this chapter, we will focus on the new developments in epidemiology and treatment approaches for OPSCC.

2.2

Epidemiology

The most common histology for OP tumors is squamous cell carcinoma (SCC). Established risk factors for these tumors include tobacco exposure (either directly or indirectly), alcohol consumption, genetic and environmental factors such as diet, poor oral hygiene, and RT exposure (ROSENQUIST 2005). A synergism between smoking and alcohol abuse has been described and could increase the relative risk of these cancers as much as 30-fold (CASTELLSAGUE et al. 2004). Marijuana consumption has also been linked to the development of OPSCC (ZHANG et al. 1999).

While the overall incidence of other HNSCC has been declining since the early 1980s because of smoking cessation, the incidence of OPSCC has either been stable or rising, especially in younger populations (ERNSTER et al. 2007; STURGIS and CINCIRIPINI 2007). This is due to the increasing number of OPSCC associated with human papillomavirus (HPV). Reports indicated that up to 50–60% of OPSCC might harbor HPV DNA, depending on the detection method used (GILLISON et al. 2000; GILLISON and SHAH 2001; MORK et al. 2001; DAI et al. 2004). HPV is most commonly found in tonsillar and base of tongue tumors, with HPV16 being found in the vast majority (>90%) (GILLISON et al. 2000; DAHLGREN et al. 2003). Evidence for the causal relationship between the presence of HPV and HNSCC incidence comes from prospective studies, indicating increased risk for developing HNSCC in patients who are seropositive for anti-HPV antibodies. In a large, nested case–control study from a Scandinavian cohort of almost 900,000 individuals, HPV-16 seropositivity was observed on the average of 9.4 years prior to the onset of disease and was associated with a 14-fold increased risk of OPSCC (MORK et al. 2001). Recent case–control studies suggest that HPV(+) and (–) tumors have distinct risk factor profile. While HPV(–) tumors had the traditional association with tobacco and alcohol use and poor oral hygiene, HPV(+) HNSCC was independently associated with marijuana exposure and several measures of sexual behavior (such as increasing numbers of lifetime vaginal or oral sex partners, casual sex participation, no barrier use during vaginal or oral sex, and history of a sexually transmitted disease) but not with tobacco or alcohol consumption (D'SOUZA et al. 2007; GILLISON et al. 2008).

Some studies have suggested that HPV-related OPSCC not only represents a molecularly distinct disease but is also associated with a better prognosis (GILLISON et al. 2000; FAKHRY et al. 2008; WEINBERGER et al. 2006; LICITRA et al. 2006). Figure 2.1 shows the disease-specific survival (DSS) curves for HPV(+) and (–) patients treated at our institution. A recent meta-analysis confirmed that HPV(+) OPSCC patients had a 28% lower risk of death than their negative counterparts (RAGIN and TAIOLI 2007). The reason for this difference in prognosis is unclear but could be related to the distinct molecular and epidemiologic profiles of these tumors. HPV(+) tumors are more likely to be undifferentiated, have basaloid histology, and more frequent nodal metastasis (FAKHRY and GILLISON 2006). At the molecular level, they

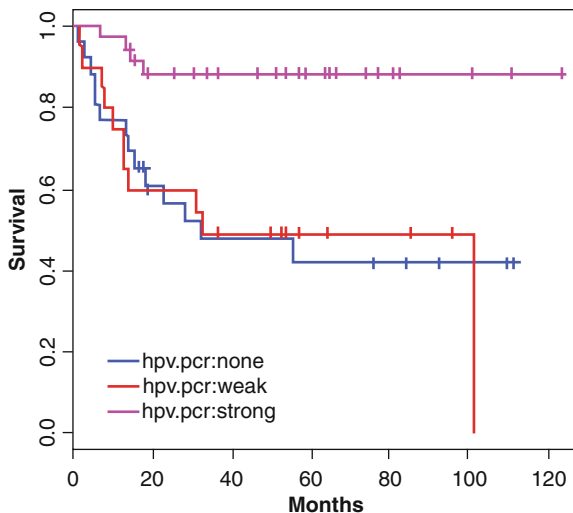


Fig. 2.1. Disease-specific survival for 82 HNSCC patients by HPV status as assessed by pyrosequencing at Stanford University. “HPV PCR none” reflects negative PCR amplification signal for HPV L1 gene ($n = 26$); “HPV PCR weak,” very weak PCR amplification signal ($n = 20$); “HPV PCR strong,” strong PCR amplification signal ($n = 36$); $p = 0.0005$

are more likely to be p53 wildtype and p16INK4a-positive (WEINBERGER et al. 2006; LICITRA et al. 2006; FAKHRY and GILLISON 2006). The intact apoptotic response to chemoradiation due to less p53 mutations and functional p16INK4a may explain the improved outcomes for HPV(+) tumors. Other hypotheses for improved outcomes include the lack of field cancerization and enhanced immune surveillance (FAKHRY and GILLISON 2006). Regardless of the underlying mechanism for improved outcome, such favorable prognosis would have significant implications for therapeutic management and posttreatment surveillance in patients with HPV(+) tumors.

2.3

Staging

Clinical staging is used for OPSCC. Evaluation is based on inspection/palpation of the tumor and neck nodes as well as nasopharyngoscopy. Radiologic assessment of the tumor should include at least a contrast enhanced computed tomography (CT) scan. Magnetic resonance imaging (MRI), which is often less sensitive to dental artefact than is CT, is useful

for assessment of the base of tongue, pterygoid muscles, skull base, and mandibular bone marrow. Panendoscopy is routinely done to determine the tumor extent and to rule out a synchronous second primary cancer. The American Joint Committee on Cancer cancer staging system is used worldwide to stage OPSCC for prognosis and treatment recommendations (GREENE et al. 2002).

2.3.1

The Role of ^{18}F Fluoro Deoxy-Glucose Positron Emission Topography in OPSCC Management

^{18}F Fluoro deoxy-glucose positron emission topography (FDG PET)/CT has become a widely used imaging modality for a variety of common malignancies, including OPSCC. The primary utility of FDG PET in OPSCC is for the detection of regional nodal and distant metastases. Several studies have established that FDG PET is superior to physical examination, and CT and MRI scans in determining the extent of involved nodes in patients with clinically enlarged nodes at diagnosis (ADAMS et al. 1998; STUCKENSEN et al. 2000; QUON et al. 2007; BRANSTETTER et al. 2005). In general, PET does not play a significant role in the characterization of the primary tumor except for aiding in the detection of the primary tumor site in patients presenting with nodal metastases from an unknown primary site (HANASONO et al. 1999; MENDA and GRAHAM 2005). In patients with clinically negative nodal (N0) involvement by clinical examination and CT or MRI, the role of PET in guiding elective neck treatment is uncertain because of its limited resolution and its unacceptably low sensitivity in detecting occult nodal metastases (HYDE et al. 2003; STOECKLI et al. 2002; SCHODER et al. 2006). In patients with more advanced tumors, PET is useful and superior to CT for detecting distant spread as well as synchronous tumors (SCHWARTZ et al. 2003; SCHMID et al. 2003; WAX et al. 2002). PET is also useful in determining response to chemotherapy and RT. However, several authors have described diminishing specificity in PET scans when performed within 3 months of RT (ANDRADE et al. 2006; PORCEDDU et al. 2005). Long-term surveillance may also be accomplished by FDG PET, where it has a higher sensitivity than CT alone.

Integrated FDG PET/CT imaging has provided a logical bridge between anatomical and functional imaging that appears ideally suited not only for

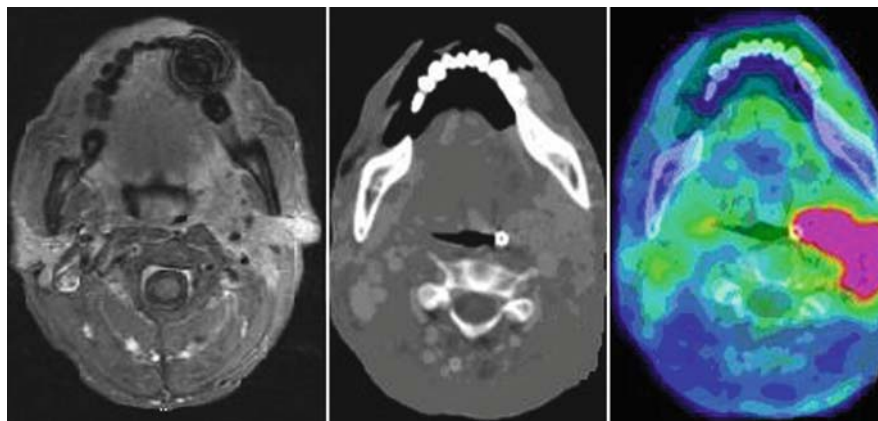


Fig. 2.2. An example of a treatment planning PET-CT scan with contrast in a patient with a T4aN2bM0 left tonsillar squamous cell carcinoma. The figure shows an axial slice across the tumor on a T1-weighted MRI scan with gadolinium, CT scan with contrast and merged PET-CT

diagnostic purposes but also for radiotherapy (RT) planning. PET data can be imported into workstations specific to RT treatment planning. Further, immobilization devices can be used during the acquisition of PET/CT scan in a similar fashion as when performed on dedicated CT scanners and can improve the registration of PET and CT images. Figure 2.2 shows an example of a treatment planning PET-CT scan. Several reports have noted that target volumes may be modified in as many as 20% of cases when using FDG PET/CT vs. CT alone (CIERNIK et al. 2003; AHN and GARG 2008). The target volume may increase in some cases, where the viable tumor fraction is larger than previously noted or smaller, particularly in bulky tumors where the fraction of necrosis may be quite large. These changes in RT planning are in addition to the changes already brought on by the detection of unexpected metastatic disease using PET. Accordingly, PET/CT is commonly used as an adjunctive examination for radiation treatment planning for HN cancers at our institution. Preliminary outcome data from a series of 42 HNSCC patients suggested that the use of FDG PET for RT treatment planning resulted in a high level of disease control combined with favorable toxicity profiles (VERNON et al. 2008). A study from our institution with 82 HNSCC, of which 45 were from the oropharynx, indicated that high metabolic tumor burden as measured by total metabolic tumor volume (MTV, semi-automatically delineated on pretreatment PET scans using a custom software) or total tumor burden (defined as the product of MTV and median standard uptake value) is an adverse prognostic factor for disease recurrence and death in these patients (LA et al. 2008). However, since there is still scant outcome data and nonstandardization of contouring methods, PET/CT is not recommended

as a prime means of treatment planning, but as an adjunct to contrast enhanced CT and/or MRI.

2.4

Treatment by Stages

Treatment of OPSCC is complex and requires participation of a multidisciplinary team. The extent of the cancer, TNM stages, pathologic findings, and the overall condition of the patient dictate the appropriate therapeutic plan. The main treatment modalities for OPSCC are surgery, radiotherapy, and chemotherapy. More recently, biologically targeted therapy has also emerged as an effective therapy for OPSCC.

2.4.1

Early Stage (Stages I–II)

Either surgery or definitive RT can effectively manage stages I–II OPSCC. The choice of treatment is dictated by functional and cosmetic considerations and the medical team expertise. Several reports have compared the results of surgery and RT and none have found any difference in outcomes between the two modalities (KRAMER et al. 1987; MENDENHALL et al. 2000a, b). The GETTEC group showed that surgery alone yielded a 5-year locoregional control (LRC) rate of 89%, DSS of 100%, and overall survival (OS) of 73% in 53 T1–2 N0 OPSCC (COSMIDIS et al. 2004). Similar results were achieved with definitive RT with a 5-year local control rate of 88% for T1 and 84% for T2 tonsillar carcinomas, and a 5-year DSS of 100% for stage I and 86% for stage

II tumors (MENDENHALL et al. 2006a). Analogous excellent results were also achieved with RT alone for early-stage base-of-tongue cancer with less functional morbidity (MENDENHALL et al. 2006a).

Patients with T1–2N0 tonsillar carcinoma with minimal base of tongue and soft palate involvement can be safely irradiated to the tumor bed and ipsilateral neck alone, thereby sparing the contralateral neck and parotid gland. O’Sullivan et al. reported a 3-year LRC rate of 77% and a contralateral neck failure rate of only 3.5% in 228 tonsillar carcinoma patients treated with ipsilateral neck irradiation alone. Specifically there was no contralateral neck failure in 118 patients with T1–2N0 tumor in that series (O’SULLIVAN et al. 2001). In patients with base-of-tongue, vallecula, or soft palate tumors that require bilateral neck treatment, intensity-modulated radiotherapy (IMRT, discussed in details below) can provide favorable outcomes with less xerostomia. GARDEN et al. (2007) reported a 2-year LRC, recurrence-free, and OS rates of 94, 88, and 94%, respectively, for 51 patients receiving IMRT treatment for T1–2 OPSCC. More important, they were able to achieve a mean dose of <30 Gy to at least one parotid gland in 95% of their patients, thereby preserving some salivary function.

2.4.2

Locally Advanced Stage (Stages III–IV)

2.4.2.1

Surgery and Adjuvant Radiotherapy vs. Radiotherapy or Chemoradiotherapy

Stages III–IV OPSCC can be treated with either surgery and RT or concurrent chemoradiation therapy (CRT). RTOG 73-03 randomized 129 patients with oropharynx and oral cavity SCC to (1) preoperative RT (50 Gy) followed by surgery, (2) surgery followed by postoperative RT (60 Gy), or definitive RT alone (65–70 Gy). There was no significant difference in between the three arms in terms of LRC or OS; however, the study was significantly underpowered to address that question (TUPCHONG et al. 1991). More recently, SOO et al. reported on a phase III randomized study, comparing cisplatin and 5-fluoruracil (5-FU) based CRT vs. surgery and postoperative RT in 119 patients with locally advanced but resectable HNSCC, among whom 21% had OP primaries. The trial was closed prematurely before the targeted accrual of 200 patients because of poor enrolment.

There was no significant difference in survival between the two groups and organ preservation was achieved in 55% of the OPSCC group (Soo et al. 2005).

2.4.2.2

Radiation Fractionation

For many years, RT alone was the main treatment modality for the majority of these patients, mainly for organ preservation. RT treatment intensification with altered fractionation such as accelerated fractionation or hyperfractionation has resulted in improved LRC and disease-free survival. EORTC 22791 randomized 325 patients with T2–3 N0–1 OPSCC to either conventional fractionation (70, 2 Gy/fraction/day over 7 weeks) or hyperfractionation (80.5, 1.15 Gy twice daily [b.i.d.] over 7 weeks) (HORIOT et al. 1992). There was a significant improvement in 5-year LRC rate (40 vs. 60%, $p = 0.02$). Specifically, patients with T3 tumors had a trend for higher 5-year survival (30 vs. 40%, $p = 0.08$) if treated with hyperfractionation. RTOG 90-03 randomized 1,113 patients with locally advanced HNSCC, of whom 60% had OP primaries, to (1) standard fractionation (70 Gy/35 fractions/7 weeks), (2) hyperfractionation (81.6 Gy/68 fractions/7 weeks), (3) split-course accelerated fractionation (67.2 Gy/42 fractions/6 weeks), and (4) concomitant boost accelerated fractionation (72 Gy/42 fractions/6 weeks) (Fu et al. 2000). Patients treated with hyperfractionation or concomitant boost accelerated fractionation had significantly higher LRC than those treated with conventional fractionation; however, there was no difference in OS. Although most randomized studies did not find a survival advantage with altered fractionation, a meta-analysis using individual patient data found an absolute 5-year survival benefit of 3.4% (hazard ratio, 0.92; 95% CI, 0.86–0.97; $p = 0.003$), favoring altered fractionation, with the largest survival advantage noted for hyperfractionation (8% at 5 years) (BOURHIS et al. 2006).

2.4.2.3

Chemotherapy and Radiation Therapy

Within the last decade, chemoradiation therapy (CRT) has become the main treatment for locally advanced OPSCC. GORTEC 94-01 randomized 226 patients with stages III–IV OPSCC to either conventional RT (70 Gy/7 weeks) or the same RT plus concurrent carboplatin and 5-FU chemotherapy. There was a significant improvement in LRC, disease-free, and overall survival, favoring the chemotherapy arm (CALAIS et al. 1999). The 5-year OS,

disease-free survival (DFS), and LRC rates were 22 vs. 16% ($p = 0.05$), 27 vs. 15% ($p = 0.01$), and 48 vs. 25% ($p = 0.002$) for CRT vs. RT arm, respectively (DENIS et al. 2004). Several other randomized studies that included all HNSCC, of which a large proportion of patient had OP primaries, also found a survival advantage with the addition of concurrent chemotherapy (BRIZEL et al. 1998; ADELSTEIN et al. 2003; JEREMIC et al. 1997; BUDACH et al. 2005). A meta-analysis of 10,826 patients with individual data confirmed an absolute 8% survival benefit with the addition of concurrent chemotherapy, with the largest benefit noted for cisplatin-based chemotherapy (PIGNON et al. 2000). These data established the role of CRT as the standard of care for locally advanced OPSCC.

As LRC improves with the addition of concurrent chemotherapy and more refined RT delivery techniques, a higher rate of distant metastasis has been observed in recent series (ARGIRIS et al. 2003). This provides a rationale for re-investigating induction chemotherapy in these patients. Phase 2 studies have shown that the addition of a taxane to a cisplatin/5-FU (PF) platform yielded promising results in unresectable HNSCC (PIGNON et al. 2004). Two large phase III studies in the USA and Europe, both included OPSCC patients and both using a taxane-platinum-5-FU (TPF) platform prior to definitive RT, reported positive survival results in comparison to induction PF. EORTC 24971/TAX 323 randomized 358 patients with unresectable pharyngeal cancer (46% OP) to either TPF or PF every 3 weeks for four cycles followed by RT alone in nonprogressing patients (VERMORKEN et al. 2007). The TPF group had a statistically superior progression-free and overall survival (11 vs. 8 months, 18.8 vs. 14.5 months). TAX 324 randomized 501 patients with HNSCC (52% OP) to three cycles of TPF or PF induction chemotherapy followed by CRT (weekly carboplatin) (POSNER et al. 2007). The estimated 3-year OS was 62 vs. 48%, favoring the TPF group. Patterns of failure study showed superior LRC for the TPF arm without any improvement in distant metastases. TPF was also better tolerated than PF in both studies. However, between 10 & 15% of TAX 323 and 21 & 25% of TAX 324 patients never completed RT as specified in the protocols. Therefore, the role of TPF induction chemotherapy in addition to CRT needs to be further tested in randomized studies and this question is presently being addressed in two international randomized trials.

2.4.2.4

Targeted Therapy

The area of targeted therapy in HNSCC is rapidly growing. A correlative study of RTOG 90-03 showed that overexpression of the epidermal growth factor receptor (EGFR) was an independent predictor of poorer LCR and OS after conventionally fractionated RT (ANG et al. 2002). This preclinical data provided the rationale for a phase III randomized study, comparing RT alone to RT plus cetuximab, an anti-EGFR antibody in 424 patients with locally advanced HNSCC (BONNER et al. 2006). The addition of cetuximab to RT resulted in superior 2-year LCR (50 vs. 41%, $p = 0.005$), progression-free survival (46 vs. 37%, $p = 0.006$) and OS (55 vs. 45%, $p = 0.03$). Subset analysis revealed that patients with OPSCC had the most survival benefit (hazard ratio of 0.62) compared with other sites. Based on these positive findings and the fact that CRT is the currently most accepted treatment approach for patients with stage III–IV HNSCC, a large randomized study (RTOG 0522) has been mounted comparing cisplatin-based CRT alone to the same regimen with cetuximab. This study will address the role of adding cetuximab to standard CRT in HNSCC.

2.4.2.5

Postoperative Treatment: Radiation and Chemoradiation

Well-accepted indications for postoperative radiation therapy (PORT) in patients with OPSCC include T3–4 tumor, multiple pathological nodal involvement (≥ 2 nodes), extracapsular nodal extension (ECE), involved surgical margins, perineural invasion, dermal involvement, and lymphovascular involvement (ANG et al. 2001). A small percentage of patients with clinical stage I–II and most patients with stage III–IV OPSCC will therefore require PORT for these high-risk features if they receive surgery as the initial treatment. It is strongly recommended that PORT be started within 3–6 weeks of surgery. Two large studies indicated that the package time, defined as the time from surgery to the date of PORT completion, should be kept as short as possible in patients with high-risk features (ANG et al. 2001; SANGUINETI et al. 2005). The best LCR and survival was observed for patients with package time <11 weeks, intermediate for 11–13 weeks, and worst for >13 weeks (ANG et al. 2001).

A retrospective analysis of patients treated with PORT on 2 RTOG studies suggests that those who

had one or more of the following features: (1) involved surgical margin, (2) ECE, or (3) ≥ 2 involved node, fared poorly despite appropriate PORT treatment (AL-SARRAF et al. 1998). A small randomized study from France showed that the addition of weekly cisplatin to PORT in patients with ECE resulted in improved disease-free and overall survival (BACHAUD et al. 1996). This data prompted two large randomized studies from the USA (RTOG 95-01) and Europe (EORTC-22931), evaluating the role of cisplatin chemotherapy delivered concurrently with PORT in high-risk patients (COOPER et al. 2004; BERNIER et al. 2004). Although the treatment regimens are identical in both studies, the eligibility criteria were different, resulting in different patient profiles. Both studies showed a significant improvement in LRC and DFS with the addition of cisplatin to PORT in high-risk patients. However, only EORTC found a significant improvement in OS. Pooled analysis of patients in both studies showed that the patients who benefited the most from PORT and chemotherapy were those with ECE and/or involved surgical margins (BERNIER et al. 2005).

2.5

Radiation Therapy Technique: Three-Dimensional Conformal Radiation Therapy vs. Intensity-Modulated Radiotherapy

Intensity-modulated radiotherapy (IMRT) is a refinement of three-dimensional conformal radiation therapy. It utilizes a computerized treatment planning

system along with sophisticated delivery machinery to tailor the radiation dose to the tumor target. By subdividing a broad radiation beam into smaller pencil beams and by varying the intensities of these pencil beams, a conformal dose distribution is generated. Tumor coverage is improved and more normal tissue sparing is achieved. Although LRC rates for OPSCC treated with non-IMRT techniques are excellent, both parotid glands are almost always included in the RT portal. As a result, patients suffer from permanent xerostomia, which has a negative impact on nutrition, dentition, communication, and emotional well-being. With parotid-sparing IMRT, patients' quality of life has improved when compared with conventional RT (LIN et al. 2003). CHAO et al. (2001) showed that IMRT significantly reduced the rate of G2–3 xerostomia when compared with conventional RT in patients treated either definitively or postoperatively for OPSCC. We also evaluated the role of IMRT in improving salivary function by administering a validated xerostomia questionnaire to 29 representative IMRT-treated patients and 75 matched conventionally treated patients at the same institution. We found that IMRT-treated patients had less xerostomia (lower score) with the largest difference noted for patients with oral cavity and OP cancers (Fig. 2.3) (DALY et al. 2007).

Dose sculpting and parotid sparing raise a general concern for possible tumor misses with IMRT. However, no clinical reports to date have shown any compromise in local control for OP cancers treated with IMRT. With a median follow-up of 32 months, EISBRUCH et al. (2004) reported a 3-year LRC rate of 94% in 80 OP cancer patients. Over 90% of the patients had stage III or IV disease. CHAO et al.

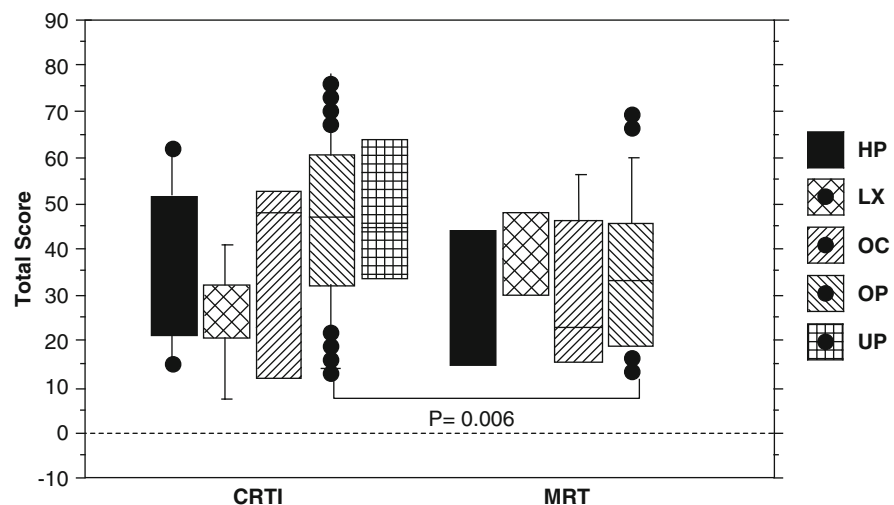


Fig. 2.3. Average xerostomia scores based on a validated xerostomia questionnaire in 29 representative IMRT-treated patients and 75 matched conventionally treated patients at the same institution. HP hypopharynx; LX larynx; OC oral cavity; OP oropharynx; UP unknown primary

Table 2.1. Results of IMRT for oropharyngeal carcinomas

References	N	Stage	Follow-up (months)	2-Year locoregional control (%)
CHAO et al. (2003)	74	I-IV	33	87
EISBRUCH et al. (2004)	80	I-IV	32	94
DE ARRUDA et al. (2006)	50	I-IV	24	92
HODGE et al. (2007)	52	I-IV	24	96
GARDEN et al. (2007)	51	I-IV ^a	45	93

^aPrimary tumor ≥ 4 cm in maximal dimension**Table 2.2.** Dose constraint guidelines for target volume and organ at risk (Adapted and modified from RTOG protocols)

Organ/volume	Constraints	Mean dose
Brachial plexus	≥ 60 Gy to any point	NS
Brainstem	< 54 Gy	NS
Larynx	NS	< 45 Gy
Mandible	< 70 Gy if no possible then no more than 1 cm^3 to exceed 75 Gy	NS
Oral cavity	NS	< 40 Gy
Parotid	At least 20 cm^3 of the combined volume of both parotid < 20 Gy or at least 50% of the volume of one parotid < 30 Gy	≥ 26 Gy (at least one gland)
Postcricoid pharynx	NS	< 45 Gy
Spinal cord	< 48 Gy to any volume larger than 0.03 cm^3	NS
Unspecified tissue outside the target volume	$\geq 5\%$ can receive greater than the dose to CTV ^a	NS
PTV ^b	No more than 20% will receive $> 100\%$ of the prescribed dose No more than 1% will receive $< 93\%$ of the prescribed dose No more than 1% or 1 cm^3 of the tissue outside the PTV will receive $> 110\%$ of the prescribed dose	NS

NS not specified

^aClinical target volume^bPlanning target volume

(2004) reported a local control rate of 87% using IMRT in 74 patients with OP cancer. In this report, 46% had T3/T4 tumors and 76% of the patients had stage III/IV disease. Other centers also reported excellent LRC rates. De Arruda et al. (2006) noted a 100% tumor control rate at a median follow-up of 24 months. An update with a median follow-up of 31 months continues to show excellent local control in this patient cohort (LEE et al. 2006). Table 2.1 shows a summary of IMRT results for OPSCC. A multi-institutional RTOG study, H-0022, using IMRT for early-stage OP cancer has completed accrual. The protocol tests the transportability of IMRT to multiple institutions. Preliminary results have been presented at an American Society of Therapeutic Radiation Oncology (ASTRO) meeting showing low IMRT violation rates and reduced xerostomia when compared with historical controls (EISBRUCH et al. 2006). This protocol also provides useful dose constraint guidelines for target volume and organ (Table 2.2). Figure 2.4 shows an example of an IMRT plan for an OP cancer.

2.6

Treatment-Related Toxicities

2.6.1 Acute Toxicities

The most common acute RT-related toxicities include dermatitis, taste impairment, pain, weight loss, and fatigue, with mucositis being perhaps the most debilitating side effect. The addition of concurrent chemotherapy has been shown to enhance mucositis (CALAIS et al. 1999). Care must be taken to minimize these incapacitating side effects. Smoking cessation is a must as studies have shown that cigarette smoking can increase the severity and the duration of the mucosal reactions and interfere with oncologic outcome if continued during RT (BROWMAN et al. 1993). Clinical practice guidelines exist for the prevention and management of oral mucositis (KEEFE et al. 2007). These include meticulous, systematic oral care hygiene with brushing, flossing, bland rinses and moisturizer, regular assessment of oral pain, early intervention with topical and systemic analgesics to promote oral comfort and involvement of a multidisciplinary team (nurses, physician, dentist, nutritionist).

Several agents have been shown to be promising in reducing mucositis in small phase II or observational studies, only to be negated in large randomized phase III trials. These include sucral-fate (DODD et al. 2003), antimicrobial lozenges (TROTTI et al. 2004; EL-SAYED et al. 2002), amifostine (BUENTZEL et al. 2006; BRIZEL et al. 2000), GMCSF (RYU et al. 2007), pilocarpine (SCARANTINO et al. 2006; WARDE et al. 2002) and aloe vera (SU et al. 2004). The use of zinc sulfate during RT may reduce severe mucositis as suggested by two small trials, but needs to be confirmed in a larger setting (ERTEKIN et al. 2004; LIN et al. 2006). A comprehensive review of the oral mucositis trials has been performed by the Cochrane Group (WORTHINGTON et al. 2007).

Recently, palifermin (@Kepivance), a recombinant human keratinocyte growth factor, has been shown to reduce the duration and severity of oral mucositis after intensive chemotherapy and RT in preparation for autologous hematopoietic stem cell transplantation in patients with hematologic malignancies (SPIELBERGER et al. 2004). It has also been shown to reduce the incidence of WHO II or higher oral mucositis in patients with metastatic colorectal cancer treated with 5-FU-based chemotherapy in a small randomized study (ROSEN et al. 2006). These results prompted a few randomized trials in HNSCC, two for patients receiving definitive CRT and one for patients receiving postoperative CRT for high-risk features. Two studies have been completed and one is still accruing patients. The results of these studies will define the role of palifermin in the management of oral mucositis in HNSCC.

2.6.2

Late Toxicities

Late toxicities, though less common, can be irreversible and unpredictable; therefore application of preventive measures and vigilant surveillance for these toxicities are critical. A higher incidence of aspiration has been noted with treatment intensification. Between a third to half of the patients treated for locally advanced OPSCC develop silent aspiration and up to a third have severe dysphagia after therapy (NGUYEN et al. 2007, 2008). Swallowing therapy during and after treatment can be effective in minimizing dysphagia and reduce the need for tube feedings (NGUYEN et al. 2007). Dose distribution studies have suggested a correlation between

aspiration/dysphagia symptoms and RT dose to the pharyngeal constrictors and supraglottic larynx (FENG et al. 2007; EISBRUCH et al. 2007). These observed dose-response relationships suggest that reducing the doses to these structures with either IMRT or brachytherapy may help to minimize the development of long-term dysphagia.

A common late toxicity is xerostomia due to RT damages to the salivary gland tissues. As indicated above, IMRT has been shown to be superior to conventional therapy in preserving salivary function in OPSCC patients without compromising tumor curability. Since parotid function has been shown to substantially decrease after a mean dose of >26 Gy, the recommendation is to limit the mean dose of one gland to <26 Gy for preservation of stimulated saliva (EISBRUCH et al. 1999, 2003). As the submandibular glands are responsible for basal saliva secretion, there is increasing interest to also minimize the dose to these glands. MURDOCH-KINCH et al. (2008) showed that above a mean dose of 39 Gy, there is no recovery in submandibular gland function, whereas recovery over time was noted when mean dose was kept below 39 Gy. These results have identified a threshold dose for submandibular glands; however, extreme caution must be exercised when sparing the submandibular gland to ensure no tumor misses due to the gland's proximity to the level II nodes.

In addition to IMRT, the addition of intravenous amifostine to conventional RT has been shown to reduce acute side effects and xerostomia in a large randomized study of 315 HNSCC (BRIZEL et al. 2000). However, the inconvenient route of administration, high cost of the drug, and daily IV infusion procedure, as well as associated side effects of nausea/vomiting, have limited its use.

An emerging late RT complication is carotid stenosis from neck irradiation. In a study of 40 patients treated with unilateral neck irradiation, ultrasound and CT angiography revealed more carotid stenosis and more high-grade stenosis in the irradiated neck compared with the untreated neck, especially for doses ≥ 50 Gy (MARTIN et al. 2005). These findings were substantiated in another study, which found that neck dissection also contributed to the increased risk of carotid stenosis (BROWN et al. 2005). Therefore, for long-term survivors after RT, especially for those who also had neck dissection, RT dose >50 Gy and/or symptomatic, ultrasonographic carotid artery screening should be considered.

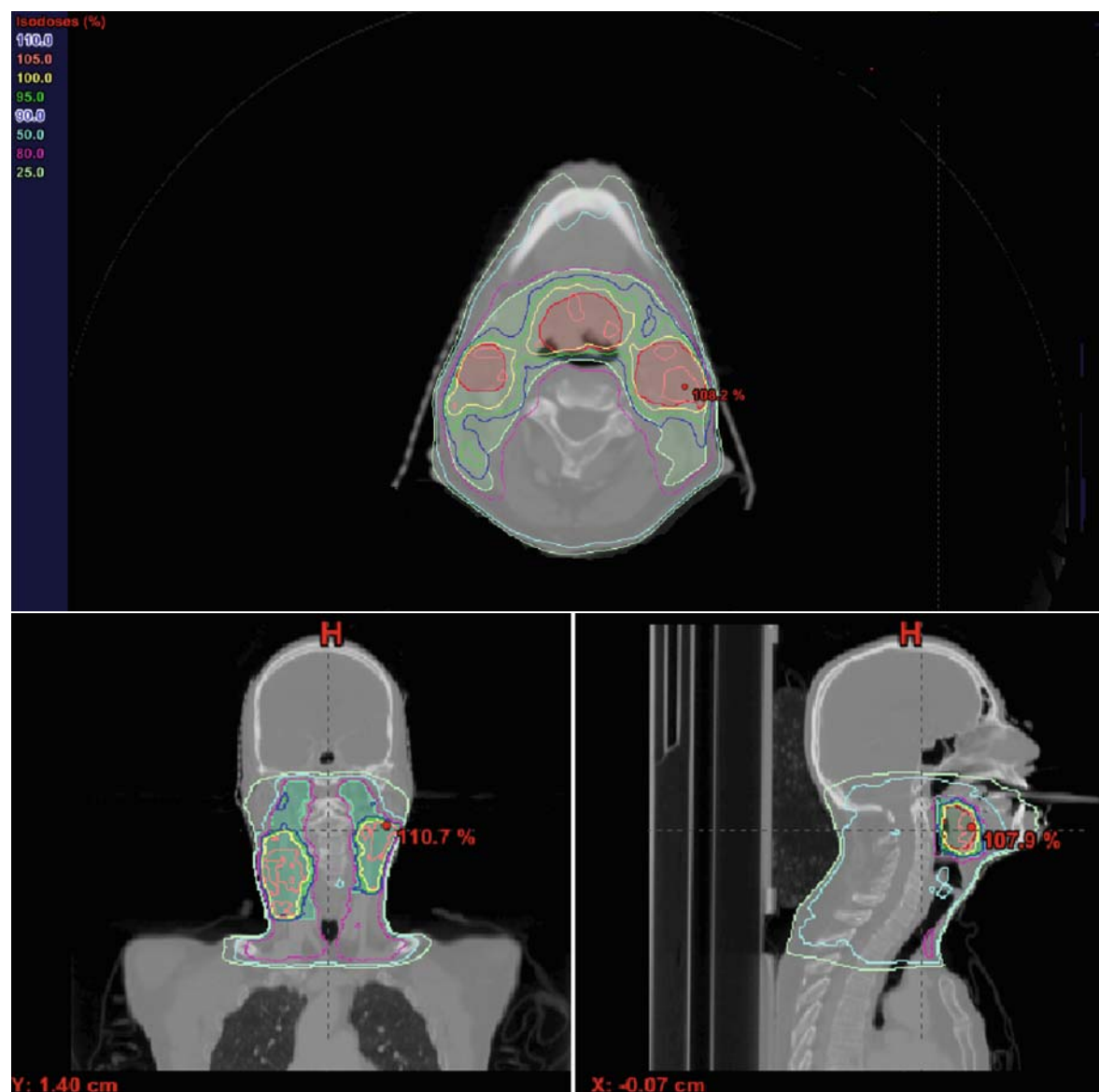


Fig. 2.4. An example of an IMRT plan for a patient with a T1N2cM0 right base of tongue squamous cell carcinoma. The figure shows an axial, coronal, and sagittal view of the plan. Dose-volume histogram and dose statistics are also included

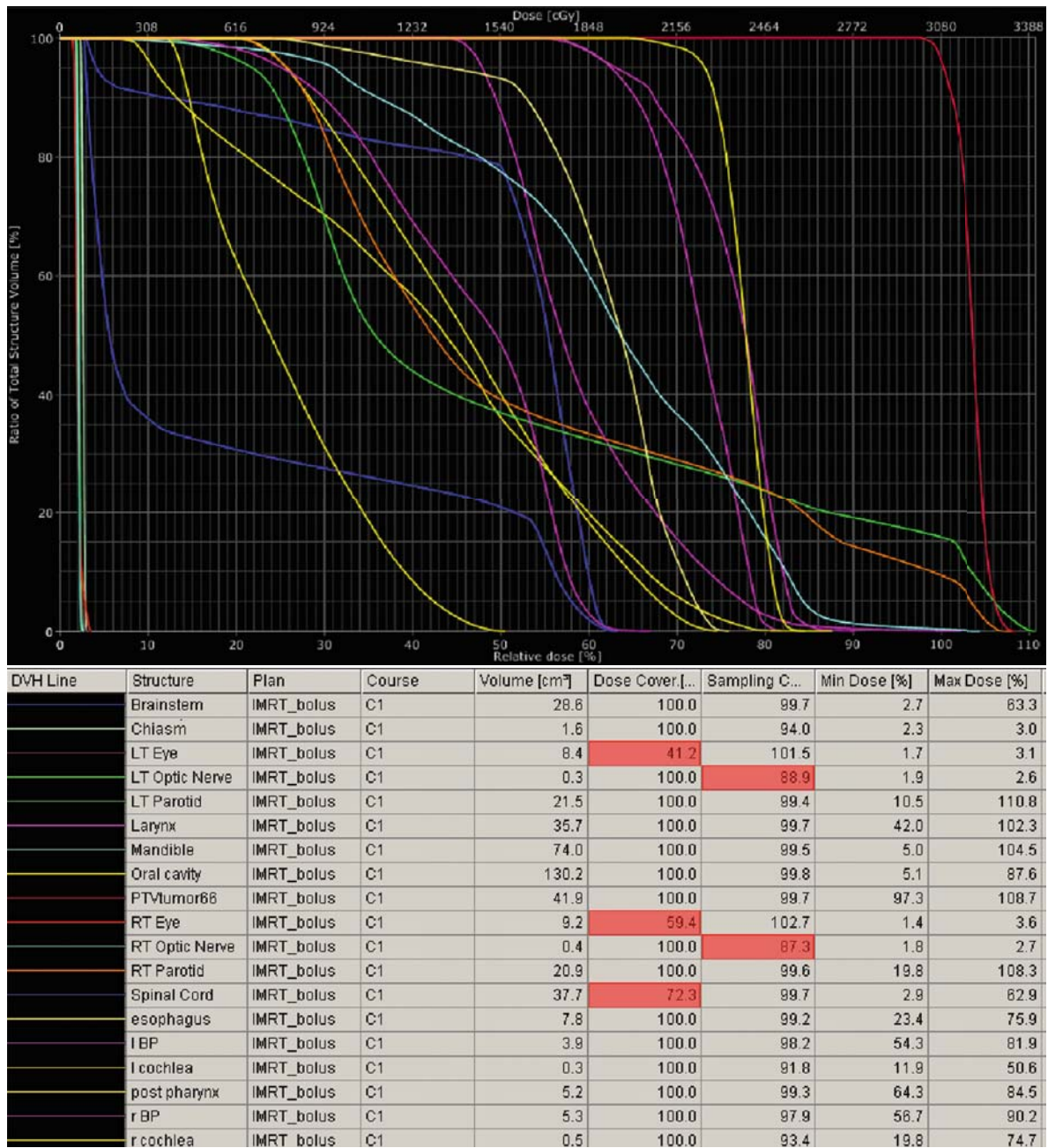


Fig. 2.4. Continued.

2.7

Conclusion

OPSCC is a highly curable cancer. The therapeutic options are expanding as more is learned about the molecular profiles and prognosis. Although standard treatments of OPSCC still consist of traditional therapeutic approaches such as surgery, RT, and chemotherapy, molecularly targeted therapy is becoming prominent in their management. Major advances in radiation delivery also hold promises of decreasing late toxicity and improving quality of life in these patients. Since HPV-related OPSCC is emerging as a new entity with distinct pathogenesis, molecular profile, and highly favorable prognosis, it is now time to conduct separate clinical trials for these tumors to avoid overtreating many of these patients.

Abbreviations

AJCC	American Joint Committee on Cancer
ASTRO	American Society of Therapeutic Radiation Oncology
CRT	Chemoradiation therapy
CT	Computed tomography scan
DFS	Disease-free survival
DSS	Disease-specific survival
ECE	Extracapsular nodal extension
EGFR	Epidermal growth factor receptor
FDG PET	Fluoro deoxy glucose positron emission tomography
HN	Head and neck
HPV	Human papillomavirus
IMRT	Intensity modulated radiotherapy
LRC	Locoregional control
MRI	Magnetic resonance imaging
MTV	Metabolic tumor volume
OP	Oropharynx
OS	Overall survival
OPSCC	Oropharynx squamous cell carcinoma
PF	Cisplatin/5-FU
PORT	Postoperative radiation therapy
RT	Radiation therapy
SCC	Squamous cell carcinoma
SUV	Standard uptake value
TPF	Taxane-platinum-5-FU
WHO	World health organization
3DCRT	3-Dimensional conformal radiation therapy
5-FU	5-Fluorouracil

References

- Adams S, Baum RP, Stuckensen T et al. (1998) Prospective comparison of 18F-FDG PET with conventional imaging modalities (CT, MRI, US) in lymph node staging of head and neck cancer. *Eur J Nucl Med* 25:1255–1260
- Adelstein DJ, Li Y, Adams GL et al. (2003) An intergroup phase III comparison of standard radiation therapy and two schedules of concurrent chemoradiotherapy in patients with unresectable squamous cell head and neck cancer. *J Clin Oncol* 21:92–98
- Ahn PH, Garg MK (2008) Positron emission tomography/computed tomography for target delineation in head and neck cancers. *Semin Nucl Med* 38:141–148
- Al-Sarraf M, LeBlanc M, Giri PG et al. (1998) Chemoradiotherapy versus radiotherapy in patients with advanced nasopharyngeal cancer: a phase III randomized intergroup study 0099. *J Clin Oncol* 16:1310–1317
- Andrade RS, Heron DE, Degirmenci B et al. (2006) Posttreatment assessment of response using FDG-PET/CT for patients treated with definitive radiation therapy for head and neck cancers. *Int J Radiat Oncol Biol Phys* 65:1315–1322
- Ang KK, Berkey BA, Tu X et al. (2002) Impact of epidermal growth factor receptor expression on survival and pattern of relapse in patients with advanced head and neck carcinoma. *Cancer Res* 62:7350–7356
- Ang KK, Trotti A, Brown BW et al. (2001) Randomized trial addressing risk features and time factors of surgery plus radiotherapy in advanced head-and-neck cancer. *Int J Radiat Oncol Biol Phys* 51(3):571–578
- Argiris A, Haraf DJ, Kies MS et al. (2003) Intensive concurrent chemoradiotherapy for head and neck cancer with 5-Fluorouracil- and hydroxyurea-based regimens: reversing a pattern of failure. *Oncologist* 8:350–360
- Bachaud JM, Cohen-Jonathan E, Alzieu C et al. (1996) Combined postoperative radiotherapy and weekly cisplatin infusion for locally advanced head and neck carcinoma: final report of a randomized trial. *Int J Radiat Oncol Biol Phys* 36:999–1004
- Bernier J, Cooper JS, Pajak TF et al. (2005) Defining risk levels in locally advanced head and neck cancers: a comparative analysis of concurrent postoperative radiation plus chemotherapy trials of the EORTC (#22931) and RTOG (# 9501). *Head Neck* 27:843–850
- Bernier J, Dommene C, Ozsahin M et al. (2004) Postoperative irradiation with or without concomitant chemotherapy for locally advanced head and neck cancer. *N Engl J Med* 350:1945–1952
- Bonner JA, Harari PM, Giralt J et al. (2006) Radiotherapy plus cetuximab for squamous-cell carcinoma of the head and neck. *N Engl J Med* 354:567–578
- Bourhis J, Overgaard J, Audry H et al. (2006) Hyperfractionated or accelerated radiotherapy in head and neck cancer: a meta-analysis. *Lancet* 368:843–854
- Branstetter Bft, Blodgett TM, Zimmer LA et al. (2005) Head and neck malignancy: is PET/CT more accurate than PET or CT alone? *Radiology* 235:580–586
- Brizel DM, Albers ME, Fisher SR et al. (1998) Hyperfractionated irradiation with or without concurrent chemotherapy for locally advanced head and neck cancer. *N Engl J Med* 338:1798–1804

- Brizel DM, Wasserman TH, Henke M et al. (2000) Phase III randomized trial of amifostine as a radioprotector in head and neck cancer. *J Clin Oncol* 18:3339–3345
- Browman GP, Wong G, Hodson I et al. (1993) Influence of cigarette smoking on the efficacy of radiation therapy in head and neck cancer. *N Engl J Med* 328:159–163
- Brown PD, Foote RL, McLaughlin MP et al. (2005) A historical prospective cohort study of carotid artery stenosis after radiotherapy for head and neck malignancies. *Int J Radiat Oncol Biol Phys* 63:1361–1367
- Budach V, Stuschke M, Budach W et al. (2005) Hyperfractionated accelerated chemoradiation with concurrent fluorouracil-mitomycin is more effective than dose-escalated hyperfractionated accelerated radiation therapy alone in locally advanced head and neck cancer: final results of the radiotherapy cooperative clinical trials group of the German Cancer Society 95-06 Prospective Randomized Trial. *J Clin Oncol* 23:1125–1135
- Buentzel J, Mücke O, Adamietz IA et al. (2006) Intravenous amifostine during chemoradiotherapy for head-and-neck cancer: a randomized placebo-controlled phase III study. *Int J Radiat Oncol Biol Phys* 64:684–691
- Calais G, Alfonsi M, Bardet E et al. (1999) Randomized trial of radiation therapy versus concomitant chemotherapy and radiation therapy for advanced-stage oropharynx carcinoma. *J Natl Cancer Inst* 91:2081–2086
- Castellsague X, Quintana MJ, Martinez MC et al. (2004) The role of type of tobacco and type of alcoholic beverage in oral carcinogenesis. *Int J Cancer* 108:741–749
- Chao KS, Majhail N, Huang CJ et al. (2001) Intensity-modulated radiation therapy reduces late salivary toxicity without compromising tumor control in patients with oropharyngeal carcinoma: a comparison with conventional techniques. *Radiat Oncol* 61:275–280
- Chao KS, Ozyigit G, Blanco AI et al. (2004) Intensity-modulated radiation therapy for oropharyngeal carcinoma: impact of tumor volume. *Int J Radiat Oncol Biol Phys* 59:43–50
- Chao KS, Ozyigit G, Tran BN et al. (2003) Patterns of failure in patients receiving definitive and postoperative IMRT for head-and-neck cancer. *Int J Radiat Oncol Biol Phys* 55:312–321
- Ciernik IF, Dizendorf E, Baumert BG et al. (2003) Radiation treatment planning with an integrated positron emission and computer tomography (PET/CT): a feasibility study. *Int J Radiat Oncol Biol Phys* 57:853–863
- Cooper JS, Pajak TF, Forastiere AA et al. (2004) Postoperative concurrent radiotherapy and chemotherapy for high-risk squamous-cell carcinoma of the head and neck. *N Engl J Med* 350:1937–1944
- Cosmidis A, Rame JP, Dassonville O et al. (2004) T1-T2 NO oropharyngeal cancers treated with surgery alone. A GETTEC study. *Eur Arch Otorhinolaryngol* 261:276–281
- D'Souza G, Kreimer AR, Viscidi R et al. (2007) Case-control study of human papillomavirus and oropharyngeal cancer. *N Engl J Med* 356:1944–1956
- Dahlgren L, Mellin H, Wangsa D et al. (2003) Comparative genomic hybridization analysis of tonsillar cancer reveals a different pattern of genomic imbalances in human papillomavirus-positive and negative tumors. *Int J Cancer* 107:244–249
- Dai M, Clifford GM, le Calvez F et al. (2004) Human papillomavirus type 16 and TP53 mutation in oral cancer: matched analysis of the IARC multicenter study. *Cancer Res* 64:468–471
- Daly ME, Lieskovsky Y, Pawlicki T et al. (2007) Evaluation of patterns of failure and subjective salivary function in patients treated with intensity modulated radiotherapy for head and neck squamous cell carcinoma. *Head Neck* 29:211–220
- de Arruda FF, Puri DR, Zhung J et al. (2006) Intensity-modulated radiation therapy for the treatment of oropharyngeal carcinoma: the Memorial Sloan-Kettering Cancer Center experience. *Int J Radiat Oncol Biol Phys* 64:363–373
- Denis F, Garaud P, Bardet E et al. (2004) Final results of the 94-01 French Head and Neck Oncology and Radiotherapy Group randomized trial comparing radiotherapy alone with concomitant radiochemotherapy in advanced-stage oropharynx carcinoma. *J Clin Oncol* 22:69–76
- Dodd MJ, Miaskowski C, Greenspan D et al. (2003) Radiation-induced mucositis: a randomized clinical trial of micronized sucralfate versus salt & soda mouthwashes. *Cancer Invest* 21:21–33
- Eisbruch A, Dawson LA, Kim HM et al. (1999) Conformal and intensity modulated irradiation of head and neck cancer: the potential for improved target irradiation, salivary gland function, and quality of life. *Acta Otorhinolaryngol Belg* 53 271–275
- Eisbruch A, Harris J, Garden A et al. (2006) Phase II Multi-Institutional Study of IMRT for oropharyngeal cancer (RTOG 00-22): early results. American Society of Therapeutic Radiology and Oncology, PA. *Int J Radiat Oncol Biol Phys* 66:S46–S47; Abstract 79
- Eisbruch A, Levendag PC, Feng FY et al. (2007) Can IMRT or brachytherapy reduce dysphagia associated with chemoradiotherapy of head and neck cancer? The Michigan and Rotterdam experiences. *Int J Radiat Oncol Biol Phys* 69:S40–S42
- Eisbruch A, Marsh LH, Dawson LA et al. (2004) Recurrences near base of skull after IMRT for head-and-neck cancer: implications for target delineation in high neck and for parotid gland sparing. *Int J Radiat Oncol Biol Phys* 59:28–42
- Eisbruch A, Ship JA, Dawson LA et al. (2003) Salivary gland sparing and improved target irradiation by conformal and intensity modulated irradiation of head and neck cancer. *World J Surg* 27:832–837
- El-Sayed S, Nabid A, Shelley W et al. (2002) Prophylaxis of radiation-associated mucositis in conventionally treated patients with head and neck cancer: a double-blind, phase III, randomized, controlled trial evaluating the clinical efficacy of an antimicrobial lozenge using a validated mucositis scoring system. *J Clin Oncol* 20:3956–3963
- Ernstner JA, Sciotto CG, O'Brien MM et al. (2007) Rising incidence of oropharyngeal cancer and the role of oncogenic human papilloma virus. *Laryngoscope* 117:2115–2128
- Ertekin MV, Koc M, Karslioglu I et al. (2004) Zinc sulfate in the prevention of radiation-induced oropharyngeal mucositis: a prospective, placebo-controlled, randomized study. *Int J Radiat Oncol Biol Phys* 58:167–174
- Fakhry C, Gillison ML (2006) Clinical implications of human papillomavirus in head and neck cancers. *J Clin Oncol* 24:2606–2611
- Fakhry C, Westra WH, Li S et al. (2008) Improved survival of patients with human papillomavirus-positive head and neck squamous cell carcinoma in a prospective clinical trial. *J Natl Cancer Inst* 100:261–269

- Feng FY, Kim HM, Lyden TH et al. (2007) Intensity-modulated radiotherapy of head and neck cancer aiming to reduce dysphagia: early dose-effect relationships for the swallowing structures. *Int J Radiat Oncol Biol Phys* 68:1289–1298
- Fu KK, Pajak TF, Trotti A et al. (2000) A Radiation Therapy Oncology Group (RTOG) phase III randomized study to compare hyperfractionation and two variants of accelerated fractionation to standard fractionation radiotherapy for head and neck squamous cell carcinomas: first report of RTOG 9003. *Int J Radiat Oncol Biol Phys* 48:7–16
- Garden AS, Morrison WH, Wong PF et al. (2007) Disease-control rates following intensity-modulated radiation therapy for small primary oropharyngeal carcinoma. *Int J Radiat Oncol Biol Phys* 67:438–444
- Gillison ML, D'Souza G, Westra W et al. (2008) Distinct risk factor profiles for human papillomavirus type 16-positive and human papillomavirus type 16-negative head and neck cancers. *J Natl Cancer Inst* 100:407–420
- Gillison ML, Koch WM, Capone RB et al. (2000) Evidence for a causal association between human papillomavirus and a subset of head and neck cancers. *J Natl Cancer Inst* 92:709–720
- Gillison ML, Shah KV (2001) Human papillomavirus-associated head and neck squamous cell carcinoma: mounting evidence for an etiologic role for human papillomavirus in a subset of head and neck cancers. *Curr Opin Oncol* 13:183–188
- Greene FL, Page DL, Fleming ID (2002) *AJCC cancer staging manual*, 6th edn. Springer, New York
- Hanasono MM, Kunda LD, Segall GM et al. (1999) Uses and limitations of FDG positron emission tomography in patients with head and neck cancer. *Laryngoscope* 109:880–885
- Hodge CW, Bentzen SM, Wong G et al. (2007) Are we influencing outcome in oropharynx cancer with intensity-modulated radiotherapy? an inter-era comparison. *Int J Radiat Oncol Biol Phys* 69:1032–1041
- Horiot JC, Le Fur R, N'Guyen T et al. (1992) Hyperfractionation versus conventional fractionation in oropharyngeal carcinoma: final analysis of a randomized trial of the EORTC cooperative group of radiotherapy. *Radiother Oncol* 25:231–241
- Hyde NC, Prvulovich E, Newman L et al. (2003) A new approach to pre-treatment assessment of the N0 neck in oral squamous cell carcinoma: the role of sentinel node biopsy and positron emission tomography. *Oral Oncol* 39:350–360
- Jemal A, Siegel R, Ward E, et al. (2008) Cancer statistics, 2008. *CA Cancer J Clin* 58:71–96
- Jeremic B, Shibamoto Y, Stanisavljevic B et al. (1997) Radiation therapy alone or with concurrent low-dose daily either cisplatin or carboplatin in locally advanced unresectable squamous cell carcinoma of the head and neck: a prospective randomized trial. *Radiother Oncol* 43:29–37
- Keefe DM, Schubert MM, Elting LS et al. (2007) Updated clinical practice guidelines for the prevention and treatment of mucositis. *Cancer* 109:820–831
- Kramer S, Gelber RD, Snow JB et al. (1987) Combined radiation therapy and surgery in the management of advanced head and neck cancer: final report of study 73–03 of the Radiation Therapy Oncology Group. *Head Neck Surg* 10:19–30
- La TH, Filion EJ, Turnbull BB et al. (2008) Metabolic tumor burden predicts for recurrence and death in head and neck cancer. *American Society of Therapeutic Radiology and Oncology*, Boston
- Lee NY, de Arruda FF, Puri DR et al. (2006) A comparison of intensity-modulated radiation therapy and concomitant boost radiotherapy in the setting of concurrent chemotherapy for locally advanced oropharyngeal carcinoma. *Int J Radiat Oncol Biol Phys* 66:966–974
- Licitra L, Perrone F, Bossi P et al. (2006) High-risk human papillomavirus affects prognosis in patients with surgically treated oropharyngeal squamous cell carcinoma. *J Clin Oncol* 24:5630–5636
- Lin A, Kim HM, Terrell JE et al. (2003) Quality of life after parotid-sparing IMRT for head-and-neck cancer: a prospective longitudinal study. *Int J Radiat Oncol Biol Phys* 57:61–70
- Lin LC, Que J, Lin LK et al. (2006) Zinc supplementation to improve mucositis and dermatitis in patients after radiotherapy for head-and-neck cancers: a double-blind, randomized study. *Int J Radiat Oncol Biol Phys* 65:745–750
- Martin JD, Buckley AR, Graeb D et al. (2005) Carotid artery stenosis in asymptomatic patients who have received unilateral head-and-neck irradiation. *Int J Radiat Oncol Biol Phys* 63:1197–1205
- Menda Y, Graham MM (2005) Update on 18F-fluorodeoxyglucose/positron emission tomography and positron emission tomography/computed tomography imaging of squamous head and neck cancers. *Semin Nucl Med* 35:214–219
- Mendenhall WM, Amdur RJ, Stringer SP et al. (2000a) Radiation therapy for squamous cell carcinoma of the tonsillar region: a preferred alternative to surgery? *J Clin Oncol* 18:2219–2225
- Mendenhall WM, Stringer SP, Amdur RJ et al. (2000b) Is radiation therapy a preferred alternative to surgery for squamous cell carcinoma of the base of tongue? *J Clin Oncol* 18: 35–42
- Mendenhall WM, Morris CG, Amdur RJ et al. (2006a) Definitive radiotherapy for tonsillar squamous cell carcinoma. *Am J Clin Oncol* 29:290–297
- Mork J, Lie AK, Glatte E et al. (2001) Human papillomavirus infection as a risk factor for squamous-cell carcinoma of the head and neck. *N Engl J Med* 344:1125–1131
- Murdoch-Kinch CA, Kim HM, Vineberg KA et al. (2008) Dose-effect relationships for the submandibular salivary glands and implications for their sparing by intensity modulated radiotherapy. *Int J Radiat Oncol Biol Phys* 72(2):373–382
- Nguyen NP, Frank C, Moltz CC et al. (2008) Dysphagia severity and aspiration following postoperative radiation for locally advanced oropharyngeal cancer. *Anticancer Res* 28: 431–434
- Nguyen NP, Moltz CC, Frank C et al. (2007) Impact of swallowing therapy on aspiration rate following treatment for locally advanced head and neck cancer. *Oral Oncol* 43: 352–357
- O'Sullivan B, Warde P, Grice B et al. (2001) The benefits and pitfalls of ipsilateral radiotherapy in carcinoma of the tonsillar region. *Int J Radiat Oncol Biol Phys* 51:332–343
- Parkin DM, Bray F, Ferlay J et al. (2001) Estimating the world cancer burden: globocan 2000. *Int J Cancer* 94:153–156
- Pignon JP, Bourhis J, Domenge C et al. (2000) Chemotherapy added to locoregional treatment for head and neck squamous-cell carcinoma: three meta-analyses of updated individual

- data. MACH-NC Collaborative Group. Meta-analysis of chemotherapy on head and neck cancer. *Lancet* 355: 949–955
- Pignon JP, Syz N, Posner M et al. (2004) Adjusting for patient selection suggests the addition of docetaxel to 5-fluorouracil-cisplatin induction therapy may offer survival benefit in squamous cell cancer of the head and neck. *Anticancer Drugs* 15:331–340
- Porceddu SV, Jarmolowski E, Hicks RJ et al. (2005) Utility of positron emission tomography for the detection of disease in residual neck nodes after (chemo)radiotherapy in head and neck cancer. *Head Neck* 27:175–181
- Posner MR, Herschock DM, Blajman CR et al. (2007) Cisplatin and fluorouracil alone or with docetaxel in head and neck cancer. *N Engl J Med* 357:1705–1715
- Quon A, Fischbein NJ, McDougall IR et al. (2007) Clinical role of 18F-FDG PET/CT in the management of squamous cell carcinoma of the head and neck and thyroid carcinoma. *J Nucl Med* 48(Suppl 1):58S–67S
- Ragin CC, Taioli E (2007) Survival of squamous cell carcinoma of the head and neck in relation to human papillomavirus infection: review and meta-analysis. *Int J Cancer* 121:1813–1820
- Rosen LS, Abdi E, Davis ID et al. (2006) Palifermin reduces the incidence of oral mucositis in patients with metastatic colorectal cancer treated with fluorouracil-based chemotherapy. *J Clin Oncol* 24:5194–5200
- Rosenquist K (2005) Risk factors in oral and oropharyngeal squamous cell carcinoma: a population-based case-control study in southern Sweden. *Swed Dent J Suppl* (179):1–66
- Ryu JK, Swann S, LeVeque F et al. (2007) The impact of concurrent granulocyte macrophage-colony stimulating factor on radiation-induced mucositis in head and neck cancer patients: a double-blind placebo-controlled prospective phase III study by Radiation Therapy Oncology Group 9901. *Int J Radiat Oncol Biol Phys* 67:643–650
- Sanguineti G, Richetti A, Bignardi M et al. (2005) Accelerated versus conventional fractionated postoperative radiotherapy for advanced head and neck cancer: results of a multicenter Phase III study. *Int J Radiat Oncol Biol Phys* 61:762–771
- Scarantino C, LeVeque F, Swann RS et al. (2006) Effect of pilocarpine during radiation therapy: results of RTOG 97-09, a phase III randomized study in head and neck cancer patients. *J Support Oncol* 4:252–258
- Schmid DT, Stoeckli SJ, Bandhauer F et al. (2003) Impact of positron emission tomography on the initial staging and therapy in locoregional advanced squamous cell carcinoma of the head and neck. *Laryngoscope* 113:888–891
- Schoder H, Carlson DL, Kraus DH et al. (2006) 18F-FDG PET/CT for detecting nodal metastases in patients with oral cancer staged N0 by clinical examination and CT/MRI. *J Nucl Med* 47:755–762
- Schwartz DL, Rajendran J, Yueh B et al. (2003) Staging of head and neck squamous cell cancer with extended-field FDG-PET. *Arch Otolaryngol Head Neck Surg* 129:1173–1178
- Soo KC, Tan EH, Wee J et al. (2005) Surgery and adjuvant radiotherapy vs concurrent chemoradiotherapy in stage III/IV nonmetastatic squamous cell head and neck cancer: a randomised comparison. *Br J Cancer* 93:279–286
- Spielberger R, Stiff P, Bensinger W et al. (2004) Palifermin for oral mucositis after intensive therapy for hematologic cancers. *N Engl J Med* 351:2590–2598
- Stoeckli SJ, Steinert H, Pfaltz M et al. (2002) Is there a role for positron emission tomography with 18F-fluorodeoxyglucose in the initial staging of nodal negative oral and oropharyngeal squamous cell carcinoma. *Head Neck* 24:345–349
- Stuckensen T, Kovacs AF, Adams S et al. (2000) Staging of the neck in patients with oral cavity squamous cell carcinomas: a prospective comparison of PET, ultrasound, CT and MRI. *J Craniomaxillofac Surg* 28:319–324
- Sturgis EM, Cinciripini PM (2007) Trends in head and neck cancer incidence in relation to smoking prevalence: an emerging epidemic of human papillomavirus-associated cancers? *Cancer* 110:1429–1435
- Su CK, Mehta V, Ravikumar L et al. (2004) Phase II double-blind randomized study comparing oral aloe vera versus placebo to prevent radiation-related mucositis in patients with head-and-neck neoplasms. *Int J Radiat Oncol Biol Phys* 60:171–177
- Trotti A, Garden A, Warde P et al. (2004) A multinational, randomized phase III trial of iseganan HCl oral solution for reducing the severity of oral mucositis in patients receiving radiotherapy for head-and-neck malignancy. *Int J Radiat Oncol Biol Phys* 58:674–681
- Tupchong L, Scott CB, Blitzer PH et al. (1991) Randomized study of preoperative versus postoperative radiation therapy in advanced head and neck carcinoma: long-term follow-up of RTOG study 73-03. *Int J Radiat Oncol Biol Phys* 20:21–28
- Vermorken JB, Remenar E, van Herpen C et al. (2007) Cisplatin, fluorouracil, and docetaxel in unresectable head and neck cancer. *N Engl J Med* 357:1695–1704
- Vernon MR, Maheshwari M, Schultz CJ et al. (2008) Clinical outcomes of patients receiving integrated PET/CT-guided radiotherapy for head and neck carcinoma. *Int J Radiat Oncol Biol Phys* 70:678–684
- Warde P, O'Sullivan B, Aslanidis J et al. (2002) A phase III placebo-controlled trial of oral pilocarpine in patients undergoing radiotherapy for head-and-neck cancer. *Int J Radiat Oncol Biol Phys* 54:9–13
- Wax MK, Myers LL, Gabalski EC et al. (2002) Positron emission tomography in the evaluation of synchronous lung lesions in patients with untreated head and neck cancer. *Arch Otolaryngol Head Neck Surg* 128:703–707
- Weinberger PM, Yu Z, Haffty BG et al. (2006) Molecular classification identifies a subset of human papillomavirus-associated oropharyngeal cancers with favorable prognosis. *J Clin Oncol* 24:736–747
- Worthington HV, Clarkson JE, Eden OB (2007) Interventions for preventing oral mucositis for patients with cancer receiving treatment. *Cochrane Database Syst Rev*:CD000978
- Zhang ZF, Morgenstern H, Spitz MR et al. (1999) Marijuana use and increased risk of squamous cell carcinoma of the head and neck. *Cancer Epidemiol Biomarkers Prev* 8:1071–1078

Functional Preservation and Quality of Life in Head and
Neck Radiotherapy

Harari, P.M.; Connor, N.P.; Grau, C. (Eds.)

2009, XIII, 329 p., Hardcover

ISBN: 978-3-540-73231-0