

Microincisional Lens Surgery

2

Jorge L. Alió, Pawel Klonowski, Bassam El Kady

Core Messages

- The minimization of the incision is a consequence of a natural evolution of the cataract surgery technique.
- Microincision cataract surgery (MICS) is the surgery performed through incisions of 1.5 mm or less.
- With MICS, you can operate all grades of cataract LOCS III, even hard cataracts, subluxated lenses, post traumatic lenses, zonular laxity, and congenital cataracts.
- One of the most important achievements of MICS is the reduction of the ultrasonic (US) power delivered into the eye.
- Among the major advantages of MICS is the reduction of surgical trauma resulting in a reduction of surgically-induced astigmatism (SIA).
- However, a major problem remains in the possibility of lens compression.
- The future belongs to the miniaturization of the tools and the wound size.
- MICS is ready to extract cataracts through sub-1-mm incisions.

2.1 Introduction: The Trends Towards Microincision Cataract Surgery

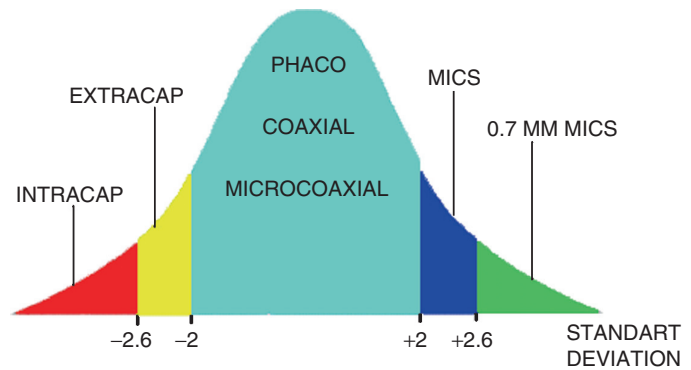
Biaxial microincision clear corneal phacoemulsification was a new method which made the corneal incision smaller; it was described by Shearing in 1985 [1]. This procedure uses separate irrigations with an irrigating chopper and sleeveless phacoemulsification tip, and also requires pulsed phacoemulsification energy.

The minimization of the incision is a consequence of a natural evolution of the cataract surgery technique in the search of excellence. When we place cataract surgery within the context of Gaussian distribution, it is clear that the normal practice today is standard coaxial phacoemulsification (Fig. 2.1). Extra-capsular 6-mm surgery is a procedure still in practice, but rarely performed, hence between -2 and -2.6 standard deviations. The Gaussian curve is like a wave. It moves from ancient to new surgical techniques. Nowadays, the standard coaxial technique

is still the most popular type of cataract surgery in the world. The coaxial wound size is still 2.75 mm, in spite of the availability of the newest foldable intraocular lenses which can be injected through smaller incisions. Microincision cataract surgery (MICS) can make the incision smaller than 1.5 mm and it should be considered beyond 2 and up to 2.6 standard deviations of our Gaussian distribution. MICS will be the standard practice in future, and what we could call sub-1-mm MICS or micro-MICS will be the next standard [2]. MICS is the next stage in the evolution of cataract surgery.

Summary for the Clinician

- The minimization of the incision is a consequence of a natural evolution of cataract surgery technique

Fig. 2.1 Natural evolution of cataract surgery [2]

2.2 MICS Definition

In 2001, MICS was patented as a new operating method by Jorge Alio. The definition of MICS is surgery performed through incisions of 1.5 mm or less. Understanding this global concept implies that it is not only about achieving a smaller incision size but also about making a global transformation of the surgical procedure towards minimal aggressiveness. In other words, a transition from conventional small incision surgery to the more developed concept of MICS [3].

Confirmed advantages of MICS:

- Surgery
 - I/A separation
 - No leakage (tight incision and well-profiled tools make wounds impermeable) [4–6]
 - Fluidics work as an instrument (high vacuum is the third power which can crumble the lens mass) [2, 3, 7]
 - Flexible surgery, assisted by fluidics (proper fluidics flow assures anterior chamber stability, while profundity and separated tools allow the possibility of faster and more precise surgery) [3, 8, 9]
 - Intraoperative control of intraocular pressure (permanent and sufficient infusion keep the eye globe in stable condition) [3, 10]
 - Smaller incision
 - New MICS irrigating hydromanipulators and the new use of fluidics leads to a reduction in the dimension of the incision [2, 3, 7–9]
 - Decreased effective phaco time (EPT)
 - Pre-chopping, new irrigating hydromanipulators, and fluidics as a tool, effectively decrease the time of phacoemulsification [4, 11–14]
- Patient
 - Minimal surgical-induced astigmatism
 - Smaller incision means smaller astigmatism [15–17]
 - Minimal aberration induction
 - Minor intraoperative injury does not lead to permanent injury of the cornea [4–6, 15, 17, 18]

- Faster postoperative recovery
 - Safe and stable anterior chamber operating system with minimal corneal injury reduces recovery time [4–6, 12, 13, 19]
- Excellent visual acuity
 - Fast and safe operation technique, and minimal harmful influence on corneal optic property [6, 8, 13, 15, 20, 21]

Ophthalmic surgeons who perform cataract surgery in the standard phacoemulsification mode will not have a problem changing their operation technique to MICS because the principle idea of the manipulation inside the eye remains unaltered. The main aim of MICS is to understand the principles.

Summary for the Clinician

- MICS is the surgery performed through incisions of 1.5 mm or less
- MICS advantages
 - I/A separation with fluidics work as an instrument
 - Smaller incision
 - Decreased effective phaco time (EPT)
 - Minimal surgical-induced astigmatism
 - Minimal aberration induction
 - Faster postoperative recovery
 - Excellent visual acuity

2.3 Indication for MICS Surgery

There is no limitation to indicate MICS cataract surgery. You can operate all grades of cataract LOCS III, even hard cataracts. The sub-luxated lenses, posttraumatic lenses, zonular laxity, and congenital cataracts can also be operated with MICS, with small doses of ultrasound. Generally MICS does not induce astigmatism. MICS is especially suitable for 'refractive cataract operation'. MICS can be used for refractive cataract

surgery by injecting multifocal lenses and toric lenses [21, 22].

Summary for the Clinician

- All grades of cataract LOCS III can be operated with MICS

2.4 Our Surgical Technique Step by Step

2.4.1 MICS Anesthesia

After the incision, intraocular anesthesia and mydriatics are applied to the eye. We use 1% lidocaine injecting it into the anterior chamber. Pupil dilatation is achieved by intraocular tropicamide (10%) and fenilefrine (10%) combination.

2.4.2 MICS Incision

The incision optimization results from maintaining a stable anterior chamber depth, adapting the incision size to the tools used, implantation of the lens, and counter-stretching in the route of manipulation. The minimization of the incision is required to carry out MICS correctly. Incisions smaller than 1.5 mm do not normally induce postoperative astigmatism [8]. Nowadays, we use 19 G (1/1.1 mm) and 21 G (0.7 mm) tools to do MICS.

The first stage of the operation is making two corneal incisions with a distance of 90–110° angle steps. To assure the reduction of existing astigmatism, a dominant incision must be made in a positive meridian of astigmatism. This leads to 30% reduction in the refractive cylinder [20]. Relaxing incisions can also be made [23, 24]. Incisions should allow correct tool manipulation and be watertight, and the wound should be correctly closed in

the postoperative period. The shape of the wound is very important, it should be trapezoidal-shaped with a smaller measurement 1.2 mm wide inside the wound near the Descemet membrane and a wider measurement 1.4 mm outside near the epithelium.

This shape is particularly important because of the necessity of the tool manipulation. By forming the wound this way it enables quite a considerable transfer of tools without any distortion, deformation, and maceration. It also protects against induced postoperative astigmatism. This is essential as the structure of the wound must be protected against leakage, and at the same time it provides an opportunity to work without tissue injury. The mechanical injury to tissues can lengthen the healing process and contribute to leakage, hypotony, and increased risk of endophthalmitis. It is also necessary to remember that too small incisions will not allow us to correct manipulations and a too big incision will lead to uncontrolled leakage from the wound. (Fig. 2.2) The value of such incisions reduces the possibility of exchanging liquids between the anterior chamber and the conjunctival sack [25–27].

To make the incision, we use trapezoidal knives, which allow different widths of incision from 1.2 mm at the peak to 1.4 mm at the base. To achieve this target, two kinds of knives can be used:

Alio's MICS knife (Katena, Denville, NJ, USA). Trapezoid shape 1.25 mm/1.4 mm/2.0 mm angled, double bevel (Fig. 2.3).

MICS diamond knife (Katena). Trapezoid shape, pale 1.25 mm/1.4 mm/2.0 mm width, laser-etched line indicating 1.25 mm width (Fig. 2.4).

2.4.3 MICS Capsulorhexis

Correctly performed capsulorhexis is vitally important for the MICS procedure. For this we used Alio's MICS capsulorhexis forceps (Katena). These are exquisitely delicate forceps with a 23-G diameter (Fig. 2.5).

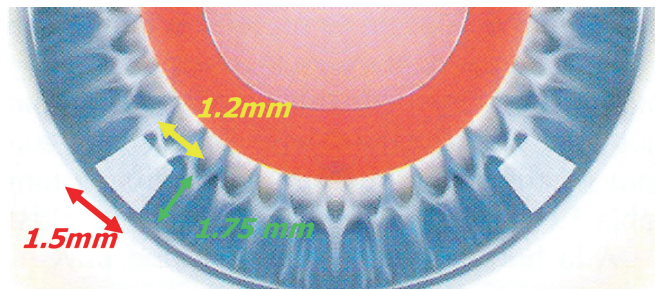


Fig. 2.2 19G Micro-incision cataract surgery (MICS) incision [3]

Fig. 2.3 Alio's MICS metal knife (Katena, Denville, NJ, USA)



Fig. 2.4 Alio's MICS diamond knife (Katena)



Fig. 2.5 Alio's MICS capsulorhexis forceps (Katena)



They can be easily located in the corneal wound. The correct profile of the hilt assures ergonomic use and normal movements inside the eye. At the end of the forceps is a pointed hook. This enables a controlled puncturing of the anterior capsule of the lens. Pressure is applied on the capsule and then with a little movement a cut is made. The wide-gauge shoulder forceps enable free manipulation of the torn capsule.

The next step is to pull the flap by tearing the capsule clockwise or anticlockwise. The size of the surgical wound and the diameter of the forceps prevent the possibility of the OVD leakage and flattening of the anterior chamber. The lens and the capsule are stabilized. The probability of bad tearing decreases. MICS capsulorhexis forceps allows capsulorhexis without the necessity of the help of the second tool.

2.4.4 MICS Hydrodissection, Hydrodelineation

The next stage of the cataract operation is the dissection of the lens from the cortex. This is important for prechopping as it enables the process of prechopping to be carried out in a safe way and does not cause complications.

Hydrodissection can diminish the power of ultrasound and surgery time [28].

In hydrodelineation, liquid is applied under the ring of the anterior capsule into the space of the lens. It enables the nucleus to be elevated and separated from the cortical masses. The maneuvers should be carried out as quickly as possible and with a very little amount of liquid. If nucleus rotation is not possible, hydrodissection maneuvers should be repeated [29].

2.4.5 MICS Prechopping

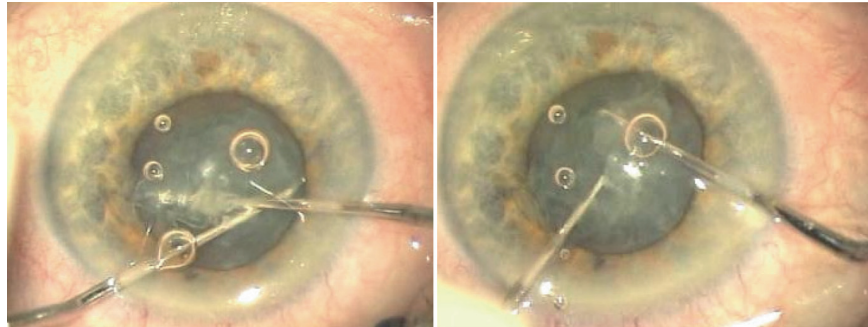
After the hydrodissection of the lens a mechanical division is made. This activity is aimed to make four lens quadrants. Prechopping reduces the amount of the ultrasonic, laser or mechanical energy delivered into the anterior chamber for fragmentation. This is a very important activity in the process of the energy reduction delivered to the eye. This is made with the help of two prechoppers (Alio-Rosen MICS prechoppers; Katena) (Fig. 2.6).

Two prechoppers should be inserted into the capsule under the anterior capsular rim, so that they are opposite each other. The hook of the chopper should be parallel

Fig. 2.6 Alio-Rosen phaco prechopper for MICS (Katena)



Fig. 2.7 MICS prechopping with Alio-Rosen phaco prechoppers



to the anterior capsule. Next, the chopper should be gently rotated along the axis of the tool. The chopper should now be situated in the lens under the anterior capsule on the perimeter (Fig. 2.7).

This activity should be made symmetrically by both hands. The choppers are crossed by situating each one symmetrically opposite to the other. Next, a cutting movement of the lens is made, gently crossing the prechoppers. The cut will be made from the perimeter to the center of nucleus. The internal edge of prechoppers is sharp which facilitates the incisions of the lens. This ambidextrous activity is important so that zonular stress does not occur. When the cut is made, two dividing hemispheres are formed. The nucleus is then rotated about 90° and the prechopping process is repeated as described. After carrying out prechopping, we have four lens quadrants in the capsular bag.

2.4.6 MICS Phacoemulsification and Removal Section

Having shared quadrants we can start phacoemulsification from the first quadrant. We use Alio's MICS hydromanipulator irrigating fingernail (Katena). Its end is fingernail-shaped. This tool helps to remove rather soft cataracts. There is an irrigation hole on the bottom lower side of the tool. The hole diameter is 1 mm. It also has very thin walls to increase the internal diameter of the instrument. This irrigation canula assures infusion of about 72 cc min⁻¹ (Fig. 2.8).

An outstanding stability of the anterior chamber is assured through the infusion and directs the liquid to

the lens masses at the back of the capsule, independently from high vacuum settings of the phacoemulsification machine (Fig. 2.9).

The strength of the stream permits the capsule to be held at a safe distance from the phacoemulsification tip and at the same time enables convenient manipulations of tools and lens masses. Additionally, this stream can clean the posterior capsule from the remaining cortical cells. A very fertile directed stream to the posterior capsule is provided with the preservation of corneal endothelial cells from mechanical and thermal damage.

The tool which allows the removal of harder cataracts is Alio's MICS irrigating stinger (Katena) (Fig. 2.10).

This tool has a 19-G diameter and is equipped with a tip at the end which is angled downwards. This tool is useful to chop off segments or for dividing masses of the nucleus in the phacoemulsification tip.

In the case of soft cataracts, having established the pressure at 500–550 mmHg, we can only use Alio's MICS hydromanipulator irrigating fingernail. This makes it possible to divide and aspirate fragments of the cataract without using ultrasound or using ultrasound in the minimum way. In this case, a torsional phacoemulsification system can be helpful. In the case of hard cataracts, when total occlusion of the tip occurs preventing aspiration, Alio's MICS irrigating stinger would be more useful. This handpiece has a narrow edge at the end which divides the masses and allows easy aspiration of the phacoemulsification tip. The fragmented elements of the hard cataracts are now easily aspirated using the high underpressure and occasionally using ultrasound energy.

Fig. 2.8 Alio's original fingernail MICS irrigating hydromanipulator (Katena)



Fig. 2.9 Posterior irrigation helps to open the capsular bag which does not induce turbulences, elevates nucleus fragments towards the phaco tip, and helps in cortex cleaning [3]

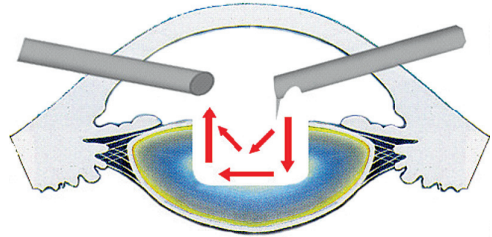
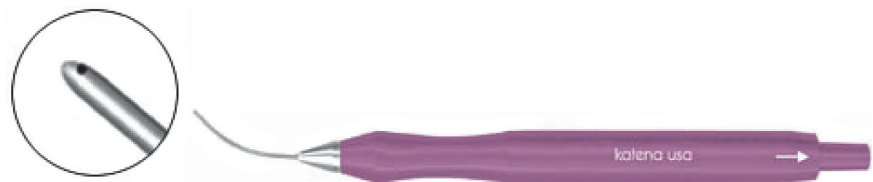


Fig. 2.10 Alio's MICS irrigating stinger (Katena)



Fig. 2.11 Alio's MICS aspiration handpiece (Katena)



For removing cortical remains, Alio's MICS aspiration handpiece (Katena) is a useful instrument. It has a port diameter of 0.3 mm which assures the stability of the hydrodynamic of liquid within the anterior chamber (Fig. 2.11).

Another auxiliary instrument, Alio's MICS scissors, exists for complicated cataracts which may require cutting within the anterior chamber. They can cut delicate membranes, adhesions, make iridotomy, and also cut the fibrosis of the capsules. This tool has a 23-G curved shaft with horizontal microblades (Fig. 2.12). Their shape allows the comfort of free manipulation in the angles of the anterior chamber.

Summary for the Clinician

- Incision should be trapezoidal-shaped with a smaller measurement 1.2 mm wide inside the wound near the Descemet membrane and a wider measurement 1.4 mm outside near the epithelium.
- Prechopping reduces the amount of the ultrasonic, laser, or mechanical energy delivered into the anterior chamber for lens fragmentation.
- Alio's MICS hydromanipulators assure an infusion of about 72 cc min^{-1} which allows the fluidics to act as a tool and cool the phaco tip.

Fig. 2.12 Alio's MICS scissors (Katena)



2.5 Flat Instruments Concept

Wound integrity is one of the most important factors that may influence the outcome of surgery. The assurance of the proper amount of the fluidics in MICS requires large dimensions of the tools. That is why the corneal tissue can be stressed during the operation. Mechanical tissue stress can evoke leakage, astigmatism, and anterior chamber instability [4–6, 25]. The requirement for tool improvement has become very important. The new Alio's MICS flat tools have been made by Katena. The irrigation and aspiration tools have rectangular cross-sections. The change of the shape did not influence the fluidics parameters. The fluidics flow of these tools is correct for MICS. Leakage around the tool is absent. Tool manipulation is easy and does not cause corneal tissue stress. Vertical manipulating does not stretch the wound and the horizontal movements do not press the angle of the wound due to the trapezoidal shape. This concept of irrigation–aspiration flat tools is a new way of treating the wound. The tools are adapted to the wound, but the wound does not have to be stressed by the tools. The tissue of the wound is untouched.

The self-sealing capability of the incision is mainly dependent on the construction of the wound: the angle, the width to depth ratio, and the multiple-plane construction of incision. The disturbance of these conditions can have an effect on the postoperative healing. The flat instruments do not affect the edges so the natural process of healing is not disturbed.

Summary for the Clinician

- MICS flat tools do not stretch the wound

2.6 Fluidics in MICS

In order to use the additional tool, the flow of liquids must be fulfilled with the following conditions:

1. Stable incision with no leakage
2. Stable anterior chamber
3. High vacuum

When the diameter of the infusion canulas is decreased a serious problem occurs. The anterior chamber does not start to fill up with the adequate amount of liquid. An infusion canula diameter of 21 G is not able to maintain a stable anterior chamber at aspiration and under pressure of 500–600 mmHg. Each attempt would end with the collapse of the anterior chamber.

Getting the high inflow of liquids into the anterior chamber is possible thanks to a new generation of tools. These tools have a relatively large infusion diameter and the right profile, allowing the right flow of liquid and a low level of internal resistance. These conditions do not allow the anterior chamber to become shallow or allow rippling of the posterior capsule. Also, the correct amount of liquid ensures chilling of the phacoemulsification tip and can function with highly efficient aspiration pumps.

According to the laws of physics the interior diameter of the tool has a major influence on fluidic resistance, because resistance is proportional to the diameter. Therefore, one is not allowed to apply standard infusion tools because of the insufficient hydrodynamics of these units. Tools assuring the flow is higher than 50 cc min^{-1} are needed for doing MICS. Current aspiration pumps have a utility which considerably exceeds the flow function of standard tools. The activity of standard infusion canulas is estimated at only 30 cc min^{-1} .

Therefore, the need for creating new tools arose in order to meet MICS needs. Katena took on the design and manufacture. A tool set came into existence with a very

small diameter in answer to MICS requirements but at the same time with a high flow of about 72 cc min⁻¹.

Using the highly efficient pump we must allow the correct inflow of liquid into the anterior chamber. In the case of the Accurus[®] and Infiniti[®] types of equipment we have the additional mechanism of pressurized inflow of fluidics – ‘gas forced infusion’. This can allow the controlling of the increase in the pressure of the irrigation bottle. This mechanism pumps filtered gas into the irrigation bottle and allows an additional increase in infusion. Highly efficient irrigation canulas and the mechanism of gas forced infusion helps provide the comfort of working in stable anatomical conditions.

We can achieve anterior chamber stability in two ways: (1) the high inflow of fluidics with proper instrument fluidics flow and forced infusion of fluidics, and (2) reduced outflow. The diminished diameter of tools and the Cruise Control stable chamber system allow proper outflow without reducing the vacuum.

MICS can be done with different kinds of aspiration systems. However, a Venturi Pump system is most popular and recommended. It has great flexibility and fast reaction. It allows a high value of underpressure and flow as the additional important tool in breaking and removing masses of the lens. The flow can be adjusted through the amount of vacuum and degree of occlusion of the tip. At present, venturi is the most efficient system. MICS settings with different phacoemulsification platforms are shown in Tables 2.1, 2.2 and 2.3.

Avoiding corneal burn:

At present, biaxial microincision clear cornea phacoemulsification makes it possible to do the treatment practically with no temperature elevation. However, development of high temperatures and incidence of corneal burns are possible (Fig. 2.13). For example, they may appear when the phacoemulsification tip is occluded for a long time with lens fragments associated with the use of highly OVD material [30]. They do not occur with the normal flow of liquids as long as the infusion liquid is circulated adequately. Flow control seems to be one of basic conditions of the entire procedure.

Table 2.1 Accurus 600 Alcon settings for 19G MICS

Quad	Phacoemulsification power	20%
	Vacuum	300 mmHg
	Irrigation	90
	Mode burst	30 ms

Table 2.2 Infinity Alcon settings for 19G MICS

Chop	Phacoemulsification power	0
	Dynamic rise	0
	Vacuum	150
	Irrigation	110
	Torsional amplitude	Limit 40 On: 20 Off: 40
	Aspiration rate	15
Quad	Phacoemulsification power	0
	Dynamic rise	2
	Vacuum	500
	Irrigation	110
	Torsional amplitude	Limit 80 On: 20 Off: 40
	Aspiration rate	30
Epi	Phacoemulsification power	0
	Vacuum	28
	Irrigation	110
	Torsional amplitude	Limit 30 On: 20 Off: 40
	Aspiration rate	28

Note: For 21 G MICS forced air infusion with air pump is necessary

Table 2.3 Millennium Bausch & Lomb settings for 19G MICS

Sculpture	Bottle height	100 cm
	Maximum bottle infusion	40 mmHg
	Fixed vacuum	200 mmHg
	Fixed U/S	10%
	Duration	20 ms
	Duty cycle	60%
Quadrant	Bottle height	100 cm
	Maximum bottle infusion	40 mmHg
	Fixed vacuum	470 mmHg
	Fixed U/S	10%
	Duration	20 ms
	Duty cycle	60%
I/A	Bottle height	80 cm
	Maximum bottle infusion	40 mmHg
	Maximum vacuum	550 mmHg

Note: For 21 G MICS forced air infusion with air pump is necessary

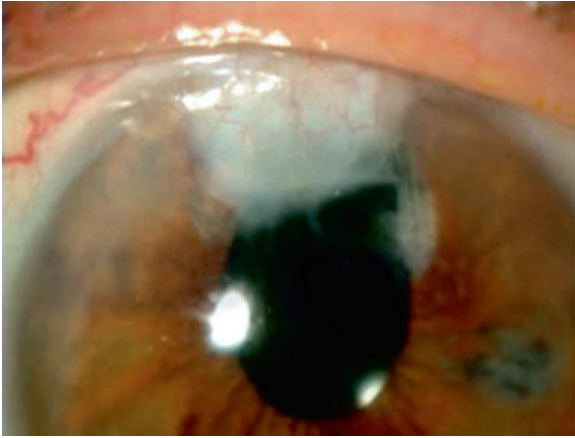


Fig. 2.13 Corneal burn after surgery. Personal case. This is the only corneal burn so far in our transmission period to MICS and was related to the use of high viscosity viscoelastics

Summary for the Clinician

- Fluidics conditions
 - Stable incision with no leakage
 - Stable anterior chamber
 - High vacuum
- MICS tools with a small diameter have a high liquid flow of about 72 cc min^{-1}
- 'Gas forced infusion' allows an additional increase in infusion
- Flow control is one of the basic conditions of the entire procedure

2.7 Irrigation and Aspiration: Creating a Balanced Fluidics Environment

The aspiration canula has a smaller internal diameter than the irrigation canula. This will cause disproportion in the resistance of the flow between infusion and aspiration and additionally will guarantee the anterior chamber stability. The aspirating canula has a hole of about 0.3 mm diameter. However, increasing the depth of the anterior chamber causes movement of the lens diaphragm which can make the lens fragments enter the space behind the iris. Fragments can get between the iris and the anterior capsule in the space surrounding the sulcus and cannot be seen. However, occasionally the fragments can be observed in the anterior chamber several hours after the operation. Rinsing out and cleaning this space is extremely important.

The stability of the anterior chamber in the case of MICS is indisputably higher than in coaxial phacoemulsification. MICS does not cause frequent and considerable changes in the anatomical proportion of the eyeball, and traction does not occur during the operation. From capsulorhexis to filling up with OVD before lens injection it is possible to maintain the anterior chamber stable.

Stable Chamber System

Cruise Control[™] of the STAAR Surgical Company is an additional system streamlining the irrigating–aspirating system [31]. It is a device specially designed for cataracts in the bimanual microincisional phacoemulsification mode at high vacuum settings. Cruise Control has a disposable flow restrictor with a 0.3-mm internal diameter. It is fixed between the phacoemulsification handpiece and the aspiration tubing. It prevents surges during occlusion breaks at higher vacuum level. It has a mesh filter which safeguards against blocking. Lens fragments remain on the filter. The restrictor limits the flow. At the underpressure of 500 mmHg, the anterior chamber does not become shallow (Fig. 2.14).

A similar device is offered by Bausch & Lomb (Rochester, NY, USA). The Stable Chamber differs in size restrictor, but the principle of action remains similar. This device can be attached to the standard phaco machine tubes (Fig. 2.15).

The Stellaris (Bausch & Lomb) offers new tubing technology called stable chamber tubing system. This kit consists of tubes integrated with a micromesh filter. The tubes have reduced diameter and the wall is much more durable. These modifications help to achieve greater power of fluidics and reduces postocclusion surge (Fig. 2.16).

Summary for the Clinician

- Flow restrictor makes the procedure safer, helps to achieve greater power of fluidics, and reduces postocclusion surge

Cruise Control Design and Placement

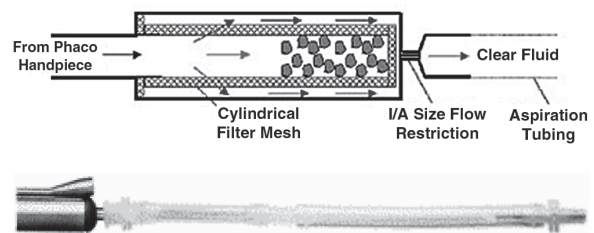


Fig. 2.14 Cruise control[™] system (STAAR Surgical, Monrovia, CA, USA)

Fig. 2.15 Stable chamber system (Bausch & Lomb, Rochester, NY, USA)




Fig. 2.16 Stable chamber tubing system (Bausch & Lomb)



2.8 Is MICS Worthwhile?

2.8.1 Clinical Outcome

One of the most important achievements of MICS is the reduction of the ultrasonic (US) power delivered into the eye. The nucleus breaking is done by mechanical movements of tools, high volume fluidics activity, and US power in the cataract surgery system. The total effective US power and total ultrasound time can be diminished in MICS surgery. Alio et al. indicated that the MICS surgery technique compared to standard coaxial phacoemulsification diminishes the mean incision size with statistical significance ($p < 0.001$), mean total phacoemulsification percent ($p < 0.001$), and mean effective phacoemulsification time ($p < 0.001$) [8]. Kahraman et al. show that in MICS the mean ultrasound time is statistically lower than in the coaxial group [12]. In Kurz et al., the microincision group had shorter EPT, and BCVA improved more rapidly than in the coaxial group [13]. Also, Cavallini et al. explain that microincision surgery can be less invasive and safer, resulting in less postoperative intraocular inflammation, fewer incision related complications, and shorter surgical time [11].

For the corneal endothelium, the clinical evaluations after MICS are variable, but most of them indicate that there is no difference between the coaxial and MICS group. Crema et al. indicate in their MICS and coaxial surgery comparative study with 1-year follow-up that central endothelial cell loss can be significant in the MICS group after 1 year. This study also shows that endothelial cell loss 6 months after surgery did not change [32]. Wilczynski et al. did not find any difference

in endothelial cell loss between the MICS and standard phacoemulsification group: the endothelial cell loss was similar in both groups and the difference was not statistically significant [33]. Kahraman et al. confirm this in their investigation [12]. Also, Mencucci et al. report that the endothelial cell loss was similar in the MICS and coaxial groups [19].

2.8.2 Outcome of the Incision

MICS is performed using new technology, so the US tip does not need to be extensively cooled. Using rapid on-off cycles you can reduce the power delivered to the tip. Donnenfeld et al. showed that the increase of temperature during bimanual phacoemulsification can be lower than temperature increase during coaxial phacoemulsification, and no wound damage was observed [5].

Experimental models of sleeveless bimanual phacoemulsification indicate that advanced microburst or hyperpulse technology does not enhance corneal temperature over the corneal damage threshold and, additionally, did not pass 39.0°C even with tip occlusion [4]. The total amount of US power used in MICS surgery is much lower than the power which can damage the cornea [34]. The sleeveless US tip does not deform the incision and there is a sufficient flow to cool the tip during phacoemulsification so the risk of thermal burn is minimal [9]. Additionally, the corneal swelling is much less significant in smaller incisions than in standard coaxial incisions [35].

The problem with leakage after the wound stress has been described [25]. However, the integrity of the wound can be achieved using MICS tools and the new Alio's

MICS flat instruments. The incision can be tight with no leakage and the tissues are not stressed. The sub-2.0-mm MICS incision has good self-sealing ability and, additionally, does not cause post-operative astigmatism in most cases [8].

2.8.3 Astigmatism Control with MICS

Among the major advantages of MICS is the reduction of surgical trauma resulting in a reduction of surgically-induced astigmatism (SIA) and aberrations and improvement of the optical quality of the cornea after surgery, thus leading to improvement of visual outcome and high patient satisfaction [7, 36].

Degraded optical quality of the cornea after incisional cataract surgery would limit the performance of the pseudophakic eye. Thus, it is important not to increase nor to induce astigmatism and/or corneal aberrations after cataract surgery [17]. Even with MICS, we could achieve reduction of astigmatism and higher order corneal aberrations [37].

The optical quality of the cornea plays an important role in the recovery of the visual function after cataract surgery, and this is determined by a combination of corneal and internal aberrations generated by the intraocular lens (IOL) and those induced by the surgery. These corneal refractive changes are attributed to the location and size of the corneal incision. The smaller the incision, the lower the aberrations, and the better the optical quality [38].

We have described the improved control of SIA with MICS when compared to conventional 3-mm phacemulsification. A great advantage of MICS is the reduction of SIA and also that the microincisions do not produce an increase in astigmatism [8]. The shorter the incision, the less the corneal astigmatism, as it was estimated that the magnitude of the SIA studied by vector analysis is around 0.44 and 0.88 D, rising as the size of the incision increases [28, 39]. This is considered important because cataract surgery today is considered more and more a refractive procedure [8].

Also, small-incision surgery (3.5-mm incision without suture) does not systematically degrade the optical quality of the anterior corneal surface. However, it introduces changes in some aberrations, especially in nonrotationally symmetric terms such as astigmatism, coma, and trefoil [18]. Therefore, one has to expect better results and fewer changes with sub-2-mm incision (MICS).

This is supported by the finding that the corneal incision of <2 mm had no impact on corneal curvature [16, 37, 40]. Going hand in hand with the modern concept of making cataract surgery a refractive procedure, one

can control and even decrease astigmatism and HOA by using MICS, which is state of the art.

2.8.4 Corneal Aberration Control with MICS

Nowadays, cataract surgery is not only removal of an opaque lens, but it is also a part of refractive surgery. The technical progress has generated high standards of ophthalmic machines and tools. We can obtain precise intraocular lens (IOL) power calculation, reduce residual astigmatism, and do surgery without SIA. Corneal refractive surgery becomes more popular and more excellent. For this reason, the lenses we are using should be perfect.

Optical quality of MICS IOL

Our experience with MICS has proved its effectiveness in stabilizing the corneal optics after surgery without degradation of the corneal optical quality [15]. Thus, for a MICS IOL to fulfill this advantage, it should help to improve the control of the optical performance of the human eye. Consequently, such IOL should be aberration and scattering free, not cause night-vision complaints such as halos and glare, and have similar or even better optical outcome when compared to conventional lenses [7].

The optical quality of the pseudophakic eye is largely affected by aberrations induced by the implanted IOL. These aberrations depend on two characteristics of the lens, thickness and surface quality, and will vary depending on the type of IOL implanted [21].

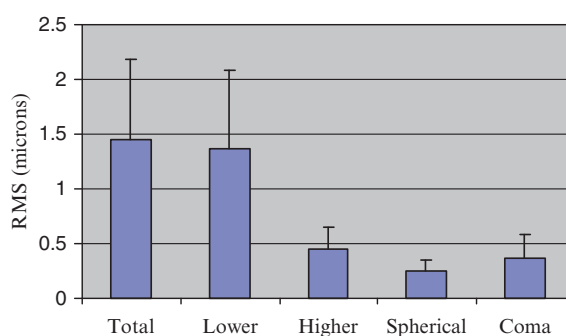
Among the currently available MICS IOLs, only a few of them have been evaluated from the optical quality point of view. Generally, they obtain optical quality and biocompatibility similar to conventional intraocular lenses *in vivo* [7, 21].

For Acri.Smart IOLs (Acri-Tec, Hennigsdorf, Berlin, Germany), studying the point spread function (PSF) before and after pushing the lens through the Acri.Glide cartridge (Acri-Tec), revealed no difference between the Acri.Smart lens before and after. This was further supported by an interesting study comparing the retinal image quality after implantation of two MICS IOLs and a conventional IOL, by evaluating the modulation-transfer function (MTF), 0.1 and 0.5 values for Acri.Smart and ThinOptX UltraChoice 1.0 IOL (ThinOptX, Abrindon, Virginia, USA) for MICS versus AcrySof conventional lens (AcrySof MA60BM; Alcon Laboratories, Ft Worth, USA), with no statistical difference between all of these lenses [21] (Table 2.4). Also, the manufacturing company studied the MTF for the ThinOptX MICS IOL, concluding that each stepped ring provides the same optical information to the same focal

Table 2.4 MTF value of Acri.Smart IOL, ThinOptX IOL, and AcrySof IOL [7]

IOL type	Incision size (mm)	Mean IOL power (D \pm SD)	Mean after surgery defocus equivalent (D \pm SD)	Mean BCVA after surgery	Mean spatial frequency (cpd) at 0.5 MTF \pm SD	Mean spatial frequency (cpd) at 0.1 MTF \pm SD
Alcon AcrySof MA60BM	3.2	19.86 \pm 6.21	1.13 \pm 0.72	20/20	2.647 \pm 0.833	8.720 \pm 3.074
ThinOptX ultraChoice 1.0	1.6–1.8	20.39 \pm 1.05	0.88 \pm 0.35	20/20	2.601 \pm 0.986	8.814 \pm 4.380
Acri.Smart 48S	1.6–1.8	23.25 \pm 4.6	1.00 \pm 0.63	20/20	3.453 \pm 0.778	11.418 \pm 2.574

IOL Intraocular lens, BCVA best-corrected visual acuity, MTF modulation transfer function

**Fig. 2.17** AcriLisa 366D ACRITEC, bifocal, aberration correcting, aspherical, foldable one piece lens for capsular capsule fixation and microincision (MICS)**Fig. 2.18** RMS values and standard deviation of total, lower order, higher order, spherical and coma-like intraocular aberrations

point on the retina and MTF and visual acuity, therefore providing excellent refractive design [7]. Recently, the aberration-correcting effect of ThinOptX IOL has been evaluated by comparing the spherical aberration between ThinOptX and Alcon Acrysof lenses. The results demonstrated that although there was no statistically significant difference in the root mean square (RMS) for spherical aberration the ThinOptX eyes showed smaller spherical aberrations, being designed for negative spherical aberration [41].

Recently, we evaluated a new MICS multifocal IOL, the Acri.LISA 366D (Acri-Tec) (Fig. 2.17) [42]. We analyzed objectively the intraocular optical quality in vivo of this diffractive asymmetrical light distribution multifocal IOL. The main outcomes were RMS values for intraocular aberrations, Strehl ratio, and the MTF (0.5 and cut-off), using an intraocular optical analysis model [43]. The Acri-Tec Acri.LISA 366D showed excellent intraocular optical performance as demonstrated by good values for the intraocular optical aberrations, Strehl ratio and MTF, (Figs. 2.18 and 2.19).

Such an effect can be additionally explained by Acri.LISA neutral asphericity and aberration-correcting profile [42].

Finally, we can conclude that for an ideal MICS IOL it is not enough to have low optical aberrations but it must also be able to compensate for corneal aberrations (coupling of two optical systems), an effect which can work with MICS in stabilizing corneal optical quality. The evaluation of MTF in vivo may be the best method to study the optical quality of eyes implanted with IOLs which could be objectively measured by the Optical Quality Analysis System (OQAS, Visiometrics S.L. Tarrasa, Spain) which also calculates the PSF. Consequently, MICS IOLs perform well inside the eye; their folding and unfolding does not cause structural and functional defects, which together with neuroprocessing allows excellent IOL optical performance in vivo [7, 8, 21].

The other study shows that UltraChoice 1.0 ThinOptX and Acri.Smart 48S MICS lenses have excellent MTF performance. In this study, there was no difference between

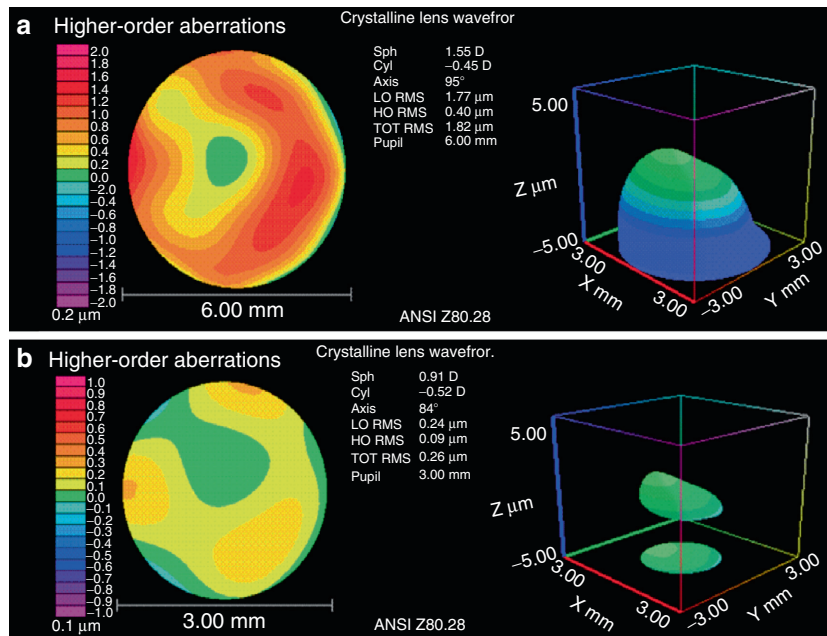


Fig. 2.19 Wavefront intraocular aberrations after surgery of the AcriLISA 366D at both (a) 6-mm and (b) 3-mm pupil diameters [42]

these lenses and AcrySof MA60BM lenses. This indicates that there is no difference between MICS lenses and conventional cataract lenses. Small incision, folding and unfolding did not cause structural and functional defects [7, 21] (Figs. 2.20 and 2.21).

Summary for the Clinician

- MICS surgery technique compared to standard coaxial phacoemulsification:
 - Diminishes the mean incision size
 - Diminishes the mean effective phacoemulsification time
 - Diminishes surgical time
 - Diminishes postoperative intraocular inflammation
 - Diminishes complications
 - Diminishes surgically induced astigmatism
- With MICS, we can achieve a reduction of astigmatism and higher order corneal aberrations

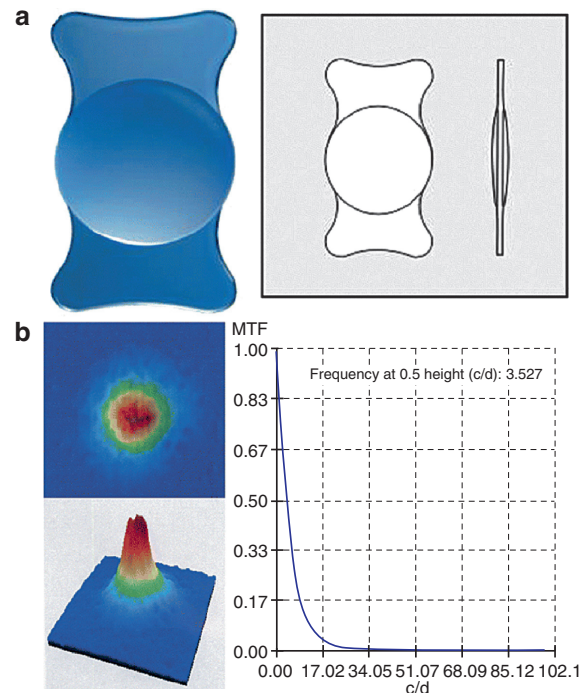


Fig. 2.20 Acri.Smart lens (a) Acri.Smart lens. (b) Optical quality analysis system (OQAS) image comparison with the PSF of treated and untreated Acri.Smart IOL [7]

2.9 End of the Surgery

Endophthalmitis prevention is the last part of the surgery. The procedure is finished by injecting 0.1–0.2 ml of cefuroxime into the anterior chamber. Next, corneal wound hydration should be done to close the wound and 2–3 drops of povidone iodine administered into the

conjunctival sac. The state of incisions is verified in the slit lamp after half an hour. If leakage appears, the procedure of hydration should be repeated.

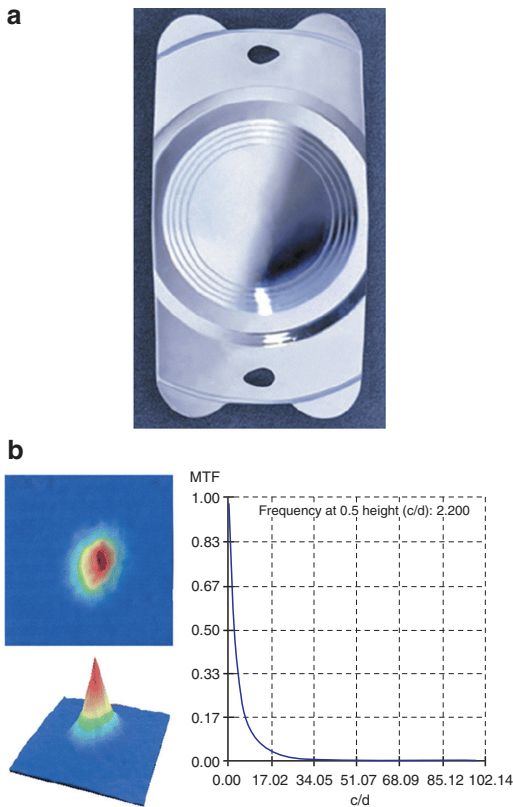


Fig. 2.21 The ThinOptX IOL. (a) The ThinOptX IOL. (b) OQAS image comparison with the MTF of treated and untreated ThinOptX IOL [7]

2.10 Future of MICS

Unfortunately, new ideas in the field of the cataract surgery are limited by technical possibilities. However, a major problem remains in the possibility of lens compression. The foldable intraocular lenses are compressed only to 1.5 mm of incision. MICS makes the wound smaller and will evolve into reduction of incision, energy, and eye injury. The future belongs to the miniaturization of the tools and the wound size. A minimization of the energy and manual activities must occur in the anterior chamber. The problem of energy still remains a problem to be solved. The next step could be subsonic oscillation and lasers. In the future, the laser will supply the ultrasound energy and may become the standard technology for breaking nuclei of the lenses. However, it is not possible to remove hard cataracts with the help of new types of lasers at the present stage of technology. Also in the future, the ultrasound energy and laser energy connection can bring the desired effect. Laser energy will make it possible to remove cataracts with incisions smaller than 0.7 mm.

Managing the flow of liquids will also change together with the development of infusion and aspirating pumps. The problem with providing large amounts of liquids by irrigation tools still occurs. The development of highly efficient fluid injectors and new liquid substances with a different viscosity will be the perfect solution.

MICS development and evolution will be necessary in the future.

References

1. Shearing SP, Relyea RL, Loaiza, Shearing RL (1985) Routine phacoemulsification through and they millimeter non-sutured incision. *Cataract* 2:6–11
2. Alió JL (2006) What is the future of cataract surgery? *Ocular Surg News* 17:3–4
3. Alió JL, Rodriguez Prats JL, Galal A (2004) MICS Microincision Cataract Surgery. *Highlights of Ophthalmology International*, Miami
4. Braga-Mele R (2006) Thermal effect of microburst and hyperpulse settings during sleeveless bimanual phacoemulsification with advanced power modulations. *J Cataract Refract Surg* 32:639–42
5. Donnenfeld ED, Olson RJ, Solomon R, Finger PT, Biser SA, Perry HD, Doshi S (2003) Efficacy and wound-temperature gradient of WhiteStar phacoemulsification through a 1.2 mm incision. *J Cataract Refract Surg* 29:1097–100
6. Soscia W, Howard JG, Olson RJ (2002) Bimanual phacoemulsification through 2 stab incisions. A wound-temperature study. *J Cataract Refract Surg* 28:1039–43
7. Alió JL, Rodriguez-Prats JL, Galal A (2006) Advances in microincision cataract surgery intraocular lenses. *Curr Opin Ophthalmol* 17:80–93
8. Alió JL, Rodriguez-Prats JL, Galal A, Ramzy M (2005) Outcomes of microincision cataract surgery versus coaxial phacoemulsification. *Ophthalmology* 112:1997–2003
9. Tsuneoka H, Shiba T, Takahashi Y (2001) Feasibility of ultrasound cataract surgery with a 1.4 mm incision. *J Cataract Refract Surg* 27(6):934–40
10. Khng C, Packer M, Fine IH, Hoffman RS, Moreira FB (2006) Intraocular pressure during phacoemulsification. *J Cataract Refract Surg* 32:301–8
11. Cavallini GM, Campi L, Masini C, Pelloni S, Pupino A (2007) Bimanual microphacoemulsification versus coaxial miniphacoemulsification: prospective study. *J Cataract Refract Surg* 33:387–92
12. Kahraman G, Amon M, Franz C, Prinz A, Abela-Formanek C (2007) Intraindividual comparison of surgical trauma after bimanual microincision and conventional small-incision coaxial phacoemulsification. *J Cataract Refract Surg* 33(4):618–22

13. Kurz S, Krummenauer F, Gabriel P, Pfeiffer N, Dick HB (2006) Biaxial microincision versus coaxial small-incision clear cornea cataract surgery. *Ophthalmology* 113:1818–26
14. Tanaka T, Koshika S, Usui M (2007) Cataract surgery using the bimanual phacoemulsification technique with an Accurus system and Mackool microphaco tip. *J Cataract Refract Surg* 33:1770–4
15. Elkady B, Alió JL, Ortiz D, Montalbán R (2008) Corneal aberrations after microincision cataract surgery. *J Cataract Refract Surg* 34:40–5
16. Olson RJ, Crandall AS (1998) Prospective randomized comparison of phacoemulsification cataract surgery with a 3.2-mm vs a 5.5-mm sutureless incision. *Am J Ophthalmol* 125:612–20
17. Yao K, Tang X, Ye P (2006) Corneal astigmatism, high order aberrations, and optical quality after cataract surgery: microincision versus small-incision. *J Refract Surg* 22:1079–82
18. Guirao A, Tejedor J, Artal P (2004) Corneal aberrations before and after small-incision cataract surgery. *Invest Ophthalmol Vis Sci* 45:4312–9
19. Mencucci R, Ponchietti C, Virgili G, Giansanti F, Menchini U (2006) Corneal endothelial damage after cataract surgery: Microincision versus standard technique. *J Cataract Refract Surg* 32:1351–4
20. Alio JL, Rodriguez-Prats JL, Vianello A, Galal A (2005) Visual outcome of microincision cataract surgery with implantation of Acri.Smart Lens. *J Cataract Refract Surg* 31:1549–56
21. Alió JL, Schimchak P, Montés-Micó R, Galal A (2005) Retinal image quality after microincision intraocular lens implantation. *J Cataract Refract Surg* 31:1557–60
22. Assaf A, El-Moatassem Kotb AM (2007) Feasibility of bimanual microincision phacoemulsification in hard cataracts. *Eye* 21:807–11
23. Kaufmann C, Peter J, Ooi K, Phipps S, Cooper P, Goggin M (2005) The Queen Elizabeth Astigmatism Study Group. Limbal relaxing incisions versus on-axis incisions to reduce corneal astigmatism at the time of cataract surgery. *J Cataract Refract Surg* 31:2261–5
24. Nichamin L (2003) Treating astigmatism at the time of cataract surgery. *Curr Opin Ophthalmol* 14:35–8
25. Berdahl JP, DeStafeno JJ, Kim T (2007) Corneal wound architecture and integrity after phacoemulsification evaluation of coaxial, microincision coaxial, and microincision bimanual techniques. *J Cataract Refract Surg* 33:510–5
26. Mehran T, Behrens A, Newcomb R, Nobe M, Saedi G, McDonnell P (2005) Acute endophthalmitis following cataract surgery and systematic review of the literature. *Arch Ophthalmol* 123:613–20
27. Nagaki Y, Hayasaka, Kadoi C, Matsumoto the M, Yanagisawa, Watanabe K, Watanabe K, Hayasaka Y, Ikeda N, Sato, Kataoka Y, Togashi M, Abe J (2003) Bacterial endophthalmitis after small-incision cataract surgery: effect of incision placement and intraocular lens type. *Cataract Refract Surg* 29:20–6
28. Vasavada AR, Singh R, Apple DJ, Trivedi RH, Pandey SK, Werner L (2002) Effect of hydrodissection on intraoperative performance: randomized study. *J Cataract Refract Surg* 28:1623–8
29. Peng Q, Apple DJ, Visessook N, Werner L, Pandey SK, Escobar-Gomez M, Schoderbek R, Guindi A (2000) Surgical prevention of posterior capsule opacification. Part 2: Enhancement of cortical cleanup by focusing on hydrodissection. *J Cataract Refract Surg* 26:188–1897
30. Tsuneoka H, Hayama A, Takahama M (2003) Ultrasmall-incision bimanual phacoemulsification and AcrySof SA30AL implantation through a 2.2 mm incision. *J Cataract Refract Surg* 29:1070–6
31. Chang DF (2004) 400 mm Hg high-vacuum bimanual phaco attainable with the staar cruise control device. *J Cataract Refract Surg* 30:932–3
32. Crema AS, Walsh A, Yamane Y, Nosé W (2007) Comparative study of coaxial phacoemulsification and microincision cataract surgery. One-year follow-up. *J Cataract Refract Surg* 33:1014–8
33. Wilczynski M, Drobniowski I, Synder A, Omulecki W (2006) Evaluation of early corneal endothelial cell loss in bimanual microincision cataract surgery (MICS) in comparison with standard phacoemulsification. *Eur J Ophthalmol* 16:798–803
34. Soscia W, Howard JG, Olson RJ (2002) Microphacoemulsification with WhiteStar: a wound-temperature study. *J Cataract Refract Surg* 28:1044–6
35. Fine IH, Hoffman RS, Packer M (2007) Profile of clear corneal cataract incisions demonstrated by ocular coherence tomography. *J Cataract Refract Surg* 33:94–7
36. Naeser K, Knudsen EB, Hansen MK (2002) Bivariate polar value analysis of surgically induced astigmatism. *J Refract Surg* 18:72–8
37. Jiang Y, Le Q, Yang J, Lu Y (2006) Changes in corneal astigmatism and high order aberrations after clear corneal tunnel phacoemulsification guided by corneal topography. *J Refract Surg* 22:1083–8
38. Holladay JT (2003) Optical quality and refractive surgery. *Int Ophthalmol Clin* 43:119–36
39. Simsek S, Yasar T, Demirok A, Cinal A, Yilmaz OF (1998) Effect of superior and temporal clear corneal incisions on astigmatism after sutureless phacoemulsification. *J Cataract Refract Surg* 24:515–8
40. Oshika T, Tsuboi S (1995) Astigmatic and refractive stabilization after cataract surgery. *Ophthalmic Surg* 26:309–15

41. Ouchi M, Kinoshita S (2007) Aberration-correcting effect of ThinOptX IOL. *Eye*, Dec 21. doi:10.1038/sj.eye.6703068
42. Alió JL, Elkady B, Ortiz D, Bernabeu G (2008) Clinical outcomes and intraocular optical quality of a diffractive asymmetrical light distribution multifocal intraocular lens (Acri.LISA 366D). *J Cataract Refract Surg* 34:942–8
43. Ortiz D, Alió JL, Bernabeu G, Pongo V (2008) Optical quality performance inside the human eye of monofocal and multifocal intraocular lenses. *J Cataract Refract Surg* 34:755–62



<http://www.springer.com/978-3-540-76378-9>

Cataract and Refractive Surgery

Progress III

Kohnen, Th.; Koch, D.D. (Eds.)

2009, XIV, 122 p., Hardcover

ISBN: 978-3-540-76378-9