

## Breast-Conserving Surgery for Central Tumours: “NACectomies”

### Introduction

Centrally located tumours have long been considered to be more serious, multifocal and more likely to recur. In fact, this is not the case; the only real problem is ensuring that the breast is preserved with a “normal” form following breast-conserving surgery and adjuvant radiotherapy.

As with more peripheral tumours, central tumours may also benefit from breast-conserving surgery.

Several techniques have been used depending on the tumour and the size and form of the breast.

### Periareolar Technique

This comprises an en bloc excision, via a periareolar incision, of the nipple-areola complex (NAC) and underlying tissue as far as the prepectoral fascia (Fig. 2.1). The mammary gland is then raised at this plane and reconstitution of the gland effected by approximating the breast parenchyma. This is performed from deep to superficial, and produces a breast with a reduced base width but increased projection. In this way, one can avoid the “flat” appearance seen in the reconstructed breast following central tumourectomy without gland remodelling (Fig. 2.2). A submammary drain is used and, where required, the skin is raised separately to facilitate closure in a “purse-string” fashion (Fig. 2.3).

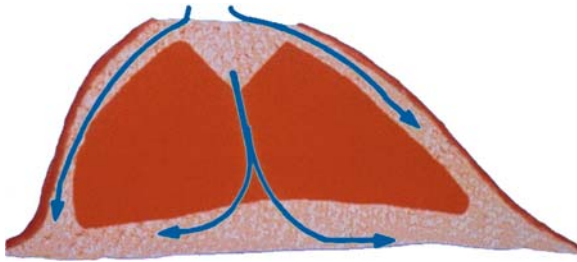
### Horizontal Technique

This is similar to the periareolar technique in all respects except the skin incision, which is semielliptical, in the shape of an eye, with the NAC resembling the iris (Fig. 2.4 and plate 2.1). Gland remodelling is identical, but skin closure is direct, yielding a transverse linear scar (Fig. 2.5). In cases of more pronounced ptosis, a longer incision may be used. This technique thus approximates the omega mammoplasty without NAC preservation.

### Mammoplasty-Associated Techniques

If the tumour is larger or deeper, and the breast parenchymal volume allows a breast reduction can be performed in association with NACectomy. The design is generally either purely vertical or an inverted T (Fig. 2.5 and plate 2.2), but it can also involve other plasties, such as J-plasty or lateral mammoplasty.

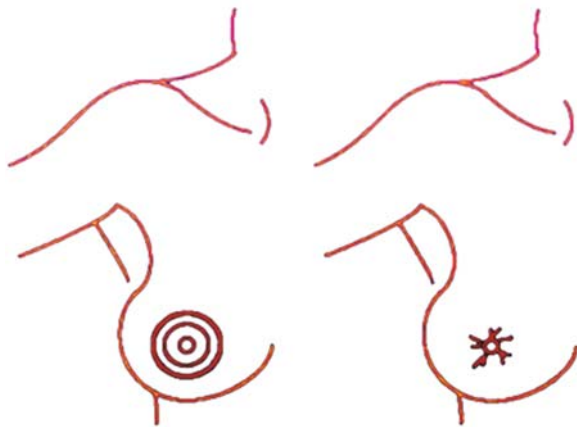
A symmetrising procedure on the contralateral breast is frequently required in a subsequent operation after adjuvant radiotherapy has been completed. All techniques are available, depending on the requirements: periareolar is usually used for small modifications, but vertical-scar, inverted-T and lateral mammoplasty are also used according to the final form of the treated breast. NAC reconstruction is conveniently performed at this second sitting, with either areolar skin grafting and a nipple graft or local flaps (Little’s technique), or areolar tattooing and local flaps (F flap) (see Chap. 6).



**Fig. 2.1** Dissection planes for tumourectomy



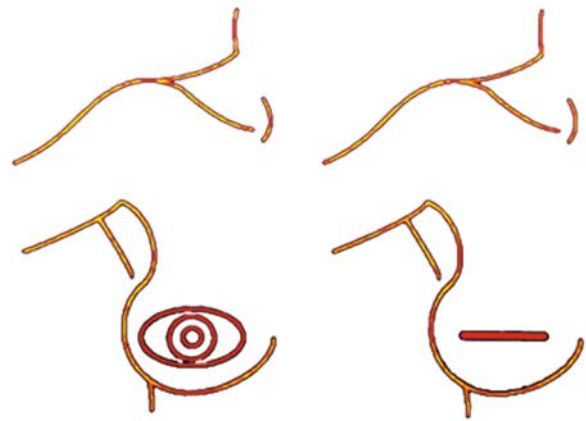
**Fig. 2.2** Parenchymal flaps allowing filling of the tumourectomy defect and reconstitution of the breast mound



**Fig. 2.3** NACectomy with purse-string closure

## Discussion

Central tumours represent 5–20% of breast cancers and are treated in the same fashion as those that are more peripherally located. Resection must be similarly wide to avoid surgical re-excisions and secondary mastectomies.



**Fig. 2.4** NACectomy with short transverse scar

Overall survival, risk of recurrence and metastatic disease are identical to other tumour locations.

Deep central tumours that are more than 3 cm from the areola are considered to be “peripheral” and are therefore treated accordingly.

In a series of 146 patients at the Institut Curie, central tumours represented 7.5% of the cases, had a mean size of 21.5 mm, and a mean distance from the areola of 5.2 mm. The most common techniques were horizontal ( $n = 72\%$ ), periareolar ( $n = 14\%$ ) and inverted T ( $n = 6\%$ ). In the remainder ( $n = 9\%$ ), other techniques such as lateral and vertical-scar mammoplasty were employed.

Symmetrising surgery was undertaken at the same time in only 17%.

The complication rate was low, of the order of 9%, comprising predominantly haematomas, wound breakdown, delayed healing and infection.

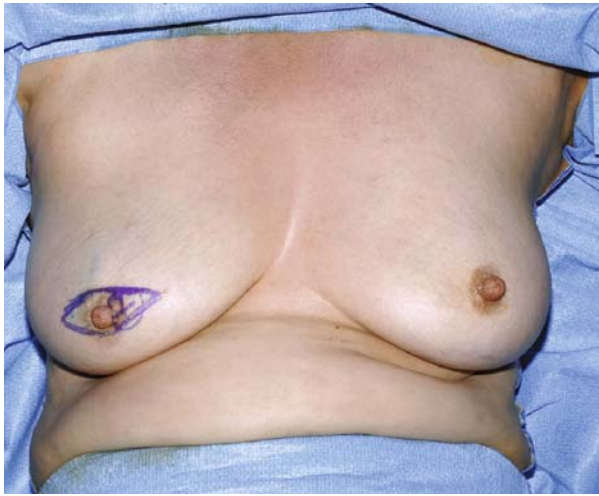Histopathological evaluation showed:

- Clear excision margins in more than 80%
- Minimally clear margins (within 2 mm) in 11%
- Involved margins in 9%
- Areolar invasion/involvement in 62%

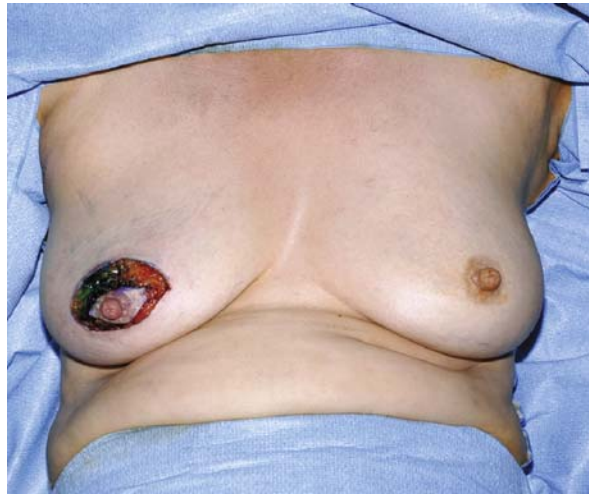These incomplete margins were treated with:

- Completion mastectomy in 9 patients
- A further wide excision plus radiotherapy in 2 patients
- An additional “boost” of local radiotherapy in 12 patients

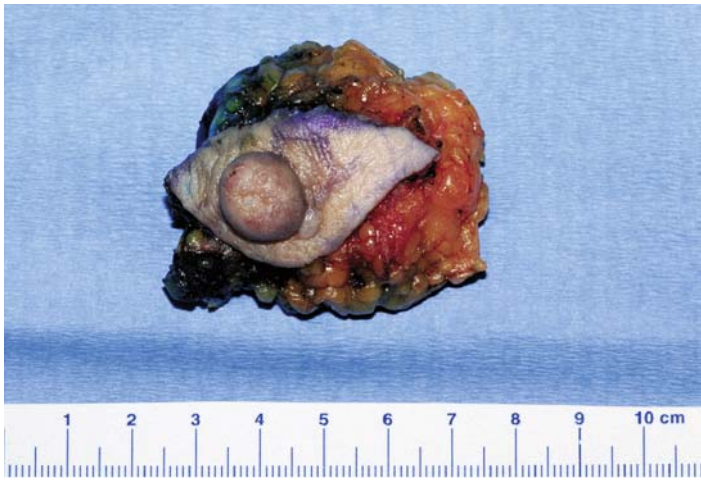Secondary NAC reconstruction was performed in a third of patients.



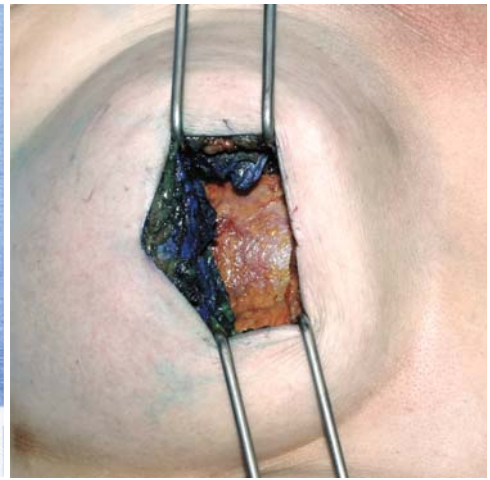
**a** medial retroareolar tumour



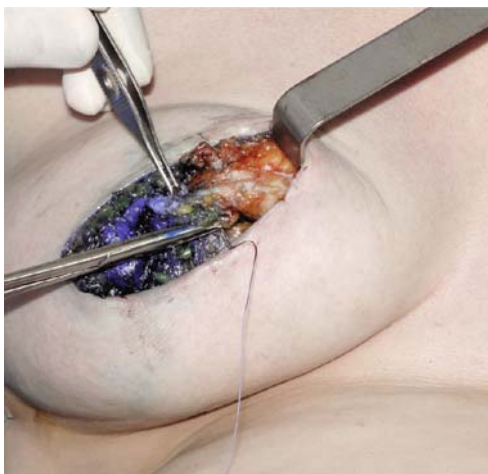**b** horizontal semielliptical excision with skin-gland dissection



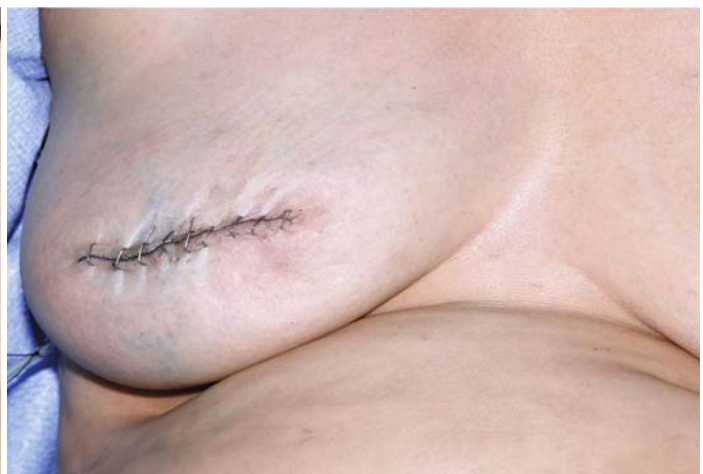**c** operative specimen with nipple areolar complex en bloc with the glandular cone



**d** NACectomy to the prepectoral fascia



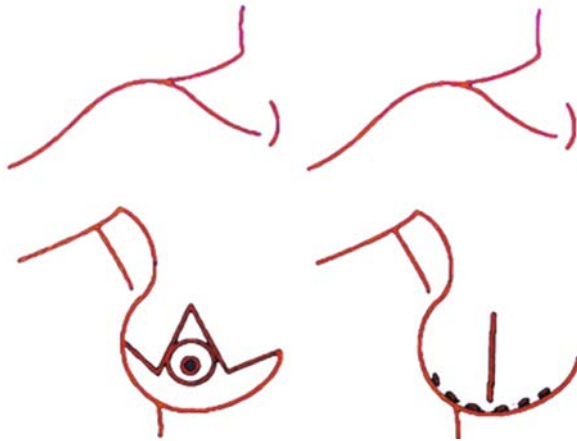
**e** reconstitution of glandular cone by approximation commencing deeply



**f** skin closure giving a good result in both form and volume

**Plate 2.1a-f** Surgical treatment of central tumours; NACectomy with horizontal incision





**Fig. 2.5** NACectomy with inverted-T scar

Patients were satisfied in more than 90% of cases, with a failure and poor result rate of 4.3%.

With a mean follow up in excess of 64 months, the overall survival was 96%, disease-free survival was 91%, and five-year local recurrence rate was 8.2%, half of which were remote from the initial tumourectomy.

## Conclusion

The management of central, retroareolar tumours is comparable to that of other conservative treatments. The challenge is to remodel the breast such that it retains a normal form prior to radiotherapy, because this form becomes fixed and subsequent surgery on an irradiated breast is much more difficult. The quality of the initial result from primary surgery is therefore paramount. (Results are displayed in Plates 2.3 and 2.4).

## Plastic Surgical Techniques in Breast Cancer Surgery (Oncoplastic Breast Surgery)

### Introduction

Conservative surgery in breast cancer management has long been the standard for tumours < 3 cm. More recent series have extended the indications for breast-

conserving surgery to include tumour sizes of up to 4 cm (Fisher et al. 1995), 5 cm (van Dongen 2000; Jacobson et al. 1995), and even larger for intraductal cancer (Fisher et al. 1995; Solin et al. 1996).

The predominant issue remains the compromise between a wide excision with clear margins and a satisfactory aesthetic result. This problem is far easier to solve if the breast volume is sufficient to allow an oncoplastic technique.

Thanks to a variety of plastic surgical techniques, this conflict can now be resolved in the majority of cases without producing a deformed breast (Clough et al. 1990).

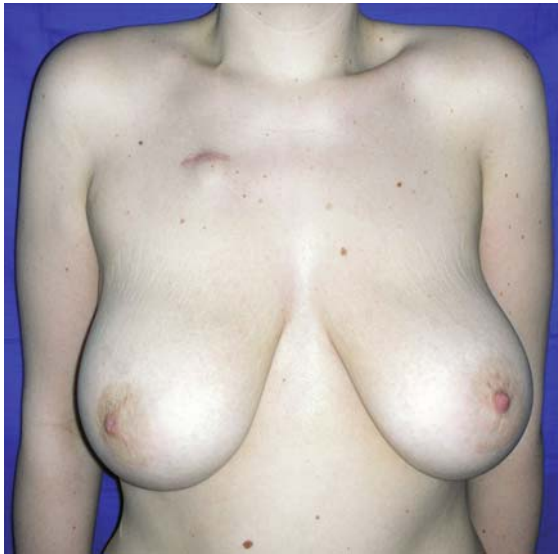Once remodelled, the breast is smaller and higher with a narrower base, but its form remains normal. A symmetrising procedure is frequently required on the contralateral breast. This may, if practical, be performed at the same operative sitting, but is usually performed some months after completion of all treatments, particularly radiotherapy.

The techniques used early in our experience included superior-pedicle, inverted-T mammaplasty, from plastic surgery, followed by J- and L-mammaplasties.

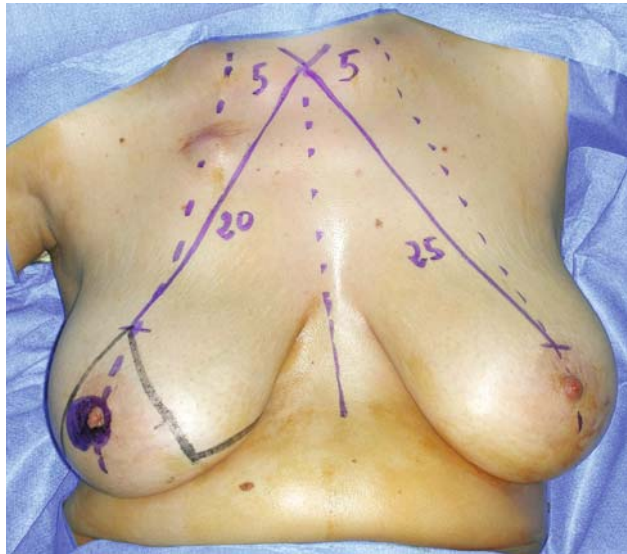
Other techniques have been developed over time and are adapted to specific tumour locations, including: inferior pedicle (for those at the junction of the superior quadrants), lateral mammaplasty (for laterally-based tumours), and the omega and V techniques (for superior and superomedial cancers, respectively). Medial tumours can be addressed with the mirror image of lateral mammaplasty: medial mammaplasty. Finally, techniques specifically intended for tumours around the IMF have been developed in order to minimise scarring and, if possible, symmetrisation on the contralateral side.

Oncoplastic techniques may be equally performed following neoadjuvant chemotherapy. Regression of the lesion, demonstrating response of the tumour to treatment, permits breast-conserving surgery so long as one allows sufficient time to ensure that surgery can be performed without undue haemorrhagic and infectious complications. On the other hand, we found that oncoplastic procedures after primary radiotherapy made for difficult subsequent surgery and generally poorer aesthetic results. Radiotherapy is thus reserved for postoperative treatment.

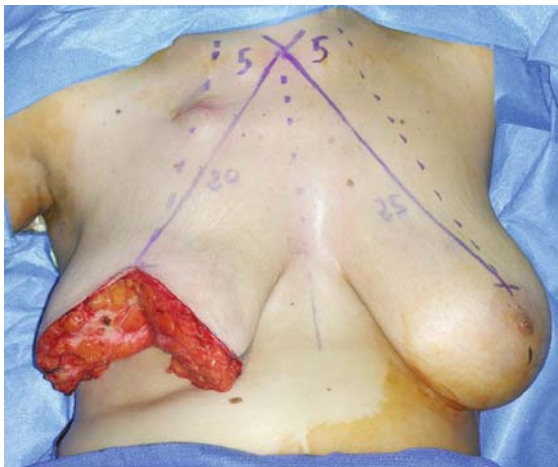
It is essential to clearly mark the excision margins with clips and document the procedure to enable the radiotherapist to calculate the optimal field of irradiation



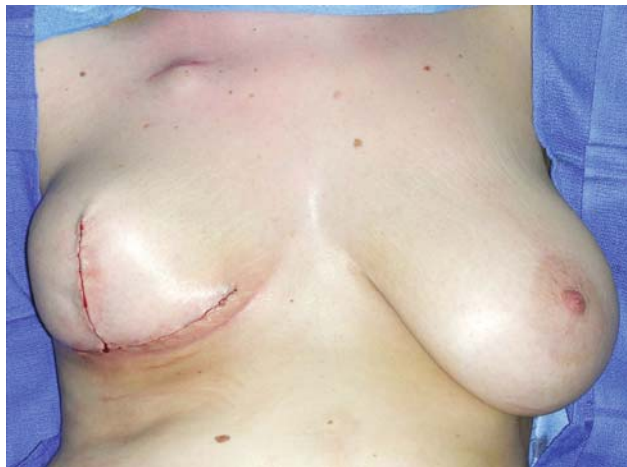**a** retroareolar central tumour



**b** inverted-T operative markings after neoadjuvant chemotherapy (segments 1 + 2 = 20 cm; segment 3 = 11 cm)



**c** very wide excision (weight of excised specimen: 330 g)



**d** reapproximation of glandular pillars and skin closure

**Plate 2.2a–d** Surgical treatment of central tumours; NAC excision associated with inverted-T mammoplasty

and, if necessary the boost required, for limitation of unnecessary irradiation.

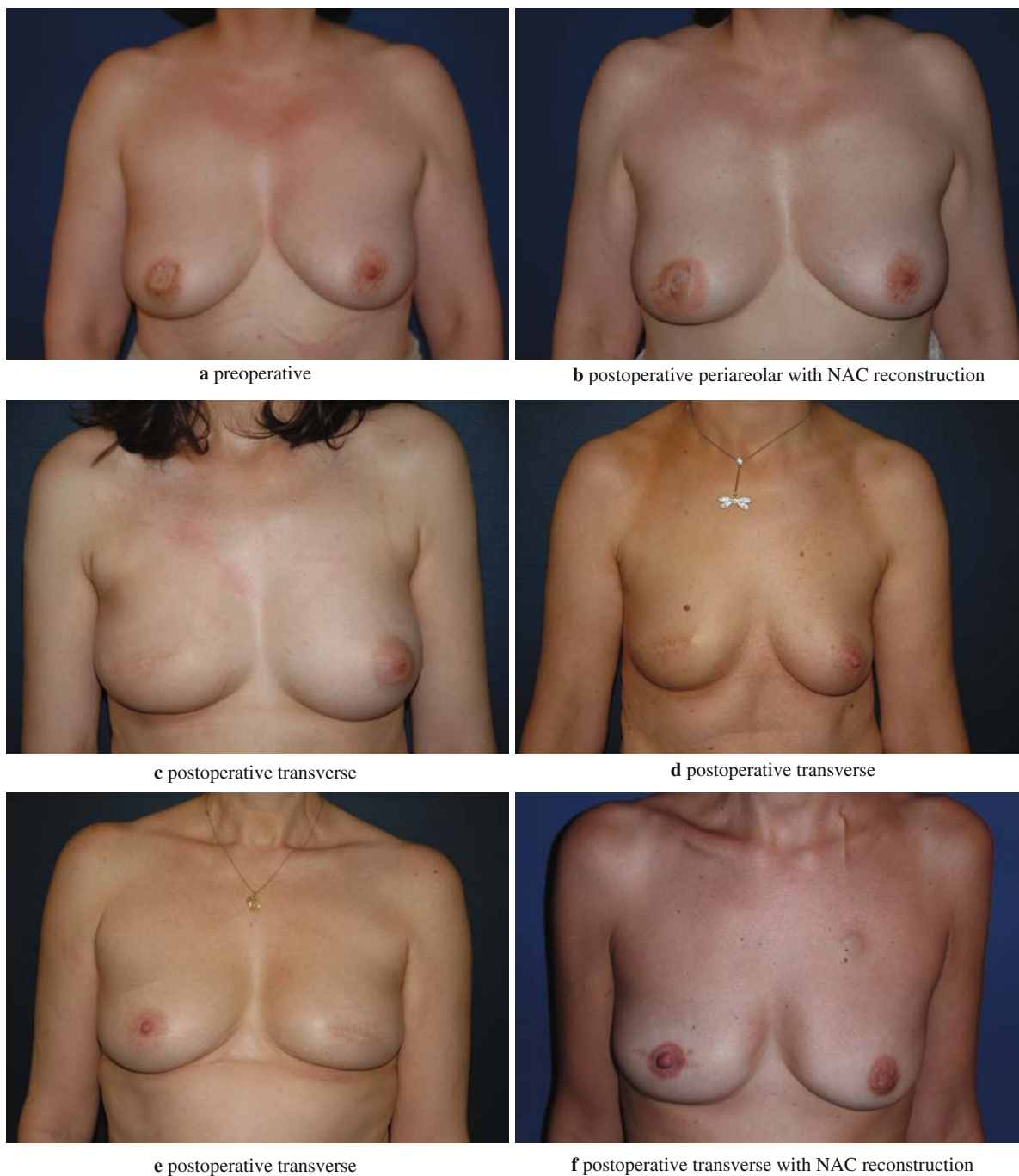At the Institut Curie we utilise ten plastic techniques according to tumour location (Figure 2.6). These therapeutic options may also be varied depending on the form and size of the breast, existing scars, and the requirement for cutaneous excision with some tumours. The desire to avoid symmetrising the contralateral breast also influences technique selection.

## ***Oncoplastic Breast Surgery Techniques***

### **Superior-Pedicle, Inverted-T Mammoplasty**

This technique is used for tumours at the junction of the inferior quadrants, as well as those inferolateral, inferomedial and close to the IMF (Plate 2.5).

The NAC, is supported on a superior-pedicle flap following de-epithelialisation, is elevated

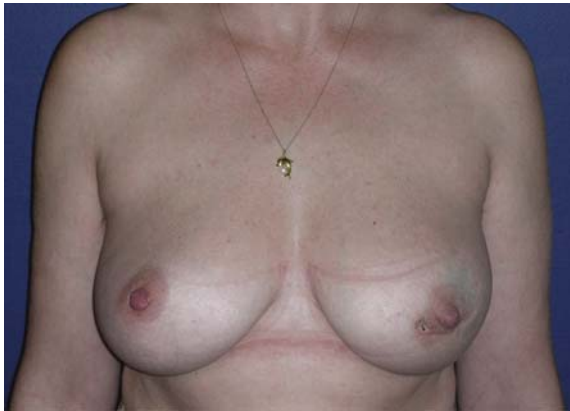
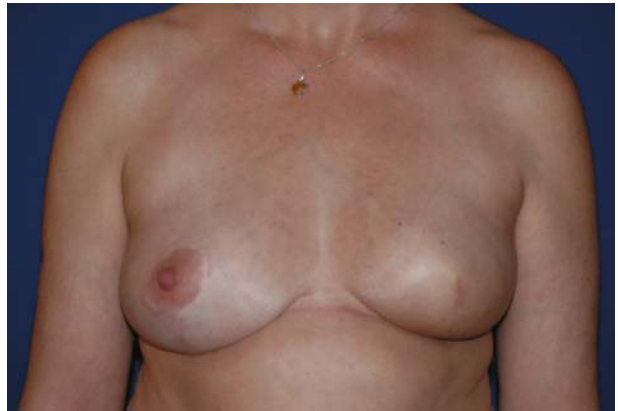
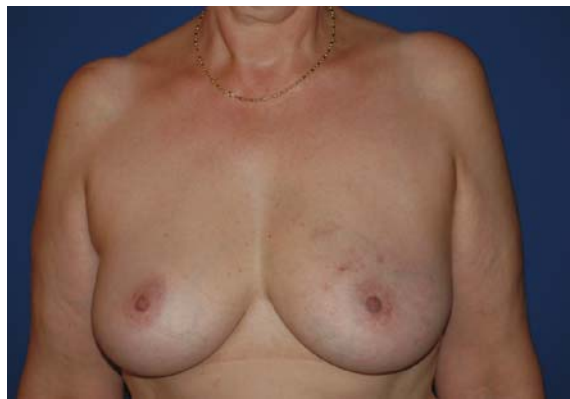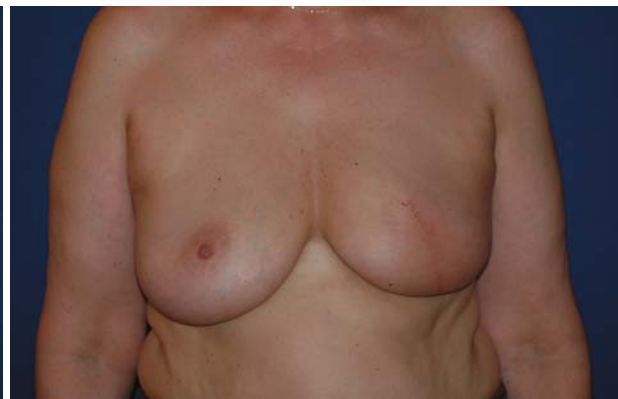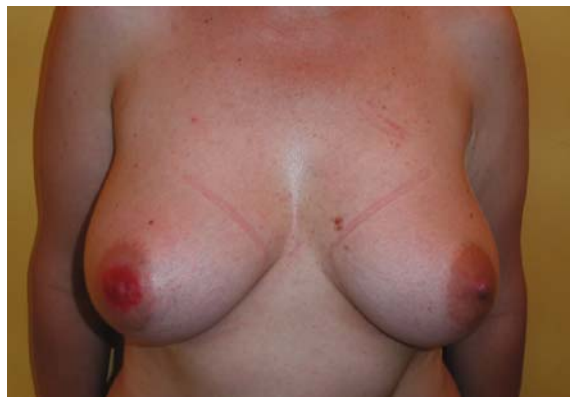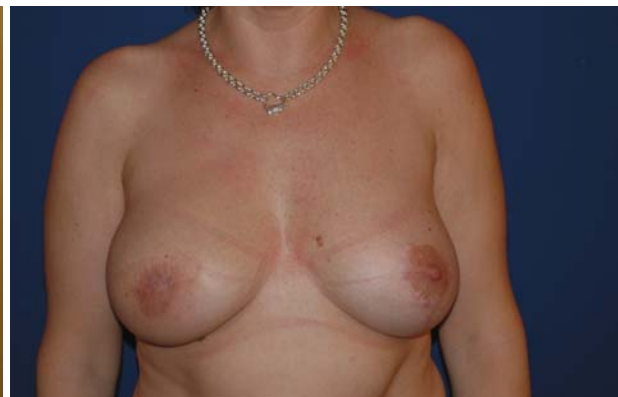**Plate 2.3a–f** NAC excision by periareolar or transverse techniques

(Fig. 2.5b). This flap is several millimetres thick and is plicated. The mammary gland is raised from the prepectoral fascia following incision at the IMF (Fig. 2.5c). Finally, the intervening gland is excised,

with a wide tumour and skin resection, at the junction of the inferior quadrants (Fig. 2.5f). The breast pillars are then reapproximated and the skin closed (Fig. 2.5g).



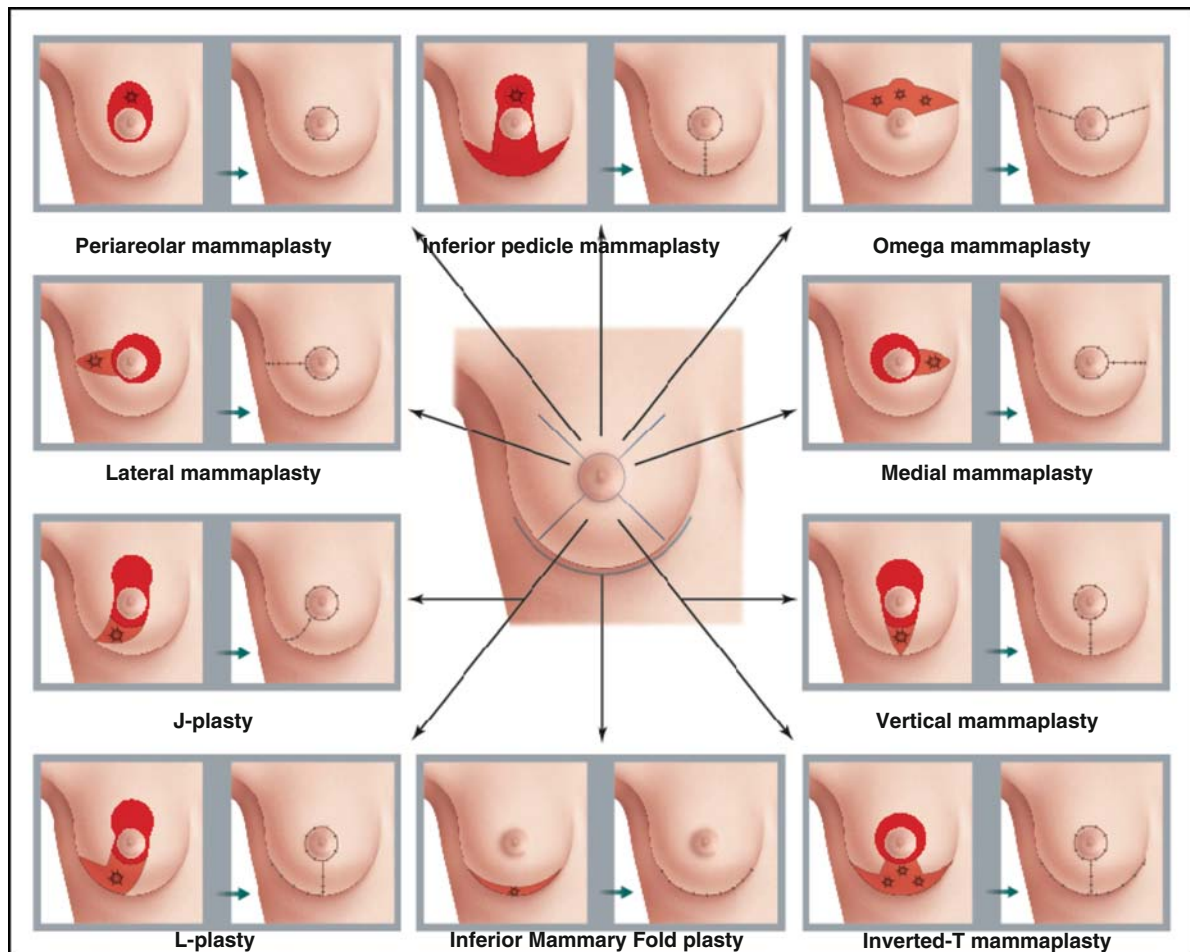
**a** preoperative**b** postoperative inverted-T**c** preoperative**d** postoperative J-plasty**e** preoperative**f** postoperative L-plasty**Plate 2.4a-f** NAC excision with plastic surgical remodelling

In this fashion, a satisfactory result can be obtained producing a smaller, higher and narrower breast (Plate 2.6).

When contralateral symmetrisation is required, it is usually done with the same technique and gland

resection (with both resections being weighed), and synchronously if circumstances allow.

If the tumour is lateral or medial, a glandular rotation flap may be fashioned in order to fill the parenchymal defect (Plate 2.6).



**Fig. 2.6** Selection of Oncoplastic Breast Surgery technique according to tumour location

In cases of significant breast hypertrophy, an immediate NAC graft, using Thorek's technique, may be used (Thorek et al. 1989). This involves an inverted-T excision with full-thickness harvesting of the NAC, which is grafted at the summit of the vertical incision. This technique applies principally to very large and ptotic breasts where the NAC pedicle will be too long and therefore poorly vascularised (Figs. 2.7).

### Vertical-Scar Mammoplasty

This technique is used for tumours at the inferior quadrant junction in smaller, non-ptotic breasts of medium size. It is the same as the inverted T, but without the IMF incision (Plate 2.8). It derives from

Lejour's vertical-scar technique (Lejour et al. 1999), and on occasion a glandular rotation flap (Plate 2.8d) is required to reconstitute the defect left after tumourectomy.

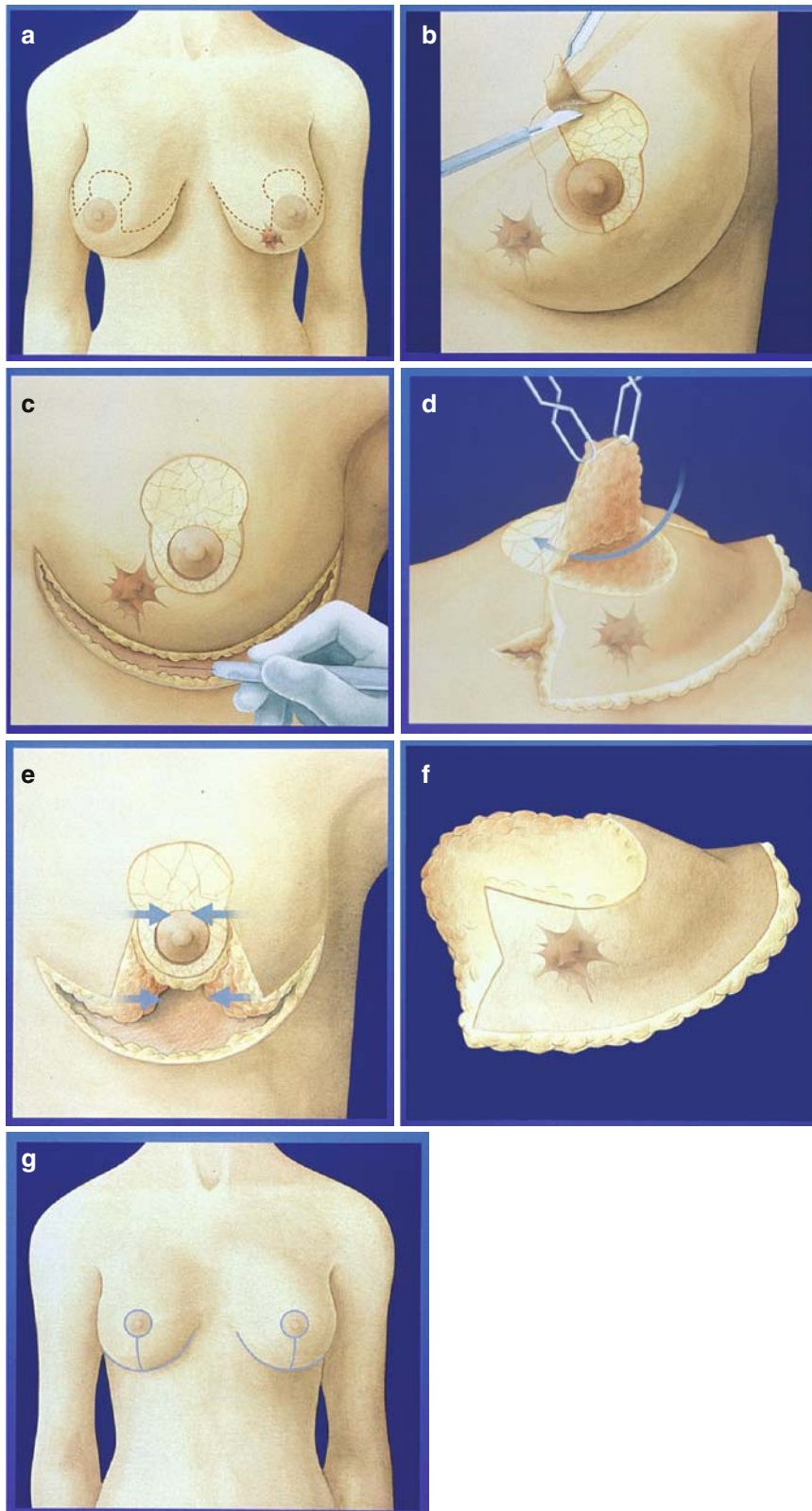
### J- and L-Mammoplasty

These have similar indications to the vertical-scar and are ideal for tumours localised to the inferior or infero-lateral quadrants (Plate 2.9).

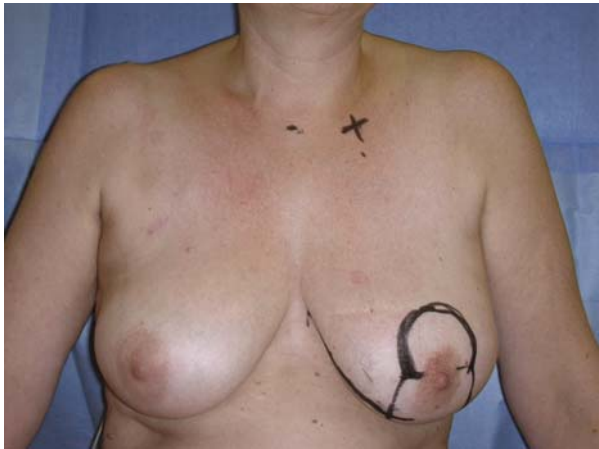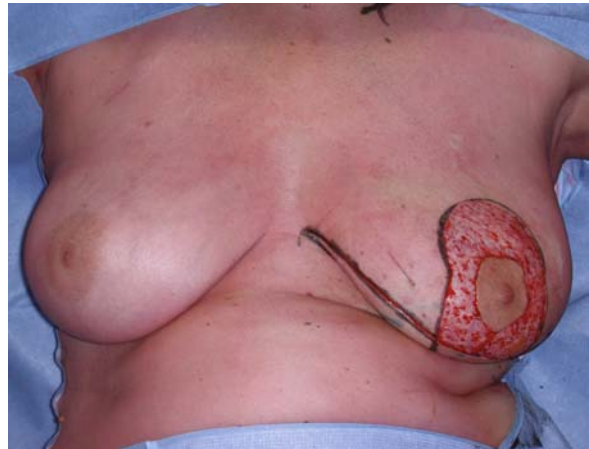
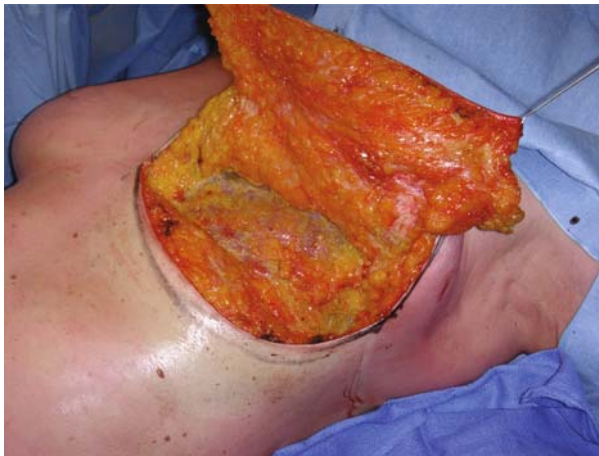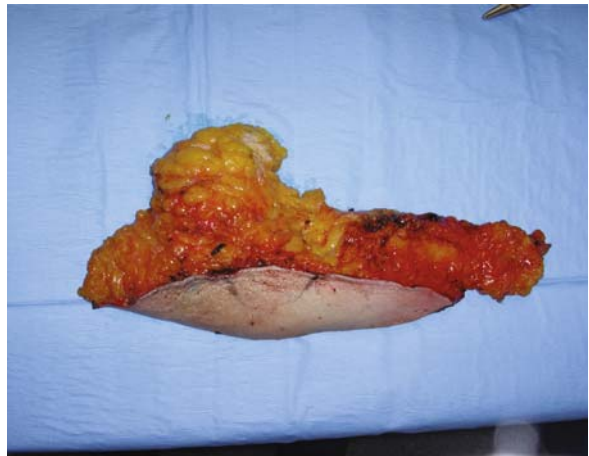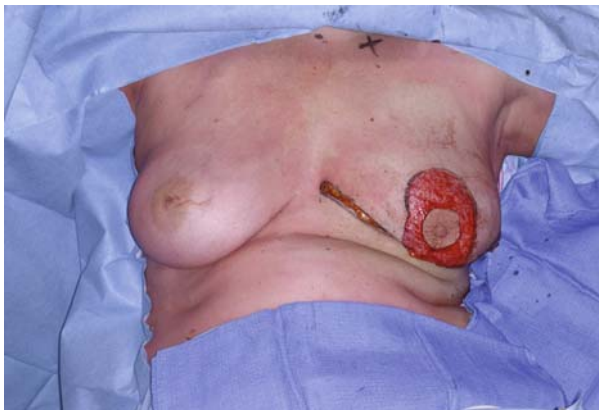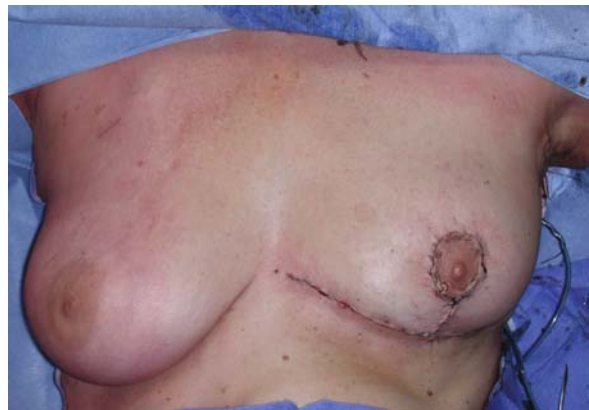The vertical incision below the areola is extended laterally, allowing limitation of the inframammary scar in large-volume breasts.

These techniques sit between a pure vertical-scar and an inverted-T mammoplasty.





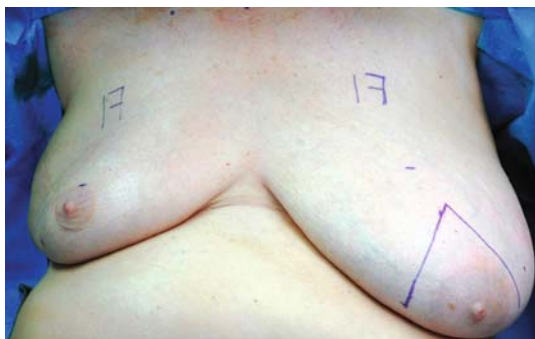**Plate 2.5a–g** Schematic of inverted-T mammoplasty **a.** operative design for tumour lying within area of excision; **b.** periareolar deepithelialisation; **c.** IMF incision and dissection of the breast at the pre-pectoral plane; **d.** raising of the superiorly-based NAC flap; **e.** approximation of the breast parenchymal pillars; **f.** very wide excision specimen; **g.** resulting scars

**a** operative design**b** periareolar deepithelialisation**c** elevation of the breast at the pre-pectoral plane**d** wide excision specimen**e** breast following tumourectomy**f** on-table result**Plate 2.6a–f** Inverted-T mammaplasty for inferior quadrant tumours**Inferior-Pedicle Inverted-T Mammaplasty**

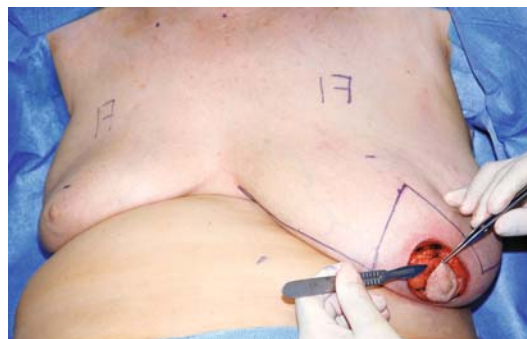This technique is ideal for superior quadrant junction tumours that are close enough to the areola (particularly

in ptotic breasts) (Plate 2.10). As in aesthetic surgery, it allows rejuvenation via the inferior pedicle; the zone of quadrantectomy is at the junction of the superior quadrants (Plates 2.10 and 2.11).

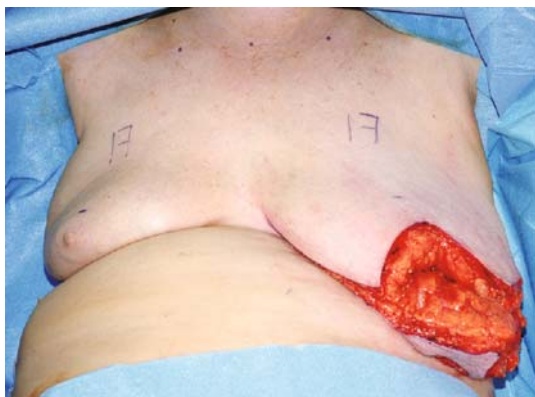




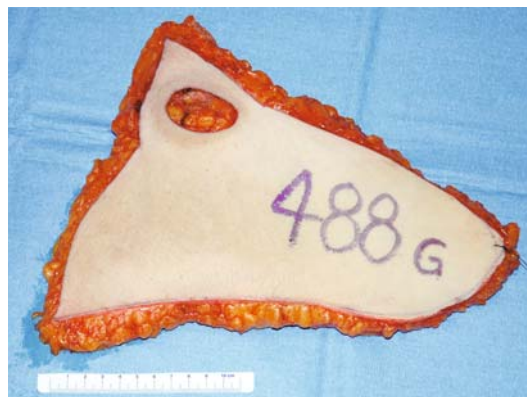**a** preoperative design



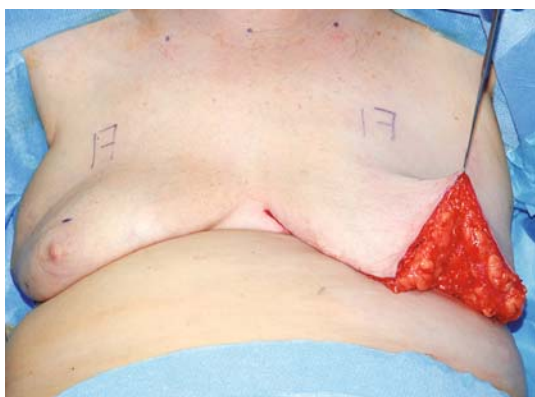
**b** NAC harvest as graft



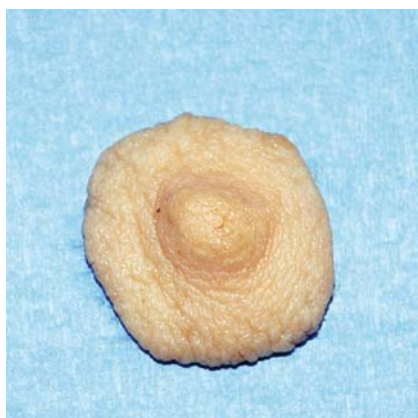**c** wide tumour excision



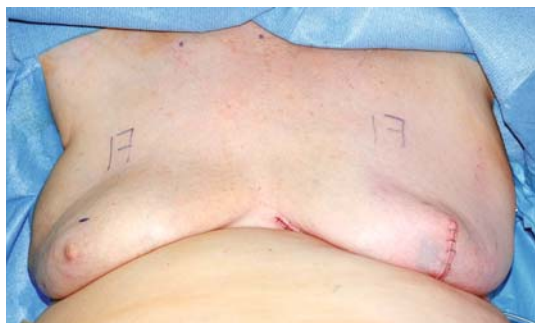**d** operative specimen



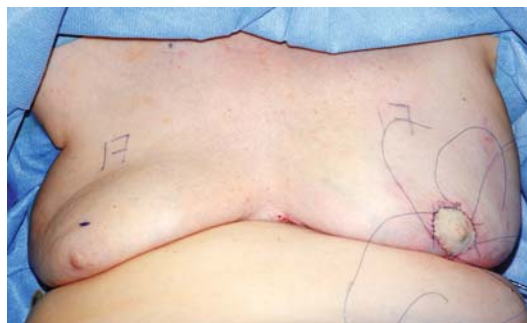
**e** remaining breast parenchyma



**f** NAC graft

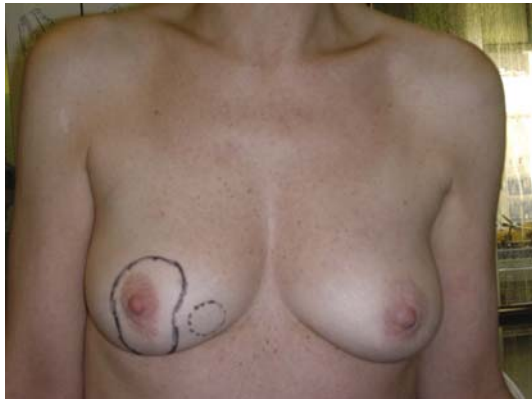

**g** parenchymal reconstitution

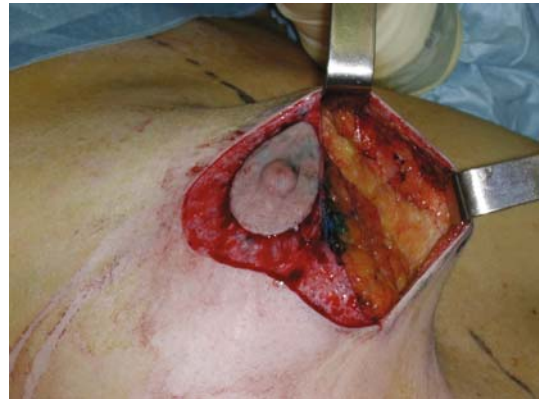

**h** application of the NAC graft

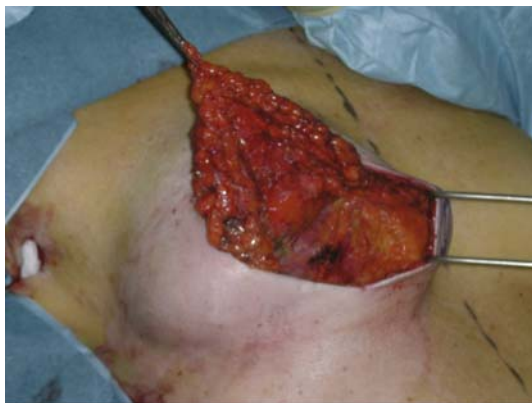



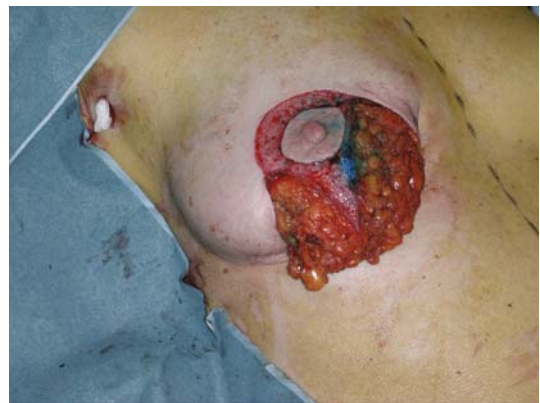**a** vertical scar design for infero-medial tumour



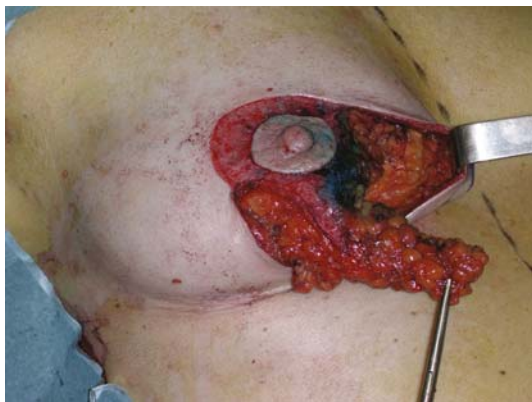**b** wide tumour excision



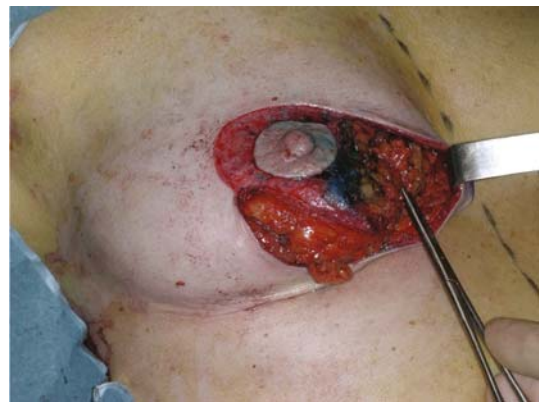**c** dissection of lateral flap



**d** lateral parenchymal flap



**e** length of lateral flap

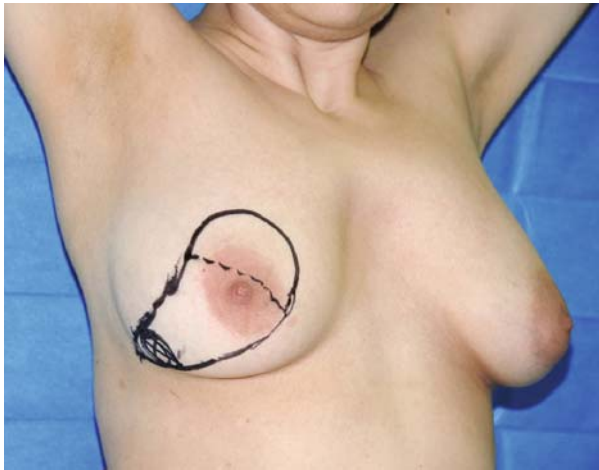

**f** lateral parenchymal flap advanced to fill tumourectomy defect

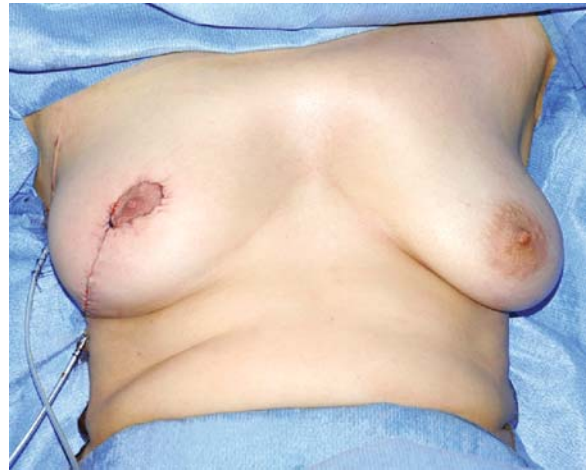**Plate 2.8a-f** Vertical-scar technique for inferior tumours

The resulting scars are identical to those obtained with superior-pedicle inverted-T techniques (Plate 2.10f).

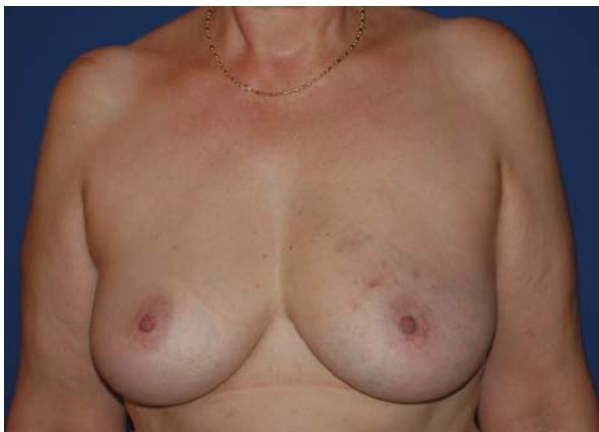The resection, where tumour and skin are removed en bloc to the pectoral plane, corresponds to the future site of the NAC (Plate 2.10a). The skin is raised later-



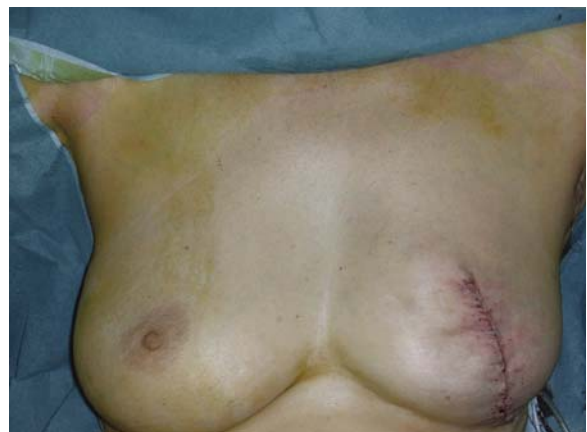**a** operative design for infero-lateral tumour



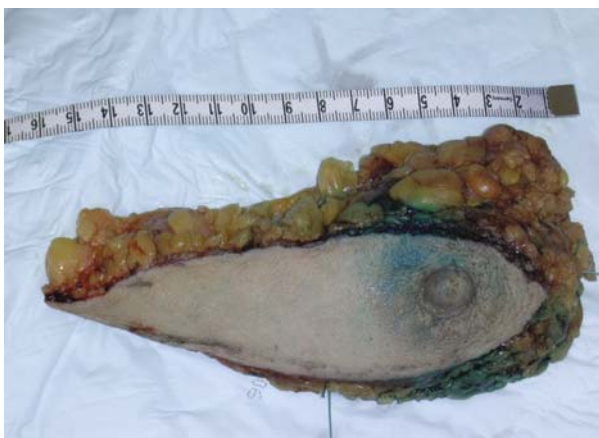**b** on-table result with NAC preservation



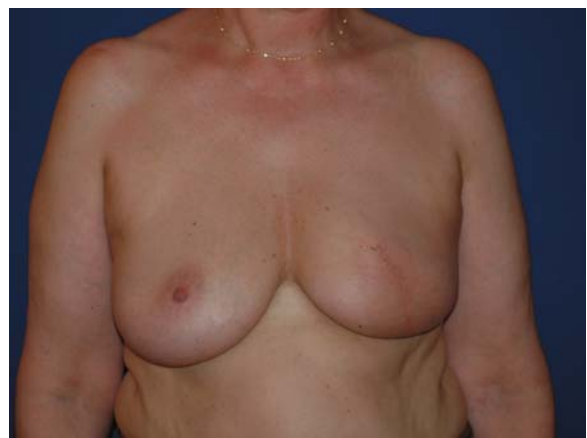**c** pre-operative



**d** post-operative without NAC preservation



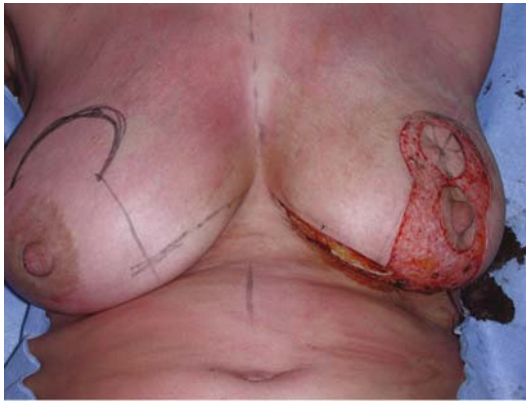
**e** operative specimen



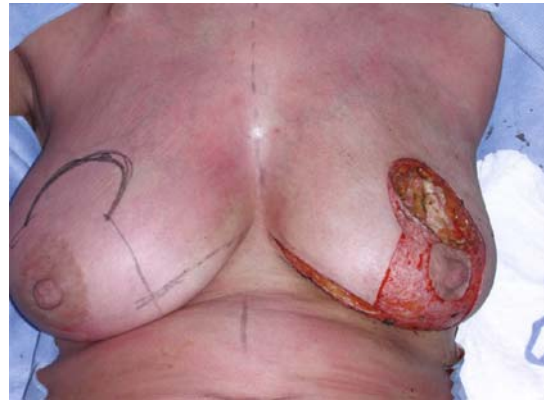**f** mature scar

**Plate 2.9a-f** J-mammoplasty technique

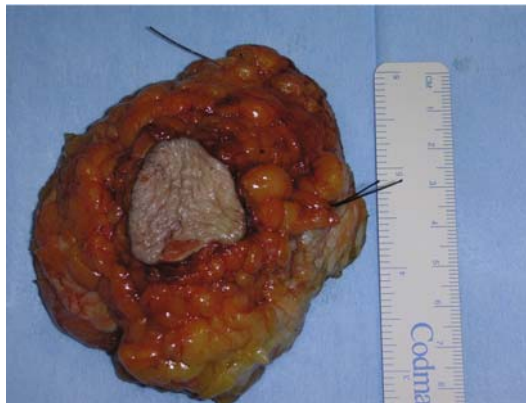



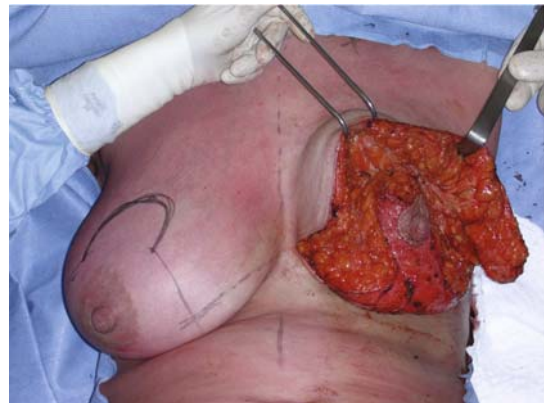**a** operative markings for left supra-areolar tumour



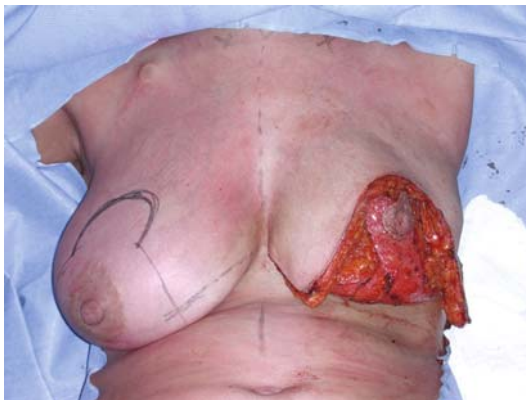
**b** wide tumour excision



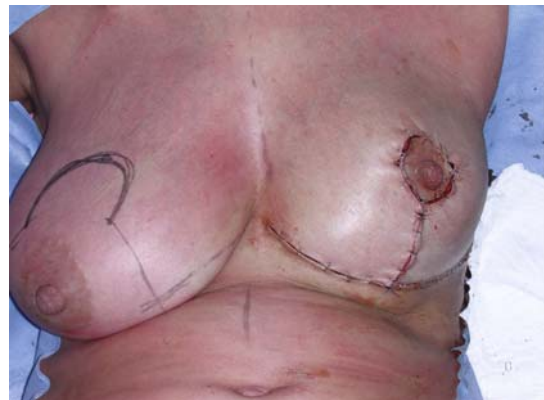**c** operative specimen



**d** mobilisation of breast parenchyma



**e** inferiorly-pedicled NAC filling tumourectomy defect



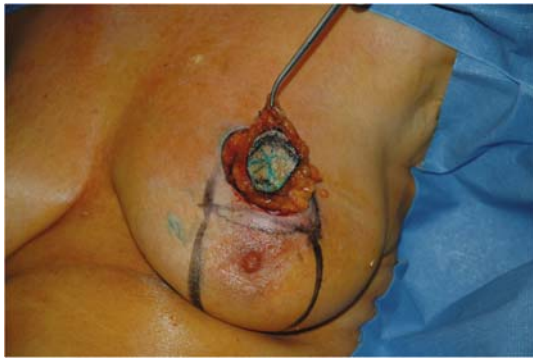**f** on-table result

**Plate 2.10a-f** Inferior-pedicle mammoplasty for supra-areolar tumours

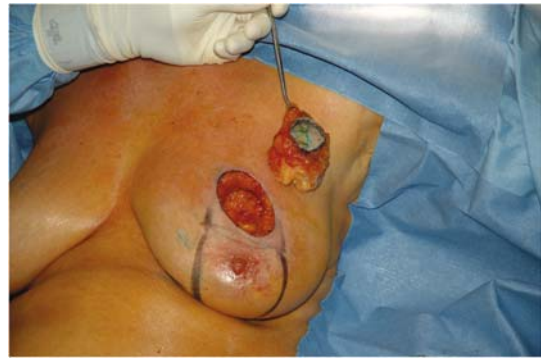ally, leaving the NAC vascularised by an inferior pedicle (Plate 2.10d,e). Thick parenchymal flaps supplied by intercostal perforators, are then raised and transposed

to fill the tumourectomy defect. Skin closure completes the procedure, and the breast is higher on the chest wall, thereby correcting ptosis (Plate 2.10f).

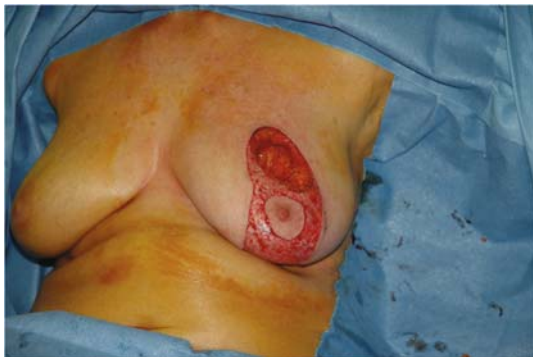



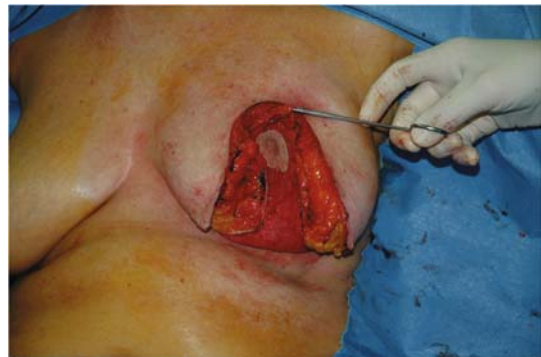a left supra-areolar tumour incised



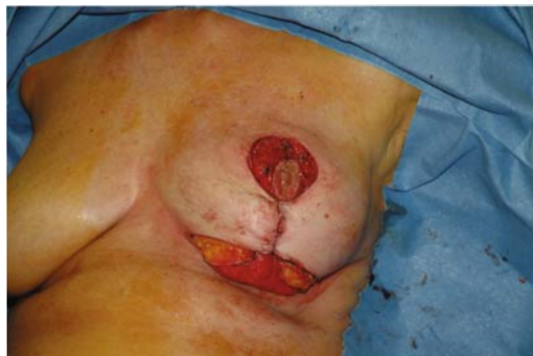b tumour excised with overlying skin



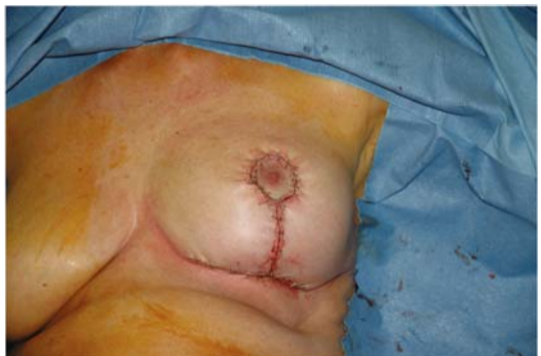c periareolar deepithelialisation



d advancement of NAC on inferior pedicle



e closure of the vertical scar



f final result

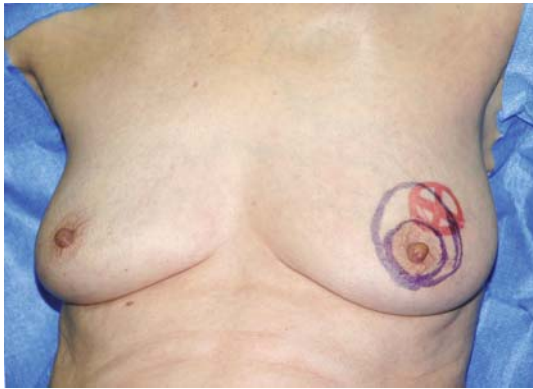**Plate 2.11a–f** Inferior-pedicle mammaplasty for supra-areolar tumours

This technique facilitates the removal of any skin associated with the tumour, and gland resection is, as usual, to the prepectoral plane (Plate 2.11b).

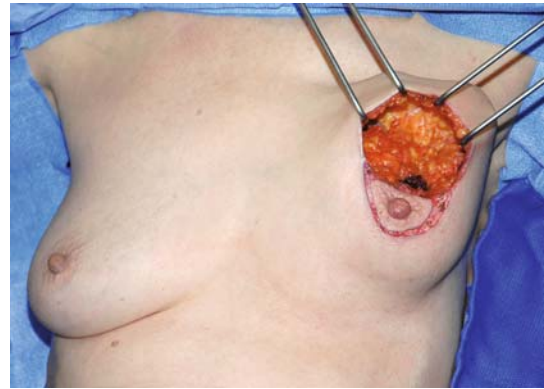
If required, symmetrisation is more easily performed on the contralateral breast with a superior-pedicle procedure.

### Periareolar Mammaplasty

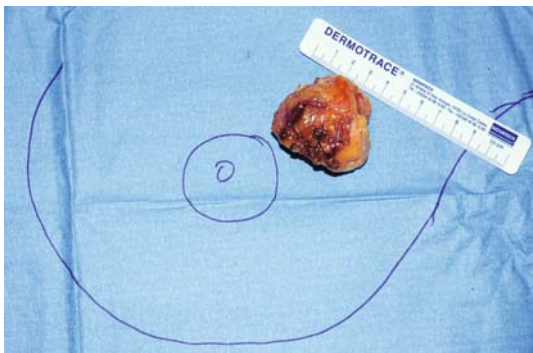
This is used for tumours at the junction of the superior quadrants, as well as those superolateral or -medial, but that are close to the areola (Plates 2.12 and 2.13). The technique is comparable to the 'round block' used



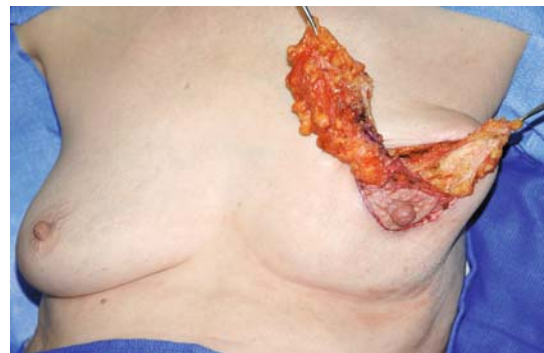**a** operative design for left periareolar tumour



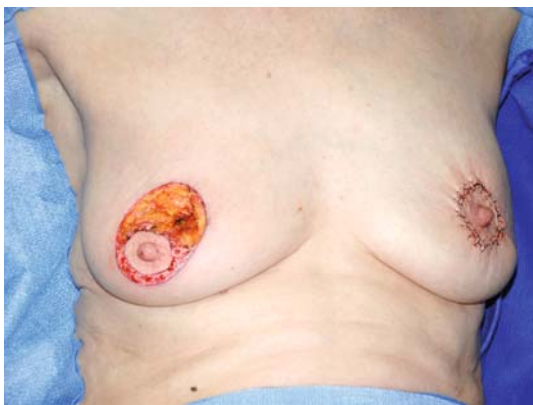**b** wide tumourectomy



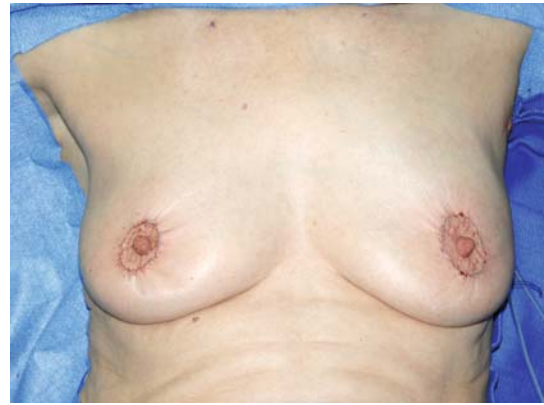**c** excision specimen



**d** mobilisation of parenchymal flap



**e** closure and use of identical technique for symmetrisation



**f** final result

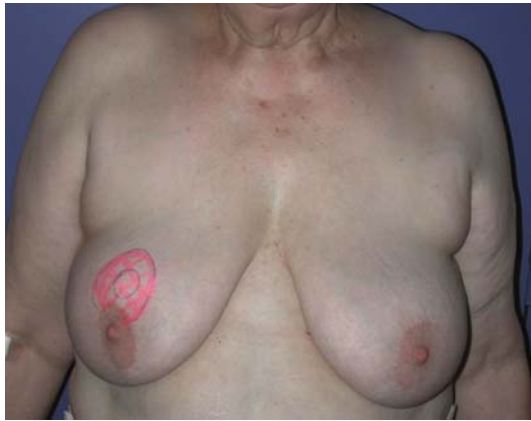**Plate 2.12a–f** Periareolar technique for tumours close to the areola that require breast remodelling

in aesthetic surgery (Benelli et al. 1990). On occasion, inferior tumours close to the areola are also amenable to this technique.

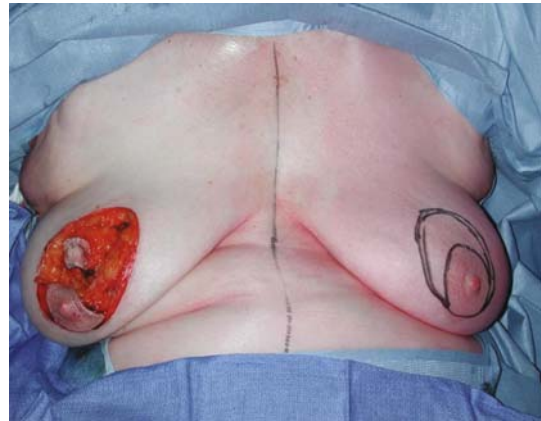
Following oval periareolar de-epithelialisation, except if the tumour is adjacent to skin, the superior quadrant skin is raised and a wide tumourectomy is

performed (Plate 2.12b). The glandular pillars are mobilised (Plate 2.12d), rotated and sutured to one another, allowing reconstitution of the gland, which will have a slightly narrower base. The skin is then closed, gathering the larger oval to the smaller areola to yield a pleated appearance (see Plate 2.12f).

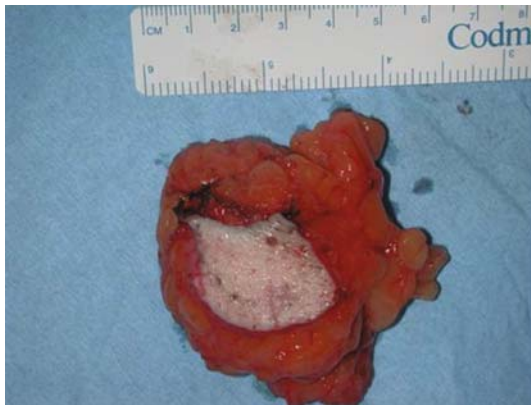



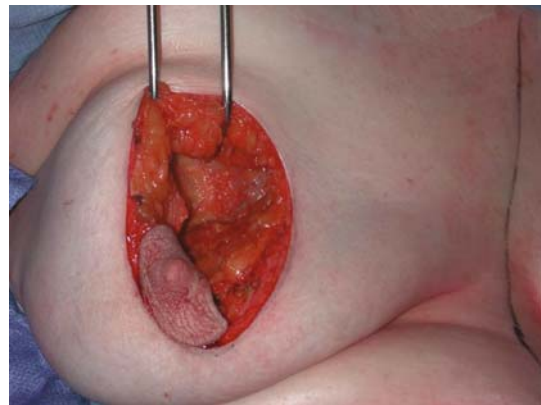
a operative design for right supra-areolar tumour



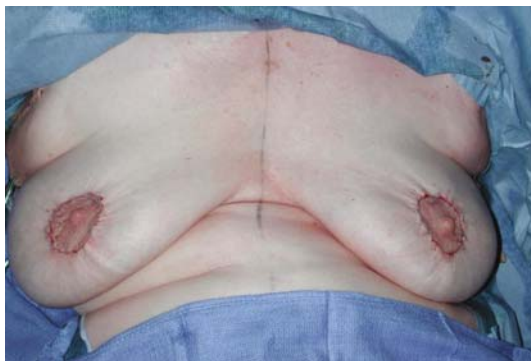b wide tumorectomy



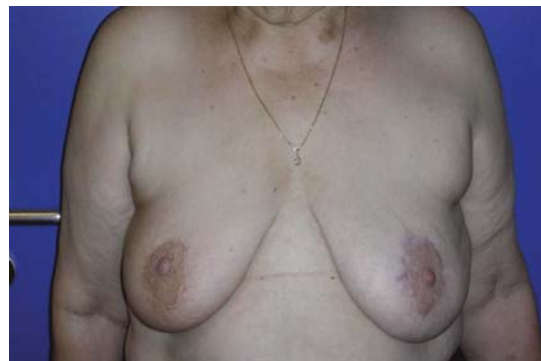c excision specimen



d mobilisation of breast parenchyma



e closure and symmetrisation



f mature result

**Plate 2.13a-f** Periareolar technique

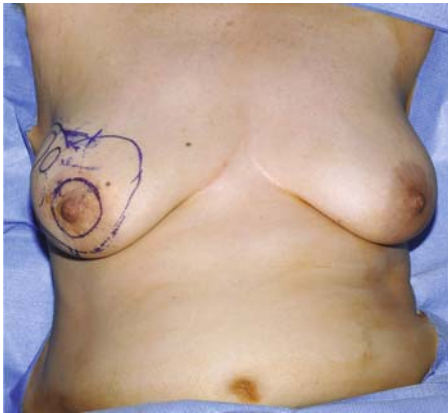### Lateral Mammoplasty

Tumours at the lateral quadrant junction or, superolateral, are by far the most frequent, and this technique is therefore finding increasing use at our institution (Plates 2.14 and 2.15).

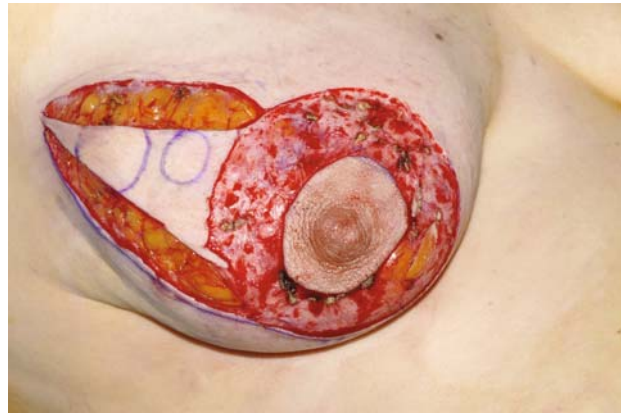
Being a simple and reliable intervention with minimal skin-gland dissection, closure is both easy and reliable.

After periareolar de-epithelialisation a cutaneo-glandular incision is made to the prepectoral fascia (Plate 2.14c). This quadrantectomy removes the tumour in a wide resection (Plate 2.14d).

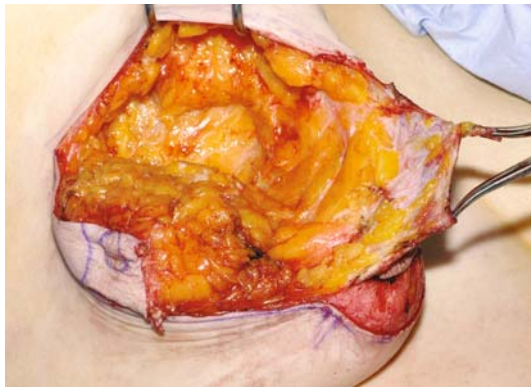



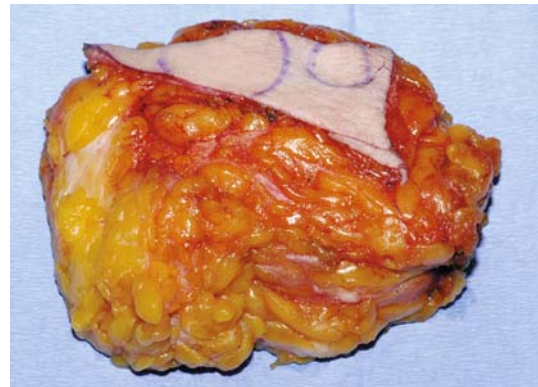
**a** operative design for right multifocal tumour



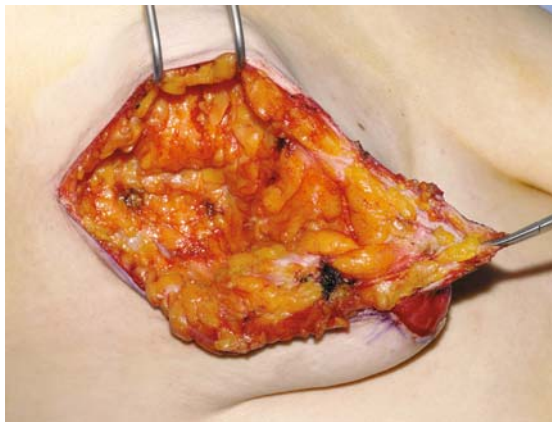
**b** periareolar deepithelialisation



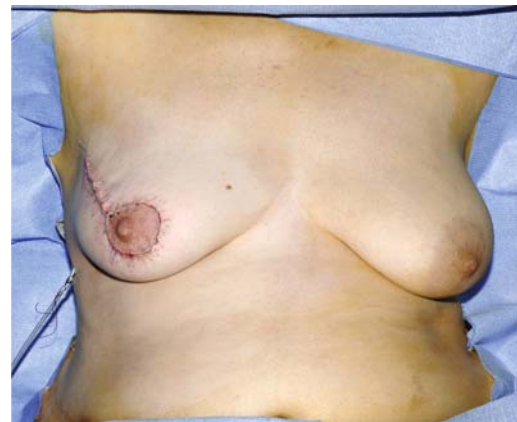**c** en bloc skin and gland excision to pre-pectoral fascia



**d** operative specimen



**e** tumorectomy defect



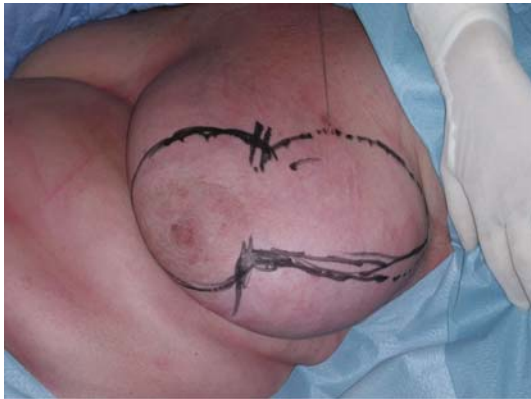**f** on-table result

**Plate 2.14a–f** Lateral mammaplasty for tumours of the lateral quadrants

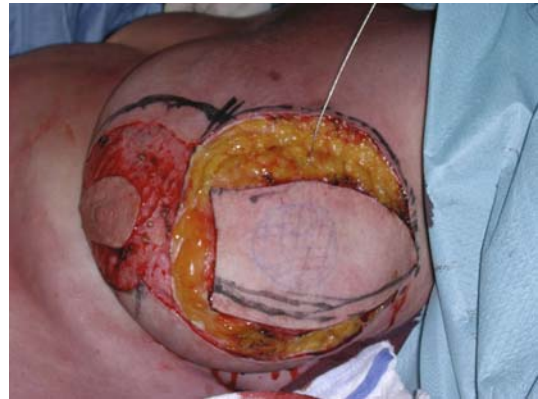
The breast is then raised, if required, at the subglandular plane, and the gland and skin are reapproximated to produce a higher breast with a narrower base.

The resulting scar is periareolar with a lateral radial extension (Plate 2.14f).

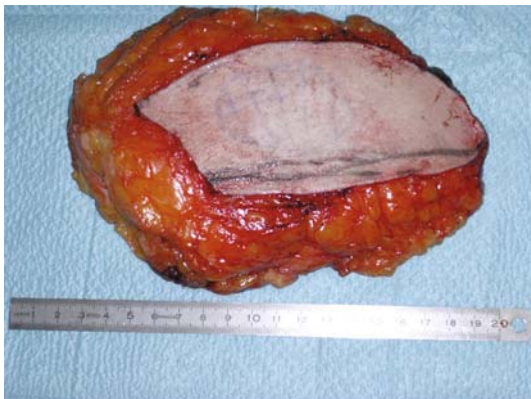
The NAC is transposed higher and more medially to avoid the inevitable inferolateral retraction following radiotherapy. Symmetrisation may be performed at the same time or later using the same technique.



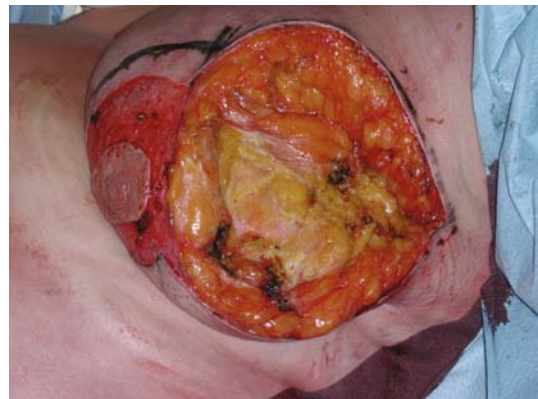a operative design for left supero-lateral tumour



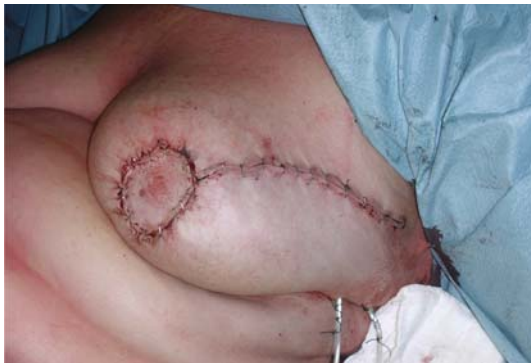b periareolar deepithelialisation



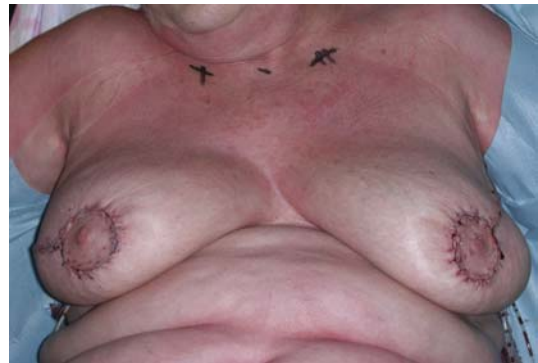c operative specimen



d tumourectomy defect



e wound closure



f on-table result with symmetrisation

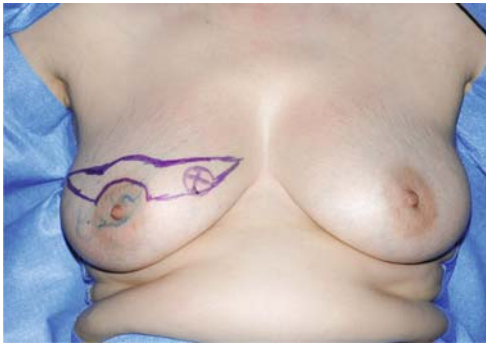**Plate 2.15a-f** Lateral mammaplasty for tumourectomy and immediate symmetrisation

One can sometimes stagger the skin and gland incisions to prevent the cutaneous scar from riding too high. A glandular flap is used to fill the deficit produced by the tumourectomy.

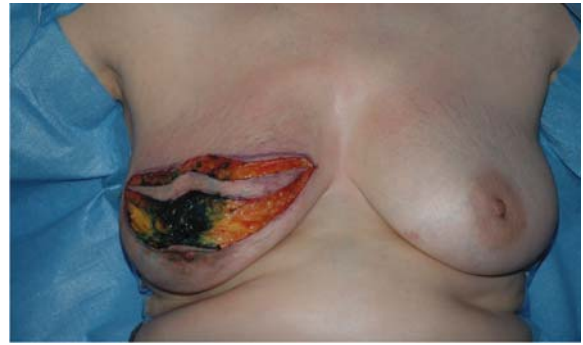### Omega Mammoplasty

This technique is ideal for superior quadrant and superomedial tumours, particularly in ptotic breasts

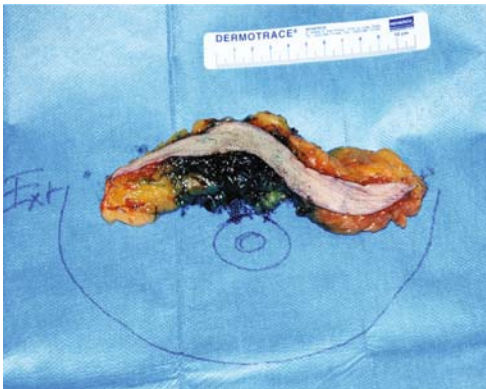




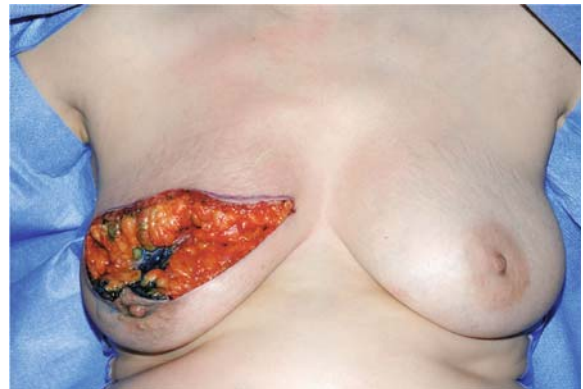**a** operative design for right supero-medial tumour



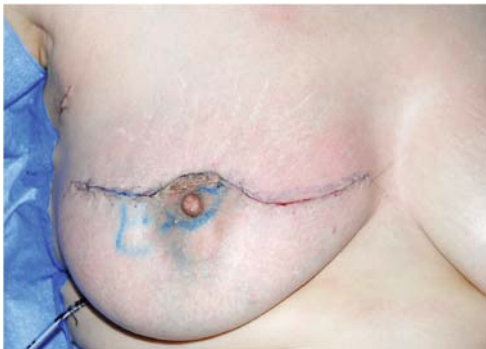**b** incision



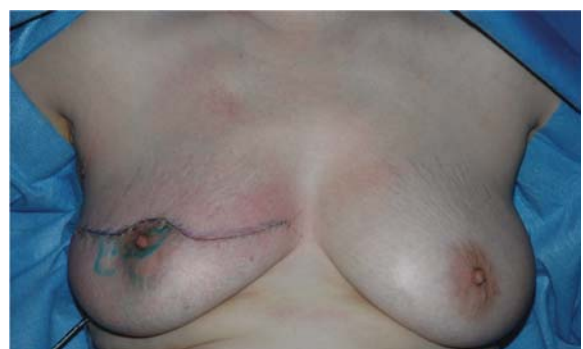**c** operative specimen



**d** tumourectomy defect



**e** wound closure



**f** on-table result showing good form and volume

**Plate 2.16a-f** Omega mammaplasty

(Plate 2.16a) that involves an en bloc excision of skin, gland and tumour, which is widely resected to the prepectoral plane (Plate 2.16).

The inferior quadrants and NAC are elevated and attached to the upper part following excision.

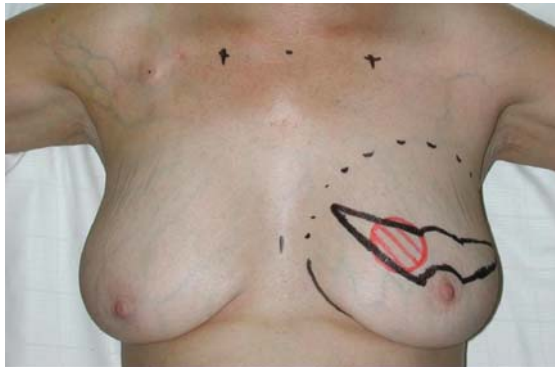
This simple technique allows the management, without extensive skin-gland dissection, of tumours in diffi-

cult locations (superomedial, particularly those situated very high) in combination with ptosis correction.

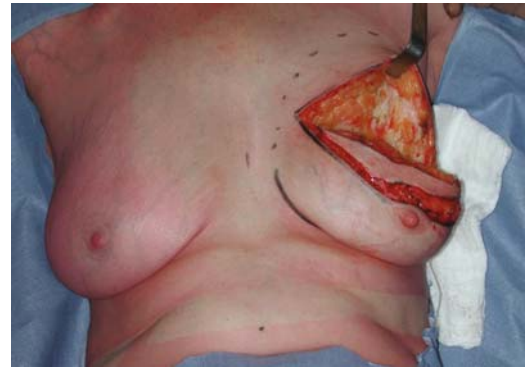
The skin associated with the tumour is removed and the resulting scar invariably improved by radiotherapy.

Contralateral breast symmetrisation is generally performed with an alternative technique (Plate 2.17).

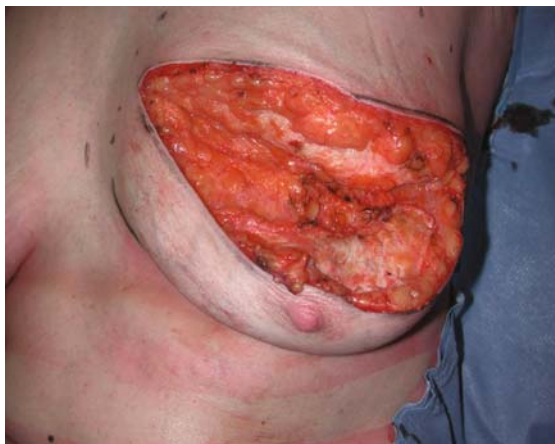



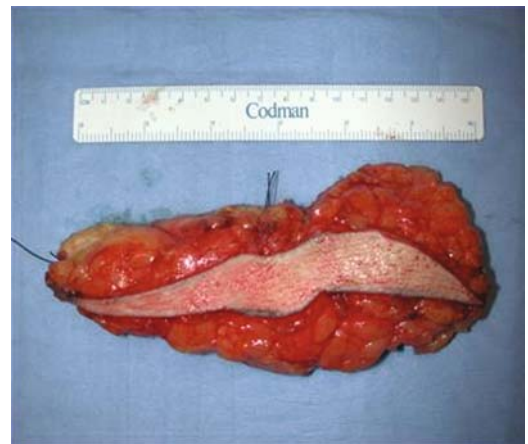a operative design for left supero-medial tumour



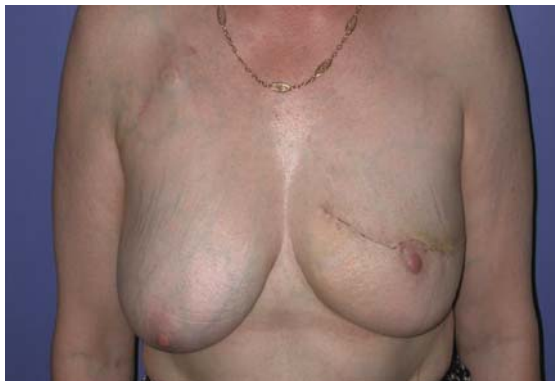b incision



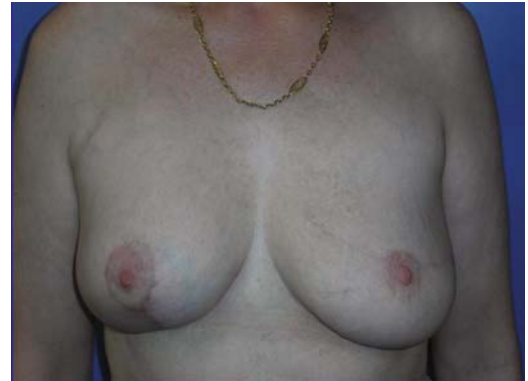c tumourectomy defect



d operative specimen



e early result



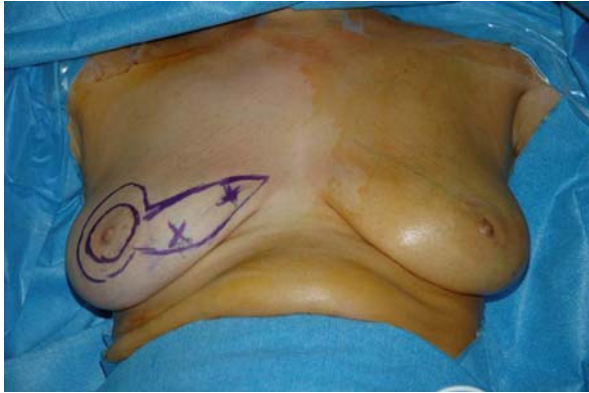f result after radiotherapy with vertical scar contra-lateral symmetrisation

**Plate 2.17a-f** Omega technique and vertical-scar contra-lateral symmetrisation

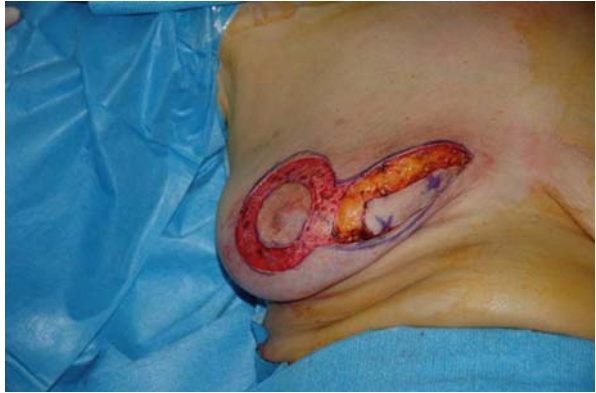### Medial Mammoplasty (Plate 18)

The medial mammoplasty technique for medial tumours is conceptually equivalent to the lateral mammoplasty. It

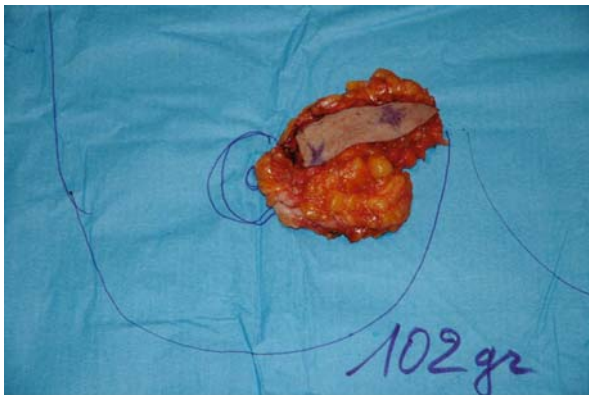
is, however, more challenging due to the much reduced tissue volume and relative immobility of the inferomedial breast. Furthermore, inferomedial tumours frequently require skin to be included with the tumour resection.



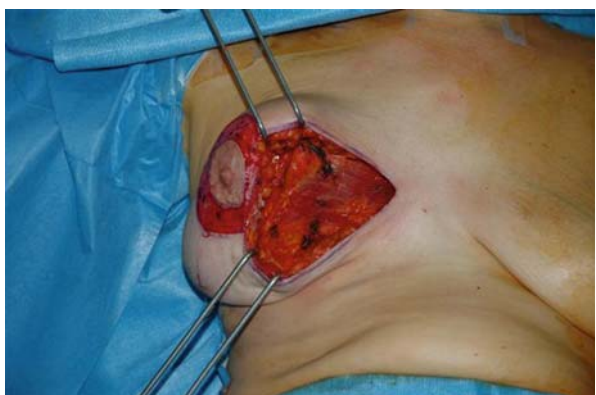**a** operative design for right bifocal medial pole cancer



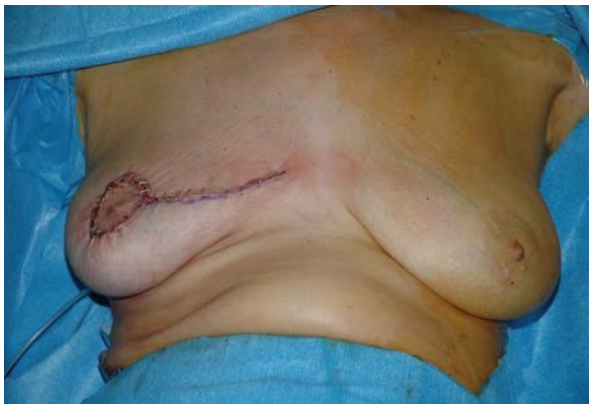**b** peri-areolar deepithelialisation and incision



**c** excision specimen



**d** tumourectomy defect



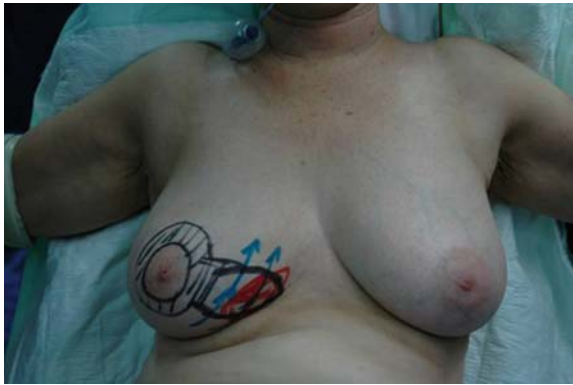**e** on-table result

**Plate 2.18a–e** medial mammaplasty technique with NAC repositioning and direct closure

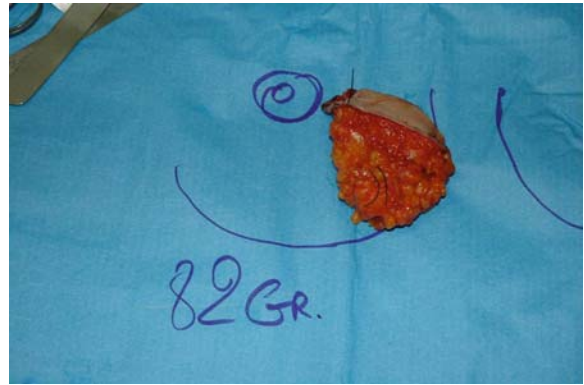Periareolar de-epithelialisation and radial extension for tumour excision are similarly performed. Because of the relative paucity of gland, however, suture of the adjacent breast pillars is not always possible. In these cases, a

lateral cutaneoglandular flap (Plate 2.19) is raised by incising the inframammary fold and then rotated medially into the defect. As usual, the resulting breast has a narrower base and sits higher on the thoracic wall.

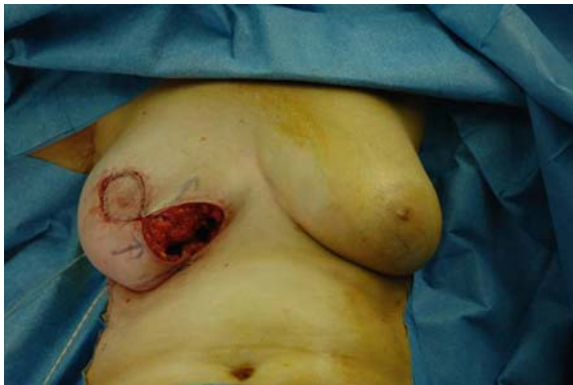



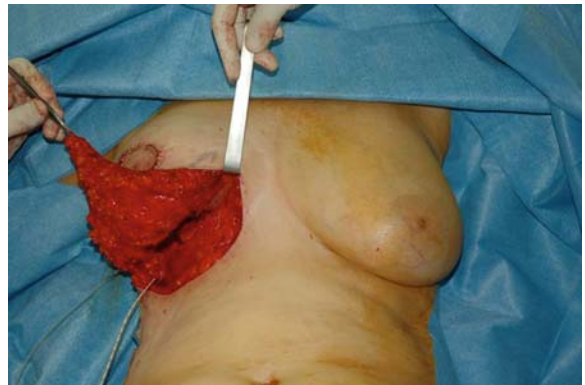a operative design for large medial pole tumour



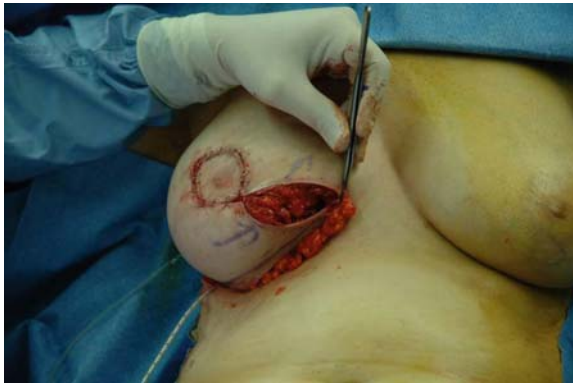b excision specimen



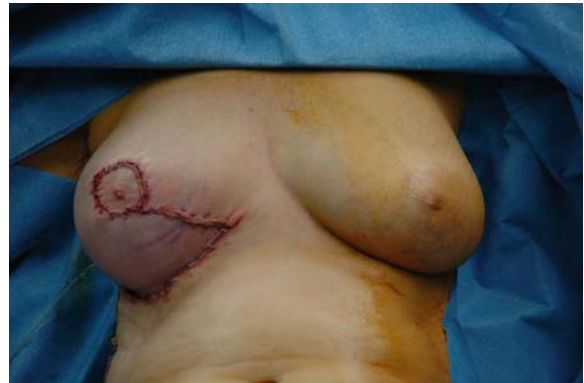c tumorectomy defect



d elevation of lateral cutaneo-glandular flap



e rotation of flap



f on-table result

**Plate 2.19a–f** medial mammaplasty technique with lateral cutaneo-glandular rotation flap

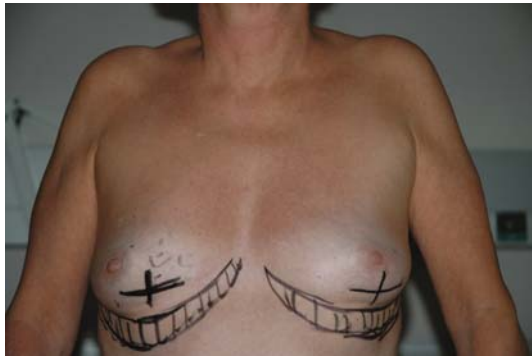### Inferior Mammary Fold (IMF) Mammaplasty

Designed for tumours at or slightly above the IMF, this technique makes it possible to avoid significant scars (as with the inverted-T) by lowering the IMF. This simple technique can be associated when required with one or two adipodermal flaps (derived from Holström's technique, Chapter 4) if the glandular deficit is significant (Plate 2.20).

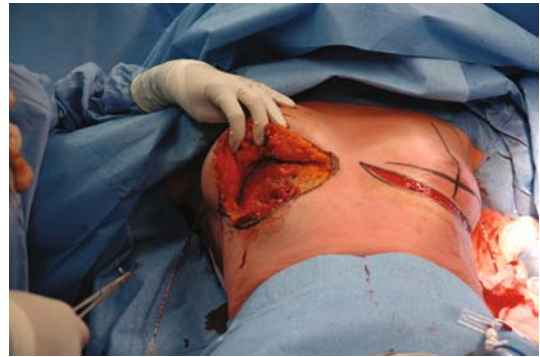When the tumour occupies the IMF it is completely excised, taking a good centimetre above and below the fold for adequate margins.

Excision is performed en bloc to the prepectoral fascia, and the two wound edges are attached to each other; this reduces segment 3, so it cannot be used with short areola–IMF distances, but it is useful for modifying the lower breast pole, particularly when ptotic.

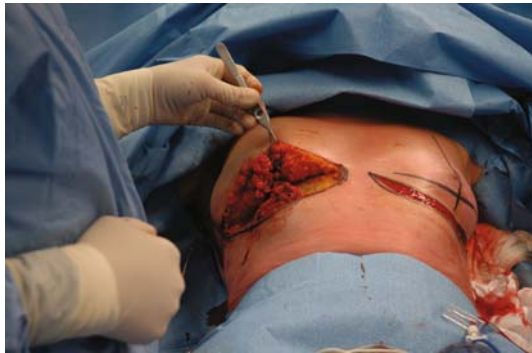



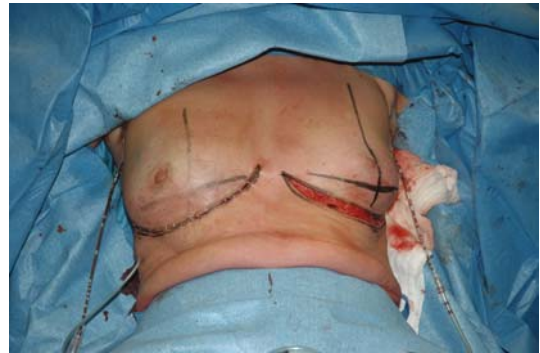**a** operative design for bilateral lower pole tumours



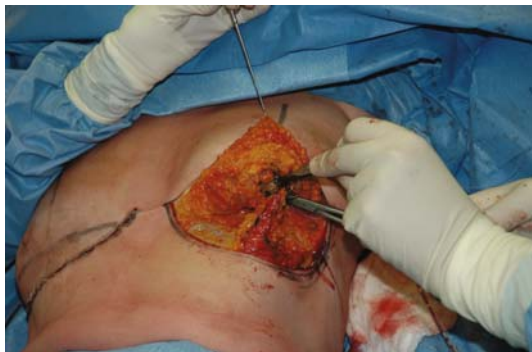**b** excision of right infero-medial tumour



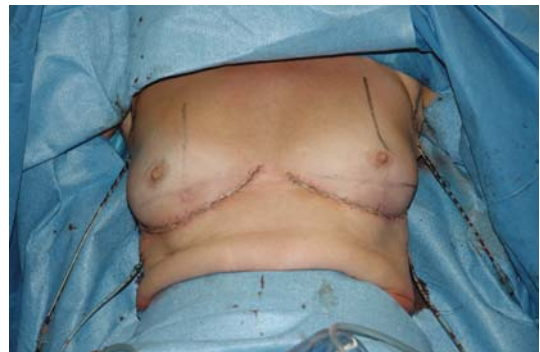**c** use of lateral parenchymal flap to preserve volume



**d** right tumourectomy



**e** right medial parenchymal flap rotated to preserve projection



**f** on-table result

**Plate 2.20a–f** IMF mammaplasty for tumours close to the inframammary fold

### Review of Oncoplastic Breast Surgery

We reviewed 299 consecutive breast cancer patients treated between 1985 and 2003 at the Institut Curie. This series concerned patients with high tumour-to-breast volume ratios or tumours in difficult locations. Mammaplasty allowed sufficient oncological resection and the avoidance of poor aesthetic results.

The mean age was 52 years (29–91)

The tumour was within the superior quadrants in 17%, medial in 19%, lateral in 20%, and at the inferior quadrant junction in 43%. The mean weight of resection in our recent series was 232 g (range 10–1,700) (Staub 2008). Symmetrisation was performed immediately in 64% and at a later date in the remainder (approximately six months after irradiation).

The mean size of these lesions was 30 mm (range 4–80) before any treatment and 25 mm (0–80 mm) after neoadjuvant chemotherapy.

The tumours were T<sub>0</sub> ( $n = 18\%$ ), T<sub>1</sub> ( $n = 18\%$ ), T<sub>2</sub> ( $n = 54\%$ ) and larger in 10%. Skin involvement was seen in four patients.

Histopathological types included carcinoma in situ ( $n = 25\%$ ); infiltrating ductal with or without with an intraductal component ( $n = 63\%$ ); infiltrating lobular ( $n = 6\%$ ); and a single case of Paget's disease.

Mammaplasty was necessary in 50% to avoid mastectomy, because of tumour location or breast deformation. In 15% it was dictated by sheer tumour volume, and in the remainder it was due to a combination of location and anticipated deformity.

## Discussion

Involved excision margins are one of the principal factors in local tumour recurrence. Some authors, including Veronesi, have therefore suggested that extra-wide “quadrantectomies” should always be performed; however, the deformities they can produce are difficult to accept at an aesthetic level.

Mammaplasties for cancer have therefore allowed reconciliation of the dual objectives of clear excision margins and aesthetically acceptable remodelling of the breast.

In our series, despite wide glandular resections with a mean weight of > 200 g, the rate of good or very good results has been very high (> 85%).

These interventions are certainly most easily adapted to medium- or large-volume breasts, but may on occasion be used effectively in smaller breasts too. The rate of breast deformity would therefore be much increased in the absence of the various techniques described above.

The scar burden, sometimes significant, is often well accepted when the alternative is a radical mastectomy, and radiotherapy usually improves the long-term appearance with little fibrous reaction. It is paradoxical that patients will often complain more about the symmetrised than the treated side, as irradiation minimises hypertrophic scarring.

The advantages of such “Oncoplastic Breast Surgery” are clear:

- Quality of excision margins

- Increase in breast-conserving treatments
- Reduction in adverse aesthetic sequelae following conservation
- Overall survival and five-year recurrence rates that are identical to standard conservative surgery
- Immediate symmetry without other reconstructive gestures

On the other hand, the duration of intervention is lengthened, and specifically trained surgeons are required to obtain optimal results.

## Conclusion

The integration of oncoplastic techniques into breast cancer surgery has allowed us to reduce the rate of mastectomy and the adverse sequelae of breast-conserving surgery.

Mastectomies are avoided in instances of sizeable tumour volume, difficult tumour location, or high tumour-to-breast volume ratios.

These limits may also be extended by diminishing the preoperative tumour volume using a medical treatment (chemotherapy or hormonal therapy). It is important, however, to understand that radiotherapy must only be used postoperatively, because it greatly increases poor aesthetic results when used preoperatively.

## References

- Benelli L (1990) A new periareolar mammaplasty: the “round block” technique. *Aesth Plast Surg* 14:93–100
- Clough KB, Soussaline M, Campana F, et al. (1990) *Plastie mammaire associée à une irradiation: traitement conservateur des cancers du sein localisés dans les quadrants inférieurs.* *Ann Chir Plast Esth* 35:117–22
- Fisher B, Anderson S, Redmond CK, et al. (1995) Reanalysis and results after 12 years of follow-up in a randomized clinical trial comparing total mastectomy with or without irradiation in the treatment of breast cancer. *N Engl J Med* 333:1456–61
- Fisher B, Dignam J, Wolmark N, et al. (1998) Lumpectomy and radiation therapy for the treatment of intraductal breast cancer: findings from National Surgical Adjuvant Breast and Bowel Project B-17. *J Clin Oncol* 16:441–52
- Jacobson JA, Danforth DN, Cowan KH, et al. (1995) Ten-year results of a comparison of conservation with mastectomy in the treatment of stage I and II breast cancer. *N Engl J Med* 332:907–11
- Lejour M (1999) Vertical mammaplasty update and appraisal of late results. *Plast Recons Surg* 104:764–81

- Solin LJ, Kurtz J, Fourquet A, et al. (1996) Fifteen-year results of breast conserving treatment and definitive breast irradiation for the treatment of ductal carcinoma in situ of the breast. *J Clin Oncol* 14:754–63
- Staub G, Fitoussi A, Falcou M-C, Salmon RJ (2008) Breast cancer surgery: use of mammaplasty. Results from Institute Curie. *Ann Chir Plast Aesthet* 53:124–34
- Thorek M (1989) Possibilities in the reconstruction of the human form. *Aesth Plast Surg* 13:55–8
- van Dongen JA, Voogd AC, Fentiman IS, et al. (2000) Long term results of a randomized trial comparing breast-conserving therapy with mastectomy. European Organization for Research and Treatment of Cancer 10801 trial. *J Natl Cancer Inst* 92:1143–50



Oncoplastic and Reconstructive Surgery for Breast  
Cancer

The Institut Curie Experience

Fitoussi, A.; Berry, M.G.; Couturaud, B.; Salmon, R.J.

2009, XI, 150 p., Hardcover

ISBN: 978-3-642-00143-7