

Chapter 2

The Role of Diagnostic Imaging in Identifying Cervical Metastases in Oral Cavity Cancer

Lawrence E. Ginsberg

Abstract Radiologic imaging is an integral part of the diagnostic evaluation of the newly diagnosed or suspected head and neck cancer patient. At the M.D. Anderson Cancer Center, for most head and neck malignancies we prefer CT for evaluation of the neck. Small nodes, or those that are nonpalpable because of location (e.g., lateral retropharyngeal or deep to the sternocleidomastoid muscle) but are nevertheless abnormal based on necrosis, shape, clustering, or other criteria, can be diagnosed with CT. This diagnosis, important for its treatment and prognostic implications, requires knowledge not only of the known or suspected primary cancer, its location, and expected sites of nodal drainage, but also of the proper imaging technique and appearance of nodal metastases. This chapter will familiarize the reader with imaging strategies, radiographic appearance, and other findings that may diagnose or suggest a likelihood of nodal metastasis.

Introduction

Nodal metastasis in oral cavity cancer has a profound effect not only on prognosis but also on therapeutic approach. Primary tumors arising from certain sites, including the oral tongue, are far more likely to be associated with nodal spread than are tumors arising from the buccal mucosa, with the likelihood of nodal metastasis increasing with T stage. Because physical examination is relatively insensitive to the detection of nodal metastases, the role of imaging becomes important. When nodal metastases are clinically or radiologically evident in an oral cavity malignancy, neck dissection and adjuvant therapy are often indicated. In cases in which routine cross-sectional imaging (magnetic resonance imaging [MRI] or computed tomography [CT]) is equivocal for nodal metastases, further imaging may be

L.E. Ginsberg (✉)

Departments of Diagnostic Radiology and Head and Neck Surgery, Department of Diagnostic Radiology Unit 370, The University of Texas M. D. Anderson Cancer Center, 1515 Holcombe Blvd, Houston, TX, 77030, USA
e-mail: lginsberg@di.mdacc.tmc.edu

warranted. This can include ultrasound and ultrasound-guided fine-needle aspiration (USG-FNA) or positron emission tomography (PET)/CT imaging. In patients for which imaging cannot firmly establish the presence of nodal disease, the treating physician is faced with the difficult issue of whether or not to dissect the neck at the time of resection of the primary cancer. Among the issues to be considered in this determination is tumor thickness, to which imaging may contribute (Fukano et al. 1997; Asakage et al. 1998; Okura et al. 2008; Kane et al. 2006).

In this chapter, we review the imaging strategies and findings relevant to the staging evaluation in patients with oral cavity carcinoma. The histologic subtype in the majority of cases is squamous cell carcinoma, but it should be remembered that minor salivary cancers may occur in any location of the upper aerodigestive tract mucosa, and these tumors have imaging findings indistinguishable from squamous cell carcinoma. Choice of imaging modality is still somewhat controversial. However, at The University of Texas M. D. Anderson Cancer Center, CT remains the imaging modality of choice for known or suspected cancers of the upper aerodigestive tract except nasopharyngeal carcinoma, for which MRI is the preferred modality. The basis of this choice is that while some small or superficial cancers may not be visible on CT, most are visible on CT, and CT is excellent for detecting bony invasion, a finding that influences surgical approach and prognosis. In addition, it is our feeling that nodal disease, and particularly necrosis within small metastatic nodes, can generally be better seen on CT than MRI. This does not, however, address the issue of metastatic disease within nodes lacking the CT characteristics suggestive of malignancy. Philosophical issues arise as to how aggressive pretreatment imaging should be in unearthing the smallest of nodal metastases, and which imaging modality is best. In truth, no available imaging modality can detect the smallest of micrometastases.

While statistics can be presented based on the best objective imaging data for each modality, one immeasurable factor is experience. Experience of the radiologist comes into play in every case he or she reads, and lack of experience can result in the failure to detect radiologically evident lesions, whether primary or metastatic. Another factor in imaging worth mentioning is that shortcomings of imaging technique can result in lesions being inconspicuous when they might otherwise be more readily seen. There is no way to measure experience or the importance of good imaging technique.

Nodal Classification

For the purpose of this chapter, and in common clinical parlance, the nodal usage terminology will conform to that published in 2000 by Som et al. (1999, 2000) (Fig. 2.1). This work sought to match the imaging description of lymph node metastases to the most commonly used clinical descriptions, in order to improve communication between radiologists and clinicians.

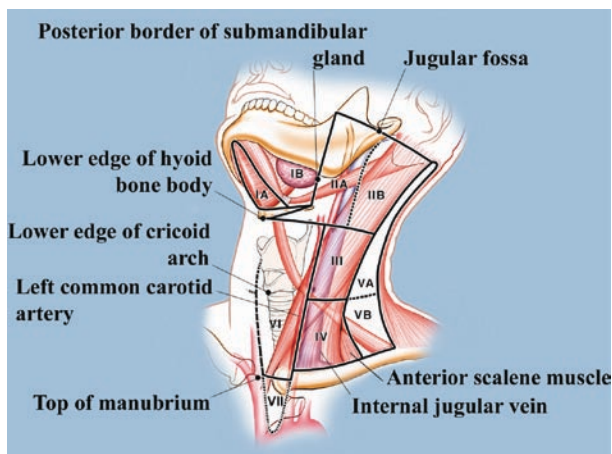


Fig. 2.1 Nodal classification Reprinted with permission from Som and Brandwein (2003)

Nodal Staging

The most commonly accepted nodal staging classification for squamous cell carcinoma of the oral cavity is as follows:

Nx: nodes cannot be assessed

N0: no lymph nodes with evidence of metastasis

N1: a single ipsilateral node with evidence of metastasis 3 cm or less

N2:

N2a- a single ipsilateral lymph node with evidence of metastasis greater than 3 cm, but not greater than 6 cm in greatest dimension.

N2b- multiple ipsilateral lymph nodes with evidence of metastasis, none greater than 6 cm in greatest dimension.

N2c- bilateral or contralateral lymph nodes with evidence of metastasis, none greater than 6 cm in greatest dimension.

N3- a lymph node with evidence of metastasis greater than 6 cm in greatest dimension.

Nodal Drainage Patterns

The vast majority of nodal metastases in oral cavity cancer involve levels I, II, and III. For oral tongue cancer, the likelihood of nodal disease is the highest among the oral cavity primary sites. Cancers of the oral tongue that are anteriorly situated tend to spread to nodes in levels I or II. Tumors more laterally or posteriorly situated tend

to spread to nodes in levels II and III. Nodal disease from other oral cavity primary sites is less common than from tongue carcinoma but follows a similar pattern (Som and Brandwein 2003). Primary sites that are more anteriorly situated, such as anterior floor of mouth or gingiva, tend to spread to level I or II; primary cancers more posteriorly located tend to spread to levels II and III. In general, there is an orderly downhill, superior-to-inferior spread, whereby once levels I and II are involved, the tendency to spread then occurs more inferiorly into level IV and so forth. The posterior triangle or level V of the neck is relatively uninvolved in the nodal spread of oral cavity malignancy (Shah et al. 1990). Primary lesions that involve or approach the midline (e.g., floor of mouth or oral tongue) are more likely to access the lymphatics bilaterally (Fig. 2.2). While larger lesions and higher N status are generally associated with a greater likelihood and degree of adenopathy, some early-stage, small primary cancers may give rise to a fairly extensive degree of nodal disease (Fig. 2.2).

Imaging Criteria for Nodal Metastasis by Imaging

CT and MRI

If a lymph node has internal heterogeneity or necrosis by imaging, there is a very high likelihood that it harbors tumor, regardless of size (Som and Brandwein 2003; Glastonbury 2004; Wiggins 2004) (Figs. 2.2–2.5). On CT, this can be seen as an area of low density (“attenuation” in CT terminology), which may be subtle or quite obvious. In the extreme, necrosis can result in a nearly cystic or cyst-like appearance (Fig. 2.3), though this is far more common in oropharyngeal carcinomas than in carcinomas of oral cavity origin (Asakage et al. 1998; Okura et al. 2008; Kane et al. 2006). Central necrosis may be observed in nodes that are quite small and nonpalpable, thus justifying imaging in the clinically N0 neck (Fig. 2.4). On MRI, internal necrosis can be harder to appreciate in smaller nodes, but in larger nodes, it can be seen as internal “high signal” or “hyperintensity” on T2-weighted images, and nonenhancement of the necrotic area on post-contrast, T1-weighted images (Fig. 2.5). Although figures vary by study design (for instance, use of a cutoff based on lymph node size, with a 1-cm size cutoff or the presence of internal necrosis), CT has a negative predictive value (NPV) of 84% and a positive predictive value (PPV) of 50% (Curtin et al. 1998).

On MRI, the differentiation between metastatic and benign or reactive nodes can be challenging. If a node is nonnecrotic or not clearly enlarged, the differentiation is difficult because metastatic and benign nodes have similar imaging characteristics, being isointense on T1-weighted images, hyperintense on T2-weighted images, and enhancing following intravenous administration of Gadolinium-based contrast agents (Som and Brandwein 2003; Glastonbury 2004; Wiggins 2004; Som 1992). With MRI, the NPV and PPV are on the order of 79% and 52%, respectively (Curtin et al. 1998).

If internal necrosis is not radiographically evident, other imaging criteria must be employed. Historically, size has been long-used as a determinant of malignancy but is highly unreliable. The generally accepted size cutoff is 1.5 cm for the subdigas-

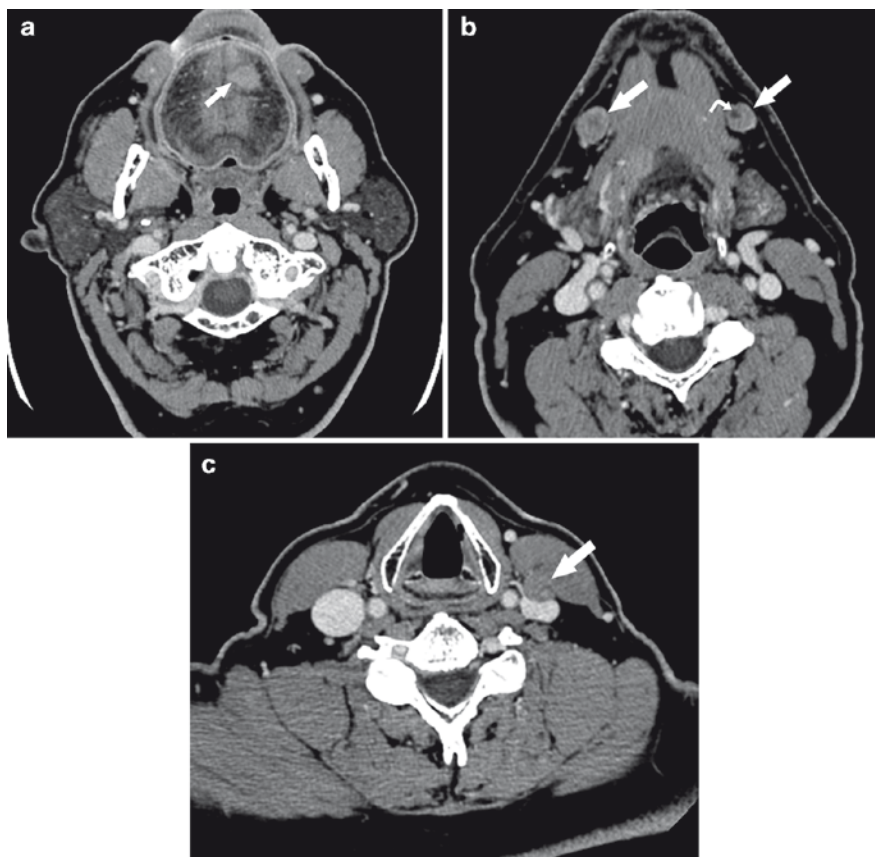


Fig. 2.2 Early-stage oral tongue carcinoma that approaches the midline, with bilateral nodal metastases. (a) Axial CT images shows fairly small left anterior oral tongue primary that reaches the midline (*arrow*). (b) Bilateral level 1b nodal metastases (*straight arrows*), each with internal areas of necrosis, perhaps more obvious on the left side (*curved arrow*). (c) Level 3 nodal metastasis (*arrow*), somewhat inapparent due to similar density compared with adjacent sternocleidomastoid muscle. The node is compressing the anterior surface of the internal jugular vein. Necrosis in this node is difficult to discern

tric node (the upper internal jugular nodes, or in the current classification scheme, level IIA), and 1 cm for other cervical lymph nodes. The lateral retropharyngeal nodes of Rouviere, which generally have a smaller size cutoff (perhaps 6–8 mm) are seldom involved by metastases in patients with oral cavity primary tumors. One exception to this is primary cancers of the maxillary alveolar ridge, which can metastasize to the lateral retropharyngeal nodes (Kimura et al. 1998) (Fig. 2.6). The smaller the size used for cutoff, the greater the sensitivity (fewer metastases missed), but also the greater the number of nonmetastatic nodes included (lower specificity) (Curtin et al. 1998). This is the trade-off when size alone is used. Thus, it is important to look at other features of lymph nodes in addition to size. The shape of a node has diagnostic value, benign nodes tending to be more oval or bean-shaped, and metastatic

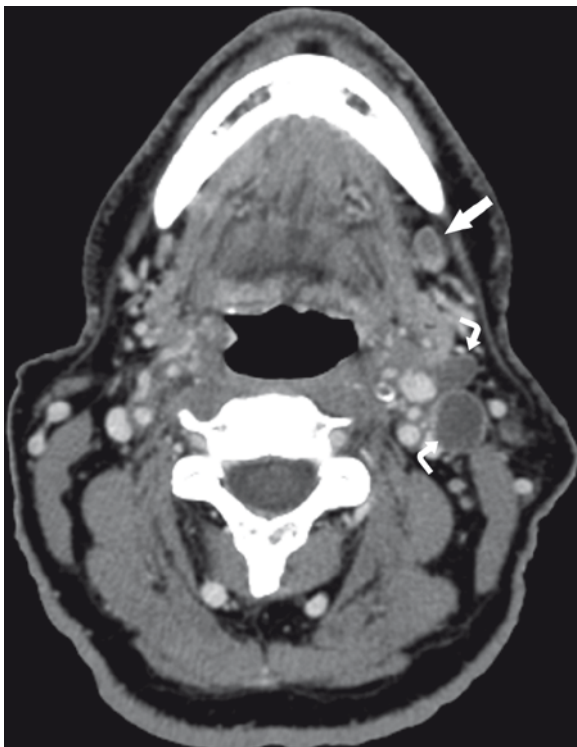


Fig. 2.3 Maxillary alveolar ridge carcinoma (not shown) with cystic nodal metastases. Level 1b node (*straight arrow*) has internal necrosis but some solid enhancement posteriorly. Level 2 nodes are so necrotic as to be essentially cystic, without any solid enhancement (*curved arrows*)

nodes tending to be round. The location of a node is important, specifically its location with respect to the known or suspected primary cancer and the expected lymphatic drainage of that site. For instance, a right-sided anterior oral tongue carcinoma, lacking ipsilateral nodal metastases, would be very unlikely to have a nodal metastasis in the left level IV; a borderline-sized node in such a location would be relatively discounted in terms of its likelihood of being metastatic in this scenario. Were a borderline-sized, non-necrotic node to be seen precisely in the location of drainage (and obviously ipsilateral) to a primary cancer, it would not as readily be dismissed. Put another way, the “oncology” of a node should reasonably enter into the interpretation of its imaging. Clustering, or the tendency of nodal metastases to congregate, should also be taken into consideration; a group of 3–5 nodes in a single location on a single image should arouse suspicion even if none of the nodes is individually abnormal based on size or morphology (Som and Brandwein 2003).

Special mention should be made of the imaging findings that suggest extracapsular extension (ECE), a known predictor of local recurrence and decreased survival (Woolgar et al. 2003; Myers et al. 2001). Imaging findings that suggest ECE include irregular spiculated margins and indistinct borders between the nodal

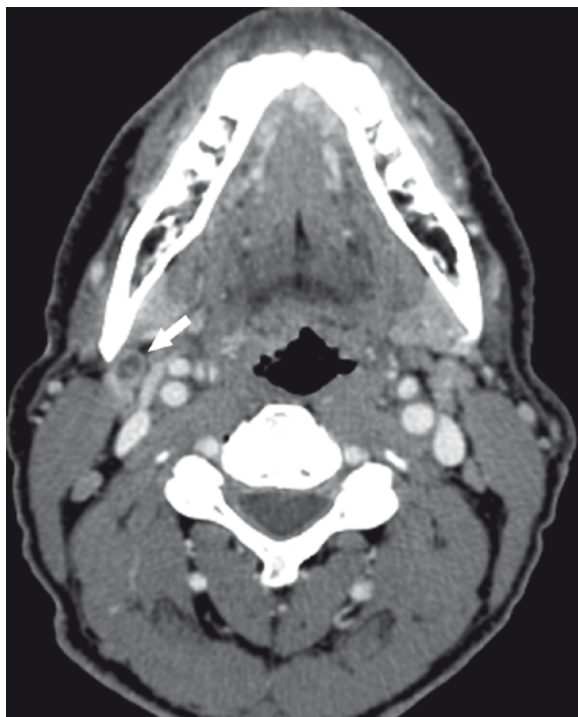


Fig. 2.4 Patient with clinically N0 neck. Small but clearly necrotic right level 2a node (*arrow*)

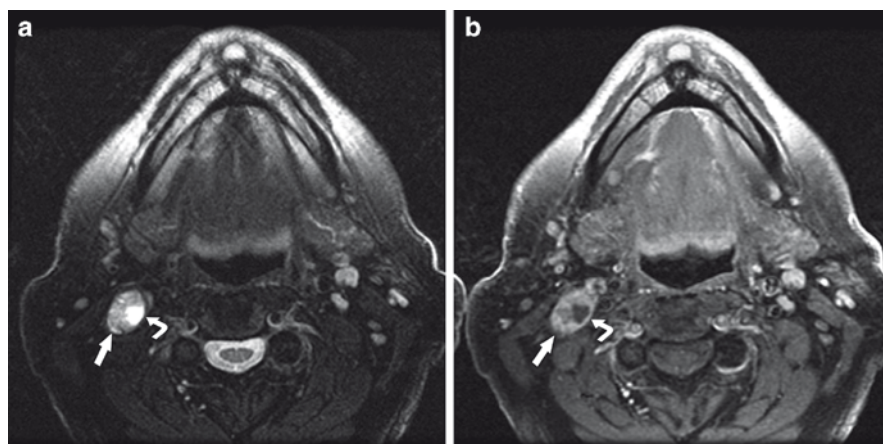


Fig. 2.5 MR images of necrotic nodal metastasis. (a, b) T2-wighted and post-contrast T1-weighted MR images, respectively, show a right upper internal jugular nodal metastasis (*straight arrow*). As with reactive and benign nodes, T2 hyperintensity is typical, but this metastatic node is enlarged, and there is a medially situated focus of internal necrosis that is seen as even greater signal hyperintensity on T2, and nonenhancement on the post-contrast image (*curved arrows in a and b, respectively*)

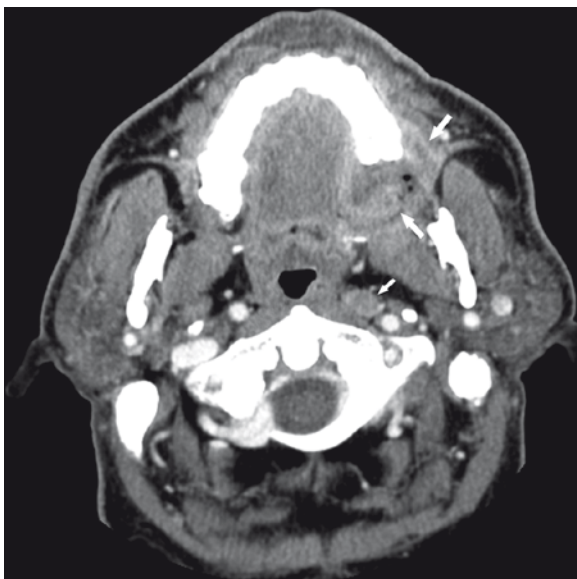


Fig. 2.6 Metastatic lateral retropharyngeal node of Rouviere in maxillary alveolar ridge carcinoma. Axial CT image shows the obvious primary along the posterior maxilla (*large arrows*) and an enlarged, perhaps subtly necrotic left-sided lateral retropharyngeal lymph node (*small arrow*)

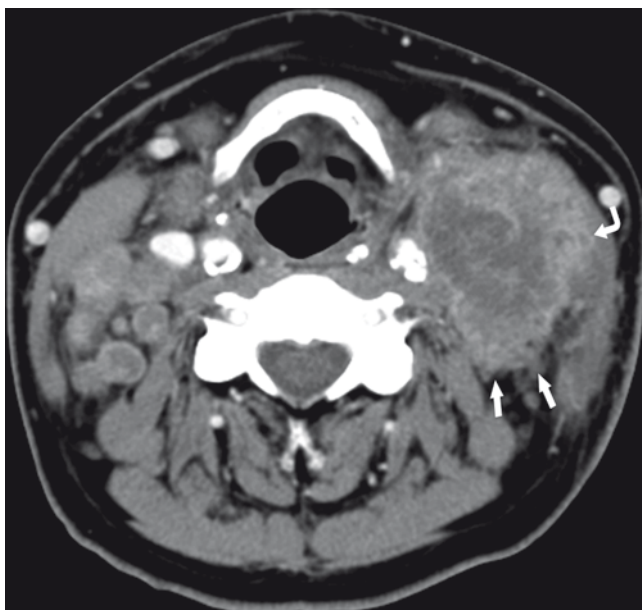


Fig. 2.7 Extracapsular extension (ECE). CT image shows extensive bilateral nodal disease, but the large left-sided node has very irregular margins, especially posteriorly (*straight arrows*), and very blurred margins between the node and the medial surface of the sternocleidomastoid muscle (*curved arrow*)

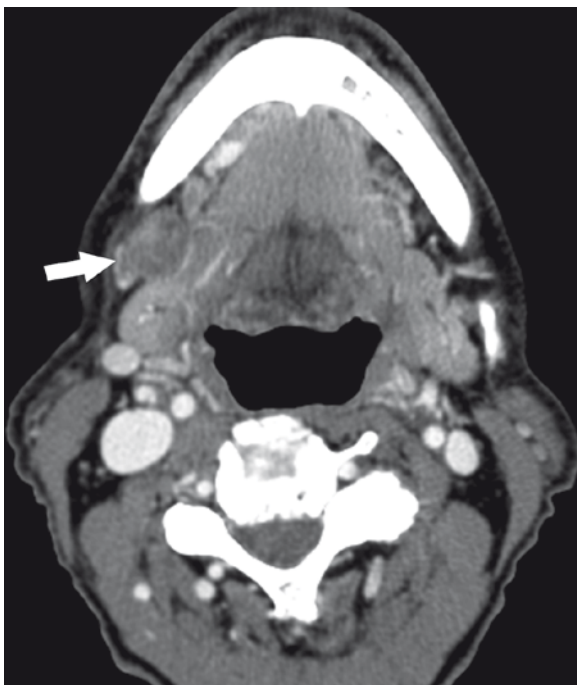


Fig. 2.8 Extracapsular extension (ECE) undetectable on imaging. Axial CT image of a patient with mandibular alveolar ridge carcinoma. There is an obviously enlarged, necrotic right-sided level 1b nodal metastasis (*arrow*), with none of the signs that would suggest ECE, but which was evident histologically

metastasis and adjacent structures such as the inner surface of the sternocleidomastoid muscle (Som 1992) (Fig. 2.7). Unfortunately, imaging is not able to detect every case of ECE, which may be only visible histologically (Fig. 2.8).

If, then, a node is not frankly pathologic at initial staging by CT or MRI because of grossly abnormal size or the presence of necrosis, how does one deal with the borderline node (for example, a node that is 1.6 cm in the subdiaphragic region, or 1.2 cm in level III with no other tell-tale sign of cancer)? Such cases may require further attention, depending on whether or not there is other indication for neck dissection. If, in the case of a thick oral tongue cancer, surgery is planned, then a borderline node will be addressed at the time of neck dissection. If surgery is not otherwise indicated, then further imaging may be used to assess the borderline or questionable lymph node. Ultrasound (US), with fine-needle aspiration (FNA), may be performed to determine if a node is truly metastatic. In experienced hands, US is very useful and highly accurate in predicting the presence or absence of metastatic disease within a lymph node and in identifying those cases that would benefit from confirmatory FNA. Unfortunately, US-guided FNA can be subject to sampling error, and false negative results may occur (Fig. 2.9). In our institution, US is often used as an adjunct test in staging the neck. The sonographic features of nodal metastases are described in this chapter.

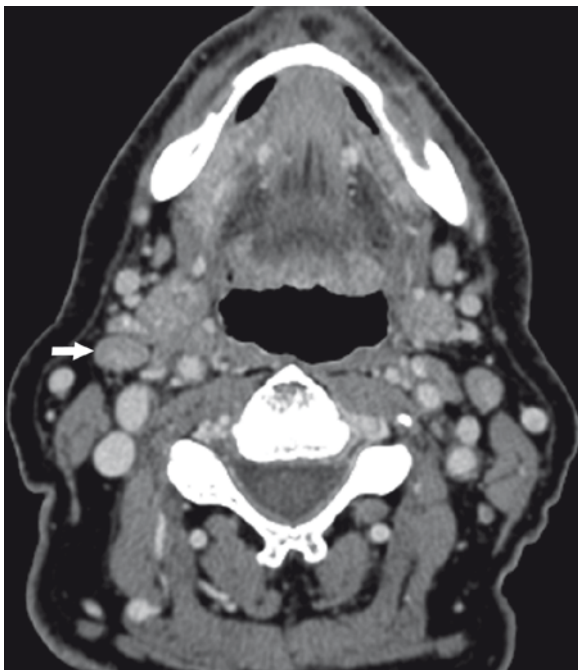


Fig. 2.9 Clinically T2 possible N1 right-sided oral tongue carcinoma. CT image shows a prominent but not frankly abnormal right subdigastric node (1.2 cm, *arrow*). Ultrasound was considered worrisome, but FNA revealed only reactive lymphocytes. Neck dissection was performed because of thickness of the primary (~1.5 cm), and histologically this node contained small foci of metastatic carcinoma that were simply nondefinitive on CT and that were apparently missed at USG-FNA due to sampling error

Generally, imaging serves to upstage, by demonstrating nodal metastases that are not evident clinically. Occasionally, particularly in the case of floor of mouth cancer, imaging can downstage. This can occur if the floor of mouth cancer obstructs the submandibular duct, causing the gland to obstruct and enlarge; in such cases, the resulting enlarged gland may be clinically interpreted (palpated) as nodal disease. Imaging can reliably differentiate an obstructed submandibular gland from a nodal metastasis (Fig. 2.10).

One additional matter is false positive imaging results. If a node is observed to be asymmetrically enlarged and within the drainage basin of a known malignancy, then one may be tempted to call it metastatic radiographically. This can be compounded if the presumably reactive node is palpable (Fig. 2.11); however, such a node may be merely reactive. Another pitfall in nodal imaging is the pseudonecrosis that may result from partial volume averaging of a normal fatty hilum. Specifically,

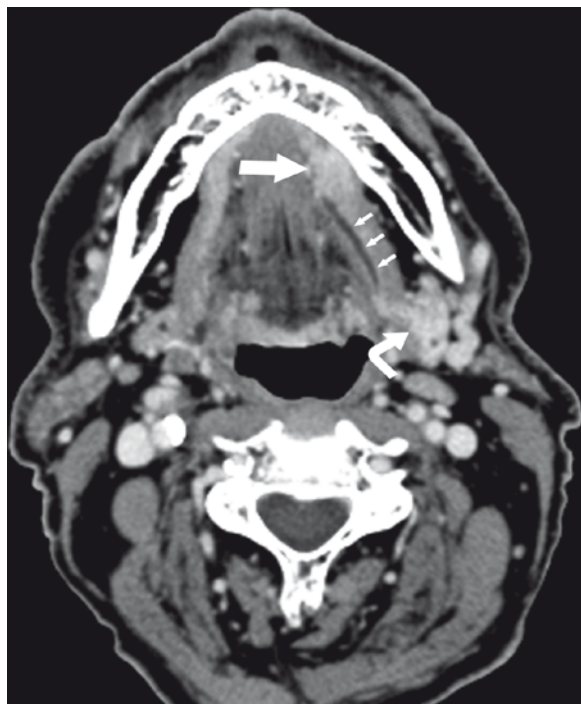


Fig. 2.10 Floor of mouth carcinoma, clinically N1. Axial CT image shows the enhancing floor of mouth primary (*large straight arrow*). Note the obstructed, dilated submandibular duct (*small arrows*) and an enlarged, enhancing left submandibular gland (*curved arrow*). This gland was palpable and presumed to be a nodal metastasis. In this case, imaging served to downstage the neck. There were no nodal metastases detectable elsewhere in the neck

when a CT slice overlaps a portion of normally low-density fat within the hilum of a lymph node and also includes a portion of normal lymphoid tissue, the “averaged” tissue may be misinterpreted as necrosis (Fig. 2.12).

Ultrasound

Ultrasound has long been used to evaluate lymph nodes, in the neck and elsewhere. Criteria for metastatic disease in a node include a rounded (abnormal) vs. oval or fusiform (normal) shape, increased size (unreliable as in cross-sectional), or an abnormal internal echo pattern. The abnormal internal echo pattern can take the form of a diffusely hypoechoic appearance or diffusely increased echogenicity – this often coincides with loss or disordering of the expected central hilar echo pattern (Evans 2003; van den Brekel and Castelijns 2005) (Fig. 2.13). Though much

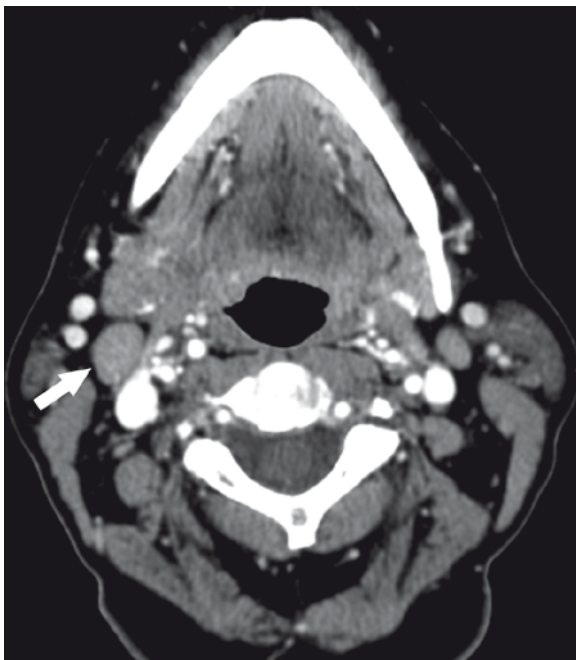


Fig. 2.11 Right-sided retromolar trigone carcinoma with clinically N1 neck. Axial CT image shows a borderline enlarged (1.5 cm) right subdigastric node (*arrow*), which was presumed metastatic because of its location relative to the primary lesion as well as the clinical impression. At neck dissection, no tumor was found in this or any other neck node

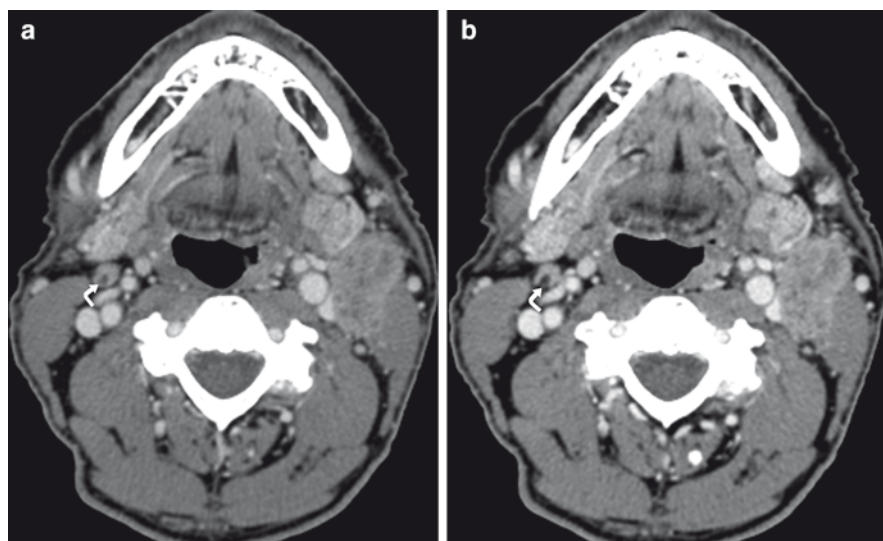


Fig. 2.12 Metastatic carcinoma to the left neck. (a) Axial CT image, in addition to obvious left-sided nodal disease, suggests the possibility of necrosis within a contralateral node (*curved arrow*). (b) The image at a slightly lower level shows that, rather than necrosis, this is a normal fatty hilum (hypodense area, *curved arrow*). The image more superiorly represents partial volume averaging and thus the illusion of necrosis that does not exist

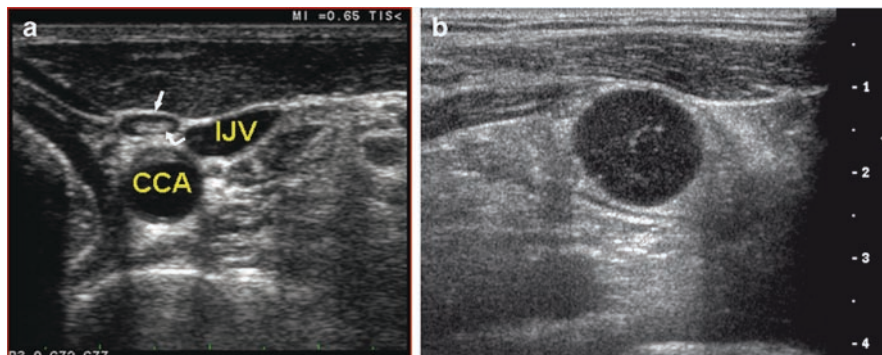


Fig. 2.13 Sonographic findings in normal and metastatic nodes. (a) Axial ultrasound image shows normal oval node (*straight arrow*), with organized central internal echoes (*curved arrow*). The common carotid artery (CCA) and internal jugular vein (IJV) are labeled. (b) Nodal metastasis with round shape, internal hypoechoic appearance, and absence of the normal central echoes seen in (a). (Images courtesy of Beth S. Edeiken, M.D.)

more common in thyroid cancer metastases, the presence of calcification in a lymph node suggests malignancy. Another sign of malignancy in a node is abnormal vascularity by color Doppler determination. Normal flow should be primarily central in location; color flow Doppler findings of malignancy include displacement of normal hilar flow, aberrant or extra vessels, focal absence of expected normal areas of perfusion, and abnormally increased peripheral, subcapsular vessels (Fig. 2.14) (Evans 2003; van den Brekel and Castelijns 2005). Internal necrosis may take the appearance of cystic degeneration (Evans 2003). One benefit of ultrasound is the ability to perform USG-FNA on any suspicious lymph node, with essentially immediate cytologic results.

PET/CT

Recent advances in F^{18} -labeled fluorodeoxyglucose (FDG) PET technology have made widely available the fusion of PET and CT in a single machine (PET/CT). The presence of correlative CT images allows far more accurate spatial and anatomic localization of abnormalities seen on the PET images. In numerous studies, PET/CT has proven to be more sensitive than MR/CT in the detection of nodal metastases from a variety of head and neck malignancies, including the oral cavity (Ng et al. 2006) (Fig. 2.15). Unfortunately, PET/CT is so sensitive that it can lead to false positives. As an example, reactive nodes may be associated with abnormally elevated FDG activity, and thus mistakenly characterized as metastatic (Schoder et al. 2006). Furthermore, PET/CT remains unable to detect micrometastases, and as such, does not have high enough NPV to prevent elective neck dissection in every case (Schoder et al. 2006). On PET/CT, nodal metastases (and potentially negative, reactive or inflammatory nodes) are seen as “hot” areas of increased FDG activity, yellow in color as presented in most systems (Fig. 2.15).

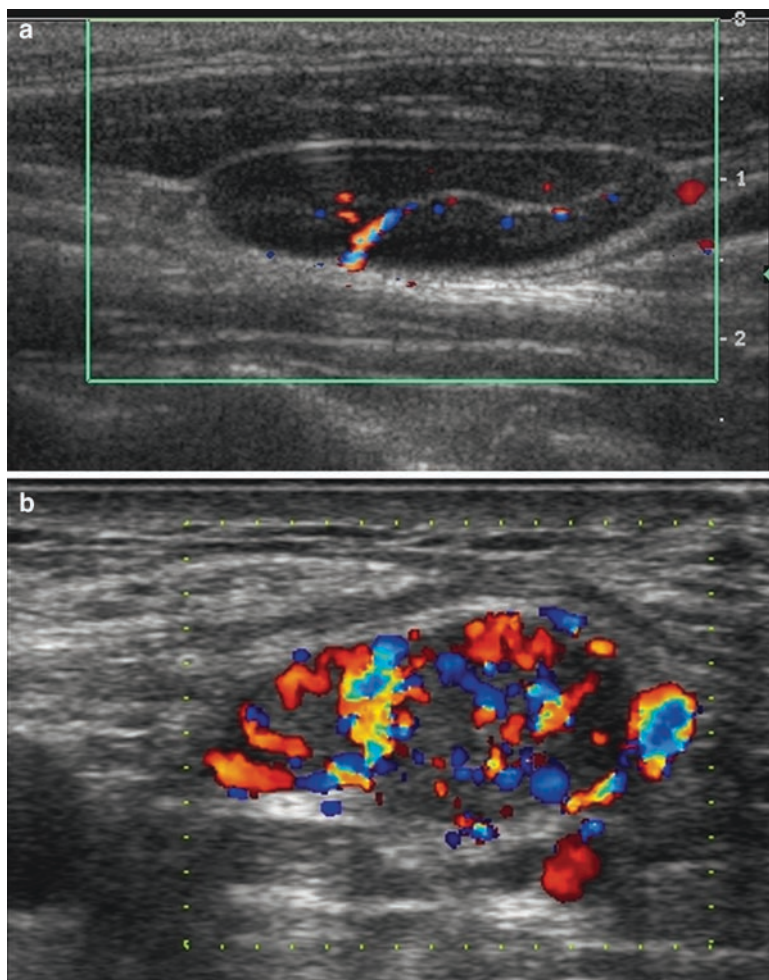


Fig. 2.14 Normal and abnormal color flow Doppler. (a) Normal centrally located internal Doppler signal. (b) Grossly abnormal increased internal vascular flow typical of metastasis. (Images courtesy of Beth S. Edeiken, M.D.)

Sentinel Lymph Node Biopsy

Recent investigations have begun examining the feasibility and efficacy of sentinel node biopsy, which is based on the concept that if one can identify the first echelon nodal drainage from a given primary cancer, then that node can be sampled even if normal by other modalities of imaging (Hart et al. 2005). Such sampling is accomplished through intratumoral or peritumoral injection of a radioisotope and then performing imaging with scintigraphy and subsequent biopsy of the sentinel

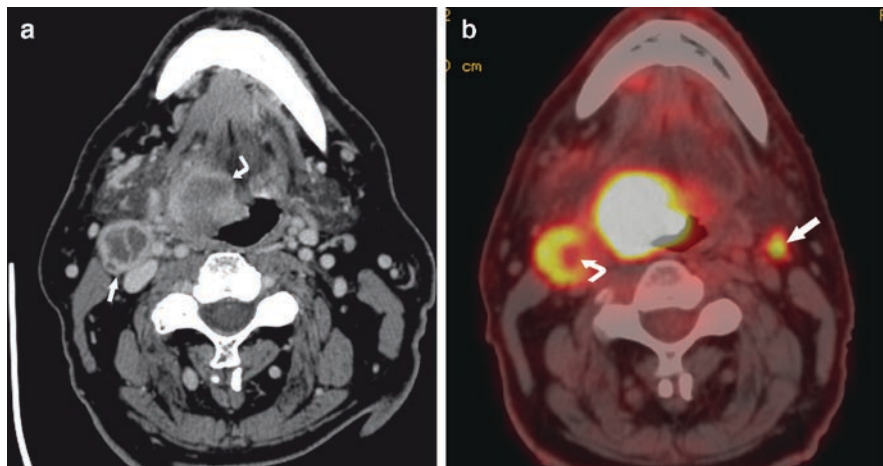


Fig. 2.15 Base of tongue carcinoma. (a) Axial CT image shows the obvious right-sided tongue base primary (*curved arrow*) and necrotic ipsilateral adenopathy (*straight arrow*), but contralateral nodal disease cannot be called. (b) Fused PET/CT image shows a small but striking area of increased metabolic activity in the left neck (*straight arrow*). This represents a nodal metastasis not detectable by any other means and illustrates the utility of PET/CT. Note that some of the internal necrosis of the right-sided nodal metastasis is not associated with abnormal metabolic activity (*curved arrow*); this is expected and a potential source of false-negative PET scan in the case of purely cystic/necrotic nodal metastases

node, either surgically or by USG-FNA. Sentinel lymph node mapping appears to have a very high NPV and thus may prove to be very useful in patients with N0 necks. While currently used primarily in cutaneous malignancies, it holds promise for mucosal tumors as well and will be discussed elsewhere in this text.

Conclusion

Imaging has much to offer in the staging evaluation of patients with oral cavity cancer. At M. D. Anderson Cancer Center, disease in most patients is staged with contrast-enhanced CT. While there are guidelines on how to approach and diagnose metastatic lymph nodes radiologically, experience is important for the evaluation of nodes that are borderline, those which cannot obviously be called metastatic. Identification of such nodes requires a high level of vigilance, an understanding of the behavior of the malignancy, attention to imaging technique, and knowledge of which adjunct tests would increase diagnostic sensitivity and avoid false negative results. Unfortunately, however, at this time there is no single imaging test that is 100% sensitive and specific and that has a 100% negative predictive value. Until there is such a test, surgeons will need to rely on other features of a primary cancer to determine who would most benefit from elective neck dissection.

References

- Fukano H, Matsuura H, Hasegawa Y, Nakamura S (1997) Depth of invasion as a predictive factor for cervical lymph node metastasis in tongue carcinoma. *Head Neck* 19:205–210
- Asakage T, Yokose T, Mukai K et al (1998) Tumor thickness predicts cervical metastasis in patients with stage I/II carcinoma of the tongue. *Cancer* 82:1443–1448
- Okura M, Iida S, Aikawa T et al (2008) Tumor Thickness and Paralingual Distance of Coronal MR Imaging Predicts Cervical Node Metastases in Oral Tongue Carcinoma. *AJNR Am J Neuroradiol* 29:45–50
- Kane SV, Gupta M, Kakade AC, D'Cruz A (2006) Depth of invasion is the most significant histological predictor of subclinical cervical lymph node metastasis in early squamous carcinomas of the oral cavity. *Eur J Surg Oncol* 32:795–803
- Som PM, Curtin HD, Mancuso AA (2000) Imaging-based nodal classification for evaluation of neck metastatic adenopathy. *Am J Roentgenol* 174:837–844
- Som PM, Curtin HD, Mancuso AA (1999) An imaging-based classification for the cervical nodes designed as an adjunct to recent clinically based nodal classifications. *Arch Otolaryngol Head Neck Surg* 125:388–396
- Som PM, Brandwein MS (2003) Lymph Nodes. In: Som PM, Curtin HD (eds) *Head and neck imaging*. Mosby, St. Louis, pp 1865–1934
- Shah JP, Candela FC, Poddar AK (1990) The patterns of cervical lymph node metastases from squamous carcinoma of the oral cavity. *Cancer* 66:109–113
- Glastonbury CM (2004) Squamous cell carcinoma nodes. In: Harnsberger HR, Wiggins RH, Hudgins PA, Michel MA, Swartz J, Davidson HC, et al. (eds) *Diagnostic imaging: Head and neck, vol III*. Amirsys, Salt Lake City, UT, pp. 2–28; 22–31
- Wiggins RH (2004) Nodal metastases, SCCa (SMS). In: Harnsberger HR, Wiggins RH, Hudgins PA, Michel MA, Swartz J, Davidson HC, et al. (eds) *Diagnostic imaging: Head and neck, vol III*. Amirsys, Salt Lake City, UT, pp. 4–46; 44–47
- Curtin HD, Ishwaran H, Mancuso AA, Dalley RW, Caudry DJ, McNeil BJ (1998) Comparison of CT and MR imaging in staging of neck metastases. *Radiology* 207:123–130
- Som PM (1992) Detection of metastasis in cervical lymph nodes: CT and MR criteria and differential diagnosis. *Am J Roentgenol* 158:961–969
- Kimura Y, Hanazawa T, Sano T, Okano T (1998) Lateral retropharyngeal node metastasis from carcinoma of the upper gingiva and maxillary sinus. *AJNR Am J Neuroradiol* 19:1221–1224
- Woolgar JA, Rogers SN, Lowe D, Brown JS, Vaughan ED (2003) Cervical lymph node metastasis in oral cancer: the importance of even microscopic extracapsular spread. *Oral Oncol* 39:130–137
- Myers JN, Greenberg JS, Mo V, Roberts D (2001) Extracapsular spread a significant predictor of treatment failure in patients with squamous cell carcinoma of the tongue. *Cancer* 92:3030–3036
- Evans RM (2003) Ultrasound of cervical lymph nodes. *Imaging* 15:101–108
- van den Brekel MW, Castelijns JA (2005) What the clinician wants to know: surgical perspective and ultrasound for lymph node imaging of the neck. *Cancer Imaging* 5 Spec No A:S41–S49.
- Ng S-H, Yen T-C, Chang JT-C et al (2006) Prospective study of [18F]fluorodeoxyglucose positron emission tomography and computed tomography and magnetic resonance imaging in oral cavity squamous cell carcinoma with palpably negative neck. *J Clin Oncol* 24:4371–4376
- Schoder H, Carlson DL, Kraus DH et al (2006) 18F-FDG PET/CT for detecting nodal metastases in patients with oral cancer staged n0 by clinical examination and CT/MRI. *J Nucl Med* 47:755–762
- Hart RD, Nasser JG, Trites JR, Taylor SM, Bullock M, Barnes D (2005) Sentinel lymph node biopsy in N0 squamous cell carcinoma of the oral cavity and oropharynx. *Arch Otolaryngol Head Neck Surg* 131:34–38



<http://www.springer.com/978-1-4419-0774-5>

Oral Cancer Metastasis

Myers, J. (Ed.)

2010, XVIII, 346 p., Hardcover

ISBN: 978-1-4419-0774-5