

Chapter 2

The History of Adrenocortical Carcinoma Treatment – A Surgical Perspective

Norman W. Thompson

The early history of adrenocortical carcinoma (ACC) is obscure because of the rarity of the disease, confusing nomenclature, inability to diagnose before death, ignorance of its hormonal manifestations, and a vague appreciation of its clinical course. Most reported cases in the 19th century were based on autopsy findings, and the tumors were classified by a variety of terms including hypernephroma, sarcoma, fibromyxosarcoma, and carcinoma. The commonly used term, hypernephroma, was first proposed by Grawitz et al. in 1893 and falsely assumed that tumors arose in rests of adrenocortical tissue within the kidney [1]. This concept was reinforced by Felix Birch-Hirschfeld who used it to define benign and malignant tumors of both adrenals and kidneys, some with apparent hormonal disturbances [2]. The designation of hypernephroma for some adrenal tumors persisted in the literature until the 1940s; later it became restricted to what is now referred to as renal cell cancer [3–8].

In 1905, it was stated that no adrenal tumor had been diagnosed before operation or autopsy [9]. None had been suspected on the basis of a hormonal syndrome although an association of virilization and an adrenal tumor found at autopsy was first observed in 1811 [10]. It was not until 1890 that a decrease in virilization was first documented following resection of an adrenal tumor. Cushing's syndrome was not recognized until 1910 but was not associated with an adrenal malignancy until Walters et al. in 1934 described the same syndrome in patients with adrenal tumors and emphasized that the characteristic findings were not exclusively related to pituitary disease [11].

The first tumor operations on the adrenal glands were done to remove “large abdominal swellings” [10]. Knowsly Thornton of London is credited with the first known successful operation to remove an adrenal cancer in 1899 [12]. His patient was a 36-year-old, very hirsute female who was found at operation to have a 20-pound left adrenal tumor. It required a left nephrectomy as well to remove this

N.W. Thompson (✉)

Surgery Emeritus Faculty, University of Michigan, Rm 2124C Taubman Health Care Center, 1500 East Medical Center Drive, Ann Arbor, MI 48105, USA
e-mail: normant@umich.edu

large tumor. She slowly recovered after developing a subphrenic abscess that spontaneously drained into a bronchus. After dramatic improvement, her hirsutism remised until a recurrence 2 years later caused her death [13]. Thornton, interestingly, was well prepared for this operation, having previously served as Joseph Lister's house surgeon (antiseptic technique) and Spencer Wells' assistant. The latter was a pioneer in the development of hemostats and hemostatic techniques. The first small series was presented by Otto Ramsay later in 1899 who reported three patients operated for large palpable malignant adrenal tumors [14]. In addition, he reviewed a total of 64 other published reports of patients with either carcinomas [15] or sarcomas [13] of the adrenals. The diagnosis was difficult in all and impossible in many. The tumors were found to spread rapidly and the prognosis was considered dismal. Surgery was considered the only hope of temporary relief, but only five patients had been operated and only two with success, Thornton's and another by Howard Kelly in Baltimore with a good result 1 year after excision of a large "fibromyxosarcoma."

From 1905 to 1929, a number of patients were described with what was termed the adrenogenital syndrome and others with adrenal tumors with virilism [5, 16]. Bulloch, in 1905, reported ten girls and two boys who all died within 2 years from malignant adrenal tumors, most with metastases. Most were considered hypernephromas associated with sexual abnormalities, usually in children [10]. In 1921, Collett from Oslo described a 2-year-old with progressive virilization over 18 months who had a palpable tumor of the left adrenal [10]. This was excised after which the hirsutism regressed for 2 years. This was probably the first successful adrenal operation in a child. Other similar cases soon followed and surgical excision seemed to confirm that these tumors caused virilism, perhaps by producing an internal secretion. Although patients with pure adrenal virilism had had tumors successfully removed, several with Cushing's or closely related syndromes had died in "shock" several hours after straightforward operations. At autopsy, their remaining adrenals were found to be atrophic. After 1932, many patients with Cushing's disease (pituitary) were reported. Cushing's syndrome and adrenal virilism were not always clearly distinguished, and the term "suprarenal cortical syndrome" was sometimes used to describe both. Kepler at the Mayo Clinic stressed the frequency of the intermediate forms, especially with ACCs [17]. By 1933 there was clear evidence that the pituitary secreted an adrenocortical factor which was later recognized as ACTH. Whatever the underlying cause, the development of Cushing's syndrome required the presence of the adrenal cortex. Those surgeons including Waltman, Waters, and James Priestly at the Mayo Clinic recognized three main problems: (1) to determine the nature of the adrenal lesion; (2) to relieve the syndrome in patients without adrenal tumors; (3) to prevent operative deaths from adrenal insufficiency. Since 1927, they had been developing an adrenocortical extract and using it perioperatively with some success. In 1934, they reported ten female patients with Cushing's syndrome who had been operated upon, with five having adrenal tumors, four of which were carcinomas. One tumor was palpable, one was seen on x-ray, and three found at operation. Three developed acute adrenocortical failure, and one of them who was treated in 1923 before cortical extract was available died. The other two received cortical extracts and recovered. Three of the five with tumors

underwent remission [11]. By 1938, the Mayo group had removed tumors successfully from 16 consecutive patients, most of whom had Cushing's syndrome. Elsewhere, adrenal crises were all too frequent after surgical excision of tumors, and by 1943 more than 80% of such patients were reported to have died [10, 17–20]. The potent preparation of “cortin” at the Mayo Clinic, apparently, was the most important factor allowing their success. The intensive search for the active cortical substance(s) was ongoing from 1927 until its eventual discovery and preparation in 1949.

It was imperative for the management of Cushing's syndrome to have such a preparation whether treatment be pituitary or adrenal surgery. The dismal prognosis for patients with Cushing's syndrome was emphasized by Charles Plotz's paper on the natural history of the disease in 222 patients in 1952 showing a high incidence of cardiovascular disease, psychosis, and osteoporosis. Therapy had been effective in only 5 of their own 33 patients (pituitary irradiation in three and excision of adrenal adenomas in two). The overall mortality was 50% after 5 years from onset. Infections and cardiovascular disease were the most common causes of death. Another 20% died from surgical operations [10].

Between 1930 and the discovery of cortisone in 1949, details of nearly 300 patients with ACC were published [15, 17, 19–22]. Metastases were still often seen initially or soon after operation. The clinical features were in order of frequency, virilism, Cushing's syndrome, and combined Cushing's and virilism. These accounted for 75% and only 25% were apparently without a syndrome. Rarely, feminization was reported. This was first described in 1915, but only 30 additional cases were seen in the next 30 years and all were associated with an adrenal malignancy producing estrogens in excess. In 1930, Anderson described an ACC with fatal hypoglycemia but no other metabolic disturbance [23]. Ten similar cases of Anderson's syndrome were reported in the next 30 years, a few of whom went into remission after tumor removal. Three quarters of the 300 patients reported underwent operation and one-third died postoperatively. The mortality was greatest in those with Cushing's and least in those with nonsecreting tumors. In the surviving group, some had good long-term results, but only when the tumor had been completely excised.

A milestone in the treatment of ACC was the general availability of cortisone after 1950. By 1948, only a few grams were available at the Mayo Clinic. The first patient with Cushing's disease in whom this was used perioperatively was on December 3, 1949. Within a year, 18 patients underwent successful subtotal adrenalectomies there using cortisol pre- and postoperatively [10,15]. Kendall, Hench, and Reichstein received the Nobel Prize in 1950 for the development of cortisone and its use in adrenal surgery as well as in rheumatology. Soon, synthetic analogues of cortisone including prednisone, prednisolone, and dexamethasone became widely available. By 1957, an intravenous preparation of cortisol, hydrocortisone, was used intraoperatively and in urgent situations of adrenal insufficiency. By 1955, Tait and Simpson in London and Reichstein in Basel had isolated and prepared electrocortin, later renamed aldosterone for clinical use as fludrocortisone in 1956 [24]. Thus, surgeons in the 1950s for the first time could operate on patients

with ACC and Cushing's syndrome without the danger of acute adrenal insufficiency causing an immediate crisis or early postoperative death. Remission of symptoms and findings followed rapidly in patients with ACCs where excisions were possible. They were usually complete within 1 year. Parallel developments occurred with the introduction of drugs which inhibited adrenocortical tumors from secreting steroids. These included amphenone, metyrapone, and aminogluthetimide in the mid-1960s. These were of some benefit in alleviating symptomatic persistence or recurrences after operations [25].

Many more cases of ACC were reported after 1950. The principal endocrine features in nearly 90% of patients were Cushing's, virilization, a combination of both, feminization and rarely aldosteronism (first case in 1955) [10, 19, 21, 22, 24, 26–31]. Although more women were diagnosed in life, the overall incidence in males was higher. Despite improved diagnostic tests such as urinary steroids, dexamethone suppression test (1960s), and an RIA for ACTH in the mid-1960s, the lag period between the onset of symptoms and the diagnosis was about 8 months. Local invasion and distant metastases at the time of exploration were still frequent. Although there were no good statistics on survival in the 1950s, the general consensus was that most patients died from the disease unless fortunate enough to have been operated before either local invasion was extensive or metastatic disease had occurred. One of the reasons for lack of good data was the rarity of the disease as emphasized by Steiner's 1954 report from the Los Angeles County Hospital [21]. In his study of all autopsies there from 1918 to 1947, only 15 cases of ACC were found, accounting for only 0.2% of all tumors. In 1952, Rappaport in a collective review found a total of 238 hormonal and 34 nonhormonal cases of ACC during the 20-year period from 1930 to 1949 [19]. Wood, in 1957, could find only 27 cases of nonhormonal ACC in the European and American literature from 1923 to 1956 [10]. MacFarlane in 1958 reviewed 55 patients from London teaching hospitals which included 35 with hormonal and 25 with nonhormonal findings [21]. Their average age was 32 years and ranged from infants to 68 years. For those with hormonal symptoms, 80% were less than 40 years of age and 65% with nonhormonal findings were greater than 50 years. The average duration of symptoms before treatment was 13.2 months, 17 months for those with hormonal symptoms but only 10.8 months for those without hormonal symptoms. One-third of all patients had local invasion and all but two of these patients had distant metastases. Overall, 34 of the 55 patients (61.8%) had metastatic disease at diagnosis. The liver was involved in 67%, the lungs in 47%, and local nodes in 44%. For those who were untreated, survival was only 2.9 months for those with nonhormonal findings and 3.8 months for those with hormonal symptoms. MacFarlane was the first to propose an operative staging system based on tumor size, local invasion, nodal and distant metastases. Stage I tumors were 5 cm or smaller without local invasion or metastases, a rare finding as the average tumor size was 12 cm. An operation was performed in 42 of the 55 patients and considered radical and potentially curative in 20 (36.4%). A palliative excision was performed in 12 (22%) patients. The operative mortality was still high at 26% overall but fell from 35% before 1952 to 16.7% after 1952. This was attributed primarily to the availability of cortisone. The 2-year survival

was 24% and occurred only in those undergoing radical extirpation and adequate hormone replacement therapy. MacFarlane considered dissection of lymph nodes of limited value and nephrectomy unnecessary unless the kidney was directly involved. London surgeons favored a thoracoabdominal extrapleural approach, resecting the 11th rib to allow maximum exposure.

The next major event in the management of ACC was the introduction of o,p'-DDD (mitotane), an analogue of the insecticide DDT which had previously been found in animal studies to cause adrenocortical atrophy. It was first used clinically in 1960 to treat inoperable or recurrent ACCs. In 1960, Bergenstad reported o,p'-DDD sufficiently effective that the National Cancer Institute sponsored its production and distribution for clinical investigation [3]. Previously, the NCI had reported 38 patients with ACC treated there [30]. In only 18 was it possible to attempt a curative operation, whereas in the others, either a palliative procedure or biopsy was done. They noted a 50% mortality 2 years after first symptoms, and only seven were alive more than 5 years after the onset of symptoms, with only two disease-free. In those in whom a curative operation could not be attempted, the mortality was 70% after 2 years. The causes of death included large pulmonary and abdominal masses causing pneumonia, caval thrombosis, sepsis, and pulmonary embolus. The first major report of the NCI evaluation of o,p'-DDD was by Hutter et al. in 1966 [33, 34]. By then, they had collected 138 previously unpublished cases in which o,p'-DDD was used and compared those with the 48 previously treated and reported cases elsewhere. The average age of their patients was 37.6 years and 92 were female and 43 were males. Cushing's syndrome was found in 59% and virilization in 19%. Local spread was found in 65%, whereas 53% developed pulmonary and 44% liver metastases. Survival was better in females with 52 versus 38 alive 4 years after diagnosis. The median survival after diagnosis for all females was 56 months and only 19 months for males. Mitotane was considered effective in some cases but was of limited value in prolonging survival. The next major report on the use of mitotane in inoperable ACC cases was by Lubitz et al. in 1973 [35]. They reported on 115 patients with inoperable ACC seen between 1965 and 1969. A disease response was seen in 61% of patients treated, lasting an average of 10.3 months. Although 84% had an adverse response to the drug involving the gastrointestinal, central nervous, and dermatological systems, these were all reversible with discontinuance or decrease in drug dosage. They found that 45% showed a favorable clinical response and that elevated steroid levels fell in 85%. Even though there were no cures, the mean duration of life for the entire group was only 8.4 months with treatment. Van Slooten, in 1983, was one of the first to observe that serum level monitoring of mitotane was important [36]. He found that if the serum level was maintained at 14 µg/ml or higher, the survival time at 26.5 months was 50% compared to only 14.5 months if the level was less than 14 µg/ml. Their recommendation was that all patients receiving mitotane should have serum level monitoring and the drug dose adjusted accordingly.

Since then, several large series of ACC patients have been reported and although there had been hope that with the widespread use of a variety of imaging techniques the diagnosis of ACC would be made at an earlier stage, that has not occurred

[26–28, 37, 38]. Luton et al. in reporting 105 patients from France, again found more females than males in a clinical series (75/30) with a mean age of 46 years [38]. Their duration of symptoms was 8.7 months at diagnosis and nearly 70% had endocrine symptoms. When steroid studies were done, 79% were functional. At the time of diagnosis, 30% had distant metastases. Operations were performed in 80% and 59% received mitotane. The median disease-free interval after operation was 12.1 months during which tumor dissemination occurred in 82%. The median survival time was 14.5 months and the 5-year survival was only 22%. They, like others, concluded that mitotane should be used as it did lower hormone levels and was transiently beneficial, particularly when endocrine symptoms were present. Again, survival benefits were not proven.

Since the first patients with ACC were recognized and treated, a radical surgical extirpation remains the only real chance for cure in those patients who do not already have hematogenous spread. In such cases, a number of important surgical principles must be considered in order to increase the possibility of a successful outcome (Table 2.1). Earlier diagnosis, allowing for that option, has not been seen in any large series. Operative mortality has improved because of the recognition and treatment of adrenal insufficiency in those patients with Cushing's syndrome and contralateral adrenal atrophy. Steroid replacement with hydrocortisone and fludrocortisone in patients treated with mitotane has also decreased morbidity. The overall operative mortality has dropped from the pre-1950s level of 30–40% to less than 5% in most reports. Chemotherapy and radiotherapy are traditionally of a very limited value in terms of a curative approach. Mitotane is the only adjunctive therapy currently available, although generally considered to be of only transient benefit. It should be noted, however, that several dozen long-term remissions in patients with distant metastases have been reported [2, 27, 39]. Obviously, the continued failure to detect ACC at an early stage remains a major deterrent to successful therapy. The hope for the future is that new drugs specifically targeted to individual tumors, based on gene profiling, can be developed. Until that day, ACC will remain a most challenging disease for physicians and surgeons to manage.

Table 2.1 Basic principles learned in surgical management of ACC (Figs. 2.1–2.3 are case sketches provided courtesy of the author N. W. Thompson)

-
1. Adequate steroid preparation and maintenance in patients with Cushing's syndrome or while on long-term mitotane therapy.
 2. In case of a high suspicion of an ACC, needle biopsy is contraindicated pre-operatively; spillage of tumor cells will prevent cure (Fig. 2.1a, b).
 3. Incisions allowing wide local exposure of the tumor and intra-abdominal metastases, making every effort to avoid rupturing the tumor capsule when it is localized and potentially curable.
 4. Avoidance of laparoscopic techniques.
 5. Preparation for possible aortopulmonary bypass in cases where tumor extends into the vena cava. This assumes appropriate pre-operative imaging in all patients (Fig. 2.2a, b).
 6. Nephrectomy is not beneficial unless kidney or renal vein is invaded (Fig. 2.3).
 7. A reoperative procedure is indicated where local recurrence can be excised without excessive risks (see Fig. 2.1).
 8. Use of mitotane postoperatively in all patients without anaplastic histopathology providing serum monitoring can maintain serum levels above 14 $\mu\text{g/ml}$ and below 20 $\mu\text{g/ml}$.
-

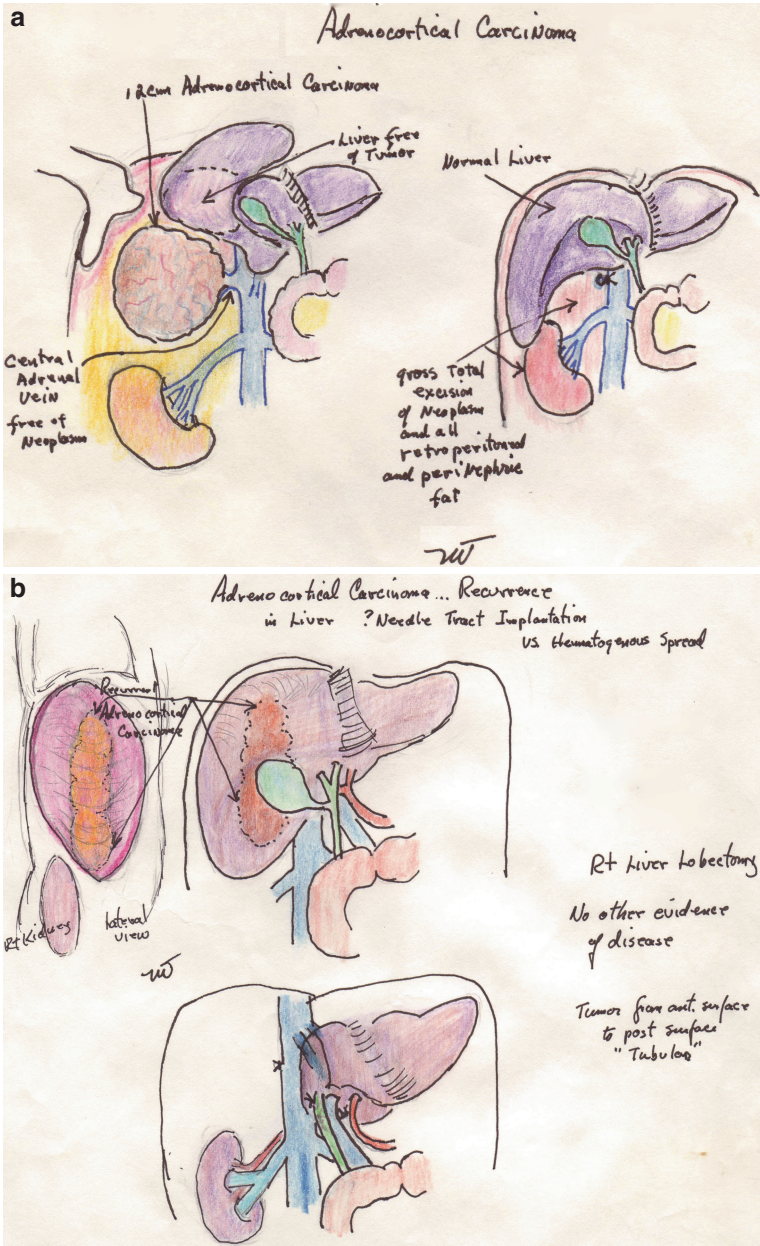


Fig. 2.1 (a) A 32-year-old female with large right adrenal ACC mistakenly diagnosed as a hepatic cell adenoma with hemorrhage because of 14-year history of birth control pills, 5-day history of severe right upper quadrant pain, and a percutaneous, transhepatic FNA diagnosis. She was referred for a right hepatic lobectomy. (b) Same patient 2 years later with recurrent ACC limited to right lobe of liver along the FNA tract. Following right lobectomy, there was no evidence of recurrence 2 years later

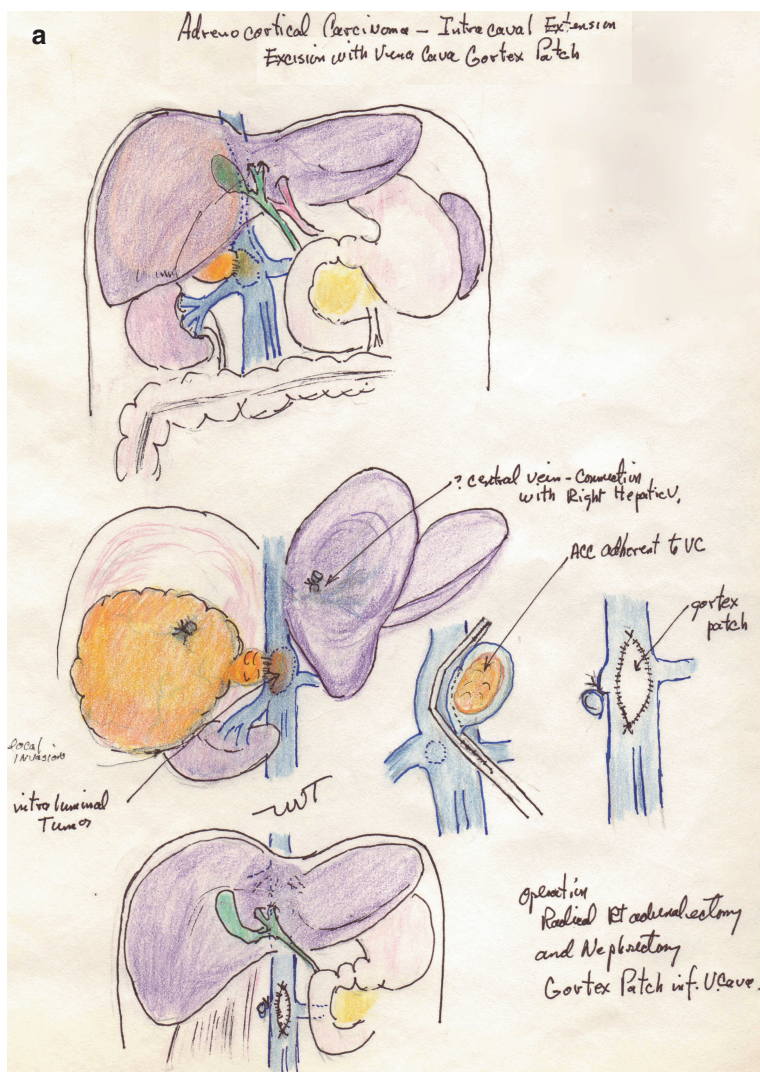


Fig. 2.2 (a) A 35-year-old female with nonfunctional ACC and limited extension into the vena cava. Right adrenalectomy and nephrectomy (tumor adherence to kidney) and gortex patch of caval excision site. (b) A 40-year-old male 1 year post right adrenalectomy for 11 cm ACC with caval extension. Developed Budd Chiari syndrome and treated with cisplatin and VP-16. Referred 2 years later for possible operative treatment. No other metastatic disease. With cardiopulmonary bypass and cold arrest, tumor thrombus into right atrium excised and endovenectomy of all tumors in vena cava and both left and middle hepatic veins excised. A pericardial patch was used for the vena cava and distal hepatic veins. The patient had an uneventful course with complete relief of the Budd Chiari syndrome

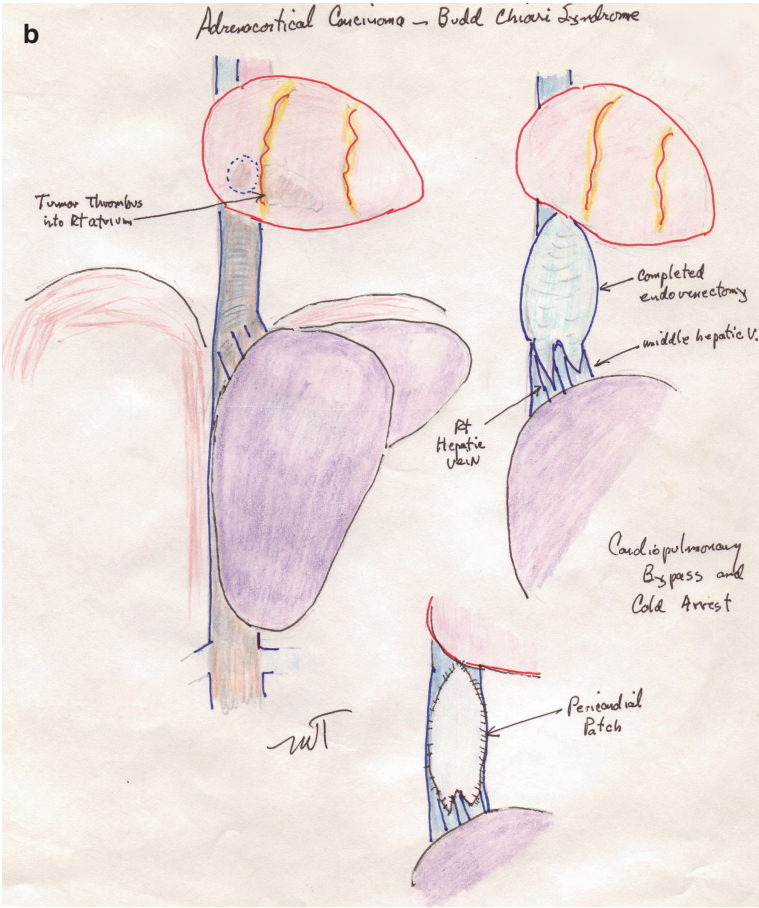


Fig. 2.2 (continued)

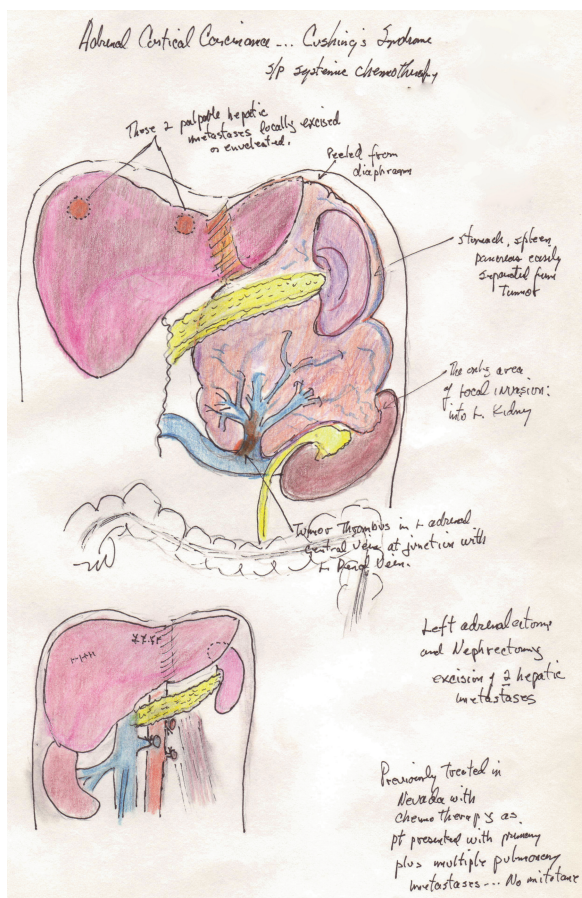


Fig. 2.3 A 47-year-old female with large left adrenal ACC with tumor thrombus into left renal vein. Adrenalectomy, nephrectomy, and excision of two liver metastases resulted in palliation of Cushing's syndrome for 16 months

References

1. Grawitz P (1883) Die sogenannten lipome der niere. Virchow's Archiv Pathol Anal and Klin Med xciii:121–124
2. Rolleston HD (1936) The endocrine organs in health and disease. Oxford University Press, London, pp 301–384
3. Curtis BF (1900) Nephrectomy for suprarenal tumor. Ann Surg 31:759–760
4. Fey B (1926) L'abord du rein par voie thoraco-abdominal. Arch Urol Clin Necker 5:168–178
5. Holmes G (1925) Virilism associated with a suprarenal tumor. Q J Med 18:143–152
6. Kennedy CM, Lister WA (1927) Suprarenal hypernephroma. Lancet 2:739–751
7. Keyser LD, Walters W (1924) Carcinoma of the suprarenal. JAMA 82:87–88
8. Lissner H (1933) Successful removal of adrenal cortical tumor. Trans Associa Am Physicians 48:224–235
9. Richards O (1905) Growths of the kidneys and adrenals. Guy's Hosp Rep 59:217–332

10. Welbourn RB (1990) The history of endocrine surgery. Praeger, New York
11. Walters W et al (1934) The suprarenal cortical syndrome. *Ann Surg* 100:670–688
12. Thornton JK (1890) Abdominal nephrectomy for large sarcoma of the left suprarenal capsule: recovery. *Trans Clin Soc London* 23:150–153
13. Robson AWM (1899) Removal of the suprarenal capsule. *Br Med J* 2:1100–1101
14. Ramsay O (1899) Malignant tumors of the suprarenal gland. *Johns Hopkins Hosp Bull* nos 94–96:20–29
15. Walters W, Sprague RG (1949) Hyperfunctioning tumors of the adrenal cortex. *Ann Surg* 129:677–701
16. Broster LB et al (1932) Adreno-genital syndrome: unilateral adrenalectomy. *Brit J Surg* 19:557–570
17. Kepler EJ, Keating FR (1941) Diseases of the adrenal glands. *Arch Int Med* 68:1010–1036
18. Murray GG, Simpson G (1929) Virilism due to an adrenal hypernephroma. *Lancet* 2:734–749
19. Rapaport E et al (1952) Mortality in surgically treated adrenocortical tumors. *Postgrad Med* 11:325–329
20. Thompson KW, Eisenharatt L (1943) Further consideration of the Cushing's syndrome. *J Clin Endocrinol Metab* 3:445–452
21. MacFarlane DA (1958) Cancer of the adrenal cortex. *Ann R Coll Surg Engl* 23:155–162
22. Priestly JT (1952) Lesions of the adrenal glands. *Surg Clin N Am* 32:1053–1064
23. Anderson HB (1933) Successful removal of adrenal cortical tumor. *Trans Associa Am Physicians* 48:224–235
24. Thompson NW (1983) Adrenocortical carcinoma. In: Thompson NW, Vinik AI (eds) *Endocrine surgery update*. Grune and Stratton, New York
25. Sahteingart DE et al (1982) Treatment of adrenal carcinomas. *Arch Surg* 117:1142–1147
26. Cohn K et al (1986) Adrenocortical carcinoma. *Surgery* 100:1170–1177
27. Icard P et al (1992) Adrenocortical carcinoma in surgically treated patients: a retrospective study on 156 cases by the French Association of Endocrine Surgery. *Surgery* 112:972–980
28. Kelly WF et al (1979) Cushing's syndrome due to adrenocortical carcinoma. *Acta Endocrinologica* 91:303–318
29. Lewinsky BS et al (1974) The clinical and pathologic features of "non-hormonal" adrenocortical tumors. *Cancer* 33:778–790
30. Lipsett MB et al (1963) Clinical and pathophysiologic aspects of adrenocortical carcinoma. *Am J Med* 35:374–383
31. Richie JP, Gittes RE (1980) Carcinoma of the adrenal cortex. *Cancer* 45:1957–1964
32. Bergenstall DM et al (1960) Chemotherapy of ACC with *o,p'*-DDD. *Ann Int Med* 53:672–680
33. Hutter AM, Kayhoe DE (1966) Adrenal cortical carcinoma: clinical features of 138 patients. *Am J Med* 41:572–580
34. Hutter MM, Jr, Kayhoe DE (1966) Adrenal cortical carcinoma. Results of treatment with *o,p'*-DDD in 138 patients. *Am J Med* 41:581–589
35. Lubitz JA et al (1973) Mitotane use in inoperable adrenal cortical carcinoma. *JAMA* 223:1109–1112
36. VanSlooten H et al (1984) The treatment of adrenocortical carcinoma with *o,p'*-DDD: prognostic simplification of serum level monitoring. *Eur J Cancer Oncol* 20:47–53
37. Hogan TF et al (1978) *o,p'*-DDD (mitotane) therapy of adrenal cortical carcinoma. *Cancer* 42:2177–2188
38. Lutton JP et al (1990) Clinical features of adrenocortical carcinoma, prognostic factors, and the effect of mitotane therapy. *N Engl J Med* 322:1195–1201
39. Boven E et al (1984) Complete response of metastasized adrenal cortical carcinoma with *o,p'*-DDD. *Cancer* 53:26–29

Adrenocortical Carcinoma

Basic Science and Clinical Concepts

Hammer, G.D.; Else, T. (Eds.)

2011, XV, 546 p., Hardcover

ISBN: 978-0-387-77235-6