

Maria Z. Siemionow, Bahar Bassiri Gharb,
and Antonio Rampazzo

Contents

2.1	Introduction	11
2.2	Facial Skin Receptors and Their Function	12
2.3	Physiology of Facial Sensation	13
2.3.1	Light Touch	13
2.3.2	Temperature and Pain	13
2.4	The Ascending Pathways of Facial Sensation	13
2.5	The Peripheral Pathways of Facial Sensation	14
2.5.1	Trigemino-Facial Communications	14
2.6	Evaluation of Facial Cutaneous Sensibility, Temperature, and Pain Thresholds	15
2.7	Conclusions	20
	References	21

Abstract The human face is a highly specialized organ which receives sensory information from the environment and transmits it to the cortex. The advent of facial transplantation has recently shown that excellent reconstruction of disfiguring defects can be achieved; thus, the expectations are now focused on functional recovery of the transplant. So far, restoration of the facial sensation has not received the same attention as the recovery of motor function. We describe the current knowledge of the sensory pathways of the human face and their respective functions, the available methods of sensory assessment, and the data on normal sensation. The topographical sensory anatomy of facial subunits is summarized, the trigemino-facial connections are illustrated, and the implications of these anatomical variations on facial allotransplantation are emphasized.

2.1 Introduction

Since 2005, 11 reports on face transplantation have confirmed that this procedure is technically and immunologically feasible. The goal of reconstructing severely disfiguring facial defects by coverage with similar tissues coming from human donors has been achieved. This opened the discussion on the best approach to achieve functional recovery of the transplanted face with restoration of fine facial movements and sensation. These two determinants of optimal functional recovery were restored differently for documented cases of face transplantation. In three patients, the facial nerve was repaired either directly (two patients)¹ or with interpositional nerve grafts (one patient),²⁻⁴ whereas the sensory nerves were satisfactorily repaired only in one case.¹ These differences in the reconstructive approaches

M.Z. Siemionow (✉)
Department of Plastic Surgery, Cleveland Clinic,
Cleveland, OH, USA
e-mail: siemiom@ccf.org

to motor and sensory nerve repairs were mainly dictated by the extent of facial trauma before transplantation.

One of the fundamental functions of the human face is the ability to receive multimodal sensory information from the environment and to convey it to the cerebral cortex for integration and processing. The presence of normal sensation is important not only for the discrimination of touch, temperature, and pain, but also for initiation of vigilant or defense reactions. The presence of labial sensation helps in avoiding drooling while eating or drinking.⁵ Stretching of the perioral skin contributes to the precise articulation in speech.⁶ Interestingly, cutaneous stimulation increases the intensity of estimates of the olfactory system.⁷ It has also been reported that facial skin cooling decreases the heart rate and increases blood pressure.⁸ Finally, normal sensory pathways allow to draw pleasure and satisfaction when exposed to external stimuli.⁹ It is clear that restoration of the above functions is expected and essential for the optimal outcomes following face transplantation.

To learn more about the importance of the face as a sensory organ, the aim of this chapter is to illustrate the complexity of the sensory pathways of the face and their specific functions, to review current methods of assessment of facial sensation, and to summarize the available data on normal sensation. Finally, the topographical sensory anatomy of facial subunits is summarized and the implications of sensory–motor communications on the mechanism of recovery of facial sensation after trauma and face allotransplantation are discussed.

2.2 Facial Skin Receptors and Their Function

Over 17,000 corpuscles have been reported in the human face, which contribute to several sensory functions.¹⁰ For the discrimination of touch, four different types of receptors have been described in the hairy skin of the face and include Ruffini corpuscles, Meissner corpuscles, Merkel cell disks, and hair receptors (Fig. 2.1).

Ruffini corpuscles are especially sensitive to skin stretch, consist of axon terminals and surrounding Schwann cells that envelop tightly bundles of collagen fibrils and are associated with vellus hairs. They are innervated by the superficial portion of the dermal neural network.

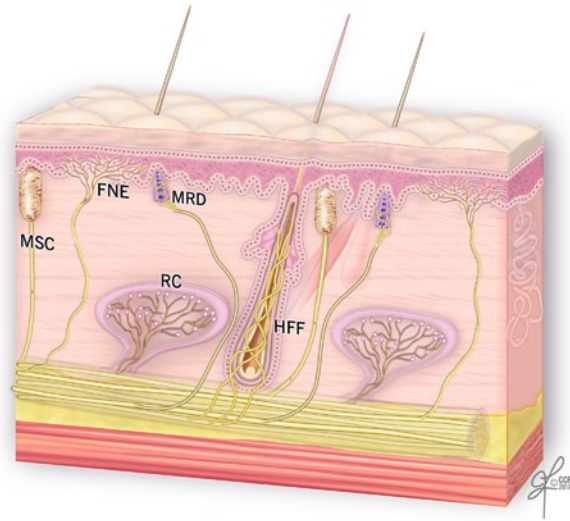


Fig. 2.1 The receptors of the human facial skin. MSC meissner corpuscle, FNE free nerve endings, MRD merkel disk, RC ruffini corpuscle, HFF hair follicle fiber (Reprinted with permission, Cleveland Clinic Center for Medical Art & Photography © 2010. All Rights Reserved)

Meissner corpuscles are more sensitive to stroking and fluttering of the skin and are localized in the dermal papillae. They are globular fluid-filled structures enclosing a stack of flattened epithelial cells. The terminal axons are entwined between the various layers of the corpuscles.

The *Merkel disk receptors* are formed by a small epithelial cell surrounding the nerve endings. Merkel receptors detect pressure applied on the skin and discriminate texture of objects. Two different types of Merkel cells have been described in facial skin.¹¹ The first type is localized in the dermis, on the external root sheath collar; it is not associated with nerve terminals and it is undifferentiated. The Merkel cells localized in the basal layer of the epidermis are associated with nerve terminals and have different granules within a single cell. An endocrine function has been attributed to them via regulation of the autonomic nerves.¹²

Interestingly, the *Pacini corpuscles*, which are well described in the fingertips and the palm of the hand where they are responsible for detection of vibrations, are absent in the skin of the human face.^{12–14}

Hair follicle fibers work in a similar way to Meissner corpuscles, displaying a lower threshold for light stroking. They form a palisade of lanceolate terminals, which abut the external root sheath of the vellus hair in

the region of the follicular neck. They derive from the deeper portion of dermal nerves.¹⁵

Beyond nerve fibers connected to mechanoreceptors and hair follicles, there are also free nerve endings with sensory function (temperature and pain). The intraepidermal nerve fibers terminate in different cellular layers, although the majority reach the stratum granulosum. The distribution of these endings is focal.^{16,17} Kawakami et al.¹⁶ reported that face presents with the highest distribution density of the free nerve endings. It was reported that beyond the sensory role, they may have also a trophic or immunoregulatory function.^{17,18}

2.3 Physiology of Facial Sensation

2.3.1 Light Touch

The response of the face to the light touch is mediated by facial mechanoreceptors. These are associated with A β fibers (myelinated, 10–15 μ m in diameter), divided into slowly and quickly adapting units. *Slowly adapting axons* initiate neural signals as soon as the skin is stimulated and continue to generate them as long as the cutaneous stimulus is sustained. *Ruffini complexes* and *Merkel cell disks* are the terminal corpuscles that are associated with these nerve fibers.¹⁹

Quickly adapting nerve fibers are activated only when new stimuli are applied. *Hair follicle fibers* and *Meissner corpuscles* are involved in transduction of these signals.^{19,20} Innervation density for both quickly and slowly adapting fibers has been reported to increase from the upper face to the mid-face, followed by the lower face and the lip.¹⁹

Receptive field sizes of the facial skin afferents have been described to be similar in dimension to the receptive fields of the afferents innervating the vermillion (7–8 mm²)¹² and the highest concentration of facial mechanoreceptors has been found at the corners of the mouth.²¹

2.3.2 Temperature and Pain

The perception of temperature changes and painful stimuli delivered to facial skin is not mediated by corpuscle receptors, but by small myelinated (A δ) and

unmyelinated fibers (C fibers). The *cold receptors* increase the firing rate with decreases in temperature, while *warmth receptors* increase the firing rate with increased temperature. In a study by Davies et al.,²² raising of the temperature between 35°C and 40°C evoked a sensation of warming. In contrast, the cold receptors increased activity at lower temperatures ranging between 35°C and 15°C.

Nociceptors of the face are responsible for central transmission of painful stimuli and are activated by high threshold skin indentations (23 or 51 g),²³ as well as temperatures below 0°C²⁴ or above 47°C.²⁵

2.4 The Ascending Pathways of Facial Sensation

The ascending pathways transmit the somatosensory information collected by the facial receptors, and conveyed by the peripheral axons of the *trigeminal sensory neurons* (along the peripheral pathways), to higher cortical centers for processing and integration.²⁶ These primary sensory neurons reside in the trigeminal ganglion (Gasser's ganglion or Ganglion Semilunaris) in the middle cranial fossa, from which afferent fibers pass into the mid-pons²⁷ (Fig. 2.2). The *second order sensory neurons* reside in trigeminal sensory nucleus. The sensory nucleus is divided into three subnuclei: the *principal sensory nucleus* is located in the pons and mediates *facial light touch* and *pressure* sensation; the *mesencephalic nucleus*, which receives *proprioceptive information* from the masticator muscles and the *nucleus of the spinal tract*, extends into the upper cervical cord (C2–C4) and is responsible for transmission of *facial pain* and *temperature* and secondarily *facial touch*.^{28,29} After entering the pons, the pain and temperature fibers run caudally, forming the descending trigeminal tract and synapse with the second order neurons of the spinal nucleus. The axons of these neurons cross the midline and extend to the contralateral ventral posteromedial (VPM) nucleus of the thalamus, forming the *ventral trigeminothalamic tract* (or lemniscus).³⁰ Sensory fibers mediating light touch synapse in the principal sensory nucleus.³¹ The secondary neuron axons ascend to the VPM nucleus of thalamus either contralaterally in the ventral trigeminothalamic tract (most) or ipsilaterally (*dorsal trigeminothalamic tract*)^{29,30,32} (Fig. 2.2).

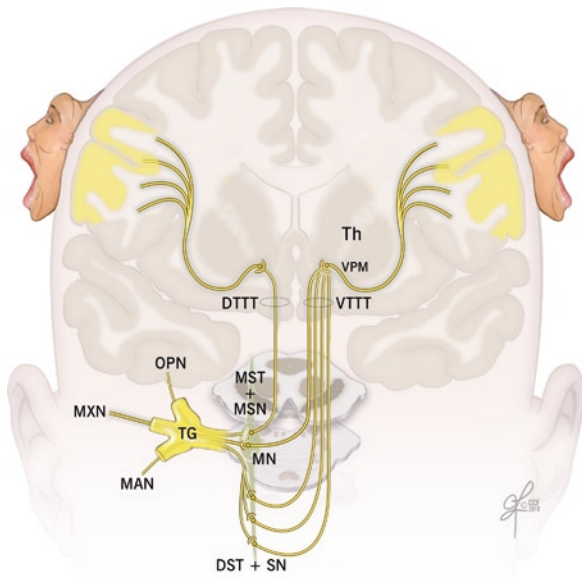


Fig. 2.2 Ascending pathways of facial sensation are shown from the peripheral branches of the trigeminal nerve which collect the sensory information and convey it to the Central Nervous system. *OPN* ophthalmic nerve, *MXN* maxillary nerve, *MAN* mandibular nerve, *TG* trigeminal ganglion, *MST+MSN* mesencephalic tract and nucleus, *MN* main sensory nucleus, *DST+SN* descending spinal tract and nucleus, *VTTT* ventral trigeminothalamic tract, *DTTT* dorsal trigeminothalamic tract, *Th* thalamus, *VPM* ventral posteromedial nucleus of thalamus (Reprinted with permission, Cleveland Clinic Center for Medical Art & Photography © 2010. All Rights Reserved)

From the ventroposteromedial thalamic nucleus, a third relay of fibers, the *thalamocortical tract* in the internal capsule, passes to the extensive face area of the main sensory neocortex (S-1 and S-2) of the post central gyrus (Brodmann areas 3, 1, 2) and the upper bank of the sylvian fissure³² (Fig. 2.2). Penfield reported that the representation of the facial structures was organized along the central sulcus, with the forehead in the superomedial region adjacent to the hand area, and the chin in the³³ inferolateral region.³³ The order of representation of the different facial subunits has been subject of debate. Tamura et al.³⁴ found, by using somatosensory-evoked magnetic fields, that topography of the areas representing intraoral structures along the central sulcus was the index finger, upper or lower lip, anterior or posterior tongue, and superior or inferior buccal mucosa, with a wide distribution, covering 30% of the S1 cortex. The skin-covered areas of the face were recently “relocated” between the thumb and the lip,

which was in contrast to the original Penfield study.³⁵ Current studies in monkeys showed evidence for an upside-down representation;³⁶ however, studies by other investigators could not confirm either orientation.³⁷

2.5 The Peripheral Pathways of Facial Sensation

The peripheral pathways, formed by the peripheral branches of the trigeminal sensory neurons, are responsible for conveying the sensory data from the facial skin to the Central Nervous System. The peripheral fibers of the primary sensory neurons exit the trigeminal ganglion organized into three trunks: the ophthalmic (V1), the maxillary (V2), and the mandibular (V3) nerves. The former two are purely sensory, whereas the latter is a mixed sensory and motor nerve. The trigeminal nerve collects sensibility of the full face except a small area around the mandibular angle and the auricular lobe, which is innervated by the great auricular nerve (C2–C3) (Fig. 2.3). The branches of these nerves supply sensation to the facial subunits of the upper face, mid-face, and lower face as summarized in Tables 2.1–2.3.

2.5.1 Trigemino-Facial Communications

When assessing the sensory recovery after facial trauma or transplantation, it is important to take into consideration the existence of direct connections between trigeminal nerve and facial nerve, which may play an important role in the mechanisms of facial sensory recovery.

The cutaneous branches of all three divisions of the trigeminal nerve and of the great auricular nerve show plexiform connections with the terminal rami of the facial nerve (Fig. 2.4). These connections can occur either in the proximal (auriculotemporal, great auricular) or distal (supraorbital, infraorbital, buccinators, mental) region of the facial nerve distribution. The auriculotemporal connections, to the upper division of the facial nerve, are the most consistent and sizable and represent the most constant pattern of the trigemino-facial communications.^{38,39}

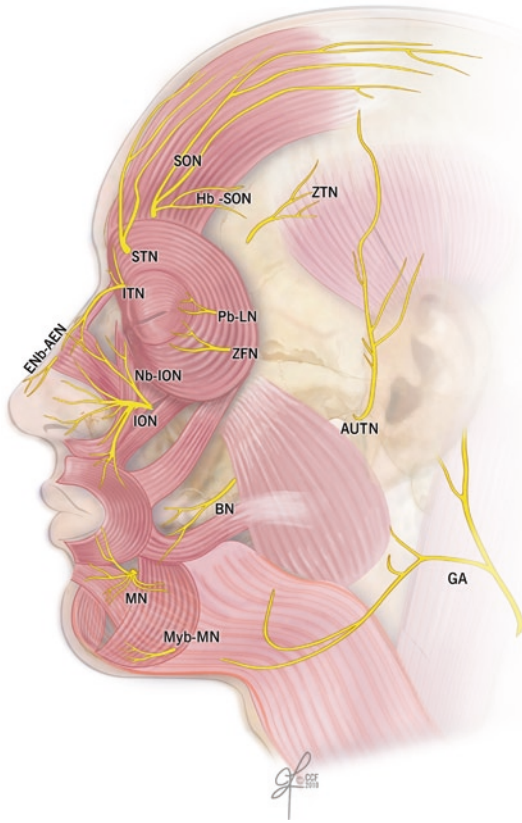


Fig. 2.3 Sensory innervation of the human face. *BN* buccal nerve, *ENb-AEN* external nasal branch-anterior ethmoidal nerve, *GA* great auricular nerve, *Hb-SON* horizontal branch supraorbital nerve, *ION* infraorbital nerve, *ITN* infratrochlear nerve, *MN* mental nerve, mylohyoid branch-mental nerve, *Pb-LN* palpebral branch-lacrimal nerve, *SON* supraorbital nerve, *STN* supratrochlear nerve, *ZFN* zygomaticofacial nerve, *ZTN* zygomaticotemporal nerve (Reprinted with permission, Cleveland Clinic Center for Medical Art & Photography © 2010. All Rights Reserved)

There is no common agreement on the function of the nerve fibers in the communicating rami. O'Connell and Huber reported that the relationship was of mere contiguity and after a joint journey, the sensory branches separated from the motor branches, each element finding the tissue it was destined to supply.^{40,41} Others suggested that the trigeminal nerve fibers, in the communicating rami, conveyed proprioceptive information regarding the mimetic muscles, and the pseudomotor fibers to the integument or secretomotor fibers to the superficial part of the parotid and buccal mucosa glands.⁴² Baumel implied⁴³ that sympathetic

and parasympathetic fibers, not belonging to the trigeminal nerve, may also be the constituents of the communicating rami.

Finally, some investigators hypothesized presence of a sensory component in the facial nerve which explained the preservation of deep facial sensation after trigeminal neurectomy.^{44,45} The connections between the facial nerve and the branches of the trigeminal and cervical nerves could also provide an additional motor supply to the superficial facial musculature.⁴¹

2.6 Evaluation of Facial Cutaneous Sensibility, Temperature, and Pain Thresholds

Current methods of sensibility testing evaluate the fiber–receptor complexes that mediate the perception of touch, temperature, and pain. *Pressure thresholds* (Semmes–Weinstein monofilament test) and *static two-point discrimination* (Disk-Criminator, Pressure-Specified Sensory Device) assess the function of slowly adapting fibers associated with Ruffini receptors and Merkel cell disks.^{19,20} *Tactile discrimination* reflects the number of innervated sensory receptors. *Moving two-point discrimination* and *vibration stimuli* (Tuning fork) assess the function of quickly adapting nerve fibers, hair follicle fibers, and Meissner corpuscles.^{19,20} Perception of two-point discrimination, vibration, and pressure threshold values improves from the lateral and posterior areas of the face to the midline, with the vermilion being the most sensitive area and the forehead being the least sensitive.^{46,47} Table 2.4, summarizes the values of normal ranges for tactile discrimination of the human face.

Two-point discrimination and vibratory values in females are reported to be lower when compared to males, although these differences are not statistically significant. There are also no significant differences between left and right side of the human face.^{46,48,49} Interestingly, all of the tests evidence higher values for smokers and subjects older than 45 years of age.^{19,46}

The facial skin is relatively uniform in its sensitivity to warming. In response to *thermal stimuli*, the infraorbital region and nose are the most sensitive to warming, whereas other areas of the face do not differ

Table 2.1 Sensory innervation of the upper face including: forehead, temporal area, and upper eyelids

Nerve	Origin	Exit foramen	Branches	Structures crossed	Areas innervated
Forehead					
Supratroclear (V1)	Terminal branch of the frontal division of the ophthalmic nerve (V1) ⁶⁴	Upper medial corner of orbit ^{65,66}	Three or four branches, ⁶⁷ connection to medial branch supraorbital nerve ⁶⁸	Corrugator and frontalis muscles ⁶⁷	Nasal root, glabella, midforehead ^{64,67,69}
Supraorbital (V1)	Largest terminal branch of the frontal nerve ⁶⁴	Orbital margin, notch, or multiple foramens ⁷⁰	Superficial and deep branches	Frontalis muscle	Forehead skin from the orbital margin to the frontal hairline, parietofrontal scalp from midline to the superior temporal line up the level of the posterior edge of the helical rim of the ear ⁶⁷
Zygomatico-temporal (V2)	First branch of the zygomatic nerve	Zygomaticotemporal foramen	None	Temporalis muscle, deep and superficial temporal fascia	Lateral forehead
Upper eyelids					
Supratroclear (V1)	Terminal branch of the frontal division of the ophthalmic nerve (V1) ⁶⁴	Upper medial corner of orbit ^{65,66}	Three or four branches, ⁶⁷ connection to medial branch supraorbital nerve ⁶⁸	Corrugator and frontalis muscles ⁶⁷	Medial upper eyelid ^{64,67,69}
Infraorbital (V1)	Largest branch of the nasociliary nerve (V1)	Anterior etmoidal foramen	Superior branches	Orbicularis Oculi	Skin of medial eyelids ⁶⁴
Infraorbital (V1)	Largest branch of the nasociliary nerve (V1)	Anterior etmoidal foramen	Inferior branches	Orbicularis Oculi	Conjunctiva ⁶⁴
Supraorbital (V1)	Largest terminal branch of the frontal nerve ⁶⁴	Orbital margin, notch, or multiple foramens ⁷⁰	Superficial and deep branches	Frontalis muscle	Central skin of upper eyelid
Palpebral branch of the lacrimal nerve (V1)	Smallest branch of the ophthalmic nerve (V1)	None	None	Lacrimal gland, orbital septum	Lateral edge of the eyelid
Temporal area					
Horizontal branch of the supraorbital nerve (V1)	Supraorbital nerve (V1)	None	None	Temporoparietal fascia	Skin with 1.5-cm radius at the border between the lateral forehead and temple ⁷¹
Zygomaticotemporal (V2)	First branch of the zygomatic nerve (V2)	Zygomaticotemporal foramen	Superficial (medial) division ⁶⁷	Temporalis muscle, deep and superficial temporal fascia	Lateral forehead and the anterior temporal areas of the skull ^{72,73}
Auriculotemporal (V3)	Posterior division of the mandibular nerve (V3)	Between the bony external acoustic meatus and the articular eminence of the temporomandibular joint	Superficial temporal nerves	Lateral to neck of mandible, perforate superficial temporal fascia	Anterior temporal area ⁷⁴

Table 2.2 Sensory innervation of the mid-face including: lower eyelids, nose, upper lips, cheek, and preauricular area

Nerve		Origin	Exit foramen	Branches	Structures crossed	Areas innervated
Lower eyelids, cheek and upper lips	Infraorbital (V1)	Terminal branch of the maxillary nerve (V2) ⁷²	Infraorbital foramen (single most cases, double or triple foramina reported) ⁷⁵⁻⁷⁷	Inferior palpebral branches ^{78,79}	Orbicularis oculi muscle	Infraorbital area, from the lower eyelid margin to upper lip vermilion, from 2 cm lateral to the external canthus to 0.5 cm from the midline
	Zygomatic-facial (V2)	Second branch the zygomatic nerve, early branch of the Maxillary nerve (V2) ⁷²	Zygomaticofacial foramen	None	Orbicularis oculi muscle	Zygomatic area of cheek
Nose	Infraorbicular (V1)	Largest branch of the nasociliary nerve (V1)	Anterior etmoidal foramen	Superior branches	Orbicularis oculi	Skin of the root of the nose
	Supratroclear (V1)	Terminal branch of the frontal division of the ophthalmic nerve (V1) ⁶⁴	Upper medial corner of orbit ^{85,86}	Three or four branches, ⁸⁷ connection to medial branch supraorbital nerve ⁸⁸	Corrugator and frontalis muscles ⁶⁷	Nasal root, glabella ^{64,67,69}
	External nasal (V1)	Branch of anterior ethmoidal nerve (from the nasociliary division of the ophthalmic nerve-V1)	Nasal bone and the upper lateral cartilage	None	Superficial nasal musculoaponeurotic system	Nasal tip
	Nasal branches of the infraorbital nerve (V2)	Infraorbital nerve	Infraorbital foramen (single most cases, double, or triple foramina reported) ^{75,77}	Internal and external nasal branches	Orbicularis oculi muscle	Philtrum, nasal septum, and the vestibule of nose
Preauricular area	Auriculotemporal nerve (V3)	Posterior division of the mandibular nerve (V3)	Between the bony external acoustic meatus and the articular eminence of the temporomandibular joint	Anterior auricular nerve and the external acoustic meatus nerve	Lateral to neck of mandible, perforate superficial temporal fascia	Auricular anterior aspect, external acoustic meatus
	Great auricular nerve (C2-C3)	Superficial branch of the cervical plexus (C2-C3)	Erb's point	Anterior and posterior branches	Platysma muscle	Parotid gland and the lower preauricular region ⁸⁰

Table 2.3 Sensory innervation of the lower face including: lower lips and chin

	Nerve	Origin	Exit foramen	Branches	Structures crossed	Areas innervated
Lower eyelids, cheek and upper lips	Mental (V3)	Terminal branch of the inferior alveolar nerve (from the mandibular nerve) (V3)	Mental foramen ^{81,82}	Angular, medial inferior labial, lateral inferior labial, and mental branch	Depressor Anguli Oris muscle	Lower lip, vermillion, vestibular gingiva, and the skin of the chin
	Branch of the mylohyoid nerve (V3)	Terminal branch of the mandibular nerve (V3) ^{74,83}	None	None	Mylohyoid muscle	Submental skin

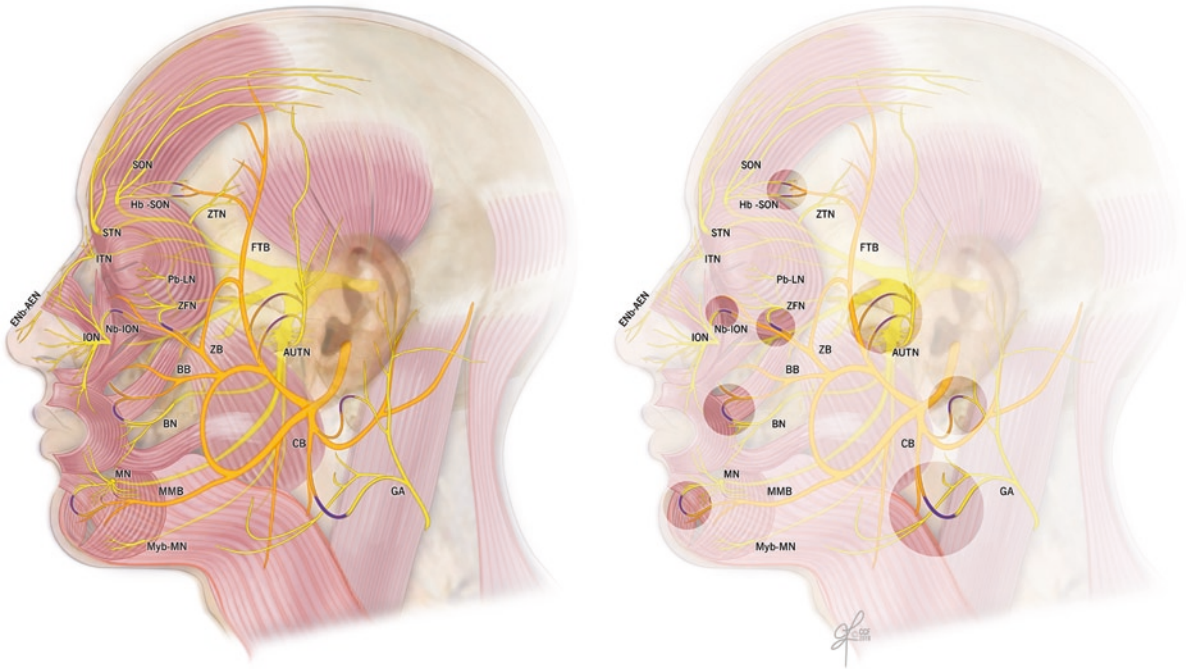


Fig. 2.4 Trigemino-facial communications. The trigeminal nerve and its branches are presented in yellow, the facial nerve in orange, and their communicating branches in blue. *BB* buccal branch of the facial nerve, *BN* buccal nerve, *CB* cervical branch of the facial nerve, *ENb-AEN*, external nasal branch-anterior ethmoidal nerve, *FTB* frontotemporal branch of the facial nerve, *GA* great auricular nerve, *Hb-SON* horizontal branch supraorbital nerve, *ION* infraorbital nerve, *ITN* infratroclear nerve,

MMB marginal mandibular branch of the facial nerve, *MN* mental nerve, mylohyoid branch-mental nerve, *Pb-LN* palpebral branch-lacrimal nerve, *SON* supraorbital nerve, *STN* supratroclear nerve, *ZB* zygomatic branch of the facial nerve, *ZFN* zygomaticofacial nerve, *ZTN* zygomaticotemporal nerve (Reprinted with permission, Cleveland Clinic Center for Medical Art & Photography © 2010. All Rights Reserved)

significantly from one another.⁵⁰ There are not significant differences in sensitivity to cooling between oral mucosa and facial skin. Moreover, all extraoral sites are equally sensitive to cooling.⁵¹

In comparison to the above discussed neurosensory tests, the *pain detection threshold* represents the highest variability in data. Upper and lower labial areas are

the most sensitive to pain stimuli, and the infraorbital areas are the least sensitive. In comparison, chin responses are in between these two areas.⁵² The reasons for these spatial variations are undoubtedly numerous and most probably correlate with innervations density, epidermal thickness, and composition as well as with the receptors' depth.

Table 2.4 Physiologic tactile discrimination data for different areas of the human facial skin^{19,20,46,48,49,52,84}

	Lateral forehead	Medial forehead	Zygoma	Cheek	Nasolabial skin	Paranasal	Superior labial skin	Upper vermilion	Upper lip mucosa	Inferior labial skin	Lower vermilion	Lower lip mucosa	Chin	Ear	Neck
Two-point discrimination (static)	13.4, 15.0	12.7, 13.0	10.58, 10.92	9.0, 13.1	7.4, 9.7	9.96, 10.38	3.25, 7.66	2.4, 7.0	2.4, 5.2	5.8, 7.04	3.0, 6.1	2.8, 4.6	5.4, 10.0	9.29, 13.2	13.7, 35.2
Two-point discrimination (dynamic)	11.0, 11.8	9.0, 11.1	9.33, 9.91	7.9, 10.0	6.6	9.63, 10.17	3.42, 3.8	4.2	6.1		4.5	3.0, 4.1	7.0, 5.1	12.9	11.5
Semmes-Weinstein (filament)	1.95	1.93		1.72, 1.84	1.75		1.75, 1.81	2.38	2.8	1.75, 1.77	2.26	2.91	1.95	1.79, 1.99	2.13
Vibratory threshold (voltage, mV)	22.0, 22.5	21.0, 22.8		17.0, 17.2	15		9.8	8.3	9.4		8.1	6.0, 9.3	11.0, 10.6	11.3	11.9
Pressure-specified sensory device 1-point static (g/mm)	0.88, 1.16	0.88, 0.95	0.71, 0.78		0.76, 0.80		0.77, 0.82	0.73, 0.77			0.69, 0.78		0.64, 0.82		
Pressure-specified sensory device 2-point static (g/mm)	31.11, 39.42	22.94, 33.38	20.58, 23.1		13.39, 13.53		11.08, 13.07	3.8, 3.98			3.27, 3.57		16.88, 17.18		
Pressure-specified sensory device 1-point moving (g/mm)	0.58, 0.71	0.56, 0.88	0.54, 0.58		0.54, 0.55		0.51, 0.57	0.49, 0.52			0.47, 0.54		0.52, 0.62		
Pressure-specified sensory device 2-point moving (g/mm)	10.16, 11.78	5.27, 8.23	5.2, 5.47		3.45, 3.72		2.66, 4.68	1.10, 1.15			1.13, 1.31		2.52, 4.28		

2.7 Conclusions

With 11 reported cases of facial allotransplantation, the technical challenges seem to be well addressed. The new challenges include achieving long-term survival under minimal immunosuppression and restoration of optimal sensory and motor functions after face transplantation. The motor function recovery after face transplantation is well documented and discussed, but the mechanisms of sensory recovery have not been adequately addressed. The presence of stable and diffuse connections between the facial and trigeminal nerves proves that the motor and sensory pathways of the human face are intrinsically interrelated; thus, every effort should be made to restore the continuity of both systems. The new era of facial reconstruction includes free tissue transfer and facial transplantation, so updating our knowledge on the sensory pathways of the face, including specific facial receptor systems, the ascending tracts, and the cortical responses to somatosensory stimulations, should add into our understanding of function and mechanisms of sensory restoration after application of modern reconstructive procedures. The facial skin presents the highest concentration of the sensory receptors in the entire body,¹⁰ as confirmed by their fundamental role in collecting and transmitting external stimuli to the cerebral cortex for processing and integration. In contrast to the significant number of studies on composition and distribution of the sensory receptors within the hand, there are only few reported anatomical studies, performed principally on nonhuman primates, assessing the spectrum of receptors present in the facial skin. Only Munger and Halata¹⁵ described the complex array of sensory receptors in the human face. There are, however, numerous micro-neurographic studies which confirmed the presence of four out of five types of tactile afferents which are known to innervate skin of the human hand as well, and excluded the presence of Pacini corpuscles.^{12,14,21} For clinical evaluation of the sensation collected by facial receptors, different instruments and assessment devices have been described, but none of the tests have been accepted as the gold standard. Pressure-Specified Sensory Device (PSSD) is probably the most appropriate instrument for recording of human cutaneous pressure thresholds by measuring both the force and the distance at which one point can be distinguished from two points either static or moving.⁴⁷ Tests for thermal sensation are difficult to

standardize since their accuracy and reliability have not been well determined.⁵³ Perception of the painful stimuli is usually not used in the clinical practice of sensory testing but has often been inferred from the necessity for local anesthesia when performing skin biopsies² or by pinprick tests. Based on previous reports, the presented summary of the range of normal values for discriminative thresholds may be useful for assessment of sensory recovery of facial sensation after free tissue transfers and in face transplant patients, since these tests are not routinely used in the current clinical practice. The reported higher tactile thresholds in patients older than 45 and in smokers should be taken into consideration during evaluation of sensibility of reconstructed or transplanted face especially if the donor age is different from the age of the recipient. During evaluation of sensory function return of a specific nerve branch, the areas to be tested should be scaled purely to the region of the repaired nerve distribution. For example, the middle third of the hemi-forehead should be tested for assessment of the supraorbital nerve, the central cheek and upper lip for the assessment of the infraorbital nerve, and the lower lip for the mental nerve. When testing thermal stimuli, the infraorbital region and nose should be considered as they were found to be the most sensitive to warm stimuli.⁵¹ Upper and lower labial regions have been reported to be most sensitive to pain and if required can be used for assessment of painful stimuli while the infraorbital regions are the least sensitive⁵² and should be avoided during sensory testing.

The distribution of the sensory nerves in the human face is usually described as a branching pattern from the main trunk to the distal rami. This approach is not helpful for sensory assessment from a reconstructive point of view, where focusing on the “complex” of peripheral nerves directly involved in the innervation of the reconstructed subunit would be more valuable. The summary offered in the Table 2.1 may be useful as a guide when deciding which is the most suitable area for sensory testing and which nerves should be considered for repair in composite unit transfers. Furthermore, the following anatomical features should be considered when repairing sensory nerves after trauma or during face transplantation. It is important to consider the fact that the supraorbital nerve exits the cranium through a bony foramen or notch, and multiple foramina have been reported. A high positioned supraorbital foramen with a long bony canal can be present in up to

24% of cases.⁵⁴ Moreover, the medial branch of the supraorbital nerve after exiting the foramen gives off multiple small rami and becomes superficial piercing the frontalis muscle. The infraorbital and mental nerves pass through long bony canals. They are already divided into their terminal branches at the level of foraminal exit, and they have a short distance to reach the skin. The presence of multiple foramina or rami, the long bony canals, and the short course of the main branches within soft tissues after exiting the cranium explains the reported difficulty in achieving direct repair of the sensory nerves in facial trauma and facial transplantation.² Osteotomy of the supraorbital canal, as proposed by Siemionow et al.,⁵⁵ or intraorbital division of the nerve and delivery of the proximal stump through the canal,⁵⁴ could be performed to lengthen the stump of the nerve available for repair. The infraorbital canal osteotomy and mandibular sagittal osteotomy are also useful to increase the length of these nerves during facial graft procurement.⁵⁵

Beside the primitive reflex functions which aim to protect the individual from the noxious stimuli, the unconscious information conveyed by the trigeminal system assists in the fine tuning of the highly specialized facial functions. Livermore et al.⁷ proved that the stimulation of the facial skin increases the perceived intensity of chemical stimuli applied simultaneously to the olfactory system. The stimulation of the trigeminal nerve has been shown to evoke systemic visceral reactions, when e.g., cooling of the face was associated with hypertension and bradycardia.⁸ Finally, due to the absence of muscle spindles and tendon organs in the perioral muscle system,^{56,57} the cutaneous receptors play an important role in the speech sensorimotor processes and adjustment of the articular motion.⁶ The cutaneous and mucosal afferents discharge vigorously during labial contact and when stimulated by the air pressure, generated by speech sounds. Deformation or strain of the facial skin and mucosa associated with various phases of voluntary lip and jaw excursions provides proprioceptive information on facial movements.⁵⁸

The second important aspect to consider is the response of the somatosensory cortex to the reconstruction of the sensory nerves. It has been proved that cortical reorganization following limb deafferentation involves reduction of the cortical representation in the motor and sensory cortices, with expansion of adjacent and contralateral areas.^{59,60} Studies on the

reorganization of the somatosensory cortex in patients undergoing hand transplantation showed the reversibility of this phenomenon. The patients showed activation of the primary somatosensory cortex, which started as early as 10 days and was observed⁶¹ up to 2 years following transplantation.⁶² Interestingly, Farne et al.⁶³ confirmed that the somatosensory perception of the transplanted hand was hampered when the ipsilateral face was simultaneously stimulated. This phenomenon disappeared 11 months after transplantation. During the remapping phase, when the transplanted hand reclaimed its original somatotopy, the face and the hand seemed to “compete” for the cortical representation and gave rise to a temporary overlapping area that received multiple conflicting inputs from two physically distant but cortically adjacent parts of the body. Equivalent modifications of the somatosensory cortex have not been studied in the face transplant patients. It would be interesting to evaluate if opposite changes can be detected. These findings are very important in the light of current attempt of simultaneous face and hand transplantation where potential competition for critical reeducation may take place jeopardizing functional outcome of one of the transplanted grafts.

In conclusion, we have illustrated the complexity of the sensory pathways of the human face and presented the role of facial sensation during interaction with the external environment. We believe that considering the present advancements in the field of facial transplantation, restoration of facial anatomy and function is crucial for the final outcome.

References

1. Dubernard JM, Lengele B, Morelon E, et al. Outcomes 18 months after the first human partial face transplantation. *N Engl J Med*. 2007;357:2451-2460.
2. Lantieri L, Meningaud JP, Grimbert P, et al. Repair of the lower and middle parts of the face by composite tissue allotransplantation in a patient with massive plexiform neurofibroma: a 1-year follow-up study. *Lancet*. 2008;372:639-645.
3. Guo S, Han Y, Zhang X, et al. Human facial allotransplantation: a 2-year follow-up study. *Lancet*. 2008;372:631-638.
4. Siemionow M, Papay F, Alam D, et al. Near-total human face transplantation for a severely disfigured patient in the USA. *Lancet*. 2009;374:203-209.
5. Rogers SN, Lowe D, Patel M, Brown JS, Vaughan ED. Clinical function after primary surgery for oral and

- oropharyngeal cancer: an 11-item examination. *Br J Oral Maxillofac Surg.* 2002;40:1-10.
6. Ito T, Gomi H. Cutaneous mechanoreceptors contribute to the generation of a cortical reflex in speech. *NeuroReport.* 2007;18:907-910.
 7. Livermore A, Hummel T, Pauli E, Kobal G. Perception of olfactory and intranasal trigeminal stimuli following cutaneous electrical stimulation. *Experientia.* 1993;49:840-842.
 8. LeBlanc J, Blais B, Barabe B, Cote J. Effects of temperature and wind on facial temperature, heart rate, and sensation. *J Appl Physiol.* 1976;40:127-131.
 9. Loken LS, Wessberg J, Morrison I, McGlone F, Olausson H. Coding of pleasant touch by unmyelinated afferents in humans. *Nat Neurosci.* 2009;12:547-548.
 10. Connor NP, Abbs JH. Orofacial proprioception: analyses of cutaneous mechanoreceptor population properties using artificial neural networks. *J Commun Disord.* 1998;31:535-542. 553.
 11. Uchigasaki S, Suzuki H, Inoue K. Merkel cells in the vellus hair follicles of human facial skin: a study using confocal laser microscopy. *J Dermatol.* 2004;31:218-222.
 12. Johansson RS, Trulsson M, Olsson KA, Westberg KG. Mechanoreceptor activity from the human face and oral mucosa. *Exp Brain Res.* 1988;72:204-208.
 13. Nordin M, Thomander L. Intrafascicular multi-unit recordings from the human infra-orbital nerve. *Acta Physiol Scand.* 1989;135:139-148.
 14. Bukowska M, Essick GK, Trulsson M. Functional properties of low-threshold mechanoreceptive afferents in the human labial mucosa. *Exp Brain Res.* 2010;201:59-64.
 15. Munger BL, Halata Z. The sensorineural apparatus of the human eyelid. *Am J Anat.* 1984;170:181-204.
 16. Kawakami T, Ishihara M, Mihara M. Distribution density of intraepidermal nerve fibers in normal human skin. *J Dermatol.* 2001;28:63-70.
 17. Johansson O, Wang L, Hilliges M, Liang Y. Intraepidermal nerves in human skin: PGP 9.5 immunohistochemistry with special reference to the nerve density in skin from different body regions. *J Peripher Nerv Syst.* 1999;4:43-52.
 18. Schulze E, Witt M, Fink T, Hofer A, Funk RH. Immunohistochemical detection of human skin nerve fibers. *Acta Histochem.* 1997;99:301-309.
 19. Kesarwani A, Antonyshyn O, Mackinnon SE, Gruss JS, Novak C, Kelly L. Facial sensibility testing in the normal and posttraumatic population. *Ann Plast Surg.* 1989;22:416-425.
 20. Fogaca WC, Sturtz GP, Surjan RC, Ferreira MC. Evaluation of cutaneous sensibility on infraorbital nerve area. *J Craniofac Surg.* 2005;16:953-956.
 21. Nordin M, Hagbarth KE. Mechanoreceptive units in the human infra-orbital nerve. *Acta Physiol Scand.* 1989;135:149-161.
 22. Davies SN, Goldsmith GE, Hellon RF, Mitchell D. Facial sensitivity to rates of temperature change: neurophysiological and psychophysical evidence from cats and humans. *J Physiol.* 1983;344:161-175.
 23. Nordin M. Low-threshold mechanoreceptive and nociceptive units with unmyelinated (C) fibres in the human supraorbital nerve. *J Physiol.* 1990;426:229-240.
 24. Chen CC, Rainville P, Bushnell MC. Noxious and innocuous cold discrimination in humans: evidence for separate afferent channels. *Pain.* 1996;68:33-43.
 25. Bushnell MC, Taylor MB, Duncan GH, Dubner R. Discrimination of innocuous and noxious thermal stimuli applied to the face in human and monkey. *Somatosens Res.* 1983;1:119-129.
 26. Gardner EP, Martin JH, Jessell TM. The bodily senses. In: Kandel ER, Schwartz JH, Jessell TM, eds. *Principles of Neural Science.* 4th ed. United States of America: McGraw-Hill; 2000:430-450.
 27. Brannagan TH, Weimer LH. Cranial and peripheral nerve lesions. In: Rowland LP, Pedley TA, eds. *Merritt's Neurology.* 12th ed. Philadelphia: Lippincott Williams & Wilkins; 2010:506.
 28. Laine FJ, Smoker WR. Anatomy of the cranial nerves. *Neuroimaging Clin North Am.* 1998;8:69-100.
 29. Nemzek WR. The trigeminal nerve. *Top Magn Reson Imaging.* 1996;8:132-154.
 30. Ropper AH, Samuels MA. Chapter 9: Other somatic sensation. In: Ropper AH, Samuels MA, eds. *Adams and Victor's Principles of Neurology.* 9th ed. New York: McGraw-Hill; 2009.
 31. Eriksen K. Neurophysiology and the upper cervical subluxation. In: Eriksen K, Rochester RP, eds. *Orthospinal Procedures: An Evidence-Based Approach to Spinal Care.* 1st ed. Philadelphia: Lippincott William & Wilkins; 2007:183-207.
 32. Terman GW, Bonica JJ. Spinal mechanisms and their modulation. In: Loeser JD, ed. *Bonica's Management of Pain.* 3rd ed. Philadelphia: Lippincott William & Wilkins; 2001:110-125.
 33. Penfield W, Boldrey E. Somatic motor and sensory representation in the cerebral cortex of man as studied by electrical stimulation. *Brain.* 1937;60:389-433.
 34. Tamura Y, Shibukawa Y, Shintani M, Kaneko Y, Ichinohe T. Oral structure representation in human somatosensory cortex. *Neuroimage.* 2008;43:128-135.
 35. Nguyen BT, Inui K, Hoshiyama M, Nakata H, Kakigi R. Face representation in the human secondary somatosensory cortex. *Clin Neurophysiol.* 2005;116:1247-1253.
 36. Servos P, Engel SA, Gati J, Menon R. fMRI evidence for an inverted face representation in human somatosensory cortex. *NeuroReport.* 1999;10:1393-1395.
 37. Nguyen BT, Tran TD, Hoshiyama M, Inui K, Kakigi R. Face representation in the human primary somatosensory cortex. *Neurosci Res.* 2004;50:227-232.
 38. Namking M, Boonruangsri P, Woraputtaporn W, Guldner FH. Communication between the facial and auriculotemporal nerves. *J Anat.* 1994;185(Pt 2):421-426.
 39. Kwak HH, Park HD, Youn KH, et al. Branching patterns of the facial nerve and its communication with the auriculotemporal nerve. *Surg Radiol Anat.* 2004;26:494-500.
 40. O'connell JE. The intraneural plexus and its significance. *J Anat.* 1936;70:468-497.
 41. Huber E. Evolution of facial musculature and cutaneous field of trigeminus. *Q Rev Biol.* 1930;5:133-188.
 42. Riessener D. Surgical procedure in tumors of parotid gland; preservation of facial nerve and prevention of postoperative fistulas. *AMA Arch Surg.* 1952;65:831-848.
 43. Baumeil JJ. Trigeminal-facial nerve communications. Their function in facial muscle innervation and reinnervation. *Arch Otolaryngol.* 1974;99:34-44.
 44. Carmichael EA, Woolard HH. Some observations on the fifth and seventh cranial nerves. *Brain.* 1933;56:109-125.
 45. Ley A, Guitart JM. Clinical observations on sensory effects of trigeminal dorsal root section. *J Neurol Neurosurg Psychiatry.* 1971;34:260-264.

46. Costas PD, Heatley G, Seckel BR. Normal sensation of the human face and neck. *Plast Reconstr Surg.* 1994;93: 1141-1145.
47. Dellon AL, Andonian E, DeJesus RA. Measuring sensibility of the trigeminal nerve. *Plast Reconstr Surg.* 2007;120: 1546-1550.
48. Chen CC, Essick GK, Kelly DG, Young MG, Nestor JM, Masse B. Gender-, side- and site-dependent variations in human perioral spatial resolution. *Arch Oral Biol.* 1995;40: 539-548.
49. Vriens JP, van der Glas HW. Extension of normal values on sensory function for facial areas using clinical tests on touch and two-point discrimination. *Int J Oral Maxillofac Surg.* 2009;38:1154-1158.
50. Green BG, Gelhard B. Perception of temperature on oral and facial skin. *Somatosens Res.* 1987;4:191-200.
51. Rath EM, Essick GK. Perioral somesthetic sensibility: do the skin of the lower face and the midface exhibit comparable sensitivity? *J Oral Maxillofac Surg.* 1990;48: 1181-1190.
52. Hung J, Samman N. Facial skin sensibility in a young healthy Chinese population. *Oral Surg Oral Med Oral Pathol Oral Radiol Endod.* 2009;107:776-781.
53. Kawano T, Kabasawa Y, Ashikawa S, Sato Y, Jinno S, Omura K. Accuracy and reliability of thermal threshold measurement in the chin using heat flux technique. *Oral Surg Oral Med Oral Pathol Oral Radiol Endod.* 2009;108:500-504.
54. Shimizu S, Osawa S, Utsuki S, Oka H, Fujii K. Course of the bony canal associated with high-positioned supraorbital foramina: an anatomic study to facilitate safe mobilization of the supraorbital nerve. *Minim Invasive Neurosurg.* 2008;51:119-123.
55. Siemionow M, Papay F, Kulahci Y, et al. Coronal-posterior approach for face/scalp flap harvesting in preparation for face transplantation. *J Reconstr Microsurg.* 2006;22:399-405.
56. Siemionow M, Agaoglu G, Unal S. A cadaver study in preparation for facial allograft transplantation in humans: part II. Mock facial transplantation. *Plast Reconstr Surg.* 2006;117: 876-885. Discussion 886-888.
57. Kubota K, Masegi T. Muscle spindle supply to the human jaw muscle. *J Dent Res.* 1977;56:901-909.
58. Trulsson M, Johansson RS. Orofacial mechanoreceptors in humans: encoding characteristics and responses during natural orofacial behaviors. *Behav Brain Res.* 2002;135:27-33.
59. Borsook D, Becerra L, Fishman S, et al. Acute plasticity in the human somatosensory cortex following amputation. *NeuroReport.* 1998;9:1013-1017.
60. Wall JT, Xu J, Wang X. Human brain plasticity: an emerging view of the multiple substrates and mechanisms that cause cortical changes and related sensory dysfunctions after injuries of sensory inputs from the body. *Brain Res Brain Res Rev.* 2002;39:181-215.
61. Neugroschl C, Denolin V, Schuind F, et al. Functional MRI activation of somatosensory and motor cortices in a hand-grafted patient with early clinical sensorimotor recovery. *Eur Radiol.* 2005;15:1806-1814.
62. Brenneis C, Loscher WN, Egger KE, et al. Cortical motor activation patterns following hand transplantation and replantation. *J Hand Surg Br.* 2005;30:530-533.
63. Farne A, Roy AC, Giraux P, Dubernard JM, Sirigu A. Face or hand, not both: perceptual correlates of reafferentation in a former amputee. *Curr Biol.* 2002;12:1342-1346.
64. Shankland WE. The trigeminal nerve. Part II: the ophthalmic division. *Cranio.* 2001;19:8-12.
65. Kimura K. Foramina and notches on the supraorbital margin in some racial groups. *Kaibogaku Zasshi.* 1977;52:203-209.
66. Webster RC, Gaunt JM, Hamdan US, Fuleihan NS, Giandello PR, Smith RC. Supraorbital and supratrochlear notches and foramina: anatomical variations and surgical relevance. *Laryngoscope.* 1986;96:311-315.
67. Knize DM. Transpalpebral approach to the corrugator supercilii and procerus muscles. *Plast Reconstr Surg.* 1995;95: 52-60. Discussion 61-62.
68. Malet T, Braun M, Fyad JP, George JL. Anatomic study of the distal supraorbital nerve. *Surg Radiol Anat.* 1997;19:377-384.
69. Andersen NB, Bovim G, Sjaastad O. The frontotemporal peripheral nerves. topographic variations of the supraorbital, supratrochlear and auriculotemporal nerves and their possible clinical significance. *Surg Radiol Anat.* 2001;23:97-104.
70. Beer GM, Putz R, Mager K, Schumacher M, Keil W. Variations of the frontal exit of the supraorbital nerve: an anatomic study. *Plast Reconstr Surg.* 1998;102:334-341.
71. Hwang K, Hwang JH, Cho HJ, Kim DJ, Chung IH. Horizontal branch of the supraorbital nerve and temporal branch of the facial nerve. *J Craniofac Surg.* 2005;16:647-649. Discussion 650.
72. Shankland WE II. The trigeminal nerve. Part III: the maxillary division. *Cranio.* 2001;19:78-83.
73. Hwang K, Suh MS, Lee SI, Chung IH. Zygomaticotemporal nerve passage in the orbit and temporal area. *J Craniofac Surg.* 2004;15:209-214.
74. Shankland WE II. The trigeminal nerve. Part IV: the mandibular division. *Cranio.* 2001;19:153-161.
75. Kazkayasi M, Ergin A, Ersoy M, Tekdemir I, Elhan A. Microscopic anatomy of the infraorbital canal, nerve, and foramen. *Otolaryngol Head Neck Surg.* 2003;129:692-697.
76. Canan S, Asim OM, Okan B, Ozek C, Alper M. Anatomic variations of the infraorbital foramen. *Ann Plast Surg.* 1999;43:613-617.
77. Aziz SR, Marchena JM, Puran A. Anatomic characteristics of the infraorbital foramen: a cadaver study. *J Oral Maxillofac Surg.* 2000;58:992-996.
78. Hu KS, Kwak HH, Song WC, et al. Branching patterns of the infraorbital nerve and topography within the infraorbital space. *J Craniofac Surg.* 2006;17:1111-1115.
79. Hwang K, Nam YS, Choi HG, Han SH, Hwang SH. Cutaneous innervation of lower eyelid. *J Craniofac Surg.* 2008;19:1675-1677.
80. Ginsberg LE, Eicher SA. Great auricular nerve: anatomy and imaging in a case of perineural tumor spread. *AJNR Am J Neuroradiol.* 2000;21:568-571.
81. Hwang K, Lee WJ, Song YB, Chung IH. Vulnerability of the inferior alveolar nerve and mental nerve during genioplasty: an anatomic study. *J Craniofac Surg.* 2005;16:10-14. Discussion 14.
82. Greenstein G, Tarnow D. The mental foramen and nerve: clinical and anatomical factors related to dental implant placement: a literature review. *J Periodontol.* 2006;77:1933-1943.
83. Hwang K, Han JY, Chung IH, Hwang SH. Cutaneous sensory branch of the mylohyoid nerve. *J Craniofac Surg.* 2005;16:343-345. Discussion 346.
84. Posnick JC, Zimble AG, Grossman JA. Normal cutaneous sensibility of the face. *Plast Reconstr Surg.* 1990;86: 429-433. Discussion 434-435.



<http://www.springer.com/978-0-85729-252-0>

The Know-How of Face Transplantation

Siemionow, M. (Ed.)

2011, XVIII, 494 p., Hardcover

ISBN: 978-0-85729-252-0