

# A New Paradigm

# 1

Science is characterized by discoveries. While the discovery of new facts is reportable, facts alone do not constitute the entirety of science. “Facts are the enemy of truth!” cried Don Quixote de la Mancha. Certainly, unprocessed facts, facts taken at face value, may limit our grasp of fundamental relationships. Understanding comes from making connections between many disparate facts. Such pattern recognition need not require immense data sets. In his insightful *The Art of Scientific Investigation*, W.I.B. Beveridge declares: “More discoveries have arisen from intense observations of a very limited material than from statistics applied to large groups, for only by being familiar with the usual can we notice something as being unusual or unexplained.”<sup>1</sup> This is especially true in the biological sciences, where progress is achieved not only by new information but also by the improved understanding of puzzling phenomena, the removal of contradictions, the making of better predictions, and the determination of connections between previously unconnected phenomena. Essential is the development of new concepts often integrating the new with the previously established facts.

A paradigm is a universal adoption of scientific achievements that for a period of time provides the model for problem solving. One can become so invested into the prevailing paradigm that revolutionary advances making their appearance are categorically denied. Nothing illustrates this more dramatically than the utterances of false prophets.

Hear the prediction of Yale Professor Irving Fisher just before the 1929 stock market crash. Fisher declared that stocks had reached “what looks like a permanently high plateau.” As we all know, the plateau abruptly turned into an abyss.

Economics is accepted for its dubious accuracy, but science is regarded as, well, scientific. But despite stunning breakthroughs in medicine over the past century, false prophets have long trumpeted the end of scientific advances.<sup>2</sup> Consider these

*X-rays will prove to be a hoax.*

Lord Kelvin, English physicist and President of the Royal Society, 1896

*Everything that can be invented has been invented.*

Charles H. Duell, commissioner of the U.S. Patent Office, in a letter to President William McKinley, urging him to close the office, 1899

*We can surely never hope to see the craft of surgery made much more perfect than it is today. We are at the end of a chapter.*

Berkeley George Moynihan, Leeds University Medical School, 1930

*The great era of scientific discovery is over. . . Further research may yield no more great revelations or revolutions, but only incremental, diminishing returns.*

John Horgan, science journalist, 1996<sup>3</sup>

Reality shows that such statements border on farce.

A shift in paradigm occurs after new discoveries, new facts, new problems concerning the facts cannot be explained within the existing framework. This shift comes only after a reevaluation of traditional procedures indicates the inadequacy of underlying concepts leading to an altering of perception and the introduction of a new paradigm. It is the initiation of inquiry into the reigning paradigm that is the most difficult

part in the transformation process. The difficulty lies in recognizing that a problem exists and in noting precisely the point or points to direct the inquiry.

In many fields – most notably in physics – advances during the twentieth century have been made by discarding mechanistic principles of what came to be known as the scientific method and adopting a new concept. The world could no longer be viewed and understood as a multitude of individual objects but rather as one indivisible dynamic whole, whose parts are interrelated and understood as integrated parts of the whole.

The fields of biology and psychology have also raised serious questions about the scientific method. Inductive reasoning comes into question with views on perception according to the reporting individual and actual objects. Experiences are subjective with the brain formulating the images we perceive. The processes of perception themselves are unconscious and involve a whole range of presuppositions. How we grasp an image is very much dependent upon multiple factors: our presuppositions, expectations, experiences. This has been demonstrated by psychologists by a series of drawings with subtle progressive differences until the last panel depicts an illustration radically different from the first (Fig. 1–1). The recognizable point of transition where the image shifts in the viewer's perception is different depending whether the viewer traces the series from left to right or backward. This illustrates that pre-conditioning – in other words, the concepts of expectation, prior knowledge, and experience – determines in large measure visual perception.

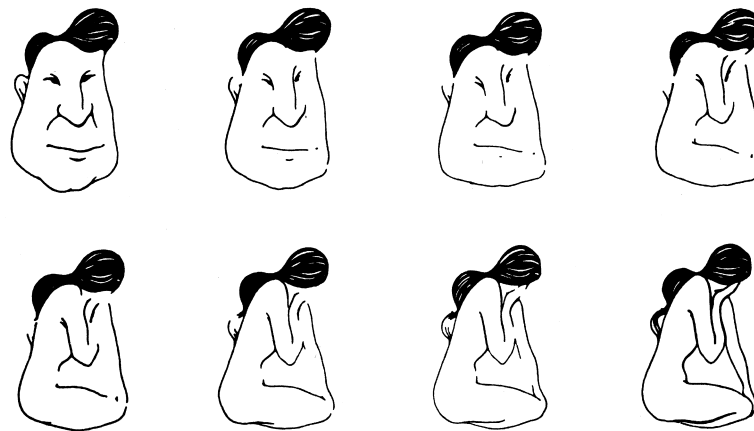
In abdominal radiology, the traditional concept divides the abdomen and pelvis into component parts. This proved useful in the broad classification of disease

processes, but with the technological developments and widespread applications of axial imaging the traditional concepts failed to explain all observations.

Axial imaging provides the exciting capability to visualize portions of the abdomen and pelvis not imaged previously. It has become apparent that the traditional analysis of compartmentalization does not fully explain certain manifestations of the spread of disease. Significantly, spread between intraperitoneal organs, spread between intraperitoneal and extraperitoneal sites, spread within the extraperitoneal compartments, and spread within areas not previously described, e.g., root of mesenteries, all demanded a new paradigm. Our perception of images of the abdomen needs a new abstraction and a new conceptual model to provide the fullest understanding of the spread and localization of disease processes.

There is always a reluctance to change paradigms, especially one that has served us for years. However, inquiry toward a new solution starts when something is unsatisfactory and traditional methods provide an inadequate solution. The critical step is to realize the problem and initiate inquiry.

Seeing is in the realm of cognition. The psychology behind this thinking derives in large part from Gestalt theory. Artists, of course, have been aware of this for years. A fresh look at reality is needed as most phenomena of nature cannot be described adequately if analyzed part by part. This realization is that the whole is greater than the sum of its parts or the whole has properties that do not reside in the parts at all. The complexity of organization and the relationships formed by interconnections play as much a part in the conception of the whole as does the naming of its parts.



**Fig. 1–1.** A drawing of a man's face subtly changes to the outline of a young female. The transition point is dependent not only on subjective variations but also on the sequence followed.

Illustrative of this phenomenon are poet John Godfrey Saxe's six blind men (from his poem "The Blind Men and the Elephant") observing different parts of an elephant and coming to a very different but equally erroneous conclusions about it. The first fell against the elephant's side and concluded that it was a wall. The second felt the smooth, sharp tusk and mistook it for a spear. The third held the squirming trunk and knew it was a snake. The fourth took the knee to be a tree. The fifth touched the ear and declared it a fan. And the sixth seized the tail and thought he had a rope. One of the poem's lessons: "Each was partly in the right, and all were in the wrong!"<sup>4</sup>

The relevance of these views on cognition becomes evident in the art and science of imaging. We can view an image and yet perceive it in different ways. Figure 1–2 illustrates that the image first seen is determined by the relationship between individual features. Both images are present in the one drawing. The viewer sees either an old woman or a young lady. The perception of both images is determined by their relationships. Interestingly, one sees the young lady or the old woman, but not both at once.

Using the same perceived images but with different concepts reveals different pictures. Salvador Dali's *Voltaire in the Marketplace* is an example (Fig. 1–3). The images seen as individual parts appear as people within the marketplace. Seen as a whole, however, the image appears as a bust of Voltaire. Each is seen individually, and each is true, only the concept behind the perception has changed.

In the same manner perceived axial images can be conceived differently. The images seen as parts correspond with the traditional concept, the abdomen and pelvis. If, however, we use a holistic concept the perceived images are seen as one space greater than its



**Fig. 1–2.** W.E. Hill's "My Wife and My Mother-in-Law."


Both images are present in the drawing. The viewer first sees either an old woman or a young lady. The old woman's prominent nose in profile is the young woman's chin. This drawing illustrates that perception is determined by the relationships.


sum. The image is the sum of its parts plus the interconnections between the parts.

Origami serves here as a useful visual metaphor to illuminate the anatomic continuity of the plane deep to the peritoneum throughout the abdomen and pelvis. Starting with a flat piece of paper, the craft of origami applies a series of creative foldings to finally yield an identifiable figure (Fig. 1–4). The essential point is this: all the planes of the folded figure distinctly remain in continuity. Despite the creases,

**Fig. 1–3.** *The Slave Market with Disappearing Bust of Voltaire* by Salvatore Dali.

Both the marketplace and the bust are in the same picture. The marketplace is seen as individuals, and the bust is seen as the sum of the parts. (Reproduced with permission of Gala-Salvador Dali Foundation. Copyright © Gala-Salvador Dali Foundation. All rights reserved.)





**Fig. 1–4. Origami Monkey.**  
(Courtesy of Annemarie Johnson.)

bends, overlaps, and projections, the surface of the original flat paper is uninterrupted.

Similarly, as detailed in the following chapters on the embryology of the abdomen and pelvis, the plane deep to the peritoneum is continuous throughout. To recognize this is to vastly extend the clinical contributions of abdominal imaging. In the planes formed by the subperitoneal space course connective tissue, blood vessels, nerves, and lymphatics.<sup>5</sup> It thus becomes evident that the roots of the mesenteries – transverse mesocolon, small bowel mesentery, sigmoid mesocolon, broad ligament – provide avenues of anatomic continuity (Figs. 1–5 and 1–6).

This holistic concept underscores the viewing of the fundamental structures of the abdomen and pelvis as one space – the subperitoneal space. This space includes the extraperitoneal space, and the ligaments and mesenteries of the abdomen and pelvis. The abdomen and pelvis conceived within this holistic paradigm readily explain the interconnections between all the organs, mesenteries, roots of mesenteries, and extraperitoneum in any conceivable combination.

A curved line, viewed from one side, is convex, but viewed from the other side, is concave. Two concepts applied to the same perceived image yield two pictures. Put another way, inherent in the grouping of lines and shadows in the illustrated drawings are two

individual perceptions, co-existing and reflective of each other. Conceiving the images as individual parts is most useful in explaining confinement of a disease process and differential diagnosis based on location. However, conceiving the image as a holistic anatomic concept illuminates a new revolutionary paradigm. The abdomen and pelvis are constituted by one interconnected space. This is of critical use in explaining the pathways of spread of disease.

The introduction and acceptance of a new paradigm is made more difficult if vocabulary from a previous paradigm continues to be used. This is due to the potentially misleading implications the term carries from its use in the previous paradigm. While it is best to use new terms, this is not always possible. A clear set of definitions of how a word or words are used in the holistic concept is useful:

*Subperitoneal Space:* Extraperitoneal space and the ligaments/mesenteries of the abdomen and pelvis.

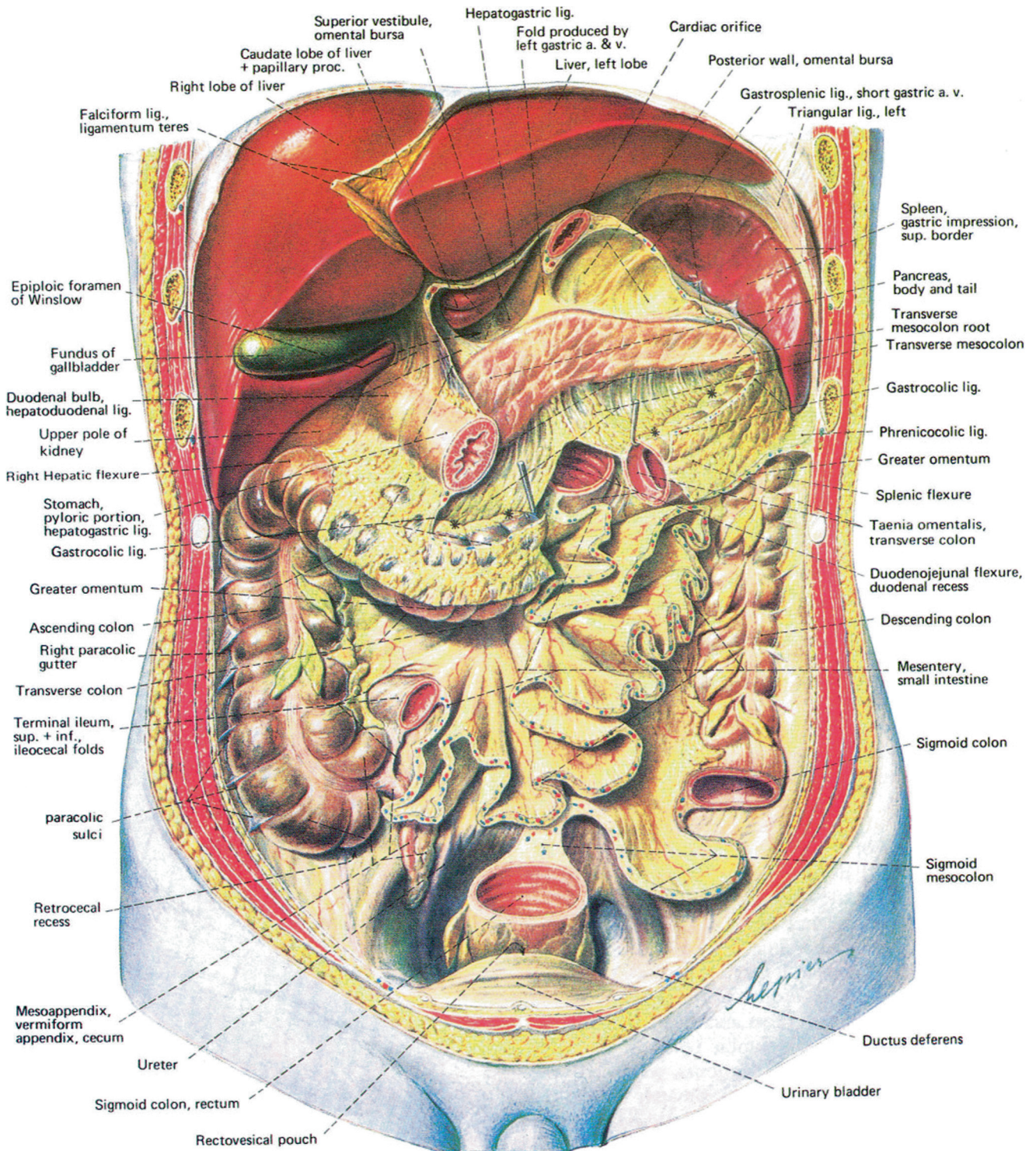
*Extraperitoneal:* The circumferential space around the abdomen and pelvis lying beneath the parietal peritoneum, stratified in the abdomen by renal fascia and in the pelvis by umbilicovesical fascia.

*Retraperitoneum:* Posterior portion of the extraperitoneum in the abdomen.

*Ligaments/mesenteries:* Formed by two peritoneal layers (visceral peritoneum) in continuity with the parietal peritoneum. The structures enclosed – connective tissue, blood vessels, nerves, and lymphatics – are in continuity with the extraperitoneum.

A major purpose of *Meyers' Dynamic Radiology of the Abdomen* is in explaining the pathways of disease spread. The subperitoneal space provides the avenues for spread interconnecting all the organs. The peritoneal cavity provides the potential pathways for intraperitoneal spread. The benefits of this cognitive framework are multiple. When the primary site of disease – whether infectious, traumatic, or neoplastic in nature – is known, precise identification can be made of the expected sites of spread and localization. On the other hand, when a patient presents with a remote lesion, the primary site – which may be clinically occult – can be inferred. Furthermore, such basic understanding facilitates identification of the expected site of recurrent disease or the pattern of progression after treatment.

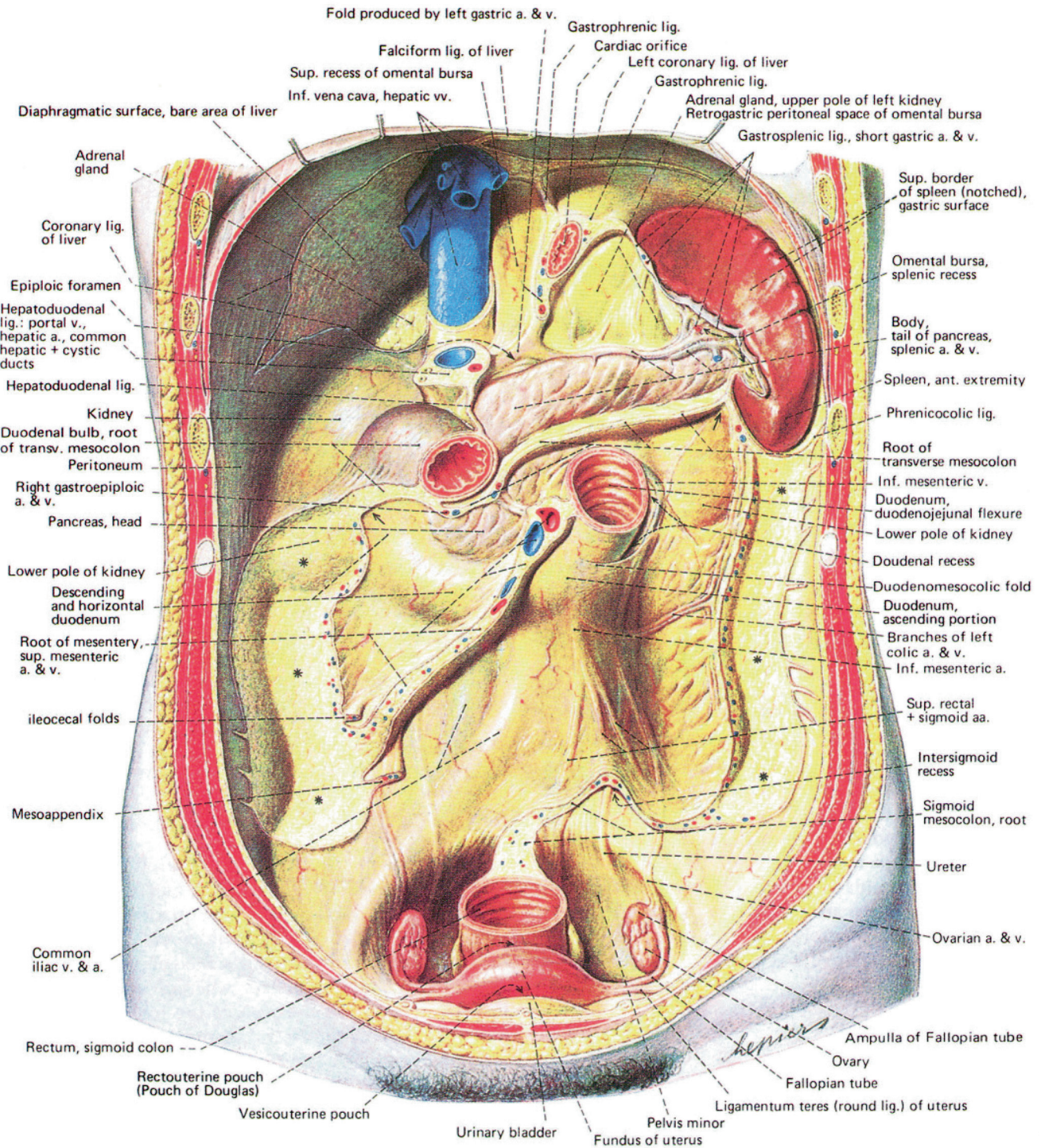
By developing focused search patterns, the radiologist serves in a critical position to direct the course of investigation, to evaluate the extent of disease, to indicate the prognosis, and to determine the appropriate management.



**Fig. 1-5. Abdominal viscera.**

The stomach has been removed from the cardia to the pylorus, revealing the lesser sac (omental bursa) and structures on the posterior wall.

(Reproduced with permission from Putz.<sup>6</sup> Copyright Elsevier [Churchill Livingstone Imprint].)



**Fig. 1–6. Retroperitoneum of an adult female.**  
(Reproduced with permission from Putz.<sup>6</sup> Copyright Elsevier [Churchill Livingstone], 2006.)

## References

1. Beveridge WIB: The Art of Scientific Investigation. W. Heinemann, London, 1957, p 105.
2. Meyers MA: Back to the future. *AJR* 2008; 190:561–564.
3. Horgan J: The End of Science. Addison–Wesley, Reading, MA, 1996.
4. Saxe JG: The Blind Men and the Elephant. McGraw-Hill, New York, 1963.
5. Oliphant M, Berne AS, Meyers MA: The subperitoneal space of the abdomen and pelvis: planes of continuity. *AJR* 1996; 167:1433–1439.
6. Putz R: Sobotta – Atlas of Human Anatomy Single Volume Edition: Head, Neck, Upper Limb, Thorax, Abdomen, Pelvis, Lower Limb, 14th ed. Churchill Livingstone, The Netherlands 2006.

Meyers' Dynamic Radiology of the Abdomen

Normal and Pathologic Anatomy

Meyers, MD, FACR, FACG, M.A.; Charnsangavej, MD, FSIR,  
C.; Oliphant, M.

2011, XVIII, 419 p., Hardcover

ISBN: 978-1-4419-5938-6