

Chapter 2

Evaluation of the Second-Trimester Products of Conception

General Considerations.....	13
Macroscopic Examination and Description.....	14
Special Procedures.....	17
Submission of Microscopic Sections.....	18
Microscopic Description, Diagnosis, and Report.....	20
Selected References.....	20

General Considerations

Second-trimester products of conception with no history of fetal demise, anomalies, or other problems can be handled in much the same way as first trimester specimens, with *documentation of intrauterine pregnancy and identification of any unexpected abnormalities*. When there are fetal anomalies, additional attention is required to document the specific anomalies present and in some cases, to submit tissue for special testing. Like first trimester specimens, there is marked variability in the type of tissue received and the extent of disruption. If the specimen is delivered spontaneously or after induction of labor, the fetus may be relatively intact, although the placenta often does not survive undamaged. When surgical procedures are performed to terminate the pregnancy or remove uterine contents, both the placenta and fetus can be quite disrupted, making examination problematic. In addition, in cases of fetal demise, autolysis may further hamper evaluation. For these reasons, examination of these specimens creates unique challenges to the pathologist. Although detailed examination for fetal anomalies is beyond the scope of this text, it is the author's hope that this chapter, covering the *general approach and overview* to the handling these types of specimens, will assist in initial evaluation of these specimens. The reader is referred to the Selected References at the end of the chapter for several excellent texts detailing fetal examination in the setting of congenital anomalies.

Macroscopic Examination and Description

The first step in gross examination is separation of *fetal tissue from the nonfetal tissue*. With practice, the fine papillary villi can be identified and separated from the remaining tissue along with membranes and fragments of umbilical cord (see Figs. 1.4–1.6). This is a relatively simple procedure in the second trimester, as the components are better defined compared to the first trimester specimen. Once the placental tissue is separated, *the placental tissue should be measured and weighed in aggregate, and the cord length and cord diameter should be ascertained if possible*. Abnormalities of the cord, such as excessive twisting, knots, constrictions, discolorations, or abnormal length, should be noted at this time, as these are important causes of demise even in the second trimester (see Chap. 15). If a cord abnormality is noted, a photograph is recommended before further examination and sectioning. The fetal membranes should be evaluated for opacity or discoloration as well as identification of the rare amnionic band (see Chap. 14). The villous tissue should be examined for blood clots, infarcts or other lesions (see Fig. 3.8).

After the fetal tissue has been separated, an attempt to “reconstruct” the fetus should be made, placing the fetal parts in anatomic position (Fig. 2.1). This will provide an opportunity to make an inventory of the fetal organs and fetal parts and possibly gain some insight into their relationships. *If any major skeletal structures are missing, it may be prudent to contact the clinician, as this could indicate that tissue is retained in the uterus*. It is important to try and identify each major organ, but disruption and maceration may prohibit identification of all organs even if they are present. If identification of each organ is not possible, it is suggested that sections be taken of “unidentifiable” tissue or “possible” organs in the hopes that additional organs will be recognized microscopically. Photographs should be taken if any abnormality is noted. In cases of fetal anomalies and in particular, fetuses with complex or unusual anomalies, photographs are invaluable for later study or consultation. Radiographs should also be taken at this time, if necessary (see below).

Many specimens show marked disruption, and it is notable that different portions of the fetus are more or less prone to disruption. Usually, the extremities are the most likely to remain intact, while the abdomen is usually the most disrupted. The pelvis, chest, and head are variably disrupted. Adequate clinical history is extremely helpful in directing examination for anomalies, but is not always forthcoming. Therefore, *a systematic approach is suggested in which each portion of the fetus is examined* in order to maximize the information gained.

The following is an example of a systematic approach to these specimens:

- External examination
 - Measurements
 - Crown-rump
 - Crown-heel
 - Head, abdominal, and chest circumferences

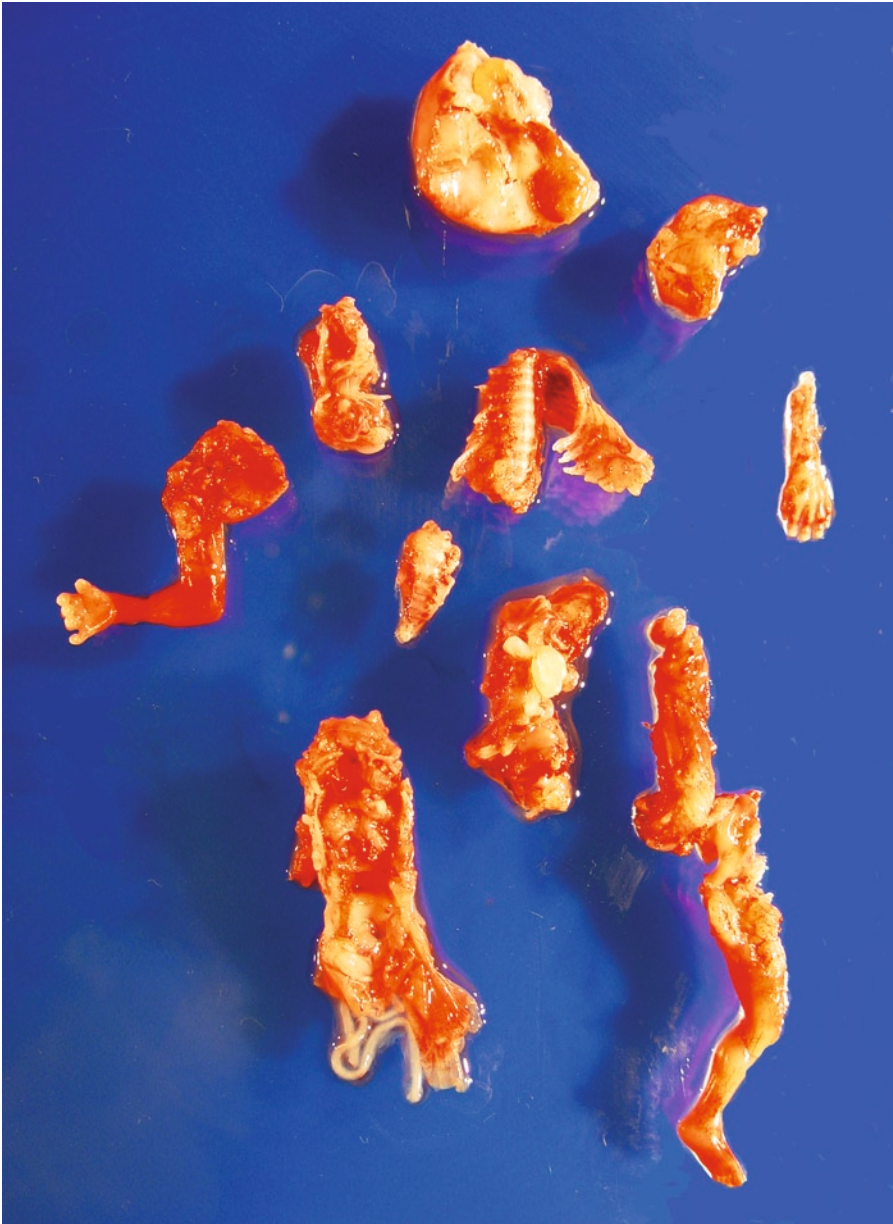


Figure 2.1. Fetus after pregnancy termination procedure with typical disruption. The fetal parts have been arranged such that the normal anatomical position has been approximated. The skull became collapsed during the procedure. This is a common artifact.

- Foot length – may be the only measurement possible in severe disruption but it has a good correlation with gestational age (Table 3.7)
- External appearance – initially give an overall evaluation of the extent of disruption. Then for each region below, describe each structure that can be identified indicating whether is anomalous

- or normal and list structures that cannot be evaluated or identified due to disruption
 - Skull, head, and face
 - Neck
 - Chest
 - Abdomen
 - Pelvis
 - Extremities
 - External genitalia
- Internal examination – describe what organs can be identified, whether they have normal relationships to other organs and whether they are anatomically normal, if possible. Then list those that cannot be evaluated due to disruption

The following is an *example* of the initial portion of a gross description of a normal, but disrupted fetus:

The fetus shows marked disruption and is quite fragmented. The head is markedly disrupted, with collapse of the skull and minimal brain tissue is present. Therefore, examination of the brain for anomalies is not possible. Evaluation of the cranium and upper face is not possible due to disruption. The lower jaw, lower lip, and portions of the upper lip are intact and show no abnormalities. There is no evidence of a cleft lip, but evaluation for a cleft palate is not possible due to disruption. One ear is present and shows normal development and placement. No other craniofacial features can be evaluated due to disruption.

It is recommended that when some portions are not present, one include what **is** present and what **cannot** be identified. It is not recommended to say that parts are missing, as this may imply that portions of the fetus were misplaced. This format is continued for the remaining areas of the body. One must be particularly careful in examination of the external genitalia because young fetuses are often missexed. The large size of the clitoris in female fetuses often gives the impression that they are male, and this is a common mistake made by novices. One must not just look at the phallus but *examine the genital folds and identify whether they are fused (scrotum) or separate (labia) and if there is a patent vagina*. These findings should be clearly stated in the gross section of the report rather than saying the fetus is “female” or “phenotypically female.” It is always helpful to have sections of the gonads to confirm sex. The sex is often important information both medically and personally for the family. If the external genitalia are entirely consistent with male or female sex, but the gonads could not be identified to confirm, then it is suggested that the diagnosis read “phenotypically male (or female) fetus” rather than “male (or female) fetus,” the latter being used when gonads are able to be examined microscopically.

The same systematic approach is used for the internal organs. Each visceral organ should be identified, and the organ relationships should be evaluated, if possible. This is particularly important in the setting of congenital heart defects where relationships with the lungs and great vessels are essential to diagnosis. Finally, anatomic defects in each organ are evaluated. Although each organ and portion of the fetus is

examined individually, attempts should be made to integrate the findings and provide as much information about each organ systems as possible. Organ weights should be included for intact organs only. The following is an example of a description of disrupted organs.

The abdomen and pelvis are markedly disrupted. Organs that can be identified are liver, bowel, stomach, kidneys, bladder, and gonads, all of which are grossly unremarkable and show no anatomic defects. Normal entrance of both ureters into the bladder is present, but the kidneys are partially disrupted and their relationship to the ureters cannot be ascertained. Other organ relationships cannot be evaluated due to disruption. Organ weights of intact organs are as follows...

When there is marked disruption, it is recommended that a comment be made indicating that "interpretation is limited due to disruption." In addition, the report should indicate whether or not the specific anomalies indicated in the clinical history may or may not be ruled out, and if the latter, why not. When specimens are macerated and autolyzed, additional artifacts are introduced. Specifically, the joints may be lax such that abnormalities of positioning of the extremities, such as arthrogryposis, cannot be evaluated. Dehydration also occurs and may make the diagnosis of hydrops or nuchal edema difficult if not impossible. The brain may not be able to be examined due to liquefaction. With fetal death, there is often hemorrhage, discoloration, and softening in many of the fetal tissues. These artifacts may also limit meaningful interpretation. In these circumstances, a "disclaimer" should also be included indicating that examination is limited due to marked autolysis.

Special Procedures

In certain situations, special procedures may be required. **Cytogenetic analysis** *is essential in cases of fetuses with multiple malformations.* Sometimes this is done prenatally via amniocentesis or chorionic villus sampling. If one is aware that these procedures have been done and has knowledge of these results, cytogenetic testing need not be repeated. In some states, it is required that these results be confirmed by sending a sample from the abortion specimen. Pathologists should be conversant with the health statutes in their area in order to be compliant. If a specimen is to be submitted for cytogenetic analysis, *it is prudent to send samples of both placenta and fetus.* The rationale for this is the following. The fetal tissue is optimal as it will be representative of the fetal genetic makeup. Placental tissue may or may not be reflective of the fetal genotype due to **confined placental mosaicism** (see Chap. 11), in which there is a variation of the placental genetic makeup disparate from the fetus. However, if the fetal tissue is macerated, fetal tissue will often not grow in culture. Therefore, it is best if both are submitted separately so that placental tissue may be used if the fetal cells do not grow. For the fetal sample, connective tissue such as tendon is often used, but skeletal muscle often grows better in culture. Chorionic villi or chorionic plate tissue is suggested for the placental sample, as this will avoid the maternal tissue that is present in the basal plate.

The specimen should be submitted in a sterile fashion in the appropriate medium as required by the specific laboratory. In cases without a significant clinical history suggesting a chromosomal anomaly and lack of fetal anomalies, the yield of karyotypic analysis is usually low, depending on the patient population.

If the constellation of malformations does not fit into one of the various chromosomal syndromes, e.g., trisomies, and the diagnosis is not apparent from prenatal testing or gross examination, it *may be sensible to freeze a portion of fetal tissue*. This requires minimal labor but the rewards are great if tissue is needed for molecular studies to make the diagnosis. If the tissue is found to be unnecessary, it may easily be discarded. Usual recommendations are to snap freeze organ tissue, such as the liver, and connective tissue in liquid nitrogen and then store at -70 to -80°C . Placental tissue may be frozen as well.

If the fetus has obvious limb or bony abnormalities, radiographs should be taken. These are necessary for the diagnosis of **skeletal dysplasias** as well as many malformation syndromes with bony anomalies. Bony abnormalities include *shortened, missing or abnormally formed limbs or digits and abnormalities of the spine, ribs, or skull*. On occasion, severe growth restriction of the fetus has been confused with skeletal dysplasias, and radiographs will help differentiate these cases. The fetal parts should be positioned anatomically with an attempt to straighten them into an anterior–posterior position. The exposure of the radiograph should be adequate for evaluation of bony structures (Fig. 2.2). In cases of suspected skeletal dysplasia, *longitudinal sections of a long bone should also be submitted for routine histology* and a portion of bone should be snap frozen and stored at -70 to -80°C , in addition to organ tissue and connective tissue.

Uncommonly, fetuses may suffer from metabolic disorders. If these are suspected, a small amount of fetal tissue should be fixed for later **electron microscopy** as well as snap-frozen. Finally, in some cases, **bacterial cultures** of the fetus or placenta may be indicated. This is particularly true when the fetal surface of the placenta is opaque, which is suggestive of an ascending infection. To take the culture, the amnionic membrane is lifted from the chorionic plate and the surface of the plate should be swabbed. This will usually avoid bacterial contamination. Unless the clinical history or gross examination suggests an ascending infection or acute chorioamnionitis, bacterial cultures are usually not recommended.

Submission of Microscopic Sections

Sections of each organ identified should be submitted for microscopic examination. At times, marked disruption may make identification of solid organs difficult, particularly the liver, spleen, and adrenals. In this situation, there are often additional fragments of tissue that cannot grossly be identified as a particular organ but are clearly of fetal origin. It is suggested that these fragments also be submitted for microscopic examination. Depending on the type of anomaly identified, special sections of the anomalous part are submitted. For example, in anencephaly

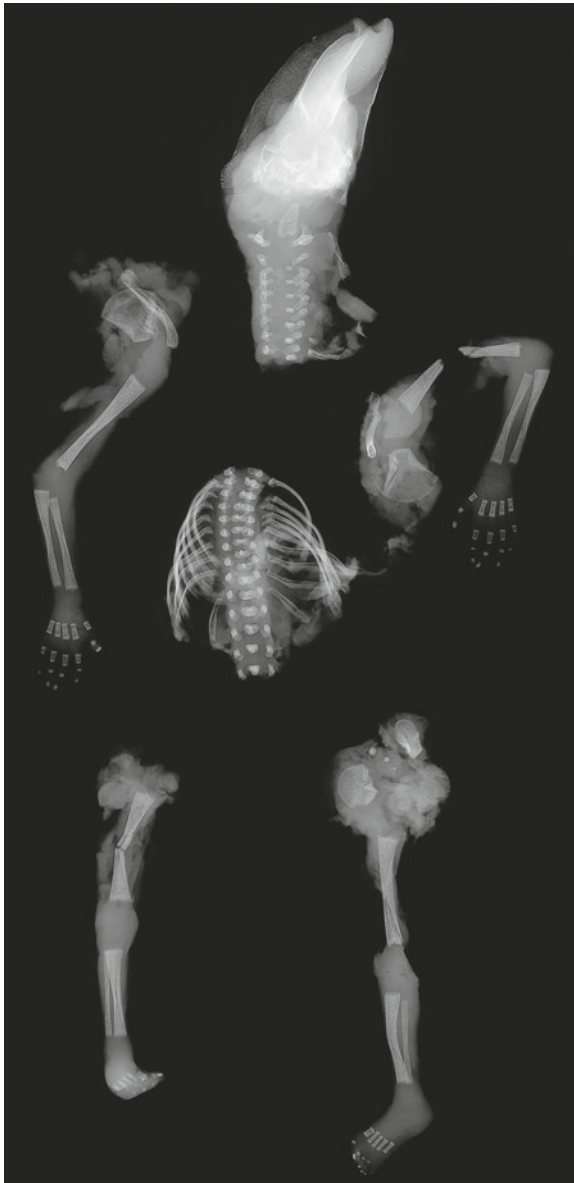


Figure 2.2. Radiograph of the fetus depicted in Fig. 2.1. The X-ray has been taken with the fetal parts placed in an approximation of the normal anatomical position. An attempt should be made to ensure that there is minimal twisting so that a typical anterior-posterior (A-P) position is achieved. This fetus showed no gross, radiographic, or microscopic abnormalities.

sections through the base of the skull are particularly illustrative of the lack of brain tissue and the presence of the cerebrovasculosa. Thus, sectioning must be tailored to the anomalies that are present as well as those that are suspected. The reader is referred to the many excellent texts on the subject of fetal anomalies and the best techniques for the

dissection of those anomalies. Sections of the placenta should also be submitted similar to that for third trimester placentas (see Chap.3), including two sections of the membranes, two sections of umbilical cord, and several sections of villous tissue. The latter should include both fetal and maternal surfaces if possible. If grossly identifiable decidual tissue is present, a small fragment should also be submitted for microscopic examination.

Microscopic Description, Diagnosis, and Report

Microscopic sections of each organ should be examined for appropriateness for stated gestational age as well as the presence of abnormalities. In some cases, this is confirmation of a grossly identified abnormality, while in others it may be primarily a microscopic finding. The gross and microscopic findings should be integrated with the goal of making a specific diagnosis. This is important in that different syndromes have markedly different recurrence risks and so have significance to the family in making decisions about future pregnancies.

A statement about whether or not the fetus is the appropriate size for the gestational age is obligatory. Tables of normative values with crown-rump, crown-heel, and foot length can be used for this purpose (see Table 3.7). The sex of the fetus should also be stated if this is known. If the determination of sex is based solely on external genitalia, it is wise to indicate that the fetus is “phenotypically” male or female. Thus, one can state “Phenotypically male fetus, size consistent with 17 weeks’ gestation.” If a diagnosis of a particular syndrome can be made, this should follow in the next statement. If a particular syndrome is suspected clinically, but cannot be confirmed, a statement such as “Clinical history of ...” may be used instead. This should be followed by the specific anomalies noted on gross and microscopic examination. Each abnormality indicated in the clinical history should be addressed as *present*, *absent*, or *unable to be evaluated due to disruption or maceration*. This is important because lack of specific anomalies may rule out certain syndromes that are in the differential diagnosis. Unfortunately, with disrupted fetuses, limitations in examination often make meaningful diagnosis impossible. In that case, it should be clearly stated that a diagnosis cannot be made and why. A general comment may also be added indicating that pathologic evaluation is limited due to marked disruption.

Selected References

- PHP5, pages 1–11 (Examination of the Placenta).
 Baldwin VJ, Kalousek DK, Dimmick JE, Applegarth DA, Hardwic DF.
 Diagnostic pathologic investigation of the malformed conceptus. *Perspect*
Pediatr Pathol 1982;7:65–108.
 Dimmick JE, Kalousek DK. Developmental pathology of the fetus and infant.
 Philadelphia: Lippincott, 1992.
 Gilbert-Barnass E (ed). *Potter’s pathology of the fetus and infant*. St. Louis:
 Mosby, 1997.

- Gilbert-Barnass E, Debich-Spicer DE. Handbook of pediatric autopsy pathology. Totowa, NJ: Humana Press, 2005.
- Gilbert-Barnass, Debich-Spicer DE, Williams M. Embryo and fetal pathology: color atlas with ultrasound correlation. Cambridge, UK: Cambridge University Press, 2004.
- Jones KL. Smith's recognizable patterns of human malformation, 5th ed. Philadelphia: WB Saunders, 1997.
- Kalousek DK, Fitch N, Paradise BA. Pathology of the human embryo and pre-viable fetus. An atlas. New York: Springer-Verlag, 1990.
- Keeling JW. Fetal pathology. Edinburgh: Churchill Livingstone, 1994.
- Keeling JW, Khong TY. Fetal and neonatal pathology, 3rd ed. London: Springer, 2007.
- Wigglesworth JS, Singer DB. Textbook of fetal and perinatal pathology, 2nd ed. Malden, MA: Blackwell Science, 1998.

Manual of Pathology of the Human Placenta

Second Edition

Baergen, R.N.

2011, XIV, 544 p. 8 illus. in color., Softcover

ISBN: 978-1-4419-7493-8