

Chapter 2

Cardiac Interpretation of Pediatric Chest X-Ray

Ra-id Abdulla and Douglas M. Luxenberg

Key Facts

- The cardiac silhouette occupies 50–55% of the chest width on an anterior–posterior chest X-ray
- When assessing the cardiovascular system on a chest X-ray, the following must be noted:
 - The size of the heart (small, normal, or large)
 - The contours of the heart reflecting various cardiovascular components which can be enlarged, absent, or displaced
 - The Pulmonary vascularity which can be diminished, normal, or increased
- Many newborn children appear to have cardiomegaly when in fact the thymus is contributing to the “cardio-thymic shadow”. The lateral view of CXR can separate this from true cardiomegaly.
- An enlarged heart coupled with an increase in pulmonary vascular markings can be indicative of left to right shunting such as with ASD, VSD, and PDA.

Introduction

Chest X-ray is an important tool in evaluating heart disease in children. Noninvasive imaging such as echocardiography and cardiac MRI provide valuable and detailed assessment of the cardiovascular system; however, the cost incurred from these

Ra-id Abdulla (✉)

Center for Congenital and Structural Heart Diseases, Rush University Medical Center,
1653 West Congress Parkway, Room 763 Jones, Chicago, IL 60612, USA
e-mail: rabdulla@rush.edu

diagnostic procedures is significant making their routine use difficult. Chest X-ray on the other hand is easy to perform, economical, and provides important information including heart size, pulmonary blood flow, and any associated lung disease. History of present illness coupled with physical examination provides the treating physician with a reasonable list of differential diagnoses which can be further focused with the aid of chest X-ray and electrocardiography making it possible to select a management plan or make a decision to refer the child for further evaluation and treatment by a specialist.

Approach to Chest X-Ray Interpretation

Unlike echocardiography, chest X-ray does not provide details of intracardiac structures. Instead the heart appears as a silhouette of overlapping cardiovascular chambers and vessels. Chest X-ray obtained in two perpendicular views, specifically anteroposterior (AP) and lateral, makes it possible to construct a mental three-dimensional image of the heart.

The size and shape of the heart as well as the pulmonary vascular markings, pleura and parenchymal lung markings provide helpful information regarding the heart/lung pathology.

It is easy to be overwhelmed with a prominent pathology on a chest X-ray thus overlooking more subtle changes; therefore, it is imperative to conduct interpretation of chest X-ray carefully and systematically considering the following issues.

Heart size: The size of the heart represents all that lies within the pericardial sac. This includes the volume within each cardiac chamber, cardiac wall thickness, pericardial space, and any other additional structure such as mass from a tumor or air trapped within the pericardium (pneumopericardium). Therefore, enlargement of any of these structures will lead to the appearance of cardiomegaly on chest X-ray. Dilated atria or ventricles such as that seen in heart failure will cause the cardiac silhouette to appear large, as would hypertrophy of the ventricular walls or fluid accumulation within the pericardial space (Tables 2.1 and 2.2).

Heart shape: The presence of certain subtleties in the cardiac shape may point to a particular pathology and thus help narrow the differential diagnosis. Enlargement or hypoplasia of a particular component of the heart will alter the normal shape of the cardiac silhouette. Therefore, each aspect of the heart border should be examined to assess for abnormalities. Examples of this include prominence of the aortic arch in patients with systemic hypertension or aortic stenosis (AS) due to dilation of the aorta. On the other hand, pulmonary atresia will cause the mediastinum to be narrow due to hypoplasia of the pulmonary artery.

Pulmonary blood flow: Pulmonary vasculature is normally visible in the hilar region of each lung adjacent to the borders of the cardiac silhouette. An increase in pulmonary blood flow or congestion of the pulmonary veins will cause prominence of the pulmonary blood vessels. A significant increase in pulmonary blood flow

Table 2.1 Cardiac pathology and changes of cardiac silhouette

Cardiac pathology	Features
Right atrial enlargement	AP view: fullness of the right heart border
Right ventricular enlargement	AP view: uplifting of the cardiac apex Lateral view: fullness of the lower retrosternal region of the cardiac silhouette
Main pulmonary artery dilation	AP view: prominence of the main pulmonary artery trunk in the midleft border of the cardiac silhouette Lateral view: fullness of the midretrosteral portion of the cardiac silhouette
Branch pulmonary artery dilation	AP view: prominent pulmonary arteries over the corresponding lung field, typically in the hilar region
Left atrial enlargement	AP view: double shadow in the midcardiac silhouette region as well as widening the tracheal branching (carina) Lateral view: prominence of the posterior border of the cardiac silhouette with posterior deviation of the esophagus
Left ventricular enlargement	AP view: enlarged cardiac silhouette with lateral and downward displacement of the cardiac apex
Aortic arch dilation	AP view: prominent aortic arch in the upper region of the left border of the cardiac silhouette
Thymus gland	AP view Enlarged: a sail like sign over the upper-midcardiac silhouette, in severe cases may give the impression of cardiomegaly Atrophy: narrowed mediastinum Lateral view Enlarged: soft tissue occupying the upper retrosternal field, typically occupied by lung tissue Atrophy: absence of soft tissue in the upper retrosternal region, may be normal in older children but in neonates should cause suspicion of DiGeorge syndrome

Table 2.2 Congenital heart diseases and changes in cardiac chambers

Atrial septal defect	Right atrial enlargement, right ventricular enlargement, pulmonary artery dilation
Ventricular septal defect	Left ventricular enlargement, pulmonary artery dilation, left atrial enlargement
Patent ductus arteriosus	Pulmonary artery dilation, left atrial enlargement, left ventricular enlargement
Aortic stenosis	Left ventricular enlargement
Pulmonary stenosis	Right ventricular enlargement
Coarctation of the aorta	Left ventricular enlargement, Rib notching
Atrioventricular canal defect	All cardiac chambers enlarged
Tetralogy of Fallot	Right ventricular enlargement, hypoplasia of pulmonary arteries, <i>coeur en sabot</i>
Double outlet right ventricle	Right ventricular enlargement
Pulmonary atresia	Right ventricular hypoplasia
Tricuspid atresia	Right ventricular hypoplasia

(continued)

Table 2.2 (continued)

Pulmonary atresia-intact ventricular septum	No tricuspid regurgitation: right ventricular hypoplasia Severe tricuspid regurgitation: right atrial enlargement, right ventricular enlargement
Truncus arteriosus	Right ventricular enlargement, pulmonary artery hypoplasia
Total anomalous pulmonary venous return	Dilation of veins draining anomalous pulmonary veins, such as vertical vein, innominate vein, superior vena cava, “Snowman” sign
Hypoplastic left heart syndrome	Left ventricular hypoplasia, ascending aorta and aortic arch hypoplasia
Transposition of the Great Arteries	Narrowed mediastinum, “egg on a string”

will cause dilation of peripheral pulmonary vessels, allowing their visualization in the normally dark peripheral lung fields.

Pleural space: Heart failure results in venous congestion which may lead to fluid accumulation within the pleural spaces manifesting as a pleural effusion. Pleural effusion may be noted on chest X-ray as a rim of fluid in the outer lung boundaries of the chest cavity or as haziness of the entire lung field in a recumbent patient due to layering of the fluid behind the lungs.

Normal CXR

Anteroposterior View

The cardiac silhouette occupies 50–55% of the chest width. Cardiomegaly is present when the cardiothoracic (CT) ratio is more than 55%. The right border of the cardiac silhouette consists of the following structures from top to bottom: superior vena cava, ascending aorta, right atrial appendage, and right atrium (Fig. 2.1). The left border of the cardiac silhouette is formed from top to bottom by the aortic arch (aortic knob), pulmonary trunk, left atrial appendage, and the left ventricle. Of note is that the right ventricle does not contribute to either heart border.

In the normal chest X-ray only the larger, more proximal pulmonary arteries can be visualized in the hilar regions of the lungs and the lung parenchyma should be clear with no evidence of pleural effusion (Fig. 2.2).

Lateral View

The cardiac silhouette in this view is oval in shape and occupies the anterior half of the thoracic cage. Lung tissue occupies the dorsal half of the chest cavity.

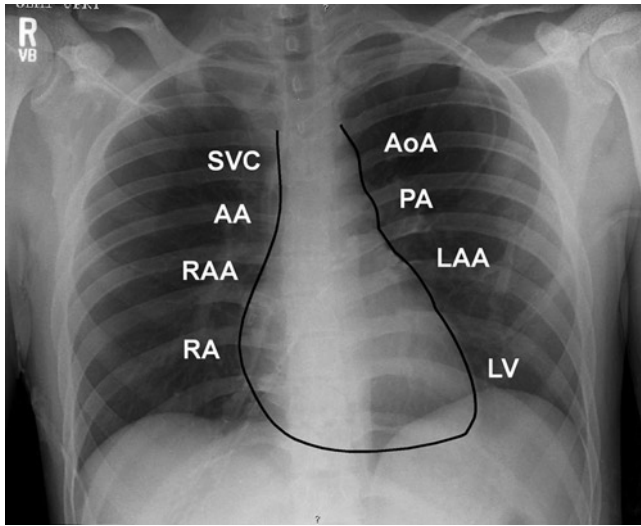


Fig. 2.1 Heart border: The cardiac silhouette is formed by a variety of cardiovascular structures. In an AP view, the right heart border is formed from top to bottom by superior vena cava, ascending aorta, right atrial appendage, and the right atrium. On the *left side*, the heart border is formed from top to bottom by the aortic arch (knob), main pulmonary artery, left atrial appendage, and the left ventricle. AA ascending aorta, AoA aortic arch, LAA left atrial appendage, RAA right atrial appendage, RA right atrium, SVC superior vena cava

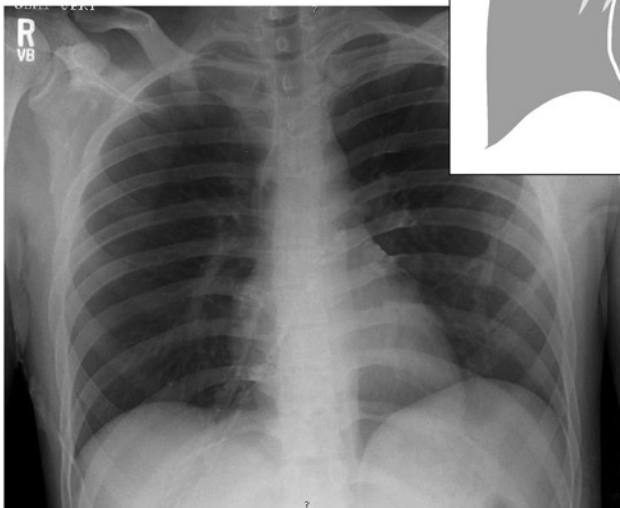


Fig. 2.2 Normal chest X-ray: The cardiac silhouette is normal in size and contour. A normal pulmonary blood flow pattern is present with no evidence of pleural disease

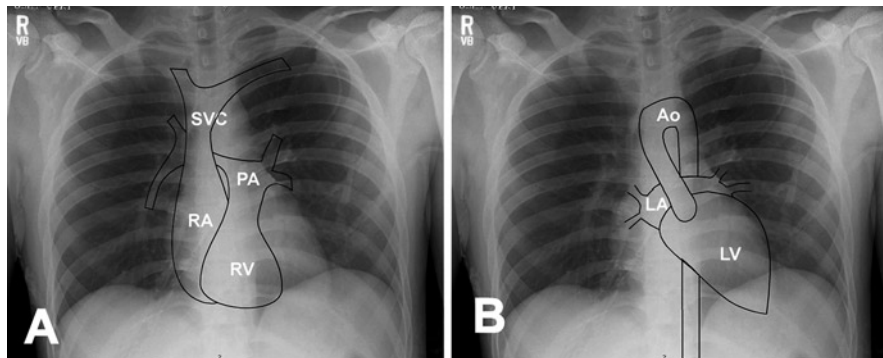


Fig. 2.3 (a) The superior vena cava forms from the union of the innominate veins. The right atrium occupies the right border of the cardiac silhouette. The right ventricle is the anterior most part of the heart and occupies the middle region within the cardiac silhouette. The main pulmonary artery is to the left of the ascending aorta and forms a small portion of the middle of the left cardiac silhouette border as it courses posteriorly and bifurcates into right and left pulmonary arteries. (b) The left atrium lies behind the left ventricle, the ascending aorta courses to the right of the pulmonary artery and then arches at the superior aspect of the mediastinum. The mediastinum is formed by the crossing of the aorta and pulmonary artery. *Ao* aorta, *LA* left atrium, *LV* left ventricle, *PA* pulmonary artery, *RA* right atrium, *RV* right ventricle, *SVC* superior vena cava

The ascending aorta and right ventricle form the anterior border, while the left atrium and left ventricle form the posterior border.

The various cardiovascular components cannot be visualized by chest X-ray, however, knowledge of cardiac and vascular anatomy within the cardiac silhouette is helpful in understanding both normal and abnormal findings on chest X-ray (Fig. 2.3a, b).

Change in the shape of the cardiac silhouette may point to specific cardiac structural abnormalities; for example, an uplifted cardiac apex points to right ventricular hypertrophy due to displacement of the left ventricular apex upward and laterally. We will now discuss some specific congenital cardiac lesions and their associated chest X-ray findings.

Shunt Lesions

Atrial Septal Defect

AP View

Because systemic vascular resistance is higher than pulmonary vascular resistance blood will flow from left to right across the defect with resultant increase in pulmonary blood flow. This will cause prominent pulmonary vascular markings on chest X-ray. In moderate to large defects, the AP view will show an enlarged cardiac silhouette due to fullness of the right atrium (Fig. 2.4).

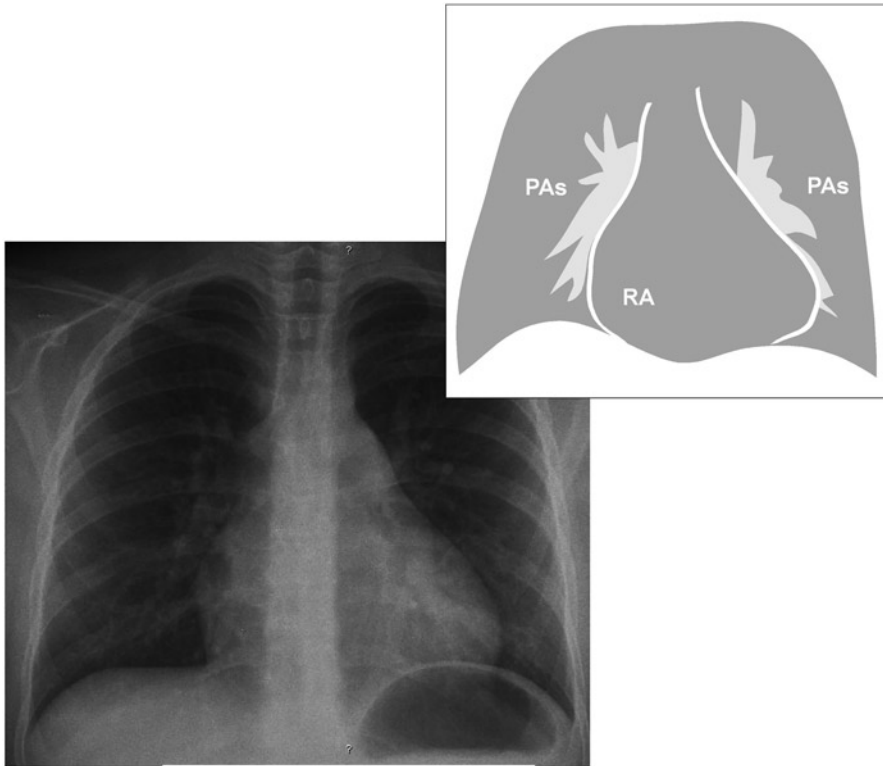


Fig. 2.4 Atrial septal defect. An atrial septal defect causes an increase in heart size with fullness of the right heart border due to right atrial enlargement. The pulmonary arteries are full and may be well visualized even in the peripheral lung fields indicating an increase in pulmonary blood flow. *PAs* pulmonary arteries, *RA* right atrium

Lateral View

Prominent pulmonary vasculature is noted, particularly in the hilar region. In severe cases, the right ventricle is dilated and is noted as fullness of the anterior most aspect of the cardiac silhouette causing obliteration of the usual space between the heart and sternum.

Ventricular Septal Defect

AP View

Left to right shunting at the ventricular level will cause an increase in pulmonary blood flow. The increase in pulmonary blood flow will manifest as engorged pulmonary vasculature. The increase in return of blood to the left atrium and ventricle may cause left atrial and left ventricular dilation (Fig. 2.5).

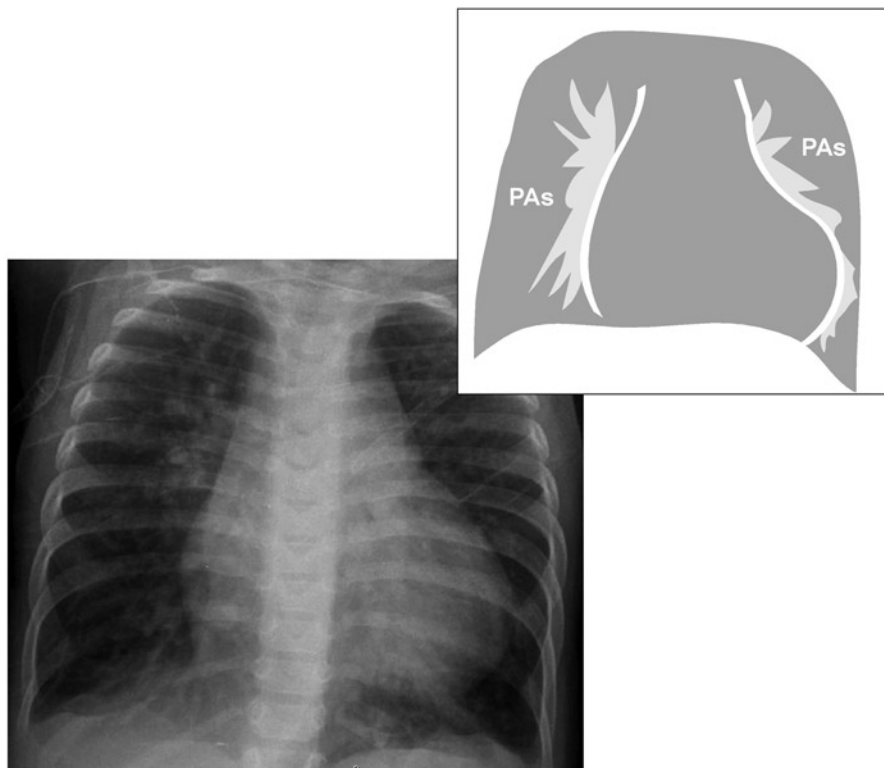


Fig. 2.5 Ventricular septal defect (VSD). Cardiomegaly is noted in most moderate to large VSDs. An increase in pulmonary blood flow results in prominent pulmonary vasculature which may be noted in the peripheral lung fields. *PAs* pulmonary arteries

Lateral View

The lateral view shows a posteriorly deviated esophagus reflective of a dilated left atrium.

Patent Ductus Arteriosus

AP View

Left to right shunting at the arterial level causes dilation of the pulmonary vasculature. The main pulmonary artery is dilated which may be noted by prominence of the main pulmonary artery segment at the left heart border just below the aortic arch on the AP view. The left atrium and ventricle become dilated due to increased

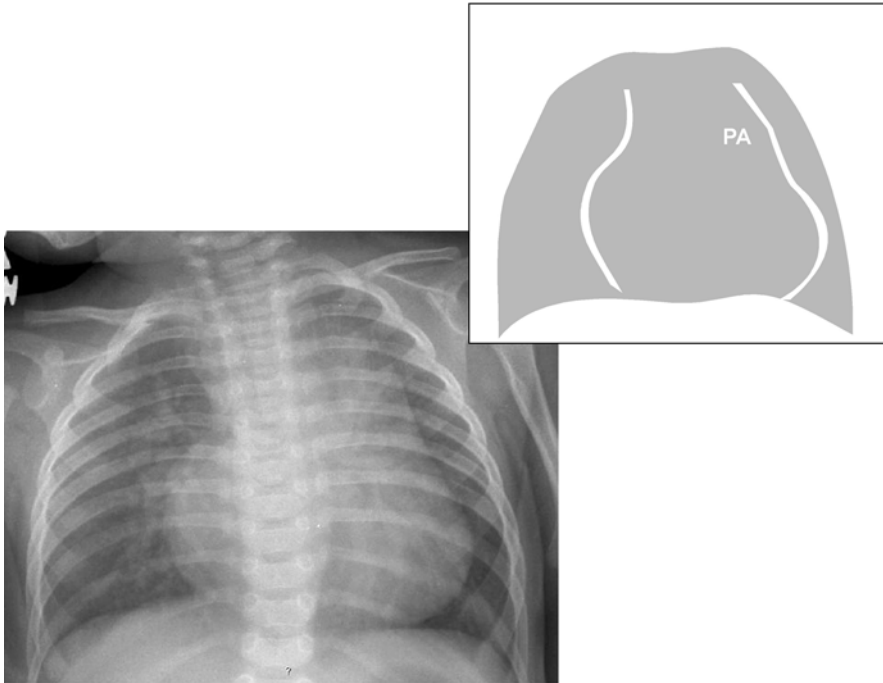


Fig. 2.6 Patent ductus arteriosus (PDA). In addition to the PDA itself, the dilated main and branch pulmonary arteries cause the middle segment of the left heart silhouette to be prominent. *PA* pulmonary artery

pulmonary venous blood return to the left atrium resulting in cardiomegaly. Left atrial dilation may cause widening of carina angle (Fig. 2.6).

Lateral View

Prominent pulmonary vasculature and a dilated left atrium are noted. Left atrial dilation may cause posterior deviation of the esophagus.

Atrioventricular Canal Defect

AP View

Large atrial and ventricular septal defects (VSDs) are common with this lesion. The resultant significant increase in pulmonary blood flow results in prominent pulmonary vasculature. This, coupled with regurgitation of the atrioventricular valve, results in cardiomegaly due to dilation of all cardiac chambers. Left atrial dilation may cause a widening of the carina angle as well (Fig. 2.7).

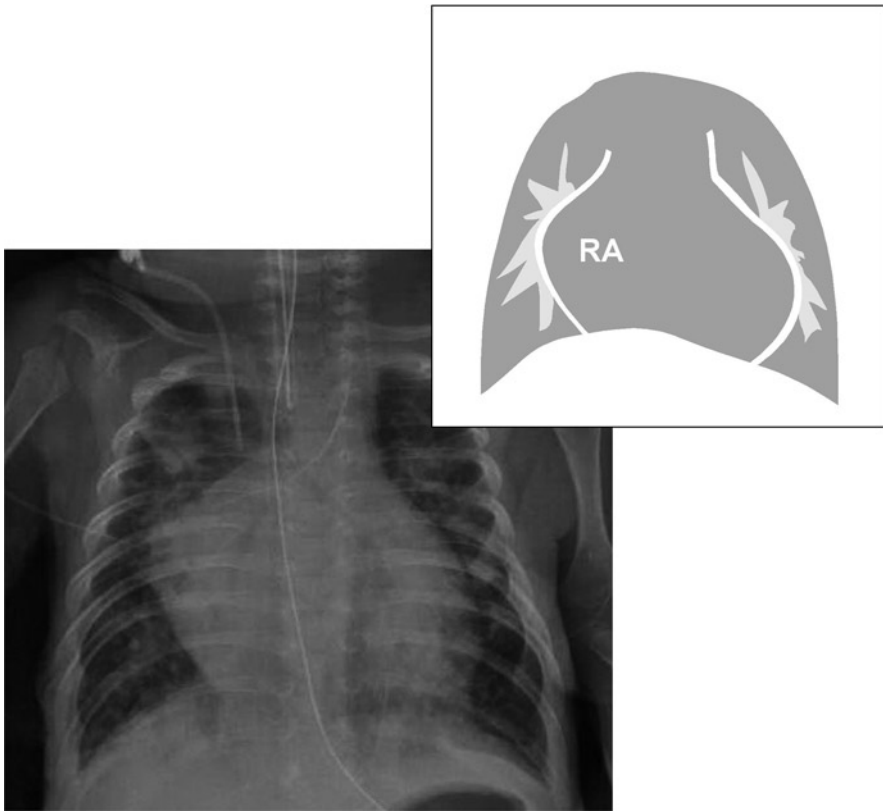


Fig. 2.7 Atrioventricular canal defect. The heart is enlarged due to dilation of all cardiac chambers from left to right shunting and atrioventricular valve regurgitation. The pulmonary arteries are very prominent. This patient also has right upper lobe atelectasis which may be seen in patients with a significant increase in pulmonary blood flow and heart failure. RA right atrium

Lateral

Prominent pulmonary vasculature and cardiomegaly are noted. Left atrial dilation may cause posterior deviation of the esophagus.

Obstructive Lesions

Pulmonary Stenosis

AP View

The jet-like flow across the narrowed pulmonary valve orifice causes the main pulmonary artery to dilate. This manifests as prominence of the pulmonary artery

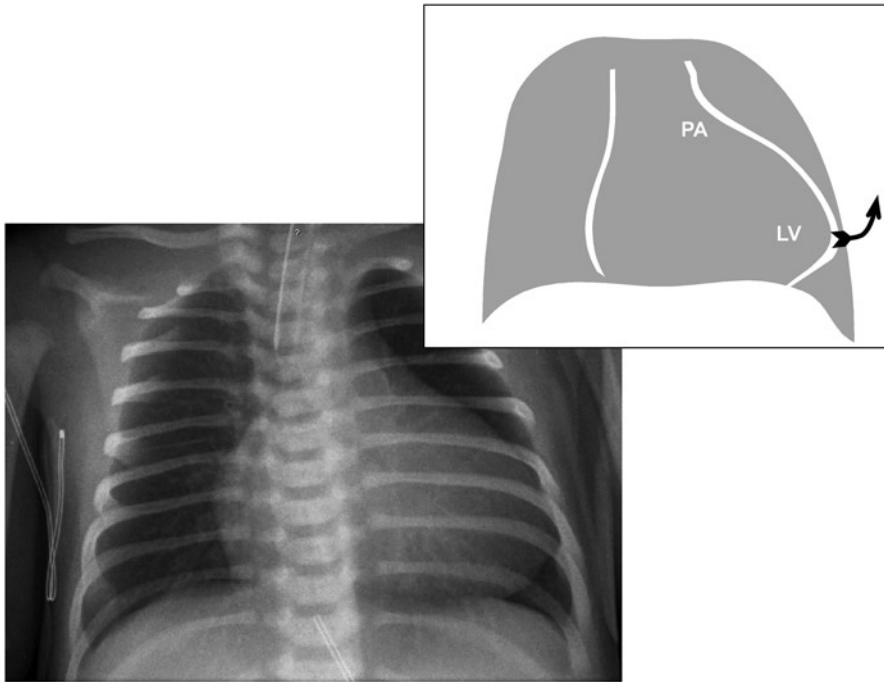


Fig. 2.8 Pulmonary stenosis. The main pulmonary artery is dilated (seen in the mid left border of the cardiac silhouette) and the left ventricular apex is uplifted secondary to right ventricular enlargement. *LV* left ventricle, *PA* pulmonary artery

segment in the midleft border of the cardiac silhouette, just below the aortic arch prominence. Right ventricular dilation and hypertrophy are present in cases of severe and prolonged pulmonary stenosis (PS). Right ventricular enlargement will manifest as uplifting of the cardiac apex (Fig. 2.8).

Lateral View

A dilated main pulmonary artery may be seen as fullness of the upper retrosternal portion of the cardiac silhouette. Right ventricular enlargement will cause fullness of the lower retrosternal portion of the cardiac silhouette.

Aortic Stenosis

AP View

The jet-like flow across the narrowed aortic valve orifice will result in the dilation of the ascending aorta which will be noted in the mid region of the right heart border.

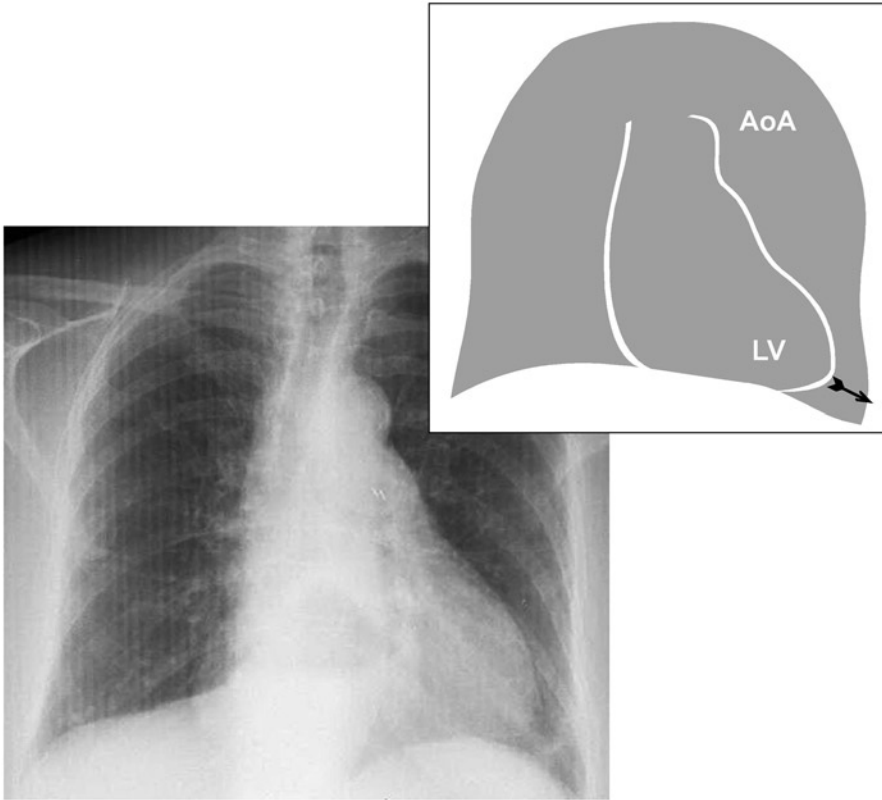


Fig. 2.9 Aortic stenosis. The aortic arch (upper left border of the cardiac silhouette) is prominent with the evidence of left ventricular dilation. Note the down and outward displacement of the cardiac apex. The heart is enlarged as well. *AOA* aortic arch, *LV* left ventricle

In severe cases, the aortic knob (the upper portion of left border of cardiac silhouette) will be prominent.

Prolonged AS will cause left ventricular failure and dilation which will manifest as a downward and lateral displacement of the cardiac apex (Fig. 2.9).

Lateral View

This is typically normal except in cases of congestive heart failure where cardiomegaly is seen.

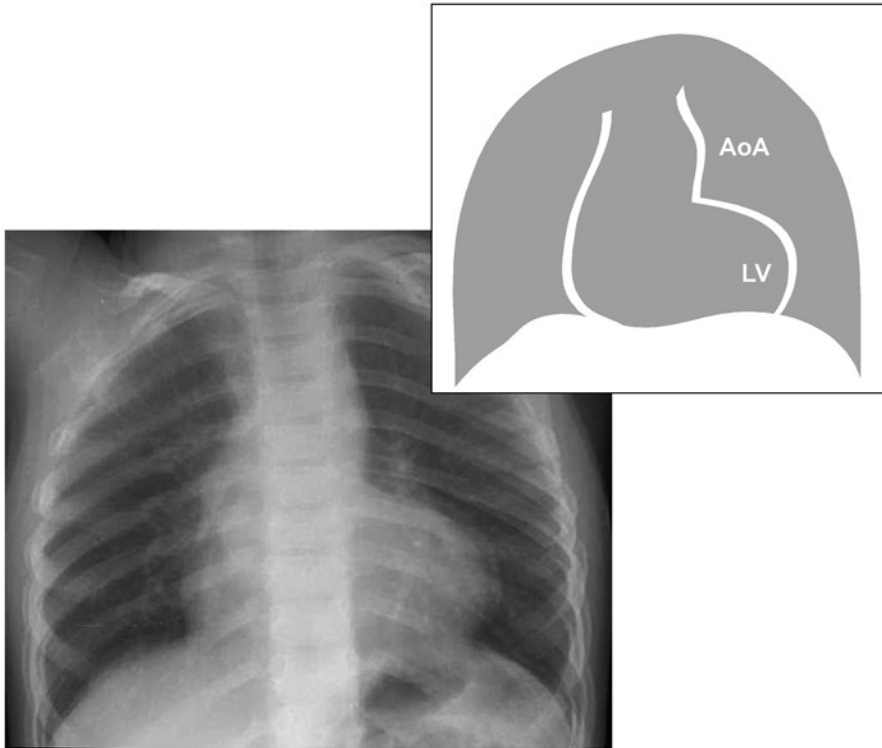


Fig. 2.10 Coarctation of the aorta. The aortic arch is hypoplastic in this patient resulting in the absence of aortic knob prominence at the upper left border of the cardiac silhouette. Cardiomegaly is present due to left ventricular failure and dilation. AOA aortic arch, LV left ventricle

Coarctation of the Aorta

AP View

While coarctation of the aorta (CoA) is most often not initially detectable by CXR, prolonged and severe disease may lead to left ventricular hypertrophy, and dilation, manifesting as cardiomegaly. Long standing CoA may cause a “reverse 3 sign” noted in the aortic knob (the upper portion of left cardiac silhouette border) and “rib notching” which is a deformation of the inferior surface of the ribs (Fig. 2.10).

Lateral View

Cardiomegaly may be noted; otherwise no significant pathology is typically present.

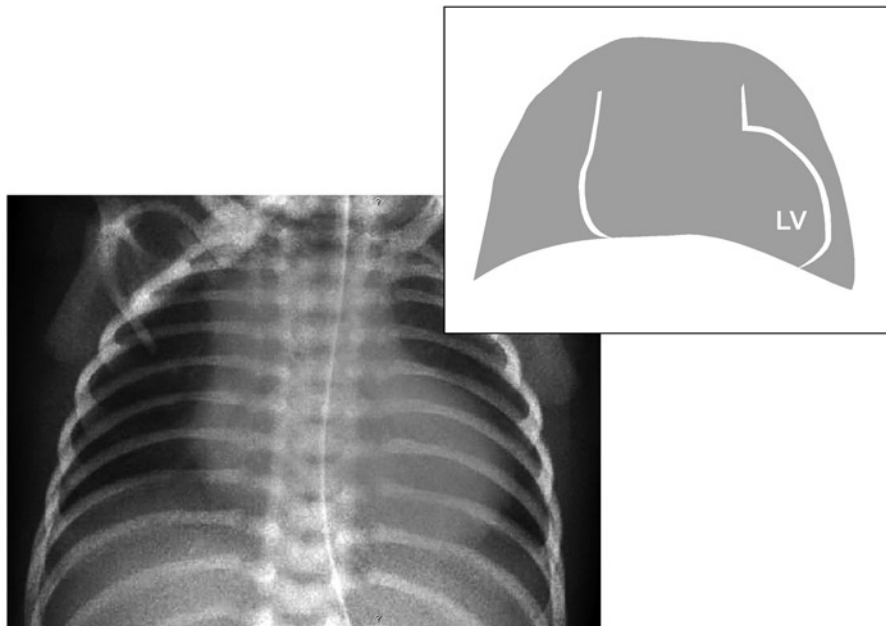


Fig. 2.11 Tetralogy of Fallot. The mediastinum is narrow due to hypoplasia of the pulmonary valve. The left ventricular apex is displaced laterally and upward due to right ventricular hypertrophy. The lungs appear anemic due to reduced pulmonary blood flow secondary to severe pulmonary stenosis and right to left shunting at the ventricular septal defect. *LV* left ventricle

Cyanotic Congenital Heart Lesions

Tetralogy of Fallot

AP View

Small, hypoplastic or atretic pulmonary arteries will cause the mediastinum to appear narrow. Right ventricular hypertrophy secondary to PS will cause an uplifting of the cardiac apex. Together, these two findings will give the classic *coeur en sabot* (boot shaped) appearance of the heart. Severe PS will restrict pulmonary blood flow, this will be manifested as diminished pulmonary vascular markings (Fig. 2.11).

Lateral View

Right ventricular hypertrophy will cause fullness of the cardiac silhouette in the retrosternal region. An “anemic” lung appearance due to reduced pulmonary blood flow will be noted.

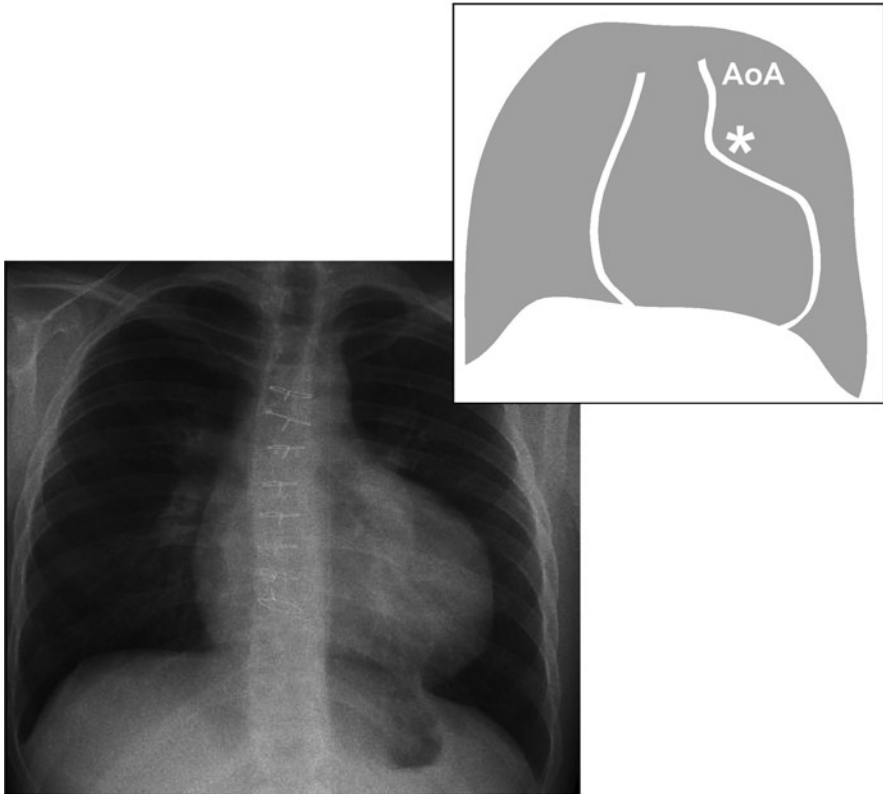


Fig. 2.12 Pulmonary atresia. Reduced pulmonary blood flow gives the appearance of “anemic lungs”; this may be seen in tricuspid atresia as well as in pulmonary atresia when the patent ductus arteriosus is small. *AoA* aortic arch, *asterisk* (*) indicates the absence of pulmonary artery segment due to hypoplasia of the main pulmonary artery

Tricuspid Atresia

AP View

In patients with tricuspid atresia (TrA) and intact ventricular septum, the right ventricle will be hypoplastic, rendering the heart size small on chest X-ray. This can be subtle and the chest X-ray may appear normal. Because patients with TrA must have a patent ductus arteriosus (PDA) or systemic-to-pulmonary arterial collaterals to survive, the pulmonary blood flow is typically increased with resultant prominent pulmonary vasculature (Fig. 2.12).

Lateral View

Increased pulmonary blood flow due to a PDA or systemic-to-pulmonary arterial collaterals may be present. Otherwise this view may be within normal limits.

Pulmonary Atresia-Intact Ventricular Septum**AP View**

Patients with pulmonary atresia-intact ventricular septum (PA-IVS) and severe tricuspid regurgitation develop dilation of the right atrium and ventricle manifesting as cardiomegaly with fullness of the right heart border. On the other hand, patients with mild or no tricuspid regurgitation will have small right ventricles and no changes on CXR. The extent of pulmonary blood flow depends upon the size of PDA or systemic-to-pulmonary arterial collaterals. Large shunts will cause an increase in pulmonary blood flow manifesting as prominent pulmonary vasculature on chest X-ray, while those with small shunts will have reduced pulmonary vascular markings (Fig. 2.12).

Lateral View

Cardiomegaly due to right atrial and ventricular enlargement may be noted with severe tricuspid regurgitation. Prominent pulmonary vasculature is noted with large shunts due to a large PDA or significant systemic-to-pulmonary arterial collaterals.

Truncus Arteriosus**AP View**

The normal mediastinum is largely contributed to by the “x-like” crossing of the pulmonary artery and aorta. In truncus arteriosus (TA) there is a single great vessel (truncus) resulting in a narrow mediastinum. In addition, many patients with TA have DiGeorge syndrome, where there is small or no thymus gland, further contributing to the appearance of a narrow mediastinum. The size and origin of the pulmonary arteries can be quite variable in this lesion and may be speculated at in this view by the amount of flow noted to each lung segment (Fig. 2.13).

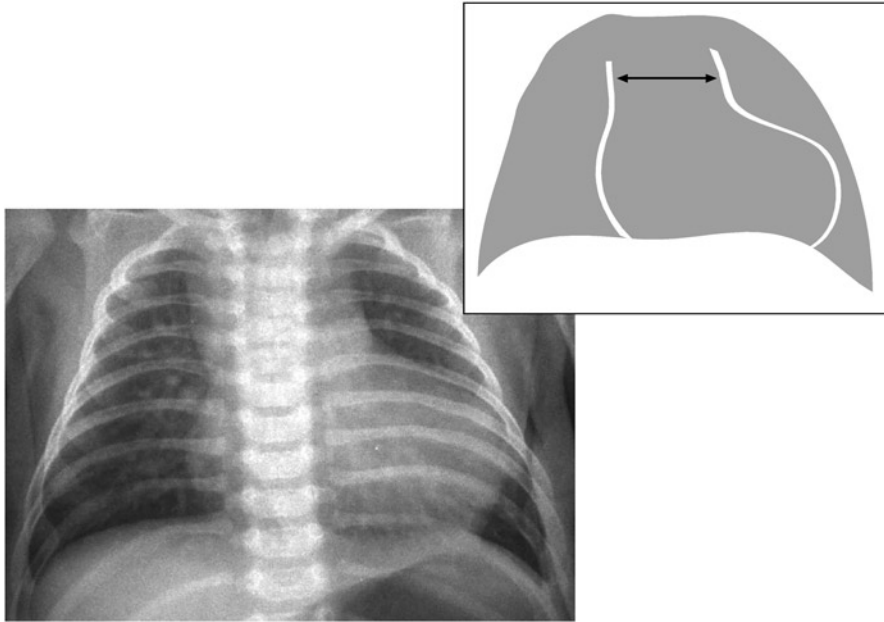


Fig. 2.13 Truncus arteriosus. Narrowed mediastinum and cardiomegaly due to biventricular enlargement as a result of increased pulmonary blood flow

Lateral View

The thymus gland is seen as soft tissue in the high retrosternal region of lateral chest X-ray. An absent thymus suggests DiGeorge syndrome.

Total Anomalous Pulmonary Venous Return

AP View

Total anomalous pulmonary venous return (TAPVR) gives a classic appearance when the anomalous pulmonary veins return through a vertical vein to the innominate vein. The dilated vertical vein, innominate vein, and superior vena cava create a round image above the cardiac silhouette giving a “snowman” appearance. The pulmonary vasculature is prominent, mainly due to pulmonary venous congestion. Other types of anomalous pulmonary venous drainage, such as those connecting to the inferior vena cava may not be noted by chest X-ray (Fig. 2.14).

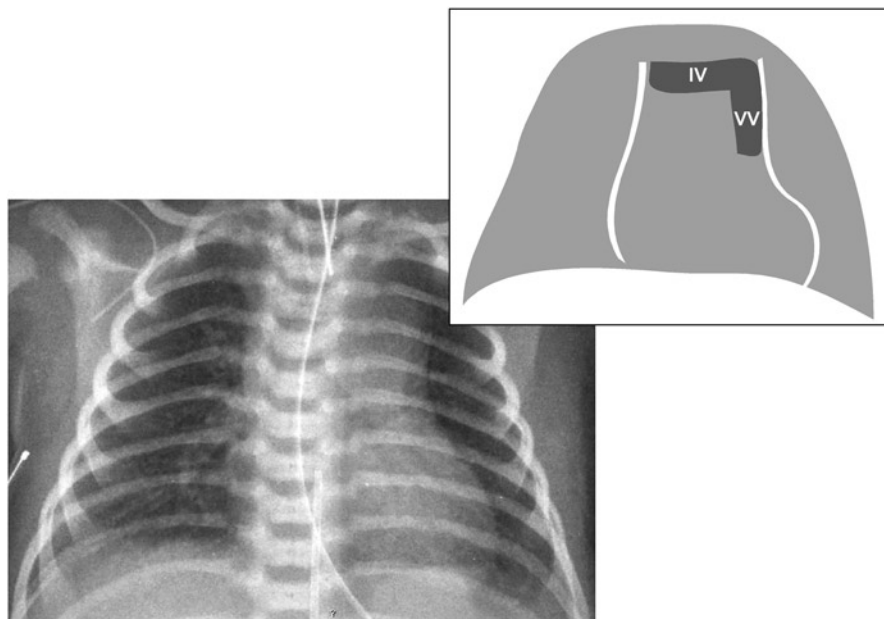


Fig. 2.14 Total anomalous pulmonary venous return to the superior vena cava. Cardiac silhouette has a “snowman” appearance formed by two round structures; the heart forms the round structure below and the dilated vertical vein, innominate vein and the superior vena cava forming the round structure above that of the heart. *IV* innominate vein, *VV* vertical vein

Lateral View

This view may demonstrate the congested pulmonary vasculature but is not otherwise helpful.

Transposition of the Great Arteries

AP View

Generally normal at birth, the oval/egg-shaped cardiac silhouette combined with the front-to-back orientation of the aorta and pulmonary artery leads to a narrowed mediastinum resulting in the classic “egg on a string” appearance. Over time, chest X-ray may demonstrate an enlarged cardiac silhouette with a marked increase in pulmonary vasculature.

Lateral View

This may show an increase in pulmonary vascularity.

<http://www.springer.com/978-1-4419-7993-3>

Heart Diseases in Children

A Pediatrician's Guide

Abdulla, R.-i. (Ed.)

2011, XXII, 486 p. 165 illus., 134 illus. in color.,

Softcover

ISBN: 978-1-4419-7993-3