

Mark E. Easley, Husam H. Darwish,
Douglas W. Schreyack, James K. DeOrio,
and Hans-Jörg Trnka

2.1 Background

In general, moderate to severe hallux valgus deformity with metatarsus primus varus demands correction with a first metatarsal shaft osteotomy; in such deformity, distal osteotomies are associated with a high recurrence rate. Several different first metatarsal shaft osteotomy patterns continue to be performed, with the particular technique based on surgeon preference (Table 2.1) Typically, a distal soft-tissue procedure is performed in conjunction with a first metatarsal shaft osteotomy. The distal soft-tissue procedure may be approached via a separate dorsal first webspace approach or through the medial midaxial incision over the first metatarsophalangeal (MTP) joint that is used for the medial capsulorrhaphy and medial eminence resection.

While first metatarsal shaft osteotomies are indicated for symptomatic moderate to severe hallux valgus, several precautions and contraindications should be considered (Table 2.2). The proximal crescentic¹⁻⁵ and closing wedge osteotomies are performed through a dorsal approach, the proximal chevron, opening wedge, long oblique, and scarf osteotomies are done from the medial aspect of the proximal first metatarsal. Several authors have suggested that dorsiflexion malunion is less likely to occur with proximal osteotomies done from the medial aspect of the first

metatarsal when compared to those performed via the dorsal aspect. Most proximal first metatarsal osteotomies require full transection of the first metatarsal; the opening and closing wedge procedures maintain lateral and medial cortical hinges, respectively. In contrast to most shaft osteotomies that rotate the distal fragment to correct the 1–2 intermetatarsal (IMA), the scarf and proximal chevron osteotomy translate the distal fragment laterally. While some rotation can be added to the scarf and proximal chevron, the translation avoids the increase in the distal metatarsal articular angle (DMAA), or proximal articular set angle (PASA), observed with shaft osteotomies that rely on rotation to correct the IMA. For all proximal osteotomies combined with a distal soft-tissue procedure, potential complications include recurrence, hallux varus, first MTP joint stiffness, malunion, nonunion, and infection.

2.2 Proximal Crescentic Osteotomy

2.2.1 Overview

The proximal crescentic osteotomy for correction of hallux valgus associated with metatarsus primus varus was popularized by Mann.⁶ Unique to the proximal crescentic osteotomy is the use of a crescentic saw blade, and most surgeons direct the convex aspect of the blade proximally. A commonly cited complication of the proximal crescentic osteotomy is dorsiflexion malunion.^{3,6,7} Recently, Jones et al.⁷ described a technique to aid surgeons in properly orienting the crescentic saw blade in the coronal plane to minimize the risk of initial dorsiflexion malpositioning.

M.E. Easley (✉)
Department of Orthopaedics, Duke University,
3116 N. Duke St., Durham, NC 27704, USA
e-mail: easle004@mc.duke.edu

Table 2.1 Metatarsal shaft osteotomies

Type of osteotomy	Approach	Method of IMA correction
Proximal crescentic	Dorsal	Rotation
Proximal chevron	Medial	Translation and rotation
Opening wedge	Medial	Rotation
Ludloff	Medial	Rotation
Mau	Medial	Rotation
Closing wedge	Dorsal	Rotation
Scarf	Medial	Translation but rotation possible

2.2.2 Surgical Technique

The proximal crescentic metatarsal osteotomy is performed through a dorsal longitudinal incision over the dorsal aspect of the proximal metatarsal, starting at the first tarsometatarsal (TMT) joint and extending 3 cm distally. The extensor hallucis longus (EHL) tendon and dorsomedial sensory nerve to the hallux must be protected. The osteotomy is performed 1 cm distal to the first TMT joint, and the screw used for fixation is started 1 cm distal to the osteotomy (Fig. 2.1). The crescentic blade is positioned neither perpendicular to the plantar foot nor metatarsal, but ideally approximately halfway between these two positions (Fig. 2.2). To limit the chance of dorsiflexion malunion, the saw must be directly in line with the longitudinal axis of the metatarsal; there is a tendency for the leg (and first metatarsal) to externally rotate, thus causing the saw to be exter-

nally rotated relative to the metatarsal. The osteotomy is performed by moving the saw in a medial to lateral direction. With a wide metatarsal, the cut may be incomplete. It is preferable to complete the cut laterally with the crescentic blade and then using a straight saw or osteotome to complete the osteotomy medially; attempting to complete the cut laterally with a separate saw puts the communicating artery that passes between the first and second metatarsal bases at risk (Fig. 2.3).

Correcting the osteotomy is technically demanding. Using a freer the proximal fragment must be forced to its full medial excursion at the first TMT joint. The distal fragment is then rotated laterally along the crescent-shaped osteotomy to reduce the 1–2 IMA while avoiding dorsiflexion of the distal fragment. The osteotomy is provisionally secured with a guide pin for a cannulated screw placed 1 cm distal to the osteotomy. (Proper position of this guide pin is facilitated by placing it prior to making the osteotomy.) The angle of the guidepin is at approximately 50° relative to the metatarsal shaft so that its screw will be plantar in the proximal fragment and not violate the first TMT joint. We routinely obtain fluoroscopic confirmation of the 1–2 IMA correction and guidepin position and use a countersink over the guidepin to create a relief area for the cannulated screw's head (to limit the risk of fracturing the dorsal cortex of the distal fragment). In the event of instability, despite compression of the osteotomy's large contact area, a small plate may be used. Some surgeons routinely use plate fixation for the proximal crescentic osteotomy.

Table 2.2 Precautions and contraindications

Precaution/contraindication	Significance	Alternative
First MTP joint arthritis	Correcting hallux valgus will not resolve first MTP joint symptoms	First MTP joint arthrodesis
First MTP joint stiffness	Correcting hallux valgus will not resolve, may worsen first MTP joint stiffness	First MTP joint arthrodesis
Inflammatory arthritis	Associate with progressive deformity despite hallux valgus correction	First MTP joint arthrodesis
First ray hypermobility	In select cases, recurrence may develop despite shaft osteotomy due to first TMT joint instability; however, most shaft osteotomies maintain correction even in the face of presumed first ray hypermobility (Kim)	Modified Lapidus procedure
Narrow first metatarsal shaft	With some shaft osteotomies, surface contact of osteotomies may be suboptimal after correction, leaving the osteotomy unstable	Consider alternative osteotomy or modified Lapidus procedure
Increased DMAA (PASA)	Shaft osteotomies that rotate to correct 1–2 IMA tend to further increase the DMAA (PASA)	Consider combined shaft and distal metatarsal osteotomies to correct 1–2 IMA and DMAA (PASA) or choose an osteotomy that translates rather than rotates to correct the IMA

Fig. 2.1 Proximal crescentic osteotomy. Diagram of the first metatarsal shaft demonstrating the metatarsocuneiform joint. Note the osteotomy site and angle of the saw blade. Also note the screw insertion site (From Mann and Mann.⁸ Used with permission)

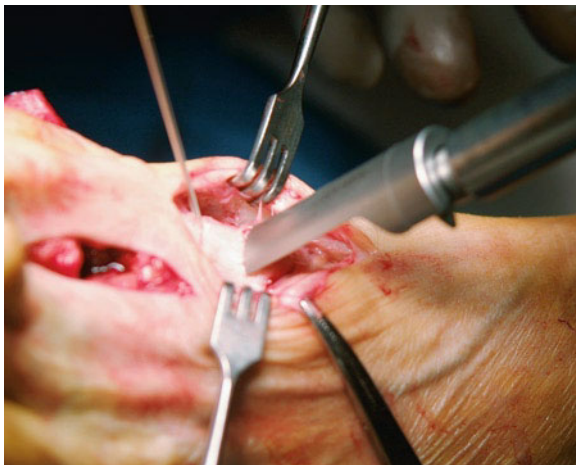
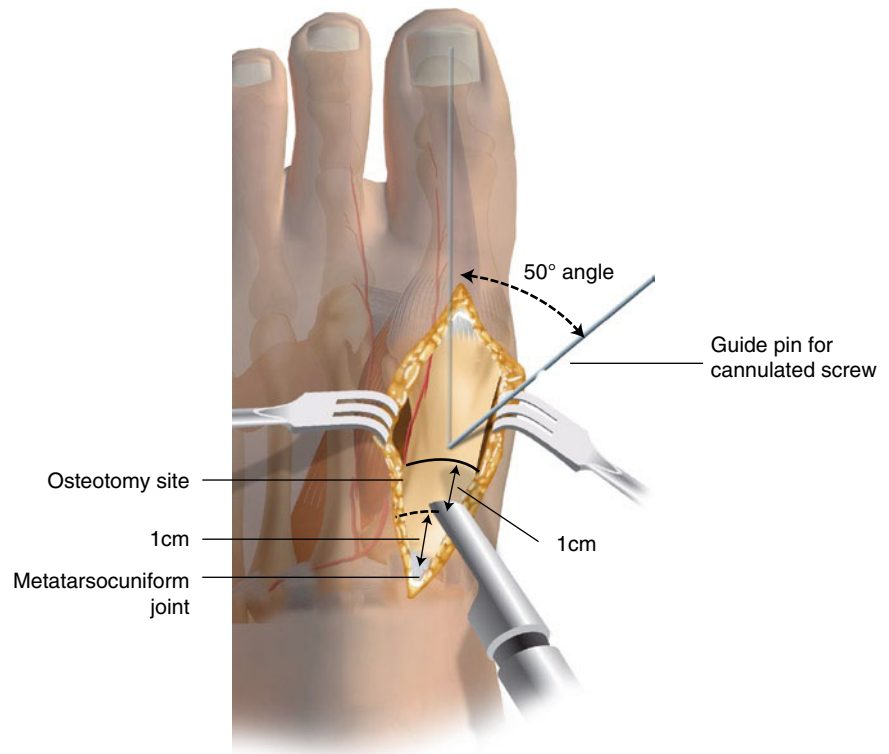


Fig. 2.2 Proximal crescentic osteotomy. The osteotomy is performed with a crescent-shaped saw blade (From Mann and Mann.⁸ Used with permission)

2.2.3 Outcomes

Several case series (Level IV evidence) at intermediate to long-term follow-up reported favorable radiographic correction, patient satisfaction, and improvement in functional outcomes with the proximal crescentic

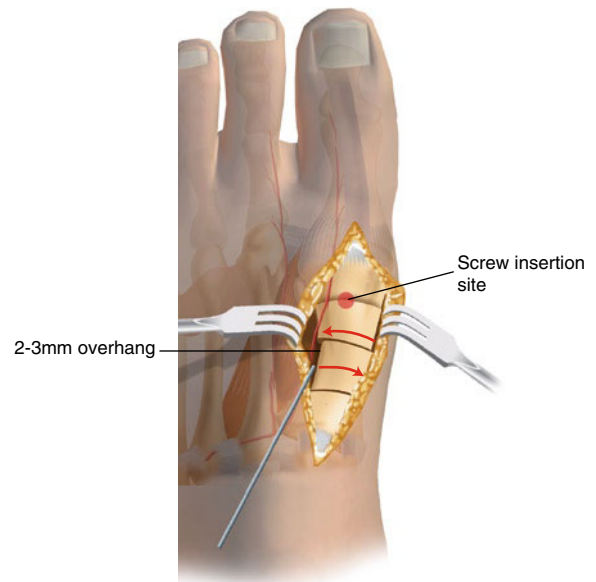


Fig. 2.3 Proximal crescentic osteotomy. Diagram of the osteotomy site. The surgeon's hand is pushing the metatarsal shaft in a lateral direction. The Freer elevator is pushing the metatarsal base in a medial direction. Note the 2–3 mm overhang on the lateral aspect of the osteotomy site (From Mann and Mann.⁸ Used with permission)

osteotomy.^{6,9,10} Patient satisfaction rates are consistently greater than 90%. For studies that report the American Orthopaedic Foot and Ankle Society (AOFAS) hallux metatarsophalangeal (MTP)–interphalangeal (IP) joint score, the mean preoperative score improved from 58 to 91 points. For these studies, the mean IMA improvement ranged from 6° to 10°. Chow et al., in a study of 32 proximal crescentic osteotomies in 26 patients noted that the favorable results are maintained from average follow-up of 2.7 years to average follow-up of 8 years, with patient satisfaction remaining stable from 96% to 92%, respectively.⁹ A prospective randomized comparison (Level II evidence) of the proximal crescentic and proximal chevron osteotomies suggested favorable radiographic correction and clinical outcomes for both procedures, with AOFAS outcome scores and radiographic correction of HVA and IMA improving significantly at an average follow-up of 24 months (proximal crescentic) and 20 months (proximal chevron).³ Dorsiflexion malunion was observed in 17% of the proximal crescentic cohort. Mann et al., in one of the original articles describing this procedure, noted dorsiflexion malunions in 28% of cases.⁶ Many of these dorsiflexion malunions were based on radiographic criteria and bore no clinical significance. Similarly, none of the 12% of patients with radiographically appreciable hallux varus was symptomatic. A comparative study of the proximal crescentic and Mau osteotomies (Level III), with short follow-up and a limited number of patients in the proximal crescentic cohort, suggested that the two techniques afforded similar outcomes but that the crescentic osteotomy was fraught with a higher complication rate.¹¹ The consistently favorable results from several case series and one Level II evidence study determine a Grade B recommendation for the use of the proximal crescentic osteotomy in the surgical management of hallux valgus.

2.3 Proximal Chevron Osteotomy

2.3.1 Overview

The proximal chevron osteotomy, first reported in the orthopedic literature by Sammarco et al.¹² relies not simply on lateral translation of the distal fragment, as with the distal chevron procedure, but concomitantly incorporates an opening wedge principle. The apex of the osteotomy is directed distally. The large contact area

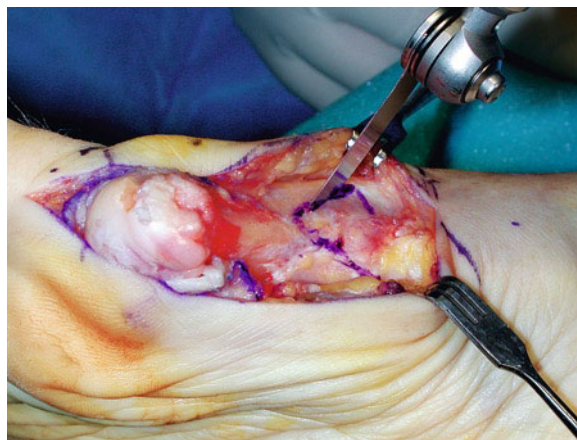


Fig. 2.4 Proximal chevron osteotomy. The osteotomy is marked with the apex approximately 2 cm from the first TMT joint and directly distally

is relatively stable, and recommended fixation is with a combination of a screw and a Kirschner wire, two screws, or a plate. The procedure has been described using a single- or two-incision technique.^{12,13}

2.3.2 Surgical Technique

We perform this osteotomy through a longitudinal medial midaxial incision. The medial dorsal and plantar sensory nerves to the hallux and EHL tendon must be protected. Approximately 2 cm distal to the first TMT joint, we mark the apex of the osteotomy (Fig. 2.4). The limbs of the osteotomy are marked at 60° to one another, extending from the apex proximally. The osteotomy is performed using a microsagittal saw, keeping both cuts in the same plane when viewed from the medial aspect, but at 60° to one another. Next, we pull the proximal fragment medially with a towel clamp while translating the distal fragment laterally (Fig. 2.5). In addition to translation, an opening wedge effect is created to optimize correction of the 1–2 IMA. The distal fragment is then slightly plantarflexed relative to the proximal fragment, even leaving a slight gap on the plantar aspect of the osteotomy to be bone grafted with bone resected from the medial prominence that is created at the osteotomy site (Fig. 2.6). In our hands, this technique modification tends to avoid dorsiflexion of the distal fragment. We place a provisional K-wire from the proximal fragment across the osteotomy, crossing the first TMT joint if necessary to stabilize the osteotomy while keeping the provisional fixation out of the way of definitive fixation.

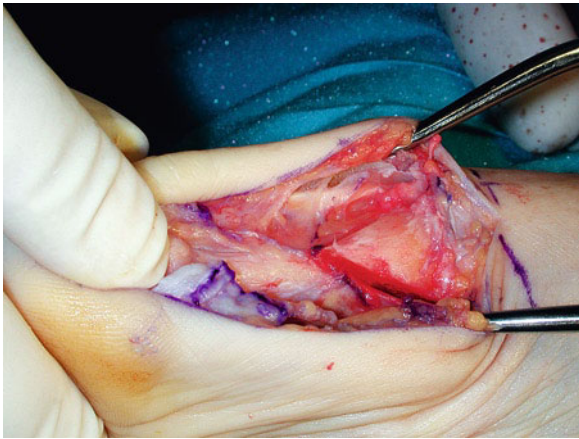


Fig. 2.5 Proximal chevron osteotomy. After completion of the osteotomy, the distal fragment is translated laterally and slightly rotated to correct the IMA

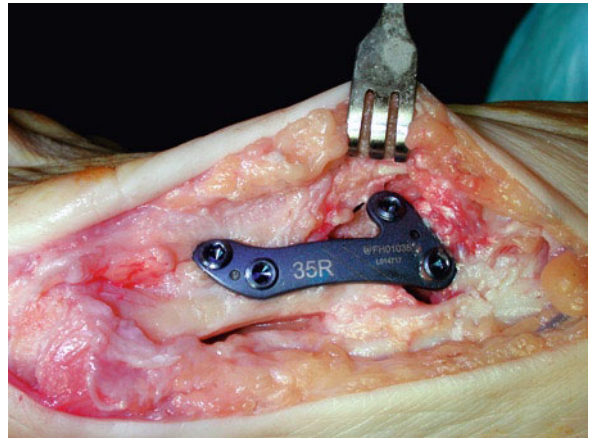


Fig. 2.7 Proximal chevron osteotomy. With the medial prominence resected, fixation with a medial locking plate is relatively simple, creating a stable osteotomy and permitting early weight-bearing

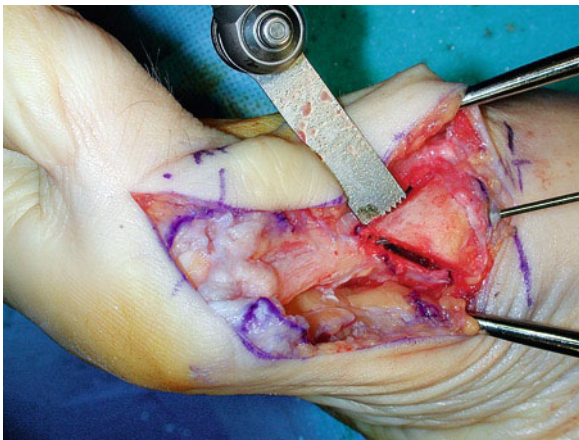


Fig. 2.6 Proximal chevron osteotomy. The osteotomy is provisionally pinned and the medial prominence is resected. Note the slight gap at the plantar limb of the osteotomy, a position that avoids dorsiflexion of the distal fragment

Fluoroscopy confirms that the 1–2 IMA is adequately corrected. We prefer to use a medial locking plate once the medial prominence is shaved and used to bone graft the plantar osteotomy (Fig. 2.7).

2.3.3 Outcomes

Several case series (Level IV evidence),^{12–16} one nonrandomized comparative study (Level III evidence)¹⁷ and one prospective, randomized comparative study (Level II evidence)³ suggest favorable radiographic correction, high rates of satisfaction, and significant improvements

in the functional outcomes with the proximal chevron osteotomy at intermediate follow-up. The average improvement in the IMA ranged from 6° to 7°, mean AOFAS hallux – IP joint scores consistently exceeded 85 points, and patient satisfaction was 83–93% or greater. In the Level II investigation comparing the proximal chevron and crescentic osteotomies, healing time was shorter and the tendency for first metatarsal shortening was less for the proximal chevron cohort.³ Dorsiflexion malunion was observed in 0% and 17% for the proximal chevron and crescentic cohorts, respectively. The Level III evidence comparison of consecutive series of proximal chevron and Ludloff osteotomies demonstrated equal clinical and radiographic outcomes.¹⁷ Taking the limited but favorable Level IV evidence and the positive Level II and III evidence into consideration, a Grade B recommendation for the use of the proximal chevron osteotomy in the operative management of hallux valgus can be made.

2.4 Opening Wedge Proximal First Metatarsal Osteotomy

2.4.1 Overview

The opening wedge proximal first metatarsal osteotomy was largely abandoned after its inception in the 1920s because of concerns of stability and nonunion. With improved fixation techniques, including fixed-angle

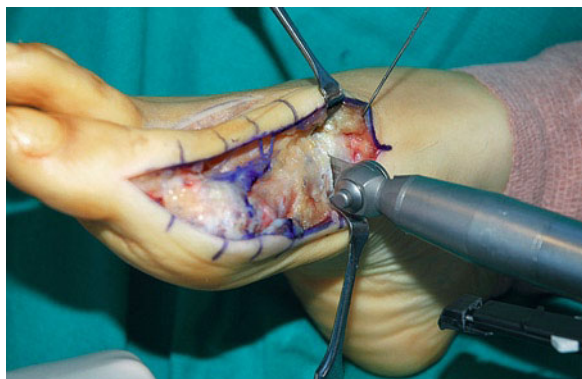


Fig. 2.8 Proximal opening wedge osteotomy. The osteotomy is performed perpendicular to the metatarsal shaft (in the medial to lateral plane) but directed slightly proximally. Note that periosteal stripping is kept to a minimum

plating, the opening wedge has regained acceptance in some centers. An opening wedge proximal first metatarsal osteotomy may modestly lengthen the metatarsal,^{18,19} but more likely it simply maintains length, a feature that may be beneficial when the first metatarsal is relatively short compared to the second metatarsal. Healing rarely is problematic despite the gap that is created; minimal periosteal stripping and an intact lateral cortex allow relatively rapid incorporation of local autograft, allograft, or bone graft substitutes.

2.4.2 Surgical Technique

The proximal metatarsal opening wedge osteotomy is performed from a longitudinal midaxial medial approach. The dorsal and plantar sensory nerves to the hallux and the EHL tendon must be protected. Minimal periosteal stripping is required. The osteotomy is performed using a microsagittal saw oriented perpendicular to the metatarsal. The osteotomy may be oriented between perpendicular to the metatarsal and perpendicular to the floor, but when using a plate with a wedge that determines how far the osteotomy is opened, the plate will not rest congruently on the metatarsal as it would if the osteotomy is performed perpendicular to the metatarsal shaft axis. We prefer to make an oblique osteotomy, starting 1.5–2.0 cm distal to the medial aspect of the first TMT joint and directing the osteotomy proximally and laterally (Fig. 2.8). Under fluoroscopic guidance, the osteotomy approaches the lateral cortex without violating it. A three osteotomy technique allows for gradual opening of the osteotomy without disrupting the lateral cortex. While breaking the lateral cortex is not ideal, the relatively thick

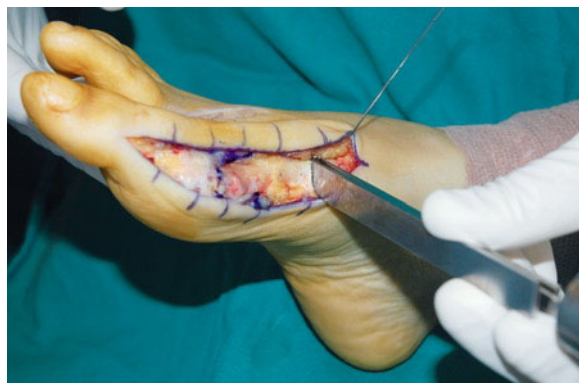

Fig. 2.9 Proximal opening wedge osteotomy. The osteotomy is opened using a “stacked” osteotomy technique rather than levering a single osteotomy

lateral periosteum, the widest part of the proximal metatarsal and obliquity to the osteotomy, allow for satisfactory stabilization. Stacking three osteotomies in succession tends to protect the lateral cortex more than using a single osteotomy and levering the osteotomy into the desired position (Fig. 2.9). In general, 1 mm of opening equals 3° of 1–2 IMA correction; thus, preoperative planning often proves rather precise. Once the desired correction is achieved, one of the osteotomies may be used to “prop” the osteotomy open so that the plate with the optimal wedge can be positioned at the osteotomy. Intraoperative fluoroscopic confirmation of satisfactory correction is recommended at this time. The plate is then secured with two screws distal and two proximal to the osteotomy. Given the obliquity of the osteotomy, one or both of the proximal screws may be placed across the osteotomy to capture the lateral cortex of the distal fragment; this may be performed whether or not the lateral cortical hinge is compromised (). We recommend placing the two screws closest to the osteotomy before placing the ones farthest removed from the osteotomy. We routinely bone graft the osteotomy, either from the medial eminence resection or using local bone graft harvested from the calcaneus (Fig. 2.10).

2.4.3 Outcomes

Several Level IV studies were recently published, with mean follow-up ranging from 11 to 30 months and patient cohorts ranging from 18 to 84 ft.^{18,20–23} The majority of patients reported decreased pain and improved function with mean radiographic improvement in the IMA ranging from 6° to nearly 10°. One study noted a 90% good to excellent patient satisfaction with a mean

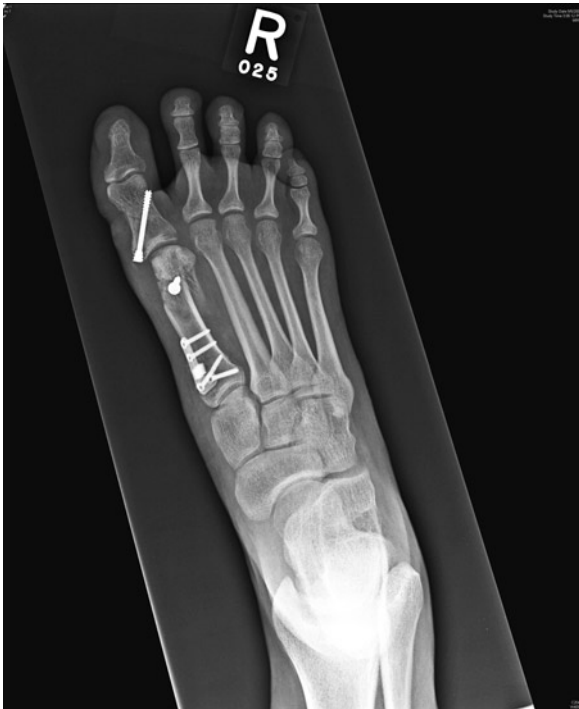

Fig. 2.10 Proximal opening wedge osteotomy. Weight-bearing radiograph of a combination proximal opening wedge osteotomy, biplanar distal chevron osteotomy, and an Akin medial closing wedge proximal phalanx osteotomy at follow-up. The proximal osteotomy tends to increase the DMAA (PASA), thus occasionally necessitating a simultaneous distal correction

improvement in the visual analog scale (VAS) from 5.9 to 0.5.²² A different study noted an average improvement in the AOFAS hallux MTP-IP score from 51 to 87 points.¹⁸ Two other authors, one in vivo and the other in vitro, suggested a modest increase in length of the metatarsal after proximal opening wedge osteotomy.^{18,19} Complications included a low number of delayed or nonunions, hallux varus, and delayed union, with a complication rate that did not appear to exceed that for other shaft osteotomies for hallux valgus correction.

2.5 Proximal Oblique (“Ludloff”) Osteotomy

2.5.1 Overview

The proximal oblique first metatarsal osteotomy was introduced in 1913 by Ludloff, but failed to gain acceptance because the original description did not include fixation. More recently, a modified technique included fixation with two screws. The first screw is placed before the osteotomy is completed, allowing the surgeon to

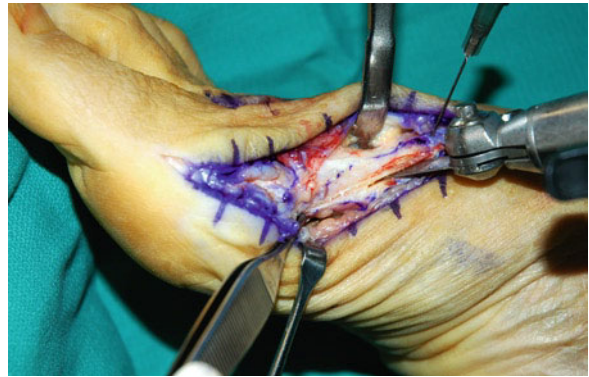

Fig. 2.11 Ludloff osteotomy. The long proximal oblique osteotomy is initially only completed over the dorsal two thirds so that control of the osteotomy is maintained

maintain full control of the osteotomy throughout the procedure. Beischer et al.²⁴ reported the optimal geometric parameters of the modified Ludloff osteotomy in a three-dimensional computer analysis. Specifically, they determined that first metatarsal shortening and rotational malalignment can be controlled if the osteotomy is started dorsally at the first TMT joint and extended distally to the plantar first metatarsal, just proximal to the sesamoid complex. They also explained that first metatarsal elevation is avoided by tilting the osteotomy 10° plantarward, thereby directing the distal fragment plantarward during correction.

2.5.2 Surgical Technique

The Ludloff proximal oblique osteotomy is performed through a medial longitudinal midline incision.²⁵ The dorsal and plantar sensory nerves to the hallux and the EHL tendon must be protected. The osteotomy is performed using a microsagittal saw, starting at the dorsal aspect of the proximal metatarsal, essentially at the first TMT joint. The blade must rest on the medial and not dorsal aspect of the metatarsal. Elevating the saw a few degrees so that the blade is directed approximately 10° plantarward limits the risk of dorsiflexing the distal fragment. We recommend identifying the desired osteotomy exit point on the plantar cortex prior to starting the osteotomy; thereby, the osteotomy will not inadvertently be too long and extend into the metatarsal head-sesamoid complex or too short and compromise the osteotomy’s stability (Fig. 2.11). Only the dorsal two thirds of the osteotomy are completed with the initial cut. A compression screw is then placed across and perpendicular to the completed

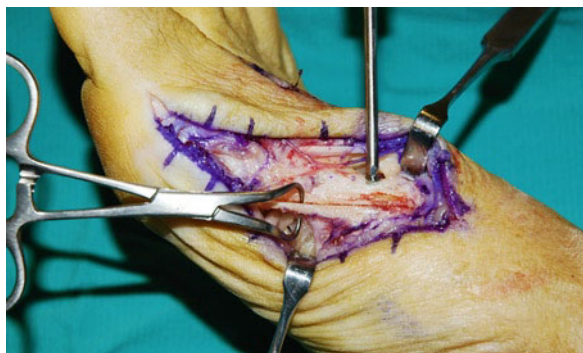

Fig. 2.12 Ludloff osteotomy. After placing the proximal screw (without fully tightening it), the osteotomy is completed over its distal third and then rotated to correct the IMA

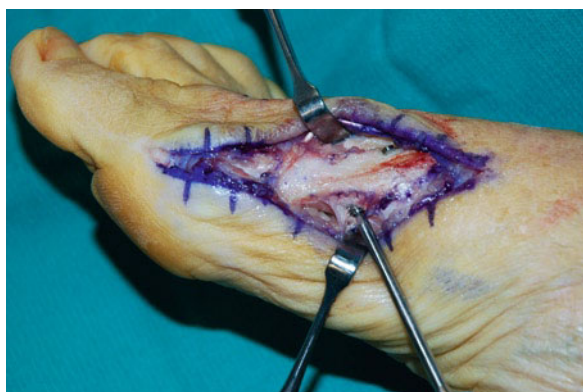

Fig. 2.13 Ludloff osteotomy. The distal screw is placed from plantar to dorsal

portion of osteotomy from dorsal to plantar, tightened enough to demonstrate effective compression, and then backed off slightly. The osteotomy is then completed. We use a towel clip to pull the proximal fragment medially and rotate the distal fragment about the screw to correct the 1–2 IMA. By placing the screw prior to completing the osteotomy, control of the osteotomy is never forfeited (Fig. 2.12). Desired correction is confirmed on fluoroscopy and the screw is tightened. A second screw is placed from plantar to dorsal, again perpendicular to the osteotomy (Fig. 2.13). The medial prominences of the distal and proximal fragments are shaved at the proximal and distal aspects of the osteotomy, respectively.

2.5.3 Outcomes

Orthopedic clinical series (Level IV evidence) of the modified Ludloff osteotomy, combined with a distal soft-tissue procedure evaluated at intermediate follow-up, suggest significant improvement in the AOFAS hallux-IP joint score, favorable patient satisfaction, and significant correction of radiographic hallux alignment.^{26,27} Specifically, the average AOFAS hallux-IP joint score improved from approximately 53–54 points preoperatively to 88–91 points at the most recent follow-up. The mean IMA improvement ranged an average 9°. A recent comparative study (Level III) of the Ludloff and proximal chevron osteotomies suggested equally favorable AOFAS outcome scores and radiographic correction, but with less pain at 6 weeks in the proximal chevron group.¹⁷ Trnka et al.²⁷ cautioned that patients over the age of 60 should maintain a longer period of protected weight-bearing postoperatively as they have a higher rate of delayed union. One study suggested that at short-term follow-up the outcomes for the scarf osteotomy were superior to the Ludloff osteotomy.²⁸ Based on the limited clinical series of level IV papers and one comparative Level III study, a Grade B recommendation exists for the modified Ludloff osteotomy and distal soft-tissue procedure in the operative management of moderate to severe hallux valgus deformity.

2.6 Mau Osteotomy

2.6.1 Overview

The Mau osteotomy's proximal oblique orientation is opposite to that of the Ludloff osteotomy, with proximal plantar and distal dorsal exit points. This osteotomy was popularized by Mau and Lauber in 1926.²⁹ Because of the plane of the osteotomy, the Mau may have greater initial stability with weight-bearing when compared to the Ludloff.

2.6.2 Surgical Technique

Like the Ludloff, the Mau is performed through a medial longitudinal midline incision. The dorsal and plantar sensory nerves to the hallux and the EHL tendon must be

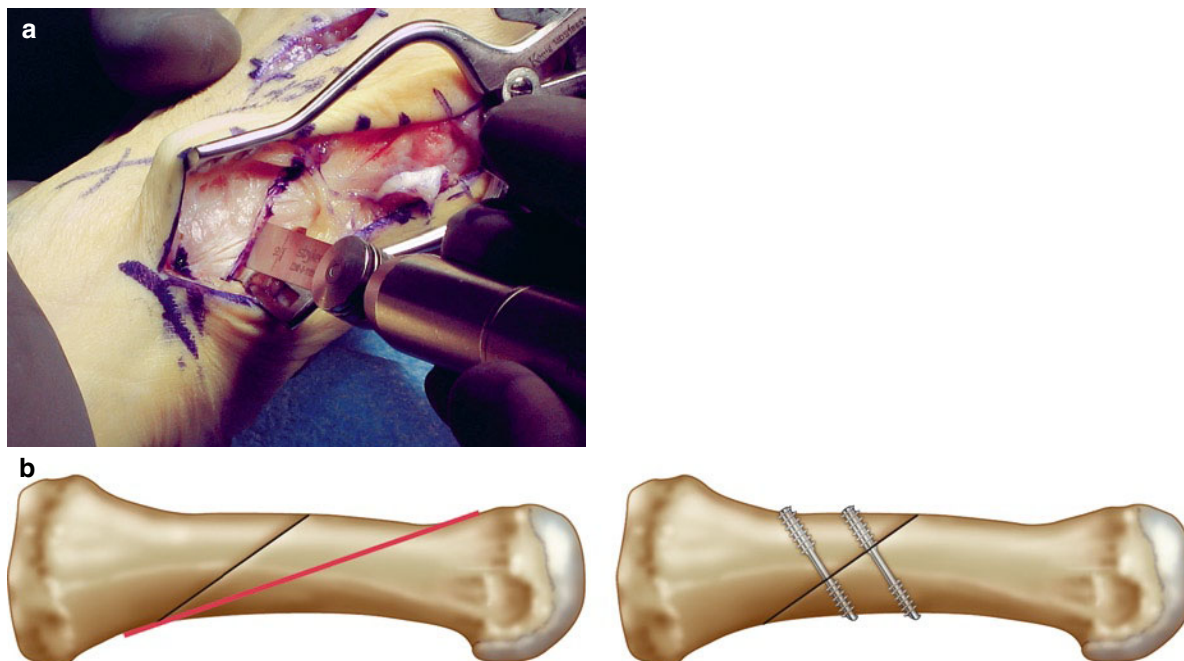


Fig. 2.14 Mau osteotomy. (a) Sagittal saw is placed parallel to the weight-bearing surface of the foot and the osteotomy is completed from proximal-plantar to distal-dorsal. (b) The traditional Mau osteotomy (red line) and the slight modification (black

line). The modified Mau does not incorporate the entire metatarsal shaft as does the traditional Mau osteotomy. The modified Mau osteotomy with two-screw fixation

protected. Minimal periosteal stripping is required. The microsagittal saw is started 1 cm distal to the first TMT joint at the plantar cortex in the medial midaxial plane and continued in a long oblique fashion to the distal dorsal metatarsal cortex, approximately one-half to two thirds of the distance to the metatarsal head (Fig. 2.14). The proximal fragment is controlled with a towel clamp while the distal fragment is rotated (and slightly translated if desired) laterally to correct the 1–2 IMA. Care must be taken to ensure that the distal fragment does not translate proximally leading to inadvertent metatarsal shortening. Fixation is with two cannulated screws placed from dorsal to plantar, perpendicular to the osteotomy. We routinely confirm optimal correction of the 1–2 IMA with the guide pins as provisional fixation prior to committing to the screws. The medial prominence is shaved.

2.6.3 Outcomes

Twenty years ago, the Mau osteotomy was suggested as an alternative to the basilar closing wedge osteotomy.³⁰ More recently, the same authors reported

favorable outcomes of 36 Mau osteotomies in 28 patients, albeit in combination with a Reverdin distal metatarsal osteotomy to correct the DMAA (PASA).³¹ At mean follow-up of 48 months, the AOFAS hallux-IP score ranged from 70 to 95 points and the average IMA correction was 12°. In two separate investigations, another institution suggested a learning curve with the Mau osteotomy.^{11,32} After reporting a relatively high complication rate with 3 recurrences and 5 undercorrections in 24 Mau osteotomies in their initial investigation,³² the same authors demonstrated a relatively low complication rate and favorable results in a second cohort.¹¹ In fact, in the second group, the complication rate was less than that in a comparative group of proximal crescentic osteotomies. Based on the limited clinical series of level IV papers and one comparative Level III study, a Grade B recommendation could be made for the Mau osteotomy and distal soft-tissue procedure in the operative management of moderate to severe hallux valgus deformity, however, with the caveat that one of the investigations was of a Mau-Reverdin double first metatarsal osteotomy.

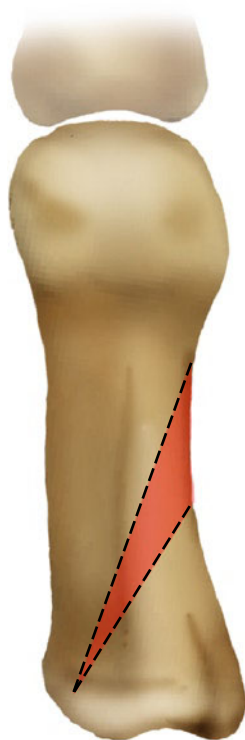


Fig. 2.15 Proximal closing wedge osteotomy. Line diagram showing the closing wedge osteotomy (From Singh and Wilson.³⁸ Used with permission)

2.7 Closing Wedge Proximal First Metatarsal Osteotomy

2.7.1 Overview

A proximal closing wedge osteotomy perpendicular to the first metatarsal longitudinal axis is not universally accepted by orthopedic foot and ankle surgeons because of concerns about complications, including shortening and dorsiflexion malunion. Perhaps with an oblique orientation these risks are diminished, but to date only presented material is available, without peer-reviewed published data in the orthopedic literature. The proximal closing wedge first metatarsal osteotomy is done through a dorsal approach, with the base of the resected segment directed laterally. Despite a medial hinge being maintained, most published series acknowledge a risk of dorsiflexion malunion.³³⁻³⁷ Given the propensity for the osteotomy to shorten, it theoretically is particularly applicable to patients with relatively long first metatarsals.

2.7.2 Surgical Technique

The closing wedge metatarsal osteotomy is performed through a dorsal incision, essentially a proximal extension of the traditional first webspace incision used for lateral release, using the interval between the extensor hallucis brevis and longus. We recommend a long oblique osteotomy, with a laterally based wedge and a more proximal medial apex (Fig. 2.15). The osteotomy should not violate the medial cortex; instead the medial cortical apex serves as a hinge. The osteotomy is performed with a microsagittal saw oriented perpendicular to the weight-bearing axis of the foot, confirmed with an intraoperative simulated weight-bearing test. We routinely make the proximal cut first followed by the distal cut (Fig. 2.16). After removing the laterally based wedge of resected bone, the osteotomy is closed while avoiding dorsiflexion of the distal fragment. We use two guidepins from medial to lateral perpendicular to the osteotomy and fluoroscopically confirm the 1–2 IMA correction. When satisfactory, definitive fixation is with two cannulated screws from medial to lateral using the guidepins placed for provisional fixation.

2.7.3 Outcomes

Few retrospective case series (Level IV evidence) of proximal first metatarsal closing wedge osteotomies and distal soft-tissue procedures with intermediate to long-term follow-up have been reported.^{34,35,37,39} Trnka et al.³⁷ published long-term retrospective results (follow-up range 10–22 years) of basal metatarsal closing wedge osteotomies. Despite good to excellent results in 85% of patients who returned for follow-up, a considerable number of complications occurred, including dorsiflexion malunion, first metatarsal shortening (mean 5 mm), transfer metatarsalgia, and hallux varus. In an intermediate follow-up case series, Resch et al.³⁹ cited a long average time to healing of the osteotomy and a 20% incidence of dorsiflexion malunion associated with transfer metatarsalgia. Granberry and Hickey³⁵ reported a retrospective uncontrolled comparative study (Level III evidence) of proximal first metatarsal closing wedge and Akin osteotomies with or without a distal soft-tissue procedure. Several dorsiflexion malunions were observed in the entire group of patients. In a more recent comparative study of the proximal closing wedge and scarf osteotomies,

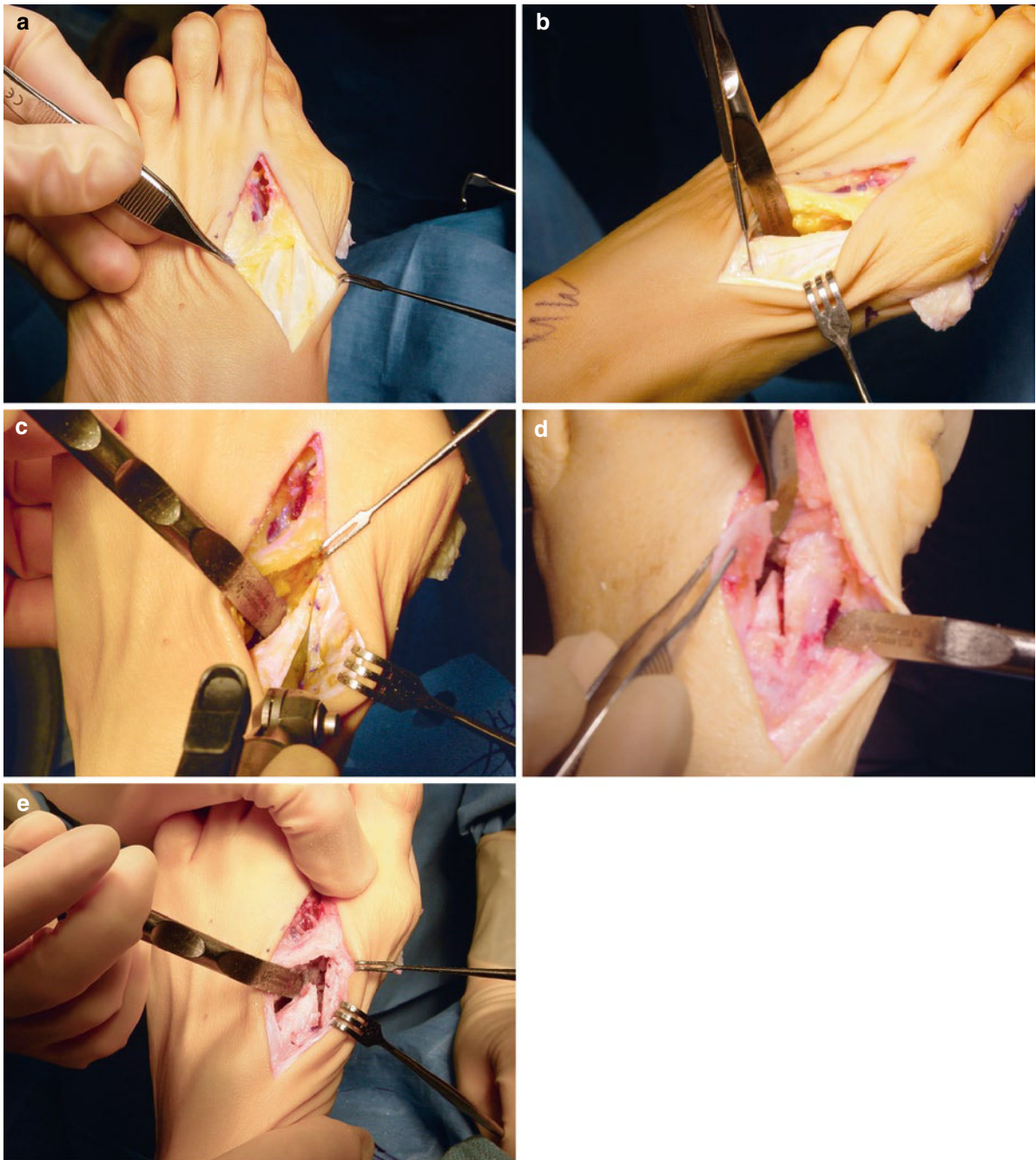


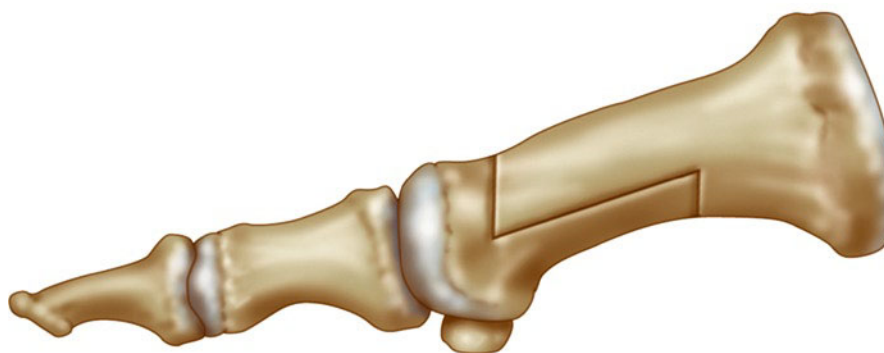Fig. 2.16 Proximal closing wedge osteotomy. (a) The web space incision is extended proximally in a lazy-S shape toward the base of the first metatarsal. The extensor hallucis brevis is identified and protected. (b) The first tarsometatarsal joint is

localized to define the limit of the cut. (c–e) The two osteotomies leave a wedge-shaped segment of bone, which is removed (From Singh and Wilson.³⁸ Used with permission)

greater metatarsal shortening and increase in the DMAA (PASA) were observed with the closing wedge osteotomy.³⁶ Unpublished data of oblique

proximal closing wedge osteotomies in 40 patients (average age 51 years) suggested favorable outcomes, average IMA correction of 7.8°, no symptomatic

Fig. 2.17 Scarf osteotomy. Typical pattern for the scarf osteotomy. Note that the proximal and distal limbs must be parallel or the osteotomy will not translate



dorsiflexion malunions, and average first metatarsal shortening of less than 2 mm, even in severe deformity Singh et al.⁴⁰. With the level III and IV evidence, a Grade B recommendation, can be made for the closing wedge proximal first metatarsal osteotomy in the correction of hallux valgus, with the observation that dorsiflexion malunion and considerable shortening of the first metatarsal are frequent in published series.

2.8 Scarf Osteotomy

2.8.1 Overview

The scarf osteotomy is diaphyseal rather than proximal first metatarsal osteotomy and is commonly used for moderate to severe hallux valgus deformity.⁴¹⁻⁴⁵ The osteotomy's configuration with (1) a distal dorsal limb (virtually identical to that of a traditional distal chevron osteotomy), (2) a long transverse cut, and (3) a proximal limb (similar to the distal extension of the Ludloff osteotomy but with a more proximal exit point on the plantar cortex) confers adequate stability and permits fixation with two screws (Fig. 2.17). It is designed primarily as an osteotomy that laterally translates the distal fragment, but with slight modification of the bone cuts, rotation also can be imparted to the distal fragment to further correct the IMA without increasing the DMAA (PASA). A potential complication unique to the scarf osteotomy is "troughing" (an impaction of the two osteotomy fragments, resulting in loss of metatarsal height).^{46,47}

2.8.2 Surgical Technique

The scarf osteotomy is approached through a medial longitudinal midline incision. The dorsal and plantar

sensory nerves to the hallux and the EHL tendon must be protected. The Z-shaped osteotomy is performed using a microsagittal saw from the medial aspect of the first metatarsal. The distal aspect of the osteotomy uses a dorsal limb that is similar to the dorsal limb of an Austin distal chevron osteotomy. We prefer not to make the longitudinal portion of the osteotomy directly in the midline of the metatarsal. Instead, this longitudinal limb is slightly dorsal where it meets the distal, more vertical limb and more plantar where it intersects with the oblique proximal limb. With this pattern, the proximal intersection of the osteotomy's limbs is protected by ample dorsal bone and less prone to stress fracture. We perform the longitudinal cut first, directing the saw blade slightly plantar from medial to lateral, thereby diminishing the risk of first metatarsal elevation. The two oblique limbs are then performed. The two shorter oblique limbs of the osteotomy should be made in the same plane from medial to lateral to ensure the osteotomy can be laterally translated; should they converge, then translation is hindered. If these shorter limbs are parallel but directed distally, the metatarsal may be slightly lengthened, and if directly proximally, the metatarsal may shorten slightly. The proximal fragment is supported with a towel clamp and the distal fragment is translated laterally. Because of the proximal and distal flares of the metatarsal, considerable translation is possible without forfeiting adequate stability. In fact, the distal fragment's diaphyseal medial cortex may be nearly superimposed on the proximal fragment's diaphyseal lateral cortex. We recommend fixation with two screws from dorsal to plantar (Fig. 2.18). Provisional fixation with the cannulated screws' guidepins should be confirmed with intraoperative fluoroscopic evaluation. Alternatively, a provisional K-wire may be used to confirm appropriate correction, followed by definitive fixation with

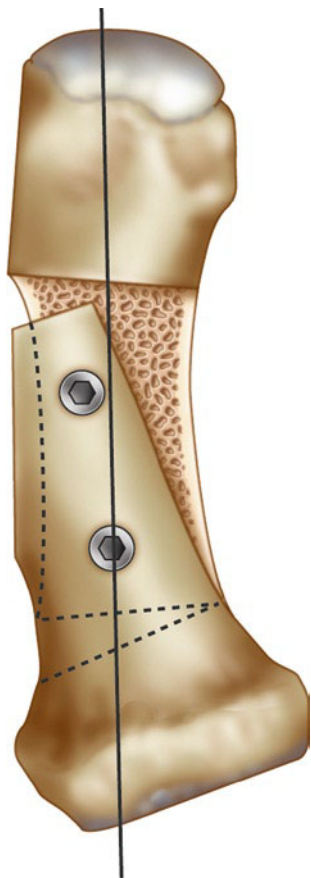


Fig. 2.18 Scarf osteotomy. Fixation for the scarf osteotomy is typically with two dorsal to plantar screws

two solid screws, one placed in lag fashion and the other as a positional screw. The medial eminence is resected in line with the medial metatarsal head.

2.8.3 Outcomes

Several prospective and retrospective case series (Level IV evidence) have reported favorable radiographic correction, high rates of patient satisfaction, and significant improvements in the functional outcomes,^{43,44,48-50} some with equally favorable pedobaric foot pressure analyses.^{45,51} Prospectively, Lorei et al.⁴⁵ observed a redistribution from the lateral forefoot to the first ray following scarf osteotomies in their case series using pedobarographic analysis. (Level IV evidence) Jones et al.⁵¹ prospectively, and Crevoisier et al.⁴³ retrospectively, reported favorable outcomes and radiographic correction using a combination of scarf and Akin osteotomies. (Level IV evidence) Level III evidence suggests that the scarf osteotomy

also demonstrates favorable outcomes when compared to the distal chevron, proximal closing wedge, and Ludloff osteotomies.^{28,36,52}

In contrast, Coetzee et al.⁴⁶ reported poor AOFAS outcome scores with an alarming complication rate in a prospective case series of scarf osteotomies (Level IV evidence). Complications included “troughing” (35%), rotational malunion (30%), metatarsal fracture (10%), and early recurrence of deformity (25%). While many authors have acknowledged the complexity of this osteotomy, several have provided technique tips and experience to accelerate the learning curve in mastering the procedure, including Coetzee in a follow-up surgical strategies article.^{47,53}

Despite one Level IV evidence case series condemning the procedure, the favorable results from numerous case series and a comparative Level III study support a Grade B recommendation for the use of the scarf osteotomy with and without supplemental Akin proximal phalanx osteotomy in the treatment of hallux valgus.

2.9 Biomechanical Testing of Proximal First Metatarsal Osteotomies

Several biomechanical studies have evaluated the initial stability of various metatarsal shaft osteotomies to determine which osteotomies may permit early MTP joint exercises and early postoperative weight-bearing. Acevedo et al.⁵⁴ demonstrated that there was no statistical difference in fatigue endurance between the proximal chevron and Ludloff osteotomies in a cadaver model; in a sawbone model, the proximal chevron was significantly more stable in fatigue endurance testing than the crescentic and scarf osteotomies, but not the Ludloff osteotomy. Trnka et al.⁵⁵ determined that the Ludloff and scarf osteotomies exhibited greater load to failure when compared to the proximal crescentic and proximal chevron osteotomies. In contrast, Shaw et al.⁵⁶ reported superior stability for the offset V (proximal chevron) osteotomy when compared to the scarf, Mau, and Ludloff osteotomies. McCluskey et al.⁵⁷ noted that a proximal chevron osteotomy stabilized with screw fixation tolerated a greater load to failure than the same osteotomy with Kirschner wire fixation and the proximal crescentic osteotomy stabilized with screws. Their findings are supported by Lian et al.⁵⁸ who noted that screw fixation for proximal chevron, crescentic, and long oblique osteotomies of the first metatarsal has superior load to failure characteristics than Kirschner wire or staple fixation. Jung et al.⁵⁹ added that supplemental axial

Kirschner wire fixation significantly enhanced the initial stability of the crescentic and Ludloff osteotomies. In a saw bones model, Jones et al.⁶⁰ reported that plate fixation provided a stronger construct than traditional screw fixation. Plate fixation is being applied to proximal first metatarsal osteotomies with greater frequency,^{9,14,61-63} particularly in opening wedge techniques,^{18,22,64} and studies suggest that there may be mechanical advantages of osteotomy fixation with plates when compared to screws.

2.10 Postoperative Care

Postoperative care is surgeon-specific. Biomechanical testing demonstrates potentially greater initial stability of some osteotomies over others, with some influence of fixation and testing method. However, in general, provided the patient restricts the first metatarsal head from load for the first 4–6 weeks (or until there is radiographic evidence for union), immediate ambulation in a postsurgical shoe is feasible. In our opinion, for patients that cannot comply with unloading of the forefoot, a short leg cast is recommended until radiographic healing is evident. Bunion strapping is according to the surgeon's preference. Bunion strapping alone cannot correct hallux valgus deformity; optimal bony realignment is required.

2.11 Summary

Given that numerous osteotomy techniques are still being employed today suggests that the optimal first metatarsal shaft osteotomy has yet to be devised. Favorable results are reported with all of these technique variations, and it is up to the surgeon's discretion to choose the technique that, in his or her hands, most reliably and reproducibly corrects symptomatic hallux valgus deformity.

References

1. Mann RA. Distal soft tissue procedure and proximal metatarsal osteotomy for correction of hallux valgus deformity. *Orthopedics*. 1990;13(9):1013-1018.
2. Dreeben S, Mann RA. Advanced hallux valgus deformity: long-term results utilizing the distal soft tissue procedure and proximal metatarsal osteotomy. *Foot Ankle Int*. 1996;17(3):142-144.
3. Easley ME et al. Prospective, randomized comparison of proximal crescentic and proximal chevron osteotomies for correction of hallux valgus deformity. *Foot Ankle Int*. 1996;17(6):307-316.
4. Markbreiter LA, Thompson FM. Proximal metatarsal osteotomy in hallux valgus correction: a comparison of crescentic and chevron procedures. *Foot Ankle Int*. 1997;18(2):71-76.
5. Veri JP, Pirani SP, Claridge R. Crescentic proximal metatarsal osteotomy for moderate to severe hallux valgus: a mean 12.2 year follow-up study. *Foot Ankle Int*. 2001;22(10):817-822.
6. Mann RA, Rudicel S, Graves SC. Repair of hallux valgus with a distal soft-tissue procedure and proximal metatarsal osteotomy. A long-term follow-up. *J Bone Joint Surg Am*. 1992;74(1):124-129.
7. Jones C et al. Proximal crescentic metatarsal osteotomy: the effect of saw blade orientation on first ray elevation. *Foot Ankle Int*. 2005;26(2):152-157.
8. Mann RA, Mann JA. Proximal crescent osteotomy. In: Wiesel SW, ed. *Operative Techniques in Orthopaedic Surgery*. Philadelphia: Lippencott Williams & Wilkins; 2011.
9. Chow FY et al. Plate fixation for crescentic metatarsal osteotomy in the treatment of hallux valgus: an eight-year followup study. *Foot Ankle Int*. 2008;29(1):29-33.
10. Zettl R et al. Moderate to severe hallux valgus deformity: correction with proximal crescentic osteotomy and distal soft-tissue release. *Arch Orthop Trauma Surg*. 2000;120(7-8):397-402.
11. Hyer CF et al. A comparison of the crescentic and Mau osteotomies for correction of hallux valgus. *J Foot Ankle Surg*. 2008;47(2):103-111.
12. Sammarco GJ, Brainard BJ, Sammarco VJ. Bunion correction using proximal Chevron osteotomy. *Foot Ankle*. 1993;14(1):8-14.
13. Sammarco GJ, Russo-Alesi FG. Bunion correction using proximal chevron osteotomy: a single-incision technique. *Foot Ankle Int*. 1998;19(7):430-437.
14. Gallentine JW, Deorio JK, Deorio MJ. Bunion surgery using locking-plate fixation of proximal metatarsal chevron osteotomies. *Foot Ankle Int*. 2007;28(3):361-368.
15. Lee WC, Kim YM. Correction of hallux valgus using lateral soft-tissue release and proximal Chevron osteotomy through a medial incision. *J Bone Joint Surg Am*. 2007;89(suppl 3):82-89.
16. Lee KB et al. Outcome of proximal chevron osteotomy for hallux valgus with and without transverse Kirschner wire fixation. *Foot Ankle Int*. 2008;29(11):1101-1106.
17. Choi WJ et al. Comparison of the proximal chevron and Ludloff osteotomies for the correction of hallux valgus. *Foot Ankle Int*. 2009;30(12):1154-1160.
18. Saragas NP. Proximal opening-wedge osteotomy of the first metatarsal for hallux valgus using a low profile plate. *Foot Ankle Int*. 2009;30(10):976-980.
19. Budny AM et al. The opening base wedge osteotomy and subsequent lengthening of the first metatarsal: an in vitro study. *J Foot Ankle Surg*. 2009;48(6):662-667.
20. Cooper MT et al. Proximal opening-wedge osteotomy of the first metatarsal for correction of hallux valgus. *Surg Technol Int*. 2007;16:215-219.
21. Randhawa S, Pepper D. Radiographic evaluation of hallux valgus treated with opening wedge osteotomy. *Foot Ankle Int*. 2009;30(5):427-431.
22. Shurnas PS, Watson TS, Crislip TW. Proximal first metatarsal opening wedge osteotomy with a low profile plate. *Foot Ankle Int*. 2009;30(9):865-872.

23. Smith WB et al. Opening wedge osteotomies for correction of hallux valgus: a review of wedge plate fixation. *Foot Ankle Spec.* 2009;2(6):277-282.
24. Beischer AD et al. Three-dimensional computer analysis of the modified Ludloff osteotomy. *Foot Ankle Int.* 2005;26(8):627-632.
25. Trnka HJ, Hofstaetter SG, Easley ME. Intermediate-term results of the Ludloff osteotomy in one hundred and eleven feet. Surgical technique. *J Bone Joint Surg Am.* 2009;91(suppl 2 pt 1):156-168.
26. Chiodo CP, Schon LC, Myerson MS. Clinical results with the Ludloff osteotomy for correction of adult hallux valgus. *Foot Ankle Int.* 2004;25(8):532-536.
27. Trnka HJ et al. Intermediate-term results of the Ludloff osteotomy in one hundred and eleven feet. *J Bone Joint Surg Am.* 2008;90(3):531-539.
28. Robinson AH et al. Prospective comparative study of the scarf and Ludloff osteotomies in the treatment of hallux valgus. *Foot Ankle Int.* 2009;30(10):955-963.
29. Mau C, Lauber H. Die operative behandlung des hallux valgus. *Dtsch Zeit Orthop.* 1926;197:361-377.
30. Neese DJ, Zelichowski JE, Patton GW. Mau osteotomy: an alternative procedure to the closing abductor base wedge osteotomy. *J Foot Surg.* 1989;28(4):352-362.
31. Neese DJ, Zelent ME. The modified Mau-Reverdin double osteotomy for correction of hallux valgus: a retrospective study. *J Foot Ankle Surg.* 2009;48(1):22-29.
32. Glover JP et al. Early results of the Mau osteotomy for correction of moderate to severe hallux valgus: a review of 24 cases. *J Foot Ankle Surg.* 2008;47(3):237-242.
33. Graziano TA. Proximal closing wedge osteotomy and adductor tenotomy for treatment of hallux valgus. *Foot Ankle.* 1989;10(3):191.
34. Jeremin PJ, DeVincentis A, Goller W. Closing base wedge osteotomy: an evaluation of twenty-four cases. *J Foot Surg.* 1982;21(4):316-323.
35. Granberry WM, Hickey CH. Hallux valgus correction with metatarsal osteotomy: effect of a lateral distal soft tissue procedure. *Foot Ankle Int.* 1995;16(3):132-138.
36. Paczesny L, Kruczynski J, Adamski R. Scarf versus proximal closing wedge osteotomy in hallux valgus treatment. *Arch Orthop Trauma Surg.* 2009;129(10):1347-1352.
37. Trnka HJ et al. Basal closing wedge osteotomy for correction of hallux valgus and metatarsus primus varus: 10- to 22-year follow-up. *Foot Ankle Int.* 1999;20(3):171-177.
38. Singh S, Wilson MG. Closing wedge proximal osteotomy. In: Wiesel SW, ed. *Operative Techniques in Orthopaedic Surgery*. Philadelphia: Lippencott Williams & Wilkins; 2011.
39. Resch S, Stenstrom A, Egund N. Proximal closing wedge osteotomy and adductor tenotomy for treatment of hallux valgus. *Foot Ankle.* 1989;9(6):272-280.
40. Singh SK, Chiodo CP, Wilson MG. A lateral closing wedge proximal osteotomy for adult hallux valgus. Podium presentation at: the AOFAS summer meeting, July 14-17, 2005; Boston.
41. Aminian A, Kelikian A, Moen T. Scarf osteotomy for hallux valgus deformity: an intermediate followup of clinical and radiographic outcomes. *Foot Ankle Int.* 2006;27(11):883-886.
42. Berg RP, Olsthoorn PG, Poll RG. Scarf osteotomy in hallux valgus: a review of 72 cases. *Acta Orthop Belg.* 2007;73(2):219-223.
43. Crevoisier X et al. The scarf osteotomy for the treatment of hallux valgus deformity: a review of 84 cases. *Foot Ankle Int.* 2001;22(12):970-976.
44. Kristen KH et al. The SCARF osteotomy for the correction of hallux valgus deformities. *Foot Ankle Int.* 2002;23(3):221-229.
45. Lorei TJ et al. Pedographic, clinical, and functional outcome after scarf osteotomy. *Clin Orthop Relat Res.* 2006;451:161-166.
46. Coetzee JC. Scarf osteotomy for hallux valgus repair: the dark side. *Foot Ankle Int.* 2003;24(1):29-33.
47. Saragas NP. Technique tip: preventing "troughing" with the scarf osteotomy. *Foot Ankle Int.* 2005;26(9):779-780.
48. Perugia D et al. The scarf osteotomy for severe hallux valgus. *Int Orthop.* 2003;27(2):103-106.
49. Lipscombe S et al. Scarf osteotomy for the correction of hallux valgus: midterm clinical outcome. *J Foot Ankle Surg.* 2008;47(4):273-277.
50. De Vil JJ et al. Scarf osteotomy for hallux valgus deformity: a prospective study with 8 years of clinical and radiologic follow-up. *J Am Podiatr Med Assoc.* 2010;100(1):35-40.
51. Jones S et al. Scarf osteotomy for hallux valgus. A prospective clinical and pedobarographic study. *J Bone Joint Surg Br.* 2004;86(6):830-836.
52. Deenik AR et al. Scarf versus chevron osteotomy in hallux valgus: a randomized controlled trial in 96 patients. *Foot Ankle Int.* 2007;28(5):537-541.
53. Coetzee JC, Rippstein P. Surgical strategies: scarf osteotomy for hallux valgus. *Foot Ankle Int.* 2007;28(4):529-535.
54. Acevedo JI et al. Mechanical comparison of cyclic loading in five different first metatarsal shaft osteotomies. *Foot Ankle Int.* 2002;23(8):711-716.
55. Trnka HJ et al. Six first metatarsal shaft osteotomies: mechanical and immobilization comparisons. *Clin Orthop Relat Res.* 2000;381:256-265.
56. Shaw N II et al. A mechanical comparison of first metatarsal diaphyseal osteotomies for the correction of hallux abducto valgus. *J Foot Ankle Surg.* 2001;40(5):271-276.
57. McCluskey LC et al. Comparison of stability of proximal crescentic metatarsal osteotomy and proximal horizontal "V" osteotomy. *Foot Ankle Int.* 1994;15(5):263-270.
58. Lian GJ, Markolf K, Cracchiolo A III. Strength of fixation constructs for basilar osteotomies of the first metatarsal. *Foot Ankle.* 1992;13(9):509-514.
59. Jung HG et al. Supplementary axial Kirschner wire fixation for crescentic and Ludloff proximal metatarsal osteotomies: a biomechanical study. *Foot Ankle Int.* 2005;26(8):620-626.
60. Jones C et al. Mechanical comparison of two types of fixation for proximal first metatarsal crescentic osteotomy. *Foot Ankle Int.* 2005;26(5):371-374.
61. Venn A, LaValette D, Harris NJ. Re: technique tip. Plate augmentation of screw fixation of proximal crescentic osteotomy of the first metatarsal. Rosenbery, GA; Donley, BG. *Foot Ankle Int.* 2003;24(7): 570-571. *Foot Ankle Int.* 2004;25(8): 605-606; author reply 606.
62. Rosenberg GA, Donley BG. Plate augmentation of screw fixation of proximal crescentic osteotomy of the first metatarsal. *Foot Ankle Int.* 2003;24(7):570-571.
63. Varner KE et al. Screw versus plate fixation of proximal first metatarsal crescentic osteotomy. *Foot Ankle Int.* 2009;30(2):142-149.
64. Hofstaetter SG et al. Biomechanical comparison of screws and plates for hallux valgus opening-wedge and Ludloff osteotomies. *Clin Biomech Bristol Avon.* 2008;23(1):101-108.



<http://www.springer.com/978-0-85729-608-5>

International Advances in Foot and Ankle Surgery

Saxena, A. (Ed.)

2012, XVI, 548 p., Hardcover

ISBN: 978-0-85729-608-5