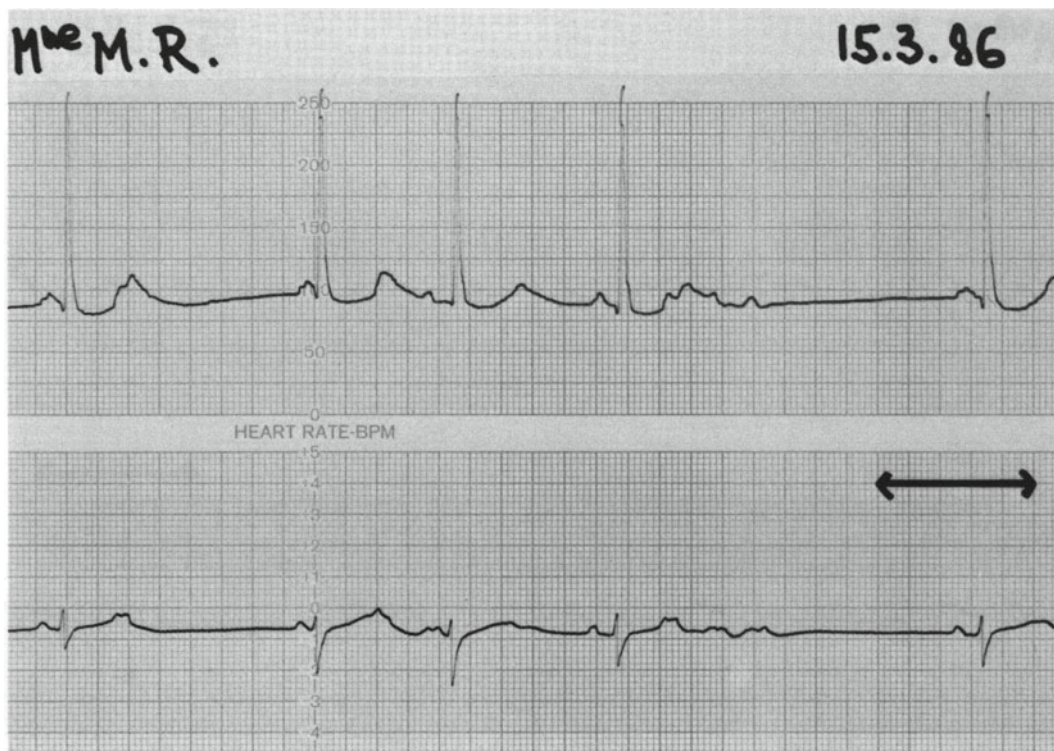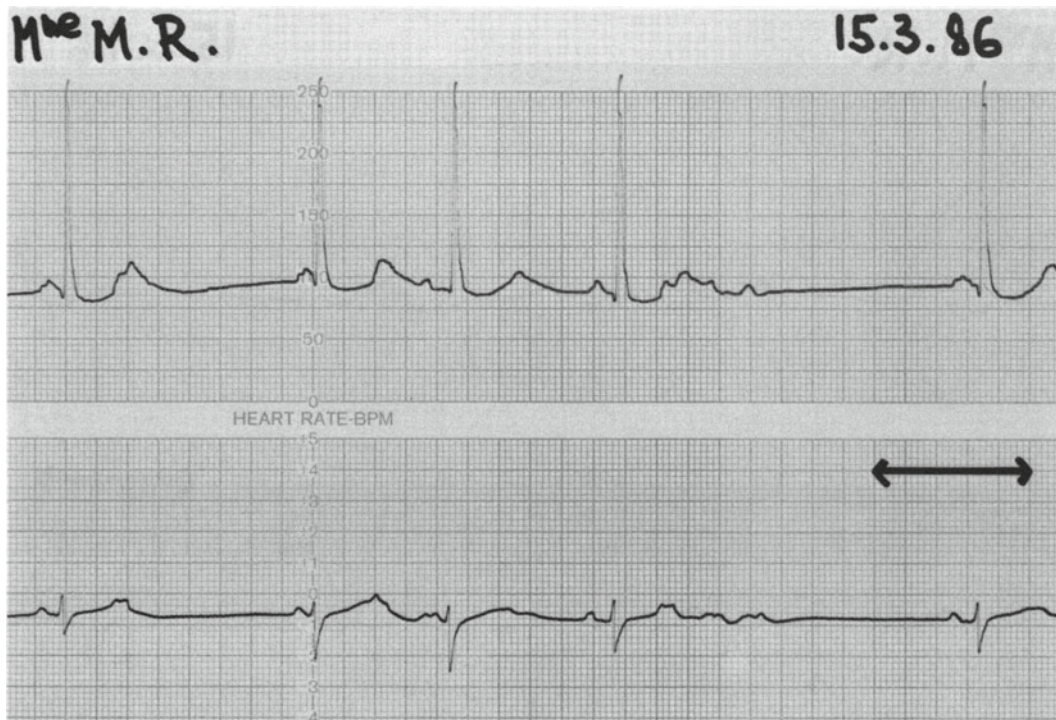


ECG no. 102: Mrs. M.R., 56 years

Palpitations, malaise
ECG Holter recording



ECG no. 102: Mrs. M.R., 56 years

ECG Holter recording

The first complex is a conducted sinus beat. In the T wave of the first QRS, there is a blocked atrial premature beat. The second QRS is preceded by a sinus P wave that is situated too close to the ventricular complex to be conducted. In and shortly after the T wave of the second QRS, two P waves are present, the second of which is conducted to the ventricle. In and after the repolarization phase of the fourth QRS, we find three ectopic P' waves, which are all blocked to the ventricle. The pause is terminated by a conducted sinus beat.

Conclusion

Repetitive atrial ectopic activity, often not conducted to the ventricle, with a short episode of atrial tachycardia.

Practical ECG Holter

100 Cases

Adamec, J.; Adamec, R.; Wellens, H.J.J. (Eds.)

2012, XVI, 225 p. 200 illus., Softcover

ISBN: 978-1-4419-9954-2