

Hair Disorders

Alopecia Classification

Non-Cicatricial (non-scarring) Alopecias

1. Androgenetic alopecia
2. Telogen effluvium
3. Trichotillomania
4. Alopecia areata
5. Postoperative (Pressure-Induced) alopecia
6. Temporal triangular alopecia
 - Patch of alopecia with normal follicles, but almost all are vellus hairs
 - Present at birth or acquired in first decade
7. Lipedematous alopecia (lipedematous scalp)
 - Doubling in scalp thickness
8. Congenital atrichia with papules
 - Very rare condition, previously known as congenital alopecia universalis
 - Fail to regrow hair after shedding their initial growth of hair shortly after birth

Cicatricial (scarring) Alopecia

1. **Group 1: Lymphocytic**
 - Chronic cutaneous lupus erythematosus (DLE)
 - Lichen planopilaris (LPP)
 - Classic LPP
 - Frontal fibrosing alopecia
 - Graham-Little syndrome
 - Brocq's alopecia
 - Central centrifugal cicatricial alopecia (CCCA)

- Alopecia mucinosa
- Keratosis follicularis spinulosa decalvans
 - Corneal dystrophy with cutaneous findings including cicatricial alopecia of the scalp, eyebrows, and eyelashes in association with perifollicular erythema and follicular hyperkeratosis
- 2. **Group 2: Neutrophilic**
 - Folliculitis Decalvans – used by different authors to mean different things; usually means the inflammatory phase of CCCA
 - Dissecting cellulitis
- 3. **Group 3: Mixed**
 - Acne keloidalis
 - Acne necrotica
 - Erosive pustular dermatosis
- 4. **Group 4: Nonspecific**

Reference:

Olsen EA, Bergfield WF, Cotsarelis G, et al. *Summary of North American Hair Research Society (NAHRS)-sponsored workshop on Cicatricial Alopecia. Duke University Medical Center, February 10 and 11, 2001.* J Am Acad Dermatol 2003; 137: 1465–71.

Alopecia Areata

Etiology and Pathogenesis

- Most widely accepted hypothesis is that alopecia areata is a T-cell mediated autoimmune condition that is most likely to occur in genetically predisposed individuals

Clinical Presentation and Types

- Recurrent non-scarring type of hair loss that can affect any hair-bearing area
- Usually asymptomatic, but some experience a burning sensation or pruritus in the affected area
- May have few or many patches. No correlation exists between the number of patches at onset and subsequent severity
- Dermoscopy – yellow “dots” around hair follicles (not seen in other alopecias)
- **Pattern Types**
 - Alopecia areata, **localized** – usually localized and patchy
 - **Circumscribed** – isolated oval patches
 - **Ophiasis** – hair loss localized to the sides and lower back of head
 - **Sisaipho** (ophiasis spelled backward) – hair loss spares sides of back of head
 - **Reticular pattern** – innumerable small patches that coalesce
 - **Alopecia areata, diffuse** – usually see circumscribed patches with alopecia areata, but can sometimes see a diffuse pattern which mimics telogen effluvium
 - **Alopecia totalis** – complete loss of all scalp hair
 - **Alopecia universalis** – complete loss of all body hair
- **Associated Conditions**
 - Thyroid disease
 - **Presence of microsomal antibodies is found in 3.3–16% of patients.** Antibodies can be found +/- symptoms of thyroid disease, but patients with positive autoantibodies have higher incidence of functional abnormalities found on thyroid-releasing hormone tests (26% vs. 2.8%)
 - Vitiligo
 - Atopic dermatitis
 - Collagen vascular diseases have been found in 0.6–2% of patients with AA
 - Emotional stress and psychiatric disease
 - Pernicious anemia, myasthenia gravis, ulcerative colitis, lichen planus, and *Candida* endocrinopathy syndrome also have been associated with AA in some studies
 - Down syndrome

Differential Diagnosis (DDx) – androgenetic alopecia, pseudopelade, syphilis, telogen effluvium, tinea capitis, trichotillomania

Treatment

- Rule out tinea if scale is present. Rule out syphilis if presentation or history suggests
- **Corticosteroids**
 - Topicals – such as Olux foam, Luxiq foam, Temovate scalp soln, clobetasol ointment, Diprolene lotion, Lidex solution, etc.
 - Itching + Alopecia → 2% sulfur ppt + 0.25% menthol in Lidex oint (or aquaphor or 2.5% hydrocortisone). Disp: 60 g tube
 - Intralesionals – first-line in adult patients for localized patches
 - Kenalog concentrations vary from 5–20 mg/mL; q 4–6 weeks
 - Hair growth may be seen for 6–9 months after injection
 - Less than 0.1 mL is injected per site; injections spread out to cover affected areas (approximately 1 cm between injection sites)
 - Avoid reinjecting areas of denting, which usually is sufficient to allow atrophy to revert
 - If you see bleb form while injecting = too superficial; may cause atrophy
- **Topical immunotherapy** – the induction and periodic elicitation of an allergic contact dermatitis by topical application of potent contact allergens
 - Commonly used agents for immunotherapy include **squaric acid dibutyl-ester** (SADBE) and diphencyprone (DPCP)
 - Dinitrochlorobenzene (DNCB) has become less popular as a result of reports that it is mutagenic in the Ames assay (a bacterial assay)
 - A lag period of 3 months usually present between onset of tx and presence of regrowth. The median time to achieve significant regrowth was 12.2 months
 - If no benefit in 12–24 months, discontinue therapy
 - The most common side effect, which is desired, is a mild contact dermatitis (redness, scaling, itching); pigment changes can occur
 - Squaric acid treatment
 - Patient is sensitized directly with 2% concentration on a 2 cm area (scalp or buttock)
 - The following week, a low concentration (0.05%) is applied 3x/week to start
 - The frequency and concentration may be slowly titrated as tolerated
 - Patients advised to avoid light exposure on scalp for 48 h, since light degrades chemical. Patients also advised not to wash the scalp for 48 h

- Anthralin
 - Both short-contact and overnight treatments have been used
 - Anthralin concentrations varied from 0.2–1%; Most → irritant contact dermatitis
 - AE – pruritus, burning, staining of clothes, folliculitis, localized pyoderma, LN
- PUVA – topical and oral
- Tacrolimus – May or may not help
- Cyclosporine – patients relapse within 3 months of discontinuing med; limited use
- Interferon alfa-2 – (1.5 million IU, 3 times per week for 3 week); no benefit in small study
- Dapsone – 50 mg BID was used in a 6-month, double-blind, placebo-controlled study
 - Did show efficacy but many dropped out due to side effects (malaise)
- Minoxidil (Rogaine)
 - Foam less likely to cause irritation than soln b/c no propylene glycol
 - Can be added to other regimens to help facilitate hair growth

Pearls and Pitfalls

- Patients and their families often need extensive counseling about this disorder, especially in pediatric setting
- Worse prognosis = ophiasis, age of onset < 5 years with alopecia totalis or alopecia universalis, association with atopy
- Recommend the National Alopecia Areata Foundation (www.naaf.org)

Alopecia – Androgenetic Type

Etiology and Pathogenesis

- Androgenetic alopecia is postulated to be a dominantly inherited disorder with variable penetrance and expression. However, it may be of polygenic inheritance
- Women who develop balding shortly after puberty are more likely to have a family history for pattern baldness. Women who develop this in the perimenopausal and menopausal phases have contributing genetic and hormonal factors
- Male androgenetic alopecia partially related to dihydrotestosterone (DHT). Testosterone converted to DHT by 5 α -reductase. Type II 5 α -reductase dominates in scalp, beard and chest hair, as well as in liver and prostate. Genetic absence of Type II 5 α -reductase prevents male androgenetic alopecia

Clinical Presentation

- Affects roughly 50% of men and perhaps as many women older than 40 years. As many as 13% of premenopausal women reportedly have some evidence of androgenetic alopecia.
- **Ludwig Pattern**
 - Grade I – minimal widening of part width
 - Grade II – moderate thinning
 - Grade III – significant thinning and widening of part width
- **Hamilton/Norwood Classification** – pattern of balding seen in men, rarely in women
- **Men**
 - Gradual thinning in the temporal areas, producing a reshaping of the anterior part of the hairline. Evolution of baldness progresses according to Norwood/Hamilton classification
 - Associations:
 - Males with androgenetic alopecia *may* have an increased incidence of myocardial infarction
 - Increased incidence of benign prostatic hypertrophy has also been associated
- **Women**
 - Usually present with diffuse thinning on the crown. Bitemporal recession does occur in women but usually to a lesser degree than in men. Women generally maintain a frontal hairline

Labs

- Females with early onset or severe patterned hair loss could have pathologic hyperandrogenism
 - Check – total and free testosterone, DHEAS, 17-hydroxyprogesterone
- Evaluate for thyroid disease – TSH, free T4
- Evaluate for anemia – CBC + diff, ferritin, TIBC, transferrin sat, total iron
 - A normal CBC does not exclude iron deficiency as a cause of hair loss
 - Check ESR in addition to ferritin. If both elevated, then ferritin may be inappropriately normal as a result of acute inflammation (both are acute phase reactants)

Histology

- Normal *total* number of follicles (about 35 in Caucasians or 20 in AA per 4-mm plug)
- Reduced number of hairs (mixture of terminal and indeterminate) when counted at the dermal/fat junction
- Increased numbers and percentage of vellus and indeterminate hairs when counted at the level of the upper dermis
- Presence of fibrous “streamers” below miniaturized hairs
- Slightly increased telogen count compared with “unaffected” scalp
- Uninvolved scalp (e.g., occiput) appears normal or relatively normal
- No significant inflammation

Treatment

- Minoxidil BID, (2% or 5% soln, 5% foam)
 - Appears to lengthen anagen phase, and may increase blood supply to follicle. Regrowth at vertex > frontal areas; is not noted for at least 4 months. Continue
 - Topical treatment with drug indefinitely; discontinuation of treatment produces rapid reversion to pretreatment balding pattern
 - Women respond better → recommend men’s formulation
- Finasteride (Propecia) 1 mg PO qd
 - 5- α -reductase inhibitor which inhibits type 2
 - Can produce ambiguous genitalia in developing male fetus. Don’t use in young women who may get pregnant
 - Affects vertex balding > frontal hair loss. Must be continued indefinitely because discontinuation results in gradual progression of the disorder

- Dutasteride (Avodart) 2.5 mg PO QD – may work better than finasteride
 - [Olsen EA, et al. The importance of dual 5-alpha-reductase inhibition in the treatment of male pattern hair loss: results of a randomized placebo-controlled study of dutasteride versus finasteride. JAAD 2006; 55(6): 1014–23.
 - 5a-reductase inhibitor – inhibits type 1 and type 2
- Females – can try spironolactone, oral contraceptives
 - Evidence exists of an association between androgenetic alopecia, hypertension, and hyperaldosteronism. Spironolactone could play a dual role in treatment
 - Spironolactone = Preg Category X. Need concomitant birth control
 - Oral contraceptives helpful if hyperandrogenism present (to suppress ovarian androgen production)
- Hair transplantation and scalp reduction

Pearls and Pitfalls

- Finasteride will decrease PSA levels by 40% (men ages 40–49) and 50% (men ages 50–60)
- Finasteride will stop hair loss in 90% of men and cause regrowth in 65%. Continued therapy need to see benefits

Alopecia – Brocq’s Alopecia

Etiology and Pathogenesis

- Brocq’s Alopecia (or Pseudopelade of Brocq) is felt to be the end stage of several different forms of scarring alopecia, especially lichen planopilaris and chronic cutaneous lupus erythematosus. Therefore, the cause of pseudopelade of Brocq is linked to the etiology of the underlying skin disease
 - If a definitive diagnosis of DLE, LPP, or another condition can be made based on clinical, histologic, or immunofluorescent features, then the term pseudopelade of Brocq cannot be used

Clinical

- Lesions are discrete, randomly distributed, irregularly shaped, and often clustered in patches on the scalp; asymptomatic
- The individual lesion is hypopigmented (porcelain white is the classic description) and slightly depressed (atrophic)
 - “footprints in the snow” refers to dermal atrophy causing a slight depression below the surrounding normal scalp
- Condition may worsen in “spurts” with periods of activity, followed “dormant” phase
- Unlike the steady disease progression seen in CCCA

Histology – shows a “burnt-out” alopecia. If typical findings of LPP, CCCA or other types of scarring alopecia are found, the diagnosis of Brocq’s alopecia can be excluded

- Decreased number of hairs, especially terminal hairs
- Loss of sebaceous glands
- Residual, “naked” hair shafts surrounded by mild, granulomatous inflammation
- Follicular stela without overlying follicles
- Cylindrical columns of connective tissue at the sites of former follicles

Labs to Consider → ANA if suspect lupus. Rule out systemic causes – anemia, thyroid, etc.

Treatment

- When lesions of pseudopelade of Brocq are burnt out, treatment is neither necessary nor possible. Unfortunately, the condition can reactivate episodically and unpredictably. If active inflammation is present, consider an alternative diagnosis, and potent topical corticosteroids, such as fluocinonide or clobetasol, can be tried

References:

- (1) Sperling LC. An Atlas of Hair Pathology with Clinical Correlations. New York: Parthenon, 2003.
- (2) Sperling LC. Alopecias. In: Bologna, Jorizzo, Rapini (eds). Dermatology, 2nd edition. Spain: Mosby Elsevier, 2008: 997–8.

Alopecia – Central Centrifugal Cicatricial Alopecia (CCCA)

Etiology and Pathogenesis

- The most common form of scarring alopecia in African-Americans; Females: Males is 3:1
 - Average age of presentation – 36 for women, 31 for men
 - Virtually all women with CCCA are using or have used chemical hair relaxers, but few men have used anything except pomades
 - Progression of the disease even after all chemical tx (if any) are discontinued
 - Patients may be predisposed to follicular damage b/c of premature desquamation of the inner root sheath
- CCCA=Recently coined term used to incorporate several variants of inflammatory, scarring alopecia. The entities grouped under CCCA include *pseudopelade* (not Brocq's pseudopelade), the *follicular degeneration syndrome*, and *folliculitis decalvans*. As variants of CCCA, they have the following features in common:
 - Chronic, progressive, with eventual spontaneous "burn out" after years
 - Predominantly centered on the crown or vertex
 - Progress in a symmetrical fashion, with the most active disease activity occurring in a peripheral zone of variable width, surrounding a central zone of alopecia
 - They show both clinical and histological evidence of inflammation in the active, peripheral zone

Clinical Presentation

- Symptoms may be mild or absent; most note only mild, episodic pruritus or tenderness of involved areas
- Scarring alopecia
 - The follicular ostia between remaining hairs are obliterated and the scalp is smooth and shiny (evidence of scarring)
 - A few isolated hairs may have tufting; "Baby doll hair"
- Early or mild disease → partially bald patch only a few cm in diameter
- Long-standing or severe disease → can result in hair loss covering entire crown of scalp
- "Transitional zone" – few inflammatory, follicular papules
- Even "normal" scalp skin can have foci of alopecia and an occasional follicular papule or perifollicular scaling
- Pustules come and go – likely related to bacterial superinfection and/or immune response to degenerating follicular components

DDx – folliculitis decalvans (for those who feel this is a separate entity), tinea capitis/kerion, true bacterial infection of scalp

Histology

- Biopsy the peripheral, partially alopecic fringe; note – *involved* follicles are selectively *destroyed*, with sparing of the relatively normal follicles
- **Premature desquamation of the inner root sheath** – most distinctive and earliest finding; can be found even in normal-appearing scalp skin
- As disease progresses ...
 - Eccentric epithelial atrophy (thinning) with hair shafts in close proximity to the dermis
 - Concentric lamellar fibroplasias (onion skin-like fibrosis) of affected follicle
 - Variably dense lymphocytic perifollicular inflammation primarily at upper isthmus and lower infundibulum
 - Occasional fusion of infundibula (polytrichia)
 - Later, total destruction of hair shaft

Treatment

- Short course of corticosteroids can temporarily eliminate purulent component of CCCA
- Relatively noninflammatory disease
 - Combination of long-acting oral TCN (doxycycline, TCN, minocycline) plus potent topical steroid (e.g., clobetasol or fluocinonide) – can be safely maintained for years
- Highly inflammatory disease (“folliculitis decalvans”)
 - PO rifampin + PO clindamycin (both at 300 mg BID) × 10–12 weeks
 - Maintenance therapy such as oral doxycycline plus topical clobetasol should follow
- Some physicians use methotrexate to decrease inflammation

References:

- (1) Sperling LC. An Atlas of Hair Pathology with Clinical Correlations. New York: Parthenon, 2003.
- (2) Sperling LC. Alopecias. In: Bologna, Jorizzo, Rapini (eds). Dermatology, 2nd edition. Spain: Mosby Elsevier, 2008: 997–8.

Alopecia – Discoid Lupus (DLE)

Etiology and Pathogenesis

- AKA – Chronic cutaneous lupus erythematosus
- One form of cutaneous lupus that often involves the scalp and can commonly cause scarring
- Autoimmune

Clinical Presentation

- Majority of patients with DLE do not have systemic lupus
- Alopecia, erythema, epidermal atrophy and dilated, plugged follicular ostia
 - Scales difficult to remove and show spines on undersurface (resembling carpet tacks)
- Central hypopigmentation and peripheral hyperpigmentation are characteristic of lesions in dark-skinned individuals
- Plaques may coalesce to form large, irregular-shaped zones of scarring alopecia
- Lesions commonly involve scalp, ears, face
- < 5% have mucosal involvement

DDx – alopecia areata (initially), lichen planopilaris, central centrifugal cicatricial alopecia, linear morphea, tinea capitis

Labs and Workup – ANA with quantitation, general alopecia labs, biopsy. Occasionally, leukopenia is present

Histology

- Superficial and deep inflammation
- Vacuolar interface alteration of dermal–epidermal junction and at the follicular epithelium
- Increased dermal mucin
- Chronic inflammation (often including plasma cells) of the eccrine sweat glands and erector pili is sometimes present
- Typically, see granular deposits of IgG and C3 (less commonly IgM or IgA) at the dermal–epidermal junction and/or the junction of the follicular epithelium and dermis

Treatment

- Sunscreens with physical blockers (zinc oxide, titanium dioxide)
- Topical and intralesional corticosteroids
- Topical tacrolimus or pimecrolimus may be helpful
- Hydroxychloroquine 200 mg PO BID
- Quinacrine 100 mg PO TID added to hydroxychloroquine regimen (OK to use these together)
- Hyperkeratotic lesions respond well to acitretin
 - Not for use in females of child-bearing potential

Pearls and Pitfalls

- Risk of SCC in long-standing DLE lesions. Consider adding acitretin if this is a recurrent issue
- Be aggressive in treating this condition since scarring is often disfiguring
- Quinacrine may lead to yellowing of the skin

Alopecia – Dissecting Cellulitis of the Scalp

Etiology and Pathogenesis

- AKA – perifolliculitis capitis abscedens et suffodiens
- Part of the “follicular occlusion tetrad” which includes hidradenitis suppurativa, acne conglobata, and pilonidal sinus. Scalp disease often stands alone

Clinical Presentation

- Tends to affect young adult men, especially African-Americans
- Lesions begin as multiple, firm scalp nodules, typically on the crown, vertex and upper occiput. Nodules rapidly enlarge into boggy, fluctuant, oval and linear ridges that discharge purulent material
- Lesions often interconnect, so that pressure on one fluctuant area may result in purulent discharge from perforations several centimeters away
- Despite massive inflammation, there can be surprisingly little pain
- Patients seek help because of hair loss and foul-smelling discharge
- Disease waxes and wanes for years, but eventually leads to dense dermal fibrosis, sinus tract formation, permanent alopecia, and hypertrophic scarring

DDx – tinea capitis (on occasion), highly inflammatory forms of cicatricial alopecia (“folliculitis decalvans”)

Histology

- Very early lesions are seldom evaluated, but may show moderately dense, lymphocytic, perifollicular inflammation surrounding the lower half of the follicle
- Increase in catagen and telogen hairs
- Sebaceous glands may persist well into the course of the disease
- Fully developed fluctuant lesions show perifollicular and mid-to-deep dermal abscesses composed of neutrophils, lymphocytes, and often copious plasma cells
- Eventually – granulation tissue, epithelium-lined sinus tracts, and fibrosis are seen

Treatment

- Rule out tinea capitis
- Culture purulent material, although usually no growth

- Isotretinoin – 0.5–1.5 mg/kg/day until 4 months after achieving a clinical remission
 - Relapses are common
- Intralesional corticosteroids
- Oral antibiotics – such as long-acting TCNs (doxycycline, tetracycline, minocycline)
 - Oral quinolones (such as ciprofloxacin) – successful case reports
- Clindamycin + rifampin, 300 mg PO BID (for each)
- Surgical approaches – ranging from incision and drainage to grafting
- Adalimumab has been successful in some case reports
- Radiation therapy – may be successful in severe, refractory cases
- Oral zinc may be helpful in some cases

Pearls and Pitfalls

- Rare reports of dissecting cellulitis being associated with spondylarthropathy
- SCC can rarely occur in the setting of long-standing disease
- Rare reports of Keratitis–Ichthyosis–Deafness (KID) syndrome being associated with follicular occlusion tetrad

References:

- (1) Sperling LC. An Atlas of Hair Pathology with Clinical Correlations. New York: Parthenon, 2003.
- (2) Sperling LC. Alopecias. In: Bologna, Jorizzo, Rapini (eds). Dermatology, 2nd edition. Spain: Mosby Elsevier, 2008: 997–8.

Alopecia – Folliculitis Decalvans

Etiology and Pathogenesis

- *Staph. aureus* seems to play important role in pathogenesis; can be isolated in almost every case
 - Has been suggested that “superantigens” or cytotoxins that bind to MHC class II molecules may stimulate T cells, but “escape” detection by the host immune system, and play a role in pathogenesis

Clinical Presentation

- Predominantly involves the vertex and occipital area of the scalp
- Initial lesion is an erythematous follicular papule
- Hallmark – development of scarred areas and pustules
- Livid to bright erythema together with yellow-gray scales can be present, especially around follicles; also follicular hyperkeratosis, erosions and hemorrhagic crusts
- Pain, itching, and/or burning sensations
- With progressive disease, develop ivory-white patches of cicatricial alopecia
- Tufting (polytrichia) is a common feature
 - Also seen in several forms of cicatricial alopecia (DLE, LPP, CCCA, acne keloidalis, dissecting cellulitis, pemphigus of the scalp and tinea capitis)

Diagnosis

- Bacterial cultures should be taken from intact pustule or from scalp swab
- A nasal swab should be performed to identify an occult *S. aureus* reservoir
- Skin biopsy of an active lesion
 - One 4-mm punch biopsy which includes subcutaneous tissue – from clinically active area, processed for horizontal sections, and stained with H&E
 - Biopsy should be taken from an active hair-bearing margin of the lesion and has to follow the direction of the hair growth
 - PAS – to rule out fungal organisms
 - Elastin – helpful to identify classic pseudopelade of Brocq
 - Can do DIF if suspicious for DLE

Histology

- Characterized as a neutrophilic primary cicatricial alopecia
- Early lesions
 - Keratin aggregation and a dilatation of the infundibulum in combination with numerous intraluminal neutrophils
 - Sebaceous glands are destroyed early in the process
 - Intrafollicular and perifollicular predominantly neutrophilic infiltrate found
- Advanced lesions
 - Infiltrate may consist of neutrophils, lymphocytes, and numerous plasma cells – extend into dermis and around blood vessels
 - Granulomatous inflammation with foreign-body giant cells are a common finding – believed to result from ectopic pieces of hair shafts
 - Follicular tufts can frequently be found
 - Sinus tracts are NOT found in folliculitis decalvans (in contrast to dissecting cellulitis)

DDx – dissecting cellulitis, acne keloidalis nuchae, erosive pustular dermatosis, acne necrotica varioliformis, deep fungal infection of scalp, DLE, CCCA, lichen planopilaris, pseudopelade of Brocq

Treatment of Folliculitis Decalvans

- Educate patient about hygiene – ok to wear bandanas, caps, hats, hair pieces and wigs – BUT these can be a reservoir for *S. aureus*. All headdresses have to be cleaned with antiseptic diligently and the patient should switch between hairpieces
- Oral antibiotics
 - Relapse is common after stopping ABX; patients often on low-dose ABX for years
 - **Rifampin 300 mg BID over 10–12 weeks** is believed to be the best anti-staphylococcal agent. May also be effective in eliminating carrier state
 - Strongly recommended to **use rifampin in combination with Clindamycin 300 mg BID** to avoid rapid emergence of resistance
 - SE Rifampin – hepatitis, induction of hepatic microsomal enzymes, OCP failure, influenza-like syndrome, hemolytic anemia, thrombocytopenia, interaction with warfarin
 - **Ciprofloxacin** or **Clarithromycin** can alternatively be used in combination with Rifampin
- Topical antibiotics and antiseptics → Combine with oral therapy
 - 2% mupirocin
 - 1% clindamycin
 - 2% erythromycin

- Shampoos
 - Use shampoo with antiseptic cleanser → Teraseptic® cleanser – contains 0.5% triclosan cleanser; can be drying, so use in conjunction with antibiotic ointment
- Topical and Intralesional corticosteroids
 - Can help with the itching, burning, and pain
 - IL Kenalog 10 mg/mL q4–6 weeks
 - Topical class I or II corticosteroids can be used BID
 - Oral corticosteroids
 - Consider PO prednisone only for highly active and rapidly progressing cases
 - *Aggressive regimen* – Prednisolone 20 mg QD tapered over 3 weeks + isotretinoin 40 mg QD, which is reduced to maintenance of 30 mg QD + PO clindamycin 300 mg QD × 6 weeks
- Isotretinoin
 - Limited used in folliculitis decalvans (but works well in dissecting cellulitis)
- Dapsone
 - 50–100 mg PO daily alone or in combination with an antibiotic
 - Long-term tx with 25 mg daily may stabilize the disease
- Isolated reports – Oral zinc sulfate, oral L-tyrosine, laser epilation with Nd:YAG. Careful with scalp surgery → can flare the disease. Proceed with caution

Pearls and Pitfalls

- Websites: www.nahrs.org and www.carfintl.org

Reference:

Otberg N, Kang H, Alzolibani AA and Shapiro J. Folliculitis Decalvans. *Dermatologic Therapy*; 21(4): 238–44.

Alopecia – Lichen Planopilaris (LPP)

Etiology and Pathogenesis

- Etiology not known, but is presumably related to the cause(s) of lichen planus
- Type of alopecia whose clinical course may be insidious or fulminant; pattern of scalp hair loss is highly variable

Clinical Presentation

- Caucasians more often affected than dark-skinned individuals; middle-aged women
- Up to 50% have other findings of lichen planus – nails, skin, oral mucosa
- Most common – several scattered foci of partial hair loss; irregularly shaped and widely scattered over the scalp
- Perifollicular erythema and scaling almost always present
- Pattern of hair loss suggestive of CCCA or pseudopelade of Brocq can also occur
- Can heal with the formation of polytrichia (tufting) – seen with any inflammatory scarring alopecia
- Indolent dz – may be asymptomatic, but itching and tenderness often present
- “Confetti-like” pattern of numerous small and widely distributed lesions is a relatively common clinical variant of LPP
- *Cannot* make diagnosis of LPP based on clinical features alone
- Clinical Variants of LPP
 - **Graham-Little Syndrome** – scarring alopecia of the scalp, loss of pubic and axillary hair, and the rapid development of keratosis pilaris. Rare
 - Considered by some to be a variant of LPP; however ... typical lichen planus lesions are not found and the histological findings are usually not lichenoid
 - **Frontal Fibrosing Alopecia** – Elderly women with progressive hair loss along the anterior hairline and the eyebrows. Histopathology similar to those in LPP
 - Lesions of lichen planus are usually not seen and the lichenoid inflammation does not affect the interfollicular epidermis

Histology

- Band-like infiltrate obscures interface between epidermis and dermis. Vacuolar changes at the interface and wedge-shaped hypergranulosis within affected infundibula is typical
- Often see prominent dyskeratosis with individually necrotic basal keratinocytes

- Colloid or Civatte bodies occasionally found as part of the interface alteration, but less common than in LP of the epidermis
- Inflammation most severe at upper portion of follicle – infundibulum and isthmus – but can extend down follicle
- Perivascular and perieccrine lymphocytic infiltrates (as seen in lupus) are absent in LPP
- Occasionally, interfollicular changes of LP are found – strongly supports a dx of LPP
- Eventually, the infundibulum and isthmus become distended and plugged with keratinous
- Basilar keratinocytes often become pink, flattened, and an artifactual cleft can form b/n epithelium and stroma – late stage of LPP; can be seen in other forms of scarring alopecia
- Follicles eventually replaced by columns of connective tissue
- **Grouped, globular immunofluorescence (especially IgM), especially when found adjacent to the follicular epithelium, is the characteristic pattern in LPP**
 - Note – Lupus has linear deposits of immunoreactants

Treatment

- Difficult condition to treat
- Corticosteroids (topical, intralesional, oral)
- Oral antibiotics with anti-inflammatory properties – doxycycline
- **Hydroxychloroquine**
 - Effective at decreasing signs and symptoms of LPP and FFA even at 6 and 12 months
 - Dose = 200 mg BID
- Mycophenolate mofetil
 - Very effective in small studies, even in patients who have failed many other treatments
 - Improvement typically seen within 6 months
 - Dose = 500 mg BID × 4 weeks, then 1 g BID
- Anecdotal reports of success with ...
 - Cyclosporine, PO
 - Systemic retinoids
 - Low-dose weekly oral methotrexate
 - (Note – the above tx should be used with caution as they themselves may cause some degree of alopecia)
- Some cases can resolve spontaneously, but others often go on for years

Pearls and Pitfalls

- Keep flowchart of patient's signs and symptoms – will help you see if progress is occurring and will help facilitate treatment decisions
 - See JAAD article for example and LPP Activity Index
 - Things to include:
 - Pruritus, pain, burning, erythema, perifollicular erythema, perifollicular scale
 - Pull test – anagen hair? Telogen hair?
 - Spreading?
 - Dimensions/extent?
 - Tufting
 - Atrophy and telangiectasis
 - Pigment changes
 - Other skin changes – skin, nails, mucosa
 - Labs – CBC, AST/ALT/Alk phos, G6PD, Eye exam, BUN/Cr, Blood pressure
 - Cultures and sensitivities
 - Treatments/comments
 - Biopsy
 - Photographs

References:

- (1) Sperling LC. An Atlas of Hair Pathology with Clinical Correlations. New York: Parthenon, 2003.
- (2) Sperling LC. Alopecias. In: Bologna, Jorizzo, Rapini (eds). Dermatology, 2nd edition. Spain: Mosby Elsevier, 2008: 997–8.
- (3) Chiang C, Sah D, Cho BK, et al. Hydroxychloroquine and lichen planopilaris: efficacy and introduction of Lichen planopilaris Activity Index scoring system. J Amer Acad Dermatol 2010; 62(3): 387–92.

Alopecia Mucinosa

Etiology and Pathogenesis

- AKA – Follicular mucinosis. Etiology unknown
- Occurs in three settings:
 - Idiopathic – Usually a benign idiopathic condition in majority of cases involving those younger than age 40; CTCL rarely associated in children but must be followed closely
 - In association with MF/CTCL – In patients older than age 40, alopecia mucinosa may be first sign of CTCL
 - In association with other neoplastic and inflammatory conditions – such as atopic dermatitis or in association with known CTCL

Clinical Presentation

- Inflammatory disorder characterized by follicular papules or infiltrated plaques with scaling, alopecia, and accumulation of mucin in sebaceous glands and the outer root sheaths of hair follicles
- Three morphologic forms:
 - Grouped follicular papules coalescing into rough patches
 - Grouped follicular papules coalescing into scaly plaques
 - Nodular, boggy plaque with overlying erythema and scaling
- Lesions usually measure 2–5 cm in diameter and are typically devoid of hair
- Distribution – face, scalp, neck, shoulders (occasionally on trunk and extremities)

DDx – lichen spinulosus, pityriasis rubra pilaris, tinea, pityriasis alba, granulomatous diseases, and papulosquamous disorders, urticarial-like follicular mucinosis (head/neck on seborrheic background but neither follicular plugging nor alopecia present)

Histology

- Accumulation of mucin within follicular epithelium and sebaceous glands, causing keratinocytes to disconnect
- More advanced lesions → follicles converted into cystic spaces containing mucin, inflammatory cells, and altered keratinocytes. A perifollicular infiltrate of lymphocytes, histiocytes, and eosinophils are seen

Treatment

- Spontaneous healing may occur in idiopathic forms
- Topical and intralesional corticosteroids
- Antimalarials – hydroxychloroquine
- Minocycline
- Indomethacin
- Dapsone
- PUVA or UVA-1 phototherapy
- Oral isotretinoin

Pearls and Pitfalls

- Follow patients closely . Detection of clonal T-cell gene rearrangements does not seem to help differentiate between primary and secondary forms

Alopecia – Telogen Effluvium

Etiology and Pathogenesis

- Interval between precipitating event and the onset of shedding corresponds to the length of the telogen phase, usually 3 months (can be 1–6 months)
- Acute illness – febrile illness, severe infection, major surgery, severe trauma, etc.
- Chronic illness – malignancy (especially lymphoproliferative disorders), systemic lupus erythematosus, end-stage renal disease, liver disease, HIV
- Hormonal changes – pregnancy and delivery (can affect both mother and child), hypothyroidism, and discontinuation of estrogen-containing medications
- Changes in diet like crash dieting, anorexia, low protein intake, and chronic iron deficiency
- Sudden weight loss
- Heavy metals such as selenium, arsenic, and thallium
- Medications –
 - ACE-inhibitors, allopurinol, amphetamines, **anticoagulants**, azathioprine, **beta-blockers (especially propranolol)**, boric acid, chloroquine, iodides, lithium, methysergide, contraceptives, **retinoids (including excess vitamin A)**, **propylthiouracil (induces hypothyroidism)**, carbamazepine, and **immunizations**
- Allergic contact dermatitis of the scalp

Clinical

- Thinning of hair which involves the entire scalp; sometimes in pubic and axillary regions
- Gentle hair pull may be positive for two or more hair shafts per pull → telogen hairs
- Forcible hair pluck (trichogram) → mix of normal anagen and telogen hairs; 20% or more telogen

Labs to Consider (based on history and physical) – CBC+diff, Ferritin, ESR, TIBC, TSH, free T4, RPR, 17-OH-testosterone, DHEA-S, Free and total testosterone, vitamin D

Other Tests

- The patient should be instructed to collect all hairs shed in a 24-h period on a non-shampoo day. Process should be repeated every other week, for a total of three or four collections

- Collections totaling 100 hairs or more in a given 24-h period are indicative of ongoing telogen effluvium. If the collections are performed over several weeks while the telogen effluvium is resolving, the number of hairs collected each time should decrease
- Scalp biopsy (**histology**):
 - Normal total number of hairs and normal number of terminal hairs
 - Increase in telogen count to greater than 20%
 - Absence of inflammation and scarring
 - Telogen count rarely exceeds 50%; greater than 80% inconsistent with telogen effluvium

Treatment

- Assess for etiology: Evaluate medication list, history, precipitating events, thyroid, anemia, etc.
- Minoxidil foam BID (men's)
- Biotin forte (3 mg) or Appearex (2.5 mg biotin)

Pearls and Pitfalls

- A chronic form of telogen effluvium can rarely occur and is a diagnosis of exclusion
- Regrowth takes months to years (in some cases)

Alopecia – Traction Alopecia

Etiology and Pathogenesis

- A form of mechanical, traumatic alopecia. Trauma is usually mild and chronic
- Most cases are caused by hairstyles involving tight braiding or banding of the hair, especially in AAF
- Biphasic form of hair loss
 - Initially the hair loss is temporary, hair regrowth occurs, and the condition behaves like a non-scarring form of alopecia. If excessive traction is maintained for years, the hair loss may eventually become permanent
 - There may be a lag period of a decade or more between the period of traction and the onset of permanent hair loss
 - Many AAF present in their 30s and 40s with a several-year history of persistent, bitemporal, or frontal hair loss
 - These women may deny having worn tight braids since childhood, although often other forms of traumatic styling (e.g., “curlers”) have been employed

Clinical Presentation

- Peripheral or marginal form of alopecia involving the frontal, temporal, and parietal margins of the scalp; pruritus often present
- In girls who wear tight braids, perifollicular erythema and pustule formation may be seen

DDx – Alopecia areata, temporal triangular alopecia, trichotillomania, tinea capitis

Histology

- Early or acute disease
 - Normal size of follicles
 - Total number of hairs (both terminal and vellus) is normal
 - Most prominent finding is ↑ number of catagen and/or telogen hairs
 - Trichomalacia and pigment casts occasionally found
 - Incomplete, disrupted follicular anatomy rarely found
 - No significant inflammation (peribulbar inflammation absent)

- End-stage or “burnt out” disease
 - Marked ↓ in total # of follicles, terminal follicles, with retention of vellus hairs
 - Dermal collagen relatively normal; occ fibrous tracts at sites of former follicles
 - Many or most follicular units still have associated sebaceous glands
 - No significant inflammation (peribulbar inflammation absent)

Treatment and Prevention

- Immediately after traction alopecia is diagnosed, any practices that exert traction on the hair must be discontinued
- Topical steroids can decrease inflammation
- Oral antibiotics that decrease inflammation – TCN, doxycycline, minocycline
- No treatment to reverse late-stage disease

Pearls and Pitfalls

- Patients often present to dermatology with other concerns, but traction alopecia is noted. Take advantage of the teachable moment and gently counsel the patient/parents about this condition
- Parents often deny that hairstyles are “too tight”, so a trial of wearing the hair down until the condition resolves may be helpful
- “Eyebrow test” – if the hairstyle literally raises the child’s eyebrows, it is too tight

References:

- (1) Sperling LC. An Atlas of Hair Pathology with Clinical Correlations. New York: Parthenon, 2003.
- (2) Sperling LC. Alopecias. In: Bologna, Jorizzo, Rapini (eds). Dermatology, 2nd edition. Spain: Mosby Elsevier, 2008: 997–8.

Alopecia – Trichotillomania

Etiology and Pathogenesis

- Impulse control disorder in DSM-IV
 1. Recurrent pulling out of one's hair resulting in noticeable hair loss
 2. An increasing sense of tension immediately before pulling out the hair or when attempting to resist the behavior
 3. Pleasure, gratification, or relief when pulling out the hair
 4. The disturbance is not better accounted for by another mental disorder and is not due to a general medical condition (e.g., dermatologic condition)
 5. The disturbance provokes clinically marked distress and/or impairment in occupational, social, or other areas of functioning
- May encompass a spectrum of patients who pull hair as a habit to those with impulse-control and personality disorder, body dysmorphic disorder, mental retardation or psychosis
 - Contrast to hair pulling which occurs in infancy and early childhood, where the behavior disappears with or without minimal treatment

Clinical Presentation

- Patchy or full alopecia of the scalp (and sometimes eyebrows, eyelashes)
- Areas of alopecia often have bizarre shapes, irregular borders, and contain hairs of varying lengths
- Plucking associated with hair shaft fractures making hair ends feel rough
- Can weekly shave a small area of involved scalp to demonstrate normal, dense regrowth

DDx – alopecia areata, tinea capitis

Histology

- Follicles are normal size and total number of hairs is normal
- Incomplete, disrupted follicular anatomy
- Trichomalacia and pigment casts
- Minimal inflammation
- Increased number of catagen and/or telogen hairs

Treatment

- Behavioral modification therapy
- Selective serotonin reuptake inhibitor (SSRI) such as fluvoxamine, fluoxetine, paroxetine, sertraline, citalopram, etc.
- Topical minoxidil to help regrow hair

Pearls and Pitfalls

- It is difficult to convince parents that the child is pulling out hair, as it is commonly not seen directly by them. A biopsy can be very helpful in convincing them if there is any question about the diagnosis

Alopecia – Other Types

Pressure-Induced Alopecia

- Occurs with prolonged contact in one position (usually the occipital scalp)
- Initially, see erythema and some induration → almost complete hair loss in demarcation area of pressure
- Usually see complete hair regrowth

Temporal Triangular Alopecia

- AKA – congenital triangular alopecia
- May present at birth or acquired during first decade of life
- Rarely occurs outside of the temporal area or presents during adulthood
- See “lancet-shaped” lesions which point superiorly and posteriorly
- Area appears hairless but actually has fine, vellus hairs
- The patches of alopecia persist for life
- Histology
 - Normal number of follicles, but almost all are vellus hairs
 - Inflammation absent
 - Epidermis, dermis, adnexae – normal

Congenital Atrichia with Papules

- Individuals shed all their hair shortly after birth and fail to regrow it
- Follicular cysts and milia-like lesions appear on skin later in life
- Associated with mutations in two different genes:
 - The *hairless gene*
 - The vitamin D receptor gene

Lipedematous Alopecia

- Thick boggy scalp associated with hair loss
- Usually seen in darker-skinned females
- See doubling of scalp thickness as a result of edema and expansion of the subcutaneous fat layer
 - Unclear how this leads to hair loss as follicular structures appear relatively normal but ectatic lymphatic vessels sometimes seen

Hair Shaft Abnormalities

Table 5 Hair shaft disorders characterized by hair fragility

Increased fragility
Trichorrhexis nodosa
Trichoschisis
Trichorrhexis invaginata
Pili torti
Monilethrix
Without increased fragility
Pili annulati
Loose anagen hair syndrome
Uncombable hair syndrome

Trichorrhexis Nodosa (TN)

- Beaded swellings with loss of cuticle and frayed “paintbrushes” against each other
- Seen in → excessive perming and chemical treatments, mechanical trauma
- Genetic disorders
 1. **Argininosuccinic aciduria** – 50% have TN. Defect in urea synthesis (argininosuccinate lyase deficiency)
 - Seizures, neurologic damage, growth retardation, coma from ↑ ammonia
 - Hair usually normal at birth with development of dull, dry hair and TN in infancy and early childhood
 - Labs – ↓ serum arginine and ↑ citrulline (serum and urine)
 - Mutations in ASL gene, autosomal recessive
 2. **Citrullinemia** – defect in urea synthesis (argininosuccinic acid synthetase)
 - Infantile onset – TN, atrophic hair bulbs, and/or pili torti. Some get rash similar to acrodermatitis enteropathica. Clinical similar to argininosuccinic aciduria.
 - Adult onset – argininosuccinic acid synthetase is liver-specific with an abnormal transporter protein citrin

Trichoschisis

- Clean, transverse fracture of the hair shaft
- Low cysteine (sulfur) content of hair is postulated to account for cuticular and cortical weakness
- Usually seen on light microscopy
- Polarized light – “tiger tail” of alternating bright and dark diagonal bands; its absence does not exclude diagnosis

- Genetic disorders
 1. **Trichothiodystrophy (TTD) – AR**
 - Brittle hair and low sulfur content of hair
 - Trichoschisis is common finding
 - Involvement of all body hair reported
 - Eight subgroups:
 - BIDS – brittle hair, intellectual impairment, decreased fertility, short stature
 - IBIDS – BIDS + ichthyosis
 - PIBIDS – IBIDS + photosensitivity
 - SIBIDS – IBIDS + osteosclerosis
 - ONMR – onychotrichodysplasia, chronic neutropenia, mental retardation
 - Tay, sabinas, and pollitt syndromes
 2. **TTD, Photosensitivity, and Impaired DNA**
 - DNA repair defects linked to defects in nucleotide excision repair (NER)
 - 95% of patients with TTD and photosensitivity and NER have xeroderma pigmentosum complement group D
 - Some have xeroderma pigmentosum type B and defects in TTD-A gene
- NOT at increased risk for developing skin cancer
 3. **Non-photosensitive TTD** → Amish brittle-hair syndrome and non-photosensitive TTD with mental retardation and/or decreased fertility

Trichorrhhexis Invaginata

- Bamboo hair or “golf-tee” hair (distal hair shaft invaginates into proximal hair shaft)
- Genetic disorders:
 1. **Netherton syndrome** – SPINK5 – encodes serine protease inhibitor LEKTI
 - Triad – ichthyosis linearis circumflexa, trichorrhhexis invaginata, atopic diathesis
 - Usually appears in infancy, may be born with collodion membrane, generalized scaling or erythema
 - Scalp hair short and brittle. Eyebrows may be affected. Hair breakage may improve with age
 - Many patients – atopic dermatitis, hay fever, food allergies, angioedema, urticarial, allergic rhinitis, hypereosinophilia, recurrent skin infections, ↑ IgE
 - Failure to thrive, recurrent infections, and dehydration (may be due to impaired epidermal barrier)
 - EM – premature lamellar body secretion in stratum corneum

- Treatment
 - Use topical medications with *extreme caution* – meds absorbed very easily and can cause systemic toxicity
 - Use of oral retinoids has yielded mixed results

Pili Torti

- Characterized by hair shafts which are flattened and twist with an angle of 180°
- Fractures occur within the twists, which is weakest point
- Early auditory testing important in all kids with pili torti
 1. **Classic PT** – presents in first 2 years of life. Inheritance – AD, AR, or sporadic
 2. **Late-onset PT** – AD, onset in childhood, or after puberty. Caucasian patient with black unruly hair. Mental deficiency. Typically presents with breakage of eyebrows and eyelashes
 3. **PT and hearing loss** → **Björnstad syndrome and Crandall syndrome**
 - **Björnstad syndrome** – congenital sensorineural hearing loss and PT; BCS1L mutation
 - **Crandall syndrome** – hearing loss, PT, hypogonadism. MR rare. Typically develop symptoms in first 2 years of life and hearing loss by age 4. Severity of hair shaft abnormalities correlates with severity of deafness
 4. **PT and ectodermal dysplasias** – widely spaced teeth and enamel hypoplasia, acrofacial dysostosis, tooth agenesis, arthrogryposis, nail dystrophy, clefting, corneal opacities, ichthyosis, hypohidrotic ectodermal dysplasia
 5. **Menkes syndrome** – XLR; gene ATP7A
 - Defective copper export from cells with normal copper absorption into cells
 - Primary finding is pili torti, but can get trichorrhexis nodosa
 - Skin and hair hypopigmentation, progressive neurodegeneration, MR, soft doughy skin, joint laxity, vascular abnormalities (aneurysms), and bladder diverticula
 - Hair – short, sparse, brittle, depigmented. Looks like steel wool
 - Labs – ↓ serum copper and ↓ ceruloplasmin
 - Tx – infusions with copper-histidine. Increases serum copper levels and can permit survival into adolescence. Many die secondary to neurodegeneration and renal failure

Monilethrix

- Beaded hair – elliptical nodes at regular intervals with intervening, nonmedulated tapered fragile constrictions
- Usually AD and presents in early childhood

- Hairs rarely grow beyond 1–2 cm in length because of breakage → gives stubbly appearance
- Common – keratotic follicular papules at base of nape of neck, keratosis pilaris and TN
- Light microscopy – nodes and internodes
- EM – at internodes, see increased longitudinal ridging with fluting
- Treatment
 - Topical minoxidil and oral retinoids reported to improve hair growth but no specific tx

Pili Annulati

- Characteristic alternating light and dark bands in hair shaft on clinical and microscopic exam
- Thought to be due to abnormal air cavities in hair shaft
- Appears at birth or in infancy
- Hair is NOT brittle – growth of scalp hair usually normal
- May affect axillae, beard, pubic regions
- No treatment necessary

Pili Trianguli et Canaliculi

- Entire hair shaft is rigid with longitudinal grooving. Cross section = triangular shape
- 1. **Uncombable Hair Syndrome** – “Spun glass hair”. May be result of premature keratinization of triangular-shaped inner root sheath caused by abnormally shaped dermal papilla
 - Scalp has >50% involvement
 - Hair shafts not twisted as in pili torti
 - Usually manifests in childhood
 - Associated problems are rare → cataracts, anomalies in bone development, alopecia areata, pili torti, and lichen sclerosus
 - Hair manageability tends to improve with age
 - Tx – may respond to biotin

Woolly Hair

- Hairs are tightly curled; can also contain wide twists over several mm along its own longitudinal axis
- Increased hair fragility, trichorrhexis nodosa, trichoschisis, and pili annulati
- Hair growth is normal (1 cm/month) but hair shafts ovoid, flattened, or irregular

- Dominant form
 - Usually affects entire scalp; seen at birth or in first few months
 - Can have pili torti, pili annulati, ocular problems, keratosis pilaris
- Recessive form
 - Fragile and fine hair which is light/blond in color at birth
 - Hair may not grow beyond few cm – likely due to shortened anagen phase
- With Cardiac disease
 1. **Naxos disease** – AR, plakoglobin
 - Woolly hair usually presents at birth
 - Palmoplantar keratoderma develops during childhood
 - Right ventricular cardiomyopathy (arrhythmogenic) – presents in adolescence or early adulthood
 2. **Carvajal syndrome** – AR, desmoplakin
 - Biventricular dilated cardiomyopathy
 - Palmoplantar keratoderma
 - Woolly hair
 3. **Naxos-like disease** – AR
 - Right ventricular cardiomyopathy (arrhythmogenic)
 - Woolly hair
 - Early-onset blistering on knees/palms/soles and dry skin
 - Skin biopsy of blister sites look like pemphigus foliaceus
- Without Cardiac disease
 1. **Woolly hair and skin fragility syndrome**
 - Similar to Naxos-like disease but NO cardiac problems
 - Recurrent *Staph aureus* on palms and soles
 - Dystrophic nails, woolly hair, focal and diffuse PPK, early onset blistering
 2. **Diffuse partial woolly hair** – AD
 - Hair is short, fine, kinky
 - Ocular problems reported
 3. **Woolly hair nevus**
 - Affects localized part of the scalp and typically presents in first 2 years of life
 - Hair is usually thinner and lighter compared to adjacent hairs
 - 50% of cases associated with epidermal or congenital nevus, usually located ipsilaterally on neck or arm
 - Also reported – bone abnormalities, precocious puberty, speech and dental anomalies

Other Hair Shaft Disorders

- **Loose anagen syndrome**
 - Anagen hairs lack inner root sheath and external root sheath
 - Ruffled cuticles that are easily pulled from scalp

- Clinical – most patients are blond girls (older than 2) who never need a haircut. May persist into adulthood. Hair is not typically brittle and of normal strength
- **Mitochondrial disorders**
 - May see trichorrhexis nodosa, trichorrhexis, longitudinal grooving, trichoschisis, pili torti
- **Marie Unna Hypotrichosis – AD**
 - Have normal to coarse sparse hair and eyebrows
 - Develop coarsening within first few years
 - Eyebrows, eyelashes, axillary hair also affected
 - Scalp – hair loss starts in parietal and vertex. Partial sparing of occipital scalp

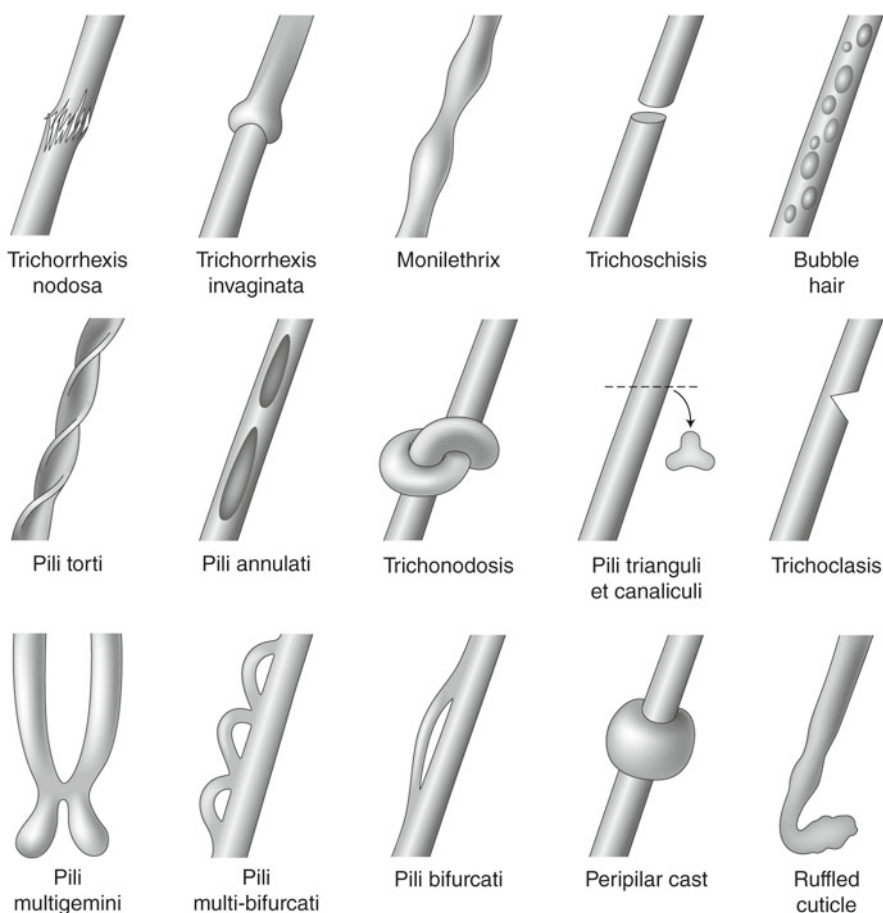


Fig. 1 Hair shaft anomalies

Hair Tips

(From Dr. Zoe Draelos)

There are many causes of hair loss including disease and genetic predisposition. Yet, the most common reason men and women experience hair loss is due to poor cosmetic grooming practices.

1. Scalp scratching

- Even though mild-to-moderate seborrheic dermatitis does not cause hair loss, the scratching associated with the scalp pruritus can definitely predispose to hair loss. It is possible to remove all of the cuticular scale off of a hair shaft with only 90 min of continuous scratching by the fingernails. This loss of cuticle leaves the hair shaft weakened and permanently cosmetically damaged. Thus, treatment of scalp itch is important to prevent hair loss.

2. Long versus short hair

- Long hair is much more likely to be cosmetically damaged than short hair. Therefore, patients who have extensive hair damage may wish to select a shorter hair style to maximize the appearance of the hair. In this case, it is extremely important to identify the cause of the hair damage so that the newly grown hair remains healthy and cosmetically attractive.

3. Age-related factors

- It is a well-known fact that hair growth slows down with age. This means that cosmetically damaged hair will be present longer on mature individuals. Also, the diameter of the hair shaft decreases with advancing age. This predisposes the thinner hair shafts to chemical damage from chemical processing. For this reason, all chemicals used on mature hair should be weaker than those used on youthful hair.

4. Hair combing and brushing

- Hair combing is a daily grooming ritual that frequently causes hair damage and loss. Hair should only be combed when dry, if possible. Wet hair is more elastic than dry hair, meaning that vigorous combing of the moist fibers can stretch the shaft to the point of fracture. The ideal comb should be made of a flexible plastic and possess smooth, rounded, coarse teeth to easily slip through the hair.
- Extensive hair brushing should also be avoided while hair is wet. A good brush should have smooth, ball-tipped, coarse, bendable bristles. The brush should not tear the hair, but rather gently glide. Brushes used while blow drying hair should be vented to prevent increased heat along the brush, which could damage hair. Patients should be encouraged to brush and manipulate their hair as little as possible to minimize breakage. Older teachings that the hair should be brushed 100 strokes a day and the scalp vigorously massaged with the brush should be dispelled.

5. Hair clasps

- Common sense applies to the selection of appropriate hair pins and clasps. Rubber bands should never be used; hair pins should have a smooth, ball-tipped surface; and hair clasps should have a spongy rubber padding where they contact the hair. Loose-fitting clasps also minimize breakage. The fact remains, however, that all hair pins or clasps break some hair since they must hold the hair tightly to stay in place. To minimize this problem, the patient should be encouraged to vary the clasp placement so that hair breakage is not localized to one scalp area. This problem is particularly apparent in women who wear a ponytail. These women frequently state that their hair is no longer growing when in actuality it is repeatedly broken at the same distance from the scalp due to hair clasp trauma. Pulling the hair tightly with clasps or braids can also precipitate traction alopecia.

6. Hair shaft architecture

- It is important to remember that curlier hair tends to fracture more readily than straight hair. For this reason, hair shaft architecture can determine how aggressively the hair can be groomed. The kinky hair of African-American patients should be gently groomed with a wide-toothed comb or hair pick. Only Asian hair can be combed with minimal friction and hair shaft damage.

7. Hair cutting techniques

- The hair should always be cut with sharp scissors. Any defect in the scissor blade will crush and damage the hair shaft. Crushing the end of the hair shaft predisposes to split ends.

8. Hair styling product use

- Hair styling products are an important way to improve the cosmetic appearance of the hair shaft, but should always leave the hair shaft flexible. High hold stiff styling products can actually precipitate hair breakage when trying to restyle the hair with combing.

9. Hair styling techniques

- In general, the less that is done to the hair, the healthier it will be. There is no hair style or procedure that can reverse hair damage, even though many salon owners would disagree. Hair is basically a textile. It works the best when new and degrades with age and use.

10. Hair coloring and bleaching

- Hair coloring and bleaching are universally damaging to the hair shaft. It is sometimes said that chemical processing adds body to the hair. This means that the dyeing procedure allows the hair to stand away from the scalp with greater ease. This is not due to better hair health, but rather due to hair damage that makes the hair frizzy and more susceptible to static electricity. The basic rules of hair dyeing are always stay within your color group, preferably dyeing the hair no more than three shades from the natural color.

11. Hair relaxing

- Hair relaxing is weakening to the hair shaft, but can actually facilitate hair length in patients with kinky hair. This is due to decreased hair breakage during combing. The relaxing procedure straightens the hair and makes it easier to groom, but the grooming should be done gently to avoid hair shaft fracture.

12. Hair permanent waving

- Lastly, hair permanent waving is also damaging. The curls should be as loose as possible with the interval between procedures as long as possible. For patients with damaged hair, the perming solution should be weak and left in contact with the hair for as short a period as possible.

Shampoos and Hair Products

- Telogen Effluvium
 - Focus on hairspray for body and not stiffness
 - Gel
- Seborrheic Dermatitis
 - Head and shoulders – good for mild seb derm, good for prolonging disease-free episodes. Good technology
 - Nizoral 2% – effective, but can be very drying. Use with conditioners
- Women of Color
 - Pantene brown bottle
 - Keracare
- Colored hair
 - A color protectant shampoo and conditioner such as L'Oreal Vive
 - L'Oreal Vive (shampoo and conditioner) or other UV protectant
- Fine hair
 - AVOID Pantene
 - Use dimethicone-based products → will smooth cuticle, hair is shiny, looks more voluminous

Hypertrichosis

Etiology and Pathogenesis

- May be congenital or acquired, generalized or localized
- Other causes – medications, malignancy

Clinical Presentation

- Excessive amount of hair on any part of the body
- **Acquired Generalized** – the presence of lanugo hair, excessive vellus hair or terminal hair on much of the body. May sometimes see transformation of terminal hairs into lanugo hair
 - Lanugo hair = nonpigmented, nonmedullated fine hair that covers the fetus. Normally shed in utero or in first few weeks of life. Replaced by vellus hair on the body and terminal hair on the scalp
 - **Acquired hypertrichosis lanuginosa** (paraneoplastic)
 - Variety of malignancies – lung, colon, breast
 - Lanugo hair develops over body in short period of time
 - May be associated with burning tongue pain and other paraneoplastic dermatoses
 - **Prepubertal hypertrichosis**
 - Relatively common in otherwise healthy children – usually Mediterranean or South Asian descent
 - Bushy eyebrows, low anterior hairline, hair on forehead, temples, preauricular area, proximal extremities, and back
 - Some have slightly elevated androgen levels
 - **Acquired generalized hypertrichosis**
 - Often related to drug ingestion and typically reversible if drug stopped. Slow growth of terminal hair. Most evident on forehead, temples, flexoral extremities and trunk
 - Drugs often associated – acetazolamide, ACTH, anabolic steroids, benoxaprofen, cetuximab, **cyclosporine**, danazol, diazoxide, fenoterol, glucocorticosteroids, hexachlorobenzene, IFN- α , methoxypsoralen, **minoxidil**, penicillamine, **phenytoin**, prostaglandin E1, streptomycin, testosterone, trimethylpsoralen
 - Other etiologies – CNS disorder (traumatic brain disorder), POEMS syndrome, juvenile hypothyroidism, juvenile dermatomyositis, acrodynia, malnutrition, advanced HIV
- **Acquired Localized**
 - **Trichomegaly** HIV, medications (cyclosporine, topiramate, latanoprost, bimatoprost, IFN- α , cetuximab, gefitinib), hypothyroidism, porphyrias, dermatomyositis, SLE, malnutrition, anorexia nervosa, kala-azar

- **Other** – trauma, friction, irritation, vaccination sites, overlying lipoatrophy, healing psoriasis and morphea, PUVA, topical steroids or tacrolimus, anthralin, creams with mercury or iodine
- **Congenital Generalized**, evaluate for:
 - Maternal drug/alcohol intake
 - Family history of hypertrichosis
 - Orofacial, skeletal, ocular or neurologic abnormalities

Table 6 Congenital conditions associated with generalized hypertrichosis

Acromegaly + hypertrichosis	AD, acromegaloid facies, hypertrichosis
Amaurosis congenital, cone-rod type + hypertrichosis	AR, photophobia, visual impairment due to retinal dystrophy, hypertrichosis
Ambras syndrome	AD. Fine, silky, long hair (>10 cm) uniformly distributed on face (including nose), ears, and shoulders. Persists for life. Minor facial dysmorphism, dental anomalies, supernumerary nipples
Barber-Say syndrome	AD, Hypertrichosis especially of the back, skin hyperlaxity and redundancy, facial dysmorphism, hypoplastic nipples
Berardinelli-Seip syndrome	Lipodystrophy, high TG, insulin resistance, fatty liver, cardiomyopathy, muscular appearance, hypertrichosis. Two types
CAHMR syndrome	AR, Cataracts, Hypertrichosis, MR
Cantu syndrome	AD, Hypertrichosis, cardiac anomalies, wide ribs, gingival hyperplasia, coarse facies, macrosomia at birth
Coffin Siris syndrome	Hypoplasia/aplasia of fifth phalanx and fifth fingernails, MR, generalized hypertrichosis, scalp hypotrichosis
Congenital hypertrichosis lanuginosa	AD, fine, downy, silvery-gray lanugo hair. May be shed over first year of life. Occasional dental anomalies. Can lead to “dog face” or “monkey face”
Cornelia de Lange	Hypertrichosis, synophrys, low-set ears, microcephaly, hearing loss, short stature, problems with digestive tract, skeletal problems
Craniofacial dysostoses	Various types. Hypertrichosis may be assoc
Donohue syndrome	AKA – Leprechaunism. Lipodystrophy, hypertrichosis, insulin resistance, acanthosis nigricans, endocrine problems
Erythropoietic porphyria	Ferrochelatase defect, photosensitivity in childhood and hepatobiliary disease. Hyper-trichosis may occur, waxy scarring on sun-exposed areas
Familial porphyria cutanea tarda	Hypertrichosis common on face, blisters, milia
Fetal alcohol syndrome	Failure to thrive, decreased muscle tone, heart defects, hypertrichosis, structural issues (face)
Fetal hydantoin syndrome	Caused by phenytoin, skull and facial abnormalities, underdeveloped nails, cleft lip and palate, developmental delays

(continued)

Table 6 (continued)

Gingival fibromatosis with hypertrichosis	AD, dark terminal hairs on peripheral face, central back and extremities. Have gingival hyperplasia, coarse facies, MR, seizures
Hemimaxillofacial dysplasia	Unilateral enlargement of the maxillary alveolar bone and the gingiva associated with hypoplastic teeth, facial asymmetry, and hypertrichosis of the facial skin on the ipsilateral side
Hepatoerythropoietic porphyria	Severe photosensitivity, hemolytic anemia, hypertrichosis on arms, splenomegaly, dark urine at birth
Hunter syndrome	Mucopolysaccharidosis. Lack iduronate sulfatase. Spasticity, MR, aggressive behavior, hypertrichosis, coarse facial features
Hurler syndrome	Mucopolysaccharidosis. Lack lysosomal alpha-L-iduronidase. Heart problems, cloudy cornea, hypertrichosis, MR, coarse facial features
MELAS syndrome	Mitochondrial myopathy, encephalopathy, lactic acidosis, and stroke (MELAS)=progressive neurodegenerative disorder. Lactic acidosis, cardiac issues, hypertrichosis, diabetes and endocrinopathies, short stature
Rubinstein-Taybi syndrome	Broad thumbs and toes, constipation, hypertrichosis, heart defects, slow motor skills
Sanfilippo syndrome	Mucopolysaccharidosis. Most common MPS. Types A-D. Coarse facial features, synophrys, MR, full lips, sleep difficulties, walking problems
Schinzel-Giedion syndrome	<i>SETBP1</i> gene defect. Midface retraction, hypertrichosis, multiple skeletal anomalies, cardiac and renal problems (hydronephrosis)
Stiff skin syndrome	Scleroderma-like disorder that presents in infancy or early childhood with rock-hard skin, limited joint mobility, mild hypertrichosis in the absence of visceral or muscle involvement, immunologic abnormalities, or vascular hyperreactivity
Universal Hypertrichosis	AD. Thicker, longer hair on frontal, temporal and preauricular areas of face, back and lower extremities. Increases during infancy and tends to persist
Winchester syndrome	Dwarfism (resulting from disturbances of the skeletal-articular system), corneal opacities, coarsening of facial features, leathery skin, hypertrichosis
X-linked Hypertrichosis	XR. Curly, shorter, dark hair most prominent on face and upper body. Anteverted nostrils, prognathism, occasional dental anomalies, deafness
Zimmerman-Laband syndrome	AD, gingival hyperplasia, coarse facies, hypoplastic nails and distal phalanges, joint hyperextensibility, macrosomia at birth, MR, hepatosplenomegaly, hypertrichosis

- **Congenital localized hypertrichosis**

- Can affect specific anatomic sites – elbows, palms/soles, auricle, eyebrows, eyelashes, nasal tip, anterior cervical, posterior cervical
- **Synophrys**
 - Isolated trait, Waardenburg syndrome, Cornelia de Lange, Zimmerman-Laband, Amaurosis congenital (cone-rod type), mucopolysaccharidoses
- **Trichomegaly**
 - Isolated trait, Oliver-McFarlane, Cornelia de Lange, Rubinstein-Taybi, Ambras, congenital hypertrichosis lanuginosa, Cantu, Coffin-Siris, Barber-Say, Amaurosis congenital (cone-rod type), Hermansky-Pudlak, Kabuki and floating harbor syndromes, fetal alcohol syndrome
- **Distichiasis (double row of eyelashes)**
 - Lymphedema-distichiasis syndrome, Setleis syndrome (double upper and absent lower eyelashes)
- **Other** – Congenital nevi, Plexiform neurofibromas, Becker's nevus, Nevroid Hypertrichosis, Spinal dysraphism
- **“Hair collar sign”** – ring of hypertrichosis surrounding aplasia cutis or ectopic neural tissue in scalp reflect incomplete neural tube defects

Labs – dependent on potential etiologies. Usually not necessary for hypertrichosis, but can be useful in hirsutism

DDx – Hirsutism

Treatment

- Depilatory creams – especially those containing barium sulfate
- Electrolysis
- Hair removal via laser – ruby, Nd:YAG, diode and alexandrite lasers
- Shaving
- Plucking
- Eflornithine cream 13.9% (Vaniqa) – inhibits ornithine decarboxylase and slows hair growth

Pearls and Pitfalls

- Depilatory creams containing barium sulfate are more effective than those containing calcium thioglycolate but also tend to be more irritating. Test a small area first
- Laser treatment and creams not typically covered by insurance plans

Hirsutism

Etiology and Pathogenesis

- Women with excessive growth of terminal hairs in a “**male pattern**” due to androgen overproduction (ovaries or adrenal glands) or increased sensitivity to androgens
- Ethnic differences – Asian women tend to have little body and facial hair, while Middle Eastern, Mediterranean, and East Indian women have moderate amounts
- **Ovarian origin** – PCOS, insulin resistance, HAIR-AN, hyperthecosis, ovarian tumors
 - ↑progesterone, Δ -4-androstenedione, and testosterone
- **Pituitary origin** – Cushing’s disease, acromegaly, hyperprolactinemia, pituitary adenoma (secreting prolactin), psychogenic drugs (dopamine inhibits prolactin), and contraceptive pills (stimulate adrenal androgen production)
 - ↑ACTH → stimulates adrenals to produce ↑ androgens and cortisol
- **Adrenal origin** – Classic congenital adrenal hyperplasia, nonclassical (late-onset) congenital adrenal hyperplasia, Cushing’s syndrome, adrenal tumors (adenomas and CA)
 - ↑ DHEA and DHEA-S
 - **Constitutional hirsutism** – May reflect familial ↑ response to normal levels of androgens
 - **Hepatic hirsutism** – SHBG made in liver. Liver disease → ↓ SHBG available → ↑ free testosterone and thus conversion to DHT may also be greater
- **Hirsutism due to ectopic hormone production** – ectopic ACTH secretion by tumors such as lung CA (especially small-cell) and carcinoids or production of β -HCG by choriocarcinomas
- **Drug-induced hirsutism**
 - Androgenic medications – testosterone, danazole, ACTH, metyrapone, phenothiazine,
 - Anabolic steroids
 - Androgenic progestins – levonorgestrel, norgestrel, norethindrone
 - Valproic acid – ↑ plasma testosterone
- **Hirsutism due to peripheral failure in converting androgens into estrogens**
- **Pregnancy** – aromatase deficiency in fetus, luteoma of pregnancy, hyperreactio luteinalis

Clinical Features

- Increased amount of hair in male pattern; may be accompanied by acne, seborrhea, androgenetic alopecia
- **Proposed diagnostic criteria for PCOS (Need two of three for diagnosis)**
 - Oligo- or anovulation (< eight menses/year or cycles > 35 days)
 - Clinical and/or biochemical signs of hyperandrogenism
 - Polycystic ovaries and exclusion of other etiologies (Cushing's syndrome, congenital adrenal hyperplasia, androgen-secreting tumors) Source = 2003 Rotterdam PCOS consensus. Fertil Steril 2004; 81:19–25.
- **PCOS features**
 - **Skin** – SAHA – seborrhea, acne, hirsutism, alopecia (androgenetic)
 - **Menstrual** – oligomenorrhea, amenorrhea, anovulation and infertility, polycystic ovaries in 80–100%, dysfunctional uterine bleeding, theoretical risk for endometrial CA
 - **Metabolic** – obesity common (BMI > 30), impaired glucose tolerance, type II diabetes, hyperlipidemia, ↑ risk of CV disease, sleep apnea
 - **Labs** – ↓SHBG, LH:FSH > 2 (suggestive but low sense and specificity), ↑ testosterone, ↑ free testosterone, ↑ DHEAS, abnormal glucose tolerance, ↑ TG and elevated LDL:HDL ratio

Table 7 Clinical and laboratory features of hirsutism

Cause of Hirsutism	Clinical Hx	Menstrual Hx	Testosterone	DHEAS	17-OHP	LH/FSH	Cortisol	Prolactin	Comments
Acromegaly	Coarse facies, large hands, ring size keeps changing, HA, visual disturbance		NL to ↑	NL	NL	NL	NL	NL to ↑ (in 40%)	Tests = Somatomedin-C (IGF-1) level, head MRI
CAH (late-onset) – CYP21A2	Acne, hirsutism, premature puberty, family history of infertility and hirsutism	Irregular, primary amenorrhea	NL to ↑	NL to ↑	↑	NL/NL	NL to ↑	NL	Tests = ↑ 17-hydroxyprogesterone, consider ACTH stim test, wrist x-ray (accl bone age)
Cushing's Disease	Fatigue, recurrent infections, mood and sleep disturbance, acne, hirsutism, alopecia, striae, fat redistribution	Irregular	NL to ↑	NL to ↑	NL	NL	↑	NL	Tests = ↑24-h urine cortisol and overnight dexamethasone suppression test, evening ACTH level, CRH stim test Risks – CV dz, osteoporosis, hypokalemia
HAIR-AN	Acne, hirsutism, insulin resist, obesity, acanthosis nigricans, HTN	Irregular	NL to ↑ ↑ > 200 ng/dL	NL to ↑	NL	NL to ↑ LH	NL	NL	Risks = CV dz, diabetes, HTN, infertility. Tests = lipids, glucose tolerance test
Idiopathic	Mild Hirsutism	Regular	NL or sl ↑	NL	NL	NL/NL	NL	NL	
Neoplasm – Adrenal	Sudden onset, older age, signs of virilization, palpable abdominal mass	May be menopausal (since likely in older patients), irregular	↑ > 200 ng/dL	↑ > 700 ug/dL	NL	NL/NL	NL to ↑	NL	Tests = transvaginal u/s, CT or MRI of abdomen and pelvis
Neoplasm – Ovarian			↑ > 200 ng/dL	NL	NL	NL/NL	NL	NL	Tests = androstendione > 100 ng/dL, Imaging, as above
PCOS	Seborrhea, acne, hirsutism (variable), alopecia, acanthosis nigricans, obesity (some), HTN	Irregular	NL to ↑	NL to ↑	NL	NL to >2:1 ratio	NL	NL to ↑	Risks = CV, diabetes, HTN, infertility, endometrial CA
Prolactinemia	Galactorrhea	Amenorrhea	NL to ↑	NL to ↑	NL	NL	NL	↑	Tests = transvaginal u/s, ↓ SHBG, glucose tolerance, lipids
Thyroid	Alopecia, weight change, heat or cold intolerance	May be irregular	NL	NL	NL	NL	NL	NL to ↑	Test = Head MRI Tests = TSH, free T4, thyroid antimicrosomal Ab

Table 8 Useful screening labs for patients with hirsutism

Lab	Evaluate for ...
Testosterone (free and total)	PCOS, nonclassical CAH, HAIR-AN, androgen-secreting neoplasms and hirsutism associated with hyperandrogenism
Sex hormone binding globulin (SHBG)	PCOS
Dehydroepiandrosterone-sulfate (DHEA-S)	Nonclassical CAH, PCOS, androgen-secreting adrenal tumors
Δ -4-androstenedione	Ovarian origin
3- α -androstenediol glucuronide (metabolite of DHT)	
17-Hydroxyprogesterone	Nonclassical CAH * get in early AM between first day of menses and ovulation
Prolactin	Reason for anovulation
Thyroid	Reason for anovulation
LH, FSH	Ovarian
Somatomedin-c	acromegaly
Transvaginal ultrasound	PCOS
24-h urine cortisol	Cushing's syndrome
ACTH level, evening	Cushing's syndrome
ACTH stimulation test <ul style="list-style-type: none"> Should be started between 0730 and 0930 in a fasting state and scheduled on day 3–8 after a spontaneous vaginal bleed or after induced withdrawal bleed Three baseline samples of 17-hydroxyprogesterone should be obtained 15 min apart and pooled Subsequently, 0.25 mg ACTH (cosyntropin) is administered IV over 60 s 17-hydroxyprogesterone should be measured again 60 min later If the 17-hydroxyprogesterone level is stimulated above 10 ng/ml, the diagnosis of C21-hydroxylase-deficient CAH is confirmed 	Nonclassical CAH
Dexamethasone suppression test – overnight	Cushing's syndrome
CRH stimulation test	Cushing's syndrome

DDx – hypertrichosis

Treatment

Table 9 Medications commonly used for hirsutism

Drug type	Active ingredient	Major mechanism	Indication	Contraindication	Dose
Cell-cycle Inhibitor					
– <i>Vaniga</i>	Eflornithine hydrochloride, 13.9%	Irreversible inhibition of ornithine decarboxylase	Focal hirsutism	Pregnancy, lactating	Topical, BID
Oral contraceptives					
– <i>Yasmin</i>	Ethinyl estradiol	Suppresses ovarian fnx	Generalized hirsutism	Breast cancer, smoking (absolutely if age >35 year), CVD, uncontrolled HTN	1 tablet PO QHS (larger estrogen doses may be necessary in heavier women for menstrual regularity)
– <i>Yaz</i>	30 µg + drospirenone				
– <i>Orthocyclen</i>	35 µg + norgestimate				
– <i>Demulen 1–50</i>	50 µg + ethynodiol diacetate				
Anti-androgens (need reliable birth control)					
	Spirolactone	Competitive inhibitor of androgen receptor binding	Moderate or severe hirsutism	Lack of contraception, kidney or liver failure	50–200 mg/day by mouth, × 6 months
	Cyproterone acetate	Competitive inhibitor of androgen receptor binding	Moderate or severe hirsutism	Lack of contraception	<i>Induction:</i> 50–100 mg PO QHS, days 5–15 <i>Maintenance:</i> 5 mg PO QHS, days 5–15
	Flutamide	Nonsteroidal competitive inhibitor of androgen receptor binding	Severe hirsutism	Lack of contraception, liver disease	125–500 mg BID for 6–9 months. Low doses of 62.5–125 mg can be used
Glucocorticoids <i>Prednisone</i>	Glucocorticoid	Suppresses adrenal function	Congenital adrenal hyperplasia	Uncontrolled diabetes, obesity	Prednisone 7.5 mg QD × 2 months, 5 mg QD × 2 months, 2.5 mg QD × 6 months Dexamethasone 0.5 mg QHS × 3 months then q other night × 3 months
Gonadotropin-releasing agents <i>Lupron Depot</i>	Leuprolide acetate, depot suspension	Suppresses gonadotropins	Reserved for severe cases and HAIR-AN	Osteoporosis	7.5 mg monthly IM, with 25–50 µg transdermal estradiol or 3.75 mg q 28 days × 6 months

Reference: Used with permission from Elsevier. Rosenfield RL. Hirsutism. N Engl J Med 2005; 353: 2578–88

Pearls and Pitfalls

- If hirsutism appears rapidly, suspect and rule out a tumor (ovarian, adrenal, pituitary)
- Suspect ovarian source if → hirsutism mainly on areola, lateral face, and neck
- Suspect adrenal source if → hirsutism mainly distributed from pubic triangle to upper abdomen and from presternal region to neck and chin
- Suspect iatrogenic source if → hair on lateral face and on back (but can spread with time)
- Suspect Androgen-secreting tumor if ...
 - Total testosterone > 200 ng/dl or DHEA-S of > 700 ug/dl
 - Imaging studies should be performed to localize the neoplasm
- Refer to endocrinology and/or gynecology if workup is significantly abnormal

The Manual of Dermatology

Cafardi, J.

2012, XIII, 573 p. 15 illus., Softcover

ISBN: 978-1-4614-0937-3