

# Chapter 2

## Evaluation and Management of Secondary Hypertension

Nathaniel Winer

### Introduction

Most patients who present with elevated blood pressure (BP) will have essential (idiopathic) hypertension; extensive laboratory evaluation for secondary causes in these patients is low-yield and cost-prohibitive. However, identification of a secondary cause may often lead to a cure of the elevated BP or to a decrease in the number and/or doses of antihypertensive agents and a reduction in the long-term cardiovascular risks of hypertension. This chapter will focus on two important causes of secondary hypertension: renovascular stenosis and primary aldosteronism. Other causes of secondary hypertension include primary renal disease, oral contraceptive use, pheochromocytoma, Cushing's syndrome, sleep apnea syndrome, and coarctation of the aorta. Clinical features which are suggestive of these disorders are given in Table 2.1.

Secondary hypertension should be suspected in the following conditions: severe or resistant hypertension; acute BP elevation in a medication-adherent patient with preceding stable hypertension; a history of prepubertal onset hypertension; young nonobese, white patients without risk factors, such as diabetes, chronic kidney disease, or a family history of hypertension; and malignant hypertension (severe hypertension associated with acute renal failure, retinal hemorrhages, papilledema, and neurologic findings).

---

N. Winer, M.D. (✉)

Department of Medicine, Division of Endocrinology, SUNY Downstate Medical Center,  
Brooklyn, NY 11203, USA

e-mail: Nathaniel.winer@downstate.edu

**Table 2.1** Other causes of secondary hypertension

Disorder	Suggestive clinical features
Primary renal disease	↑ Serum creatinine, abnormal urinalysis
Oral contraceptives	New-onset hypertension related to BCP use
Pheochromocytoma	Paroxysmal BP spikes, headaches, sweats, tachycardia
Cushing's syndrome	Moon facies, central obesity, striae, hirsutism, ↑ BP, ↑ glucose
Sleep apnea syndrome	Male obesity, loud snoring, daytime somnolence
Coarctation of aorta	↑ BP in arms, ↓ femoral pulses, ↓ BP in legs
Hypothyroidism	Symptoms of hypothyroidism, ↑ TSH, ↓ Free T4
1° hyperparathyroidism	Hypercalcemia, ↑ PTH

## Causes of Secondary Hypertension

### *Renovascular Hypertension*

#### Prevalence

Although renovascular stenosis is a common and progressive disease in patients with atherosclerosis, it is a relatively uncommon cause of hypertension in patients with mild hypertension. Of 834 individuals  $\geq 65$  years old who underwent renal artery duplex ultrasound as part of their cardiovascular health study, the overall prevalence rate of significant renovascular disease was 6.8% [1]. In contrast, renal artery stenosis is more frequent in certain high-risk populations. For example, renovascular stenosis was seen in 30% of patients undergoing screening renal artery angiography at the time of cardiac catheterization [2], in 22–59% of patients with carotid artery and peripheral vascular disease [3], and in 10–45% of white patients with severe or malignant hypertension [4]. Nonwhite patients with severe or malignant hypertension are more likely to have essential hypertension.

#### Pathophysiology

About 90% of all renal stenotic lesions are due to atherosclerosis, which often accompanies systemic atherosclerosis that involves the aortic, coronary, cerebral, or peripheral arteries. Fibromuscular dysplasia (FMD) is the second most common cause of renal artery stenosis and most frequently affects young women, although FMD can occur in either gender at any age.

#### Clinical Cues

Findings that suggest renovascular stenosis are onset of BP  $< 160/100$  mmHg after 55 years of age; a 25% or greater rise in serum creatinine after institution of an ACE

**Table 2.2** Clinical clues to diagnosis of renovascular hypertension<sup>a</sup>

Onset of hypertension before 30 years or severe hypertension after 55 year
Accelerated, malignant, or resistant hypertension
New-onset azotemia or worsening renal function after ACE/ARB Rx
Unexplained atrophic kidney or difference in kidney size >1.5 cm
Sudden, unexplained pulmonary edema
Abdominal systolic diastolic bruit
Multivessel coronary artery disease
Unexplained congestive heart failure
Refractory angina

<sup>a</sup>Adapted from [6]

inhibitor or angiotensin II receptor blocker; moderate or severe hypertension in a patient with a kidney <9 cm in length or a >1.5 cm difference in renal size; recurrent episodes of flash pulmonary edema, resolved by angioplasty or surgical treatment [5]; and an abdominal systolic–diastolic bruit (found in 40% of patients) (Table 2.2). Radiographic studies should be undertaken if clinical history and physical findings are suggestive of renal artery stenosis, BP uncontrolled despite optimal doses of anti-hypertensive medications, and the patient agrees to undergo remedial procedures.

**Primary Diagnostic Tests**

Although renal angiography remains the gold standard for diagnosing renal artery stenosis, less invasive alternative screening procedures such as magnetic resonance angiography (MRA), computed tomographic angiography (CTA), and Duplex Doppler ultrasonography may be appropriate initial steps. However, if findings are inconclusive with these methods, and clinical suspicion is high, renal angiography may be required. MRA is highly sensitive in patients who have clinical characteristics of renal artery stenosis except in those who are likely to have fibromuscular disease, which typically affects the distal two-thirds of the renal artery and its branches, in contrast to atherosclerotic disease which usually involves the ostium and proximal one-third of the main renal artery and the perirenal aorta [7]. The sensitivity and specificity of CTA for detecting stenoses >50% and lesions in the main renal artery is over 90%. Duplex Doppler ultrasonography, which directly visualizes the renal arteries via B-mode imaging and compares the systolic flow velocity in the aorta with that in the renal artery via Doppler, can identify a narrowed artery segment by an increase in flow velocity. In a meta-analysis of 88 studies of 9,974 arteries in 8,147 patients, peak systolic velocity was more accurate than renal-aortic ratio peak systolic velocity, showing a sensitivity of 85% and specificity of 92% [8]. The method has the advantage of being able to detect both unilateral and bilateral renal artery disease, but is time consuming to perform, has a steep learning curve, and is highly operator dependant.

## Ancillary Diagnostic Tests

Selective renal vein renin measurements, plasma renin activity, and renal scintigraphy are not helpful screening tests because of poor sensitivity and specificity, and the need to discontinue antihypertensive agents, including ACE inhibitors, angiotensin II receptor blockers,  $\beta$ -blockers, and diuretics, which may affect plasma renin activity. However, if captopril, 25–50 mg, is administered 1 h prior to the renal scan, blockade of the angiotensin II-mediated decline in GFR in the affected kidney, and an accompanying increase in GFR in the contralateral kidney, may decrease or delay the uptake, or slow the washout of radiolabeled DPTA, hippurate, or MAG3 in the stenotic kidney. Thus, captopril renal scintigraphy may be useful in screening for renovascular stenosis in patients at high risk for renovascular stenosis and in evaluating the hemodynamic significance of a stenotic lesion [6].

## Treatment

Medical therapy with agents that block the renin-angiotensin system (ACE inhibitors and angiotensin II blockers) has been effective in BP control [9]; thiazide diuretics (especially chlorthalidone), calcium channel blockers, and  $\beta$ -blockers may be added, if needed. With medical therapy there is a risk that progression of the stenosis may occur [10]; however, concomitant treatment of dyslipidemia and effective glycemic control in patients with diabetes may mitigate progression of atherosclerosis. Worsening kidney failure during medical therapy appears to be unlikely in unilateral renal artery stenosis [11], but in patients with bilateral renal artery stenosis or stenosis in a solitary functioning kidney deterioration of renal function and mortality risk are greater [12].

Revascularization may be indicated in patients with hemodynamically significant lesions who meet the criteria listed in Table 2.2. The procedure of choice in most centers is percutaneous transluminal angioplasty with stent implantation, particularly with proximal artery or ostial disease [6, 13]. Surgical revascularization would be indicated if angioplasty fails or with multiple small arteries, early branching of the main renal artery, or with coexisting aortic aneurysm or severe aortoiliac disease [6].

## Primary Aldosteronism

### *Pathophysiology*

The two major secretagogues for aldosterone are angiotensin II (AII) and serum  $K^+$  levels. AII signals adrenal glomerulosa cells via G-protein-coupled receptors, which activate  $K^+$  channels to set glomerulosa cell resting membrane potential. Both AII signaling and increased extracellular  $K^+$  cause cell membrane depolarization leading to activation of voltage-gated  $Ca^{++}$  channels. Increased intracellular  $Ca^{++}$ , in turn, stimulates expression of enzymes, such as aldosterone synthase, which are

**Table 2.3** Subtypes of PA (% of cases)

• Bilateral adrenal hyperplasia (IHA)	(60%)
• Aldosterone-producing adenoma (APA)	(35%)
• Unilateral adrenal hyperplasia	(2%)
• Aldosterone-producing adrenocortical carcinoma	(<1%)
• Glucocorticoid-remediable aldosteronism (GRA)	(<1%)
• Ectopic aldosterone-producing adenoma/carcinoma	(<1%)
• Familial hyperaldosteronism (FH type II)	?

required for aldosterone production and also produces glomerulosa cell proliferation. Recently, two loss of function mutations in the gene, *KCNJ5*, which encodes the glomerulosa cell K<sup>+</sup> channel, have been identified in aldosterone-producing adrenal tumors in 8 of 22 patients with primary aldosteronism and a third mutation was found in a father and two daughters with massive adrenal hyperplasia [14]. Excessive aldosterone secretion promotes renal tubular sodium reabsorption, renal K<sup>+</sup> loss, extracellular volume expansion, and hypertension, findings which characterize classical primary aldosteronism (Conn’s syndrome).

*Subtypes of PA*

The most common subtypes of PA are bilateral adrenal hyperplasia (idiopathic hyperaldosteronism or IHA) and unilateral aldosterone-producing adenoma (APA). Less common varieties are given in Table 2.3. Primary adrenal hyperplasia (PAH), characterized by predominantly unilateral micro- or macro-nodular hyperplasia of the adrenal glomerulosa, and adrenal cortical carcinoma are relatively rare causes of PA. Glucocorticoid remediable aldosteronism (GRA, dexamethasone-suppressible hyperaldosteronism, or familial hyperaldosteronism, type I) is a rare, dominantly inherited form of PA, often found in early childhood or adolescence, and associated with an increased incidence of cerebral aneurysms. The disorder results from a “chimeric” gene whose product (located ectopically in the adrenal fasciculata) has actions of both aldosterone synthase and 11β-hydroxylase. In GRA aldosterone secretion is regulated by ACTH, rather than by angiotensin II. Consequently, aldosterone secretion parallels the diurnal variation of ACTH rather than changes in sodium balance, resulting in chronic mineralocorticoid excess and hypertension. Genetic testing of peripheral blood leucocyte DNA is a highly sensitive and specific method for diagnosing GRA [15]. Familial hyperaldosteronism (FH II) due to either IHA or APA is reported to be more common than GRA, but its genetic basis remains to be determined.

The prevalence of PA increases with the degree of hypertension and with resistant hypertension [16]. Patients with PA are at greater risk for cardiovascular events compared to those with comparable blood pressure levels. PA is also associated with increased arterial wall thickness, central artery stiffness, and albumin excretion compared to age-matched controls. Blocking the actions of aldosterone with spironolactone improves survival in older persons with congestive heart failure.

## Diagnosis of PA

### *Screening for PA*

Since the introduction of plasma aldosterone:plasma renin activity (PAC:PRA) ratio in 1981 the prevalence rate of PA has increased from <0.5% to the current 4.6–13% [17]. Newly diagnosed cases have increased more than tenfold; the proportion of IHA cases has risen from 40% to 60%, while APA cases have declined from >70% to 35%; concurrently, the incidence of hypokalemia has decreased from  $\geq 80\%$  to  $\leq 20\%$ .

The morning PAC:PRA ratio has >90% sensitivity and specificity. PAC:PRA is unaffected by posture and antihypertensive drugs, except for amiloride (Midamor) and the mineralocorticoid receptor antagonists, spironolactone (Aldactone) and eplerenone (Inspra), which must be discontinued for at least 6 weeks prior to testing. Angiotensin-converting enzyme inhibitors, angiotensin receptor blockers, and diuretics can be continued; because these agents stimulate renin secretion, suppressed PRA makes underlying PA more likely. Inappropriate elevation of PAC in the face of suppression of renin secretion by adrenergic blockade with  $\beta$ -blockers or central  $\alpha_2$ -agonists is consistent with PA. In hypokalemic subjects raising serum potassium levels into the mid-normal range with potassium supplementation will increase PAC and optimize the PAC:PRA ratio. Table 2.4 lists clinical settings in which screening should be performed in patients with hypertension.

### *Confirming PA*

Techniques to confirm the diagnosis of PA rely on evaluating the effect of volume expansion on the suppressibility of PAC or urinary aldosterone. These consist of:

1. *Oral Salt-loading.* Patients whose hypertension and hypokalemia have been controlled are placed on a high sodium diet for 3 days and given supplementary sodium chloride tablets to achieve a sodium excretion >200 mmol per day. Since high dietary sodium intake may increase potassium excretion, serum potassium must be monitored and replaced as needed. On day 3 aldosterone  $\geq 12$   $\mu\text{g}$  and sodium  $\geq 200$  mmol in a 24-h urine collection indicate autonomous adrenal function.
2. *Intravenous saline infusion.* Unlike normal subjects patients with PA fail to show suppression of PAC with saline infusion. After overnight fasting 2 L of normal saline are infused over a 4-h period. Preexisting left ventricular dysfunction or renal dysfunction may increase the risk for acute volume overload. Postinfusion PAC in normal subjects is <5  $\mu\text{g/dL}$ , whereas patients with PA do not suppress below 10 ng/dL. Patients with IHA may have PAC between 5 and 10 ng/dL.
3. *Fludrocortisone suppression.* Fludrocortisone acetate (Florinef), 0.1 mg every 6 h for 4 days, is given with sodium chloride, 2 g three times daily with meals,

**Table 2.4** Indications to screen for PA

- 
- Hypertension and hypokalemia, spontaneous or diuretic induced
  - Resistant hypertension
  - Blood pressure: systolic  $\geq 160$  or diastolic  $\geq 100$  mmHg
  - Juvenile hypertension
  - Family history of early onset hypertension/hemorrhagic strokes
  - Adrenal incidentaloma
- 

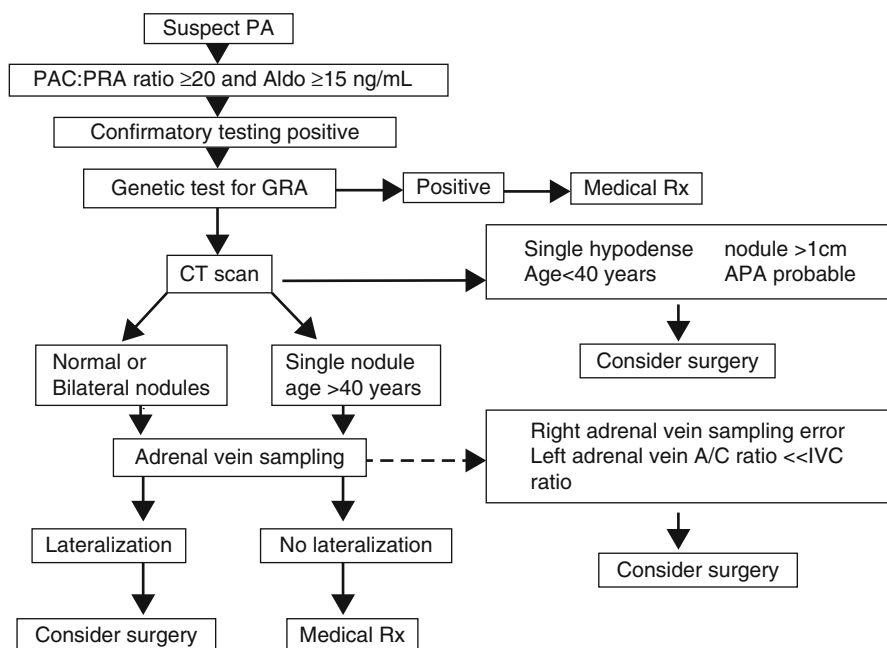
while monitoring BP and serum K<sup>+</sup> daily. Confirmation of PA requires morning upright PAC to be  $\geq 6$  ng/dL on day 4. The association of QT dispersion and left ventricular dysfunction with fludrocortisone testing has discouraged its use.

## Determining Subtype

Subtype diagnosis is critical because unilateral adrenalectomy will correct hypokalemia and improve or normalize blood pressure in up to 60% of patients with APA or PAH, whereas surgery in IHA or GRA is usually ineffective and necessitates lifetime adrenal corticoid replacement therapy.

*Adrenal CT scan.* In a patient <40 years old with PA and a 1–2 cm, unilateral, hypodense, single adenoma, unilateral adrenalectomy should be considered, since nonfunctioning “incidental” adrenal masses are less common in younger patients. However, because adrenal CT often fails to reveal adenomas <1 cm, or may show small bilateral macro- or micro-adenomas, minimal thickening of adrenal limbs, or nonfunctioning adrenal masses in older persons, further testing may be indicated. Patients with “high probability APA” are likely to be younger, more hypertensive, more often hypokalemic, and have higher aldosterone levels than those with IHA.

*Adrenal vein sampling.* Because adrenal CT lacks reliability in differentiating APA from IHA, adrenal vein sampling is necessary in patients who have high probability APA and seek potential surgical cure of hypertension. Aldosterone and cortisol are measured in blood samples obtained from the adrenal veins and inferior vena cava (IVC). Cosyntropin (Cortrosyn) infusion stabilizes cortisol secretion, maximizes the adrenal vein/IVC cortisol gradient, and stimulates aldosterone secretion from an adenoma. A post-cosyntropin adrenal vein/IVC cortisol ratio  $\geq 10:1$  confirms appropriate catheter positioning. Since cortisol secretion is similar from each adrenal the aldosterone/cortisol (A/C ratio) serves as a marker of the dilution of the aldosterone concentration by venous blood. Adrenal vein A/C: ratios  $\geq 4:1$  (affected vs. contralateral adrenal) are consistent with unilateral aldosterone excess (APA or PAH), whereas ratios  $\leq 3:1$  indicate bilateral aldosterone hypersecretion. Because the right adrenal vein is short and angles superiorly, angiographers inexperienced in adrenal vein catheterization may be unsuccessful in cannulating the right adrenal vein. However, in the absence of a right adrenal vein sample, if the left adrenal vein A/C ratio is significantly lower than that of the IVC, a right adrenal source of the aldosterone excess is likely [19]. Pharmacologic treatment should be



**Fig. 2.1** Algorithm for adrenal vein sampling. Young patients (age <20 years) with positive screening and confirmatory tests for hyperaldosteronism should have a genetic test for glucocorticoid-remediable aldosteronism (GRA) if there is a family of hypertension and hemorrhagic strokes. Laparoscopic excision of the adrenal should be considered if CT scan shows a single hypodense nodule >1 cm in persons <40 years of age. Older patients with a unilateral nodule, bilateral nodules, or a normal CT scan require adrenal vein sampling for aldosterone and cortisol. Findings can still be interpreted in the event of failure to obtain a right adrenal vein sample if the inferior vena cava A/C ratio is markedly greater than the left adrenal A/C ratio

considered in clinical settings in which adrenal vein sampling is not available or experience in performing the procedure is lacking. An algorithm showing the diagnostic steps in the differential diagnosis of primary aldosteronism is shown in Fig. 2.1.

<sup>131</sup>I-19-Iodocholesterol adrenal scintigraphy, posture stimulation testing, and measurement of plasma 18-hydroxycorticosterone levels have largely been abandoned because of lack of sensitivity and/or availability.

## Treatment

The goal of treatment is not only to normalize elevated blood pressure and hypokalemia, but also to protect against the adverse cardiovascular effects of aldosterone excess.



*Surgical treatment of APA or PAH.* Unilateral laparoscopic adrenalectomy is preferred over laparotomy because of lower morbidity and shorter hospitalization stays. Preoperative correction of hypokalemia with potassium supplements and/or mineralocorticoid receptor antagonists decreases surgical risk; however, these agents should be withdrawn postoperatively to prevent hyperkalemia. PAC should be determined 1–2 days after surgery to confirm biochemical cure. Short-term fludrocortisone and a liberal sodium intake may be required in the 5% of patients who develop hyperkalemia after surgery.

*Pharmacologic treatment.* Patients with IHA and GRA and those with APA who are not treated surgically should receive mineralocorticoid receptor antagonists. Traditionally, spironolactone is started at 12.5–25 mg per day and titrated to 400 mg per day, if necessary, to raise serum potassium into the high-normal range without oral potassium supplementation. Normalization of elevated blood pressure may take 1–2 months after which spironolactone can be tapered. Spironolactone, by blocking testosterone receptors and stimulating progesterone receptors, may cause gynecomastia, erectile dysfunction, and decreased libido in men and menstrual abnormalities in women. Eplerenone is a selective mineralocorticoid receptor antagonist which has relatively weak binding affinity for testosterone and progesterone receptors. Because eplerenone has a shorter half-life than spironolactone and may be 25–50% less potent on a weight basis, its starting dose is 25 mg twice daily. Patients with IHA frequently require addition of a thiazide diuretic, since hypervolemia may cause resistance to antihypertensive drug therapy.

Treatment of patients with GRA requires treatment with physiologic doses of a shorter acting glucocorticoid, such as prednisone or hydrocortisone. A mineralocorticoid receptor antagonist may be equally effective and may avoid the potential adverse effects of steroid therapy, especially in children.

## References

1. Hansen KJ, Edwards MS, Craven TE, et al. Prevalence of renovascular disease in the elderly: a population-based study. *J Vasc Surg.* 2002;36:443–51.
2. Harding MB, Smith LR, Himmelstein SI, et al. Renal artery stenosis: prevalence and associated risk factors in patients undergoing routine cardiac catheterization. *J Am Soc Nephrol.* 1992;2:1608–16.
3. Zierler RE, Bergelin RO, Polissar NL, et al. Carotid and lower extremity arterial disease in patients with renal artery atherosclerosis. *Arch Intern Med.* 1998;158:761–7.
4. Svetkey LP, Kadir S, Dunnick NR, et al. Similar prevalence of renovascular hypertension in selected blacks and whites. *Hypertension.* 1991;17:678.
5. Pickering TG, Herman L, Devereux RB, et al. Recurrent pulmonary oedema in hypertension due to bilateral renal artery stenosis: treatment by angioplasty or surgical revascularization. *Lancet.* 1988;2:551.
6. Hirsch AT, Haskal ZJ, Hertzner NR, et al. ACC/AHA 2005 practice guidelines for the management of patients with peripheral arterial disease (lower extremity, renal, mesenteric, and abdominal aortic): a collaborative report from the American Association for Vascular Surgery/Society for Vascular Surgery, Society for Cardiovascular Angiography and Interventions,

- Society for Vascular Medicine and Biology, Society of Interventional Radiology, and the ACC/AHA task force on practice guidelines (writing committee to develop guidelines for the management of patients with peripheral arterial disease): endorsed by the American Association of Cardiovascular and Pulmonary Rehabilitation; National Heart, Lung, and Blood Institute; Society for Vascular Nursing; TransAtlantic Inter-Society Consensus; and Vascular Disease Foundation. *Circulation*. 2006;113:e463–654.
7. Safian RD, Textor SC. Renal artery stenosis. *N Engl J Med*. 2001;344:431–42.
  8. Williams GJ, Macaskill P, Chan SF, et al. Comparative accuracy of renal duplex sonographic parameters in the diagnosis of renal artery stenosis: paired and unpaired analysis. *Am J Roentgenol*. 2007;188:798.
  9. Tullis MJ, Caps MT, Zierler RE, et al. Blood pressure, antihypertensive medication, and atherosclerotic renal artery stenosis. *Am J Kidney Dis*. 1999;33:675.
  10. Pohl MA, Novick AC. Natural history of atherosclerotic and fibrous renal artery disease: clinical implications. *Am J Kidney Dis*. 1985;5:A120.
  11. Leertouwer TC, Pattynama PM, van den Berg-Huysmans A. Incidental renal artery stenosis in peripheral vascular disease: a case for treatment? *Kidney Int*. 2001;59:1480.
  12. Chábová V, Schirger A, Stanson AW, et al. Outcomes of atherosclerotic renal artery stenosis managed without revascularization. *Mayo Clin Proc*. 2000;75:437.
  13. van de Ven PJ, Kaatee R, Beutler JJ, et al. Arterial stenting and balloon angioplasty in ostial atherosclerotic renovascular disease: a randomised trial. *Lancet*. 1999;353:282.
  14. Choi M, Scholl UI, Yue P, et al. K + channel mutations in adrenal aldosterone-producing adenomas and hereditary hypertension. *Science*. 2011;331:768–72.
  15. Litchfield WR, Anderson BF, Weiss RJ, et al. Intracranial aneurysm and hemorrhagic stroke in glucocorticoid-remediable aldosteronism. *Hypertension*. 1998;31:445.
  16. Calhoun DA, Nishizaka MK, Zaman MA, et al. Hyperaldosteronism among black and white subjects with resistant hypertension. *Hypertension*. 2002;40:892.
  17. Hiramatsu K, Yamada T, Yukimura Y, et al. A screening test to identify aldosterone-producing adenoma by measuring plasma renin activity. Results in hypertensive patients. *Arch Intern Med*. 1981;141:1589.
  18. Mulatero P, Stowasser M, Loh KC, Fardella CE, et al. Increased diagnosis of primary aldosteronism, including surgically correctable forms, in centers from five continents. *J Clin Endocrinol Metab*. 2004;89:1045.
  19. Young WF, Stanson AW, Thompson GB, et al. Role for adrenal venous sampling in primary aldosteronism. *Surgery*. 2004;136:1227.



<http://www.springer.com/978-1-60327-356-5>

Diabetes and Hypertension

Evaluation and Management

McFarlane, S.I.; Bakris, G.L. (Eds.)

2012, XI, 190 p. 35 illus., 12 illus. in color., Hardcover

ISBN: 978-1-60327-356-5

A product of Humana Press