

Heather A. Hall and Hisham S. Bassiouny

2.1 Introduction

Stroke continues to be a significant cause of morbidity and mortality throughout the world. According to the World Health Organization, 15 million people suffer stroke worldwide annually and of these, 5 million die, and another 5 million are permanently disabled. In the United States, about 795,000 people suffer from stroke, and 143,579 people die from stroke annually. In Canada, stroke accounted for 7% of all deaths in 2000, and in Europe, nearly 650,000 stroke deaths occur per year.^{1–3} Approximately 85% of all strokes are ischemic, and though many are termed cryptogenic, at least 20% of ischemic strokes can be attributed to carotid bifurcation disease.^{4,5}

Atherosclerosis is a systemic disease in which many factors have been implicated in its pathogenesis. These include hypertension, cigarette smoking, diabetes, hyperlipidemia, and hyperhomocysteinemia. The earliest report associating cervical carotid artery disease with stroke was by Savory in 1856, and similar case reports followed, reemphasizing the relationship between carotid artery occlusive disease and stroke.⁶ The frequency of atherosclerotic plaque formation involving the extracranial carotid bifurcation at regions of flow division and low shear stress suggests that fluid dynamics and vessel geometry also play a

key role in the inception of atherosclerotic plaque at such regions. Both in vitro and in vivo models have demonstrated this association between flow dynamics and localization of plaque formation.^{7–10}

Current noninvasive imaging modalities allow for assessment of plaque structural morphology in addition to measuring degree of stenosis. These tools currently allow for detection of plaque formation as well as surveillance of plaque progression and composition and can identify vulnerable plaques potentially at risk for disruption and thromboembolic ischemic cerebral or retinal events.

2.2 Mechanisms of Atherogenesis

2.2.1 Anatomy of the Arterial Wall

Implicit in our understanding of carotid artery bifurcation atherosclerosis pathobiology is knowledge of the structural microanatomy of a normal artery wall. The response of an artery to injury, subsequent changes in the thickness and composition of the arterial wall, and its role in subsequent symptom causation can then be examined. The primary role of the carotid arterial system is to act as a nonthrombogenic conduit for blood flow to the brain and is inherently a highly responsive and adaptive organ.

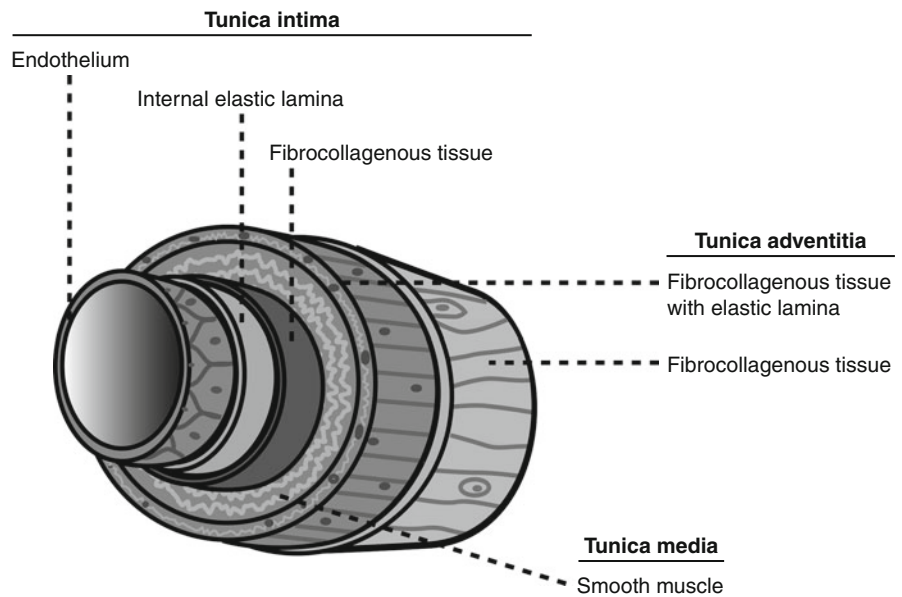
As indicated in Chap. 1, the mural structure of the carotid artery is composed of three layers: the *tunica intima*, *tunica media*, and *tunica adventitia*. Each layer plays a specific and essential role in the overall function of the artery (Fig. 2.1).

The intima, or inner lining of the vessel directly adjacent to blood flow, is an extremely dynamic layer

H.A. Hall
Section of Vascular Surgery, University of Chicago,
Chicago, IL, USA

H.S. Bassiouny (✉)
Department of Surgery, University of Chicago,
Chicago, IL, USA

Fig. 2.1 Mural structure of the carotid artery (Illustration by Matthew Maday)



composed of a monolayer of endothelial cells. Endothelial cells have surface receptors interacting with blood proteins and molecules to regulate vascular permeability as well as playing a key role in platelet aggregation and resistance to thrombosis. The ability of the endothelial monolayer to repair itself and maintain function has a significant role in the development of atherosclerotic plaque. Beneath the intima lies a single layer of elastic fibers forming a matrix called the internal elastic lamina.

The media, or middle layer, is composed of an inner circumferential layer and an outer longitudinal layer of smooth muscle cells surrounded by a matrix of elastin, collagen, and proteoglycans.¹¹ The carotid artery is considered a muscular artery as it has a greater content of smooth muscle cells than central, elastic, arteries. Hemodynamic stresses applied to the wall of the artery as well as the effects of systemic inflammatory molecules impact the media in a way that alters the composition of this layer. Of note, pathologic changes seen in the composition and architecture of the media are largely secondary effects of intimal injury and repair. When the medial layer functions properly, it provides structure but is also important in maintaining vascular tone. In response to alteration in function of the intima, the media responds with proliferation of smooth muscle cells, as well as further promoting the migration of leukocytes and monocytes into this layer. Within the media layer, the derangements of cells and extracellular matrix initiate formation of the carotid plaque (Fig. 2.2).

Beneath the media lies another matrix of elastic fibers, the external elastic lamina, which underlies the adventitial, outer layer of the artery. This layer is remarkably strong, composed mostly of collagen as well as autonomic nerve fibers that extend into the media. While the intima relies on oxygen diffusion from the luminal blood supply, the media obtains oxygen necessary for its function by diffusion from the arterial lumen through the intima luminal blood supply, as well as the vasa vasorum that enter through the adventitial layer.

2.2.2 Response to Endothelial Damage and the Formation of Atherosclerotic Plaque

The term atherosclerosis comes from the Greek *athero*, meaning gruel, and *sclerosis*, meaning hardening. Atherosclerosis begins at the adluminal surface, at the interface between blood and the arterial wall. When physical or metabolic injury disrupts endothelial integrity, the endothelium transduces stress or strain into a biochemical signal. There is an alteration in expression of cellular adhesion molecules (such as VCAM-1 and ICAM) and other surface receptors and a resultant alteration in blood cell adhesion. This results in endothelial cytoskeletal rearrangement and an increase in cell permeability. A simplistic model of intimal disruption is an experimental balloon-injury model,¹² in which platelets adhere to the

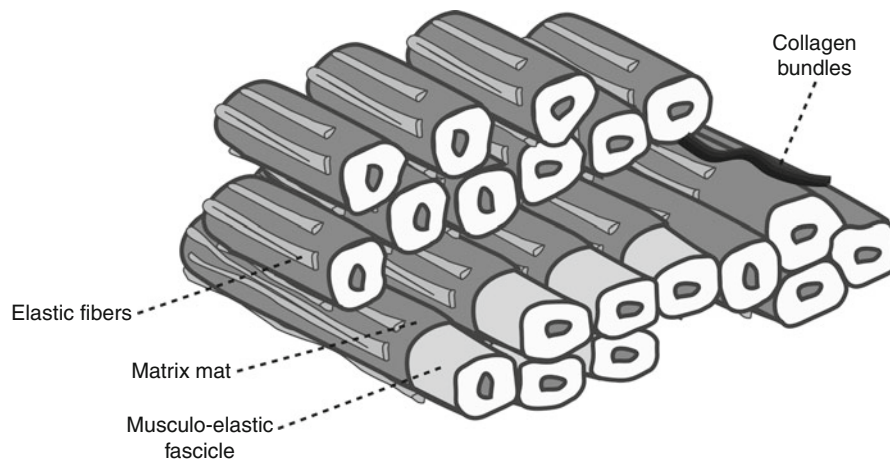


Fig. 2.2 Organization of cells and matrix fibers in the carotid artery. Each musculo-elastic fascicle contains a group of commonly oriented cells, invested by a matrix mat consisting of

basal lamina and a meshwork of collagen fibrils, surrounded by a system of elastic fibers oriented in the same direction (Illustration by Matthew Maday)

disrupted intima and degranulate, releasing cytokines and growth factors which induce vascular smooth muscle cell proliferation and migration from the medial layer to the subintimal space resulting in the formation of a neointima. Factors released and contributing to smooth muscle cell proliferation include platelet-derived growth factor (PDGF), epidermal growth factor (EGF), and transforming growth factor beta (TGF- β).¹³ In addition, the adhesiveness of platelets and subsequent degranulation results in the further recruitment of other inflammatory cells to the area of intimal damage.

As endothelial cell injury becomes more chronic, intimal cells become more permeable to circulating cells. The endothelial monolayer in conjunction with formerly circulating cells, now resident in the media layer, begins to secrete proinflammatory cytokines that participate in attracting various inflammatory cells (such as monocytes, T cells, and macrophages) into the subendothelial layer.^{14,15} The smooth muscle cells of the underlying media respond to these local effects by proliferating, and in the milieu of the forming lesion, smooth muscle cells also begin to alter their function from a contractile to a synthetic phenotype. In addition, there is an alteration in extracellular matrix composition and organization. Macrophages, now within the media, begin to engulf surrounding lipids and become so-called lipid-laden macrophages.^{16–18} While the initial intent of recruiting circulating cells and the subsequent inflammatory cascade is to heal local endothelial injury,

repeated damage results in the formation of a fatty streak and the beginning of an atherosclerotic plaque.

This process begins early in life, and whether or not such early lesions progress to pathologic or even symptomatic lesions may be largely dependent on individual hemodynamic, metabolic, environmental, and genetic risk factors. Persistence of such risk factors perpetuates the inflammatory response and plaque progression. The arterial wall does not thicken after initial injury and smooth muscle cell proliferation, rather only after the smooth muscle cells migrate into the intima.¹⁹ Propagation of the immune response within the wall of the artery, as well as altered smooth muscle cell function, leads to formation of a fibrous cap. Once the fibrous cap forms, the lesion is termed an atheroma, and may protrude into the arterial lumen causing a reduction in luminal diameter or cross-sectional area. An atheroma is an active lesion, producing cytokines and undergoing constant remodeling. Over time, smooth muscle cell proliferation continues, and the production of matrix metalloproteinases (MMPs) is altered such that increases in MMP-9 and MMP-2 remodel the artery and lead to dilation of the arterial segment.^{20,21} This process initially dilates the artery enough to compensate for the luminal loss to plaque (Glagovian remodeling); however over time, this adaptive enlargement to developing plaque is self limited and fails to compensate for luminal loss once plaque occupies more than 40–50% of the cross-sectional area. Further plaque progression can lead to progressive focal arterial stenosis.

2.3 Hemodynamic Force Localization of Plaque at the Carotid Bifurcation

2.3.1 Wall Shear Stress and Other Forces on the Arterial Wall

Hemodynamic forces at the carotid bifurcation play a significant role in the localization of intimal thickening at predictable regions of the vessel wall. The magnitude and rate of change of blood flow at the luminal surface have been closely tied to the pathogenesis of atherosclerotic plaque formation. Laminar flow results in a gradient of fluid velocities as you move from the wall towards the center of a tube. Friction between fluid along the wall and the wall itself creates a tangential force exerted by flowing fluid on the wall of the tube, and this is referred to as “wall shear stress.” The greater the velocity elevation, the greater the wall shear stress. Arterial segments with low and oscillatory wall shear stress appear to be atheroprone. In vivo and in vitro research has shown that disturbed flow and low shear conditions predispose to endothelial dysfunction^{7–10,22} (Fig. 2.3).

Blood flow within a dynamic artery is certainly more complex than laminar flow through a rigid, strictly linear tube. Pulsatile flow due to the cardiac cycle creates what is referred to as “oscillatory shear stress.” An arterial wall is also highly dynamic, and pulsatile flow alters its radius, shape, curvature, and length so that blood flow is not strictly laminar. In addition, when blood flow separates at an arterial bifurcation, there is a complex pattern of fluid velocities. The highest velocities at the center of flow come in contact with the flow divider, and flow

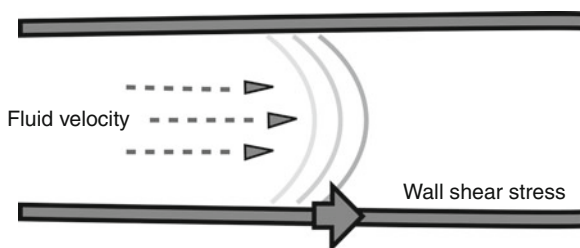


Fig. 2.3 Wall shear stress. Friction between fluid along the wall and the wall itself creates a tangential force exerted on the wall, and this is referred to as “wall shear stress” (Illustration by Matthew Maday)

separation occurs until some distance into the subsequent branches (Fig. 2.4).

2.3.2 Effect of Wall Shear Stress and Other Forces on Endothelial Function and Remodeling

The endothelial monolayer is highly responsive to changes in wall shear stress magnitude and direction. Physiologic variations of shear stress regulate immediate changes in vascular diameter and when sustained induce slow, adaptive, structural-wall remodeling.²¹ These flow-induced forces may act independently of previously mentioned risk factors for atherosclerosis.²³ Changes occur in local concentrations of growth factors, biochemical pathways, gene expression, and cytoskeleton arrangements, and continued remodeling of the vessel wall takes place. Further changes in vessel geometry occur as a result of atheroma

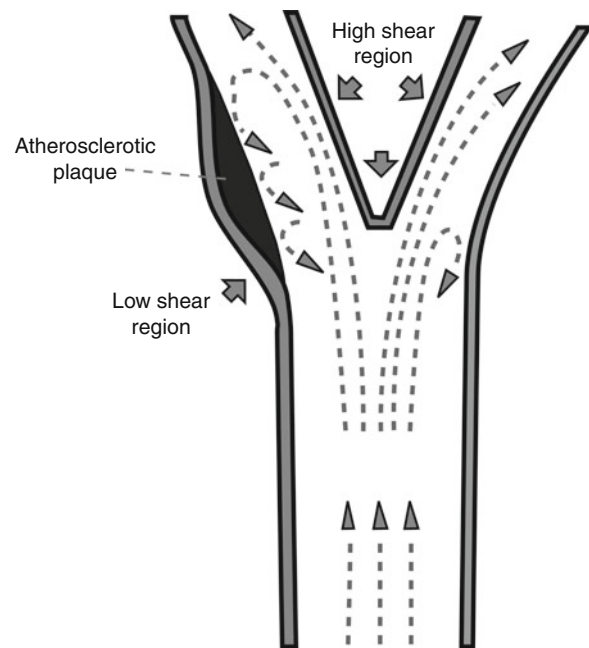


Fig. 2.4 Wall shear stress with boundary layer separation. Blood flow near the center of the artery is laminar. Blood flow near the intima, referred to as the boundary layer, is slower and has more disturbed currents. This is referred to as boundary layer separation. The areas of lower shear force ($< 4 \text{ dyn/cm}^2$) have been found to induce endothelial injury and are, as demonstrated at the carotid bifurcation, typically found on the outer walls at arterial branch points (Illustration by Matthew Maday)

formation, and further modify local near wall shear stress direction, oscillation, and magnitude.

It has long been hypothesized that functional alterations in the endothelial monolayer occur as a result of low wall shear stress and increased residence time of atherogenic blood particles.²⁴ Wall shear stress induces changes in endothelial cell morphology and spatial orientation. Increased wall shear stress causes endothelial cells to elongate and align in the direction of flow, whereas endothelial cells exposed to low wall shear stress remain more rounded and have no preferred orientation.^{25,26} Low wall shear stress may also increase intercellular permeability and consequently increase the vulnerability of these regions of the vessel to atherosclerosis.²⁷

Shear stress not only affects the shape and orientation of the cell, but alters the cell's production and release of vasoactive substances (i.e., prostacyclin, nitric oxide, and endothelin-1). An acute increase in wall shear stress *in vitro* elicits rapid cytoskeletal remodeling and activates a signaling cascade in endothelial cells, with the consequent acute release of endothelial-derived relaxing factor (EDRF), i.e., nitric oxide and prostacyclin.²⁸ Nitric oxide in particular appears to be a key mediator in the atheroprotective effect of high wall shear stress.²⁹ High laminar shear stress sharply reduces endothelial cell levels of precursor preproendothelin mRNA. This decreases the level of endothelin-1 peptide, which exerts a constricting and mitogenic effect on vascular smooth muscle cells.³⁰ Finally, prolonged oscillatory shear stress induces expression of endothelial leukocyte adhesion molecules, which are important in mediating leukocyte localization in the arterial wall.³¹

In summary, high wall shear stress influences the orientation of endothelial cells and the subsequent production and release of factors that inhibit coagulation, permit migration of leukocytes, and induce smooth muscle proliferation, while simultaneously promoting endothelial cell survival. Conversely, low wall shear stress shifts the profile of secreted factors and expressed surface molecules to one that favors the opposite effects, thereby contributing to the development of atherosclerosis.²⁷ This complex endothelial cell response to shear stress may also provide a mechanism by which known risk factors act to promote atherosclerosis.³⁰ In regions of moderate to high shear stress, where flow remains unidirectional and axially aligned, intimal thickening is limited. Intimal

thickening and atherosclerosis develop largely in regions of relatively low wall shear stress, flow separation, and departure from axially aligned, unidirectional flow. Wall shear stress mapping has the potential to become part of the multifactorial, multidisciplinary approach to early atherosclerosis detection, and following plaque progression.

2.4 Progression of Carotid Bifurcation Atherosclerosis

Focal endothelial dysfunction and the formation of fatty streaks within human arterial walls begin at a young age. Many factors influence whether a plaque will continue to grow and develop, become quiescent, rupture, or thrombose. The composition of a plaque and the ongoing presence of physical and biochemical stress influence plaque vulnerability to disruption. The interaction of the flow forces with plaque structural components, such as hard or soft regions, will determine the degree in biomechanical stress on the fibrous cap and likelihood of its structural failure, notwithstanding the role of MMP's in influencing the structural integrity of the fibrous cap extracellular matrix.

The composition and heterogeneity of atherosclerotic plaque influences progression by virtue of ongoing remodeling of the arterial wall.³² Modeling has shown that stress distribution and magnitude are influenced by the shape and the composition of the fibrous plaque.³³ In addition, vulnerable plaques become more susceptible to rupture as the fibrous cap thins with remodeling of the extracellular matrix by metalloproteinases (MMPs) secreted by leukocytes within the intima.^{34,35} The inflammatory response in the juxtaluminal fibrous cap and necrotic core is a key mechanism in human atherosclerotic plaque vulnerability.³⁶ In vulnerable atherosclerotic plaques, the fibrous cap thins out and is more likely to disrupt, resulting in thromboembolic events and cerebrovascular ischemia.³⁷

Inflammation is a key element of atherosclerotic plaque vulnerability and disruption, and fibrous cap inflammation is more likely to occur in noncalcified plaques as compared to calcified plaques, indicating that plaque calcification is a marker of stability.³⁸ Symptomatic plaques are less calcified and more inflamed than asymptomatic plaques.³⁹

2.4.1 How to Assess Carotid Stenosis

2.4.1.1 Arteriography

Arteriography is still considered the “gold standard” for diagnosing carotid artery luminal stenosis against which all other imaging modalities are compared. With defined risks inherent in angiography, there is a perpetual move toward noninvasive evaluation. This shift culminated in investigations by Strandness at the University of Washington, with criteria for estimating carotid stenosis using velocity measurements obtained by duplex ultrasound.⁴⁰ Criteria for carotid stenosis, intervention, and outcomes have been validated in several large trials including the North American Symptomatic Carotid Endarterectomy Trial (NASCET),⁴¹ European Carotid Surgery Trial (ECST),⁴² and the Asymptomatic Carotid Atherosclerosis Trial (ACAS).⁴³ These trials are the basis of current indications for surgical intervention in patients with carotid stenosis. However, it must be mentioned that the data remain marginal for surgical intervention on patients with asymptomatic plaques, given that the number needed to treat is at least 20 patients to prevent one stroke in 5 years.⁴³ It has become clear that stenosis alone is not sufficient to predict which asymptomatic plaques will progress to become symptomatic. Plaque morphology and histobiochemical analysis have emerged as additional factors in assessing plaque at risk. Imaging modalities that remain central to the evaluation of carotid artery disease include angiography, duplex ultrasound, computed tomography angiography (CTA), and magnetic resonance angiography (MRA). Further refinements in these imaging modalities have further altered the data obtainable from each exam. Newer ways of evaluating carotid plaque structural characteristics continue to evolve and allow for identification of features such as extensive necrosis, fibrous cap thinning, and intraplaque hemorrhage. These plaque characteristics connote vulnerability and propensity to embolization, transient ischemic attack (TIA), and stroke.

2.4.1.2 Duplex Ultrasound

Duplex ultrasound has become the screening and diagnostic imaging modality of choice in carotid occlusive disease largely because of its low cost, accuracy, and noninvasiveness. Early studies have arrived at velocity criteria for the diagnosis and classification of carotid disease, and the most widely used in the 1980s and

1990s have been those developed by Strandness and Zweibel^{40,44,45} (Table 2.1). It should be pointed out that the early velocity criteria were developed for stenosis expressed as a percentage of the bulb diameter based on microcalcification on the arterial wall as seen on angiograms and using mechanically rotating transducers. It should also be noted that with modern linear array transducers spectral broadening cannot be used as a criterion. A recent meta-analysis showed that ultrasound was best for more critical lesions, those at least 70% or greater, with a sensitivity of 89% and specificity of 84%. Examination of lesions between 50% and 69% using velocity criteria yielded a sensitivity of only 36% and a specificity of 91%.⁴⁶ Using arteriography as the gold standard, the Strandness criteria are less reliable in patients with contralateral occlusion, high-grade contralateral stenosis, or less than 70% ipsilateral stenosis.⁴⁷ However, for plaques producing moderate or mild stenosis B-mode combined with color flow in cross-sectional views provide accurate measurements of lumen and vessel diameters from which the percentage diameter stenosis can be calculated (see Chap. 28).

An analysis of the Strandness criteria for ICA stenosis (European Carotid Surgery Trial [ECST] method, i.e., in relation to bulb diameter) conducted at the University of Chicago correlated ultrasonographic velocity measurements with CT angiogram measurements. The rationale for the study was to better outline the boundary of the ICA plaque by CT rather than using an estimated line as was done with angiography in developing the Strandness criteria when microcalcification in the arterial wall was not present. The optimal threshold velocity to identify at least a 50% stenosis of the ICA were a PSV of 155 cm/s and an internal carotid artery/common carotid artery (ICA/CCA) ratio of at least two.³⁸ Velocity criteria for a stenosis of at least 80% were found to be peak systolic velocity (PSV) >370 cm/s, end diastolic velocity (EDV) >140 cm/s, and an ICA/CCA ratio of at least 6.0.³⁸

A full description of currently used techniques for grading internal carotid stenosis will be found in Chap. 28.

2.4.1.3 Computed Tomography (CT)

The advancement of high-resolution multidetector CT (MDCT) has allowed CT angiography to be performed to evaluate the carotid bifurcation in a noninvasive

Table 2.1 Summary of the Strandness and Zweibel duplex criteria for ICA stenosis

Strandness Stenosis (%) in relation to bulb diameter	Duplex findings	Zweibel Stenosis (%) in relation to distal ICA diameter	Duplex findings
0	PSV < 125 cm/s No spectral broadening Bulb flow reversal	0	PSV < 110 cm/s EDV < 40 cm/s PSV ICA/CCA <1.8 EDV ICA/CCA <2.4 Spectral broadening < 30 cm/s
1–15	PSV < 125 cm/s No or minimal spectral broadening Bulb flow reversal absent	1–39	PSV < 110 cm/s EDV < 40 cm/s PSV ICA/CCA <1.8 EDV ICA/CCA <2.4 Spectral broadening < 40 cm/s
16–49	PSV > 125 cm/s Marked spectral broadening	40–59	PSV < 130 cm/s EDV < 40 cm/s PSV ICA/CCA <1.8 EDV ICA/CCA <2.4 Spectral broadening < 40 cm/s
50–79	PSV > 125 cm/s EDV < 140 cm/s	60–79	PSV > 130 cm/s EDV > 40 cm/s PSV ICA/CCA >1.8 EDV ICA/CCA >2.4 Spectral broadening > 40 cm/s
80–99	PSV > 125 cm/s EDV > 140 cm/s	80–99	PSV > 250 cm/s EDV > 100 cm/s PSV ICA/CCA >3.7 EDV ICA/CCA >5.5 Spectral broadening > 80 cm/s
100	No flow	100	No flow

fashion. Early studies evaluating this technology were performed with single-slice scanners at a time when resolution was inferior. Currently, however, high-resolution CT scanners can not only evaluate the presence and degree of stenosis but also offer further information regarding plaque morphology and composition. Cinat published a study of eight patients and found a 72.6% agreement between CT assessment of plaque composition and histological examination, and a higher degree of calcification within the plaque improved sensitivity to near 100%.⁴⁸ Conversely, noncalcified components such as necrotic core, lipid volume, intraplaque hemorrhage, and connective tissue confound the ability of CT to accurately determine plaque histopathology. Further studies with larger sample sizes looking at MDCT evaluation of plaque composition may contribute to our understanding of assessing overall plaque risk.

2.4.1.4 Magnetic Resonance Imaging (MRI)

It has been shown that MRI is useful to accurately evaluate plaque size and composition and can thus aid in identifying vulnerable plaques. A study by Takaya et al. prospectively followed 154 patients with initially asymptomatic carotid stenosis by ultrasound for a mean of 38.2 months. MRI was also performed at baseline. Among this group of asymptomatic patients, MRI plaque characteristics including a thin or ruptured fibrous cap, intraplaque hemorrhage, larger lipid-rich necrotic core, and larger maximum wall thickness were all associated with subsequent cerebrovascular events.⁴⁹ This was a small study but does lay the groundwork for larger prospective studies to examine the role of MRI in identifying atherosclerotic plaques at higher risk of causing ischemic events. Although MRI avoids the use of ionizing radiation, the disadvantages associated with this imaging

Table 2.2 Different types of human atherosclerotic lesions in pathology

Terms for atherosclerotic lesions in histological classifications		Appearance of lesions often based on the unaided eye	
Type			
I	Initial lesion		Early lesions
IIa	Progression-prone type II lesion	Fatty dot or streak	
IIb	Progression-resistant type II		
III	Intermediate lesion (preatheroma)		
IV	Atheroma	Atheromatous plaque	
Va	Fibroatheroma (type V lesion)	Fibrolipid plaque, Fibrous plaque, plaque	
Vb	Calcific lesion (type VII lesion)	Calcified plaque	Advanced lesions
Vc	Fibrotic lesion (type VIII lesion)	Fibrous plaque	Raised lesions
VI	Lesion with surface defect, and/or hematoma-hemorrhage, and/or thrombotic deposit	Complicated lesion, complicated plaque	

Source: Adapted from Stary et al.⁵¹

Note: Type I to type Va are early, type Vb advanced, and type Vc and VI are raised lesions

modality make its usefulness in imaging the carotid bifurcation limited in some patients. Long scanning times increase overall motion artifact, and the risk of gadolinium-induced nephrogenic systemic fibrosis can occur in up to 3% of patients with renal insufficiency.⁵⁰

2.4.1.5 Histopathology

Advancements in current imaging modalities are allowing more detailed assessment of carotid plaque characteristics in vivo. Numerous studies are attempting to standardize in vivo appearance on imaging to ex vivo histology evaluation. The American Heart Association has published various reports including one by the Committee on Vascular Lesions of the Council on Arteriosclerosis that defines and classifies advanced types of atherosclerotic lesions based on histology⁵¹ [Chap. 1]. The Committee on Vascular Lesions also attempted to correlate the appearance of lesions on clinical imaging studies with histological lesion types (Table 2.2). Correlation of images to ex vivo plaque is helping advance our understanding of plaque morphology and vulnerability.

2.5 Stroke and Carotid Bifurcation Atherosclerosis

2.5.1 Historical Perspective

One of the earliest reports linking stroke and carotid artery disease was made by Savory in 1856 who reported a case of a young woman with left monocular symptoms and right hemiplegia attributed to occlusion of the left cervical internal carotid artery and bilateral subclavian arteries found at autopsy.⁶ Gowers in 1875 also described left carotid artery occlusion in a patient with a right hemiplegia and loss of sight in the left eye.⁵² Subsequent case reports increasingly linked carotid artery occlusive disease to the development of neurological symptoms, namely, stroke and transient ischemic attacks.⁵³ In a major leap forward, Edgar Moniz developed cerebral angiography in 1927, and in 1937, he described internal carotid occlusion as documented by angiography.^{54,55} Even today, arteriography of the carotid artery and its branches remains the gold standard to which newer imaging modalities are compared.

In 1951, Dr. Fisher published a landmark paper in the history of carotid artery disease in which he described occlusion of the extracranial carotid artery and its relation to cerebrovascular disease.⁵⁶ This included the first description of transient hemispheric attack and monocular vision loss (now termed amaurosis fugax) as attributable to carotid disease and as potential precursors of stroke. Prior to this, some 55% of strokes were attributed to vasospasm. The idea of a carotid bruit as an indicator of underlying carotid disease, and its use as a screening tool for diagnosis was also described by Fisher in 1957.⁵⁷ Dr. Fisher commented in his 1951 paper. . . “Some day vascular surgery will find a way to by-pass the occluded portion of the internal carotid artery during the period of ominous fleeting symptoms.”⁵⁶ Today, it is well accepted that carotid artery occlusive disease is a risk factor for transient ischemic attack (TIA) and stroke, and medical disease modification as well as surgical intervention, carotid endarterectomy, for carotid disease have been shown to provide benefit in reducing the risk of stroke and stroke-related death.

The first successful carotid reconstruction was completed by Carrea in Argentina in 1951, on a 51-year-old man who presented with right hemiplegia and left eye blindness. The patient was diagnosed with severe left internal carotid artery stenosis on a percutaneous carotid angiogram. The stenotic segment of the internal carotid artery was resected, and an end-to-end anastomosis was performed between the external carotid and the distal internal carotid artery. Patency was confirmed by angiogram and the patient regained strength in his right side over time.⁵⁸ Reports of similar operations were reported by others in the coming decade including Eastcott in 1954.⁵⁹ Based on the idea of endarterectomy introduced by Cid dos Santos in 1947 for aortoiliac atherosclerosis,⁶⁰ the first carotid endarterectomy was performed in 1953 by Strully, Hurwitt, and Blankenberg on a patient 2 weeks after the patient had a stroke. There was no back-bleeding from the distal ICA however, and the vessel was ligated.⁶¹ The first successful carotid endarterectomy was performed by DeBakey in 1952, though that particular case was not published until 1975.⁶² Carotid endarterectomy was performed by Cooley, Al-Naaman, and Carton in 1956 and was the first to be published in the literature.⁶³ During this time, other studies showed improvement in patients given anticoagulants for cerebral thrombosis.^{64–66} The

story continues with improvement in medical prevention and treatment of atherosclerotic disease and the current debate over the use of carotid endarterectomy versus carotid artery stenting in the interventional treatment of both symptomatic and asymptomatic carotid artery disease.

2.6 Role of Imaging in Identifying the Vulnerable Asymptomatic Plaque

Stenosis of the carotid artery is noninvasively assessed with duplex ultrasound, as well as by CT-angiography or MR-angiography. However, despite large trials and refinement of criteria, stenosis alone is inadequate in predicting which asymptomatic plaques are at risk for causing cerebrovascular symptoms. Recently, additional data garnered from standard imaging modalities has been investigated to help identify those plaques at risk for causing cerebrovascular symptoms. The development of high-resolution B-mode ultrasound has improved the ability of duplex scanning to evaluate not only severity of stenosis but also morphology of the plaque. Candidate descriptors of carotid plaque morphology include echolucency, calcification, and intraplaque hemorrhage, as well as other characteristics such as plaque volume, surface irregularity, fibrous cap thickness, and the size and location of the necrotic core. Assessing additional plaque features via ultrasound is important for the stratification of high-risk patients.^{67,68}

2.6.1 Echolucency/Gray Scale Median

Carotid atherosclerosis with echolucent plaque is closely related to the occurrence of cerebrovascular events.^{69,70} The more echolucent a plaque on ultrasound, the more likely it is to cause TIA or stroke in the future. Initially, plaque echolucency was subjective and qualitative, thus making it difficult to correlate and attribute risk.^{71–74} Echolucency has been further defined and quantified using the method of image normalization and measurement of the gray scale median (GSM). GSM is a computer-quantified measurement of plaque echolucency,^{75–77} and several studies have shown a correlation between low GSM and plaque instability^{78–80}; (Chaps. 12, 15, 24, 29, 33, 36, 37).

2.6.2 Calcification

Calcification is a relatively common structural feature of the atherosclerotic plaque and is enhanced with advanced age, chronic renal failure, diabetes, and inflammation⁸¹ (Chap. 1). Calcified atherosclerotic plaques are less prone to disrupt and result in symptoms than noncalcified plaques.⁸² This implies that calcification imparts structural stability to the fibrous cap.³⁸ A study of patients undergoing carotid endarterectomy (CEA) found that those patients with calcified carotid plaques had fewer cerebrovascular events than those with noncalcified plaques.⁸³ Grogan et al. showed that using B-mode ultrasound, symptomatic plaques are more echolucent and less calcified than asymptomatic plaques and are associated with a greater degree of histopathologic plaque necrosis.⁸⁴ Calcification, however, is not a normal feature of the aging process, but a dynamic process in the progression of atherosclerosis.^{85,86} It is a result of a complex interplay between inflammatory cytokines and the activation of bone building cells.⁸⁷

The presence and degree of carotid plaque calcification can be accurately quantified with ex vivo CT and is inversely related to plaque macrophage infiltration and symptomatic outcome.³⁹ In vivo quantitative assessment of carotid plaque calcification may help in the future to identify patients with asymptomatic but vulnerable carotid plaques who are at risk for development of cerebrovascular events and benefit from carotid interventions.

2.6.3 Intraplaque Hemorrhage

Intraplaque hemorrhage is a plaque characteristic thought to correlate with symptomatology. The American Heart Association Type VI plaque is characterized by surface irregularity, intraplaque hemorrhage, or thrombus, and is designated as a complicated plaque. Although there is some controversy over whether intraplaque hemorrhage alone is a predictor of future ischemic events, it is a marker of plaque inflammation and instability. A study by Hatsukami et al. looked at 43 plaques from both symptomatic and asymptomatic patients undergoing carotid endarterectomy for highly stenotic lesions and compared histologic findings to preoperative images.⁷³ In this study, they found no difference between symptomatic and

asymptomatic patients with regard to the presence or volume of intraplaque hemorrhage, nor did they see a difference in calcification, fibrous intimal tissue, lipid core, or necrotic core. These findings show a limited use for intraplaque hemorrhage alone as a surrogate for plaque vulnerability. On the contrary, other studies utilizing either ultrasonography or MRI to detect intraplaque hemorrhage have indeed shown intraplaque hemorrhage to be a plaque characteristic that is predictive of cerebrovascular events.^{88,89}

References

- Centers of Disease Control and Prevention [homepage on the Internet]. Atlanta: Centers of Disease Control and Prevention; [cited 2010 Mar 17]. Available from: <http://www.cdc.gov/>
- Roger VL et al. Heart disease and stroke statistics – 2010 update: a report from the American Heart Association. *Circulation*. 2010;121(7):e46–e215.
- Heart and Stroke Foundation of Canada. *The Growing Burden of Heart Disease and Stroke in Canada 2003*. Ottawa: Heart and Stroke Foundation of Canada; 2003.
- Donnan GA, Fisher M, Macleod M, Davis SM. Stroke. *Lancet*. 2008;371(9624):12–23.
- Chaturvedi S et al. Carotid endarterectomy – an evidence-based review: report of the Therapeutics and Technology Assessment Subcommittee of the American Academy of Neurology. *Neurology*. 2005;65:794–801.
- Savory WS. Case of a young woman in whom the main arteries of both upper extremities and of the left side of the neck were throughout completely obliterated. *Med Chir Trans Lond*. 1856;39:205–219.
- Caro CG, Fitz-Gerald JM, Schroter RC. Arterial wall shear stress and distribution of early atheroma in man. *Nature*. 1969;223:1159–1161.
- Friedman MH, Hutchins GM, Barger CB, Deters OJ, Mark FF. Correlation between intimal thickness and fluid shear in human arteries. *Atherosclerosis*. 1981;39:425–436.
- Ku DN, Giddens DP, Zarins CK, Glagov S. Pulsatile flow and atherosclerosis in the human carotid bifurcation: positive correlation between plaque location and low and oscillating shear stress. *Arteriosclerosis*. 1985;5:293–302.
- Zarins CK et al. Carotid bifurcation atherosclerosis: quantitative correlation of plaque localization with flow velocity profiles and wall shear stress. *Circ Res*. 1983;53:502–514.
- Clark J, Glagov S. Transmural organization of the arterial wall. The lamellar unit revisited. *Arteriosclerosis*. 1985;5:19–34.
- Baumgartner HR, Studer A. Consequences of vessel catheterization in normal and hypercholesterolemic rabbits. *Pathol Microbiol*. 1966;29:393–405.
- Bowen-Pope DF, Ross R, Seifert RA. Locally acting growth factors for vascular smooth muscle cells: endogenous synthesis and release from platelets. *Circulation*. 1985;72:735–740.

14. Faggiotto A, Ross R, Harker L. Studies of hypercholesterolemia in the nonhuman primate. *Arteriosclerosis*. 1984;4:323–340.
15. Gerrity RG, Naito HK, Richardson M, Schwartz CJ. Dietary induced atherogenesis in swine. *Am J Pathol*. 1979;95:775–792.
16. Fowler S, Shio H, Haley WJ. Characterization of lipid-laden aortic cells from cholesterol-fed rabbits. IV. Investigation of macrophage-like properties of aortic cell populations. *Lab Invest*. 1979;41:372–378.
17. Schaffner T et al. Arterial foam cells with distinctive immunomorphologic and histochemical features of macrophages. *Am J Pathol*. 1980;100:57–80.
18. Haberland ME, Fong D, Cheng L. Malondialdehyde-altered protein occurs in atheroma of Watanabe heritable hyperlipidemic rabbits. *Science*. 1988;241:215–218.
19. Clowes AW, Ryan GB, Breslow JL, Karnovsky MJ. Absence of enhanced intimal thickening in the response of the carotid arterial wall to endothelial injury in hypercholesterolemic rats. *Lab Invest*. 1976;35(1):6–17.
20. Godin D, Ivan E, Johnson C, Magid R, Galis Z. Remodeling of carotid artery is associated with increased expression of matrix metalloproteinases in mouse blood flow cessation model. *Circulation*. 2000;102:2861–2866.
21. Glagov S. Intimal hyperplasia, vascular remodeling, and the restenosis problem. *Circulation*. 1994;89:2888–2891.
22. Lind L, Andersson J, Larsson A, Sandhagen B. Shear stress in the common carotid artery is related to both intima-media thickness and echogenicity. The Prospective Investigation of the Vasculature in Uppsala Seniors study. *Clin Hemorheol Microcirc*. 2009;43(4):299–308.
23. Gibson CM et al. Relationship of vessel wall shear stress to atherosclerosis progression in human coronary arteries. *Arterioscler Thromb*. 1993;13:310–315.
24. Glagov S, Zarins C, Giddens DP, Ku DN. Hemodynamics and atherosclerosis: insights and perspectives gained from studies of human arteries. *Arch Pathol Lab Med*. 1988;112:1018–1031.
25. Levesque MJ, Nerem RM. The elongation and orientation of cultured endothelial cells in response to shear stress. *J Biomech Eng*. 1985;107:341–347.
26. Levesque MJ, Liepsch D, Moravec S, Nerem RM. Correlation of endothelial cell shape and wall shear stress in a stenosed dog aorta. *Arteriosclerosis*. 1986;6:220–229.
27. Okano M, Yoshida Y. Junction complexes of endothelial cells in atherosclerosis-prone and atherosclerosis-resistant regions on flow dividers of brachiocephalic bifurcations in the rabbit aorta. *Biorheology*. 1994;31:155–161.
28. Ballermann BJ, Dardik A, Eng E, Liu A. Shear stress and the endothelium. *Kidney Int Suppl*. 1998;67:S100–S108.
29. Traub O, Berk BC. Laminar shear stress: mechanisms by which endothelial cells transduce an atheroprotective force. *Arterioscler Thromb Vasc Biol*. 1988;18:677–685.
30. Sharefkin JB, Diamond SL, Eskin SG, McIntire LV, Dieffenbach CW. Fluid flow decreases preendothelin mRNA and suppresses endothelin-1 peptide release in cultured human endothelial cells. *J Vasc Surg*. 1991;14:1–9.
31. Chappell DC, Varner SE, Nerem RM, Medford RM, Alexander RW. Oscillatory shear stress stimulates adhesion molecule expression in cultured human endothelium. *Circ Res*. 1998;82:532–539.
32. Glagov S, Bassiouny HS, Giddens DR, Zarins CK. Intimal thickening: morphogenesis, functional significance and detection. *J Vasc Invest*. 1995;1:1–14.
33. Beattie D, Xu C, Vito R, Glagov S, Whang MC. Mechanical analysis of heterogeneous, atherosclerotic human aorta. *Trans ASME*. 1998;120:602–607.
34. Welgus HG et al. Neutral metalloproteinases produced by human mononuclear phagocytes. Enzyme profile, regulation, and expression during cellular development. *J Clin Invest*. 1990;86(5):1496–1502.
35. Galis ZS, Sukhova GK, Lark MW, Libby P. Increased expression of matrix metalloproteinases and matrix degrading activity in vulnerable regions of human atherosclerotic plaques. *J Clin Invest*. 1994;94(6):2493–2503.
36. Ross R. Atherosclerosis – an inflammatory disease. *N Engl J Med*. 1999;340:115–126.
37. Naghavi M et al. From vulnerable plaque to vulnerable patient: a call for new definitions and risk assessment strategies – part I. *Circulation*. 2003;108:1664–1672.
38. Wahlgren CM, Zheng W, Shaalan W, Tang J, Bassiouny HS. Human carotid plaque calcification and vulnerability. Relationship between degree of plaque calcification, fibrous cap inflammatory gene expression and symptomatology. *Cerebrovasc Dis*. 2009;27:193–200.
39. Shaalan WE et al. Degree of carotid plaque calcification in relation to symptomatic outcome and plaque inflammation. *J Vasc Surg*. 2004;40:262–269.
40. Strandness D Jr. Extracranial arterial disease. In: Duplex Scanning in Vascular Disorders. 2nd ed. New York: Raven; 1993.
41. North American Symptomatic Carotid Endarterectomy Trial Collaborators. Beneficial effect of carotid endarterectomy in symptomatic patients with high-grade carotid stenosis. *N Engl J Med*. 1991;325(7):445–453.
42. European Carotid Surgery Trialists' Collaborative Group. MRC European Carotid Surgery Trial: interim results for symptomatic patients with severe (70–99%) or with mild (0–29%) carotid stenosis. *Lancet*. 1991;337(8752):1235–1243.
43. The Asymptomatic Carotid Atherosclerosis Study Group. Study design for randomized prospective trial of carotid endarterectomy for asymptomatic atherosclerosis. *Stroke*. 1989;20(7):844–849.
44. Zwiebel WJ. Spectrum analysis in carotid sonography. *Ultrasound Med Biol*. 1987;13(10):625–636.
45. Zwiebel WJ. *Introduction to Vascular Ultrasonography*. Philadelphia: W.B. Saunders; 1992.
46. Wardlaw JM, Chappell FM, Best JJ, Wartolowska K, Berry E. Non-invasive imaging compared with intra-arterial angiography in the diagnosis of symptomatic carotid stenosis: a meta-analysis. *Lancet*. 2006;367(9521):1503–1512.
47. AbuRahma AF et al. Effect of contralateral severe stenosis or carotid occlusion on duplex criteria of ipsilateral stenoses: comparative study of various duplex parameters. *J Vasc Surg*. 1995;22(6):751–761.
48. Cinat M et al. Helical CT angiography in the preoperative evaluation of carotid artery stenosis. *J Vasc Surg*. 1998;28:290–300.

49. Takaya N et al. Association between carotid plaque characteristics and subsequent ischemic cerebrovascular events. A prospective assessment with MRI – initial results. *Stroke*. 2006;37:818–823.
50. Issa N et al. Nephrogenic systemic fibrosis and its association with gadolinium exposure during MRI. *Cleve Clin J Med*. 2008;75:95-97. 103-4, 106 passim.
51. Stary HC et al. A definition of advanced types of atherosclerotic lesions and a histologic classification of atherosclerosis, a report from the committee on vascular lesions of the Council on Arteriosclerosis, American Heart Association. *Circulation*. 1995;92:1355–1374.
52. Gowers W. On a case of simultaneous embolism of central retinal and middle cerebral arteries. *Lancet*. 1875;2:794.
53. Hunt JR. The role of the carotid arteries, in the causation of vascular lesions of the brain, with remarks on certain special features of the symptomatology. *Am J Med Sci*. 1914;147(5): 704–712.
54. Moniz E. L'encephalographie arterielle, son importance dans la localisation des tumeurs cerebrales. *Rev Neurol (Paris)*. 1927;2:72-90. [Translated from the French by Espinosa RE and reprinted in: Bruwer AJ. Classic descriptions in diagnostic roentgenology. Springfield: Charles C. Thomas; 1964.]
55. Moniz E, Lima A, de Lacerda R. Par thrombose de la carotide interne. *Presse Med*. 1937;45:977–980.
56. Fisher CM. Occlusion of the internal carotid artery. *Arch Neurol Psychiatry*. 1951;65:346–377.
57. Fisher CM. Cranial bruit associated with occlusion of the internal carotid artery. *Neurology*. 1957;7:299–306.
58. Carrea R, Molins M, Murphy G. Surgical treatment of spontaneous thrombosis of the internal carotid artery in the neck: carotid carotideal anastomosis. *Acta Neurol Latinoam*. 1955;1:71–78.
59. Eastcott HHG, Pickering GW, Robb CG. Reconstruction of internal carotid artery in a patient with intermittent attacks of heiplegia. *Lancet*. 1954;2:994–996.
60. dos Santos JC. Sur la deobstruction des thromboses arterielles anciennes. *Mem Acad Chir*. 1947;73:409–411.
61. Strully KJ, Hurwitt ES, Blankenberg HW. Thromboendarterectomy for thrombosis of the internal carotid artery in the neck. *J Neurosurg*. 1953;10:474–482.
62. DeBakey ME. Successful carotid endarterectomy for cerebrovascular insufficiency; nineteen year follow-up. *JAMA*. 1975;233:1083–1085.
63. Cooley DA, Al-Naaman YD, Carton CA. Surgical treatment of arteriosclerotic occlusion of common carotid artery. *J Neurosurg*. 1956;13:500–506.
64. Hedenius P. The use of heparin in internal diseases. *Acta Med Scand*. 1941;107:170–182.
65. Millikan CH, Siekert RG, Shick RM. Studies in cerebrovascular disease, III: the use of anticoagulant drugs in the treatment of insufficiency or thrombosis within the basilar arterial system. *Proc Staff Meet Mayo Clin*. 1955;30: 116–126.
66. Fisher CM. The use of anticoagulants in cerebral thrombosis. *Neurology*. 1958;8:311–332.
67. Grønholdt ML, Nordestgaard BG, Schroeder TV, Vorstrup S, Sillesen H. Ultrasonic echolucent carotid plaques predict future strokes. *Circulation*. 2001;104:68–73.
68. Hennerici M, Baezner H, Daffertshofer M. Ultrasound and arterial disease. *Cerebrovasc Dis*. 2004;17(suppl 1):19–33.
69. Polak JF et al. Hypochoic plaque at US of the carotid artery: an independent risk factor for incident stroke in adults aged 65 years or older. *Radiology*. 1998;208:649–654.
70. Mathiesen EB, Bønaa KH, Joakimsen O. Echolucent plaques are associated with high risk of ischemic cerebrovascular events in carotid stenosis: the Tromsø study. *Circulation*. 2001;103:2171–2175.
71. Bassiouny HS et al. Juxtaluminal location of plaque necrosis and neof ormation in symptomatic carotid stenosis. *J Vasc Surg*. 1997;26:585–594.
72. Gray-Weale AC, Graham JC, Burnett JR, Byrne K, Lusby RJ. Carotid artery atheroma: comparison of preoperative B-mode ultrasound appearance with carotid endarterectomy specimen pathology. *J Cardiovasc Surg (Torino)*. 1988;29:676–681.
73. Hatsukami TS et al. Carotid plaque morphology and clinical events. *Stroke*. 1997;28:95–100.
74. Carr S, Farb A, Pearce WH, Virmani R, Yao JS. Atherosclerotic plaque rupture in symptomatic carotid artery stenosis. *J Vasc Surg*. 1996;23:755–765.
75. el Barghouty N, Nicolaides A, Bahal V, Geroulakos G, Androulakis A. The identification of the high risk carotid plaque. *Eur J Vasc Endovasc Surg*. 1996;11:470–478.
76. Sabetai MM et al. Reproducibility of computer-quantified carotid plaque echogenicity. Can we overcome the subjectivity? *Stroke*. 2000;31:2189–2196.
77. Lal BK et al. Pixel distribution analysis of B-mode ultrasound scan images predicts histologic features of atherosclerotic carotid plaques. *J Vasc Surg*. 2002;35:1210–1217.
78. Tegos TJ et al. Echomorphologic and histopathologic characteristics of unstable carotid plaques. *Am J Neuroradiol*. 2000;21:1937–1944.
79. Grønholdt MLM, Nordestgaard BG, Wiebe BM, Wilhjelm JE, Sillesen H. Echo-lucency of computerized ultrasound images of carotid atherosclerotic plaques are associated with increased levels of triglyceride-rich lipoproteins as well as increased plaque lipid content. *Circulation*. 1998; 97:34–40.
80. Sabetai MM et al. Hemispheric symptoms and carotid plaque echomorphology. *J Vasc Surg*. 2000;31:39S-49S.
81. Pecovnik-Balon B. Cardiovascular calcification in patients with end-stage renal disease. *Ther Apher Dial*. 2005; 9:208–210.
82. Nandalur KR et al. Calcified carotid atherosclerotic plaque is associated less with ischemic symptoms than is noncalcified plaque on MDCT. *AJR Am J Roentgenol*. 2005;184:295–298.
83. Hunt JL et al. Bone formation in carotid plaques: a clinicopathologic study. *Stroke*. 2002;33:1214–1219.
84. Grogan JK et al. B-mode ultrasonographic characterization of carotid atherosclerotic plaques in symptomatic and asymptomatic patients. *J Vasc Surg*. 2005;42:435–441.
85. Doherty TM, Detrano RC. Coronary arterial calcification as an active process: a new perspective on an old problem. *Calcif Tissue Int*. 1994;54:224–230.
86. Wexler L et al. Coronary artery calcification: pathophysiology, epidemiology, imaging methods, and clinical implications – a statement for health professionals from the

- American Heart Association Writing Group. *Circulation*. 1996;94:1175–1192.
87. Doherty TM et al. Calcification in atherosclerosis: bone biology and chronic inflammation at the arterial crossroads. *Proc Natl Acad Sci USA*. 2003;100:11201–11206.
88. Moody AR et al. Characterization of complicated carotid plaque with magnetic resonance direct thrombus imaging in patients with cerebral ischemia. *Circulation*. 2003;107(24):3047–3052.
89. AbuRahma AF, Kyer PD 3rd, Robinson PA, Hannay RS. The correlation of ultrasonic carotid plaque morphology and carotid plaque hemorrhage; clinical implications. *Surgery*. 1998;124(4):721–726.

<http://www.springer.com/978-1-84882-687-8>

Ultrasound and Carotid Bifurcation Atherosclerosis

Nicolaides, A.; Beach, K.W.; Kyriacou, E.; Pattichis, C.S.

(Eds.)

2012, XVII, 649 p., Hardcover

ISBN: 978-1-84882-687-8