

## 2.1 Introduction

Although facial proportions, angles, and contours vary with age, sex, and race [1], it is worthwhile to consider aesthetic “ideals” when analyzing the face preoperatively and planning surgical rejuvenation. This chapter describes the surface markings of the face, soft-tissue cephalometric points for orientation, and commonly described facial planes and angles. Facial proportions, measurements, and angles that are deemed “ideal” are outlined to facilitate the surgeon with facial analysis and add a quantifiable dimension to perioperative assessment in surgical facial rejuvenation.

## 2.2 Surface Markings

The area anterior to the auricles, from the hairline superiorly to the chin inferiorly, represents the human face (Fig. 2.1). The forehead occupies the upper face, from the hairline to the eyebrows. Its contour, usually convex, is determined by the shape of the underlying frontal bone and distribution of subcutaneous and submuscular fat pads. There is a subtle prominence between the eyebrows called the glabella. Contraction of the procerus and corrugator muscles in this area results in hyperdynamic wrinkles. The eyebrows are positioned horizontally in males, overlying the supraorbital ridges.

In females, the brows arch slightly from medial to lateral, with the highest part ideally in line vertically with the lateral limbus, or between the lateral limbus and lateral canthus.

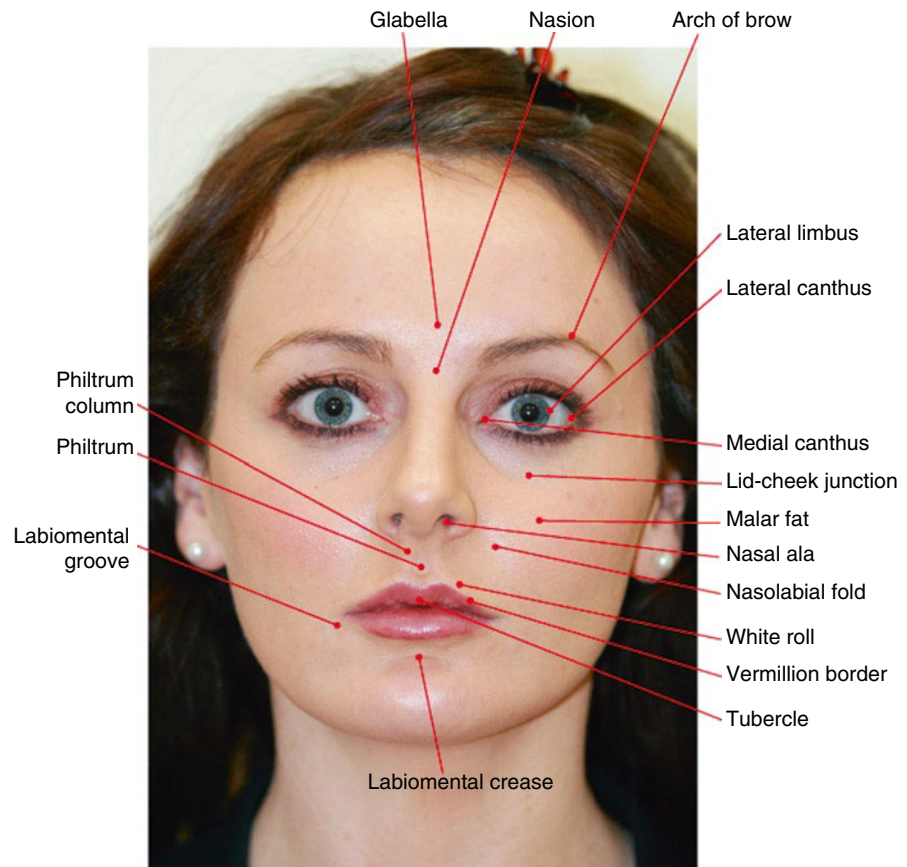
In the midline, several soft-tissue cephalometric points are defined along the midsagittal plane from the glabella superiorly to the cervical point inferiorly (Fig. 2.2). These landmark points are used to describe facial proportions and angles. The external nose is pyramidal in shape with its base sitting over the nasal aperture of the skull. The root of the nose lies inferior to the glabella in the midline, over the frontonasal suture. The nose projects anteriorly and inferiorly from the nasion, or deepest part at the root, to the tip, or apex. The dorsum connects the nasion to the apex and is supported by immobile nasal bone superiorly and mobile cartilage inferiorly. The widest part of the nose consists of the alae, or nostrils, which lead into the nasal vestibule. Centrally, the columella connects the apex of the nose to the philtrum of the cutaneous upper lip. The junction of the red part of the lips with the skin is the vermillion border. Immediately adjacent to the vermillion border is the white roll, a tubelike structure that runs the length of the lip. In the midline, the top lip projects anteriorly as the tubercle. Below the lower lip, the labiomental groove passes between the lip and the chin. Between the alae of the nose and the lateral borders of the lip, the nasolabial groove or fold separates the upper lip from the cheek.

The soft tissue of the upper lateral cheek projects anteriorly over the zygomatic arch and represents a feature of beauty in most cultures. Anteriorly, the convexity of the cheek and smooth lid–cheek junction are attributable to the deep cheek fat compartments below the eye and deep to the cheek muscles. Further down and laterally, the buccal fat pad gives the cheek its roundness, especially in children.

---

P.M. Prendergast  
Venus Medical, Heritage House,  
Dundrum Office Park, Dundrum, Dublin 14, Ireland  
e-mail: peter@venusmed.com

**Fig. 2.1** Surface markings of the face



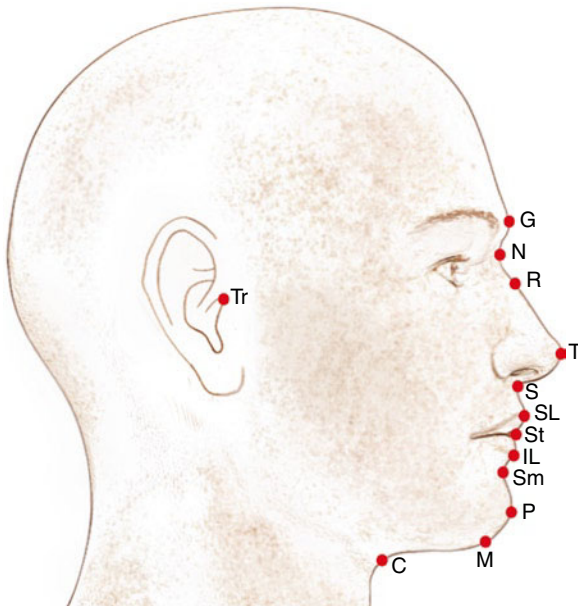
The inferior margin of the face runs from the menton in the midline at the chin, laterally along the inferior and lateral borders of the mandible, to the auricle. Jowl fat and laxity of platysma lead to ptosis and interrupt the definition of the jawline along this margin and are improved with lipoplasty and rhytidectomy.

## 2.3 Proportions

The face is divided into horizontal thirds (Fig. 2.3). The upper third extends from the hairline to the glabella, the middle third from the glabella to the subnasale, and the lower third from the subnasale to the menton. These facial thirds are rarely equal. In Caucasians, the middle third is often less than the upper third, and the middle and upper thirds are less than the lower third [2]. In East Asians, the middle third of the face is often greater than the upper third and equal to the lower third, and the upper third is less

than the lower third [3]. The lower third is further divided into its own thirds, defining the upper lip, lower lip, and chin (Fig. 2.3). Anic-Milosevic et al. [4] compared the proportions of the lower facial third segments in males and females. The chin represented the largest segment and the lower lip height the smallest in both sexes. Although the vermilion height of upper and lower lips did not differ between men and women, the upper and lower lip heights were larger in males. In both genders, the upper vermilion height was smaller than the lower vermilion height. The height of the upper lip vermilion relative to the upper lip was significantly greater in females than in males. The width of the lips should be about 40% of the width of the lower face, and usually equal to the distance between the medial limbi. The width-to-height ratio of the face is typically 3:4, with an oval-shaped face being the aesthetic ideal.

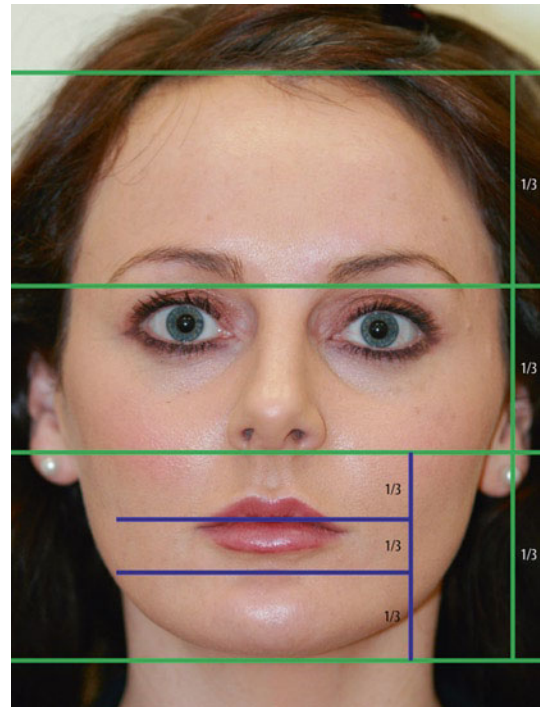
The neoclassical canon of facial proportions divides the face vertically into fifths, with the width of each eye, the intercanthal distance, and the nasal width all



**Fig. 2.2** Soft-tissue cephalometric points. The glabella (*G*) is the most prominent part in the midline between the brows. The nasion (*N*) lies at the root of the nose in the midline. The rhinion (*R*) is the junction of the bony and cartilaginous dorsum of the nose in the midline. The tip (*T*) is the most anterior part of the nose. The subnasale (*S*) is the junction of the columella and upper cutaneous lip. The superior labrum (*SL*) is the junction of the red and cutaneous parts of the lip at the vermillion border in the midline. The stomion (*St*) is the point where the lips meet in the midline. The inferior labrum (*IL*) is the point in the midline of the lower lip at the vermillion border. The supramentale (*Sm*) is midpoint of the labiomentalar crease between the lower lip and chin. The pogonion (*P*) is the most anterior point of the chin. The menton (*M*) is the most inferior point of the chin. The cervical point (*C*) is the point in the midline where the neck meets the submental area. The tragon (*Tr*) is the most superior point on the tragus


measuring one-fifth (Fig. 2.4). However, studies using direct anthropometry and photogrammetric analyses in white and Asian subjects found variations in these proportions, with the width of the eyes and nasal widths often being either less than or greater than the intercanthal distance [2, 3, 5].

Crumley and Lancer describe appropriate projection of the nose and nasal tip [6]. A ratio of 5:4:3 should apply, respectively, to a line from the nasion to the nasal tip, a line from the nasion to the alar crease, and a perpendicular line joining the other two (Fig. 2.5). Nasal tip projection can be measured using other parameters. The Baum ratio is calculated by dividing the length of a line from the nasion to the nasal tip by the length of a perpendicular line from the nasal tip to

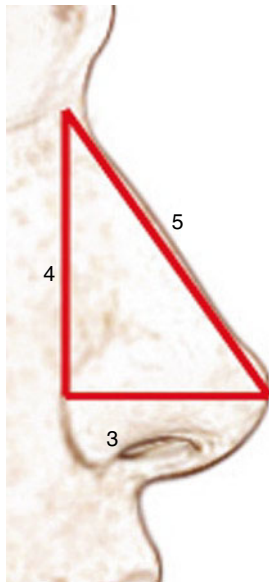


**Fig. 2.3** Horizontal facial thirds. The upper third extends from the hairline to glabella, the middle third from glabella to subnasale, and lower third from subnasale to menton. The lower third is further divided into thirds: the upper third from subnasale to stomion, middle third from stomion to the labiomentalar crease, and the lower third from the labiomentalar crease to menton. These thirds define the upper lip, lower lip, and chin. Note that the thirds are not equal

a vertical line from the subnasale (Fig. 2.6). The Simons ratio also reflects nasal tip projection and is found by dividing the length from the subnasale to the nasal tip by the length from the subnasale to the superior labium (Fig. 2.7). According to Powell and Humphreys [7], the ideal Baum and Simons ratios for whites are 2.8:1 and 1, respectively. The rotation of the nose is described by the nasolabial angle: the angle formed between a line from the anterior columella and the subnasale and a line from the subnasale to the mucocutaneous border of the upper lip. According to Leach [8], this measurement is inaccurate as a representation of nasal rotation if the subject has a protruding maxilla or procumbent incisors. As such, a more accurate measurement is to use a line perpendicular to the Frankfurt horizontal plane in lieu of the subnasale to upper lip line (Fig. 2.8). The basal view of the nose can be divided into thirds with the ratio of the columella to the lobule about 2:1 (Fig. 2.9). Aesthetically,

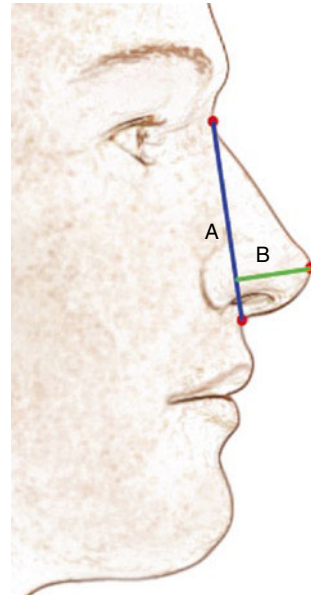


**Fig. 2.4** Vertical fifths. The eye usually measures one-fifth the width of the face

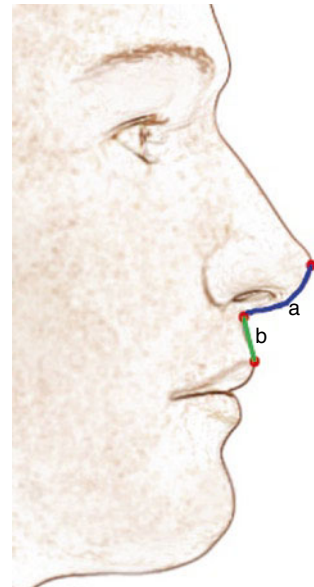


**Fig. 2.5** Nasal proportions

a narrow nasal tip width, measured as a lobule to nasal base ratio, is preferred. Biller's study [9] showed a preference for a nasal tip width ratio of 0.35 in 30-year-old Asian women and 60-year-old white and Asian



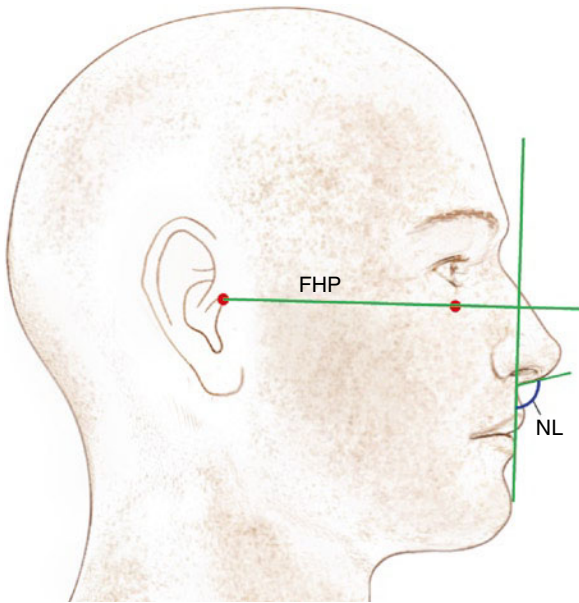
**Fig. 2.6** The Baum ratio used to calculate nasal tip projection. The length of the nose ( $a$ ) divided by a perpendicular line ( $b$ ) from the nasal tip to the line from the nasion to subnasale gives the ratio



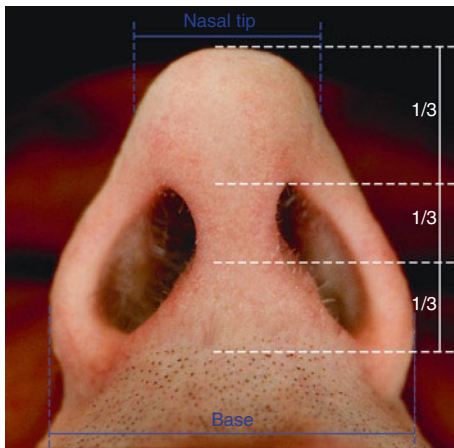
**Fig. 2.7** The Simons ratio used to calculate nasal tip projection. A line from the subnasale along the anterior aspect of the columella to the nasal tip ( $a$ ) divided by a line from the subnasale to the superior labium ( $b$ ) gives the Simons ratio

women, although a ratio of 0.45 was considered more attractive in 30-year-old white women. On basal view, the nasal apertures are usually oriented at an angle of 45–60° to the vertical, although racial variations exist (Fig. 2.10). Abdelkader et al. compared the length and



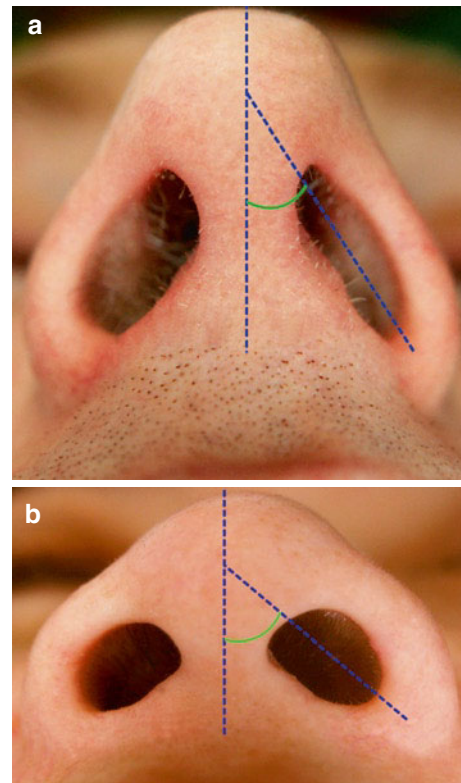


**Fig. 2.8** Nasolabial angle. The Frankfurt horizontal plane (FHP) is found by drawing a line from the superior aspect of the external auditory canal to the most inferior point of the orbital rim. The nasolabial angle is formed between a line along the anterior part of the columella and a line perpendicular to the FHP



**Fig. 2.9** Basal view of the nose. The lobule should represent approximately one-third (upper third) and the columella two-thirds (lower two-thirds) of the basal view. The width of the lobule (nasal tip) should be about 35–45% the width of the nasal base

width of the nasal aperture in men of three racial groups [10]. The nasal aperture was longer at maximum length in the Indian group compared to the Chinese and white groups. There was no significant difference between the length and width of the columella in all three racial groups.

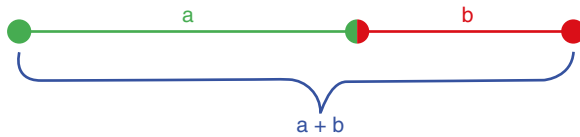


**Fig. 2.10** Orientation of nasal apertures. (a) Caucasian nose showing an angle less than 45° and (b) Chinese nose showing an angle greater than 45°

## 2.4 The Golden Ratio

Beauty and facial attractiveness are easy to identify but difficult to quantify. Despite its subjective nature, we can attempt to define, measure, and explain the captivating phenomenon of beauty by describing it numerically and geometrically [11]. The measurement of aesthetically pleasing features, animate and inanimate, over at least the last two millennia, has produced an extraordinary finding. The same number, or ratio, appears so frequently as a measurement of beauty that it has almost become synonymous with beautiful and harmonious form. This number has been called the golden ratio.

The golden ratio, denoted by the symbol  $\Phi$  (phi), is an irrational number of the order of 1.618033988. The ratio is obtained when a line  $a+b$  is sectioned such that  $a+b/a=a/b$  (Fig. 2.11). Although Indian mathematicians studied the golden ratio over 2,000 years ago, it first appeared in written documentation in Euclid's

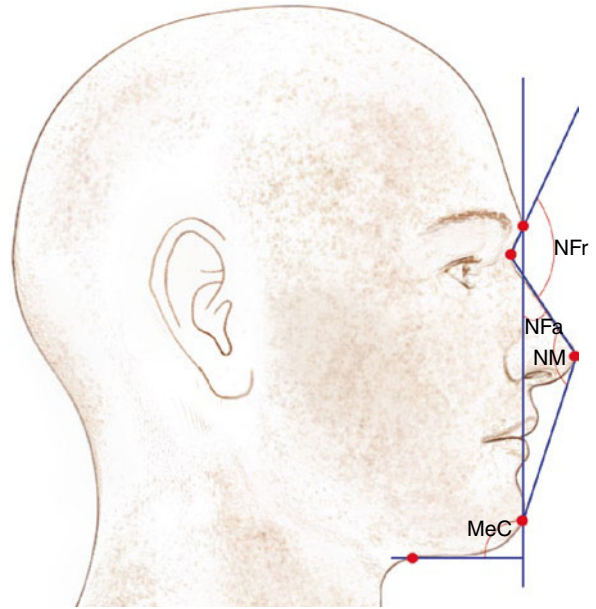


**Fig. 2.11** The golden proportion. A line  $(a + b)$  is sectioned such that  $(a + b)/a = a/b = 1.618033988$

elements about 300 B.C. [12]. The golden ratio, also known as the divine proportion, is considered by many to be the key to the mystery of aesthetics, attraction, and human beauty [13]. From the era of the ancient Greeks, through to the Renaissance, and the present day, mathematicians, scientists, architects, artists, and cosmetic surgeons have been intrigued by the ubiquitous nature of the divine proportion and its correlation with aesthetics. Ricketts showed that the proportions in a face generally perceived as being beautiful are intimately related to the golden ratio [14–17]. The width of the mouth is  $\Phi$  times the width of the nose. The distance between the lateral canthi is  $\Phi$  times the width of the mouth. The height of the face from pupils to chin is  $\Phi$  times the height from the hairline to the pupils. Marquardt devised a mathematical model using  $\Phi$  as the central measurement to map out facial proportions and aesthetically “ideal” shapes and sizes [18]. The result is a “Phi mask” that can be used as a tool to analyze facial beauty and determine its closeness to the aesthetically ideal golden proportion. Despite enthusiasm for the thesis that  $\Phi$  is the Holy Grail in defining beauty and harmony of the human form, Holland [19] reminds us that several studies have not found a relationship between facial attractiveness and the golden ratio. Furthermore, Marquardt’s mask does not represent the ideal female face but rather a masculinized face, with prominent supraorbital ridges, low eyebrows, high cheekbones, and a square jaw. These observations tell us that while the golden proportion is certainly a prominent and recurring theme in aesthetics, it should not be embraced as the only method by which we measure human beauty to the exclusion of other factors.

## 2.5 Planes and Angles

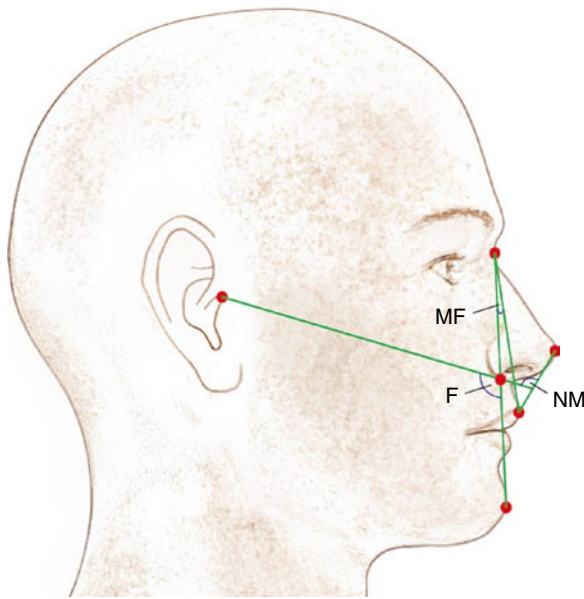
Powell and Humphreys [7] provide a detailed analysis of facial contours, proportions, and angles on profile (Fig. 2.12). These angles facilitate preoperative assessment and planning in facial rejuvenation. The ideal



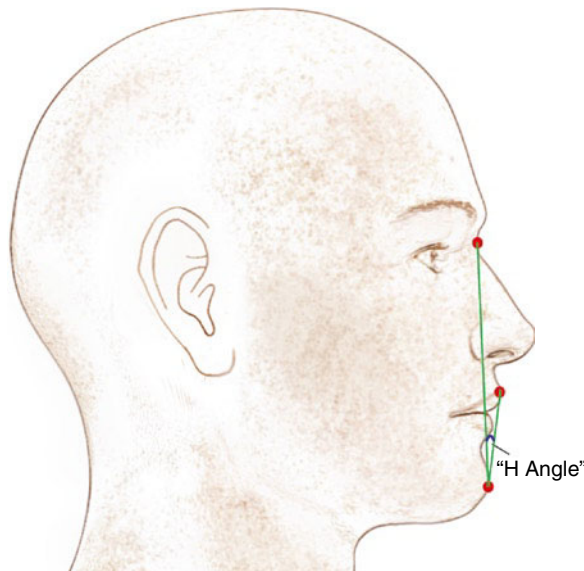
**Fig. 2.12** Powell and Humphreys’ aesthetic angles. A line from the glabella to pogonion creates the anterior facial plane. The angle formed by lines from the nasion to the glabella and from the nasion to the nasal tip is the nasofrontal angle (*NFr*). The nasomental angle (*NM*) lies between the line along the dorsum to the nasion, and a line drawn from the nasal tip to the pogonion. The nasofacial angle (*NFa*) is formed between the anterior facial plane and the line tangent to the dorsum of the nose. A line is drawn from the cervical point to the menton. This line intersects the anterior facial plane to create the mentocervical angle (*MeC*)

ranges in Caucasians are as follows: nasofrontal angle, 115–130°; nasofacial angle, 30–40°; nasomental angle, 120–130°; mentocervical angle, 80–95°. Racial variations include a wider nasofrontal angle in Chinese. The upper and lower lips are usually posterior to the nasomental line in Caucasians, but on or anterior to this line in individuals of African or Asian descent.

Peck and Peck [20] describe another orientation plane formed by a line from the trignon that bisects a line from the nasion to the pogonion (Fig. 2.13). The facial, maxillofacial, and nasomaxillary angles developed from these lines relate the upper lip to the chin and nasal tip and the nasion to the chin. In Caucasians, the mean facial angle as described by Peck and Peck is 102.5°, maxillofacial angle 5.9°, and nasomaxillary angle 106.1°. Holdaway’s “H angle” [21] describes the degree of soft-tissue protrusion of the maxilla relative to the mandible and is ideally about 10° (Fig. 2.14). This angle can be manipulated by surgical intervention on the chin, by lip augmentation, or indeed by orthodontics.



**Fig. 2.13** Peck and Peck's aesthetic angles. A plane is developed by drawing a line from the tragon anteriorly to bisect a line from the nasion to pogonion. The angle created by the intersection of these two lines is the facial angle (*F*). A line dropped from the nasion to the superior labium creates the maxillofacial angle (*MF*) with the line from nasion to pogonion. The nasomaxillary angle (*NM*) relates the upper lip to the nasal tip and arises between a line from the tip to the superior labium and the orientation plane from the tragon



**Fig. 2.14** Holdaway's "H angle." This angle is formed between a line from the nasion to pogonion and a line from the pogonion to the most anterior part of the upper lip. The angle is normally about 10°

## 2.6 Conclusions

Patients often are specific in their request for facial rejuvenation procedures: nose reduction, nose tip elevation, lip enhancement, brow lift, or chin augmentation. Creating the aesthetic "ideal" relies less on site-specific reduction, augmentation, or straightening of facial features and more on a holistic approach, considering each feature as it relates to the rest of the face. The aesthetic surgeon should be mindful of average and ideal proportions and facial angles as they apply to the patient's race so that rejuvenation procedures can be performed with the goal in mind of achieving an attractive and harmonious appearance. Facial proportions and angles are easily determined in the office using photogrammetric analysis. With this information, the surgeon should educate the patient on the role of facial proportions in aesthetics, discuss the most appropriate measures, and tailor a plan to achieve the best results. Once there is an understanding of the importance of proportion in facial aesthetics, the proposed surgical plan is usually more acceptable, even if it deviates from the patient's initial requests.

## References

1. Larrabee WF, Makielski KH, Henderson JL. Variations in facial anatomy with race, sex, and age. In: Larrabee WF, Makielski KH, Henderson JL, editors. *Surgical anatomy of the face*. Philadelphia: Lippincott Williams & Wilkins; 2004. p. 22–8.
2. Farkas LG, Hreczko TA, Kolar JC, Munro IR. Vertical and horizontal proportions of the face in young adult North American Caucasians: revision of neoclassical canons. *Plast Reconstr Surg*. 1985;75(3):328–38.
3. Sim RST, Smith JD, Chan ASY. Comparison of the aesthetic facial proportions of Southern Chinese and white women. *Arch Facial Plast Surg*. 2000;2(2):113–20.
4. Anic-Milosevic A, Mestrovic S, Prlic A, Slaj M. Proportions in the upper lip–lower lip–chin area of the lower face as determined by photogrammetric method. *J Cranio-maxillofac Surg*. 2010;38(2):90–5.
5. Wang D, Qian G, Zhang M, Farkas LG. Differences in horizontal, neoclassical facial canons in Chinese (Han) and North American Caucasian populations. *Aesthet Plast Surg*. 1997;21(4):265–9.
6. Crumley RJ, Lanser M. Quantitative analysis of nasal tip projection. *Laryngoscope*. 1988;98(2):202–8.
7. Powell N, Humphreys B. *Proportions of the aesthetic face*. New York: Thieme-Stratton; 1984.

8. Leach J. Aesthetics and the Hispanic rhinoplasty. *Laryngoscope*. 2002;112(11):1903–16.
9. Biller JA, Kim DW. A contemporary assessment of facial aesthetic preferences. *Arch Facial Plast Surg*. 2009;11(2): 91–7.
10. Abdelkader M, Leong S, White PS. Aesthetic proportions of the nasal aperture in three different racial groups of men. *Arch Facial Plast Surg*. 2005;7(2):111–3.
11. Atiyeh BS, Hayek SN. Numeric expression of aesthetics and beauty. *Aesthet Plast Surg*. 2008;32(2):209–16.
12. Vegter F, Hage J. Clinical anthropometry and canons of the face in historical perspective. *Plast Reconstr Surg*. 2000;106(5):1090–6.
13. Bashour M. History and current concepts in the analysis of facial attractiveness. *Plast Reconstr Surg*. 2006;118(3): 741–56.
14. Ricketts RM. Esthetics, environment, and the law of lip relation. *Am J Orthod*. 1968;54(4):272–89.
15. Ricketts RM. The biologic significance of the divine proportion and Fibonacci series. *Am J Orthod*. 1982;81(5): 351–70.
16. Ricketts RM. The golden divider. *J Clin Orthod*. 1981;15(11):752–9.
17. Ricketts RM. Divine proportion in facial aesthetics. *Clin Plast Surg*. 1982;9(4):401–22.
18. Marquardt SR. Dr Stephen Marquardt and the golden decagon of human facial beauty. Interview with Dr Gottlieb. *J Clin Orthod*. 2002;36(6):317–8.
19. Holland E. Marquardt's phi mask: pitfalls of relying on fashion models and the golden ratio to describe a beautiful face. *Aesthet Plast Surg*. 2008;32(2):200–8.
20. Peck H, Peck S. A concept of facial esthetics. *Angle Orthod*. 1970;40(4):284–318.
21. Holdaway R. A soft tissue cephalometric analysis and its use in orthodontic treatment planning. Part II. *Am J Orthod*. 1984;85(4):279–93.



<http://www.springer.com/978-3-642-17837-5>

Advanced Surgical Facial Rejuvenation

Art and Clinical Practice

Erian, A.; Shiffman, M.A. (Eds.)

2012, XIV, 740 p. 653 illus., 620 illus. in color.,

Hardcover

ISBN: 978-3-642-17837-5