

Chapter 2

History of the Origin of Ankylosing Spondylitis

2.1 Introduction

There is always a continuous debate about the origin and early detection of a disease. This is inevitable as diagnoses and labels change over time, and this problem also occurs with ankylosing spondylitis. Multiplicity of diagnostic labels is certainly a problem with ankylosing spondylitis, and in a recent review of this condition, it was described by 20 different names over the last two centuries (Benedek 2009).

Diseases associated with infections may eventually progress to an overt rheumatological disorder as occurs in 'Gram-negative reactive arthritis'.

Palaeohistorical evidence provides only limited material on which to make a diagnostic assessment, and therefore the hunt for the first sighting of a disease becomes a rather problematic enterprise.

2.2 Ankylosing Spondylitis and the Egyptian Pharaohs

It has been suggested that among the pharaohs of the eighteenth and nineteenth dynasty there were at least three rulers who may have had ankylosing spondylitis based on radiological examinations: Amenhotep II, Ramses II the Great and his son Mereptah (Feldtkeller et al. 2003).

However a reappraisal by Canadian radiologists proposed that the findings suggested 'diffuse idiopathic skeletal hyperostosis' (DISH) and not ankylosing spondylitis in the skeleton of Ramses II (Chem et al. 2004).

2.3 Ankylosing Spondylitis in the Middle Ages

A comprehensive review of 560 adult skeletons, with at least part of the vertebral column intact, on remains gathered from various churches and cemeteries including the bones of 7 Saxon bishops interred in Wells Cathedral were examined by a group from Bristol (Rogers et al. 1985).

Nearly half of the skeletons examined had some degree of spinal osteophytosis, but despite the large number of specimens examined, only two cases of spondyloarthritis could be identified.

A medieval adult male skeleton from Bath Abbey showed axial changes including bilateral ankylosis of sacroiliac joints and ankylosis between T7 and L1. Spinal syndesmophytes were asymmetrical and predominantly anterior lateral.

'Diffuse idiopathic skeletal hyperostosis' (DISH) was found in 2.3 % of specimens and this is similar to the rate found in Finnish patients (Julkunen et al. 1968).

2.4 Ankylosing Spondylitis and Realdo de Colombo

Probably the first suggestive sighting of an ankylosing spondylitis skeleton occurred in Italy. Realdo de Colombo was an assistant to Andreas Vesalius and later became Professor of Anatomy in the University of Padua. The University is one of the oldest in Europe having been founded in 1222. In 1559, Realdo de Colombo produced anatomical descriptions of two skeletons typical of ankylosing spondylitis in his book *De Re Anatomica*.

Spinal kyphosis could not have been a rare occurrence in those times since the surgeon Johannes Scultetus (1595–1645) described horrendous contraptions to straighten a kyphotic patient.

2.5 Connor's Observations in France

The first definite description of ankylosing spondylitis may be credited to Bernard Connor (1666–1695) who described an unusual skeleton.

Bernard Connor was born in county Kerry in Ireland, attended the medical schools of Paris, Montpellier and Rheims, where he received his M.D.

Whilst demonstrating anatomy in France, he came across a most peculiar skeleton, found in a graveyard in Rheims, in which the sacrum and the 15 lowest vertebrae and adjoining ribs form one continuous bone.

Connor fully realised the importance of his discovery and reported it in three languages; in French in a letter published in Paris to Sir William de Waldegrave in 1691 (Fig. 2.1), in Latin published in Oxford and in English in his Rheims thesis which was published by the Royal Society in 1695.

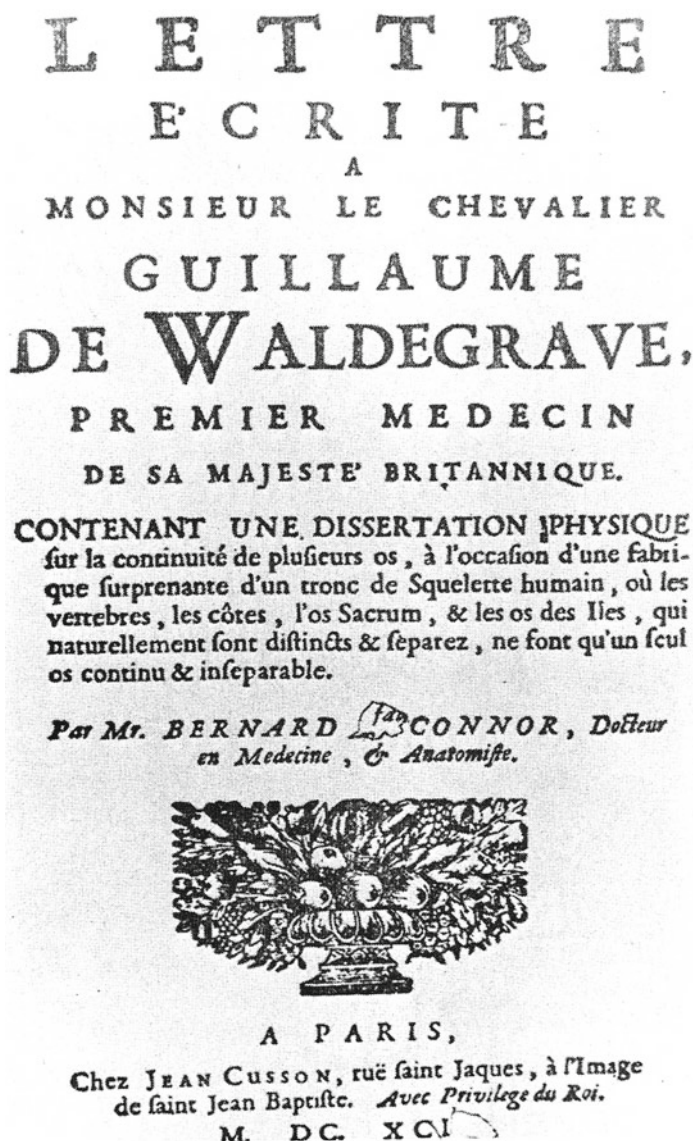


Fig. 2.1 Title page of letter from Connor to Sir William Waldegrave (Courtesy of the Editor, *Journal of History of Medicine*, as quoted by E. Bywaters)

He surmised that the man must have had difficulty in walking or turning and in view of his fused ribs could only have abdominal or diaphragmatic breathing. Connor died rather young, but he had made a significant contribution to the history of rheumatology and medicine.

2.6 The Eighteenth Century in Europe

A second human spine similar to Connor's was discovered in Coburg in Germany by three students whilst on a botanical excursion, and the find was promptly published by their Professor Johann Sebastian Albrecht in 1748.

2.7 The Nineteenth Century in London

There were several descriptions of ankylosing spondylitis in the nineteenth century in London:

1. *Sir Benjamin Brodie's case*

Sir Benjamin Brodie (1783–1862) described in 1850, a case of a man whose disease started when he was 27 years old, becoming completely rigid within 6 years, had a long continued rheumatism of the spine, with a 'hoop-like' deformity and occasionally suffering from inflammation of the eyes.

This would appear to be the first reported case of uveitis in a patient with ankylosing spondylitis.

2. *Charles Fagge's case*

The first correlation of clinical and pathological findings was by Charles Fagge (1838–1883), a clinician at Guy's Hospital who in 1877 described a man of 34 years, with a cough, a rigid curved spine and fixity of the ribs, breathing exclusively with his abdomen (Fagge 1877). 'His dorsal vertebrae formed one large rounded curve, with little or no movement. He had but slight power of moving his neck; the ribs also seemed quite fixed'. When he did the autopsy, he found not only ankylosis of the vertebral bodies, but also fixed apophyseal joints, ribs and a rigid right hip joint as well as upper lobe fibrosis, bronchiectasis and a cardiac valve lesion.

3. *W. Sturge's case*

In 1858, W. Sturge (1850–1919) gave a detailed description of a man of 26, with a fixed spine and chest, starting at the age of 18 with back pain, urethritis and iritis. Clearly, this is an early sighting of Reiter's disease.

2.8 Bechterew in St. Petersburg

Vladimir Bechterew (1857–1927) was a neurologist who in 1892 described three patients: a mother and daughter and a man who had sometime in the past incurred some trauma to his back.

These were his conclusions:

Based on the clinical data we may assume that we are dealing with a chronic process of the vertebrae that develops independently and leads to ankylosis. It also probably leads to a diffuse, chronic inflammation of the epidural connective tissue. One must also consider that

the presentation of our cases resembles spondylitis deformans. The process on the one hand leads to expanding intervertebral rigidity and on the other pressure on the nerve roots.

This sufficiently explains the rigidity or stiffness of the vertebral column, as well as the sensory symptoms of the spinal nerve roots, the weakness and mild atrophy of the neck and back muscles, as well as the weakness of the muscles of upper extremities that is sometimes observed (Bechterew 1899).

Although Bechterew favoured a neurological explanation for the disease, a myelopathy, his observation of a mother and daughter being affected, suggested to him that there was also a genetic predisposition to the condition.

2.9 Strümpell in Erlangen and Berlin

Adolph Strümpell (1853–1925), in 1897, described two patients with complete ankylosis of the spine and of both hip joints. He also emphasised that lumbar lordosis in a rigid spine was a prominent feature and published dramatic photographs of such patients.

Strümpell suggested the disease should be labelled in more descriptive terms as 'chronic inflammation of the large joints and vertebral column', without mentioning the neurological features favoured by Bechterew.

2.10 Pierre Marie and Léri in France

It is now generally agreed that Pierre Marie (1853–1940) has given the most detailed and characteristic clinical description of ankylosing spondylitis (Bywaters 1983) and coined the word 'spondylose rhizomélisque'. He gave detailed descriptions of six male patients.

He worked as an assistant to Jean Marie Charcot at the Salpêtrière Hospital before becoming Professor of Neurology.

Léri, Marie's assistant, described the full pathological characteristics of ankylosing spondylitis after he had carried out autopsies on two of Pierre Marie's patients. His conclusions anticipated modern developments.

'La spondylarthrite ankylosante est une maladie avec certaines propriétés: C'est un trouble trophique à développement lent, sans doute parfois diathésique et probablement souvent infectieux ou toxico-infectieux (Léri 1926).'

A prophetic statement anticipating the HLA-B27 discoveries of the 1970s.

2.11 Buckley's Observations in the 1930s

Charles Buckley said in 1935, 'The cause of ankylosing spondylitis is an infection of low virulence, acting for prolonged period and sensitising certain tissues' (Buckley 1935).

2.12 The Heart and Ankylosing Spondylitis

Original studies of heart disease in ankylosing spondylitis included six cases of aortic incompetence, but this was attributed to probable antecedent rheumatic fever.

However, association between ankylosing spondylitis and aortic incompetence occurred serendipitously in 1956, when the first 100 patients into whom Charles W Hufnagel had inserted a prosthetic aortic valve were reviewed, and it was found that five had ankylosing spondylitis, a frequency which was recognised to be far greater than could be attributed to chance (Schilder et al. 1956).

2.13 Diagnostic Help from Physics

Roentgen had developed X-rays in 1896. The first spines showing ankylosing spondylitis were taken by Beneke in 1897.

Since that time refinements and new developments in diagnostic methods, such as magnetic resonance imaging and computerised tomography, have assisted in characterising the early stages of the disease (Sieper et al. 2002).

2.14 Conclusion

Although the recognition of advanced ankylosing spondylitis with patients having rigid spines took some time to be of interest to anyone else but specialised rheumatologists, immunology threw a bombshell into this field by the pre-eminent discovery of HLA-B27 in 1973.

References

- Bechterew W. Neue Beobachtungen und pathologische-anatomische Untersuchungen über Steifigkeit der Wirbelsäule. *Deut Ztschr Nervenheilk.* 1899;15:45–57.
- Benedek TG. How did ankylosing spondylitis become a separate disease? *Clin Exp Rheumatol.* 2009;27 Suppl 55:S3–9.
- Buckley CW. Ankylosing spondylitis. In: *Reports on chronic rheumatic diseases.* London: Lewis; 1935. p. 77–89.
- Bywaters E. Historical perspectives in the aetiology of ankylosing spondylitis. *Br J Rheumatol.* 1983;27 Suppl 2:1–4.
- Chem RK, Schmit P, Fauré C. Did Rameses II really have ankylosing spondylitis ? A reappraisal. *Can Assoc Radiol J.* 2004;55:211–7.
- Fagge CH. A case of simple synostosis of the ribs to the vertebrae and of the arches and articular processes of the vertebrae themselves and also of one hip joint. *Trans Pathol Soc Lond.* 1877;28:201–6.

- Feldtkeller E, Lemmel EM, Russell AS. Ankylosing spondylitis in the Pharaohs of ancient Egypt. *Rheumatol Int.* 2003;23:1–5.
- Julkunen H, Pyöralä K, Lehtaurirta F. Hyperostosis of the spine in relation to age and hyperglycaemia in men aged 30–60. *Ann Med Intern Fenn.* 1968;57:1–7.
- Léri A. *Études sur les affections de la colonne vertébrale.* Paris: Masson; 1926.
- Rogers J, Watt I, Dieppe P. Paleopathology of spinal osteophytosis, vertebral ankylosis, ankylosing spondylitis and vertebral hyperostosis. *Ann Rheum Dis.* 1985;44:113–20.
- Schilder DP, Harvey WP, Hufnagel CA. Rheumatoid spondylitis and aortic insufficiency. *N Engl J Med.* 1956;255:358–61.
- Sieper J, Braun J, Rudwaleit M, Boonen A, Zink A. Ankylosing spondylitis: an overview. *Ann Rheum Dis.* 2002;61(Suppl III):iii8–18.

Ankylosing spondylitis and Klebsiella

Ebringer, A.

2013, XX, 256 p., Hardcover

ISBN: 978-1-4471-4299-7