

Chapter 2

The Human Respiratory System

2.1 Anatomy and Structure

Respiration is the act of breathing, namely inhaling (inspiration) oxygen from the atmosphere into the lungs and exhaling (expiration) into the atmosphere carbon dioxide [53]. The respiratory system is made up of the organs involved in breathing, and consists of the nose, pharynx, larynx, trachea, bronchi, and lungs, as depicted in Fig. 2.1.

The respiratory system can be divided into two major parts: the upper airways part and the lower airways part. The upper respiratory tract includes the nose, with its nasal cavity, frontal sinuses, maxillary sinus, larynx, and trachea. The lower respiratory tract includes the lungs, bronchi and the alveoli.

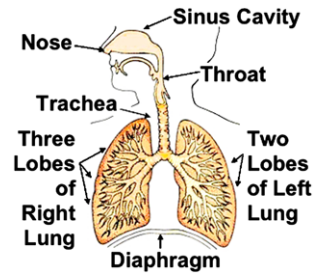
The lungs take in oxygen, which is required by all the cells throughout the body to live and carry out their normal functions. The lungs also get rid of carbon dioxide, a waste product of the body's cells. The lungs are a pair of cone-shaped organs made up of spongy, pinkish-gray tissue. They take up most of the space in the chest, or the thorax (the part of the body between the base of the neck and diaphragm).

The lungs are separated from each other by the mediastinum, an area that contains the following:

- heart and its large vessels;
- trachea;
- esophagus;
- thymus;
- lymph nodes.

The right lung has three sections, called lobes. The left lung has only two lobes. When one breaths, the air enters the body through the nose or the mouth, travels down the throat through the larynx (voice box) and trachea (windpipe) and goes into the lungs through the tubes called main-stem bronchi. One main-stem bronchus leads to the right lung and the other one leads to the left lung. In the lungs, the main-stem bronchi divide into smaller bronchi and then into even smaller tubes called bronchioles, which finally end in tiny air sacs called alveoli. At this level, the act of

Fig. 2.1 Schematic representation of the respiratory system and its main components



diffusion takes place. Diffusion allows the oxygen from the alveoli to pass through the alveolar walls into the blood and the carbon dioxide to pass through the capillary walls into the alveoli.

In order to move air in and out of the lungs, the volume of the thoracic cavity is increased (or decreased). The lungs do not contract but increase or decrease in volume. Muscles like intercostals or diaphragm contract during inspiration. Normally, the expiration is passive, the inspiration is active (= contraction of muscles). By increasing the thoracic cavity, the pressure around the lungs decreases, the lungs expand, and air is sucked in.

2.2 Morphology

In the literature, there are two representative sets of airway morphological values: the symmetric case and the asymmetric case of the respiratory tree, schematically depicted in Fig. 2.2. The *symmetric* case assumes a dichotomously equivalent bifurcation of the airways in subsequent levels and is agreed by a group of authors e.g. [97, 135, 164] as in Table 2.1. The *asymmetric* case is when the bifurcations are still dichotomous, but they occur in non-sequent levels, as given in Table 2.2. The parameter Δ denotes the asymmetry index. In this case, a parent airway will split into two daughters: one of subsequent level $m + 1$ and one of level $m + 1 + \Delta$. This latter anatomical context is agreed by another group of authors: [54, 65].

2.3 Specific Pulmonary Abnormalities

Chronic Pulmonary Emphysema refers to a class of respiratory disorders which implies the existence of excess air in the lungs [6, 53, 64]. It results from three major pathophysiological events in the lungs:

- chronic infection, caused by inhaling smoke or other substances that irritate the bronchi and bronchioles;
- the infection, the excess of mucus, and inflammatory edema of the bronchiolar epithelium together cause chronic obstruction of smaller airways;

Fig. 2.2 A very brief schematic representation of the bronchial tree: generations 1–16 transport gas and 17–24 provide gas exchange [97, 135, 164]. This is not an accurate anatomical representation and it is modified with respect to numbering from the original Weibel model [164]. The notation implies here the number of levels and, as described later in this book, the number of elements in an analogy to electrical ladder networks

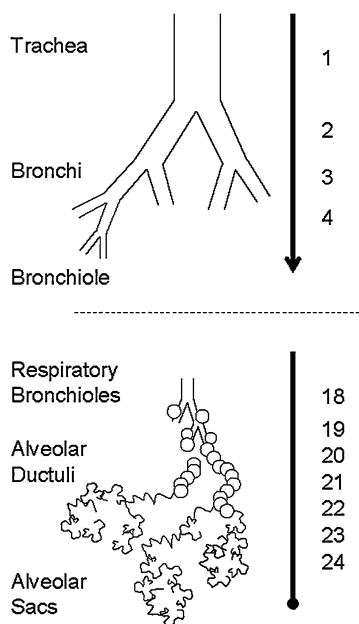
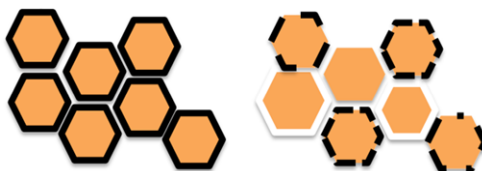

Fig. 2.3 A schematic representation of alveolar tissue in normal lungs (*left*) and disrupted alveolar walls in emphysematous lungs (*right*)



- the obstruction of the airways makes it especially difficult to expire, causing entrapment of air in the lungs (i.e. barrel chest effect) and over-stretching the alveoli.

The physiological effects of chronic emphysema are extremely varied, depending on the severity of the disease and on the relative degree of bronchiolar obstruction versus parenchymal destruction at the alveolar level. A schematic representation of tissue samples can be observed in Fig. 2.3.

The bronchiolar obstruction causes increased airway resistance and results in greatly increased work of breathing. It is especially difficult for the person to move air through the bronchioles during expiration, because the compressive force on the alveoli acts also on the bronchi, further increasing their resistance during expiration. Another physiological effect is that of a decreased diffusive capacity, from the marked loss of lung parenchyma (see Fig. 2.3 on the right). This will reduce the ability of the lungs to oxygenate the blood and to remove the carbon dioxide. Another effect is that of abnormal ventilation-perfusion ratio, i.e. portions of the lungs will be well ventilated, while others will be poorly ventilated, depending on the degree of the obstructive process. Chronic emphysema progresses slowly over many years, leading to necessity of ventilatory assist devices and finally to death.

Table 2.1 The tube parameters for the sub-glottal airways depths, whereas depth 1 denotes the trachea and depth 24 the alveoli, as used in [59, 66, 85, 97, 100, 164]

Depth m	Length ℓ (cm)	Radius R (cm)	Wall thickness h (cm)	Cartilage fraction κ
1	10.0	0.80	0.3724	0.67
2	5.0	0.6	0.1735	0.5000
3	2.2	0.55	0.1348	0.5000
4	1.1	0.40	0.0528	0.3300
5	1.05	0.365	0.0409	0.2500
6	1.13	0.295	0.0182	0.2000
7	1.13	0.295	0.0182	0.0922
8	0.97	0.270	0.0168	0.0848
9	1.08	0.215	0.0137	0.0669
10	0.950	0.175	0.0114	0.0525
11	0.860	0.175	0.0114	0.0525
12	0.990	0.155	0.0103	0.0449
13	0.800	0.145	0.0097	0.0409
14	0.920	0.140	0.0094	0.0389
15	0.820	0.135	0.0091	0.0369
16	0.810	0.125	0.0086	0.0329
17	0.770	0.120	0.0083	0.0308
18	0.640	0.109	0.0077	0.0262
19	0.630	0.100	0.0072	0.0224
20	0.517	0.090	0.0066	0.0000
21	0.480	0.080	0.0060	0.0000
22	0.420	0.070	0.0055	0.0000
23	0.360	0.055	0.0047	0.0000
24	0.310	0.048	0.0043	0.0000

Asthma is characterized by spastic contraction of the bronchioles, which causes extremely difficult breathing [17, 53]. The usual cause is bronchial hyperresponsiveness towards a variety of specific and a-specific stimuli. In fact, in younger patients, under the age of 30, the asthma is in about 70 % of the cases caused by allergic hypersensitivity (i.e. plant pollen, dust mite, cats, dogs). In elder persons, the hypersensitivity is to non-allergic types of irritants in air, such as smog.

As a result of the irritants, the allergic person has a tendency to produce a high amount of antibodies, which attach to specific cells in the bronchioles and small bronchi. As a result of the antibodies reaction with the irritant, some substances are released (e.g. histamine). The combined effect of all these factors will produce:

- localized edema in the walls of the small bronchioles as well as secretion of thick mucus into bronchiolar airways, and
- spasm of the bronchiolar smooth muscle.

Table 2.2 The tube parameters for the sub-glottal airways depths, whereas depth 1 denotes the trachea and depth 35 the alveoli, as used in [54, 65]

Depth m	Length ℓ (cm)	Radius R (cm)	Wall thickness h (cm)	Cartilage fraction κ	Bifurcation Δ
1	10.0	0.80	0.3724	0.67	1
2	5.0	0.6	0.1735	0.5000	2
3	2.2	0.55	0.1348	0.5000	3
4	1.1	0.40	0.0528	0.3300	3
5	1.05	0.365	0.0409	0.2500	3
6	1.13	0.295	0.0244	0.2000	3
7	1.13	0.295	0.0244	0.0926	3
8	0.97	0.270	0.0205	0.0851	3
9	1.08	0.215	0.0149	0.0671	3
10	0.860	0.175	0.0126	0.0526	3
11	0.950	0.175	0.0126	0.0525	3
12	0.990	0.155	0.0118	0.0450	3
13	0.800	0.145	0.0114	0.0410	3
14	0.920	0.140	0.0112	0.0389	3
15	0.820	0.135	0.0111	0.0370	3
16	0.810	0.125	0.0107	0.0329	3
17	0.770	0.120	0.0105	0.0309	3
18	0.640	0.109	0.01	0.0262	3
19	0.630	0.100	0.0096	0.0224	3
20	0.517	0.090	0.0091	0.0000	3
21	0.480	0.080	0.0085	0.0000	3
22	0.420	0.070	0.0079	0.0000	3
23	0.360	0.055	0.0067	0.0000	2
24	0.310	0.048	0.0060	0.0000	2
25	0.250	0.038	0.0050	0.000	1
26	0.11	0.0315	0.0042	0.000	0
27	0.131	0.0265	0.0036	0.000	0
28	0.105	0.024	0.0032	0.000	0
29	0.075	0.0215	0.0029	0.000	0
30	0.059	0.04	0.0052	0.000	0
31	0.048	0.04	0.0052	0.000	0
32	0.048	0.04	0.0052	0.000	0
33	0.048	0.04	0.0052	0.000	0
34	0.048	0.04	0.0052	0.000	0
35	0.048	0.04	0.0052	0.000	0

There may be a wheezing or whistling sound, which is typical of asthma. Wheezing occurs because muscles that surround the airways tighten, and the inner lining of the airways swells and pushes inward. It also occurs because membranes that line the airways secrete extra mucus and furthermore the mucus can form plugs that may block the air passages. As a result, the rush of air through the narrowed airways produces the wheezing sounds. Usually, the asthmatic person can inspire quite easily, but has difficulty to expire air from the lungs. Also here the long-term effect of barrel chest will occur, similarly to chronic obstructive emphysema.

Although anyone may have an asthma attack, it most commonly occurs in children, by the age of 5, adults in their 30s, adults older than 65, and people living in urban communities (smog or allergic reactions). Other factors include: family history of asthma and personal medical history of allergies.

Cystic Fibrosis is an inherited disease characterized by an abnormality in the glands that produce sweat and mucus [35, 132]. It is chronic, progressive, and may be fatal. Cystic fibrosis affects various systems in children and young adults, including the following: respiratory system, digestive system, and the reproductive system.

Approximately 1 in 20 people in the US and Europe are carriers of the cystic fibrosis gene. They are not affected by the disease and usually do not know that they are carriers. Abnormalities in the glands that produce sweat and mucus can cause:

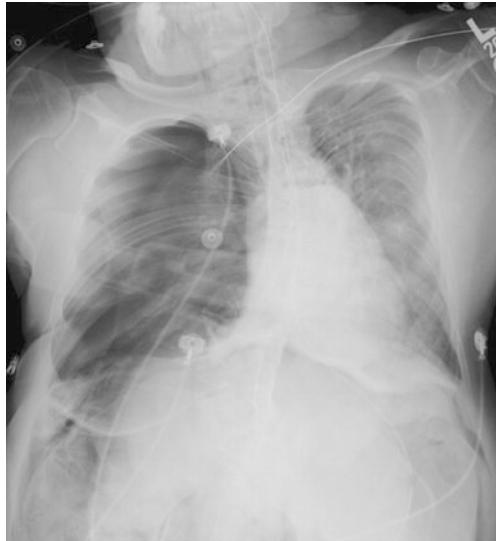- excessive loss of salt, which in turn can cause an upset in the balance of minerals in the blood, abnormal heart rhythms and possibly, shock;
- thick mucus that accumulates in lungs and intestines, which in turn can cause malnutrition, poor growth, frequent respiratory infections, breathing difficulties and in general, lung disease;
- other medical problems.

Under the item of medical problems one can enumerate: sinusitis, nasal polyps, clubbing of fingers and toes, pneumothorax—rupture of lung tissue, hemoptysis—coughing blood, enlargement of right side of the heart, abdominal pain, gas in the intestines, liver disease, diabetes, pancreatitis and gallstones.

Kyphoscoliosis is a deformation of the spine, as a combination effect of scoliosis and kyphosis [103]. An example of an X-ray is given in Fig. 2.4, courtesy of Prof. Derom from Ghent University Hospital. The patient was hospitalized for severe breathing insufficiency.

Scoliosis, is a medical condition in which a person's spine is curved from side to side, shaped like an *S* or *C*, and may also be rotated. To adults it can be very painful. It is an abnormal lateral curvature of the spine. On an X-ray, viewed from the rear, the spine of an individual with a typical scoliosis may look more like an *S* or a *C* than a straight line. It is typically classified as congenital (caused by vertebral anomalies present at birth), idiopathic (sub-classified as infantile, juvenile, adolescent, or adult according to when onset occurred) or as neuromuscular, having developed as a secondary symptom of another condition, such as spina bifida, cerebral palsy, spinal muscular atrophy or due to physical trauma. Scoliotic curves of 10 degrees or less affect 3–5 out of every 1000 people.

Fig. 2.4 X-ray of a patient presenting kyphoscoliosis. Courtesy of Prof. Dr. MD Eric Derom from Ghent University Hospital, Belgium



Kyphosis, also called hunchback, is a common condition of a curvature of the upper (thoracic) spine. It can be either the result of degenerative diseases (such as arthritis), developmental problems, osteoporosis with compression fractures of the vertebrae, and/or trauma. In the sense of a deformity, it is the pathological curving of the spine, where parts of the spinal column lose some or all of their normal profile. This causes a bowing of the back, seen as a slouching back and breathing difficulties. Severe cases can cause great discomfort and even lead to death.

As a result of these deformities at the spinal level, the thorax cannot perform its normal function, leading to changes in airway resistance and total lung compliance.

2.4 Structural Changes in the Lungs with Disease

The term *airway remodeling* refers to the process of modification and sustained disruption of structural cells and tissues leading to a new airway-wall structure with implicit new functions. Airway remodeling is supposed to be a consequence of long-term airway diseases. Some studies suggest that the remodeling may be a part of the primary pathology rather than simply a result of chronic inflammation [9]. Of crucial importance in this quest to understand airway remodeling is the composition and structure of the lung tissue [82, 153]. The composition and structure determines the mechanical properties of the lungs. Structural changes will induce alternations in tissue elasticity and viscosity. Structural alternations introduced by pathological processes are traditionally divided into three layers: the inner wall, the outer wall and the smooth-muscle layer. The inner wall consists of the epithelium, basement membrane and submucosa, while the outer layer consists of cartilage and loose connective tissue between the muscle layer and the surrounding lung parenchyma.

In COPD, major structural alternations occur in the small bronchi and membranous bronchiole (airway diameter < 2 mm). Changes occur around the supporting cartilage and bronchial glands in the peripheral airways (≈ 2 mm diameter). Here, the thickening occurs mainly in the inner wall area of the large airways [9, 82, 86].

The most important changes in asthma are located in the conducting airways, which can thicken up to 300 %. Asthma patients have thickened segmental and subsegmental bronchial walls over their entire size range. This thickening is dependent on the degree of the disease, more severe and older patients will depict these characteristics more than young patients [9, 85]. In asthma, the inflammatory reactions takes place in the higher part of the airways than in COPD. Unfortunately for COPD patients, the airway obstruction that accompanies these changes is resistant to medication which makes the changes persistent. By contrast, in asthma the inflammatory processes can be controlled by the use of corticosteroids. There are also important differences in the remodeling of the extracellular matrix and the role of proteolytic enzymes and growth factors which lead to specific airway remodeling results by disease. More clinical information about inflammation mechanics in airway remodeling can be found in [13]. For remodeling effects in asthma, an important role is played by the degree to which the smooth muscle surrounds the airway lumen. These muscles are located within the posterior membranous sheath in the trachea and main-stem bronchi, whereas they surround the entire lumen of the airway in the bronchioles [53]. Consequently, the same degree of muscle shortening in asthma patients has a smaller effect on the central airways than on the lower situated bronchioles [53].

In COPD, hyperplasia and mucous metaplasia are observed in central and peripheral airways which ends in a more even distribution of secretory cells. This leads to a state where the smaller airways (diameter < 400 μm), which are normally populated with very little goblet cells, become large contributors to the excess of mucous which characterizes COPD [64]. Mucous, produced in both asthma as COPD, is quantitatively and qualitatively abnormal with alternations in its molecular and cellular composition. The elevated ratio of mucous/serous acini provides a secretion of a thicker, gel-like mucus in COPD. Partial or complete occlusion of the small airways occurs.

The lungs consist of large surface areas with small diffusion distances to guarantee proper gas exchange. The 3D structure of the alveoli can be compared to a honeycomb structure of thin-walled septa which form a fractal network [64, 71]. This structure is unstable at low inflating pressures and would collapse if there would not be a mechanical stress at the end of expiration. This 'pre-stress' is generated by the pleural pressure around the lung. Changes in mechanical properties of the lung tissue by pathology will influence the response on this pre-stress. Once an alveolar wall starts to rupture, the stress the original wall carried is redistributed to the neighboring walls. These areas will experience a increased pre-stress which will result in a relentless increase of the unbinding and cleavage rate and the unfolding of new binding sites. A single rupture will induce a cascade of ruptures and serves as a positive feedback for further breakdown. It is obvious that there must be a kind of 'tipping point' beyond which the structure–function relationship cannot return to

the healthy condition. The rupturing process develops in time and depends on sudden exacerbations. After the rupture of (one) septal wall(s), a new stable mechanical equilibrium can be reached. However, exacerbations triggered by bacterial or viral infections or tissue fatigue due to hard breathing or forceful coughing can lead to physical failure of the walls.

It is clear that mechanical forces invoked during breathing on enzyme-injured lungs have an important role in the breakdown of the septal walls of the alveoli. Changes in network topology will influence the macroscopic elasticity which may be detectable by the FOT (Forced Oscillations Technique) lung function test. When pressure oscillations are applied to this injured and mechanical adapted tissue, a significantly higher amount of nonlinear dynamics will be present.

2.5 Non-invasive Lung Function Tests

Normal quiet breathing (such as during the FOT lung function test) is accomplished by contraction of the diaphragm, the parasternal muscles and the scaleni. During inspiration, the diaphragm pulls the lower surfaces of the lung downwards. Expiration results from simple relaxation of these muscles. Changes in the elastic recoil of the lungs (more, or less, stiffness) will affect their normal function, in particular total lung volume and pressure–volume relationships.

Some measurements are performed during forced inspirations and forced expirations, i.e. the spirometry lung function test. A person's vital capacity can be measured by a spirometer [109]. In combination with other physiological measurements, the vital capacity (VC) can help make a diagnosis of underlying lung disease. Vital capacity is the maximum amount of air a person can expel from the lungs after a maximum inspiration. It is equal to the inspiratory reserve volume plus the tidal volume plus the expiratory reserve volume. Forced vital capacity (FVC) is the maximum volume of air that a person can exhale after maximum inhalation. It can also be the maximum volume of air that a person can inhale after maximum exhalation. Another important measure during spirometry is the forced expired volume in one second (FEV1). The FEV1/FVC ratio is used in the diagnosis of obstructive and restrictive lung disease, and normal values are approximately 80 %. In obstructive lung disease, the FEV1 is reduced due to obstruction to air escape. Thus, the FEV1/FVC ratio will be reduced. In restrictive lung disease, the FEV1 and FVC are equally reduced due to fibrosis or other lung pathology (not obstructive pathology). Thus, the FEV1/FVC ratio should be approximately normal.

The compliance is expressed as the volume increase in the lungs for each unit of trans-pulmonary pressure (which is the difference between the alveolar and pleural pressures). For instance, the compliance of the normal lungs and thorax combined is 0.13 liter per centimeter of water pressure (l/cmH₂O). This means that every time the alveolar pressure is increased by 1 cmH₂O, the lungs expand 130 ml. The most common representation of the compliance is given by the pressure–volume (PV) loops. The area between the inspiratory and expiratory PV curve is called the work of breathing; this will again vary with pathology.

Factors that cause abnormal compliance can be in fact anything which destroys the lung tissue, causing it to become fibrotic or edematous, blocks the bronchioli or in any other way impedes lung expansion and contraction. When considering the compliance of the lungs and thorax together, one should keep in mind any abnormality of the thoracic cage (e.g. kyphosis, scoliosis).

2.6 Summary

The purpose of this chapter was to provide a basic knowledge of anatomy and structure of the lungs, necessary to understand further developments in this book. The morphology plays an important role here, so a great deal of attention has been given to its implications in fractal analysis. The mechanical properties of the lungs are the result of a dynamic interplay between structure, active and passive breathing, all due to variations in pressure between the mouth and the alveoli. An overview of the spirometry non-invasive lung function test is also provided, since it helps the reader understand the clinical significance of the mechanical work of respiration.

The Human Respiratory System

An Analysis of the Interplay between Anatomy,
Structure, Breathing and Fractal Dynamics

Ionescu, C.M.

2013, XXV, 217 p. 148 illus., 129 illus. in color.,

Hardcover

ISBN: 978-1-4471-5387-0