

Chapter 2

History of ACL Treatment and Current Gold Standard of Care

Martha M. Murray

ACL injuries are increasingly common, with estimates as high as of 400,000 patients each year in the United States sustaining this injury (in comparison with 120,000 patients undergoing hip replacement surgery) [1]. The ACL injury is important, not only due to the number of people affected by the injury but also because of the sequelae of the injury. The ACL does not heal on its own, and as a result, many methods have been designed to treat the ACL-injured knee. However, even our gold standard of treatment, ACL reconstruction, cannot prevent the premature onset of arthritis for patients with ACL injuries. This is worrisome for those of us who care for patients with ACL injuries, and as such, we are extremely interested in finding improved solutions for people with ACL injuries.

There has been a great deal of work done over the past two centuries regarding the diagnosis and treatment of the ACL. We will briefly review some of the highlights that seem most relevant to these injuries and those that give us hints of what might work better. Certainly, any work in this field “stands upon the shoulders” of these wonderful physicians and scientists who have laid a great foundation for future studies.

The earliest reports of ACL injuries largely relied on the history and physical examination of the patient, two areas which remain critical to the accurate diagnosis of this injury today. The first identification of the ACL was attributed to Claudius Galen (150 A.D., Fig. 2.1) who cared for the gladiators and likely had the opportunity to visualize the ACL through gashes in the knee. In 1845, Amedee Bonnet of Lyon reported that patients who heard a snap and developed swelling and loss of function in the knee would most likely have a ligamentous injury, including ACL injury. Thirty years later, Georgios Noulis from Greece performed a series of cadaver studies where he found that forced anterior subluxation of the tibia could

M.M. Murray, MD (✉)

Department of Orthopedic Surgery, Division of Sports Medicine, Boston Children’s Hospital,
Harvard Medical School, 300 Longwood Ave, Boston, MA 02115, USA
e-mail: martha.murray@childrens.harvard.edu

Fig. 2.1 Claudius Galen, b. 129 A.D., d circa 200 A.D. Galen was a physician for the gladiators in Rome and is credited with the initial observation of the anterior cruciate ligament and its traumatic injury (From The Wellcome Library, London)

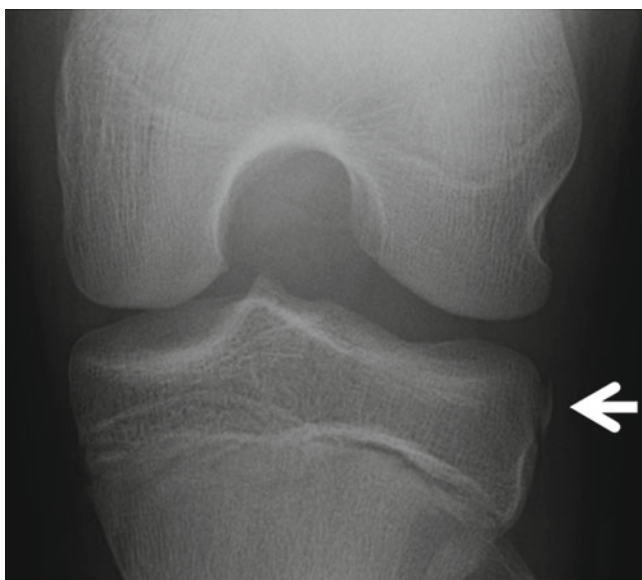


Fig. 2.2 X-ray appearance of a Segond fracture. In 1879, Paul Segond recognized that patients who had a small avulsion fracture off the anterolateral tibial plateau (*arrow*) typically had an ACL tear

cause an ACL rupture, and he described a test very similar to the Lachman test used today for diagnosing a tear of the ACL. After radiography started to become more available in 1879, Paul Segond recognized that patients with a small avulsion fracture off the anterolateral tibial plateau (now called a Segond fracture, Fig. 2.2) typically had an ACL tear. The history, physical exam, and x-ray findings were all critical to the diagnosis of patients with ACL tears.

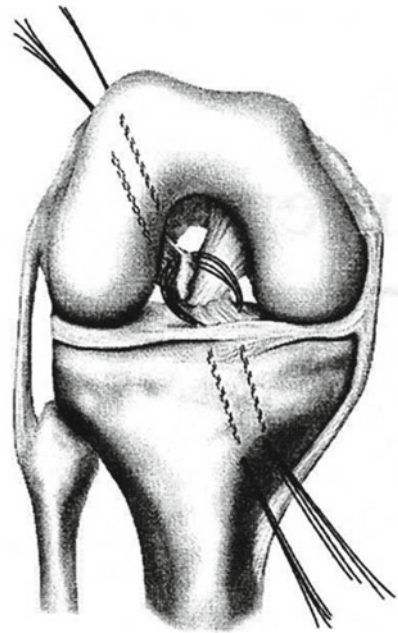
History of Primary Repair

With the recognition of ACL injury came the realization that untreated ACL tears often caused progressive deterioration of the knee with instability and damage to the menisci and cartilage [2, 3]. For this reason, surgical treatments emerged. The first repair of the ACL is attributed to A.W. Mayo Robson in 1895, who reported on the suture repair of both the ACL and PCL in a miner who had been injured 3 years prior. Six years later, the patient still described his knee as “perfectly strong” and he was able to walk without a limp. Since his discharge from the hospital, he did not miss a day of work due to his knee injury – certainly an outcome of “good patient satisfaction.” With the advent of aseptic techniques and general anesthesia, surgery for knee injuries became even more prevalent. In 1938, Ivar Palmer discussed the failure of spontaneous healing of a complete ACL tear and subsequent importance of repair [4]. Palmer thought that early repair was critical to its success. In 1950, D. H. O’Donoghue, from the University of Oklahoma, reported his technique of ACL repair, which consisted of a suture weave through the tibial stump and passing it up through a tunnel in the femur and using postoperative immobilization for 4 weeks with the knee held at 30° [5]. He, like Palmer, thought early repair was critical to successful healing.

O’Donoghue was also very active in the basic science of ACL healing and its repair. In the 1960s, he published a study of repair of the ACL in dogs and found that even with a suture repair of the ligament, the repaired ACL only achieved 10 % of its normal strength at 4 weeks [6]. In 1979, Cabaud et al. evaluated the results of ACL repair in both rhesus monkeys and dogs [7] and found that while repairs reached 45 % of the intact ACL strength at a year in monkeys, the repairs in dogs were less favorable, only achieving 10 % of the ACL strength. The reasons for the failures were unknown, but hypotheses about inadequate immobilization and early stress on the repair were discussed. Interestingly enough, animal studies performed since using ACL reconstruction (the current gold standard of ACL treatment) have also reported high rates of failure and abnormal knee laxity in these large animal models, making one wonder if ACL procedures are less effective in animals who cannot undergo skilled rehabilitation [8–11].

John Marshall expanded the description of primary ACL repair, with placement of multiple loop, varying-depth sutures in both cruciate stumps, and passing the sutures through drill holes in the opposite bone [12, 13]. John Feagin and Walter Curl reported on using a modified Marshall technique with catgut sutures to repair the ACL in West Point cadets (Fig. 2.3). While 25 of 30 patients were doing well at 2 years out from surgery [15], the 5-year follow-up results were less encouraging [16], with 71 % of patients having pain and 94 % presenting with knee instability. One should note, however, that these surgeries were performed in military personnel, the majority of which were commissioned to full duty and many went to fight in the Vietnam War. However, these results were less than heartening to those caring for active patients with ACL tears. Later articles appeared more promising, with Marshall, Warren, and Wickewicz publishing a 2.5-year follow-up

Fig. 2.3 The Marshall technique of primary repair of the ACL. Sutures were placed in a variable depth fashion in the tibial stump and femoral stumps and tied over a bone bridge. In the Feagin and Curl studies, these sutures were made of catgut (Used with permission from McCulloch et al. [14])



study where no patients with repair had giving way symptoms or had needed subsequent meniscal surgery (even though 93 % of them were active in sports) [12]. In 1985, Odensten et al. published the first prospective, randomized trial of suture repair vs iliotibial band reconstruction vs nonoperative therapy for patients with ACL injuries [17]. The suture repair in that paper was described as “the distal fragment of the ACL was sutured with seven or eight non-absorbable sutures to the anatomic insertion point on the lateral femoral condyle. The sutures were pulled out through two drill channels in the lateral femoral condyle and were tied on the outside.” The limbs were immobilized for 6 weeks at 30 degrees of flexion. At 18 months out from surgery, there was no significant difference between operated and nonoperated knees in terms of overall outcome scores; however, the authors did note that while 95 % of patients in the repaired group had a stable knee at follow-up (with a negative pivot shift or Slocum test), only 11 % in the nonoperated group did. In addition, twice as many patients in the nonoperative group required further meniscal surgery in the 18 months after injury [17].

In 1987, Sandberg et al. published a second prospective study of primary repair versus nonoperative treatment [18]. As in the Odensten paper, the printed conclusion was that primary repair was no better than non-operative treatment. However, it is interesting to note that the rate of a positive pivot shift test also decreased with surgery (from 62 to 28 %) as did the risk of presenting with a subsequent meniscal tear (24 % vs. 8 %). Thus, while both of these studies concluded that functional

performance was comparable between the two groups, other important characteristics (stable knee, preservation of the menisci) appeared to be better in the group undergoing primary ACL repair.

During the 1980s, a debate raged as to the best surgical treatment for the ACL. Primary repair continued to have its advocates [19], but repair augmented with other tissue (the iliotibial band or a bone-patellar tendon-bone graft) was also coming into favor [20]. While both ACL reconstruction and primary repair had similar results in terms of rate of return to full sports (60–75 %), reinjury (1.5 %), and a normal Lachman exam after surgery (50 %), the repairs needed to be done relatively quickly, while the repairs augmented with a reconstruction could be delayed for months. This convenience factor for both patients and surgeons alike must have been irresistible, as much of the repair literature drops away after these series of reports.

History of ACL Reconstruction

In 1917, Ernest W. Hey Groves reported on the first ACL reconstruction using an iliotibial band transplant, and in 1920, he reported on the results of this procedure in his first 14 patients [21]. None of the patients were made worse by the operation. Four were reported to have no benefit, four had “some benefit,” and four were cured (although two were still in rehabilitation at the time the paper was written). In 1935, Willis Campbell of Memphis, Tennessee, reported the first use of a patellar tendon graft and fixation through bony tunnels in the femur and tibia [22]. Additional advances in ACL reconstructive surgery were subsequently made by Kenneth G. Jones of Arkansas, Helmut Bruckner of Germany, and Kurt Franke of Germany.

In the 1970s, nonanatomic ACL reconstruction techniques became more in favor, even though primary ACL repair was commonly performed. The MacIntosh procedure (pioneered by D. L. MacIntosh of Toronto) was a primarily extra-articular procedure that utilized a fascia lata graft left attached to the tibia, passed under the lateral collateral ligament, and attached to the intermuscular septum (Fig. 2.4) [23]. The MacIntosh II procedure involved using a longer graft which could be passed under the lateral collateral ligament, through the intermuscular septum, then over the back of the lateral femoral condyle, and through the joint to a tibial tunnel. This procedure was the predecessor of one of the techniques currently used to reconstruct the ACL in skeletally immature patients (Fig. 2.5) [24, 25].

In the 1980s, intra-articular ACL reconstruction began to come to the forefront. John Insall is often given credit for the early intra-articular reconstructions – he reported a technique where a band of fascia lata was passed through the knee and sutured to the front of the tibia [26]. Another procedure, described by MacIntosh, involved taking a central slip of the patellar tendon with tissue from the top of the patella, leaving it attached distally at the tibia and passing the tendon through the notch to reapproximate the course of the ACL (Fig. 2.6).

A free patellar tendon graft came shortly thereafter. Clancy is typically credited with popularization of this technique [27], although he advocated simultaneous

Fig. 2.4 MacIntosh I.
Lateral extra-articular
reconstruction with a strip of
IT band passed through the
intermuscular septum and
under the lateral collateral
ligament (Used with
permission from McCulloch
et al. [14])

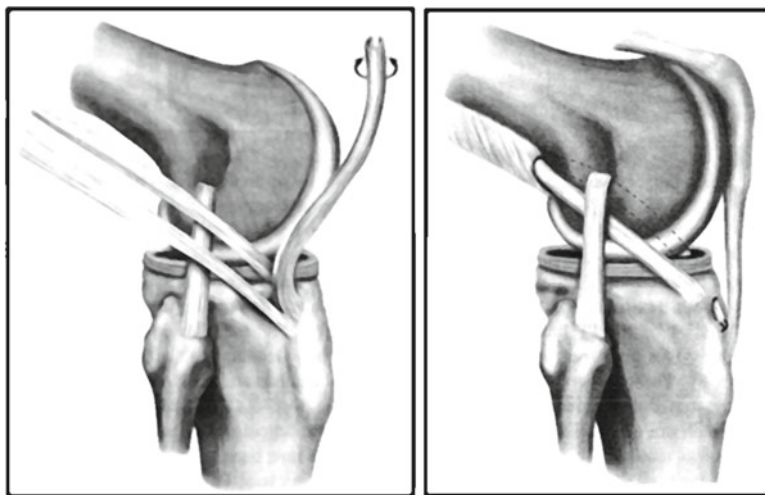
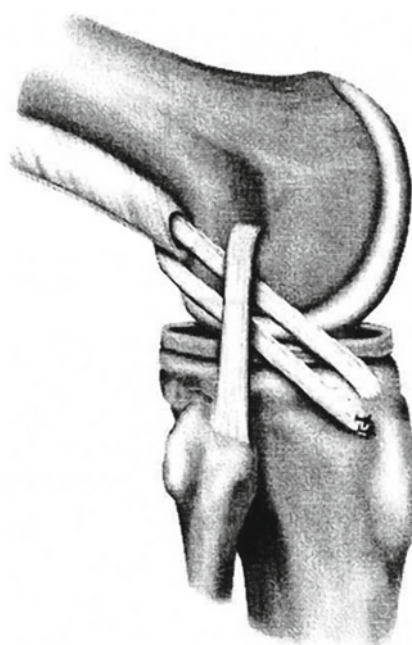

Fig. 2.5 The MacIntosh II. The MacIntosh II procedure involved using a longer graft which could be passed under the lateral collateral ligament, through the intermuscular septum, then over the back of the lateral femoral condyle, and through the joint to a tibial tunnel (Used with permission from McCulloch et al. [14])

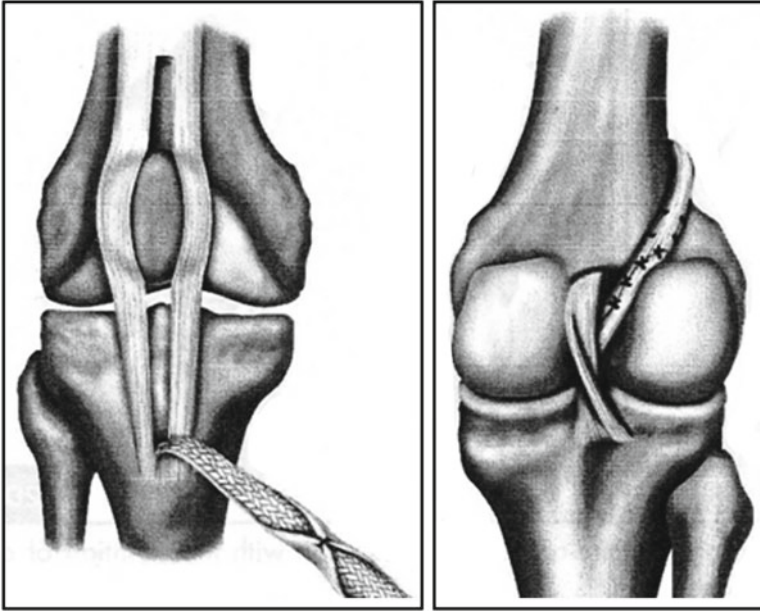


Fig. 2.6 Intra-articular ACL replacement using the central slip of the patellar tendon. Another procedure was described by MacIntosh involved taking a central slip of the patellar tendon with tissue from the top of the patella, leaving it attached distally at the tibia and passing the tendon through the notch to reapproximate the course of the ACL (Used with permission from McCulloch et al. [14])

medial and lateral capsular repairs – techniques later shown to not be necessary for a good outcome by O’Brien [28]. Other tissues were also explored as grafts, including the medial meniscus [29] (no longer in practice) and hamstring grafts [30, 31]. Current standard of practice is to use a free tendon graft (bone-patellar tendon-bone, hamstring, or allograft) through tunnels in the tibia and femur along the course of the prior ACL.

History of Synthetic Replacement of the ACL

The first ACL replacement with synthetic material was reported by F. Lange of Munich, who used a braided silk construct to replace the ACL. The procedure did not work but perhaps set the stage for the next few decades. Since that time, many synthetic materials have been trialed, including Gore-Tex, carbon fiber, and modified silk scaffolds (Fig. 2.7). The details of those materials and their performance will be covered in Chap. 14. In brief, to date there has not been a synthetic ligament which performs well over time. This is likely due to the fact that none of the synthetic materials used have encouraged sufficient cellular and tissue ingrowth.



Fig. 2.7 Photograph of a Gore-Tex graft

Biologic tissues have the amazing ability to engineer their own repair. Small injuries, many of which occur with daily “wear and tear,” can be fixed by the cells within the tissues as they occur. Thus, small, repetitive injuries do not typically lead to catastrophic failure for living tissues. However, synthetic materials which do not have biologic incorporation subsequently do not have the ability to heal the small injuries which occur over time. These small injuries thus continue to accrue, until enough damage has occurred to produce catastrophic failure of the ligament. A typical pattern for these synthetics is good stability of the knee for a period of time, even several years, and then a sudden complete failure. In the future, a synthetic ligament replacement which encourages biologic incorporation may be a very useful addition to the armamentarium of an ACL surgeon.

Current Gold Standard of Treatment

The current gold standard of treatment for a skeletally mature patient is an ACL reconstruction with a free tendon graft, placed through tunnels in the distal femur and proximal tibia and anchored at both sides. For young patients, the graft of choice is autograft, with surgeons recommending either hamstring or patellar tendon, based on personal experience and preference. There is currently no data to suggest the superiority of hamstring or patellar tendon grafts as will be detailed in the next chapter. Other surgical decisions, such as choice of fixation method, will also be discussed in the next chapter. The preservation of the ACL remnant, and placing smaller tunnels for the graft through the center of the remaining ACL tissue, is a technique that is gaining much popularity, especially for young active

patients where the preservation of the torn ACL tissue may allow for a source of proprioceptive nerve fibers which may be particularly important on the patient's return to sports.

Conclusions

Our current treatment of ACL injuries has evolved over the past few centuries. Information gained by surgeons and investigators studying and comparing methods of conservative treatment, primary suture repair, and ACL reconstruction has led to the majority of patients being treated with an ACL reconstruction today. This is due to the prior failure of primary suture repair and the superiority of the ACL reconstruction over conservative treatment for the majority of patients. Future improvements in ACL treatment will build on the findings of these prior investigators, and hopefully, the advances in ACL surgery over the next few decades will be as rapid and exciting as that over the past few.

Acknowledgement Research reported in this chapter was supported by the National Institute of Arthritis and Musculoskeletal and Skin Diseases of the National Institutes of Health under Award Number RO1-AR054099. The content is solely the responsibility of the authors and does not necessarily represent the official views of the National Institutes of Health.

References

1. Junkin DM, Johnson DL, Fu FH, et al. Knee ligament injuries. In: Kibler WB, editor. Orthopedic knowledge update: sports medicine. Rosemont: American Academy of Orthopedic Surgeons; 2009. p. 136.
2. Marshall JL, Fetto JF, Botero PM. Knee ligament injuries: a standardized evaluation method. Clin Orthop Relat Res. 1977;123:115–29.
3. Noyes FR, Mooar PA, Matthews DS, Butler DL. The symptomatic anterior cruciate-deficient knee. Part I: the long-term functional disability in athletically active individuals. J Bone Joint Surg Am. 1983;65(2):154–62.
4. Palmer I. On the injuries to the ligaments of the knee joint: a clinical study. Acta Chir Scand. 1938; Suppl 53:1–282.
5. O'Donoghue DH. Surgical treatment of fresh injuries to the major ligaments of the knee. J Bone Joint Surg Am. 1950;32:721–38.
6. O'Donoghue DH, Rockwood Jr CA, Frank GR, Jack SC, Kenyon R. Repair of the anterior cruciate ligament in dogs. J Bone Joint Surg Am. 1966;48(3):503–19.
7. Cabaud HE, Rodkey WG, Feagin JA. Experimental studies of acute anterior cruciate ligament injury and repair. Am J Sports Med. 1979;7:18–22.
8. Hunt P, Scheffler SU, Unterhauser FN, Weiler A. A model of soft-tissue graft anterior cruciate ligament reconstruction in sheep. Arch Orthop Trauma Surg. 2005;125(4):238–48.
9. Drez DJ, DeLee J, Holden JP, Arnoczky S, Noyes FR, Roberts TS. Anterior cruciate ligament reconstruction using bone-patellar tendon-bone allografts. A biological and biomechanical evaluation in goats. Am J Sports Med. 1991;19(3):256–63.

10. Jackson DW, Grood ES, Arnoczky SP, Butler DL, Simon TM. Freeze dried anterior cruciate ligament allografts. Preliminary studies in a goat model. *Am J Sports Med.* 1987;15(4): 295–303.
11. Butler DL, Noyes FR, Grood ES, Olmstead ML, Hohn RB. The effects of vascularity on the mechanical properties of primate anterior cruciate ligament replacements. *Trans Orthop Res Soc.* 1983;8:93.
12. Marshall JL, Warren RF, Wickiewicz TL. Primary surgical treatment of anterior cruciate ligament lesions. *Am J Sports Med.* 1982;10:103–7.
13. Marshall JL, Warren RF, Wickiewicz TL, et al. The anterior cruciate ligament: a technique of repair and reconstruction. *Clin Orthop.* 1979;143:97–106.
14. McCulloch PC et al. An illustrated history of anterior cruciate ligament surgery. *J Knee Surg.* 2007;20(2):95–104.
15. Feagin JA, Abbott HG, Roukous JA. The isolated tear of the ACL [Abstract]. *J Bone Joint Surg.* 1972;54A:1340.
16. Feagin Jr JA, Curl WW. Isolated tear of the anterior cruciate ligament: 5-year follow-up study. *Am J Sports Med.* 1976;4(3):95–100.
17. Odensten M, Hamberg P, Nordin M, Lysholm J, Gillquist J. Surgical or conservative treatment of the acutely torn anterior cruciate ligament. A randomized study with short-term follow-up observations. *Clin Orthop Relat Res.* 1985;198:87–93.
18. Sandberg R, Balkfors B, Nilsson B, Westlin N. Operative versus non-operative treatment of recent injuries to the ligaments of the knee. A prospective randomized study. *J Bone Joint Surg Am.* 1987;69(8):1120–6.
19. Warren RF. Primary repair of the anterior cruciate ligament. *Clin Orthop.* 1983;172:65–70.
20. Clancy Jr WG, Ray JM, Zoltan DJ. Acute tears of the anterior cruciate ligament. Surgical versus conservative treatment. *J Bone Joint Surg Am.* 1988;70(10):1483–8.
21. Hey Groves EW. Operation for the repair of cruciate ligament. *Lancet.* 1917;2:674–5.
22. Campbell WC. Reconstruction of the ligaments of the knee. *Am J Surg.* 1939;43:473–80.
23. MacIntosh DL, Tregonning RJ. A follow-up study and evaluation of “over the top” repair of acute tears of the anterior cruciate ligament. *J Bone Joint Surg Br.* 1977;59:505.
24. Kocher MS, Garg S, Micheli LJ. Physseal sparing reconstruction of the anterior cruciate ligament in skeletally immature prepubescent children and adolescents. *J Bone Joint Surg Am.* 2005;87(11):2371–9.
25. Kocher MS, Garg S, Micheli LJ. Physseal sparing reconstruction of the anterior cruciate ligament in skeletally immature prepubescent children and adolescents surgical technique. *J Bone Joint Surg Am.* 2006;88 Suppl 1 Pt 2:283–93.
26. Insall J, Joseph DM, Aglietti P, Campbell Jr RD. Bone-block iliotibial-band transfer for anterior cruciate insufficiency. *J Bone Joint Surg Am.* 1981;63(4):560–9.
27. Clancy Jr WG, Nelson DA, Reider B, Narechania RG. Anterior cruciate ligament reconstruction using one-third of the patellar ligament, augmented by extra-articular tendon transfers. *J Bone Joint Surg Am.* 1982;64(3):352–9.
28. O’Brien SJ, Warren RF, Pavlov H, Panariello R, Wickiewicz TL. Reconstruction of the chronically insufficient anterior cruciate ligament with the central third of the patellar ligament. *J Bone Joint Surg Am.* 1991;73(2):278–86.
29. Ivey FM, Blazina ME, Fox JM, Del Pizzo W. Intraarticular substitution for anterior cruciate insufficiency. A clinical comparison between patellar tendon and meniscus. *Am J Sports Med.* 1980;8(6):405–10.
30. Macey H. A new operative procedure for repair of ruptured cruciate ligament of the knee. *Joint Surg Gynecol Obstet.* 1939;69:108–9.
31. Zarins B, Rowe CR. Combined anterior cruciate-ligament reconstruction using semitendinosus tendon and iliotibial tract. *J Bone Joint Surg Am.* 1986;68(2):160–77.

The ACL Handbook

Knee Biology, Mechanics, and Treatment

Murray, M.M.; Vavken, P.; Fleming, B. (Eds.)

2013, XI, 317 p., Hardcover

ISBN: 978-1-4614-0759-1