

Vittorio Luigi Piloni, Corrado R. Asteria,
and Sergio Bellarosa

Abstract

Conventional (radiographic) defecography has an established role as the benchmark test in the assessment of the postoperative anatomy after the construction of an ileo-anal pouch, a colo-anal anastomosis, or novel endoanal stapled resections such as the stapled transanal rectal resection procedure (and its variants). In addition to depicting the most common postoperative complications such as dehiscence and sinus tract formation, defecography shows the potential causes of poor postoperative functional outcomes including strictures, neorectal enlargement with delayed emptying and contrast retention, asymmetric wall out-pocketing, and abnormal lengthening of a rectal segment distal to the anastomotic site. This chapter outlines the radiological perspective and interpretation of these complex patients in whom postoperative functional outcome is compromised and provides management algorithms for an approach to reoperative surgery.

Keywords

Radiographic defecography • STARR procedure • Coloanal anastomosis • Rectal cancer
• Ileo-anal pouch • Ulcerative colitis • Obstructed defecation syndrome

Introduction

Despite its well-known drawbacks and methodological weaknesses—most notably, radiation exposure, variations in the projectional nature of the technique, and an inability to detect soft-tissue structures—conventional (radiographic) defecography is still an established part of the imaging assessment of the anorectal region after various surgical procedures performed for both benign and malignant diseases.

V.L. Piloni, M.D. (✉)
SICCR Imaging Section,
Diagnostic Imaging Center “N. Aliotta” Villa Silvia Clinic,
Via Marche 24, Senigallia (AN) 60019, Italy
e-mail: vittorio.piloni@libero.it

C.R. Asteria, M.D.
Department of Surgery and Orthopaedics,
General Surgery Unit, Carlo Poma, Mantua, Italy

S. Bellarosa, M.D.
Department of Radiology,
Carlo Poma, Mantua, Italy

These include (1) construction of an ileo-anal pouch for ulcerative colitis and familial polyposis, (2) colo-anal anastomosis after low rectal tumor resection, and (3) stapled transanal rectal resection (STARR) procedure for obstructed defecation syndrome. The radiologist is asked to address two major issues: (1) to depict the new anatomical configuration and (2) to evaluate the efficiency of neorectal emptying. The goal of the radiological examination is to rule out the presence of any abnormality that might explain poor functional results and/or recurrence of previous symptoms in individual cases, both of which will assist the coloproctologist in surgical decision making.

Although designed to exclude different pathologies and encompass different surgical procedures, an understanding of the postoperative anatomy of the anorectum shares some common characteristics that are commonly faced by the radiologist, including assessment of the suture line and the segments cranial and caudal to any anastomosis. The normal radiographic appearance and complications occurring with each of the three procedures described are presented, along with their

radiologic interpretation, which is designed to aid the colorectologist during their specific radiological referral.

The Ileo-Anal Pouch

The combination of total colectomy, mucosal proctectomy, and endorectal ileoanal anastomosis in selected patients with ulcerative colitis and familial polyposis [1–3] offers various advantages, including (1) total removal of diseased mucosa, (2) avoidance of a permanent abdominal stoma, and (3) maintenance of a transanal path of fecal flow. A temporary diverting loop ileostomy, which usually is closed after a 6- to 8-week interval, also is constructed proximally to allow for healing of the suture lines and results in ultimate functionality of the reservoir. With regard to the pouch design, three main configurations have been described in the literature [4, 5], two of which are in widespread clinical use. The first is an S-shaped pouch that is fashioned by apposing three segments of terminal ileum leading to a globular reservoir constructed with afferent and efferent loops; the second is a smaller J-shaped, two-loop reservoir that is directly anastomosed to the anal canal because of the absence of the efferent segment. The third configuration is a bigger four-loop, W-shaped reservoir, but this has been virtually abandoned because of excessive fecal stasis.

An initial radiographic examination within 1 week after surgery is required to exclude any leakage from the suture lines [6]. Potential sources of leakage include both the extensive anastomoses performed during construction of the reservoir and the anastomosis of the reservoir to the anal canal itself. Adequate distension of the reservoir is obtained using careful administration of the radiopaque contrast agent (dilute gastrografin or dilute barium) under fluoroscopic guidance through a soft rubber catheter. To avoid injury of the ileo-anal anastomotic suture line, care should be taken not to inflate the balloon with more than 3 ml of air within the anal canal. Alternatively, contrast medium preferably is administered via the ostomy (Fig. 2.1). After withdrawal of the catheter, anteroposterior and lateral views of the pouch during full distension are obtained for identification of the pouch design. The S reservoir has a globular appearance with an easily recognizable efferent limb, whereas the J reservoir shows two distinct raphes corresponding to the anastomoses, with no evidence of efferent segments and nothing more than a short limb. Although great care should be taken to not misinterpret the opacification of the afferent limb as a sign of an anastomotic leak, extraluminal contrast extravasation within the perianastomotic site is virtually diagnostic of leakage, dehiscence, or both. In addition, careful inspection for any ventral displacement of the pouch on the lateral view is recommended because it may represent an indication of a presacral collection.

The overall sensitivities reported by Thoeni et al. [7] for the detection of complications using different imaging

modalities were as follows: 60 % with pouchography, 78 % with computed tomography (CT), and 79 % with In-labeled leukocyte scintigraphy [8]. According to these authors, fistulas were frequently missed with all three methods, whereas only CT correctly diagnosed all abscesses. Currently, magnetic resonance imaging is considered the method of choice and should be the initial test. If negative, a scintigram should then be obtained. In the absence of any adverse event, at 6–8 weeks after surgery, 200 ml of liquid barium is administered quickly from above through the ostomy (Fig. 2.2), resulting in full distension of the afferent segment of the reservoir so as to act as a “fluid overload” test. Radiographic imaging of the pouch provides a baseline for determination of reservoir capacity and acts as a broad prognostic indicator of future continence in patients who are continent during the radiologic “stress” conditions; these patients tend to display clinical continence after bowel reconstruction. Conversely, should there be only marginal continence with contrast media “stress” in the radiographic study, the time for stoma closure should be delayed until good control is obtained with a dedicated pelvic floor rehabilitation program.

Although many factors are credited with determining future pouch function, including its volume, capacity, small-bowel motor activity, transit, gut hormone levels, sepsis, and bacterial overgrowth, to provide additional information about the emptying function of the reservoir, defecography [9, 10] usually is obtained 3 months after bowel reconstruction, in the lateral projection with the patient seated on a specially designed commode. For the examination, up to 200 ml of a semisolid barium sulphate suspension (Pronto Bario E, 70 % mass/volume, Bracco Spa, Milan, Italy) is administered transanally and the following features are noted:

1. The overall geometrical configuration and size of the (neo)rectum at full distension, depending on the original pouch design.
2. The position in the pelvis of the pouch, measured as the perpendicular distance of the ano-pouch junction from the pubococcygeal line, where the distal segment is defined, according to Pescatori et al. [11], as the tract of bowel between the pouch and the anal margin.
3. The ano-pouch angle, defined as the angle between the luminal axis of the anal canal and the axis of the (neo)rectum or pouch obtained by drawing a line along the posterior wall of the distal rectum. This is preferred by the authors as opposed to the central axis of the rectal lumen, called the “centroid,” as described by Kmiot et al. [8], because we believe the latter measurement is excessively influenced by either the pouch design or the degree of filling. The angle is measured at rest and during squeezing, straining, and emptying.
4. The pattern of pouch emptying (whether by a single movement or split), with the test being considered terminated only after the patient has been straining to evacuate

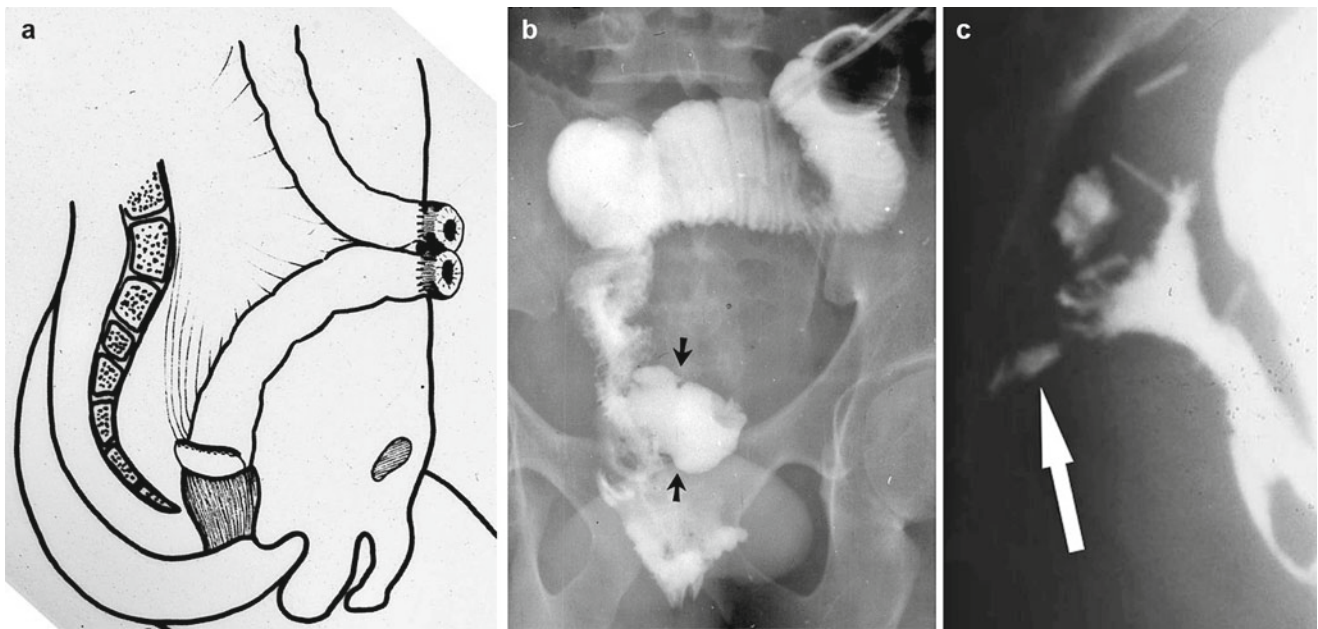


Fig. 2.1 Early postoperative complication after construction of a J-shaped ileoanal pouch. (a) Schematic drawing and (b) radio-opaque contrast administration through the temporary ileostomy. Note the parastomal extraluminal collection (arrows) due to leakage at the

suture line. (c) An outpouring of radio-opaque contrast from the efferent loop (arrow) mimicking the presence of a sinus tract in the presacral region

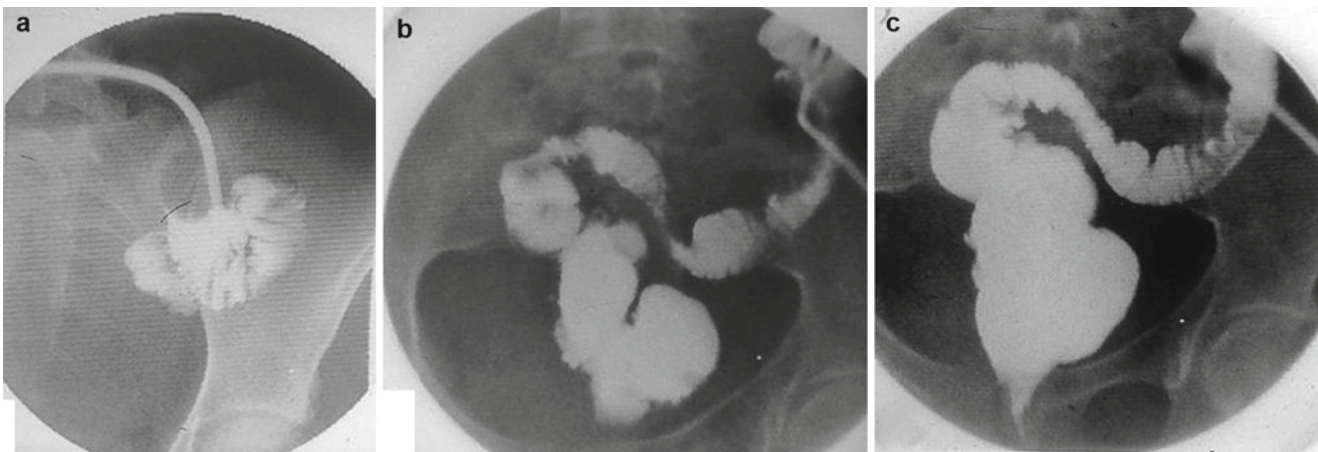


Fig. 2.2 Fluid overload test performed before closure of the ileostomy and restoration of intestinal continuity: 200 ml of liquid barium administered through the ileostomy over 2 min. Images taken at 15 s (a), 60 s

(b), and 90 s (c), respectively, to assess both the peristaltic activity and the capacity of the pouch without leakage

as much of the introduced contrast material as possible for no less than 3 min.

5. The amount of contrast retained, expressed as a fraction (one-third, two-thirds, or more) of the amount infused.

Defecographic findings associated with good functional results (e.g., stool frequency of no more than three to four movements per day and an absence of incontinence to gas or solid feces) include an anteroposterior diameter of the (neo) rectum not greater than 5–6 cm, no anal opacification or gaping at rest, mobility of the ano-pouch junction during squeezing and straining no less than 3 cm upward and no more than

3 cm downward, respectively; expulsion of the rectal content by no more than two to three movements within 60 s and a progressive decrease of the rectal diameter after filling by two-thirds during emptying, with no more than one-third barium retention at the end of the expulsion phase. On the other hand, major abnormal findings associated with poor functional results include an anal stricture, narrowing of the anastomotic ring, increased distance from the anastomotic ring to the anal verge due to progressive lengthening of the distal segment, and disproportionate enlargement of the pouch with difficult emptying and barium retention (Fig. 2.3).

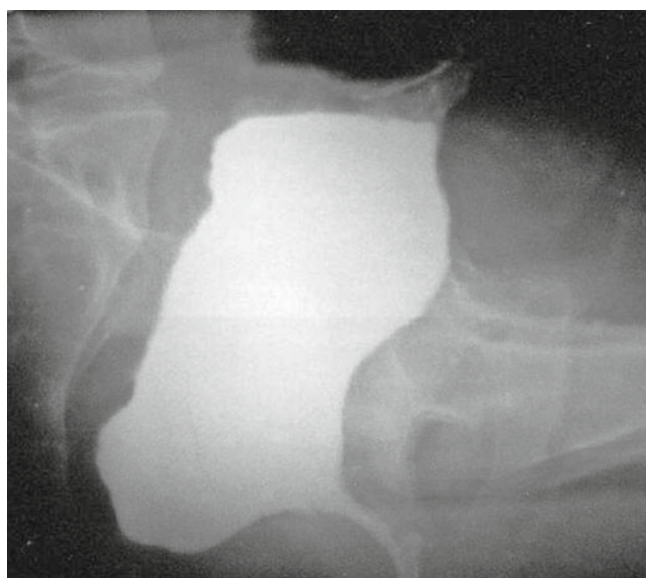


Fig. 2.3 Lateral view of a W-shaped ileo-anal pouch after evacuation. Note the barium retention within the dilated pouch

Pouchitis is the complication reported to be best diagnosed by scintigraphy (sensitivity, 80 %), followed by CT scanning (71 %) and pouchography (53 %) [7]. Pouchitis is relatively common, with the incidence ranging from 9 to 34 % and an important impact on functional outcome causing increased stool frequency, pain during evacuation, urgency, anal irritation, and stool leakage. Possible etiological factors that have been reported to be responsible for pouchitis include abnormal pouch motility, leading to stasis, bacterial overgrowth, ischemia, or reperfusion injury, and occult Crohn's disease [12, 13]. Histologic and endoscopic pouchitis is associated with leukocytosis, rheumatologic extraintestinal disease, disease initially proximal to the splenic flexure, age at diagnosis, and prior use of steroids. Intraoperative factors with greater risk of pouchitis include an S-pouch reconstruction, a multi-stage procedure, and perioperative transfusion, all of which are surrogate signs of operative complexity [14]. In a recent study by Lipman et al. [14] from the Cleveland Clinic, patients with pouchitis have worse outcomes than those without it, with more strictures, bowel obstructions, and fistulas and a lower quality of life. Histologic pouchitis that is found incidentally on biopsy and is asymptomatic does not seem to influence projected outcome.

Colo-Anal Anastomosis

Colo-anal anastomosis after tumor resection in the lower two thirds of the anus has rapidly gained acceptance worldwide despite some drawbacks, including excessive stool frequency and urgency, mainly caused by decreased compliance of the (neo)rectum. To improve functional outcome, the interposi-

tion of a J-shaped colonic segment just cranial to the anastomosis has been proposed by Lazorthes et al. [15] and Parc et al. [16] as an alternative to total proctectomy and straight colo-anal anastomosis. Although most authors claim the advantage of the J-shaped procedure over the straight colo-anal anastomosis during the first 2 years after construction [17], no single diagnostic test has been proven particularly useful in predicting the superiority of one procedure over the other. Dynamic radiology (i.e., defecography) may help the clinician to obtain an objective assessment of the functional outcome [18, 19]. During the examination, the reconstructed anorectal junction is filled with a standard amount of semi-solid barium sulphate suspension (200 ml of Pronto Bario E, 70 % mass/volume, Bracco Spa) with the patients lying on their left side on the table. The standard volume chosen corresponds to the sensation at which patients normally respond to the urge to defecate and is considered by the authors as more physiologic than the method in which the pouch is overdistended to the maximum volume tolerated. After withdrawing the probe, the table is tilted upright and the patient is positioned seated sideways on a specially designed commode (Bipot 125, Platinum, Giordanoshop, Naples, Italy). Intermittent fluoroscopy is used for both patient positioning and proper centering of the reconstructed bowel. Image acquisition is obtained directly from the intensifier using a video recording system that has playback and slow-motion facilities as well as a timer set at 100 per second.

The following phases are recorded with the patients seated in the lateral position: retrograde filling, upright at rest, squeeze, coughing, straining, and emptying. In addition, the ability to interrupt the barium stream on command, called the "stop test," also is used and rated as maintained (0), reduced (−1), and lost (−2). Occasionally, anteroposterior and oblique views also are obtained. On sagittal images, the radiologist identifies and draws lines for computing distances and angles to register the following variables:

- The maximum anteroposterior diameter of the (neo)rectum before and after evacuation
- The pubococcygeal line extending from the inferior border of the pubic symphysis to the last point of the coccyx, representing the level of the pelvic floor
- The distance from the anorectal junction on images obtained when the patient is at rest, during squeeze, at maximal straining, and during emptying
- The colo-anal angle, defined as the angle between the luminal axis of the anal canal and the axis of the (neo)rectum or pouch, obtained by drawing a line along the projected posterior wall of the distal rectum.

To estimate the pouch-anal angle, common difficulties encountered by the radiologist include a sigmoid loop-like appearance of the rectal ampulla, an asymmetric form of the distal rectum, an indistinct outline of the posterior rectal wall, and a variable impression of the puborectalis sling. Any

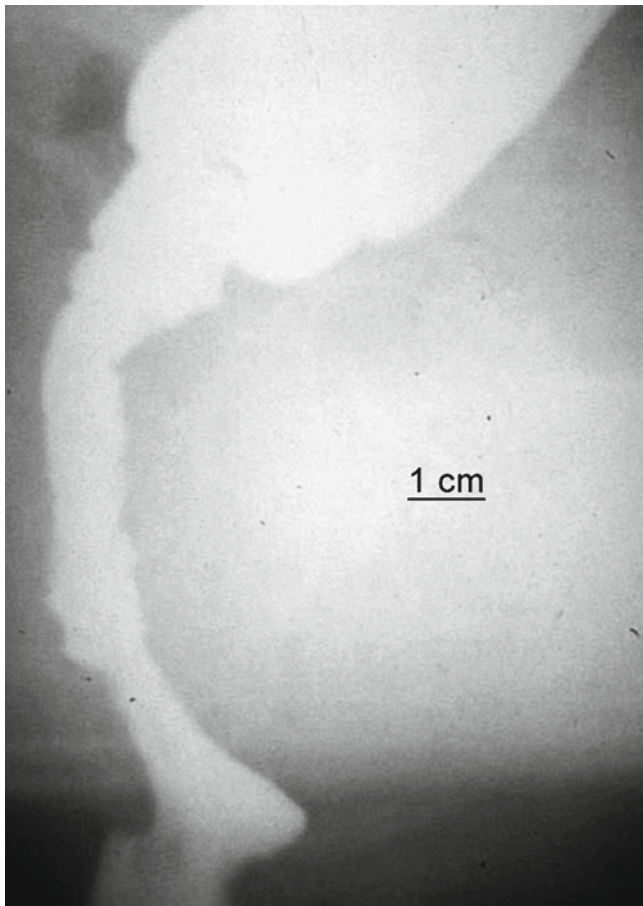


Fig. 2.4 Straight colo-anal anastomosis after rectal tumor resection. Postoperative defecography performed 1 year after surgery in a 54-year-old man with both difficult emptying and episodes of fecal incontinence. The segment distal to the suture line has become >7 cm in length and inert

impairment of pouch emptying caused by an anal stricture and/or abnormal angulation, lengthening of the segment distal to the anastomotic line (Fig. 2.4), as well as involuntary loss of contrast through the anus during the examination are noted.

Stapled Transanal Rectal Resection (STARR)

The STARR operation, first described by Longo [20] in the late 1990s as an alternative to traditional surgical techniques for the treatment of prolapsed hemorrhoids, subsequently was adopted for obstructed defecation syndrome (ODS) secondary to internal rectal intussusception, anterior rectocele, and rectal mucosal redundancy (rectal internal mucosal prolapse) after failed first-line medical therapy, rehabilitative therapy, or both. The procedure consists of two separate anterior and posterior rectotomies performed with the objective of restoring a more normal anatomy using two circular stapler devices (PPH-01, Ethicon Endo-Surgery, Cincinnati, OH) with modifications including the use of the STARR stapler and the

trans-STARR staple device [21, 22]. The first is applied anteriorly to reduce the intussusception and rectocele, thus correcting the anterior rectal wall muscle defect, and the second is applied posteriorly to complete correction of the corresponding portion of intussusception. As such, the resection of 3–10 cm of full-thickness rectal wall is obtained, allowing coincident removal of both anatomical defects. In women, when the anterior rectal wall is resected, the posterior wall of the vagina is checked for potential damage to the rectovaginal septum and coincident small-bowel loops in an associated enterocele. The posterior rectal wall, however, cannot be similarly monitored because it lies directly on the puborectalis muscle, offering a potential risk for inadvertent entrapment of the muscle when closing and firing the circular stapler, which is a potential cause of severe postoperative proctalgia [23].

Two purse-string sutures are placed 2 and 5 cm above the anorectal ring, taking the mucosa, submucosa, and a small portion of the muscular wall. Instruments for bowel anastomosis were not originally designed to be hemostatic, requiring the use of reinforcement absorbable sutures to reduce bleeding at the staple line, although this need for reinforcement has been reduced with the introduction of the newer PPH-03 stapler for use during the procedure for prolapse and hemorrhoids/hemorrhoidopexy. Most frequently, the additional resection of two lateral bridges of residual mucosa, called “dog-ears” because separate anterior and posterior stapler firings are not performed equally around the circumference of the rectal wall, also is required. More recently, however, to improve the anatomical correction necessary for the best functional outcome, a new curved, cutting stapler device, called the Contour Transtar, has been developed; it allows for a more uniform, full-thickness, circumferential resection and a greater volume of tissue to be removed under the surgeon’s direct vision. Despite this, there are still significant complications reported, including rectovaginal fistula, incontinence, and anastomotic dehiscence [24], the assessment of which may require specialized radiology.

The STARR procedure has rapidly gained wide popularity among surgeons, particularly in Italy but also throughout Europe. The procedure has been greeted with enthusiasm because of a number of factors, including reduced operative time (average, 25 min), minimal anal distraction, a short hospital stay, low postoperative pain, and an early return to normal activity. Moreover, encouraging short-term results initially have been reported by many groups [25–27], with good to excellent results reported in up to 91 % of patients. On the other hand, its general acceptance and increasing usage after acquiring more experience has resulted in a progressive enlargement of the indications for the surgical treatment of ODS without adequate objective controls or clear guidelines concerning the indications and contraindications for the procedure. Moreover, there is a poor understanding of the physiologic and morphologic changes that occur after the

Table 2.1 Reported causes of failure after the stapled transanal rectal resection procedure

Abnormality	Likely cause
Intractable pain	Staple suture too close to the dentate line; agrapphe (staple) retention with or without scar tissue
Rectal pockets, diverticulum	Aberrant purse-string placement
Anastomotic stricture	Chronic bleeding at the staple line; peristaple fibrosis (scar tissue); agrapphe retention; clumsy/excessive suture reinforcement
Rectovaginal fistula	Peristaple infection; vaginal wall entrapment in the staple line
Urgency and frequency	Decreased rectal size (compliance)
Fecal incontinence	Sphincter damage, overstretching
Pelvic sepsis, necrotizing fasciitis	Suture line dehiscence; inadvertent bowel loops entrapment/perforation
Persistent rectocele	Insufficient rectal wall resection at the anterior side
Failed anorectal angle widening	Prior underestimated anismus

Sources: See Refs. [23, 29, 31–33]

STARR procedure [26, 28]. These facts may explain the emergence of a new symptomatology after the STARR procedure and the occurrence of unusual and occasionally life-threatening complications such as intractable chronic pelvic pain, anorectal strictures, and rectal wall perforation with pelvic sepsis, which may require a diverting stoma [29]. Many of these symptoms are resistant to revisional surgery, most notably severe proctalgia, and incontinence where a pre-existing psychological disturbance in many patients has been detected [30].

Recently, other studies [31–33] have shown persistence of symptoms in 44 % of postoperative patients, with a lack of improvement at a mean follow-up of 20 months in 35 % and the need for reintervention due to postoperative complications in 9 % and recurrence of the disease in 11 % of patients. At present, the somewhat indiscriminate use of the STARR procedure has given way to a more realistic view concerning the true efficacy of the procedure; this was expressed in the publication of a Consensus Conference [34], listing the exclusion criteria for the safe execution of the STARR operation as follows: perineal infections, inflammatory bowel disease, anal stenosis and/or anal incontinence, an enterocele, anismus, the presence of mesh adjacent to the rectum, and abnormalities of pelvic floor, all of which are considered absolute contraindications to the procedure [35], although the presence of an enterocele may provide an opportunity for a laparoscopically guided STARR procedure in the prevention of small-bowel injury [36]. A balanced view of the issue now considers the STARR procedure to be a useful part of the coloproctologist's armamentarium for selective indications. Particularly, it is of some benefit in cases of obstructed defecation associated with rectocele and intussusception but at the cost of a high reintervention rate of 19 % within 18 months because of either postoperative complications or disease recurrence. Moreover, that the STARR procedure may fail, even in expert hands, and may be followed by persistent intractable and distressing symptoms, such as fecal urgency, increased stool

frequency, and chronic proctalgia, should be taken into consideration. Table 2.1 shows a list of common and uncommon adverse events reported after the STARR operation that resulted in poor outcomes.

Preoperative radiographic defecography combined with small-bowel and vaginal opacification (400 ml of liquid barium administered orally 2 h before the examination with 3–4 ml of semisolid barium intravaginally, respectively) is essential because it may determine treatment decisions and plays a key role in both the preoperative selection of patients (Fig. 2.5) and monitoring of the functional outcome. More precisely, inclusion criteria for surgery with preoperative defecography in patients with ODS with no evidence of slow transit constipation are as follows:

- No evidence of an enterocele or puborectalis muscle dyssynergia.
- An anterior rectocele measuring >2.5 cm in depth (according to the Bartram method) [9] with barium trapping.
- Intrarectal or intra-anal intussusception.
- Multiple intraluminal filling defects >1 cm in size due to excessive mucosal redundancy (mucosal prolapse).
- Rectal enlargement >7 cm, prolonged evacuation time (i.e., >60 s with or without a split emptying pattern [>3 attempts]), and barium retention at the end of evacuation.

Postoperatively, defecography or, more recently, magnetic resonance defecography [37] is routinely employed at 3- to 6-month intervals to monitor functional outcomes and anatomical changes, although there is a poor correlation between morphology and symptoms even when anatomical anomalies are corrected. One of the expected results after the STARR procedure is the disappearance (significant decrease in size) of the anatomic defects that have led patients to surgery (i.e., rectocele, intussusception, and rectal enlargement with no interference or impairment in either continence or emptying of radio-opaque contrast medium). The most common features reported on defecography after successful surgery include

Fig. 2.5 Inclusion (a) versus exclusion (b) criteria for the stapled transanal rectal resection operation on defecography. (a) Anterior rectocele >2 cm in size and barium trapping after evacuation. (b) Anterior rectocele (top) with persistent impression (arrow) as a result of excessive puborectalis muscle activation, followed by intra-anal intussusception (bottom, black arrows)

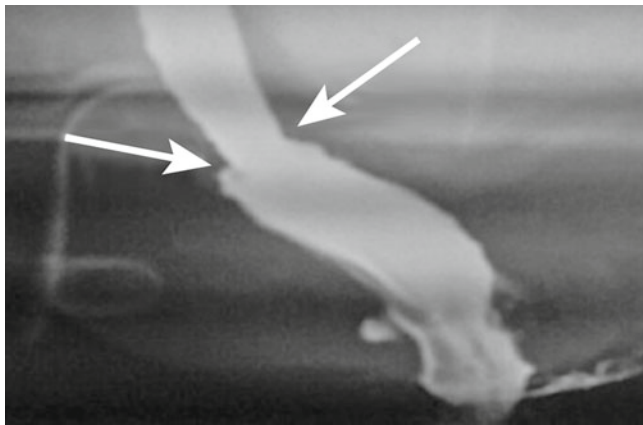
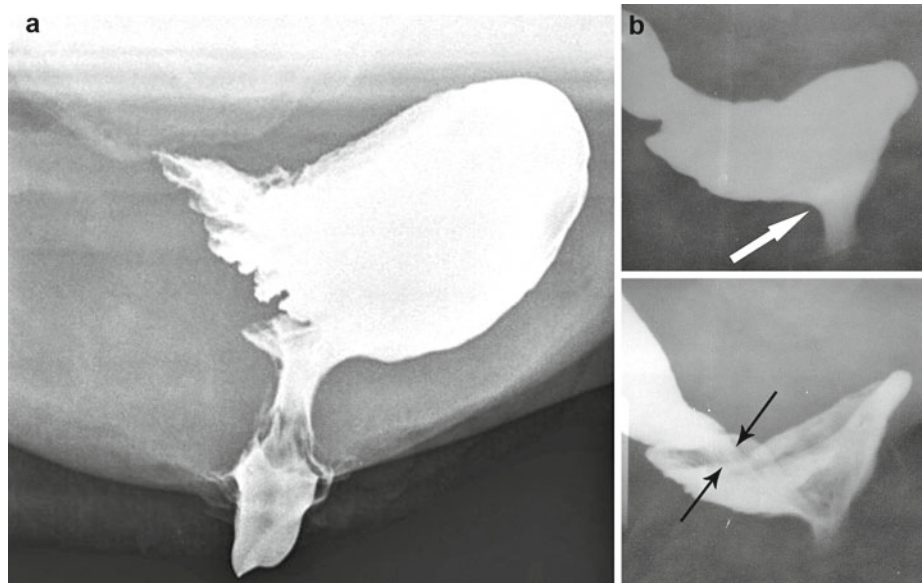


Fig. 2.6 Common postoperative defecographic features after the stapled transanal rectal resection operation; note the small size of the rectal ampulla and uniform annular narrowing (opposed arrows) at the staple line

(1) an average rectal luminal diameter measuring 5 cm (range, 4–8 cm) at the level of the suture line; (2) evidence of a radio-opaque suture line as a uniform and minimal annular narrowing (Fig. 2.6); (3) an average distance of the suture line from the anorectal junction (i.e., the internal anal orifice, measuring 5 cm [range, 3.8–11.6 cm]); (4) vertical dislocation of the anorectal junction ranging from 1 to 4 cm during straining; and (5) occasional evidence of radio-opaque staples. Conversely, abnormal findings found in patients with STARR failure include asymmetry of the suture line, strictures, rectal outpocketing (Fig. 2.7), persistent intussusception and/or a rectocele >2 cm, incomplete emptying, and intraluminal collections of barium and/or extraluminal penetration into adjacent viscera (sinus tract) with anal gaping at rest and involuntary barium loss.

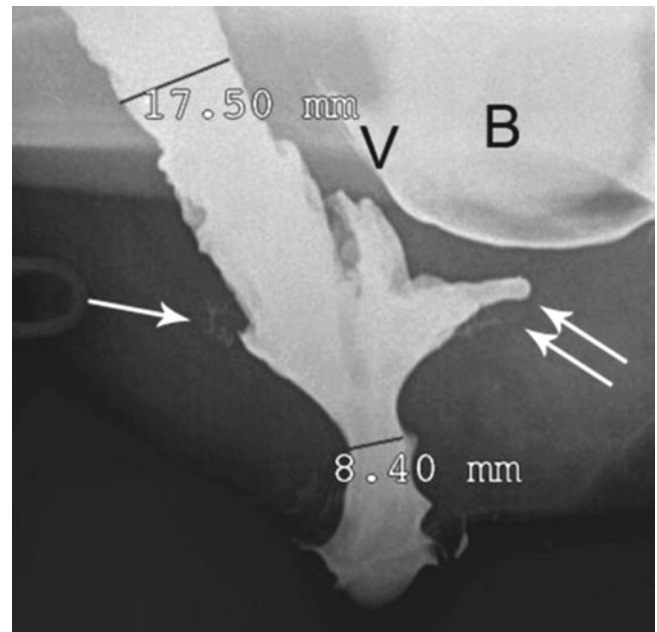


Fig. 2.7 Four-contrast defecography: asymmetric narrowing at the opposite site of the staple line (single arrow) and rectal pocket (double arrows) in a 55-year-old woman with persistent symptoms of obstructed defecation and pain 2 years after a STARR operation. B bladder, V vagina

Conclusion

Conventional (radiographic) defecography is the most traditional imaging technique that has a major impact on the evaluation of functional aspects particularly after pouch-anal or endoanal stapled surgery with regard to patient selection and outcome. In everyday practice, however, its clinical utility occasionally has been proven to define postoperative anatomy and the most common complications, most notably dehiscences, sinus tracts, strictures, ulceration, poor emptying, poor contrast retention, and rectal pockets.

References

1. Utsunomiya J, Iwama T, Imago M, Matsuo S, Sawai S, Yaegashi K, et al. Total colectomy, mucosal proctectomy and ileo-anal anastomosis. *Dis Colon Rectum*. 1980;23:459–66.
2. Parks AG, Nicholls RJ, Belliveau P. Proctocolectomy with ileal reservoir and anal anastomosis. *Br J Surg*. 1980;67:533–8.
3. Dozois RR, Goldberg SM, Rothemberger DA, Utsunomiya J, Nicholls RJ, Cohen Z, et al. Restorative proctocolectomy with ileal reservoir. *Int J Colorectal Dis*. 1986;1:2–19.
4. Nicholls RJ, Pezim ME. Restorative proctocolectomy with ileal reservoir for ulcerative colitis and familial adenomatous polyposis: a comparison of three reservoir design. *Br J Surg*. 1985;72:470–4.
5. Thayer ML, Madoff RD, Jacobs DM, Bubrick M. Comparative intrinsic and extrinsic compliance characteristic of S, J and W ileoanal pouches. *Dis Colon Rectum*. 1992;35:547–51.
6. Kremers PW, Scholz FJ, Schoetz DJ, Veldenheimer MC, Collier JA. Radiology of the ileoanal reservoir. *AJR Am J Roentgenol*. 1985;145:559–67.
7. Thoeni RF, Fell SC, Engelstad B, Schrock TB. Ileoanal pouches: comparison of CT, scintigraphy and contrast enemas for diagnosing postsurgical complications. *AJR Am J Roentgenol*. 1990;154:73–8.
8. Kmiot WA, Yoshioka K, Pinho M, Keighley MR. Videoproctographic assessment after restorative proctocolectomy. *Dis Colon Rectum*. 1990;33:566–72.
9. Bartram CI, Turnbull GK, Lennard-Jones JE. Evacuation proctography: an investigation of rectal expulsion in 20 subjects without defecatory disturbance. *Gastrointest Radiol*. 1988;13(1):1372–80.
10. Turnbull GK, Bartram CI, Lennard-Jones JE. Radiological studies of rectal evacuation in adults with idiopathic constipation. *Dis Colon Rectum*. 1988;31:190–7.
11. Pescatori M, Manhire A, Bartram CI. Evacuation pouchography in the evaluation of ileoanal reservoir function. *Dis Colon Rectum*. 1983;26:365–8.
12. Ascanelli S, Bartolo DCC. Functional outcome after restorative proctocolectomy. *Tech Coloproctol*. 1999;3:145–51.
13. Yu ED, Shao Z, Shen B. Pouchitis. *World J Gastroenterol*. 2007;13:5598–604.
14. Lipman JM, Kiran RP, Shen B, Remzi F, Fazio VW. Perioperative factors during ileal pouch-anal anastomosis predict pouchitis. *Dis Colon Rectum*. 2011;54:311–7.
15. Lazorthes F, Fages P, Chiotasso P. Resection of the rectum with construction of a colonic reservoir and colo-anal anastomosis for carcinoma of the rectum. *Br J Surg*. 1986;73:136–8.
16. Parc R, Tiret E, Frileux P, Moszkowski E, Loygue J. Resection and coloanal anastomosis with colonic reservoir for rectal carcinoma. *Br J Surg*. 1986;73:139–41.
17. Nicholls RJ, Lubowski DZ, Donaldson DR. Comparison of colonic reservoir and straight colo-anal reconstruction after rectal excision. *Br J Surg*. 1988;75:318–20.
18. Landi E, Marmorale C, Piloni V, et al. Functional assessment of coloanal anastomosis with and without reservoir. *Coloproctology*. 1993;6:359–62.
19. Piloni V, Pieri L, Pomerri F, Pittarello F, Salvetti M, Leo E, et al. The 3rd National workshop on defecography: functional radiology of the (neo)rectum (ileal pouch, colo-anal-anastomosis, continent perineal colostomy) [in Italian]. *Radiol Med*. 1996;91:66–72.
20. Longo A. Treatment of haemorrhoidal disease by reduction of mucosal and haemorrhoidal prolapse with a circular-suturing device: a new procedure. In: *Proceedings of the sixth world congress of endoscopic surgery*. Rome: Monduzzi Editori; 1998. p. 777–84.
21. Schwandner O, Stuto A, Jayne D, Lenisa L, Pigot F, Tuech J-J, et al. Decision-making algorithm for the STARR procedure in obstructed defecation syndrome: position statement of the group of STARR pioneers. *Surg Innov*. 2008;15:105–9.
22. Boccasanta P, Venturi M, Roviato G. What is the benefit of a new stapler device in the surgical treatment of obstructed defecation? Three-year outcomes from a randomized controlled trial. *Dis Colon Rectum*. 2011;54:77–84.
23. De Nardi P, Bottini C, Faticanti Scucchi L, Palazzi A, Pescatori M. Proctalgia in a patient with staples retained in the puborectalis muscle after STARR operation. *Tech Coloproctol*. 2007;11:353–6.
24. Jacopo M, Pasquale T, Alfonso C. Early complications after STARR with Contour Transtar. *Int J Colorectal Dis*. 2010;20:83–85. [Epub ahead of print].
25. Boccasanta P, Venturi M, Stuto A, Bottini C, Caviglia A, Carriero A. Stapled transanal rectal resection for outlet obstruction: a prospective, multicenter trial. *Dis Colon Rectum*. 2004;47:1285–96.
26. Dindo D, Weishaupt D, Lehmann K, Hetzer HFH, Clavien PA, Hahnloser D. Clinical and morphological correlation after stapled transanal rectal resection for obstructed defecation. *Dis Colon Rectum*. 2008;51:1768–74.
27. Stuto A, Renzi A, Carriero A, Gabrielli F, Gianfreda V, Villani RD, et al. Stapled trans-anal rectal resection (STARR) in the surgical treatment of the obstructed defecation syndrome: results of STARR Italian Registry. *Surg Innov*. 2011;18:248–253.
28. Boenicke L, Jayne DG, Kim M, Reibetanz J, Bolte R, Kenn W, et al. What happens in stapled transanal rectum resection? *Dis Colon Rectum*. 2011;54:593–600.
29. Dodi G, Pietroletti R, Milito G, Binda G, Pescatori M. Bleeding, incontinence, pain and constipation after STARR transanal double stapling rectotomy for obstructed defecation. *Tech Coloproctol*. 2003;7:148–53.
30. Pescatori M, Zbar A. Reinterventions after complicated or failed STARR procedure. *Int J Colorectal Dis*. 2009;24:87–95.
31. Pescatori M, Dodi G, Salafia C, Zbar AP. Rectovaginal fistula after double-stapled transanal rectotomy (STARR) for obstructed defecation. *Int J Colorectal Dis*. 2005;20:83–5.
32. Sciaudone G, Di Stazio C, Guadagni I, Selvaggi F. Rectal diverticulum: a new complication of STARR procedure for obstructed defecation. *Tech Coloproctol*. 2008;12:61–3.
33. Pescatori M, Gagliardi G. Post operative complications after procedure for prolapsed hemorrhoids (PPH) and stapled transanal rectal resection(STARR) procedures. *Tech Coloproctol*. 2008;12:7–19.
34. Corman ML, Carriero A, Hager T, Herold A, Jayne DG, Leher PA, et al. Consensus conference on the stapled transanal rectal resection (STARR) for disorders defaecation. *Colorectal Dis*. 2006;8:98–101.
35. Stuto A, Schwander O, Jayne D. Assessing safety of the STARR procedure for ODS: preliminary results of the European STARR registry. *Dis Colon Rectum*. 2007;50:724.
36. Carriero A, Picchio M, Martellucci J, Talento P, Palimento D, Spaziani E. Laparoscopic correction of enterocele associated to stapled transanal rectal resection for obstructed defecation syndrome. *Int J Colorectal Dis*. 2010;25:381–7.
37. Grassi R, Romano S, Micera O, Fioroni C, Boller B. Radiographic findings of postoperative double stapled trans-anal rectal resection (STARR) in patients with obstructed defecation syndrome (ODS). *Eur J Radiol*. 2005;53:410–6.

Reconstructive Surgery of the Rectum, Anus and
Perineum

Zbar, A.P.; Madoff, R.D.; Nasser, Y. (Eds.)

2013, XXIII, 606 p. With online files/update., Hardcover

ISBN: 978-1-84882-412-6