

# Epstein–Barr Virus and Cytomegalovirus Infections

Alex Tselis

**Abstract** Epstein–Barr virus and cytomegalovirus are members of the human herpesviruses that have an extremely high seroprevalence in all populations studied. The initial infection is usually asymptomatic, or causes a febrile illness, but can rarely manifest itself neurologically. These viruses are increasingly important in the modern era of immunosuppression, whether due to AIDS or in the transplant or cancer chemotherapy population, and their reactivation gives rise to a wide spectrum of neurological diseases. The pathogenesis of these infections is not completely understood, but certainly multifaceted. In CMV lytic infection damages systemic tissues directly, whereas EBV involves an activated and distorted immune system. These diseases are treatable, but need to be recognized early in their course so that antiviral intervention can be effected promptly. The choice of therapeutic strategy can be counterintuitive: while CMV infections are conventionally managed with antiviral medications, EBV infections may demand a neoplastic treatment paradigm as an addition to (or alternative to) antiviral treatment.

**Keywords** Cytomegalovirus • Diagnostic virology • Encephalitis • Epstein–Barr virus • Immunosuppression • Lymphoproliferative disorder • Myelitis • Opportunistic infections • Primary CNS lymphoma

## 1 Introduction

Epstein–Barr Virus (EBV) and cytomegalovirus (CMV) are two herpesviruses occasionally associated with neurologic disease. They share with other herpesviruses the property of initial infection of young hosts, establishment of latency, and “reactivation” later in life, with variable consequences. While most initial infections with these viruses

---

A. Tselis (✉)

Department of Neurology, Wayne State University, Detroit, MI, USA  
e-mail: [atselis@med.wayne.edu](mailto:atselis@med.wayne.edu)

are clinically self-limited, some have prominent neurological manifestations. In the modern era of immunocompromised patients who have had a transplant, cancer chemotherapy, autoimmune disease, or AIDS, reactivation of these viruses can have devastating consequences. These reactivations can have quite novel manifestations and reflect unusual pathogenetic mechanisms.

## 2 Epstein–Barr Virus

### 2.1 *A Brief History*

The history of the discovery of EBV is one of the great medical detective stories of the twentieth century. A febrile pharyngitis with cervical lymphadenopathy was described late in the nineteenth century. While a number of illnesses can have this presentation, a subset with very high peripheral mononuclear cell counts was defined in 1920 by Sprunt and Evans (1920) and called “infectious mononucleosis (IM).” The observation by Haganutziu and Deicher that serum sickness was associated with a sheep red cell agglutinin was confirmed by Paul and Bunnell (1932). They attempted to define the specificity of this observation by examining control sera. One of these showed a very high titer of such agglutinins, and was found to be from an IM patient. This led to the discovery of the so-called “heterophile antibodies (HA),” which evolved into a diagnostic test for IM. Attempts to transmit the disease to other humans or animals were inconsistently successful and further advances had to wait several decades.

In 1946, a British colonial surgeon, Denis Burkitt, was assigned to a post in Uganda, where he took care of a population of 250,000 people. In 1957, he was asked to see a child with a peculiar mass in the jaw, which rendered him “totally baffled.” He saw other such cases and reviewed the hospital records for other cases. These showed that the tumor, a lymphoma, often affected the internal organs and the nervous system, rather than lymph nodes. He sent questionnaires to clinics around the continent using mails, and was able to establish the geographic distribution of this tumor, and noted that it overlapped the distribution of malaria and yellow fever, as well as an epidemic of o’nyong nyong fever. The fact that the geographical distribution of Burkitt’s lymphoma (BL) overlapped that of several mosquito-borne diseases suggested the possibility that the disease was transmittable. Burkitt gave several talks about his findings on a visit to London, and Anthony Epstein, a virologist interested in tumor viruses, was present. He had Burkitt send him samples of the tumors and was able to detect a herpes-like virus by electron microscopy. However, the virus could not be cultured. For more accurate characterization of the virus, samples were sent to the laboratory of Werner and Gertrude Henle. They were able to show that antibodies to the Epstein–Barr virus (EBV) were present not only in pediatric oncology patients, but also were common in the general population. The first connection between EBV and a specific disease was made when a technician in

the Henles' laboratory, who was seronegative, developed IM. Her serum, previously used as a negative control, became strongly seropositive (Henle et al. 1968). This observation provided the impetus for the studies of college students by Niederman et al. (1968) in which the etiologic role of EBV in IM was established. The role of EBV was then established in a number of tumors. This includes BL, a number of B and T cell lymphomas, Hodgkin's lymphoma, and leiomyosarcoma. Further, systemic "opportunistic lymphomas" in the context of transplantation, AIDS, and chemotherapy are often caused by EBV. These include posttransplant lymphoproliferative disorder (PTLD) and the experiment-of-nature X-linked lymphoproliferative disorder (XLPD), in which there is an uncontrolled proliferation of EBV-infected B cells because of a novel immune defect.

## 2.2 *Basic Virology*

The virus consists of a nucleocapsid containing a 184 kbp double stranded (ds) DNA molecule surrounded by 162 capsomers. The nucleocapsid is surrounded by a protein-rich tegument, which in turn is surrounded by an envelope.

The genome of the virus is structured similar to other herpesviruses, in which there are unique long and short regions, separated by a long run of internal repeats, and flanked by terminal repeats. There are about 190 genes per genome.

There are overall two types of genes in the EBV genome. When the virus infects its target cells, it replicates in two different ways, latent and lytic replication. In latent replication in EBV-infected B cells, the EBV genome replicates along with the cellular DNA, using the cell's own DNA polymerase. Thus, cellular and viral DNA are replicated by cellular DNA polymerase in latent replication. In the latent state, there is minimal expression of viral genes. In lytic replication, which occurs in epithelial cells and plasma cells, the viral DNA is replicated by viral DNA polymerase, and assembled into full virions that are released by lysis of the infected cell. It is important to note that antiviral drugs such as acyclovir and ganciclovir will inhibit the viral but not the cellular DNA polymerase. Thus, these drugs decrease lytic but not latent replication. The spectrum of disease depends on the type of replication as will be seen later.

## 2.3 *Spectrum of Systemic Disease Associated with EBV*

Primary EBV infection is often asymptomatic, especially in children. In young adults, the infection causes a febrile pharyngitis with prominent cervical lymphadenopathy and significant fatigue and malaise. This illness is called EBV-associated infectious mononucleosis (EBV IM). Usually, recovery is complete within a few weeks, although cases lasting several months have been reported. Interestingly, many patients develop a rash when treated for their pharyngitis with ampicillin, in order to cover a possible bacterial infection. The disease can be

diagnosed by one of the slide tests to screen for it or more definitively by an EBV panel (see below). Other mimics of EBV IM include primary CMV disease, human herpes virus 6 disease (HHV6), acute retroviral syndrome, secondary disseminated syphilis, and acute toxoplasmosis (Hurt and Tammaro 2007).

Other manifestations of EBV IM include severe tonsillitis (which can potentially interfere with swallowing), splenomegaly (with a small risk of splenic rupture), hepatitis, myocarditis, pneumonitis, interstitial nephritis, and hemolytic anemia. These are uncommon, but point to the diversity of clinical manifestations of acute EBV infection.

EBV-infected B cells are transformed and tend to proliferate spontaneously. This proliferation, if uncontrolled, can result in serious disease. Therefore, EBV infection does not cause illness by causing lysis of tissues, but by the immune suppression of these proliferating B cells. Thus, rarely, IM can be severe, with poorly controlled proliferation of the infected B cells, and fatal results. This is a rare entity known as fatal IM (FIM) and can be seen in X-linked lymphoproliferative disorder, and it may be seen in other more subtle immune deficiencies. Acute EBV can cause a hemophagocytic syndrome, a sepsis-like syndrome caused by EBV triggering widespread macrophage activation and histiocytosis leading to a cytokine storm with multiple organ failure. In a few cases, EBV-driven lymphoproliferative syndrome can affect the central nervous system, as part of the systemic disease.

EBV can also result in a broad spectrum of neoplasms and lymphoproliferative states. One of the first to be characterized, as discussed above, is Burkitt's lymphoma, in which there is systemic lymphomatous involvement, particularly with visceral involvement. A high proportion of the original patients with Burkitt's lymphoma has central nervous system involvement. Others, as mentioned above, include Hodgkin's lymphoma (HL), posttransplant lymphoproliferative disorder (PTLD), X-linked lymphoproliferative disorder (XLPD), primary CNS lymphoma (especially in AIDS patients), nasopharyngeal carcinomas of Southeast Asia, T cell and NK cell lymphomas, and leiomyosarcomas. These generally involve latent infection of the neoplastic cells. Oral hairy leukoplakia, an infection of the tongue epithelium, is a lytic infection.

## ***2.4 Pathology and Pathogenesis***

EBV is transmitted by intimate oral contact, with virus shed asymptomatically in the saliva. The initial infection is of B cells in the oral mucosa. These cells are immortalized and proliferate, with latent replication of the virus within the B cells. The latently infected B cells express a very limited set of proteins and latency-associated RNA molecules. These sets (or latency types) depend on the stage of the illness (Table 1). These antigens are recognized by the immune system and a T cell response is generated. The infection is thereby controlled, but not eliminated. In some cases, the manifestations of the disease tend to be focal, with a clinical picture of hepatitis, meningitis, or encephalitis. It is not clear why this occurs in an otherwise systemic disease.

**Table 1** Latency antigens and types

| Latency type  | Latency antigens                                      |        |        |        |       |       |       |
|---------------|---|--------|--------|--------|-------|-------|-------|
|               | EBER  | EBNA-1 | EBNA-2 | EBNA-3 | LMP-1 | LMP-2 | BARTs |
| 1             | +   | +      | –      | –      | –     | –     | +     |
| 2             | +   | +      | –      | –      | +     | +     | +     |
| 3             | +   | +      | +      | +      | +     | +     | +     |
| Other         | +   | +/–    | –      | –      | –     | +     | +/–   |
| Latency types |   |        |        |        |       |       |       |
| Latency 1     | Burkitt’s lymphoma                                    |        |        |        |       |       |       |
| Latency 2     | Nasopharyngeal carcinoma, Hodgkin’s disease           |        |        |        |       |       |       |
| Latency 3     | Infectious mononucleosis, lymphoproliferative disease |        |        |        |       |       |       |
| Other         | Peripheral blood B lymphocytes                        |        |        |        |       |       |       |

*EBER* Epstein–Barr virus-encoded RNA, *EBNA* Epstein–Barr nuclear antigen, *LMP* Latent membrane protein, *BART* BamHI A rightward transcripts

The pathogenesis of encephalitis (or meningitis or hepatitis or other focal visceral involvement) is not completely clear and there are several possibilities, which are not mutually exclusive. First, EBV may affect neurons (or other neural cells or endothelium) directly (Jones et al. 1995). There have been a few scattered reports of neurons and glial cells staining with EBV antigens, although there is not much detail (Biebl et al. 2009). In some patients with EBV encephalitis, as well as some with primary CNS lymphoma, lytic EBV mRNA was detected in the CSF, suggesting lytic replication of EBV in the brain in addition to latent replication (Weinberg et al. 2002a). Secondly, EBV-infected B cells are in an activated state and elaborate several proinflammatory cytokines, which can cause injury of the surrounding parenchyma (Foss et al. 1994). This injury is not necessarily irreversible. Third, EBV-infected B cells are actively attacked by EBV-specific cytotoxic T cells, and this can also injure the surrounding parenchyma. Finally, an acute disseminated encephalomyelitis can be triggered as in other viral infections.

Normally, EBV-infected B cells are suppressed (though not eliminated) by the immune system and lymphoproliferation can result during immunosuppression. In tissue culture in which T cells have been eliminated, B cells are immortalized and proliferate. In vivo, the B cell lymphoproliferation proceeds sequentially from polyclonal to oligoclonal to monoclonal, and evolves into a lymphoma. This can occur under circumstances of immunosuppression in transplant, chemotherapy, and AIDS patients as mentioned above. The lymphoproliferation can be accompanied by the elaboration of various cytokines, and a severe systemic illness resembling sepsis can result.

**2.5 Spectrum of Neurologic Disease Associated with EBV**

The spectrum of neurologic disease caused by EBV is very broad, and encompasses all of the neurological syndromes, pure or mixed: meningitis, encephalitis, myelitis,

radiculopathy, plexitis, psychosis, and behavioral abnormalities. These syndromes may precede, follow, or occur independent of IM.

### 2.5.1 Aseptic Meningitis

Aseptic meningitis was one of the first reported complications of acute EBV infection, reported by Johansen (1931). Headaches are not rare in IM, and it is likely that some of these are due to aseptic meningitis. The early appreciation of aseptic meningitis is illustrated by a 1950 review of neurological complications of IM in which it was found in 41 % of the cases (Bernstein and Wolfe 1950). It is self-limiting.

### 2.5.2 Encephalitis

Encephalitis is an uncommon manifestation of IM with a broad clinical spectrum, but most cases have the usual presentation of fever, headache, confusion, seizures, and focal features. EBV encephalitis can precede, coincide with, or follow typical IM, and IM may be absent altogether (Silverstein et al. 1972; Friedland and Yahr 1977; Greenberg et al. 1982; Russell et al. 1985; Leavell et al. 1986; McKendall et al. 1990).

Brainstem encephalitis due to EBV has been reported in three cases, with one complete recovery, one with a residual ataxic gait, and one death (Shian and Chi 1994; North et al. 1993; Angelini et al. 2000). The syndrome of opsoclonus–myoclonus has been described in several cases of acute EBV infection. In one case, the patient had opsoclonus–myoclonus with ataxic gait. EBV was detected in the cerebrospinal fluid (CSF) by polymerase chain reaction (PCR) amplification. He was treated with intravenous methylprednisolone followed by intravenous immunoglobulin and returned to work 5 months later (Verma and Brozman 2002). Other cases of EBV-associated opsoclonus–myoclonus have a similar benign outcome.

Movement disorders have been reported in EBV encephalitis cases. In one case which resembled encephalitis lethargica, the patient developed an akinetic-rigid syndrome with tremor and sialorrhea. The MRI showed strongly abnormal signal in the striatum. Corticosteroids and antiparkinson drugs were given and the symptoms resolved over 2 months (Dimova et al. 2006). In another parkinsonian syndrome developed coincident with EBV encephalitis, antineuronal antibodies were detected in the serum of the patient but not three controls. Brain MRI was normal. Acyclovir, dexamethasone, and antiparkinsonian medications were given and the patient returned to normal over the next 2 months (Roselli et al. 2006).

### 2.5.3 Cranial Nerve Palsy

The most common cranial nerve palsy associated with acute EBV infection is Bell's palsy, which may be unilateral or bilateral (Grose et al. 1973; Egan 1960).

Sometimes several cranial nerves can be affected. A case of unilateral Bell's palsy with ipsilateral deafness and facial numbness has been reported to follow IM (Taylor and Parsons-Smith 1969). Optic neuritis and retinal involvement, which can be bilateral, has rarely occurred with IM (Ashworth and Motto 1947; Blaustein and Caccavo 1950; Bonynghe and Van Hagen 1952).

#### **2.5.4 Transverse Myelitis**

Transverse myelitis has occasionally coincided with acute EBV infection. Several cases of TM have been reported in the literature, in which lower extremity paresthesias followed clinical IM, and progressed rapidly to flaccid paraplegia within a few days. Sensory levels and upgoing toes were seen (Cotton and Webb-Peploe 1966; Grose and Feorino 1973; Clevenbergh et al. 1997). One patient had a transient tetraparesis but normal gait on examination. Spinal sensory level was noted. Diagnosis was made by serology in two cases and PCR detection of EBV DNA in CSF in one (Clevenbergh et al. 1997). In all cases there was slow recovery over months. One of the patients received ACTH.

#### **2.5.5 Cerebellar Ataxia**

Acute cerebellar ataxia occurs in some patients with acute EBV infection, often following mild disease. Classically this has been attributed to varicella zoster virus (VZV) infection, especially in children. However, a significant number of cases are associated with EBV both in children and adults (Bergen and Grossman 1975; Cleary et al. 1980; Bennett and Peters 1961; Gilbert and Culebras 1972; Lascelles et al. 1973). The patients have gait ataxia and dysarthric speech, with mild pleocytosis and modestly increased CSF protein. Some have responded to ACTH, prednisone, and plasmapheresis (Schmahmann 2004). Recurrent cerebellitis was reported, in which a patient with dysarthria, dysmetria, and gait ataxia had a positive EBV VCA IgM, and resolved with prednisone. A year later, the symptoms recurred and resolved again with another course of prednisone (Shoji et al. 1983).

#### **2.5.6 Alice-in-Wonderland Syndrome**

Alice-in-Wonderland syndrome is a peculiar neuropsychiatric entity in which the patient develops metamorphopsia or distortion of spatial perception in which objects around the patient are perceived to be distorted in size, shape, and orientation. These episodes last about half an hour, and are understandably anxiety provoking. Neurologic examination is usually normal and EEGs are normal or minimally abnormal. Single patients were treated with prednisone and phenytoin, without clear effect. The symptoms resolve spontaneously over a few weeks (Copperman 1977; Eshel et al. 1987). Visual evoked potentials have an increased

P100-N145 wave complex, and hexamethylpropylene amine oxime single-photon emission computed tomography showed decreased perfusion in the visual tracts and visual cortex (Lahat et al. 1999; Kuo et al. 1998).

### 2.5.7 Acute Hemiplegia

Occasionally acute EBV infection can be associated with a rapidly developing hemiplegia, which can resemble a stroke. Some cases of so-called “acute hemiplegia of childhood” may well be due to acute EBV, and there are detailed reports of such cases. A 14-year-old girl had a left hemiplegia and left-sided numbness that evolved over several days along with right-sided headache, vomiting, and photophobia. She had two seizures and cervical lymphadenopathy. A fever prompted a CSF examination which showed moderate pleocytosis. She became confused and ataxic. Acute EBV infection was demonstrated by serology. She recovered completely in a few months (Leavell et al. 1986). Two other similar cases with unilateral headache and contralateral hemiplegia were reported in a 9-year-old girl and a 32-year-old man (Baker et al. 1983; Adamson and Gordon 1992). The former patient’s hemiplegia spontaneously improved to normal over a few days. The latter, who had a normal brain CT, resolved completely within a day of starting on dexamethasone.

### 2.5.8 Neurological Lymphoproliferative Disorder

As discussed above, EBV-infected B cells have a tendency to proliferate. This is stopped by the immune system, but if immunity is ineffective, then proliferation proceeds relatively unchecked, leading to polyclonal expansion and eventually oligoclonal and finally monoclonal lymphomas. Such lymphoproliferative disorders can affect the nervous system in the course of systemic disease. For many of these the distinction between infection, inflammation, and neoplasm is obscured. In one case of a 14-year-old girl with a chronic febrile illness, ataxia and hemiparesis led to an MRI of the brain which showed multifocal white matter lesions. Acute EBV was diagnosed by serology. These resolved with steroids, which needed to be used several times over the next few years, when she had relapses. Several years later she developed pneumonitis and a biopsy found lymphomatoid granulomatosis. A few years after that she developed disseminated intravascular coagulation with hemophagocytic syndrome. In patients with lymphomatoid granulomatosis, there is both pulmonary and CNS involvement. Often, biopsy of the lesions show scattered lymphocytes that stain positively for EBV antigens. Various treatments have been used, including chemotherapy and radiation, rituximab, and cyclophosphamide, with some success (Mizuno et al. 2003; Zaidi et al. 2004). In another case of lymphoproliferative disorder, a 17-year-old boy developed EBV-IM which in a few weeks evolved into a sepsis-like syndrome with encephalopathy. He was found to have hemophagocytic



syndrome on bone marrow biopsy and a very high EBV load in the blood. He was treated with methylprednisolone, intravenous immunoglobulin, rituximab (B cell depleting antibody), etanercept (anti-TNF $\alpha$  antibody), and etoposide. His medical condition improved, but he showed no cognitive improvement and an MRI showed scattered nonenhancing frontal white matter disease. Intrathecal chemotherapy was instituted with both cognitive and imaging improvement (Mischler et al. 2006).

In patients with severe immunosuppression, especially in advanced HIV disease, primary CNS lymphoma (PCNSL) is not uncommon. In the AIDS population, this is almost 100 % driven by EBV, whereas PCNSL is only rarely EBV-related in those not infected with HIV (Larocca et al. 1998; Hochberg et al. 1983).

## **2.6 *Diagnosis***

The strategy of the diagnosis of EBV-related neurologic disease depends upon the patient's age, history, and degree of immunosuppression, in addition to the clinical presentation. The demonstration of the appropriate serologic findings, viral antigens, and DNA supports the clinical impression and may confirm the diagnosis. There are, of course, subtleties which will be mentioned below.

In the case of an adolescent patient with fever, headache, sore throat, enlarged cervical lymph nodes, and splenomegaly, leukocytosis with atypical lymphocytes in the peripheral smear, the diagnosis of EBV meningitis can be confirmed by a CSF examination to rule out other etiologies, and either a heterophile slide test or an EBV panel in the serum. Other neurological syndromes, especially in the past, have been attributed to EBV because of the coincidence of the symptoms and serology demonstrating acute EBV infection. More recently, the acute EBV panel is used to confirm disease, since the heterophil slide tests can be falsely negative (uncommon). The heterophil test continues to be relevant, however, since occasionally the EBV panel is difficult to interpret.

### **2.6.1 Serological Tests for EBV**

#### **Heterophile Slide Tests**

It may be recalled that early in the twentieth century IM was noted to be associated with a sheep red cell agglutinin. This antibody is specific for but not directed at EBV antigens and is known as a heterophile antibody (HA), since it is elicited by one type of antigen and is directed to a separate, unrelated one. A positive serum HA test conclusively establishes an acute EBV infection. Before the EBV panel became available, neurologic disease was related to EBV by the coincidence of the clinical illness with a positive HA test.

**Table 2** Serology in EBV infection

| EBV status                      | VCA IgM | VCA IgG | EA  | EBNA |
|---------------------------------|---------|---------|-----|------|
| Seronegative                    | —       | —       | —   | —    |
| Recent primary                  | +       | +       | +/- | —    |
| Seropositive (remote infection) | —       | +       | +/- | +    |
| Infectious mononucleosis        | +       | +       | +   | —    |
| Reactivated infection           | +/-     | +++     | +++ | +    |

*VCA IgG* Viral capsid antigen immunoglobulin G, *VCA IgM* Viral capsid antigen immunoglobulin M, *EA* Early antigen (antibody to), *EBNA* Epstein–Barr nuclear antigen (antibody to)

(—) No antibody

(+/-) Either positive or negative

(+) Detectable antibody

(+++)

### EBV Panel

The EBV panel tests for antibodies to specific EBV antigens. Different patterns of antibodies appear at different stages of EBV infection. These antigens are comprised of the viral capsid antigen (VCA), which is a structural protein, early antigen (EA), which is a complex expressed during viral lytic replication, and Epstein–Barr nuclear antigen (EBNA), which is a group of proteins confined to the nucleus and expressed during latent infection in B cells. It was found by Henle et al. (1974) that in acute EBV infection, the first antibody to appear is against EBV VCA, IgM followed by IgG, the second is to EA, and, finally, the third, to EBNA after the acute infection has resolved. Thus, a positive EBV VCA IgM and negative EBNA IgG indicate acute EBV infection while a positive EBV VCA IgG and positive EBNA IgG would be compatible with a remote infection. A guide to interpretation of the EBV panel is given in Table 2.

### PCR Detection of EBV DNA

The detection of EBV DNA by PCR in the CSF has become the gold standard for the demonstration of EBV disease in the CNS, although few systematic studies have been done. There have been reports of acute neurologic syndromes in which EBV serology indicated acute infection, and EBV was detected in the CSF by PCR, which suggests the strategy of using both PCR and serology. In a series of 39 patients with acute neurologic disease, and PCR detection of EBV DNA in CSF, three categories of disease were noted: acute EBV encephalitis, PCNSL, and postinfectious EBV complications (such as acute disseminated encephalomyelitis, Guillain–Barre syndrome (GBS), and transverse myelitis). The quantity of EBV and degree of inflammation (as measured by pleocytosis) were both high in encephalitis. In PCNSL, the quantity of virus was high, but there was little inflammatory pleocytosis, as would be expected of a virally driven neoplasm. In postinfectious complications, the viral burden was low, and the inflammatory

pleocytosis high. These patterns are as expected, and underline that detection of EBV DNA is not specific for EBV encephalitis (Weinberg et al. 2002a).

Furthermore, some patients with acute neurologic infections have been found to have EBV and another pathogen detected in the CSF (Weinberg et al. 2005). It was estimated that in 25 % of the patients (both immunocompetent and immunosuppressed) with EBV detected in the CSF, a second pathogen may be present. Some of the co-pathogens included CMV, VZV virus, JC polyomavirus, West Nile virus, pneumococcus, Cryptococcus, ehrlichiosis, and mycoplasma. These results may be due to “reactivation” of EBV because of another infection, or to dual, independent infections. The significance is unclear, and underscores the utility of EBV panels and heterophile testing to provide independent information.

### Viral Antigen Detection

Viral antigen detection is not commonly used in the diagnosis of neurologic EBV disease, but is used mostly in systemic disease, particularly in transplants. Thus, the differentiation between lymphoproliferative disorder (PTLD) in a transplanted liver and rejection may be difficult. A biopsy that detects lymphocytes bearing latency antigens would suggest PTLD. The diagnosis cannot be made on morphology alone, since there is great variability and not all neoplasms have a monomorphic appearance. Similarly, the diagnosis of PCNSL in AIDS patients often relies upon the detection of latent antigens in lymphocytes.

### 2.6.2 Magnetic Resonance Imaging

There are no characteristic imaging findings that specifically suggest EBV encephalitis. Brain MRI can be normal, or show abnormal signal in the hemispheres (with gyral pattern or diffuse edema), basal ganglia, cerebellum, brainstem, thalamus, and limbic system (Tselis et al. 1997; Abul-Kasim et al. 2009). The abnormal signal may involve white matter as well as the deep gray structures, such as the basal ganglia and thalamus (Caruso et al. 2000; Garamendi et al. 2002; Phowthongkum et al. 2007). There are examples of simultaneous gray and white matter involvement (Fujimoto et al. 2003). There may be pathogenetic implications of the imaging findings. Thus, pure cortical or deep gray involvement may imply a “pure EBV encephalitis,” whereas pure white matter involvement may be due to parainfectious demyelination.

Imaging findings may also have some prognostic value. In the Abul-Kasim et al. (2009) study, it was found that of those with normal imaging, 92.5 % had a good outcome, while of those with abnormal imaging, only 60.7 % did.

## 2.7 *Management*

The management of neurologic EBV disease depends upon the pathogenesis of the illness and there is no clear consensus on how to treat the diseases this virus causes. Therapeutic modalities would have to be exceptionally safe, since neurologic EBV disease tends to have a very benign course, even if it were very severe during the acute phase. Thus neurologic EBV disease tends to improve whether patients are treated with antivirals or not, and whether the patient is immunodeficient (e.g., HIV positive) or not (Weinberg et al. 2002a).

EBV encephalitis illustrates these issues well. If the major pathogenesis of the disease is direct lytic infection of neurons or endothelial cells in the brain (as in herpes simplex encephalitis), then antiviral drugs such as acyclovir or ganciclovir should be used since they inhibit viral DNA polymerase and prevent lytic infection. However, there is no much evidence for lytic infection in EBV encephalitis. In one autopsy, viral antigens were found in neurons and astrocytes (Biebl et al. 2009). In the CSF of EBV encephalitis and PCNSL, lytic EBV mRNAs were found but the source (neurons, glia, endothelial cells, lymphocytes, or plasma cells) is unknown (Weinberg et al. 2002b). In EBV IM, acyclovir reduces viral shedding, but has no effect on symptoms. It is not recommended to use acyclovir for EBV encephalitis by the Infectious Diseases Society of America (IDSA) guidelines, although corticosteroids can be given consideration (Tunkel et al. 2008).

On the other hand, if EBV encephalitis were due to the accumulation of activated EBV-infected B cells secreting inflammatory cytokines, which caused the damage, a strategy to eliminate such B cells would be considered, using a drug such as rituximab, which specifically depletes B cells. Of course, such a drug would have to have access to the CNS in order to remove parenchymally placed B cells. However, since the disease seems to have a relatively benign course, such treatment may not be especially useful. Other immunomodulatory or immunosuppressive drugs, such as corticosteroids or intravenous immunoglobulin, often seem to be followed by improvement and are relatively safe to use.

For neurological EBV disease that is part of an EBV lymphoproliferative syndrome (LPD), the disease has a systemic neoplastic character and chemotherapy and radiation, possibly combined with rituximab (to deplete B cells) should be considered.

## 3 Cytomegalovirus

### 3.1 *A Brief History*

In contrast to the dramatic history of the discovery of the nature of EBV, the elucidation of the pathogenesis of CMV disease came about by an almost logical

accumulation of discrete steps of important observations and discoveries (Ho 2008; Riley 1997; Weller 1970, 2000).

The characteristic cytomegalic cells of CMV disease were first noted by Ribbert in 1881 in the kidney and parotid glands of a syphilitic neonate, and confirmed by Jesionek and Kiolemenoglu (1904). They interpreted these cells as protozoa. Others took up the search and found similar cells in other infants. The similarity of these cells to those seen in herpes zoster and herpes genitalis was remarked by Goodpasture and Talbot (1921) and by Von Glahn and Pappenheimer (1925). The prominence of these cells in salivary glands prompted the term “salivary gland virus.” In 1926, a guinea pig model of salivary gland virus disease bolstered the case for the viral nature of the agent as salivary gland disease was shown to be transmissible by a filterable agent. As experience accumulated, a neonatal illness with petechiae, hepatosplenomegaly, and brain calcifications was characterized and correlated with the presence of cytomegalic cells. Wyatt et al. (1950) coined the term “generalized cytomegalic inclusion disease.” When it was found that kidney tubule cells had viral inclusions, the idea of detecting cytomegalic cells in urine was used to make the diagnosis antenatally by Fetterman in 1952. The virus was isolated by three independent groups, those of Smith (1956), Weller et al. (1957), and Rowe et al. (1956). The latter developed a complement-fixation test that was used to show that the seroprevalence in human populations was very high with an increase in age prevalence. From the mid-1950s to the mid-1980s, more disease associations were established. These include the connection between congenital CMV infection, defined by CMV viruria, and deafness and cognitive difficulties later in life; the connection between CMV and CMV mononucleosis; transmission of CMV by transfused blood during cardiac surgery known as the “postperfusion syndrome”; and CMV disease in transplant and AIDS patients (Ho 2008; Riley 1997; Weller 2000).

### 3.2 *Basic Virology*

The structure of the CMV virion is similar to that of other herpesviruses with a double-stranded DNA viral genome enclosed in a capsid, which is surrounded by a protein-rich tegument, enveloped within a viral membrane. The genome codes for about 230–250 proteins, depending on the isolate (clinical vs laboratory), and is composed of a unique long (UL) and a unique short (US) region, flanked by terminal repeats. The proteins encoded by the open reading frames (ORFs) are labeled according to their position on the genome, following a common descriptive name. Thus, a phosphoprotein of molecular weight 65 coded by the 83rd ORF in the UL region would be labeled as pp65 (UL83).

CMV genes consist of latent and lytic types. The former are not as well characterized as those of EBV, but generate RNA transcripts that are reminiscent of the latency-associated transcripts (LATs) in herpes simplex infection or the EBERs of EBV infection. The lytic genes are grouped into three categories:

immediate early (or alpha) genes (IE), early (or beta) genes (E) and late (or gamma) genes (L). These permit viral takeover of macromolecular synthesis, synthesis of products necessary for DNA replication (e.g., viral DNA polymerase), and synthesis of structural components of the virion (e.g., capsid proteins), respectively.

### ***3.3 Spectrum of Systemic CMV Disease***

Initial infection is usually asymptomatic or results in a self-limited mononucleosis-like syndrome with fever, malaise, and sweats (Klemola and Kaariainen 1965). Signs of hepatitis are noted in about a third of the patients and there is less pharyngitis and only minimal cervical adenopathy. The heterophile antibody test is always negative and helps to differentiate CMV-associated IM (CMV IM) from EBV IM. Lymphocytosis with atypical cells is seen in both. Severe end organ involvement is rare in primary CMV infection in otherwise healthy hosts.

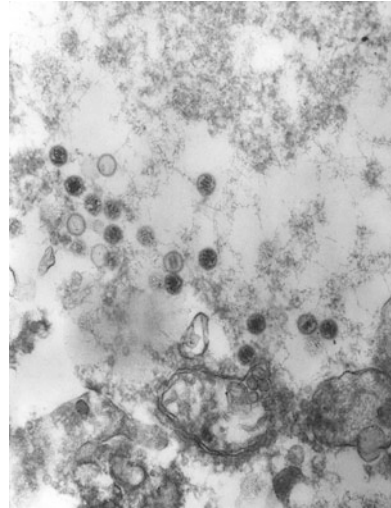
Serious CMV disease is mostly confined to immunosuppressed patients, especially AIDS, transplant, and chemotherapy patients. The disease is usually organ specific in solid organ transplants, but is often systemic in bone marrow or stem cell transplants (SCT). Active CMV infection after a transplant resembles CMV mononucleosis with evolution to involve specific organs, especially pneumonitis, hepatitis, colitis, esophagitis, gastritis, colitis, adrenalitis, and rarely encephalitis. Often the organ infected is the transplanted one, and in AIDS patients, multiple organs are often involved.

### ***3.4 Pathology and Pathogenesis***

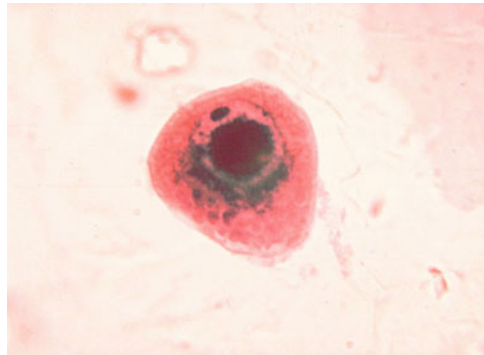
In contrast to the multiple pathogenic processes by which EBV causes disease, the pathogenesis of direct CMV infection is much simpler, in that it mainly causes lytic infection of different types of cells. The typical CMV infected cell has a characteristic appearance (see Fig. 1), but CMV antigens can be detected in normal-appearing cells.

The initial infection occurs when virus, shed in secretions such as saliva, urine, and genital secretions, infects the naïve host. It attaches to and initially infects epithelial cells. A cell-associated viremia then ensues and the virus is deposited systemically, infecting fibroblasts, epithelial cells, endothelial cells, and smooth muscle cells (Sinzger et al. 1995). Viral antigen can be detected in multiple organs, including the brain, even in asymptomatic patients (Toorkey and Carrigan 1989). The virus latently infects myeloid precursor cells, from CD34<sup>+</sup> pluripotent stem cells to CD14<sup>+</sup> monocytes. When the latter enter visceral parenchyma and differentiate into macrophages and myeloid dendritic cells, the latent infection reactivates into a lytic one, with lytic infection of and damage to the surrounding

**Fig. 1** Epstein–Barr virions seen in this transmission electron micrograph. Courtesy of Dr. Fred Murphy, CDC, CDC Public Health Image Library



**Fig. 2** Cytomegalic cell in urine. Courtesy of Dr. Haraszti, CDC, CDC Public Health Image Library



parenchyma. However, T cell immunity develops and active infection is suppressed.

CMV can “reactivate” periodically with nonspecific changes in CMV antibody titers and shedding of virus in saliva, urine, genital secretions, or even in the circulation. Thus, the virus can potentially spread through day care centers, caregivers, organ and blood recipients, and sexual partners. Known specific triggers of reactivation include radiation, allogeneic stimulation, TNF $\alpha$ , and cytotoxic drugs. In a murine model, CMV was reactivated in an allogeneic but not in a syngeneic kidney transplant (Hummel and Abecassis 2002). This was also noted in bone marrow transplant patients. In a study of 100 bone marrow transplants (BMT) between syngeneic identical twins, no CMV pneumonia was noted, whereas this occurred in 20 % of allogeneic pairs (Applebaum et al. 1982).

In the early transplant patients, pathologic examination of the brain showed scattered microglial nodules that were attributed to CMV encephalitis (Schober and

Herman 1973; Schneck 1965; Hotson and Pedley 1976). Inclusion-bearing cells are seen less commonly (Dorfman 1973). In patients with more severe immune suppression, for example with AIDS or transplants, ventriculitis was seen (Morgello et al. 1987).

### 3.5 *Spectrum of Neurologic CMV Disease*

CMV can affect the nervous system at all levels, from the hemispheres to the peripheral nerves, with presentations reflecting the pattern of anatomic involvement. Clinically, the patient can present with a febrile encephalopathy, myelopathy, optic neuropathy, psychosis, hallucinations, hemiplegia with headache, brainstem involvement, locked-in syndrome—the entire panoply of neurologic syndromes.

#### 3.5.1 Encephalitis

CMV encephalitis is very rare in the general population and uncommon even in the immunosuppressed. The presentations can be similar in patients with intact and suppressed immunity, but the course tends to be more severe in the latter.

In the normal host, CMV encephalitis usually occurs during primary CMV infection, as part of the systemic illness. The illness consists of headache, fever, lethargy, seizures, and focal weakness, which is typical for any viral encephalitis (Back et al. 1977; Siegman-Igra et al. 1984; Dorfman 1973; Philips et al. 1977; Chin et al. 1973; Tyler et al. 1986; Miles et al. 1993; Waris et al. 1972; Perham et al. 1971; Studahl et al. 1992). The outcome has been variable. Several patients had good recoveries, with return to work (Chin et al. 1973; Back et al. 1977; Studahl et al. 1992) while others died or became disabled (Waris et al. 1972; Dorfman 1973; Studahl et al. 1992). Two patients who were treated with vidarabine recovered (Philips et al. 1977). A pregnant patient with CMV encephalitis made a complete recovery after treatment with acyclovir. A case of systemic primary CMV infection with multiple end organ involvement, including encephalitis, resolved completely after acyclovir therapy (Khattab et al. 2009).

Other unusual presentations of CMV encephalitis have been reported in the immunocompetent population. A rare form of CMV encephalitis with opsoclonus–myoclonus, treated with ganciclovir, steroids, and immunoglobulin has been reported. The patient recovered (Zaganas et al. 2007). Recently, a “paroxysmal” form of CMV encephalitis has been reported in the literature. In this condition, neurologic deficits lasting a few hours occur and then resolve, to be repeated over a week or so. The outcome appears to be benign, irrespective of whether patients are treated with antiviral drugs (Chalaupka Devetag and Boscariolo 2000; Richert et al. 1987).

In the AIDS patient, CMV encephalitis tends to present somewhat more indolently, with the first symptoms often noted only in retrospect (Arribas et al. 1996).



There are two recognizable presentations, mirroring to some extent the pathological findings. In the first, there is a syndrome of a flat affect, confusion and disorientation, lethargy, withdrawal, and apathy, which can be difficult to distinguish from HIV dementia (Holland et al. 1994). The pathology in these cases is that of diffuse microglial nodules in the brain parenchyma. The second type of CMV encephalitis begins in the same way, but multiple cranial nerves become involved, especially with nystagmus and facial palsy (Kalayjian et al. 1993). Often the patients have hypo- or hypernatremia (probably reflecting a concurrent CMV adrenalitis or possibly diencephalic involvement). Such patients have ventriculitis on MRI, and the CSF characteristically has a neutrophilic pleocytosis with hypoglycorrhachia. I have personally seen a case of AIDS-associated CMV encephalitis in which the CSF glucose was 0 mg/dL (confirmed on repeat testing). The prognosis appears to be rather poor, with a median survival of 42 days, irrespective of whether the patients were treated with antiviral drugs (Arribas et al. 1996). More recently, an open label study of a combination of both ganciclovir and foscarnet showed a median survival of 94 days in the participants, and when two patients were put on highly active antiretroviral therapy (HAART), they were able to survive beyond the study, off anti-CMV drugs (Anduze-Fafri et al. 2000). Finally, a case of AIDS-associated CMV encephalitis appearing after HAART was instituted was reported. The CD4 T cell count was low and the HIV viral load high. Ten days later, he had a headache and the CSF showed a mild pleocytosis with a high proportion of neutrophils. CMV PCR was positive. An MRI showed enhancement of the ependyma, typical of CMV ventriculitis. He was treated with ganciclovir and foscarnet with improvement. The CSF CMV PCR became negative and his symptoms resolved. He was given valganciclovir for maintenance therapy until there was complete immune recovery, and then discontinued. He had no recurrence to a follow-up 16 months later. This was most likely an immune reconstitution inflammatory syndrome (IRIS) causing a flare up of CMV ventriculitis (Janowicz et al. 2005).

A study of the natural history of AIDS-associated CMV encephalitis in the HAART era would be very valuable.

CMV encephalitis was reported early in the transplant era and had a poor prognosis (Dorfman 1973; Schober and Herman 1973; Hotson and Pedley 1976; Schneck 1965). In transplant patients, CMV is an important cause of systemic disease and patients are often put on prophylactic or preemptive antiviral drugs such as acyclovir or ganciclovir for several months after the transplant. This has reduced systemic CMV considerably but did not completely eliminate it (Ljungman 2002). Indeed, CMV encephalitis can occur in patients already on both ganciclovir and foscarnet for CMV viremia (“preemptive” treatment) (Seo et al. 2001). This is true especially for stem cell transplant recipients, who may develop CMV encephalitis late after transplant, and seem to have a poor prognosis despite treatment with various combinations of ganciclovir, foscarnet, and cidofovir (Reddy et al. 2010). This may be in part due to the emergence of resistance mutations during prolonged prophylactic or preemptive treatment.

### 3.5.2 Polyradiculopathy and Mononeuropathy Multiplex

CMV has been implicated as a potential cause of GBS, characterized by rapidly progressively ascending flaccid weakness. In a survey of the etiologies of inflammatory neurologic disorders, two patients with GBS were shown to be linked to CMV by CMV complement fixation seroconversion and in one patient, isolation of CMV from the urine, followed by the detection of cytomegalic cells in the urine (Klemola et al. 1967). In a similar study, ten patients with GBS (one of whom had Miller-Fisher variant) were found to have CMV IgM seroconversion (Schmitz and Enders 1977).

A superficially similar syndrome has been seen in patients with advanced AIDS except that it is due to direct infection of nerve roots and peripheral nerves. It is characterized by subacutely progressive lower extremity pain and paresthesias, flaccid weakness, and urinary retention with ascending weakness, reflecting progression from polyradiculopathy to necrotizing myelopathy. CSF often shows a neutrophilic pleocytosis with hypoglycorrhachia and is positive for CMV by PCR. EMG shows denervation changes and MRI demonstrates enhancing nerve roots (Bazan et al. 1991; Talpos et al. 1991).

CMV mononeuropathy multiplex is a rare complication seen in AIDS patients, in which there is multifocal sensory and motor loss, with progression to severe painful sensorimotor neuropathy. CSF is usually positive for CMV by PCR and EMG demonstrates the typical findings of a mononeuropathy multiplex. Sometimes, demyelination is prominent (Roullet et al. 1994; Morgello and Simpson 1994).

### 3.5.3 Pathogenetic Model of CMV Infection of the Nervous System

A pathogenetic model of CMV infection of the nervous system has been proposed as a way of summarizing the evolution of the disease (Tselis and Lavi 2000). The pattern of disease involvement in the CSN is combined with the severity of infection and summarized as follows:

1. Diffuse multifocal CMV encephalitis (CVE)
  - a. Isolated inclusion-bearing cells
  - b. Microglial nodule encephalitis
  - c. Focal parenchymal necrosis
2. CMV ventriculoencephalitis
  - a. Ependymitis
  - b. Ependymitis and subependymitis
  - c. CVE with necrotizing periventricular lesions
3. CMV radiculomyelitis
  - a. CMV polyradiculitis
  - b. Necrotizing radiculomyelitis

Inspection of this pattern suggests routes of access of virus to the nervous system: through the blood–brain barrier in parenchymal blood vessels, choroid plexus, and nerve roots, respectively, with the degree of infection depending on the viral inoculum.

### **3.6 *Diagnosis***

Diagnosis of CMV encephalitis is made on the basis of a compatible clinical picture and demonstration of CMV in the CSF. This has been validated in the HIV population, and is commonly used in other immunosuppressed patients such as in transplantation. In the AIDS population, CSF viral loads correlate to some extent with the extent and severity of encephalitis (Arribas et al. 1995). In the critically ill patient, it is important to consider other diagnostic possibilities such as seizures, septic encephalopathy, and effects of medications such as cyclosporine. Serologic methods, such as increase in titers of CMV antibody, are not useful.

### **3.7 *Management***

The currently available antiviral drugs that act against CMV are ganciclovir, foscarnet, and cidofovir. These have been shown to treat CMV retinitis in AIDS patients and their use in CMV encephalitis and radiculomyelitis has been an extrapolation.

Monotherapy seems not to affect the course of AIDS-associated CMV encephalitis (Arribas et al. 1996). The use of combination therapy with ganciclovir and foscarnet is probably more effective, although not ultimately curative (Anduze-Faris et al. 2000). The dose of ganciclovir was 5 mg/kg twice a day and foscarnet 90 mg/kg twice a day for an induction period of 3–6 weeks, followed by a maintenance phase of once daily dosing for both drugs. However, both drugs are rather toxic and the patient needs to be followed closely for bone marrow suppression (ganciclovir) and nephrotoxicity (foscarnet). Cidofovir has unreliable CNS penetration, and is not recommended in the IDSA guidelines (Tunkel et al. 2008). There is preliminary evidence that immune reconstitution from HAART therapy may allow long-term survival off anti-CMV drugs. There is even less data to guide the use of these drugs in the non-AIDS population. In the normal host, CMV encephalitis is often followed by disability, although a number of patients seem to recover well without anti-CMV medications. It is reasonable to treat with these drugs and follow the patients very closely for toxicity.

### 3.8 Summary and Conclusions

EBV and CMV are human gamma and beta herpesviruses that cause universal infection, usually self-limited. However, they are occasionally the cause of severe neurological syndromes. Despite the similarity of these viruses their effects are due to very different pathogeneses, EBV is primarily immunopathogenic and thus indirectly damaging whereas CMV causes more direct lytic infection. These viruses are more dangerous in the immunosuppressed, and are of increasing interest given the use of strongly immunosuppressing and immunomodulating agents. Despite a great deal of research and knowledge, we must still turn to clinical research to understand the natural history of the disease and test therapeutic modalities.

### References

- Abul-Kasim K, Palm L, Maly P, Sundgren P (2009) Neuroanatomic localization of Epstein-Barr virus encephalitis may be a predictive factor for its clinical outcome: a case report and a review of 108 cases in 28 reports. *J Child Neurol* 24:720–726
- Adamson D, Gordon P (1992) Hemiplegia: a rare complication of acute Epstein-Barr virus (EBV) infection. *Scand J Infect Dis* 24:379–380
- Anduze-Fafri B, Fillet A, Gozlan J, Lancar R, Boukli N, Gasnault J et al (2000) Induction and maintenance therapy of CMV central nervous system infection in HIV infected patients. *AIDS* 14:517–524
- Anduze-Faris B, Fillet A, Gozlan J, Lancar R, Boukli N, Gasnault J et al (2000) Induction and maintenance therapy of CMV central nervous system infection in HIV infected patients. *AIDS* 14:517–524
- Angelini L, Bugiani M, Zibordi F, Cinque P, Bizzi A (2000) Brainstem encephalitis resulting from Epstein-Barr virus mimicking an infiltrating tumor in a child. *Pediatr Neurol* 22(2):130–132
- Applebaum F, Meyers J, Fefer A, Flourney N et al (1982) Nonbacterial nonfungal pneumonia following bone marrow transplantation in 100 identical twins. *Transplantation* 33:265–268
- Arribas J, Clifford D, Fichtenbaum C, Commons D et al (1995) Level of cytomegalovirus (CMV) DNA in cerebrospinal fluid of subjects with AIDS and CMV infection of the central nervous system. *J Infect Dis* 172:527–531
- Arribas J, Storch G, Clifford D, Tselis A (1996) Cytomegalovirus encephalitis. *Ann Int Med* 125:577–587
- Ashworth J, Motto S (1947) Infectious mononucleosis complicated by papilloretinal edema. *N Engl J Med* 237:544–545
- Back E, Hoglund C, Malmund H (1977) Cytomegalovirus infection associated with severe encephalitis. *Scand J Infect Dis* 9:141–143
- Baker F, Kotchmar G, Foshee W, Sumaya C (1983) Acute hemiplegia of childhood associated with Epstein-Barr virus infection. *Pediatr Infect Dis J* 2:136–138
- Bazan C, Jackson C, Jenkins J, Barohn R (1991) Gadolinium enhanced MRI in a case of cytomegalovirus polyradiculopathy. *Neurology* 41:1522–1523
- Bennett D, Peters H (1961) Acute cerebellar syndrome secondary to infectious mononucleosis in a fifty-two year old man. *Ann Intern Med* 55(1):147–149
- Bergen D, Grossman H (1975) Acute cerebellar ataxia of childhood associated with infectious mononucleosis. *J Pediatr* 87:832–833
- Bernstein T, Wolfe H (1950) Involvement of the nervous system in infectious mononucleosis. *Ann Intern Med* 33:1120–1138

- Biebl A, Webersinke C, Traxler B, Povysil B, Furthner D, Schmitt K (2009) Fatal Epstein-Barr virus encephalitis in a 12 year old child: an underappreciated neurological complication? *Nature Clin Pract Neurol* 5:171–174
- Blaustein A, Caccavo A (1950) Infectious mononucleosis complicated by bilateral papilloretinal edema. *Arch Ophthalmol* 43:853–856
- Bonyngne T, Van Hagen K (1952) Severe optic neuritis in infectious mononucleosis. *J Am Med Assoc* 145:933–934
- Caruso J, Tung G, Gascon G, Rogg J, Davis L, Brown W (2000) Persistent preceding focal neurologic deficits in children with Epstein-Barr encephalitis. *J Child Neurol* 15:791–796
- Chalaukpa Devetag F, Boscarolo L (2000) Cytomegalovirus meningoencephalitis with paroxysmal course in immunocompetent adults: a new nosographical entity. Clinical, diagnostic, and therapeutic correlations and pathogenetic hypothesis. *Eur Neurol* 44:242–247
- Chin W, Magoffin R, Frierson J, Lennette E (1973) Cytomegalovirus infection: a case with meningoencephalitis. *JAMA* 225:740–741
- Cleary T, Henle W, Pickering L (1980) Acute cerebellar ataxia associated with Epstein-Barr virus infection. *J Am Med Assoc* 243:148–149
- Clevenbergh R, Brohee P, Velu T, Jacobs E, Liesnard C, Deneft E, Thys J (1997) Infectious mononucleosis complicated by transverse myelitis: detection of the viral genome by polymerase chain reaction in the cerebrospinal fluid. *J Neurol* 244:592–594
- Copperman S (1977) “Alice in Wonderland” syndrome as a presenting symptom of infectious mononucleosis in children. *Clin Pediatr* 16:143–146
- Cotton P, Webb-Peploe M (1966) Acute transverse myelitis as a complication of glandular fever. *Br Med J* 1:654–655
- Dimova P, Bojinova V, Georgiev D, Milanov I (2006) Acute reversible parkinsonism in Epstein-Barr virus-related encephalitis lethargica-like illness. *Mov Disord* 21:564–566
- Dorfman L (1973) Cytomegalovirus encephalitis in adults. *Neurology* 23:136–144
- Egan R (1960) Facial diplegia in infectious mononucleosis in the absence of Landry-Guillain-Barré syndrome. *N Engl J Med* 262(23):1178–1179
- Eshel G, Eyov A, Lahat E, Brauman A (1987) Alice in Wonderland syndrome, a manifestation of acute Epstein-Barr virus infection. *Pediatr Infect Dis J* 6:68
- Foss H, Herbst H, Hummel M, Araujo I, Latza U, Rancso C, Dallenbach F, Stein H (1994) Patterns of cytokine gene expression in infectious mononucleosis. *Blood* 83:707–712
- Friedland R, Yahr M (1977) Meningoencephalopathy secondary to infectious mononucleosis unusual presentation with stupor and chorea. *Arch Neurol* 34:186–188
- Fujimoto J, Asaoka J, Imaizumi T, Ayabe M, Shoji H, Kaji M (2003) Epstein-Barr virus infection of the central nervous system. *Intern Med* 42:33–40
- Garamendi I, Montejo M, Cancelo L, Lopez L et al (2002) Encephalitis caused by Epstein-Barr virus in a renal transplant recipient. *Clin Infect Dis* 34:287–288
- Gilbert J, Culebras A (1972) Cerebellitis in infectious mononucleosis. *J Am Med Assoc* 220(5):727
- Greenberg D, Weinkle D, Aminoff M (1982) Periodic EEG complexes in infectious mononucleosis encephalitis. *J Neurol Neurosurg Psychiatry* 45:648–651
- Goodpasture E, Talbot F (1921) Concerning the nature of “protozoan-like” cells in certain lesions of infancy. *Am J Dis Child* 21:415–421
- Grose C, Feorino P (1973) Epstein-Barr virus and transverse myelitis. *Lancet* 1:892
- Grose C, Feorino P, Dye L, Rand J (1973) Bell’s palsy and infectious mononucleosis. *Lancet* 2:231–232
- Henle G, Henle W, Diehl V et al (1968) Relation of Burkitt’s tumor-associated herpes-type virus to infectious mononucleosis. *Proc Natl Acad Sci* 59:94–101
- Henle W, Henle G, Horwitz C (1974) Epstein-Barr virus specific diagnostic tests in infectious mononucleosis. *Hum Pathol* 5:551–565
- Ho M (2008) The history of cytomegalovirus and its diseases. *Med Microbiol Immunol* 197:65–73
- Hochberg F, Miller G, Schooley R, Hirsch M, Feorino P, Henle G (1983) Central nervous system lymphoma related to Epstein-Barr virus. *N Engl J Med* 309:745–748

- Holland N, Power C, Mathews V, Glass J et al (1994) CMV encephalitis in acquired immunodeficiency syndrome. *Neurology* 44:507–514
- Hotson J, Pedley T (1976) The neurological complications of cardiac transplantation. *Brain* 99:673–694
- Hummel M, Abecassis M (2002) A model for reactivation of CMV from latency. *J Clin Virol* 25:s123–s136
- Hurt C, Tammaro D (2007) Diagnostic evaluation of mononucleosis-like illness. *Amer J Med* 120:911.e911–911.e918
- Janowicz D, Johnson R, Gupta S (2005) Successful treatment of CMV ventriculitis immune reconstitution syndrome. *J Neurol Neurosurg Psychiatry* 76:691–692
- Jesionek A, Kiolemenoglou R (1904) Über einen Befund von protoenartigan. ... *Muench Med Wochenschr* 51:1905–1907
- Jones K, Rivera C, Sgadari C, Franklin J, Max E, Bhatia KG, Tosato G (1995) Infection of human endothelial cells with Epstein-Barr virus. *J Exp Med* 182:1213–1221
- Johansen A (1931) Serous meningitis and infectious mononucleosis. *Acta Med Scand* 76:269
- Kalayjian R, Cohen M, Bonomo R, Flanigan T (1993) Cytomegalovirus ventriculoencephalitis in AIDS: a syndrome with distinct clinical and pathological features. *Medicine* 72:67–77
- Khattab M, Eslam M, Abd-eelfattah E (2009) Encephalitis, acute renal failure, and acute hepatitis caused by a viral infection in an immunocompetent young adult: a case report. *J Med Case Rep* 3:9289
- Klemola E, Kaariainen L (1965) Cytomegalovirus as a possible cause of a disease resembling infectious mononucleosis. *Br Med J* 2:1099–1102
- Klemola E, Weckman N, Haltia K, Kaariainen L (1967) The Guillain-Barre syndrome associated with acquired cytomegalovirus infection. *Acta Med Scand* 181:603–607
- Kuo Y, Chiu N, Shen C et al (1998) Cerebral perfusion in children with Alice in Wonderland syndrome. *J Child Neurol* 19:105–108
- Lahat E, Berkovitch M, Barr J, Peret G, Barzilai A (1999) Abnormal visual evoked potentials in children in “Alice in Wonderland” syndrome due to infectious mononucleosis. *J Child Neurol* 14:732–735
- Larocca L, Capello D, Rinelli A, Nori S, Antinori A et al (1998) The molecular and phenotypic profile of primary central nervous system lymphoma identifies distinct categories of the disease and is consistent with histogenetic derivation from germinal center-related B-cells. *Blood* 92:1011–1019
- Lascelles R, Johnson P, Longson M, Chiang A (1973) Infectious mononucleosis presenting as acute cerebellar syndrome. *Lancet* 2:707–709
- Leavell R, Ray CG, Ferry P, Minnich LL (1986) Unusual acute neurological presentations with Epstein-Barr virus infection. *Arch Neurol* 43:186–188
- Ljungman P (2002) Beta-Herpesvirus challenges in the transplant recipient. *J Infect Dis* 186:S99–S109
- McKendall R, Sadiq S, Calverley J (1990) Unusual manifestations of Epstein-Barr virus encephalomyelitis. *Infection* 18(1):33–35
- Miles C, Hoffman W, Lai C-W, Freeman J (1993) Cytomegalovirus-associated transverse myelitis. *Neurology* 43:2143–2145
- Mischler M, Fleming G, Shanley T, Madden L, Levine J, Castle V, Filipovich A, Cornell T (2006) Epstein-Barr virus-induced hemophagocytic lymphohistiocytosis and X-linked lymphoproliferative disease: a mimicker of sepsis in the pediatric intensive care unit. *Pediatrics* 119:e1212–e1218
- Mizuno T, Takanashi Y, Onodera H et al (2003) A case of lymphomatoid granulomatosis/angiocentric immunoproliferative lesion with long clinical course and diffuse brain involvement. *J Neurol Sci* 213:67–76
- Morgello S, Simpson D (1994) Multifocal cytomegalovirus demyelinating polyneuropathy associated with AIDS. *Muscle Nerve* 17:176–182

- Morgello S, Cho E-S, Nielsen S, Devinsky O, Petito C (1987) Cytomegalovirus encephalitis in patients with acquired immunodeficiency syndrome: an autopsy study of 30 cases and a review of the literature. *Hum Pathol* 18:289–297
- Niederman J, McCollum R, Henle G, Henle W (1968) Infectious mononucleosis clinical manifestations in relation to EB virus antibodies. *JAMA* 203:139–142
- North K, de Silva L, Procopis P (1993) Brain-stem encephalitis caused by Epstein-Barr virus. *J Child Neurol* 8:40–42
- Paul J, Bunnell W (1932) The presence of heterophile antibodies in infectious mononucleosis. *Am J Med Sci* 183:191–194
- Perham T, Caul E, Clarke S, Gibson A (1971) Cytomegalovirus meningoencephalitis. *Br Med J* 2:50
- Phillips C, Fanning L, Gump D, Phillips C (1977) Cytomegalovirus encephalitis in immunologically normal adults: successful treatment with vidarabine. *JAMA* 238:2299–2300
- Phowthongkum P, Phantumchinda K, Jutivorakool K, Suankratay C (2007) Basal ganglia and brainstem encephalitis, optic neuritis, and radiculomyelitis in Epstein-Barr virus infection. *J Infect* 54:e141–e144
- Reddy S et al (2010) CMV central nervous system disease in stem-cell transplant recipients: an increasing complication of drug-resistant CMV infection and protracted immunodeficiency. *Bone Marrow Transplant* 45:979–984
- Richert J, Potoicchio S, Garagusi V, Manz H, Cohan S, Hartmann D, Johnson R (1987) Cytomegalovirus encephalitis associated with episodic neurologic deficits and OKT-8+ pleocytosis. *Neurology* 37:149–152
- Riley H Jr (1997) History of the cytomegalovirus. *South Med J* 90:184–190
- Roselli F, Russo I, Fraddosio A, Aniello M, De Mari M, Lamberti P, Livrea P, Defazio G (2006) Reversible parkinsonian syndrome associated with anti-neuronal antibodies in acute EBV encephalitis: a case report. *Parkinsonism Relat Disord* 12:257–260
- Roullet E, Assuerus V, Gozlan J, Ropert A, Said G, Baudriment M et al (1994) Cytomegalovirus multifocal neuropathy in AIDS: analysis of 15 consecutive cases. *Neurology* 44:2174–2182
- Russell J, Fisher M, Zivin J, Sullivan J, Drachman D (1985) Status epilepticus and Epstein-Barr virus encephalopathy diagnosis by modern serologic techniques. *Arch Neurol* 42:789–792
- Rowe W, Hartley J, Waterman S, Al E (1956) Cytopathogenic agent resembling human salivary gland virus recovered from tissue cultures of human adenoids. *Proc Soc Exp Biol Med* 92:418–424
- Schmahmann J (2004) Plasmapheresis improves outcome in postinfectious cerebellitis induced by Epstein-Barr virus. *Neurology* 62:1443
- Schmitz H, Enders G (1977) Cytomegalovirus as a frequent cause of Guillain Barre syndrome. *J Med Virol* 1:21–27
- Schneck E (1965) Neuropathologic features of human organ transplantation I. Probable cytomegalovirus infection. *J Neuropathol Exp Neurol* 24:415–429
- Schober R, Herman M (1973) Neuropathology of cardiac transplantation. Survey of 31 cases. *Lancet* 1:962–967
- Seo S, Regan A, Cihlar T, Lin D, Boulad F, George D, Prasad V, Kiehn T, Polsky B (2001) Cytomegalovirus ventriculoencephalitis in a bone marrow transplant recipient receiving antiviral maintenance: clinical and molecular evidence of drug resistance. *Clin Infect Dis* 33:e105–e109
- Shian W, Chi C (1994) Fatal brainstem encephalitis caused by Epstein-Barr virus. *Pediatr Radiol* 24:596–597
- Shoji H, Goto Y, Yanase Y, Sato Y, Nakashima K, Natori H, Kaji M (1983) Recurrent cerebellitis. A case report of a possible relationship with Epstein-Barr virus infection. *Kurume Med J* 30:23–26
- Siegmán-Igra Y, Michaeli D, Doron A, Weinberg M, Heilbrun Y (1984) Cytomegalovirus encephalitis in a noncompromised host. *Isr J Med Sci* 20:163–166

- Silverstein A, Steinberg G, Nathanson M (1972) Nervous system involvement in infectious mononucleosis. The heralding and/or major manifestation. *Arch Neurol* 26:353–358
- Sinzger C, Grefte A, Plachter B, Gouw A, The T, Jahn G (1995) Fibroblasts, epithelial cells and smooth muscle cells are major targets of human cytomegalovirus infection in lung and gastrointestinal tissues. *J Gen Virol* 76:741–750
- Smith M (1956) Propagation in tissue cultures of a cytopathic virus from human salivary gland virus (SGV) disease. *Proc Soc Exp Biol Med* 92:242–430
- Sprunt T, Evans F (1920) Mononuclear leucocytosis in reaction to acute infections (“infectious mononucleosis”). *Johns Hopkins Hospital Bulletin* 357:410–416
- Studahl M, Ricksten A, Sandburg T, Burgstrom T (1992) Cytomegalovirus encephalitis in four immunocompetent patients. *Lancet* 340:1045–1046
- Talpos D, Tien R, Hesselink J (1991) Magnetic resonance imaging of AIDS-related polyradiculopathy. *Neurology* 41:1996–1997
- Taylor L, Parsons-Smith G (1969) Infectious mononucleosis, deafness and facial paralysis. *J Laryngol Otol* 83:613–616
- Toorkey C, Carrigan D (1989) Immunohistochemical detection of an immediate early antigen of human cytomegalovirus in normal tissues. *J Infect Dis* 160:741–751
- Tselis A, Lavi E (2000) Cytomegalovirus in the adult nervous system. *Infectious diseases of the nervous system* LE Davis and PGE Kennedy. Butterworth–Heinemann, Boston
- Tselis A, Duman R, Storch G, Lisak R (1997) Epstein-Barr virus encephalomyelitis diagnosed by polymerase chain reaction: detection of the genome in the CSF. *Neurology* 48:1351–1355
- Tunkel A, Glaser C, Bloch K, Sejvar J, Marra C, Roos K, Hartman H, Kaplan S, Scheld W, Whitley R (2008) The management of encephalitis: clinical practice guidelines by the Infectious Diseases Society of America. *Clin Infect Dis* 47:303–327
- Tyler K, Gross R, Cascino G (1986) Unusual viral causes of transverse myelitis: hepatitis A and cytomegalovirus. *Neurology* 36:855–858
- Verma A, Brozman B (2002) Opsoclonus-myoclonus syndrome following Epstein-Barr virus infection. *Neurology* 58:1131–1132
- Von Glahn W, Pappenheimer A (1925) Intranuclear inclusions in visceral disease. *Am J Pathol* 1:445–465
- Waris E, Rasanen O, Kreis K-E, Kreis R (1972) Fatal cytomegalovirus disease in a previously healthy adult. *Scand J Infect Dis* 4:61–67
- Weinberg A, Li S, Palmer M, Tyler K (2002) Quantitative CSF PCR in Epstein-Barr virus infections of the central nervous system. *Ann Neurol* 52:543–548
- Weinberg A, Bloch K, Li S, Tang Y, Palmer M, Tyler K (2005) Dual infections of the central nervous system with Epstein-Barr virus. *J Infect Dis* 191:234–237
- Weller T, Macauley J, Craig J, Wirth P (1957) Isolation of intranuclear inclusion producing agents from infants with illnesses resembling cytomegalic inclusion disease. *Proc Soc Exp Biol Med* 94:4–12
- Weller T (1970) Cytomegalovirus. The difficult years. *J Infect Dis* 122:532–539
- Weller T (2000) Cytomegalovirus: a historical perspective. *Herpes* 7:66–69
- Wyatt J, Saxton J, Lee R, Al E (1950) Generalized cytomegalic inclusion disease. *J Pediatr* 36:271–294
- Zaganas I, Prinianakis G, Xirouchaki N, Mavridis M (2007) Opsoclonus-myoclonus syndrome associated with cytomegalovirus encephalitis. *Neurology* 68:1636
- Zaidi A, Kampalath B, Peltier W, Viesole D (2004) Successful treatment of systemic and central nervous system lymphomatoid granulomatosis with rituximab. *Leuk Lymphoma* 45:777–780



Viral Infections of the Human Nervous System

Jackson, A. (Ed.)

2013, XII, 416 p., Hardcover

ISBN: 978-3-0348-0424-0